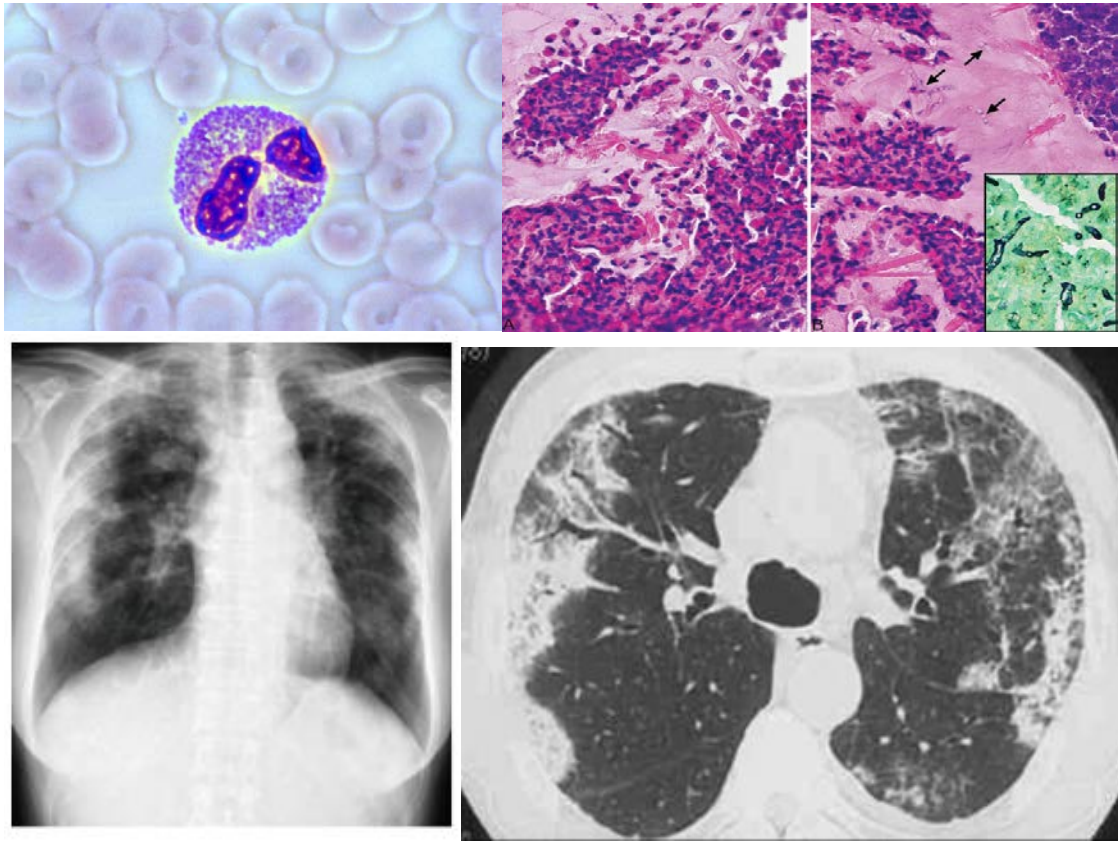

Eosinophilic Lung Disease

Internal Medicine Grand Rounds

University of Texas Southwestern Medical Center

February 10, 2017

Jonathan C Weissler MD

This is to acknowledge that Jonathan C Weissler MD has disclosed that he does not have any financial interests or other relationships with commercial concerns related directly or indirectly to this program. Dr. Weissler will not be discussing off-label uses in his presentation.

Cover: Photomicrograph of an eosinophil in peripheral blood (upper left), eosinophils in mucus in an airway of an asthmatic with bronchopulmonary aspergillosis (upper right), and the CXR and chest CT of a patient with chronic eosinophilic pneumonia.

Jonathan C Weissler MD

Professor and Vice Chair, Department of Internal Medicine

Chief of Medicine, UT Southwestern University Hospitals

Division of Pulmonary and Critical Care Medicine and Interim Chief, Division of Hospital Medicine

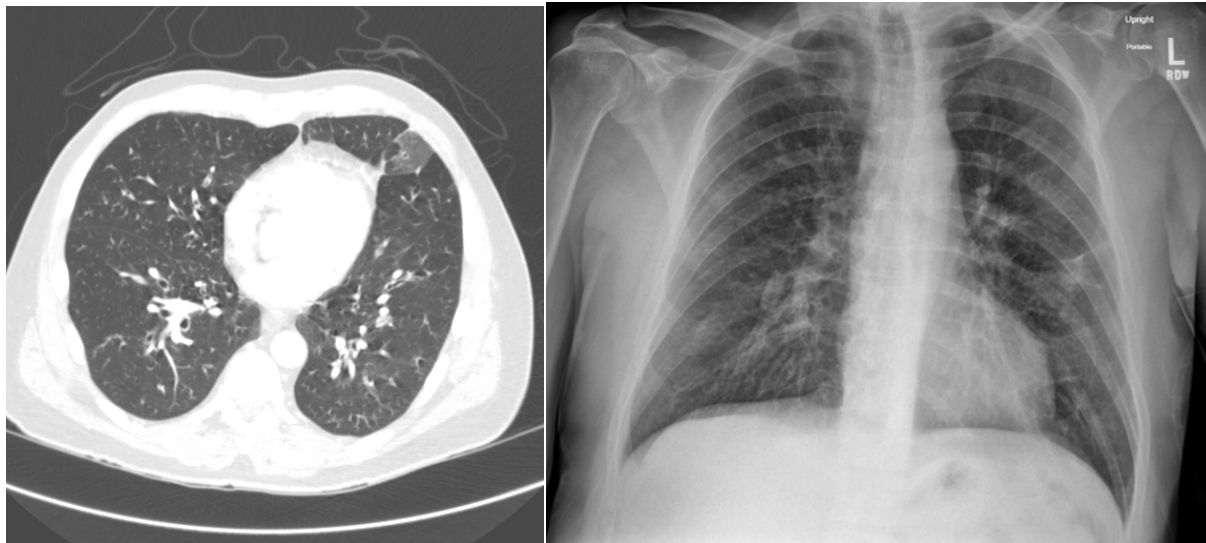
Interests: Immunobiology of the lower respiratory tract, pathogenesis of interstitial lung diseases, transcription factors for lipophilic surfactant proteins; spatial control of golf ball-sized particles.

Purpose and Overview: This presentation will focus on the role of eosinophils in a variety of lung disorders. Emphasis on the mechanisms of cytokine mediated eosinophil expansion and recruitment to the lung will be utilized to discuss newer anti-cytokine therapies being utilized in some forms of asthma. The clinical presentation and strategies for diagnosing and treating other forms of eosinophilic lung disease will be reviewed.

Educational Objectives:

1. To discuss the role of interleukin 5 (IL-5) in expanding eosinophil number, activation state, and longevity, and to understand that this is distinct from recruitment of eosinophils to specific tissues.
2. To understand the rationale for new therapies in asthma which target IL-5, IL-4 and IL-13.
3. To clinically differentiate acute and chronic eosinophilic pneumonias, and discuss drugs inducing eosinophilia.
4. To review pathogens capable of causing pulmonary eosinophilia.
5. To discuss the prognostic significance of eosinophilia in lung transplant patients.

Case: A 62 year old man had no pulmonary complaints until January 2015 when he developed productive cough and wheezing. He improved with systemic steroids but symptoms returned when switched to inhaled corticosteroids and a long acting beta agonist (fluticasone and salmeterol). Prednisone was instituted; an absolute peripheral blood eosinophil count of 1000 was noted. He was subsequently admitted to Clements University Hospital in 6/15 with worsened shortness of breath. Physical exam demonstrated both wheezing and rhonchi. Admitting laboratories revealed an absolute eosinophil count of 5500 and an IgE of 1640 (2 SD from mean=127). Although he had scattered peripheral pulmonary infiltrates a chest CT did not reveal marked bronchiectasis.



Pulmonary functions were remarkable for severe obstructive lung disease with an FEV1 of 40% predicted. Workup for ABPA (allergic bronchopulmonary aspergillosis) was negative. ANCA serologies were negative and there was no clinical evidence of vasculitis. He improved with systemic corticosteroids and was discharged. When seen in clinic in 7/15 a presumptive diagnosis of an allergic mycosis was made and a trial of itraconazole was instituted, prednisone was dropped to 10 mg/day. Peripheral eosinophil count was 100. He improved somewhat but in 11/15 had another exacerbation requiring admission. Despite being on 10-20 mg/day of prednisone his eosinophil count was 1500. He was placed on higher doses of steroids and improved, with a drop in his eosinophil count. He was continued on itraconazole and 10 mg a day of prednisone and had intermittent worsening of his symptoms over the next few months. On 10 mg/day of prednisone in 1/16 and 3/16 his absolute eosinophil count was noted to be 2000 and 1200 respectively. A change in therapy was made.

Introduction

Eosinophilic lung disease (ELD) is characterized by an abnormal accumulation of eosinophils in airways, lung parenchyma, or the alveolar space. The clinical manifestations of this disorder are diverse and range from common obstructive lung diseases such as asthma to severe restrictive diseases such as eosinophilic pneumonia. Patients may have a prior history of atopic disease in some types of ELD but not others, and the impact on gas exchange may be severe leading to hypoxic respiratory failure or mild. Conventional approach to these disorders has largely focused on the presence or absence of peripheral blood eosinophilia, however the lack of correlation between tissue and blood eosinophilia is well recognized in ELD.

One hallmark of ELD is the high responsiveness of many, but not all, of these processes to corticosteroid therapy. Recent experience with immunomodulatory therapy targeting IL-5, IL-4, and IL-13 has provided both additional options for management and further insight into the pathogenesis of eosinophil mediated lung disorders. This review will focus on current advances in eosinophil biology, the clinical manifestations of ELD, and potential utilization of anti-cytokine therapy for these disorders.

Your Basic Eosinophil

Eosinophils are terminally differentiated granulocytes arising from CD34+ precursor cells, which can develop into either eosinophils or basophils. The expression of receptors for IL-5, CCR3 (a receptor for C-C chemokines including eotaxin (CCL11), eotaxin-3 (CCL26), MCP-3 (CCL7), MCP-4 (CCL13) and RANTES(CCL5)), and CD34 (an adhesion molecule expressed in early hematopoietic and vascular tissue) commits the progenitor cell to becoming an eosinophil [1, 2]. There are few other cells which express receptors for IL-5, particularly in bone marrow (though a few basophils and B cells may express the IL-5 R alpha chain[3]), and thus IL-5 responsiveness is a key differentiating feature of eosinophils.

Integral to the growth and maturation of eosinophils in the bone marrow is the production of IL-5, GM-CSF, and IL-3 by stromal cells, mast cells, and activated T cells[4]. Similar to other cytokines which drive allergic responses, production of IL-5 is proximally driven by the transcription factor GATA-3 (GATA-binding protein 3) which induces Th2 lymphocyte differentiation while simultaneously suppressing a Th1 phenotype [5]. As opposed to neutrophils, eosinophils contain numerous intracellular granules which stain a bright red by the acidophilic dye eosin. These granules contain pre-formed cationic proteins such as major basic protein (MBP), eosinophil derived neurotoxin, eosinophil peroxidase, and eosinophil cationic protein. The highly basic properties of these cationic proteins are not only toxic to helminthic organisms but bind to negatively charged lipid bilayers in cell membranes thus producing injury to airway epithelium[4].

In contrast to other cells in the immune system which require a time consuming and complex series of signals to produce cytokines and other proteins, eosinophils may immediately release their pre-formed contents by degranulation upon the triggering of surface receptors.

Eosinophils likely function in innate immunity and express a number of pattern recognition molecules, including toll-like receptors capable of recognizing and interacting with helminthic and viral organisms, as well as some bacteria and fungi[6]. Some of these receptors also recognize damage-associated molecular patterns, which are multifaceted signals produced by necrotic or impaired tissue.

Cytokines and growth factors contained within these granules, including IL-5 GM-CSF, and eotaxin potentially provide an autocrine pathway for eosinophil chemotaxis (see below) and long term survival in tissue. Additional cytokines contained in preformed granules include IL-4, IL-13, and IL-25 which provide help to ongoing Th2 lymphocyte mediated allergic responses; eosinophils have also been demonstrated to be capable of functioning as antigen presenting cells[7] and express CD80, CD86 and CD40 which co-stimulate antigen-specific Th2 responses with Class II antigen. Collagen formation and tissue remodeling may be enhanced by release of TGF-B, and a variety of lipid mediators including platelet activating factor, leukotrienes, and prostaglandins may enhance inflammation following release.

While eosinophils are potent inflammatory cells, they may also play a role in limiting inflammation in some settings. The GI tract (with the exception of the esophagus) contains a significant population of eosinophils. Eosinophils in Peyer's patches help retain IgA producing plasma cells and assist in the maintenance of normal gut flora. Experimental models of colitis in eosinophil depleted mice show a severe pathologic lesion compared to control mice and production of anti-inflammatory lipids such as PD1 help terminate acute inflammation[8-10]. Additionally sialic acid binding receptors on eosinophils are also capable of terminating inflammation by inducing apoptosis of eosinophils[11].

Eosinophils in blood and tissue

Eosinophils leave the bone marrow, in part due to production of IL-5, and have a half-life of 8-18 hours in the peripheral circulation. Normally eosinophils account for 1-6% of circulating peripheral WBC with an absolute eosinophil count of <499 cells/uL. Of note significant data suggests that there may be wide variation in absolute eosinophil counts in the same individual within a 24 hour period [12, 13]. Additionally a number of factors may lower eosinophil counts acutely including fever, bacterial infection, and systemic corticosteroids[14].

By definition mild peripheral eosinophilia occurs with an absolute eosinophil count between 500-1500, moderate between 1500-5000, and severe eosinophilia above 5000 cells/uL . Eosinophilia in response to IL-5 is polyclonal; rarely a monoclonal population may exist in

certain myeloproliferative disorders. **Importantly while IL-5 promotes expansion of eosinophil numbers and activation it does not contribute to the trafficking of eosinophils into specific tissues.** Eosinophils are commonly found in the uterus, GI tract, and thymus in healthy individuals and are presumed to be directed by tonic antigen-specific T cell activation. However in the presence of a robust active Th2 response where IL-4 and IL-13 are produced, with the subsequent production of eotaxin and other C-C chemokines, trafficking into skin and lung occurs[15]. Up-regulation of VCAM-1 in response to these cytokines helps facilitate egress from the vascular compartment.

Migration of eosinophils into the lung is an incompletely understood process, in part because the vascular supply to different portions of the lung is distinct. The alveolar space is supplied primarily by a low pressure pulmonary arterial circulation, while the airways may be supplied by the higher pressures of systemic bronchial arteries. Some authors have speculated that recruitment into the alveolar space is largely due to the presence of chemoattractants [16] while post-capillary capture and endothelial transmigration is the mechanism of recruitment into airways[17]. The post-capillary egress into pulmonary parenchyma is in contrast to that seen in neutrophil recruitment and indeed eosinophilia in the lung is usually unaccompanied by tissue neutrophilia[18]. IL-13 may play an important role in this recruitment by increasing expression of P-selectin and VCAM1 on endothelial cells, with resultant binding through PSGL-1 and VLA-4 on activated eosinophils. There are likely multiple potential chemotaxins apart from eotaxin and other C-C chemokines which assist in eosinophil recruitment, as suggested by observations that oral antagonists to the C-C chemokines have been unimpressive in terms of reducing eosinophils in the sputum of asthmatics[19].

Once in the lung, long-term survival of eosinophils in the interstitium likely depends on IL-5, which prevents caspase release and Fas-mediated apoptosis[20]. Of note, IL-5 receptor expression is somewhat downregulated on parenchymal eosinophils and has been attributed to chronic stimulation with IL-5[21]. Additional interaction and tethering of the eosinophil to extracellular matrix also contributes to stability, though eosinophils which migrate into airway rapidly undergo apoptosis with granular contents released or recycled by macrophages[22]. Indeed the finding of MBP in lung tissue of asthmatics without concomitant significant eosinophilia suggests that inflammation and tissue damage may persist long after an eosinophilic influx.

Clinical Approach to Eosinophilic Lung Disease

How do we know when eosinophils are in the lung?

While some patients simultaneously have elevated peripheral blood eosinophils and pulmonary eosinophilia, many times there is a disparity between these compartments. In addition, some therapies (see below) which block the production of eosinophil chemotaxins and allergic mediators may lower lung eosinophil burden while concomitantly increasing serum eosinophils, presumably as the result of interfering with recruitment into the lung. Many patients with severe illness from ELD may have already received corticosteroids prior to formal evaluation, decreasing the yield of diagnostic procedures. In addition measuring eosinophils in specific lung compartments (airway, airspace, interstitium) pose different practical challenges, and prior experience with other immune cells in the lung suggest that extrapolation based on cells obtained from one lung compartment may not be representative of another[23, 24].

Much of the effort to quantitate lung eosinophil burden has been done on asthmatic populations using sputum cytology. While theoretically attractive this technique has failed to gain widespread clinical utility. Sputum eosinophilia in most clinical trials is defined by >3% of expectorated cells. Sputum must be induced and the processing of sputa in the laboratory requires a lengthy and detailed technique. When utilized in the NHLBI sponsored Asthma Clinical Research Network, induced sputum was the most expensive component of a patients evaluation other than bronchoscopy[25]. While still an important research tool in dedicated centers[26] it is not practical for routine clinical use. Attempts to utilize exhaled nitric oxide, peripheral blood eosinophils, or serum IgE as surrogate markers to predict sputum eosinophilia in asthmatics have shown only moderate correlation[27]. Better results have been obtained with serum periostin[28] though further confirmation awaits.

Bronchoscopy with either bronchoalveolar lavage (BAL) or less commonly biopsy may be helpful to quantitate the degree of eosinophilia in the alveolar space or lung tissue. Eosinophils are uncommon cells in normal alveoli; finding >10% eosinophils amongst recovered cells should be considered abnormal. In patients with eosinophilic pneumonias the degree of BAL eosinophilia has been utilized to separate acute (>25%) and chronic (>40%) eosinophilic pneumonias [29, 30].

Classification of eosinophilic lung diseases

Several different classification systems have been proposed for ELD [31-34] but none is uniformly accepted. Some ELD have known causes (helminthic infection, allergic bronchopulmonary aspergillosis (ABPA), drugs) but many do not. Some have predominantly airway involvement (asthma, certain parasitic diseases) while others involve the alveolar space disproportionately (acute and chronic eosinophilic pneumonia, hypersensitivity pneumonitis). In some cases ELD is part of a systemic process (eosinophilic granulomatosis with polyangitis,

i.e. Churg Strauss syndrome, DRESS syndrome, hypereosinophilic syndromes) while in others the lung is the primary site of disease (asthma, acute eosinophilic pneumonia). To designate processes as primary or secondary would imply a far greater understanding of disease pathogenesis than currently exists. Experience with anti-cytokine therapies which ablate eosinophilia may ultimately help to further classify diseases based on Koch's postulate. For the purposes of this review we will instead classify ELD based on whether the process is relatively common, less common, or rare. While eosinophilia may occur in the setting of other illnesses such as lung cancer, lymphoma, adrenal insufficiency, or nonspecifically in atopic patients who acquire additional disorders, only processes where eosinophils are believed pivotal to the pathogenesis of the disease will be discussed.

Common types of ELD

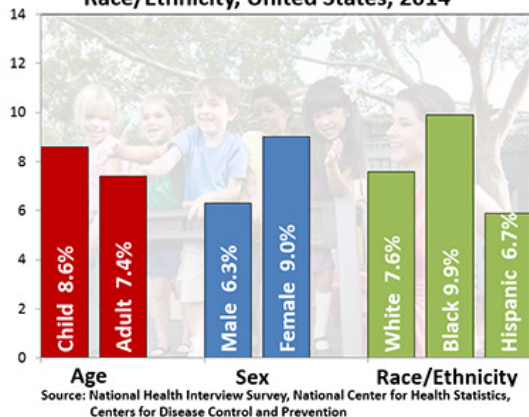
Asthma

Asthma is estimated to affect 7-8% of the US population (Figure 1)

(https://www.cdc.gov/asthma/images/2014_datagraph.jpg) and has a number of different phenotypes.

Traditionally phenotypic classification of asthma has focused on variables such as age of onset, presence of associated allergic /atopic symptoms, aspirin sensitivity, and exercise induced symptoms. Several indirect lines of evidence suggest that the presence of eosinophils in the lung is associated with poorer outcomes in asthma, including more frequent and severe exacerbations in patients with persistent eosinophilia[35, 36].

Current Asthma Prevalence Percents by Age, Sex, and Race/Ethnicity, United States, 2014



Recently attempts have been made to utilize clusters of well-defined asthma populations on whom proteomic, “metabonomic”, and genomic analysis is performed to define asthma “endotypes” (Table 1)[37].

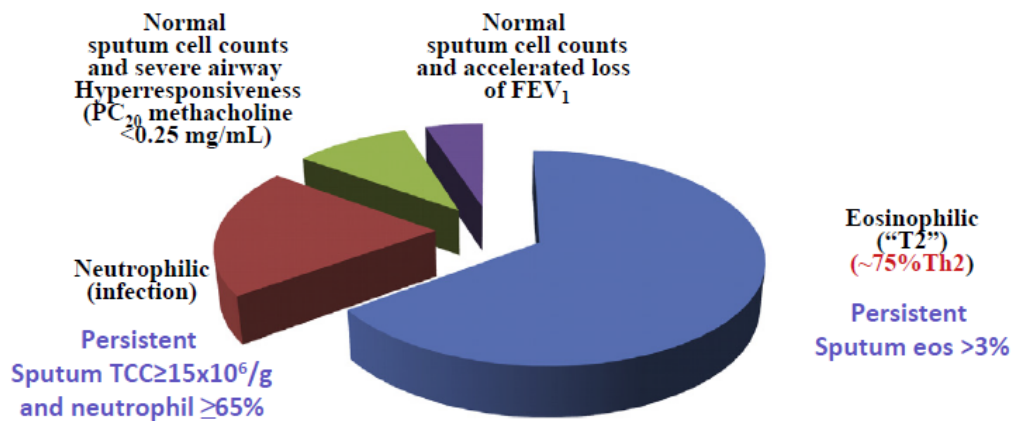
Table 1. Asthma Phenotypes Associated with Type 2 Signatures

	Age at Onset	Corticosteroid Responsiveness	IgE/Atopy	Cellular Inflammation	Additional Characteristics
Mild-moderate allergic asthma	Childhood	Good to excellent	High	Low level, corticosteroid-responsive eosinophilia	Seasonal allergic symptoms
Severe allergic asthma	Childhood	Modest to poor	High	Low level, less corticosteroid-responsive eosinophilia and neutrophilia	Fewer allergic symptoms
Highly eosinophilic (blood), despite ICS	30-40 yrs of age	Typically requires (but responds to) systemic corticosteroids	Generally low	Persistent high eosinophilia possible ILC2 involvement	Nasal polyps, sinusitis, aspirin sensitivity
Type 2 plus additional immune pathways (type 1, 17, etc.)	Middle age	Poor	Low	Persistent eosinophils	Systemic connective tissue symptoms, familial autoimmunity

Definition of abbreviations: ICS, inhaled corticosteroids; ILC2, innate lymphoid cell type 2.

This is very much a field in evolution but studies have strongly validated the presence of a late onset, less allergic, highly eosinophilic and relatively severe phenotype which is poorly responsive to inhaled corticosteroid (ICS) therapy[37, 38]. Indeed one of the seminal observations in the field of asthma was that patients with severe asthma could be divided into distinct populations based on either the absence or persistence of eosinophils on bronchial biopsy despite the use of corticosteroid therapy[39]. In addition recent studies have shown that nutritional factors may predispose to eosinophilic asthma, most notably Vitamin D. Low levels of vitamin D have been observed to correlate with asthma severity[40] and sputum eosinophilia can be reduced by supplementing Vitamin D[41]. However little data exists that Vitamin D supplementation results in significant clinical improvement.

Although many studies have tended to focus on more severe patients, it is likely that well in excess of 50% of patients with asthma in the community who are well controlled on ICS have a form of eosinophilic asthma, though only 20-25% have peripheral eosinophilia. Poorly controlled patients seen in referral because of difficult to control asthma may have more complicated patterns of inflammation, including the presence of neutrophils and Th1-type cytokines such as gamma interferon or IL-17, which is produced by its' own class of T helper cells (Figure 2)[42].



Taken together these observations suggest that an important sub classification of eosinophilic asthma is the degree of responsiveness to corticosteroid therapy. Integral to understanding asthma associated with eosinophilia therefore is a discussion of how glucocorticoids affect Th₂ inflammation. Glucocorticoids exert their impact in asthma by inducing or suppressing transcription of relevant proteins. This is accomplished predominantly by binding to a cytoplasmic glucocorticoid receptor (GR), the induction of a conformational change and subsequent migration into the nucleus where binding to cis-acting glucocorticoid-response elements occurs. Binding to both positive and negative response elements occurs, resulting in either upregulation or suppression of transcription. Suppression is often accompanied by the recruitment of histone deacetylase complexes, which effectively restores histone binding to DNA sequences rendering further transcription impossible. In addition the receptor-glucocorticoid complex in the cytoplasm may bind and retain second messengers such as NF-kappa B and prevent them from transmigration to the nucleus thus down-regulating the impact of pro-inflammatory signals.

The mechanisms of steroid resistance in asthma are multiple, but in the majority of patients is likely to be due to the presence of prolonged inflammation. GR has two RNA isoforms, designated as GR-alpha and GR-beta[43, 44]. The GR-beta isoform cannot bind glucocorticoids, inhibits nuclear translocation of the normal GR molecule, and moves to the nucleus where it competes for the binding sites of the normal GR-glucocorticoid complex. Inflammation in asthma has been reported to alter the splicing of pre-mRNA for the GC receptor, resulting in an increase in the production of the GR-beta isoform[45, 46]. Autopsies of patients with fatal asthma have increased expression of GR-beta[47]. Although the GR-beta hypothesis is compelling it is important to note that GR-beta is a highly effective suppressor of IL-5 and IL-13 genes in airway cells[48].

Attention has focused on the failure of inflamed airway cells in asthma to produce IL-10(which downregulates many Th₂-type responses and is usually induced by glucocorticoids) as an important downstream effect of excess GR-beta. Alternatively in patients with forms of severe

asthma marked by neutrophilic inflammation, steroid resistance may reflect the overall inability of glucocorticoids to impact cytokines such as IL-17 and IL-33[48, 49].

Clinically glucocorticoid resistance in asthma is usually relative, and can be overcome to some extent by higher doses of glucocorticoids. From a practical standpoint patients who require high doses of ICS (greater than 1000 ug/day fluticasone) should be considered to have evidence of steroid resistance. Equally important for the purposes of this review, patients who have continued peripheral blood or airway eosinophilia despite the use of systemic corticosteroids should be viewed as steroid resistant. The kinetics of eosinophil reduction in peripheral blood in response to corticosteroids is poorly characterized and varies with the etiology of the eosinophilia but rapid reduction within 72 hours is common; airway eosinophilia may take several weeks to show significant response to ICS. **In patients with poorly controlled asthma and continued eosinophilia despite the use of glucocorticoids it is rational to consider other therapies, and it is in these patients that newer anti-cytokine therapies are attractive.**

Anti-cytokine therapy in asthma

Anti-cytokine therapies for eosinophilic asthma are either FDA approved or in the approval process[50]. This is a significant accomplishment as early experience with anti-IL-5 therapy for asthma was disappointing and led to questions about the value of this approach[51-53] It was subsequently realized that anti-IL-5 therapy was solely of value in patients with peripheral eosinophilia who were poorly controlled on high doses of ICS with supplemental long acting beta agonists[54, 55]. Efficacy of therapy correlated with the degree of peripheral blood eosinophilia[56], and thus obviated the need for assessment of lung eosinophilia in these patients. Several agents are available for potential therapy.

Anti-IL-5 agents

Mepolizumab

Mepolizumab (MPZ), which is marketed as *Nucala* was approved by the FDA in 2015 and is a humanized monoclonal IgG1 antibody which binds to IL-5 and prevents binding to the IL-5 receptor. MPZ is administered subcutaneously every 4 weeks and has a biologic half-life of approximately 20 days. The kinetics of eosinophil depletion is somewhat slower than other agents, with a peak effect seen at 4 weeks on peripheral blood eosinophils. Reduction of tissue or sputum eosinophils is less dramatic; a 52% median reduction bone marrow eosinophils[57] and approximately 55% reduction in lung eosinophils[58] have been reported (Figure 3) .

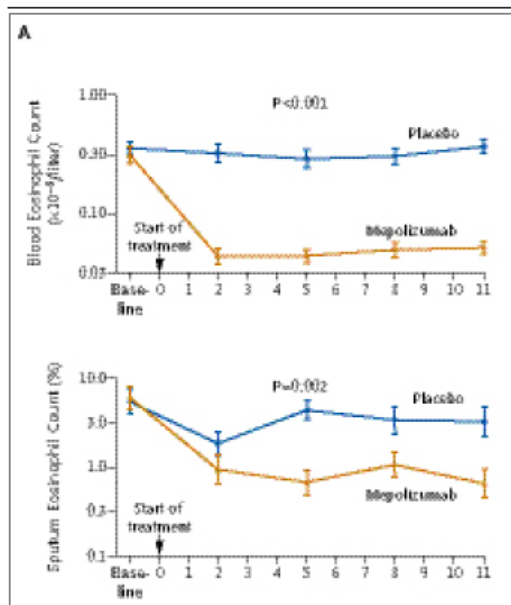


Figure 3 Mepoluzimab had a greater impact on blood vs sputum eosinophils[58]

In a 621 patient clinical trial (DREAM) patients with a peripheral eosinophil count of 300/ul or greater were randomized to MPZ or placebo. The annual number of clinically significant exacerbations was reduced by 48% and this was accompanied by a 78% reduction in blood eosinophils[54]. A subsequent trial (MENSA) demonstrated improvement in FEV1 and severity of illness scores[55]. Reduction of exacerbation rates with MPZ increased from 52% in patients with lower eosinophil counts to 70% in those with eosinophil counts above 500 cels/ul[56].

Reslizumab

Reslizumab (RLZ), which is marketed as *Cinqair* is a humanized rat anti IL-5 monoclonal antibody of IgG4 subtype and was approved by the FDA in May 2016. In contrast to MPZ this drug must be administered by intravenous infusion. Data with RLZ is somewhat better than that reported with MPZ in terms of a 54% reduction in exacerbations and a clearer impact on severity of illness scores and FEV1[59, 60]. However this may reflect the enrollment of patients with somewhat higher baseline eosinophil counts than in the MPZ trials, as benefit with RLZ is also correlated with extent of peripheral blood eosinophilia[61]. RLZ appears to have a quicker onset of action in terms of depleting eosinophils from peripheral circulation.

Benralizumab

Benralizumab (BEZ), which is not yet FDA approved, has important differences from both MPZ and RLZ. This humanized IgG1 monoclonal antibody binds not to IL-5, but rather to the alpha

chain of the IL-5 receptor on eosinophils. As such it can mediate antibody dependent cellular cytotoxicity of eosinophils (and basophils) and is markedly more effective at depleting tissue eosinophils (greater than 90%)[62], with natural killer cells playing an integral role in this process. Importantly apoptosis of eosinophils induced by BEZ does not provoke eosinophils to degranulate, reducing the potential damage which could occur during apoptosis[63]. Administered either intravenously or subcutaneously, a single dose of BEZ depleted serum eosinophils for almost 3 months. Nevertheless subcutaneous dosing in most clinical trials has occurred monthly for the first few months and then every 8 weeks[64]; regimens of every 8 weeks appear equivalent to every 4 weeks[65]. A 60-66% reduction in annual exacerbation rates, as well as significant improvements in lung function and symptom score have been demonstrated in these trials. Whether the superior depletion of eosinophils in tissue translates into improved efficacy over competing agents for eosinophilic asthma is yet to be determined.

While the anti-IL-5 therapies are a significant advance, their utility is not uniform even in patients with eosinophilic asthma. Additionally patients with poorly controlled asthma without peripheral eosinophilia are not suitable candidates for therapy. In some of these patients alternative mechanisms of Th2 inflammation likely exist and indeed this concept is supported by recent experience with agents targeting IL-4 and IL-13.

Anti-IL-13 and IL-4 agents

IL-13 enhances a variety of processes in asthma including smooth muscle contraction, airway hyper-responsiveness, and goblet cell hyperplasia[66]. In conjunction with IL-4, IL-13 induces IgE production, and is responsible for generation of C-C chemokines capable of recruiting eosinophils to sites of disease. **Importantly the receptors for IL-4 and IL-13 share the same alpha chain.** While antibodies directed against either cytokine would affect only that cytokine, an antibody directed against the alpha chain of the IL-4 and IL-13 receptor would impact both. Two antibodies have been developed against IL-13 for clinical use, tralokinumab and lebrikizumab. Clinical results with these agents have been uneven[50]. In contrast dupilumab, which targets the IL-4/IL-13 receptor alpha subunit has exhibited significant activity in both eosinophilic and non-eosinophilic asthma.

Dupilumab

Dupilumab (DPB) is a fully human IgG4 monoclonal antibody directed against the IL-4 R-alpha subunit, and blocks both IL-4 and IL-13 mediated processes[67]. This agent, which will be evaluated for FDA approval in early 2017, has resulted in significant improvement in asthma

control, airflow, and symptom improvement in patients with asthma poorly controlled by traditional therapy. This has occurred in patients regardless of the presence of baseline peripheral blood eosinophilia. Indeed similar to experience with the anti-IL-13 agents[68], DPB results in an increase in peripheral blood eosinophils while simultaneously improving asthma control. This would be consistent with the inhibition of the C-C chemokine family and blockade of recruitment into lung[69].

Optimal utilization of anti-cytokine therapies for asthma (both eosinophilic and non-eosinophilic) remain to be determined. It is clear that such drugs should be reserved for patients with poorly controlled asthma, despite otherwise maximal therapy. The safety profiles of all the above agents to date have appeared acceptable. While DPB appears to work on a broader population of asthmatics, it in theory could impact broader humoral immunity and might ultimately have a different risk profile. There will likely be a role for both DPB and the anti-IL-5 agents going forward.

Allergic fungal airway disease

The development of an IgE-mediated allergic response to filamentous fungi such as *Aspergillus fumigatus*, *Penicillium* species, other fungi and occasionally yeast is among the more common types of ELD. Usually associated with asthma, the disease can also occur frequently in cystic fibrosis[70] and occasionally in COPD[71]. Allergic bronchopulmonary aspergillosis (ABPA) is estimated to occur in 1-2% of patients with persistent asthma, and much higher in patients with difficult to treat asthma[72]. Allergy to other fungi, designated as allergic bronchopulmonary mycosis (ABPM) is less common and is often suggested by clinical features of ABPA without evidence of the presence of aspergillus.

ABPA may be seen in 2-9% of patients with cystic fibrosis. Airway eosinophilia in the form of dense, impacted mucoid conglomerates of inflammatory cells, products of eosinophil degranulation such as Charcot-Leiden crystals, and fungi often obstruct airways and lead to the development of central bronchiectasis. Areas of eosinophilic pneumonia may occur; the development of bronchocentric granuloma is often observed, leading to mass like consolidation.

Production of IL-5, IL-4 and IL-13 has been described in both blood and lung tissue in ABPA[73]. Characteristically peripheral blood eosinophilia is observed, as is an IgE of >1000 IU/ml. However many times the diagnosis is clouded by recent systemic corticosteroid therapy which lowers both eosinophil count and IgE. Recent criteria for diagnosing ABPA[74] have stressed that patients must either have asthma or CF as an underlying condition with aspergillus skin test positivity AND an IgE of >1000. Additional confirmatory criteria include an eosinophil count

>500 cells/ul, precipitating antibodies to *A.fumigatus*, and a chest radiograph consistent with ABPA.

Treatment of allergic mycosis usually requires a prolonged course of systemic corticosteroids[75]. Many patients can be successfully weaned either completely or to low doses of corticosteroids by the use of anti-fungal therapy. Both itraconazole and voriconazole have demonstrated efficacy, though the timing and duration of this intervention remain an area of contention [76-78]. Some experience with omalizumab, the humanized monoclonal antibody to IgE marketed as Xolair, has suggested that this may also be a valuable therapy[79, 80]. However the use of omalizumab (whose dose must be titrated based on degree of IgE elevation) in patients with markedly elevated IgE may be impractical. No direct data regarding the efficacy of anti-cytokine therapy for ABPA/ABPM yet exists.

Less Common types of ELD

Idiopathic Eosinophilic Pneumonias

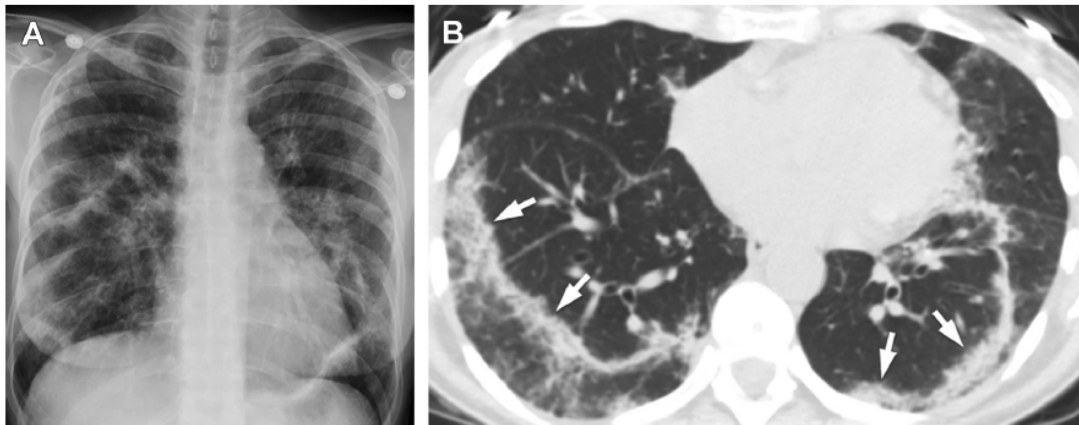
Idiopathic eosinophilic pneumonias are uncommon disorders, and can be divided into chronic and acute presentations (Table 2). Chronic eosinophilic pneumonia (CEP) is estimated to account for 1- 3% of interstitial lung disease and is associated with marked tissue and peripheral blood eosinophilia[30, 31]. More frequent in women by a 2:1 predominance, nonsmokers, and patients with a prior history of asthma and atopy, CEP usually produces subtle and progressive respiratory symptoms without producing respiratory failure. Blood eosinophils may exceed several thousand, and BAL eosinophils are usually above 40% of total cells. IL-5 levels are elevated in both serum and BAL, but do not necessarily correlate with the degree of

eosinophilia in lung[81].

Acute vs. chronic eosinophilic pneumonia		
	AEP	CEP
Etiology	Unknown, though associated with environmental exposures	Unknown, though associated with environmental exposures
Presentation	Acute symptoms which progress rapidly	Subacute, milder symptoms
Sex	Male predominance 2:1	Female predominance 2:1
Risk	Higher incidence in smokers	Higher incidence in nonsmokers
Labs	Normal eosinophil count to mild/moderate peripheral eosinophilia	Leukocytosis, peripheral eosinophilia (absolute eosinophil count >1000 cells/ μ L)
BAL	>25 % eosinophils	>40 % eosinophils
Imaging	Diffuse hazy infiltrates on chest imaging	Bilateral, dense multifocal consolidation on chest imaging
Course	Rapid progression to acute respiratory failure	Indolent course which may be relapsing and remitting, without respiratory failure
Atopy	Asthma does not predispose individual	Asthma predisposes individual
Management	Systemic corticosteroids	Systemic corticosteroids

Table 2 [1]

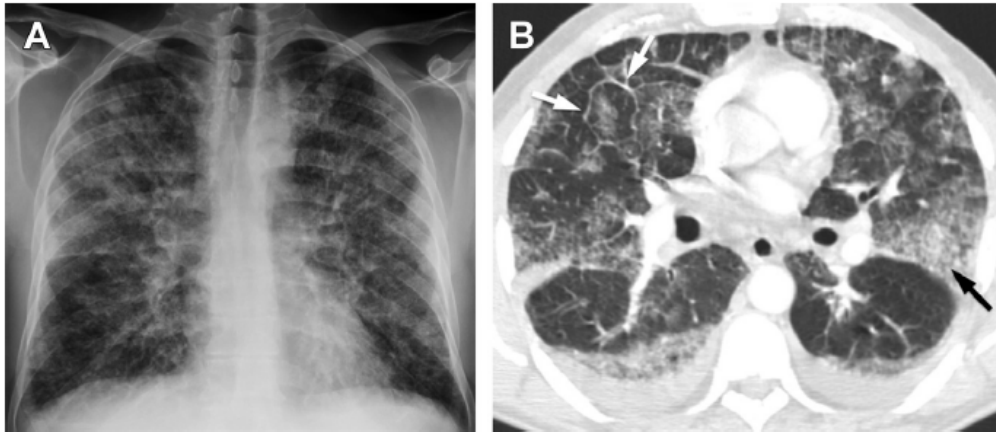
Chest imaging is often helpful, though the “characteristic” finding of dense peripheral infiltrates, which has been described as a photographic negative of pulmonary edema, occurs less than 50% of the time [82, 83]. Importantly biopsy of CEP may show evidence of other lung processes such as idiopathic organizing pneumonia (BOOP or COP) not usually associated with eosinophilia.



Chronic eosinophilic pneumonia[83]

Acute eosinophilic pneumonia (AEP) is an exceedingly rare process which causes respiratory failure and largely mimics ARDS clinically. AEP is more common in men, active smokers, and those without a prior history of atopy. At times it has been reported in clusters, such as among

military personnel in Iraq[29] and at the fallen World Trade Center[84], suggesting an inhalational toxin. Eosinophils are present in BAL but somewhat lower than in CEP; serum eosinophilia is usually absent on presentation but may develop during the course of the illness. IL-5 levels in BAL have been reported to be higher in AEP than CEP, despite the lower level of eosinophilia.



Acute eosinophilic pneumonia[83]

Response to corticosteroids is usually seen in both CEP and AEP. It is likely that empiric use of corticosteroids prior to bronchoscopy may lead to the under-diagnosis of AEP in some patients with refractory respiratory failure.

Drug-Induced ELD

Currently the drug induced respiratory disease website www.pneumotox.com lists 173 drugs capable of causing ELD. Common medications which may induce pulmonary disease associated with either peripheral blood or lung eosinophilia include all non-steroidal anti-inflammatory drugs (NSAIDs) including aspirin, several antidepressants including fluoxetine, amiodarone, anticonvulsants such as phenytoin and carbamazepine. Common antibiotics to cause ELD include dapsone, minocycline, daptomycin, ampicillin, and nitrofurantoin.

Medications associated with eosinophilic pneumonia

Antibiotics

- Nitrofurantoin
- Daptomycin
- Dapsone
- Minocycline

NSAIDs (Cardiovascular medications)

- Amiodarone
- ACE inhibitor
- β -Blocker

Antidepressants

- Amitriptyline
- Velafaxine
- Fluoxetine

Anticonvulsants

- Phenytoin
- Carbamazepine

Others

- Mesalazine

Abbreviations: ACE, angiotensin converting enzyme; NSAIDs, nonsteroidal anti-inflammatory drugs.

Data from Bonniaud Ph, Baudouin N, Fanton A, et al. The drug-induced respiratory disease website. Dijon (France): Department of Pulmonary Medicine and Intensive Care University Hospital; 2016. Available at: <http://www.pneumotox.com/>.

[83]

The DRESS syndrome (drug rash with eosinophilia and systemic syndromes) is clearly associated with ELD, though involvement of other organs is believed to be more common. Patients usually have rash, fever, lymphadenopathy and may have profound facial edema. The incidence of ELD varies with the causative agent; 33% of patients with minocycline induced DRESS had evidence of ELD while only 10% of those with DRESS due to abacavir were thought to have ELD[85-87]. Because of the delayed onset of symptoms in DRESS, which can range from several weeks to months, a detailed past history of medication use is necessary in all patients with clinical evidence of ELD. While pulmonary infiltrates on chest x-ray may be clearly appreciated in DRESS associated with some drugs such as minocycline, other forms of DRESS may have nonspecific abnormalities[88]. DRESS producing ELD has been reported to respond well to systemic corticosteroids.

Other toxins/hypersensitivity processes

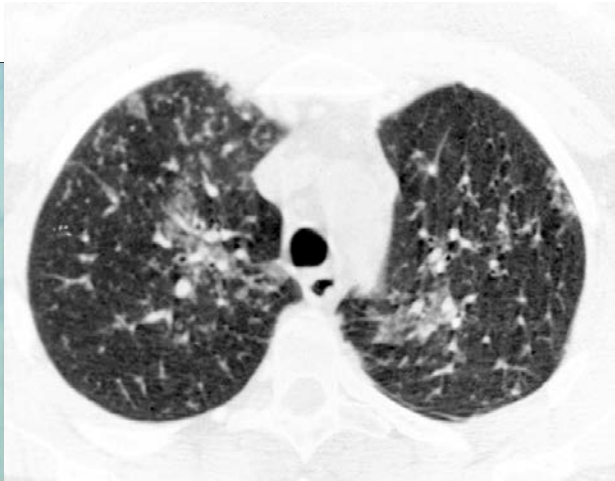
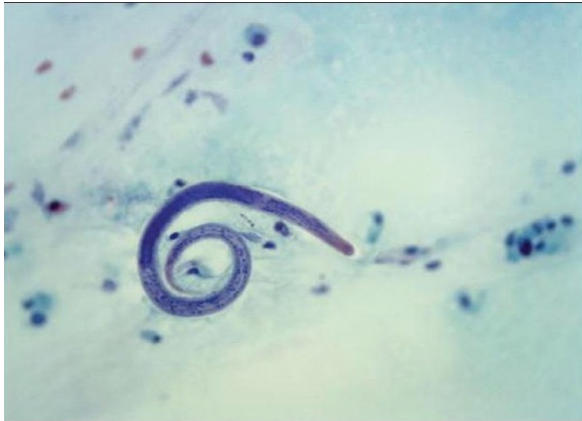There have been a number of outbreaks of toxin-induced pulmonary eosinophilic diseases reported. The largest was the “toxic oil syndrome” in Spain in 1981 due to ingestion of rapeseed oil contaminated with aniline[89]. The eosinophilic-myalgia syndrome recognized in 1989, produced by L-tryptophan ingestion was reported to have evidence of ELD in 17% of patients[90]. Metals, including aluminum, sulfites, crack cocaine, heroin inhalation, scorpion stings, and inhalation of *Scotchgard* have all been associated with ELD[34, 91-93].

Avoidance of the causative agent is the primary therapy.

Parasitic Disease

A number of helminthic infections are capable of producing ELD with the clinical spectrum varying depending on the route of entry into the lung and the life cycle of the organism[94]. The classic description of Loeffler syndrome, characterized by fleeting pulmonary infiltrate, cough, peripheral and sputum eosinophilia was described in infection with *Ascaris lumbricoides* acquired through transmission from infected human stool. The life cycle of *Ascaris* is similar to *Strongyloides stercoralis*, and the hookworms *Ancylostoma duodenale* and *Necator americanus*, in that transmission to the lung occurs hematogenously, with penetration into the alveolar space where they mature, before ascending the airway and then are swallowed/descend into the GI tract. Patients with strongyloides infection in the GI tract characteristically have profound watery diarrhea. Diagnosis is usually not made from stool culture during the period of pulmonary involvement alone and requires identification of the organisms on bronchoscopy or in respiratory secretions. Presenting symptoms may be either asthma, or dyspnea associated with infiltrates mimicking an idiopathic eosinophilic pneumonia.

Specific testing for IgG directed against *strongyloides* is often positive. *Strongyloides* in particular may have a latent period lasting years before the onset of symptoms. Varying degrees of peripheral eosinophilia may be present. Immunosuppression, particularly with steroids, may result in evidence of hyperinfection and can result in fatalities. Often in the US, patients who have received ablative chemotherapy and are cytopenic may NOT demonstrate peripheral eosinophilia. Nodular infiltrates, which may produce large masses are common.



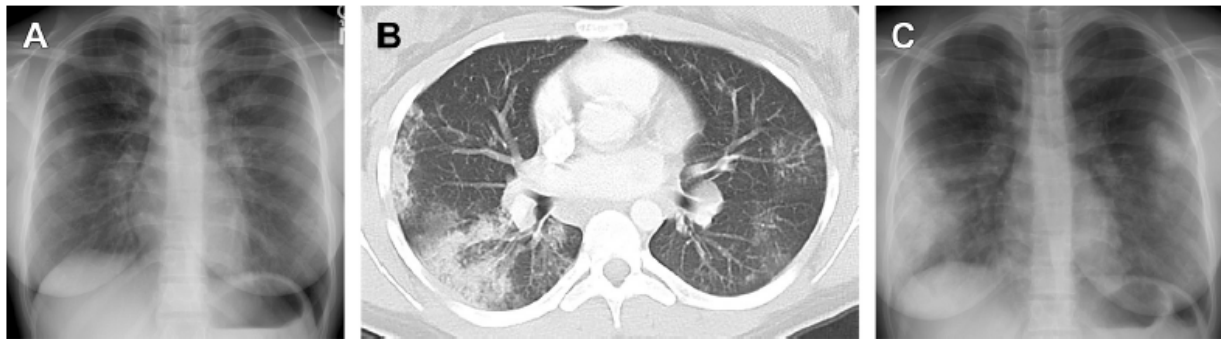
Strongyloides in BAL and CT of patient with *strongyloides*

The syndrome of tropical pulmonary eosinophilia (TPE) is caused by an eosinophilic response to filarial nematodes or roundworms that may infect bloodstream or lymphatics. TPE occurs in tropical areas, particularly the Indian subcontinent. Only a minority (<1%) of individuals infected with lymphatic filarial organisms develop TPE[95]. Three species of filaria, *Wuchereria bancrofti*, *Brugia malayi*, and *Brugia timori*, are associated with TPE and are transmitted by mosquitoes. Symptoms include a dry persistent cough, wheezing, and dyspnea. Eosinophilia is usually marked in TPE which helps distinguish it from *strongyloides*, with peripheral eosinophils above 3000 cells/ul and a dramatic eosinophilia in BAL. Production of eotaxin, IL-5, and IL-4 in the lungs has been demonstrated. Chest radiograph may be normal in a third of patients, others may have increased interstitial markings. Cases usually occur in endemic areas, but have been reported amongst immigrants in Canada[96]. Fibrosis may result from longstanding unrecognized infection.

Other nematodes may induce pulmonary disease and eosinophilia not as a result of life cycle but rather through direct invasion. *Paragonimus* lung flukes may produce a radiographic pattern of lower lobe nodules, cavitation and a syndrome of hemoptysis[97]. Blood eosinophilia occurs only in the early stages of disease. Cestodes such as *echinococcus* and *taenia solium* may produce eosinophilia following rupture of lung cysts[98]. Occasionally *schistosomiasis* can produce ELD in the early stages of infection or following treatment in patients with portal hypertension[99]. Rarely *trichinella* can produce ELD in the setting of overwhelming organism load.

Primary hyper-eosinophilic syndromes and eosinophilic granulomatosis with polyangitis

These two entities are often viewed as distinct, but recent opinion has suggested that they are part of the same spectrum [100]. Hypereosinophilic syndrome (HES) and eosinophilic granulomatosis with polyangitis (EGPA, previously known as Churg-Strauss) are characterized by marked peripheral eosinophilia with invasion of eosinophils into distant organs. Primary HES often involves heart, GI tract, brain, and kidneys[101] in addition to lung[102]. Peripheral eosinophilia greater than 1500 cells/ul for several months is usually required for diagnosis. Symptoms of pulmonary involvement include cough and dyspnea, and are present in 25% of patients at presentation[103]. Radiographic abnormalities are often migratory, but may include lower lung field nodules with a ground glass halo on CT scan[83].



Progression of pulmonary opacities in a 32 year old woman with HES at presentation (A&B) and 2 weeks later[83]

EGPA is classically considered a small vessel necrotizing vasculitis, but it is clear that a significant number of patients with EGPA lack clinical evidence of a vasculitis. An analysis of 157 patients in Europe with a diagnosis of EGPA found that only 41% of patients had proven or suspected vasculitis. While often considered as one of the ANCA-positive vasculitides, only 53% of the EGPA patients with a diagnosis of vasculitis had a positive ANCA. The presence of mononeuritis multiplex and pANCA positivity were independently associated with a higher incidence of vasculitis. Patients with polyangitis (defined as definite vasculitis, strong surrogate of vasculitis, mononeuritis multiplex and/or ANCA positivity with at least one non respiratory systemic manifestation) comprised just 59% of patients with a diagnosis of EGPA. The remainder blended into a primary HES like phenotype with asthma, eosinophilia, and an increased incidence of cardiac involvement [100]. The American College of Rheumatology criteria for diagnosing EGPA include asthma (which is usually late onset), hyperplastic sinusitis, eosinophilia (>10%), pulmonary infiltrates, mono or poly-neuropathy, and evidence of extravascular eosinophils on biopsy. 4 out of 6 criteria yields a sensitivity of 85% and a specificity of 99% for diagnosing EGPA[104].

Radiographically EGPA usually has nonspecific consolidation and more rarely distinct nodules. Lung biopsy may find an eosinophilic vasculitis of small arteries and veins, interstitial and perivascular necrotizing granulomas, or simply a nonspecific eosinophilic infiltrate. The constellation of severe asthma, paranasal sinusitis, and peripheral eosinophils >1500 cells/ul should raise the possibility of EGPA. EGPA may be unmasked in these patients by withdrawal of systemic corticosteroids; virtually all common asthma therapies (leukotriene modifiers, ICS) which prompt a discontinuation of systemic steroids have been reported to induce a *forme fruste* version of EGPA.

Both HES and EGPA respond to systemic corticosteroids. HES in particular may be an attractive target for anti-cytokine therapies. Patients with ANCA positive EGPA and overt vasculitis are usually treated with agents used for other ANCA-positive vasculitides.

Rare causes of ELD

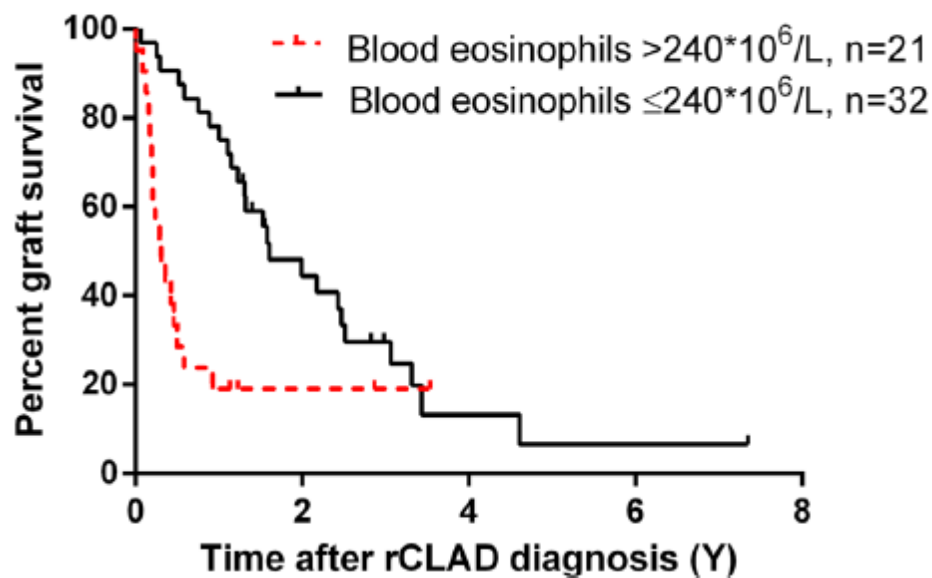
Heiner Syndrome

This rare disorder initially tied to ingestion of cow's milk is accompanied by pulmonary hemosiderosis, wheezing, iron deficiency anemia, and peripheral eosinophilia. Soy, egg, and pork have also been reported to cause this syndrome. The disease is primarily described in infants[105].

Lung Transplantation

Chronic rejection occurring in lung allografts can be characterized physiologically into obstructive processes (such as chronic bronchiolitis obliterans) and restrictive chronic lung allograft dysfunction (rCLAD). Approximately 30% of patients with chronic rejection have the rCLAD phenotype[106]. In a retrospective analysis of BAL following transplant, 66/319 patients demonstrated a BAL eosinophil count >2%. Patients with BAL eosinophilia demonstrated worse overall survival and rejection-free survival[107].

More recently [108], 53 patients with rCLAD in two transplant centers were analyzed for the importance of eosinophils and other cells as prognostic markers. Mean peripheral blood eosinophil count was 330 cells/ul at the time of rCLAD diagnosis. Elevated blood eosinophil count was associated with worse survival and a blood eosinophil count (>240) had a 71% sensitivity and 86% specificity to predict 1 year survival. The peripheral blood eosinophilia highly correlated with BAL eosinophilia in these patients.



The etiology of the eosinophilia is unclear; 9/53 patients with rCLAD had a diagnosis of cystic fibrosis, raising the possibility of aspergillus-mediated eosinophilia. Regardless of the cause, peripheral blood and BAL eosinophilia appear to connote a worse outcome after transplant.

Our Patient

On 3/1/16 the patient was noted to have an absolute eosinophil count of 1280 cells/ul and 2 weeks later was started on anti-IL5 therapy with mepoluzimab (Nucala). He was weaned off systemic corticosteroids and itraconazole, but continued on ICS/LABA. Subsequent eosinophil counts have been <200. As of January 2017 he has not had an exacerbation since the institution of MPZ, has not used his rescue albuterol in months, and denies any history of wheezing.

Summary

Eosinophilic lung disease has many different clinical presentations and is either idiopathic, due to readily identifiable causes, or difficult to characterize. New anti-cytokine therapies for ELD are likely to change the management of some of these disorders in patients who are poorly responsive to corticosteroids. **ELD should be suspected in patients with reactive airway disease or a pneumonic process and:**

Peripheral blood eosinophils >500/ul, or eosinophils >250 cells/ul in patients on 10 mg/day of prednisone or higher.

Peripheral infiltrates on CT or CXR

Eosinophilia and recent medication change or history of travel to endemic areas for helminthic organisms

BIBLIOGRAPHY

1. Eng, S.S. and M.L. DeFelice, *The Role and Immunobiology of Eosinophils in the Respiratory System: a Comprehensive Review*. Clinical Reviews in Allergy & Immunology, 2016. **50**(2): p. 140-158.
2. Valent, P., et al., *Contemporary consensus proposal on criteria and classification of eosinophilic disorders and related syndromes*. Journal of Allergy and Clinical Immunology, 2012. **130**(3): p. 607-612.e9.
3. Kolbeck, R., et al., *MEDI-563, a humanized anti-IL-5 receptor α mAb with enhanced antibody-dependent cell-mediated cytotoxicity function*. Journal of Allergy and Clinical Immunology, 2010. **125**(6): p. 1344-1353.e2.
4. Long, H., et al., *A Player and Coordinator: The Versatile Roles of Eosinophils in the Immune System*. Transfusion Medicine and Hemotherapy, 2016. **43**(2): p. 96-108.
5. Yagi, R., J. Zhu, and W.E. Paul, *An updated view on transcription factor GATA3-mediated regulation of Th1 and Th2 cell differentiation*. International Immunology, 2011. **23**(7): p. 415-420.
6. Kvarnhammar, A.M. and L.O. Cardell, *Pattern-recognition receptors in human eosinophils*. Immunology, 2012. **136**(1): p. 11-20.
7. Walsh, E.R., et al., *Strain-specific requirement for eosinophils in the recruitment of T cells to the lung during the development of allergic asthma*. The Journal of Experimental Medicine, 2008. **205**(6): p. 1285-1292.
8. Chu, Van T., et al., *Eosinophils Promote Generation and Maintenance of Immunoglobulin-A-Expressing Plasma Cells and Contribute to Gut Immune Homeostasis*. Immunity, 2014. **40**(4): p. 582-593.
9. Masterson, J.C., et al., *Eosinophil-mediated signalling attenuates inflammatory responses in experimental colitis*. Gut, 2015. **64**(8): p. 1236-1247.
10. Yamada, T., et al., *Eosinophils promote resolution of acute peritonitis by producing proresolving mediators in mice*. The FASEB Journal, 2011. **25**(2): p. 561-568.
11. Nutku, E., et al., *Ligation of Siglec-8: a selective mechanism for induction of human eosinophil apoptosis*. Blood, 2003. **101**(12): p. 5014-5020.
12. Spector, S.L. and R.A. Tan, *Is a Single Blood Eosinophil Count a Reliable Marker for "Eosinophilic Asthma?"*. Journal of Asthma, 2012. **49**(8): p. 807-810.
13. Sennels, H.P., et al., *Diurnal variation of hematology parameters in healthy young males: The Bispebjerg study of diurnal variations*. Scandinavian Journal of Clinical and Laboratory Investigation, 2011. **71**(7): p. 532-541.
14. Roufosse, F. and P.F. Weller, *Practical approach to the patient with hypereosinophilia*. The Journal of allergy and clinical immunology, 2010. **126**(1): p. 39-44.
15. Ying, S., et al., *Eosinophil Chemotactic Chemokines (Eotaxin, Eotaxin-2, RANTES, Monocyte Chemoattractant Protein-3 (MCP-3), and MCP-4), and C-C Chemokine Receptor 3 Expression in Bronchial Biopsies from Atopic and Nonatopic (Intrinsic) Asthmatics*. The Journal of Immunology, 1999. **163**(11): p. 6321-6329.
16. Wardlaw, A.J., *Molecular basis for selective eosinophil trafficking in asthma: A multistep paradigm*. Journal of Allergy and Clinical Immunology, 1999. **104**(5): p. 917-926.
17. Woolnough, K. and A.J. Wardlaw, *Eosinophilia in Pulmonary Disorders*. Immunology and Allergy Clinics of North America, 2015. **35**(3): p. 477-492.

18. Woltmann, G., et al., *Interleukin-13 induces PSGL-1/P-selectin-dependent adhesion of eosinophils, but not neutrophils, to human umbilical vein endothelial cells under flow*. *Blood*, 2000. **95**(10): p. 3146-3152.
19. Neighbour, H., et al., *Safety and efficacy of an oral CCR3 antagonist in patients with asthma and eosinophilic bronchitis: a randomized, placebo-controlled clinical trial*. *Clinical & Experimental Allergy*, 2014. **44**(4): p. 508-516.
20. Dewson, G., G.M. Cohen, and A.J. Wardlaw, *Interleukin-5 inhibits translocation of Bax to the mitochondria, cytochrome c release, and activation of caspases in human eosinophils*. *Blood*, 2001. **98**(7): p. 2239-2247.
21. Gregory, B., et al., *Differential Regulation of Human Eosinophil IL-3, IL-5, and GM-CSF Receptor α -Chain Expression by Cytokines: IL-3, IL-5, and GM-CSF Down-Regulate IL-5 Receptor α Expression with Loss of IL-5 Responsiveness, but Up-Regulate IL-3 Receptor α Expression*. *The Journal of Immunology*, 2003. **170**(11): p. 5359-5366.
22. Muessel, M.J., et al., *CCL11 and GM-CSF Differentially Use the Rho GTPase Pathway to Regulate Motility of Human Eosinophils in a Three-Dimensional Microenvironment*. *The Journal of Immunology*, 2008. **180**(12): p. 8354-8360.
23. Weissler, J.C., et al., *Human Pulmonary Macrophages: Functional comparison of cells obtained from whole lung and by bronchoalveolar lavage*. *American Review of Respiratory Disease*, 1986. **133**(3): p. 473-477.
24. Weissler, J.C., et al., *Natural Killer Cell Function in Human Lung Is Compartmentalized*. *American Review of Respiratory Disease*, 1987. **135**(4): p. 941-949.
25. Peters, S.P., *Counterpoint: Is measuring sputum eosinophils useful in the management of severe asthma? no, not for the vast majority of patients*. *Chest*, 2011. **139**(6): p. 1273-1275.
26. Hargreave, F.E. and P. Nair, *Point: Is measuring sputum eosinophils useful in the management of severe asthma? yes*. *Chest*, 2011. **139**(6): p. 1270-1272.
27. Korevaar, D.A., et al., *Diagnostic accuracy of minimally invasive markers for detection of airway eosinophilia in asthma: a systematic review and meta-analysis*. *The Lancet Respiratory Medicine*, 2015. **3**(4): p. 290-300.
28. Jia, G., et al., *Periostin is a systemic biomarker of eosinophilic airway inflammation in asthmatic patients*. *Journal of Allergy and Clinical Immunology* 2012. **130**(3): p. 647-654.e10.
29. Shorr, A.F., et al., *Acute eosinophilic pneumonia among us military personnel deployed in or near iraq*. *JAMA*, 2004. **292**(24): p. 2997-3005.
30. Cottin, V. and J.-F. Cordier, *Eosinophilic Pneumonia*, in *Orphan Lung Diseases: A Clinical Guide to Rare Lung Disease*, V. Cottin, J.-F. Cordier, and L. Richeldi, Editors. 2015, Springer London: London. p. 227-251.
31. Wechsler, M.E., *Pulmonary Eosinophilic Syndromes*. *Immunology and Allergy Clinics* 2007. **27**(3): p. 477-492.
32. Roufousse, F. and P.F. Weller, *Practical approach to the patient with hypereosinophilia*. *Journal of Allergy and Clinical Immunology*, 2010. **126**(1): p. 39-44.
33. Valent, P., et al., *Contemporary consensus proposal on criteria and classification of eosinophilic disorders and related syndromes*. *Journal of Allergy and Clinical Immunology*, 2012. **130**(3): p. 607-612.e9.
34. Cottin, V., *Eosinophilic Lung Diseases*. *Clinics in Chest Medicine*, 2016. **37**(3): p. 535-556.
35. Petsky, H.L., et al., *A systematic review and meta-analysis: tailoring asthma treatment on eosinophilic markers (exhaled nitric oxide or sputum eosinophils)*. *Thorax*, 2012. **67**(3): p. 199-208.
36. Tran, T.N., et al., *High blood eosinophil count is associated with more frequent asthma attacks in asthma patients*. *Annals of Allergy, Asthma & Immunology*, 2014. **113**(1): p. 19-24.

37. Wenzel, S.E., *Emergence of Biomolecular Pathways to Define Novel Asthma Phenotypes. Type-2 Immunity and Beyond*. 2016. *Am. J. Respir Cell Mol Biol* **55**(1): p.1-4
38. Wenzel, S.E., *Complex phenotypes in asthma: Current definitions*. *Pulmonary Pharmacology & Therapeutics*, 2013. **26**(6): p. 710-715.
39. WENZEL, S.E., et al., *Evidence That Severe Asthma Can Be Divided Pathologically into Two Inflammatory Subtypes with Distinct Physiologic and Clinical Characteristics*. *American Journal of Respiratory and Critical Care Medicine*, 1999. **160**(3): p. 1001-1008.
40. Vasiliou, J.E., et al., *Vitamin D deficiency induces Th2 skewing and eosinophilia in neonatal allergic airways disease*. *Allergy*, 2014. **69**(10): p. 1380-1389.
41. de Groot, J.C., et al., *Vitamin D reduces eosinophilic airway inflammation in nonatopic asthma*. *Journal of Allergy and Clinical Immunology*, 2015. **135**(3): p. 670-675.e3.
42. McGrath, K.W., et al., *A Large Subgroup of Mild-to-Moderate Asthma Is Persistently Noneosinophilic*. *American Journal of Respiratory and Critical Care Medicine*, 2012. **185**(6): p. 612-619.
43. Lu, N.Z. and J.A. Cidlowski, *Translational Regulatory Mechanisms Generate N-Terminal Glucocorticoid Receptor Isoforms with Unique Transcriptional Target Genes*. *Molecular Cell*, 2005. **18**(3): p. 331-342.
44. Oakley, R.H. and J.A. Cidlowski, *The biology of the glucocorticoid receptor: New signaling mechanisms in health and disease*. *Journal of Allergy and Clinical Immunology*. **132**(5): p. 1033-1044.
45. Goleva, E., et al., *Increased Glucocorticoid Receptor β Alters Steroid Response in Glucocorticoid-insensitive Asthma*. *American Journal of Respiratory and Critical Care Medicine*, 2006. **173**(6): p. 607-616.
46. Vazquez-Tello, A., et al., *Induction of glucocorticoid receptor- β expression in epithelial cells of asthmatic airways by T-helper type 17 cytokines*. *Clinical & Experimental Allergy*, 2010. **40**(9): p. 1312-1322.
47. Christodoulopoulos, P., et al., *Increased number of glucocorticoid receptor- β -expressing cells in the airways in fatal asthma*. *Journal of Allergy and Clinical Immunology*, 2000. **106**(3): p. 479-484.
48. Saglani, S., et al., *IL-33 promotes airway remodeling in pediatric patients with severe steroid-resistant asthma*. *Journal of Allergy and Clinical Immunology*, 2013. **132**(3): p. 676-685.e13.
49. Zijlstra, G.J., et al., *Interleukin-17A induces glucocorticoid insensitivity in human bronchial epithelial cells*. *European Respiratory Journal*, 2012. **39**(2): p. 439-445.
50. Nixon, J., et al., *Monoclonal antibody therapy for the treatment of asthma and chronic obstructive pulmonary disease with eosinophilic inflammation*. *Pharmacology & Therapeutics* 2017. **169**(1): p. 57-77
51. Leckie, M.J., et al., *Effects of an interleukin-5 blocking monoclonal antibody on eosinophils, airway hyper-responsiveness, and the late asthmatic response*. *The Lancet*, 2000. **356**(9248): p. 2144-2148.
52. Kips, J.C., et al., *Effect of SCH55700, a Humanized Anti-Human Interleukin-5 Antibody, in Severe Persistent Asthma*. *American Journal of Respiratory and Critical Care Medicine*, 2003. **167**(12): p. 1655-1659.
53. Flood-Page, P., et al., *A Study to Evaluate Safety and Efficacy of Mepolizumab in Patients with Moderate Persistent Asthma*. *American Journal of Respiratory and Critical Care Medicine*, 2007. **176**(11): p. 1062-1071.
54. Pavord, I.D., et al., *Mepolizumab for severe eosinophilic asthma (DREAM): a multicentre, double-blind, placebo-controlled trial*. *The Lancet*, 2012. **380**(9842): p. 651-659.

55. Ortega, H.G., et al., *Mepolizumab Treatment in Patients with Severe Eosinophilic Asthma*. New England Journal of Medicine, 2014. **371**(13): p. 1198-1207.
56. Ortega, H.G., et al., *Severe eosinophilic asthma treated with mepolizumab stratified by baseline eosinophil thresholds: a secondary analysis of the DREAM and MENSA studies*. The Lancet Respiratory Medicine, 2016. **4**(7): p. 549-556.
57. Flood-Page, P.T., et al., *Eosinophil's Role Remains Uncertain as Anti-Interleukin-5 only Partially Depletes Numbers in Asthmatic Airway*. American Journal of Respiratory and Critical Care Medicine, 2003. **167**(2): p. 199-204.
58. Haldar , P., et al., *Mepolizumab and Exacerbations of Refractory Eosinophilic Asthma*. New England Journal of Medicine, 2009. **360**(10): p. 973-984.
59. Castro, M., et al., *Reslizumab for inadequately controlled asthma with elevated blood eosinophil counts: results from two multicentre, parallel, double-blind, randomised, placebo-controlled, phase 3 trials*. The Lancet Respiratory Medicine, 2015. **3**(5): p. 355-366.
60. Castro, M., et al., *Reslizumab for Poorly Controlled, Eosinophilic Asthma*. 2011. **184**(10): p. 1125-1132.
61. Corren, J., et al., *Phase 3 Study of Reslizumab in Patients With Poorly Controlled Asthma: Effects Across a Broad Range of Eosinophil Counts*. Chest, 2016. **150**(4): p. 799-810.
62. Laviolette, M., et al., *Effects of benralizumab on airway eosinophils in asthmatic patients with sputum eosinophilia*. Journal of Allergy and Clinical Immunology, 2013. **132**(5): p. 1086-1096.e5.
63. Kolbeck, R., et al., *MEDI-563, a humanized anti-interleukin-5 receptor-alpha monoclonal antibody with enhanced antibody-dependent cell-mediated cytotoxicity function*. J Allergy Clin Immunol, 2010. **125**(6): p. 1344-53.
64. Bleecker, E.R., et al., *Efficacy and safety of benralizumab for patients with severe asthma uncontrolled with high-dosage inhaled corticosteroids and long-acting β 2-agonists (SIROCCO): a randomised, multicentre, placebo-controlled phase 3 trial*. The Lancet, 2016. **388**(10056): p. 2115-2127.
65. FitzGerald, J.M., et al., *Benralizumab, an anti-interleukin-5 receptor α monoclonal antibody, as add-on treatment for patients with severe, uncontrolled, eosinophilic asthma (CALIMA): a randomised, double-blind, placebo-controlled phase 3 trial*. The Lancet, 2016. **388**(10056): p. 2128-2141.
66. Rael, E.L. and R.F. Lockey, *Interleukin-13 Signaling and Its Role in Asthma*. World Allergy Organization Journal, 2011. **4**(3): p. 54.
67. Wenzel , S., et al., *Dupilumab in Persistent Asthma with Elevated Eosinophil Levels*. New England Journal of Medicine, 2013. **368**(26): p. 2455-2466.
68. Corren , J., et al., *Lebrikizumab Treatment in Adults with Asthma*. New England Journal of Medicine, 2011. **365**(12): p. 1088-1098.
69. Wenzel, S., et al., *Dupilumab efficacy and safety in adults with uncontrolled persistent asthma despite use of medium-to-high-dose inhaled corticosteroids plus a long-acting β 2 agonist: a randomised double-blind placebo-controlled pivotal phase 2b dose-ranging trial*. The Lancet, 2016. **388**(10039): p. 31-44.
70. Stevens, D.A., et al., *Allergic Bronchopulmonary Aspergillosis in Cystic Fibrosis—State of the Art: Cystic Fibrosis Foundation Consensus Conference*. Clinical Infectious Diseases, 2003. **37**(Supplement 3): p. S225-S264.
71. Greenberger, P.A., *Allergic bronchopulmonary aspergillosis*. Journal of Allergy and Clinical Immunology, 2002. **110**(5): p. 685-692.
72. Agarwal, R., *Allergic Bronchopulmonary Aspergillosis*. Chest, 2009. **135**(3): p. 805-826.

73. Chauhan, B., et al., *T cell subsets, epitope mapping, and HLA-restriction in patients with allergic bronchopulmonary aspergillosis*. The Journal of Clinical Investigation, 1996. **97**(10): p. 2324-2331.
74. Agarwal, R., et al., *Allergic bronchopulmonary aspergillosis: review of literature and proposal of new diagnostic and classification criteria*. Clinical & Experimental Allergy, 2013. **43**(8): p. 850-873.
75. Agarwal, R., et al., *Allergic Bronchopulmonary Aspergillosis: Lessons From 126 Patients Attending a Chest Clinic in North India*. Chest, 2006. **130**(2): p. 442-448.
76. Knutsen, A.P., et al., *Fungi and allergic lower respiratory tract diseases*. Journal of Allergy and Clinical Immunology, 2012. **129**(2): p. 280-291.
77. Patterson, T.F., et al., *Practice Guidelines for the Diagnosis and Management of Aspergillosis: 2016 Update by the Infectious Diseases Society of America*. Clinical Infectious Diseases, 2016. **63**(4): p. e1-e60.
78. Stevens, D.A., et al., *A Randomized Trial of Itraconazole in Allergic Bronchopulmonary Aspergillosis*. New England Journal of Medicine, 2000. **342**(11): p. 756-762.
79. Li, J.-X., et al., *Beneficial effects of Omalizumab therapy in allergic bronchopulmonary aspergillosis: A synthesis review of published literature*. Respiratory Medicine, 2017. **122**: p. 33-42.
80. Voskamp, A.L., et al., *Clinical Efficacy and Immunologic Effects of Omalizumab in Allergic Bronchopulmonary Aspergillosis*. The Journal of Allergy and Clinical Immunology: In Practice, 2015. **3**(2): p. 192-199.
81. Okubo, Y., et al., *Predominant Implication of IL-5 in Acute Eosinophilic Pneumonia: Comparison with Chronic Eosinophilic Pneumonia*. International Archives of Allergy and Immunology, 1998. **116**(1): p. 76-80.
82. Gaensler, E.A. and C.B. Carrington, *Peripheral opacities in chronic eosinophilic pneumonia: the photographic negative of pulmonary edema*. American Journal of Roentgenology, 1977. **128**(1): p. 1-13.
83. Price, M., et al., *Imaging of Eosinophilic Lung Diseases*. Radiologic Clinics of North America, 2016. **54**(6): p. 1151-1164.
84. Rom, W.N., et al., *Acute Eosinophilic Pneumonia in a New York City Firefighter Exposed to World Trade Center Dust*. American Journal of Respiratory and Critical Care Medicine, 2002. **166**(6): p. 797-800.
85. Choudhary, S., et al., *Drug Reaction with Eosinophilia and Systemic Symptoms (DRESS) Syndrome*. The Journal of Clinical and Aesthetic Dermatology, 2013. **6**(6): p. 31-37.
86. Peyrière, H., et al., *Variability in the clinical pattern of cutaneous side-effects of drugs with systemic symptoms: does a DRESS syndrome really exist?* British Journal of Dermatology, 2006. **155**(2): p. 422-428.
87. Favrolt, N., et al., *[Severe drug rash with eosinophilia and systemic symptoms after treatment with minocycline]*. Revue des maladies respiratoires, 2007. **24**(7): p. 892-895.
88. Erasmus, J.J., H.P. McAdams, and S.E. Rossi, *High-resolution CT of drug-induced lung disease*. Radiologic Clinics of North America, 2002. **40**(1): p. 61-72.
89. Alonso-Ruiz, A., et al., *Toxic Oil Syndrome A Long-term Follow-up of a Cohort of 332 Patients*. Medicine, 1993. **72**(5): p. 285-295.
90. Swygert, L.A., et al., *Eosinophilia-myalgia syndrome: Results of national surveillance*. JAMA, 1990. **264**(13): p. 1698-1703.
91. Nadeem, S., N. Nasir, and R.H. Israel, *Löffler's Syndrome Secondary to Crack Cocaine*. Chest, 1994. **105**(5): p. 1599-1600.

92. Schwarz, Y.A., et al., *Eosinophilic Lung Reaction to Aluminium and Hard Metal*. Chest, 1994. **105**(4): p. 1261-1263.
93. Shah, P.K.D., et al., *Pulmonary Infiltration with Blood Eosinophilia after Scorpion Sting*. Chest, 1989. **95**(3): p. 691-692.
94. Craig, J.M. and A.L. Scott, *Helminths in the lungs*. Parasite Immunology, 2014. **36**(9): p. 463-474.
95. Vijayan, V.K., *Tropical pulmonary eosinophilia: pathogenesis, diagnosis and management*. Current Opinion in Pulmonary Medicine, 2007. **13**(5): p. 428-433.
96. Boggild, A.K., J.S. Keystone, and K.C. Kain, *Tropical Pulmonary Eosinophilia: A Case Series in a Setting of Nonendemicity*. Clinical Infectious Diseases, 2004. **39**(8): p. 1123-1128.
97. Ogakwu, M. and C. Nwokolo, *Radiological findings in pulmonary paragonimiasis as seen in Nigeria: a review based on one hundred cases*. The British Journal of Radiology, 1973. **46**(549): p. 699-705.
98. Singh, P., et al., *Thoracic imaging findings in a case of disseminated cysticercosis*. Postgraduate Medical Journal, 2011. **87**(1024): p. 158-159.
99. Schwartz, E., J. Rozenman, and M. Perelman, *Pulmonary manifestations of early schistosome infection among nonimmune travelers*. The American Journal of Medicine, 2000. **109**(9): p. 718-722.
100. Cottin, V., et al., *Revisiting the systemic vasculitis in eosinophilic granulomatosis with polyangiitis (Churg-Strauss): A study of 157 patients by the Groupe d'Etudes et de Recherche sur les Maladies Orphelines Pulmonaires and the European Respiratory Society Taskforce on eosinophilic granulomatosis with polyangiitis (Churg-Strauss)*. Autoimmunity Reviews, 2017. **16**(1) p.1-9
101. Weller, P. and G. Bubley, *The idiopathic hypereosinophilic syndrome*. Blood, 1994. **83**(10): p. 2759-2779.
102. Slabbynck, H., et al., *Idiopathic Hypereosinophilic Syndrome-Related Pulmonary Involvement Diagnosed by Bronchoalveolar Lavage*. Chest, 1992. **101**(4): p. 1178-1180.
103. Ogbogu, P.U., et al., *Hypereosinophilic syndrome: A multicenter, retrospective analysis of clinical characteristics and response to therapy*. Journal of Allergy and Clinical Immunology, 2009. **124**(6): p. 1319-1325.e3.
104. Masi, A.T., et al., *The American College of Rheumatology 1990 criteria for the classification of churg-strauss syndrome (allergic granulomatosis and angiitis)*. Arthritis & Rheumatism, 1990. **33**(8): p. 1094-1100.
105. Moissidis, I., et al., *Milk-induced pulmonary disease in infants (Heiner syndrome)*. Pediatric Allergy and Immunology, 2005. **16**(6): p. 545-552.
106. Verleden, S.E., et al., *Restrictive chronic lung allograft dysfunction: Where are we now?* The Journal of Heart and Lung Transplantation, 2015. **34**(5): p. 625-630.
107. Verleden, S.E., et al., *Elevated Bronchoalveolar Lavage Eosinophilia Correlates With Poor Outcome After Lung Transplantation*. Transplantation, 2014. **97**(1): p. 83-89.
108. Verleden, S.E., et al., *Predictors of survival in restrictive chronic lung allograft dysfunction after lung transplantation*. The Journal of Heart and Lung Transplantation, 2016. **35**(9): p. 1078-1084.