

Video Article

Herlyn-Werner-Wunderlich syndrome; laparoscopic treatment of obstructing longitudinal vaginal septum in patients with hematocolpos - a different technique for virgin patients

Boyraz et al. Laparoscopic Treatment of Vaginal Septum

Gökhan Boyraz, Alper Karalök, Taner Turan, Nejat Özgül

Clinic of Gynecologic Oncology, University of Health Sciences, Etlik Zübeyde Hanım Women Diseases Training and Research Hospital,

Address for Correspondence: Gökhan Boyraz

e-mail: gokhan.boyraz@gmail.com ORCID: orcid.org/000-0001-6165-1497

DOI: 10.4274/jtgga.galenos.2019.2019.0046

Received: 13 March, 2019 **Accepted:** 18 August, 2019

Abstract

We aimed to define a new laparoscopic treatment approach for the patients with hematocolpos and obstructed hemi-vagina due to longitudinal obstructing vaginal septum. This technique is particularly essential for the patients who desire to preserve virginity. To the best of our knowledge this is the first case reporting laparoscopic resection of vaginal septum with an obstructed hemivagina and hematocolpos.

Introduction

Herlyn-Werner-Wunderlich Syndrome is a rare congenital anomaly characterized by uterus didelphys with blind hemivagina and ipsilateral renal agenesis, was initially described by Herlyn and Werner in 1971. The true incidence of this anomaly is unknown, however it has been reported between 0.1% and 3.8% [1, 2].

A 30-year-old patient presented with severe abdominal-pelvic pain and dysmenorrhea. Pelvic Magnetic Resonance Imaging indicated a complete uterine septum coexisting with longitudinal obstructing vaginal septum that might cause hematocolpos. Unilateral renal agenesis was detected in computerized tomography (CT) urogram. She had not been sexually active and in spite of the severe pelvic pain she absolutely rejected vaginal surgery in order to preserve her hymeneal integrity and virginity. This situation forced us to perform laparoscopic approach. Therefore, we aimed to define a new laparoscopic treatment approach for the patients with hematocolpos and obstructed hemi-vagina due to longitudinal obstructing vaginal septum. This technique is particularly essential for the patients who desire to preserve virginity. All of the techniques described previously were based on vaginal approach and to the best of our knowledge this is the first case reporting laparoscopic resection of vaginal septum with an obstructed hemivagina and hematocolpos. This technique of laparoscopic approach in patients with obstructing longitudinal vaginal septum with hematocolpos not only provides to preserve hymeneal integrity but also to define types of genital tract anomalies and coexisting anomalies exactly. The procedure was consisted of two major steps (video). Firstly, a transvers incision is made in the anterior vagina wall. Secondly, longitudinal vaginal septum is rejected and transvers vaginal incision is closed with intracorporeal suturing.

In conclusion, laparoscopic approach seems to be alternative treatment options in patients with hematocolpos in patients who desire to preserve virginity.

References

1. Zhu L, Chen N, Tong JL, Wang W, Zhang L, Lang JH. New classification of Herlyn-Werner-Wunderlich syndrome. *Chin Med J (Engl)*, 2015. 128(2): p. 222-5.
2. Herlyn, U. and H. Werner, [Simultaneous occurrence of an open Gartner-duct cyst, a homolateral aplasia of the kidney and a double uterus as a typical syndrome of abnormalities]. *Geburtshilfe Frauenheilkd*, 1971. 31(4): p. 340-7.

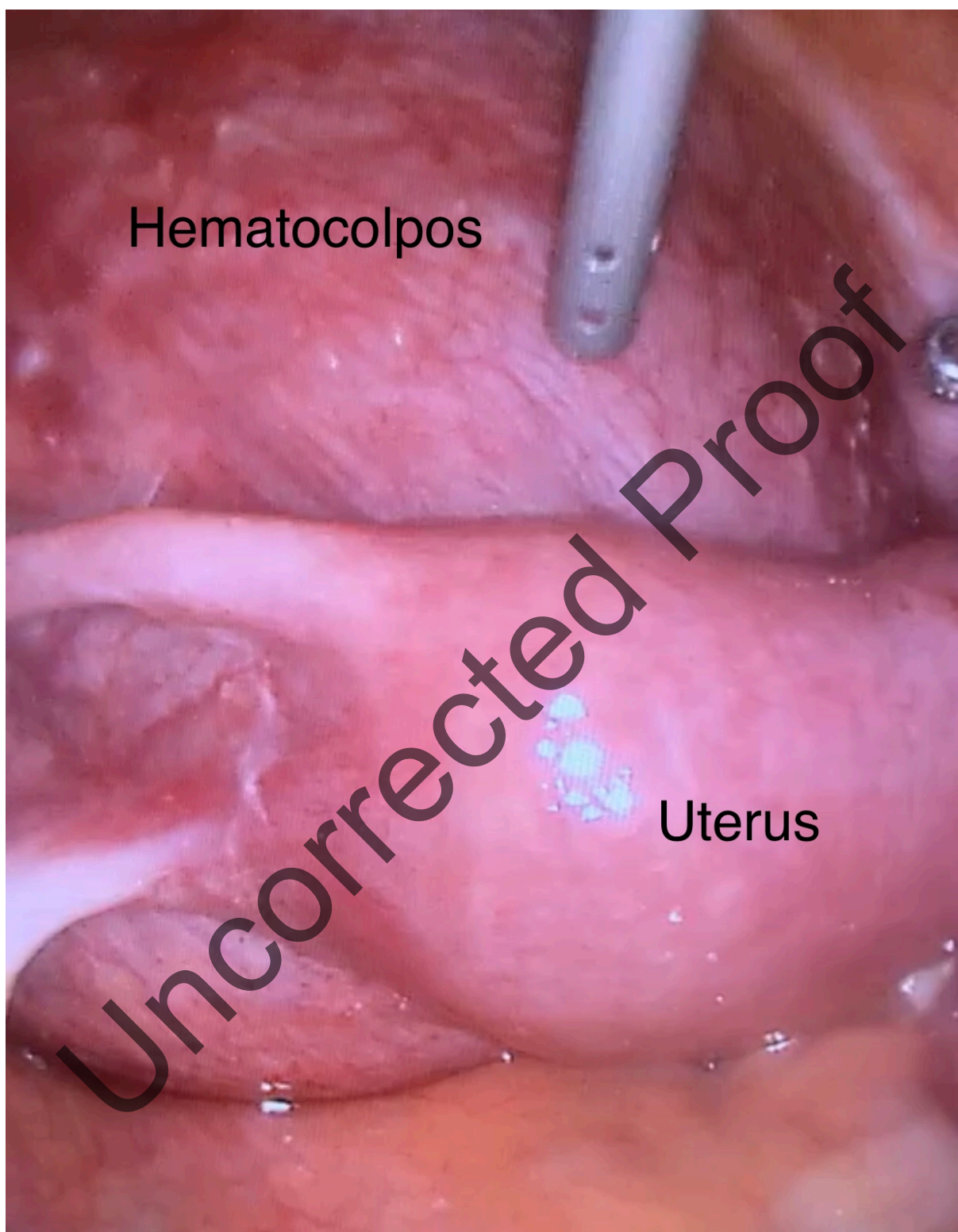


Figure 1: A wide hematocolpos corresponding to the obstructed left hemivagina

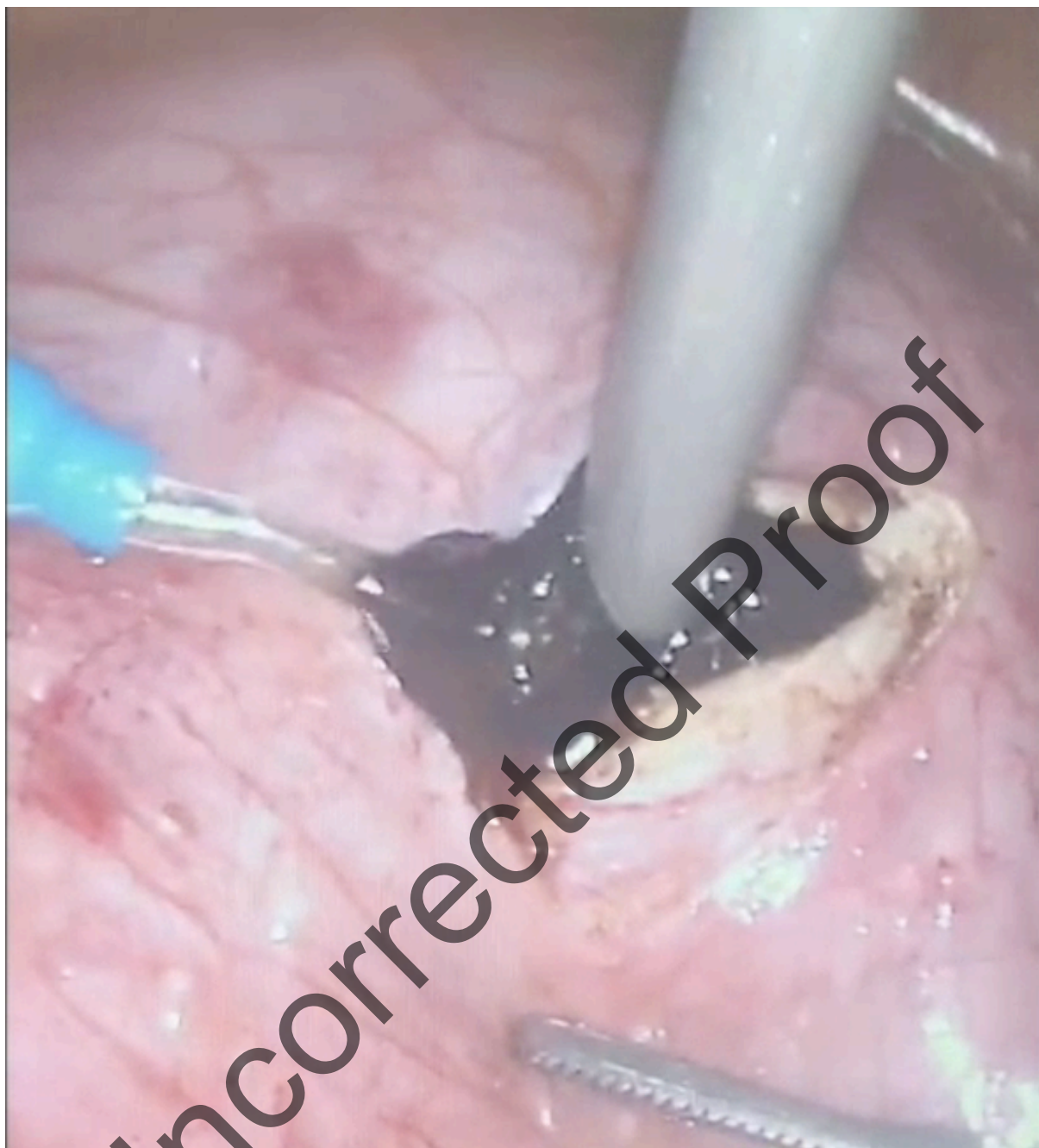

Figure 2: Draining the old menstrual blood

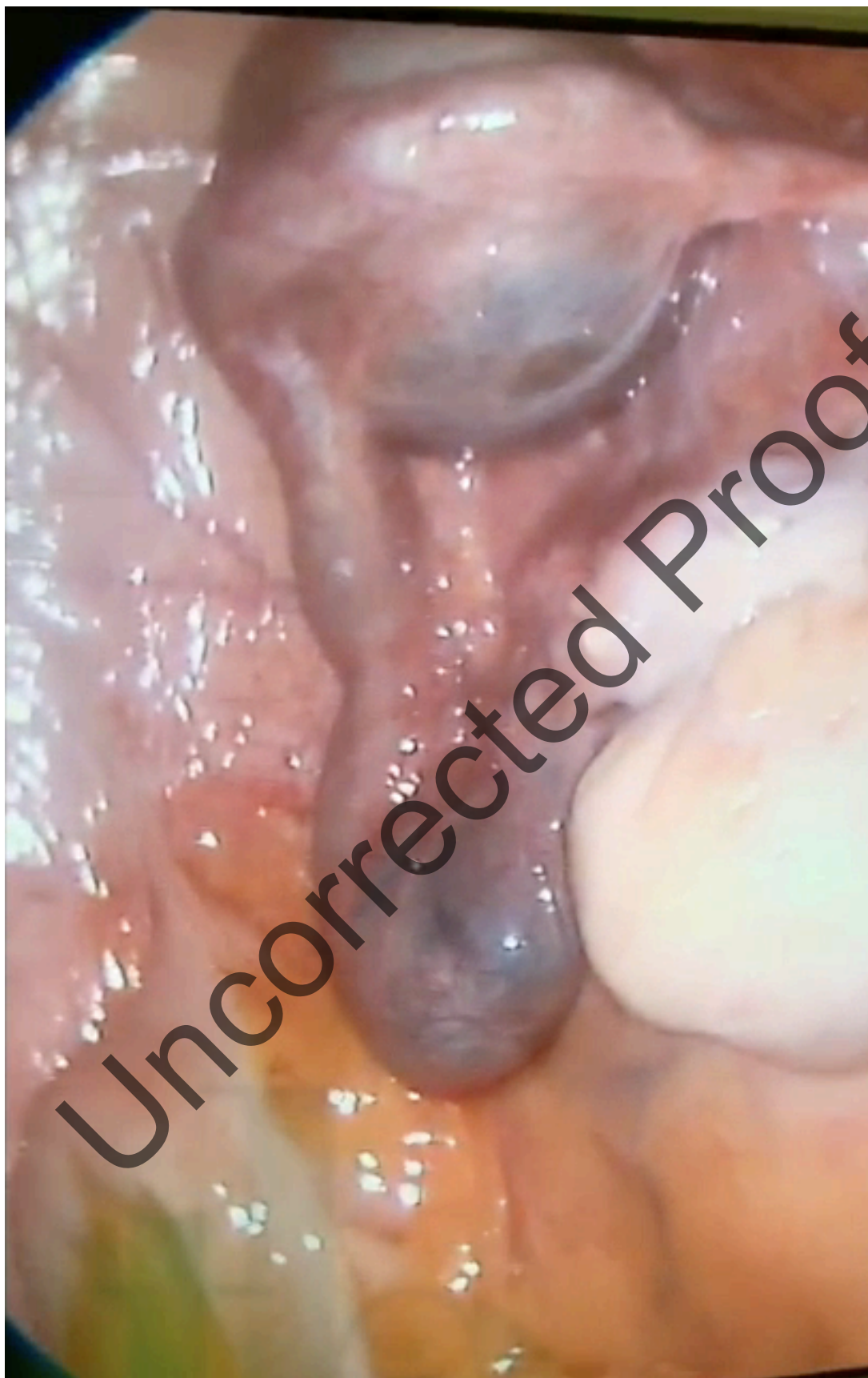

Figure 3: Fimbrial phimosis of left fallopian tube