

Left-sided Acute Appendicitis in a Case of Situs Inversus Totalis

İbrahim Altundağ¹, Burak Özçelik², Davut Tekyol², Sinem Doğruyol²

¹University of Health Sciences Turkey, Başakşehir Çam and Sakura City Hospital, Clinic of Emergency Medicine, İstanbul, Turkey

²University of Health Sciences Turkey, Haydarpaşa Numune Training and Research Hospital, Clinic of Emergency Medicine, İstanbul, Turkey

Abstract

The displacement of all thoracic and abdominal organs is called situs inversus totalis (SIT). Its incidence is 0.01% and it is characterized by abnormal anatomy but normal organ functions. It is a benign condition with a normal life expectancy and an asymptomatic course. Situs inversus; causes difficulties in the diagnosis and treatment of all internal organ pathologies. Having detailed information about human structure and anatomical variations is of great importance in daily clinical practice and particularly in emergency medical interventions and surgeries. Anatomical variations can be fatal in routine patient evaluations and emergency interventional procedures. Acute appendicitis is the most common pathology requiring emergency surgery and constitutes 4%-8% of all emergency department admissions. Although it can be easily diagnosed by clinical examination without the need for imaging studies due to typical symptoms such as pain migration, there is difficulty in definitive diagnosis in patients with anatomical variations such as SIT. The symmetrical localization of the appendix in situs inversus cases causes acute appendicitis to be included in the differential diagnosis of left lower quadrant pain. The differential diagnosis of left lower quadrant appendix vermiformis with gynecopathology, such as ovarian cyst rupture, causes more difficulties in female patients with SIT. The differential diagnosis of left lower quadrant pain is more difficult in women than in male patients. SIT is mostly diagnosed incidentally. The different anatomical location of the organs from normal healthy individuals causes the patient management to take a very careful situation in the applications of patients with situs inversus in cases requiring emergency intervention. When these patients present to the emergency department with acute abdomen findings, both the diagnosis and consultation process to the necessary branches should be clearer than other patients. A definitive diagnosis should be avoided without clarification of organ localization.

Keywords: Situs inversus totalis, acute appendicitis, left-sided appendicitis, ovarian cyst

Introduction

Situs inversus totalis (SIT) is a genetically originated condition in which the thoracic or abdominal structures are located symmetrically in their normal anatomical position concerning the midline [1]. The incidence of this syndrome is 0.01%, and it is characterized by abnormal anatomy with normal organ functions. It is a benign condition with normal life expectancy and it presents no clinical symptoms [2]. SIT causes difficulties in the diagnosis and treatment of all internal organ pathologies, especially pathologies that affect one side of the body, such as acute cholecystitis and appendicitis.

Having detailed information about the human body and anatomical variations is critical in daily clinical practice,

and particularly in emergency interventions and surgeries. Anatomical variations can be fatal in a routine patient evaluation. Acute appendicitis is the most common pathology requiring emergency surgery and constitutes 4%-8% of all emergency department admissions [3]. Although acute appendicitis can be easily diagnosed by clinical examination without the need for imaging studies due to typical symptoms such as pain migration, finding the definitive diagnosis in patients with anatomical variations such as SIT can cause a challenging process. The differential diagnosis of left lower quadrant appendix vermiformis with gynecopathology, such as ovarian cyst rupture, causes more difficulties in female patients with SIT [4].



Address for Correspondence: İbrahim Altundağ MD, University of Health Sciences Turkey, Başakşehir Çam and Sakura City Hospital, Clinic of Emergency Medicine, İstanbul, Turkey

Phone: +90 544 890 44 40 **E-mail:** dr.ibrahimaltundag@gmail.com **ORCID-ID:** orcid.org/0000-0002-0880-7218

Received: 09.07.2022 **Accepted:** 24.11.2022

In this article, we presented a case of acute appendicitis in a female patient who was newly diagnosed with SIT and presented to the emergency department with left lower quadrant pain. Also, we emphasized the importance of anamnesis, physical examination and electrocardiography (ECG) findings in the differential diagnosis of SIT considering this case.

Case Report

A 44-year-old female patient with no known chronic diseases other than an ovarian cyst and no medication use was admitted to the emergency department with abdominal pain, nausea-vomiting and fever that had started the day before the admission. After the patient’s pain that started in the middle part of the abdomen was localized to the left lower quadrant a few hours later. She was conscious, cooperative and oriented. Vital signs on admission were the following; blood pressure 124/76 mmHg, heart rate 85 beats per minute, oxygen saturation 98% and body temperature 37.8 °C. On physical examination, severe tenderness, defense and rebound in the left lower quadrant were detected, and pre-op tests were requested. Since a history of ovarian cyst and the abdominal pain was located in the left lower quadrant, a gynecological consultation was requested with the preliminary diagnosis

of ovarian cyst rupture. Laboratory results of the patient were as follows; white blood cell 18.66/uL, neutrophil 16.9/uL, hemoglobin 12.9 g/dL, C-reactive protein (CRP) 0.2 mg/dL, B-HCG <1.2 mIU/mL and ketone (+) was in urinalysis. Other laboratory results did not display any pathology. In the abdominal ultrasonography images, both ovaries were normal in size and a hemorrhagic cyst of 15 mm in diameter was found in the left ovary. In ECG, right axis deviation and loss of R wave progression were detected in the precordial leads (Figure 1). After confirming the placement of the electrodes several times, her ECG was interpreted as dextrocardia. Postero-anterior chest X-ray was requested to differentiate dextrocardia. On the chest X-ray, right-sided gastric air and dextrocardia were detected (Figure 2). Contrast-enhanced abdominal computed tomography (CT) was requested for differential diagnosis of newly diagnosed SIT, considering the development of symptoms and physical examination findings to be compatible with acute appendicitis. On CT images, SIT and 13.5 mm appendix vermiformis located on the left side with closed lumen were detected (Figure 3). The patient was operated with a diagnosis of acute appendicitis. Because of the operation, pathology results showed that an edematous, inflamed appendix vermiformis with a length of approximately

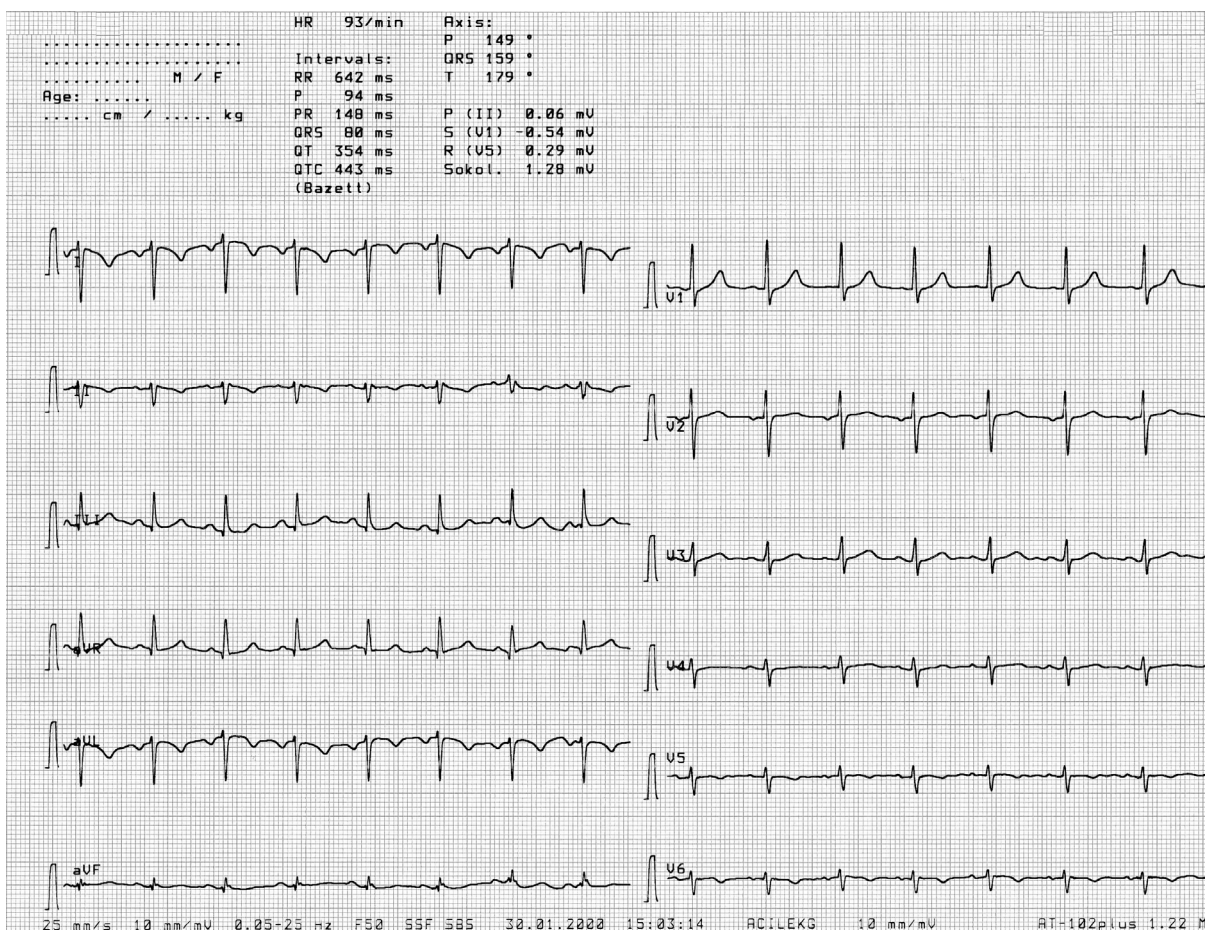


Figure 1. Right axis deviation and loss of R wave progression in the precordial leads, compatible with dextrocardia

7 cm and a width of 1.5 cm containing fecaloid material was obtained. The patient had no additional complaints on the second post-op day and was discharged with full recovery.

Discussion

Abdominal pain is one of the most common causes of emergency department admission. The etiologic causes of the acute abdominal pain range from benign pathologies to serious pathologies with high mortality [5]. Also, complications in these patients who were applied with abdominal pain constitute a large percentage of medicolegal actions [6].

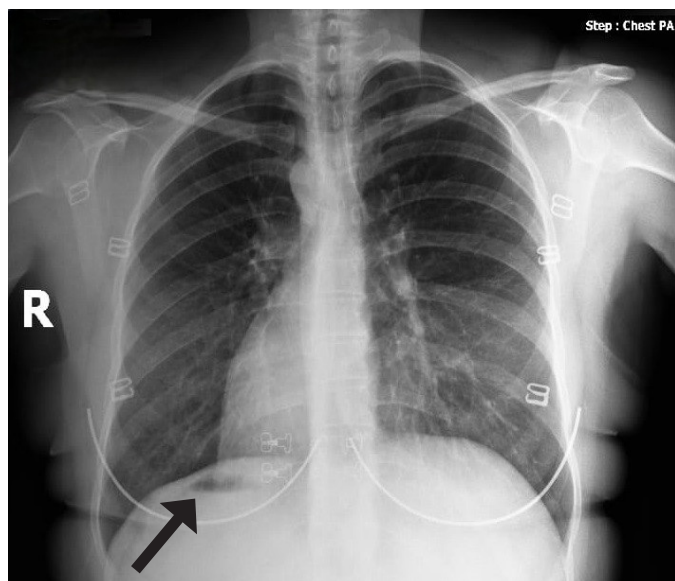


Figure 2. Right-sided gastric fundus air and dextrocardia appearance on chest X-ray (black arrow)

The causes of left lower quadrant pain include gastrointestinal and urinary system and gynecological pathologies. In the differential diagnosis; sigmoid diverticulitis, intestinal obstructions, inguinal hernia, renal colic, cystitis, pelvic inflammatory disease and epididymal, testicular, ovarian pathologies are considered. The symmetrical localization of the appendix in SIT cases causes acute appendicitis to be included in the differential diagnosis of left lower quadrant pain. The only difference in abdominal pain due to acute appendicitis in SIT compared to the normal population is that the localization of pain to the left lower quadrant instead of the right lower quadrant within 24 h of the onset of the abdominal pain in the umbilicus [7]. Because of the symmetrical location of the heart, thoracic and abdominal organs in SIT, there are some differences compared with the normal population. Right axis deviation (QRS negativity in DI and QRS positivity in aVF) due to dextrocardia is seen in ECG. Additionally, QRS wave positivity in aVR suggests the possibility of incorrectly connected electrodes. The main criterion in differential diagnosis is that the loss of R progression is seen only in the precordial leads in dextrocardia and is not seen in the case of incorrectly connected electrodes. In this study, the right axis deviation and loss of R progression on ECG were the main features that led to the diagnosis of dextrocardia instead of SIT. These ECG findings were similar to the ECG findings in the literature [8].

Identifying the leading cause of abdominal pain in female patients with SIT is similar to solving a puzzle. The main reason for the difficulty in the differential diagnosis of left lower quadrant pain in female patients with SIT is the presence of ovarian and other gynecological pathologies. Once an acute gynecopathological finding that may cause this

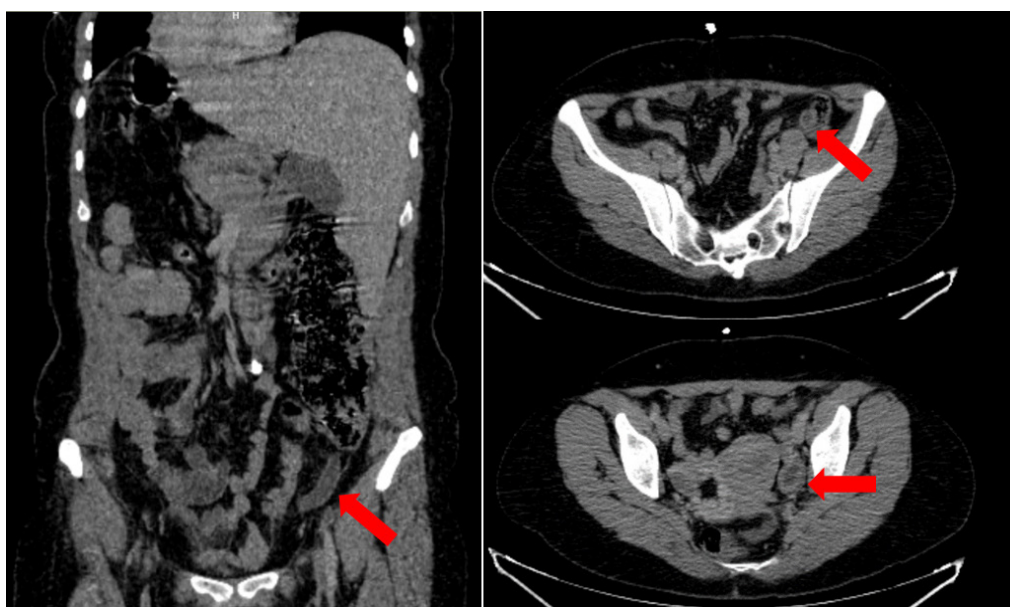


Figure 3. Appearance of 13.5 mm acute appendicitis in the coronal plane (left) and axial plane (top right) and left ovarian cyst (bottom right) with accompanying situs inversus in abdominal computed tomography examination (red arrow)

abdominal pain is detected, as in our patient, the possibility of acute appendicitis can be missed/ignored. This will delay the diagnosis of the patient and worsen her clinical features. Our case is important and special because it will change the perspective on the etiology of abdominal pain in female patients.

Despite successful laparoscopic appendectomy case reports, the abdominal anatomical difference in patients with SIT causes difficulties in the laparoscopic approach to acute appendicitis. This difficulty causes surgeons to prefer open surgery mostly. In the case, open surgery was preferred instead of laparoscopy.

Conclusion

SIT is a rare condition in the population, and due to its asymptomatic clinical course, it is mostly diagnosed incidentally during examination or imaging performed for any complaint. For the clinician faced with an undiagnosed female patient with SIT, this clinical evaluation can be quite a challenge. When these patients present to the emergency department with acute abdomen findings, both the diagnosis and consultation process to the necessary branches should be clearer than other patients. Before deciding on a definitive diagnosis for the patient, the localization of the organs should be confirmed by imaging.

Ethics

Informed Consent: Informed consent was obtained from the patient.

Peer-review: Externally peer-reviewed.

Authorship Contributions

Surgical and Medical Practices: İ.A., B.Ö., D.T., S.D., Concept: İ.A., B.Ö., D.T., S.D., Design: İ.A., B.Ö., D.T., S.D., Data Collection

or Processing: İ.A., B.Ö., D.T., S.D., Analysis or Interpretation: İ.A., B.Ö., D.T., S.D., Literature Search: İ.A., B.Ö., D.T., S.D., Writing: İ.A., B.Ö., D.T., S.D.

Conflict of Interest: No conflict of interest was declared by the authors.

Financial Disclosure: The authors declared that this study received no financial support.

References

1. Morelli SH, Young L, Reid B, Ruttenberg H, Bamshad MJ. Clinical analysis of families with heart, midline, and laterality defects. *Am J Med Genet.* 2001;101:388-92.
2. Palanivelu C, Rangarajan M, John SJ, Senthilkumar R, Madhankumar MV. Laparoscopic appendectomy for appendicitis in uncommon situations: the advantages of a tailored approach. *Singapore Med J.* 2007;48:737-40.
3. Cotran RS, Kumar V, Robbins SL. 4th ed. Philadelphia, Pa: WB Saunders Co; 1989. Robbins pathological basis of disease; p.777.
4. Nelson MJ, Pesola GR. Left lower quadrant pain of unusual cause. *J Emerg Med.* 2001;20:241-5.
5. Chanana L, Jegaraj MA, Kalyaniwala K, Yadav B, Abilash K. Clinical profile of non-traumatic acute abdominal pain presenting to an adult emergency department. *J Family Med Prim Care.* 2015;4:422-5.
6. Kachalia A, Gandhi TK, Puopolo AL, Yoon C, Thomas EJ, Griffey R, et al. Missed and delayed diagnoses in the emergency department: a study of closed malpractice claims from 4 liability insurers. *Ann Emerg Med.* 2007;49:196-205.
7. Oh JS, Kim KW, Cho HJ. Left-sided appendicitis in a patient with situs inversus totalis. *J Korean Surg Soc.* 2012;83:175-8.
8. Saad M, Ford DO, Goddard KK, Abuzaid A. A twist of fate: situs inversus totalis with dextrocardia. *Am J Med.* 2015;128:477-9.