

# OCCLUSAL CONCEPTS IN COMPLETE DENTURE

ا. د رغاء كريم جاسم

LEC3,4

**OCCLUSION** the static relationship between the incising and masticating surfaces of the maxillary or mandibular teeth or tooth analogues.

**ARTICULATION** It is defined as the contact relationship of maxillary and mandibular teeth as they move against each other.

**centric relation CR;** a maxilla mandibular relationship, independent of tooth contact, in which the condyles articulate in the anterior-superior position against the posterior slopes of the articular eminences .it is a clinically useful, repeatable reference position.(bone to bone)

**centric occlusion :** the occlusion of opposing teeth when the mandible is in centric relation; this may or may not coincide with the maximal intercuspal position. (tooth to tooth)

**occlusal balance :** a condition in which there are simultaneous contacts of opposing teeth or tooth analogues on both sides of the opposing dental arches during eccentric movements within the functional range

**occlusal harmony :** a condition in maximal intercuspal position and eccentric jaw relation in which there are no interceptive or deflective contacts of occluding surfaces

## **occlusal interference**

1. Any tooth contact that inhibits the remaining occluding surfaces from achieving stable and harmonious contacts;
2. Any undesirable occlusal contact

**Maximal intercuspal** position the complete intercuspation of the opposing teeth,independent to condylar position

Mandibular movement can be: opening closing, protrusive, and lateral in lateral it may be

- Working side is the side that the mandible move toward it in lateral excursion.
- Nonworking side is the side that the mandible move away from during lateral excursion.

Natural teeth	Artificial teeth
<ol style="list-style-type: none"> <li>1.Fixed in bone</li> <li>2.Supported by periodontal ligament</li> <li>3.Tooth move into socket during mastication because of elasticity of ligament</li> <li>4.When teeth , move one side during mastication the other side is not affected</li> <li>5. When teeth move in socket, they produce stretching effect and exert tensile force</li> <li>6.Tensile force produce stimulation to under lying bone</li> <li>7.Physiologic stimulation maintain good health of the bone</li> <li>8.To maintain the stimulus optimal occlusion of natural teeth is important</li> </ol>	<ol style="list-style-type: none"> <li>1.Rest on residual ridge</li> <li>2.not fixed to soft tissue</li> <li>3.Denture move toward tissue because of resiliency of mucosa</li> <li>4.When teeth meet on one side ,the other side loses balance upsetting retention and stability</li> <li>5.Compression of soft tissue causes displacement of the supporting tissue</li> <li>6.Compression causes pressure on mucosa of affecting vascular supply of bone</li> <li>7.Instability of denture causes loss of bone because of leverage</li> <li>8.To maintain the supporting tissue in good health ,planed occlusion is necessary</li> </ol>

*Requirements of ideal complete denture occlusion:*

1. Stability of denture in both centric and eccentric relation.
2. Balanced occlusal contact bilateral.
3. Cusp height reduced to control horizontal force.
4. Cutting, penetrating and shearing efficiency of occlusal surface.
5. Incisal clearance during posterior function like chewing.
6. Unlocking (removing interference) of cusps mesiodistally.

Objectives of occlusion in complete denture

- Preservation of the remaining tissues
- Proper masticatory efficiency
- Enhancement of denture stability, retention and support
- Enhancement of phonetics and esthetics

### **Requirement of Complete Denture Occlusion**

1. Stability of occlusion in centric relation.
2. Balanced for all eccentric contacts bilaterally for all eccentric mandibular movements.
3. Unlocking the cusp mesiodistally to allow for gradual but inevitable settling of the bases due to tissue deformation and bone resorption.
4. Control of horizontal forces by buccoligual cusp height reduction according to the residual ridge resistance and interridge space.
5. Functional lever balance by favorable tooth to ridge crest position
6. Cutting and shearing efficiency of the occlusal surface (sharp cusps or ridges)
7. Anterior clearance of teeth during mastication. Minimum occlusal
8. contact between the upper and lower teeth to reduce pressure during function (lingualized occlusion)

### **TYPES OF OCCLUSION**

- Balance occlusion
- Lingualized occlusion
- Monoplane occlusion

### ***Balance occlusion***

Balance occlusion in complete dentures can be defined as stable simultaneous contact of the opposing upper and lower teeth in centric relation position and a continuous smooth bilateral gliding from this position to any eccentric position within the normal range of mandibular function.

#### **In lateral excursion: (working side)**

- ***Anterior teeth***- the maxillary & mandibular anterior teeth contact on the working side.
- ***Posterior teeth***- the buccal & lingual cusps of the maxillary & mandibular posterior teeth are in contact. If lingualized occlusion, the maxillary lingual cusp will be in contact with the mandibular lingual cusp.

#### **In lateral excursion: balancing side**

- ***Anterior teeth***- the maxillary & mandibular anterior teeth may contact on the balancing side.
- ***Posterior teeth***- the lingual cusps of the maxillary teeth will be in contact with the buccal cusps of the mandibular teeth. With monoplane balanced occlusion, usually only the second molars are in contact or the balancing ramp.

### Advantages of Balance occlusion

1. Distribution of load
2. Stability
3. Reduced trauma
4. Functional movement
5. Efficiency
6. Comfort

### Factors affecting the balanced occlusion (Laws of Articulation Hanau quint)

1. Condylar guidance
2. Incisal guidance
3. The occlusal plane
4. The compensatory curves
5. Cusp angulation

Inter relation between these factors may be described by Theilman's formula

$$\text{Balanced occlusion} = \frac{\text{condylar inclination} \times \text{Incisal guidance}}{\text{Occlusal plane} \times \text{compansatory curve} \times \text{cusps angulation}}$$

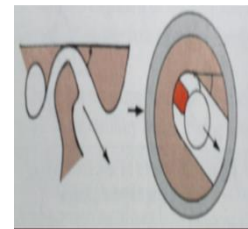
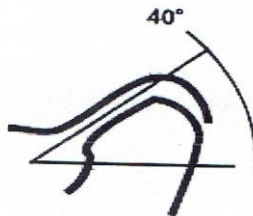
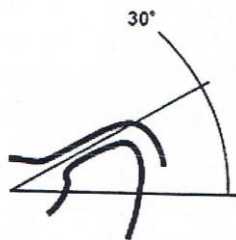
## 1. Condylar guidance

The angle formed by an imaginary horizontal line at the superior head of the condyle and the path that the condyle will pass through during function. It varies from individual to individual because of anatomical differences. About 33°

### **Definitions**

1. condylar guidance: mandibular guidance generated by the condyle and articular disc traversing the contour of the articular eminence GPT9
2. condylar guidance : the mechanical form located in the posterior region of an articulator that controls movement of its mobile member GPT9

The first factor of occlusion is the condylar guidance, this factor recorded from the patient .so it is fixed factor cannot be modified by the dentist.




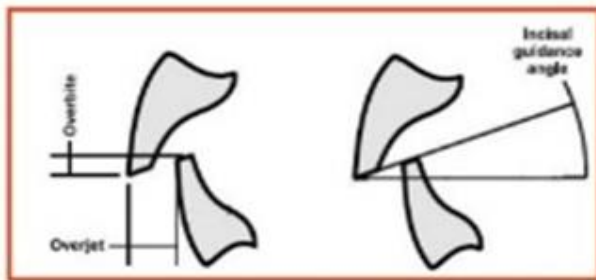
## **2. Incisal guidance:**

### **Definitions**

1. Incisal guidance: - the influence of the contacting surfaces of the mandibular and maxillary anterior teeth on mandibular movements.

It is usually expressed in degrees of angulation from the horizontal by a line drawn in the sagittal plane between the incisal edges of the upper and lower incisor teeth when closed in centric occlusion.

2. Incisal guidance:-the influences of the contacting surfaces of the guide pin and guide table on articulator movements.



*Incisal guidance depends on the:*

- 1.Desired over jet.

- 2.Over bite.

- *This angle varies directly with the vertical overbite and inversely with the horizontal over jet.*
- *This angle is set to 10° in CD and not exceeding 20°*
- *This angle determined by esthetic, phonetic, ridge relation, inter-alveolar distance, this means it is under the control of the dentist,*

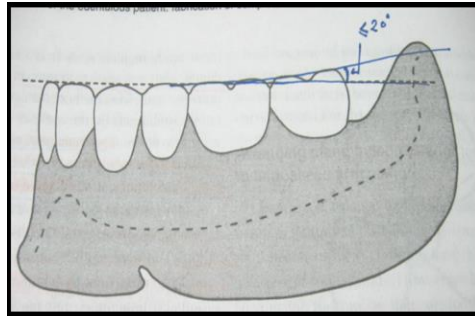
## **3.plane of occlusion:**

1. It is imaginary surface related anatomically to the cranium and theoretically touches the incisal edge of incisors and the tip of occluding surface of posterior teeth
2. Maxillary occlusal plane should parallel to interpapillary line ,posteriorly usually parallel to the ala-tragus line
3. In the mandible established anteriorly by the cusp height of lower canine near the commissure of the mouth(corner) and posteriorly by the retromolar pad.

**4.The compensating curve:** the arc introduced in the construction of complete removable dental prostheses to compensate for the opening influences

produced by the condylar and incisal guidance's during lateral and protrusive mandibular eccentric movements GPT9

- The compensating curve incorporated in a properly oriented plane of occlusion
- Compensating curve in artificial dentition is anteroposterior curve



**Anteroposterior compensating curves**

## **5. Cuspal angulations** or inclination of cusplless artificial teeth

It depends on several factors residual ridge,neuromuscular control, esthetics,etc)however, it's better to reduce the cuspal inclination to help reduce horizontal forces of occlusion.

### **Interaction of the five factor**

Of the four that he can control two of them (the incisal guidance and the plane of occlusion) can be altered only a slight amount because of esthetic and physiologic factors. The important working factors for the dentist to manipulate are the compensating curve and the inclinations or cusp on the occlusal surfaces of the teeth.

*For the balanced occlusion, it is important to use adjustable articulator*

How to record the condylar guidance?

After recording of jaw relation (orientation relation, vertical ,centric jaw relation)then a protrusive record should be made, in order to set the condylar guidance on articulator according to the following steps:-

- 1.place V shape notch.
2. allow the patient protrude aminimum of 5-6mm ,but less than 12mm

3. place elastomeric registration material between occlusal rim while the patient close in protrude position.
4. after complete setting of material .record base and registration are removed, place on articulator.
5. on the articulator the condylar element release from hinge position, instrument protrude ,they record approximated. The condyle element are rotated until there is maximum interdigitating of the registration and opposing occlusal rim.

## ***Lingualized occlusion:***

It involves use of large upper palatal cusp against wide shallow lower central fossa.

- The buccal cusps of upper and lower teeth do not contact each other.
- The maxillary palatal cusp tip should contact opposite mandibular central fossa.
- The cusp incline of mandibular teeth relatively flat result in less lateral force and displacement during function

### ***Indication:***

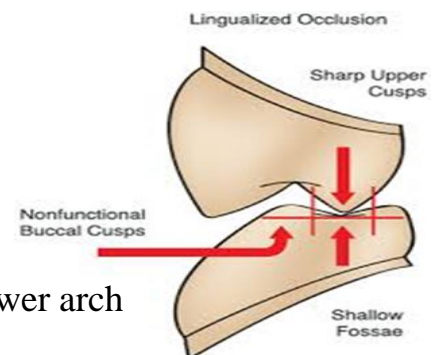
1. High esthetic needed.
2. Weak muscle of mastication.
3. Displaceable supporting tissue.
4. Severe alveolar bone resorption.
5. Discrepancy in jaws size. Narrow upper arch and wide lower arch
6. Implant supported over denture.
7. Previous successful denture with lingualized occlusion.

### ***Advantages:***

1. Simpler technique. Less precise CR records
2. Esthetics.
3. Better penetration of the food bolus.
4. easier to adjust occlusion
5. it may be used in cII, class III and cross bite.
6. Centralization of vertical forces.
7. Minimizing tipping force.
8. Potentially of bilateral balance

### ***Disadvantages:-***

1. Difficulty in obtaining repeatable centric record (incoordination, jaw malrelation)
2. Severe ridge resorption (lateral forces displace the denture) may more easily be handled with a monoplane scheme



## ***Monoplane or occlusion (neurocentric) :***

- Flat occlusal plane set with non anatomic teeth.
- The antero-posterior occlusal plan parallel to the denture foundation area.
- There is no vertical overlap of anterior teeth.
- Tooth Contact should occur only when mandible in centric relation. .
- Opposing artificial teeth should not contact when jaws in eccentric relation.
- In protrusion there is disclosure of posterior teeth as a result of arrangement in single plane.the patient is instructed not to incise the bolus
- There is no curve of spee or curve of Wilson (compensating curves).

### *Indications*

- 1.Jaw size discrepancies CI II, CI III ,malocclusion and cross bite
- 2.Uncoordinated jaw movement.
- 3.Mostly for geriatric patients.
- 4.minimal ridge ,resorbed ridge ,it reduces horizontal forces—implant may help.

### *Advantages:*

- 1.Simple technique and less time consuming.
- 2.Less precise jaw relation records.
- 3.Lateral forces are reduced by eliminating Cuspal inclines.
- 4.Simpler and easier occlusal adjustments.
- 5.Occlusion is not locked.

### *Disadvantages:*

- 1.Least esthetic.
- 2.Poor bolus penetration.
- 3.Cannot be balanced in eccentric excursions

## **Types of Occlusal Scheme:**

### **1.Anatomic teeth. '**

Simulate the natural teeth form with inclination approximately 33 degree

### *Advantages:*

- 1.Esthetic.
- 2.Better food penetration.
- 3.Vertical stress decrease.
- 4.Harmony with TMJ and muscle of mastication.
- 5.Balance occlusion in eccentric position



*Disadvantages: \_*

- 1.Precise technique requires.
- 2.More time.
- 3.Difficult teeth position in CL II &CL III
- 4.Greater lateral fore

### **2.Semi anatomic teeth**

Cusp incline less steep than anatomical teeth called modified anatomical teeth (less than  $33^{\circ}$ )

*Advantages:*

- 1.Esthetic.
- 2.Good chewing efficacy.
- 3.Less lateral force.
- 4.Balance occlusion.

*Disadvantages*

- 1.least esthetic.
- 2.poor bolus penetration.
- 3.cannot be balanced in eccentric excursions

### **3.Non anatomical teeth:-Flat and without cusp height.**

*Advantages*

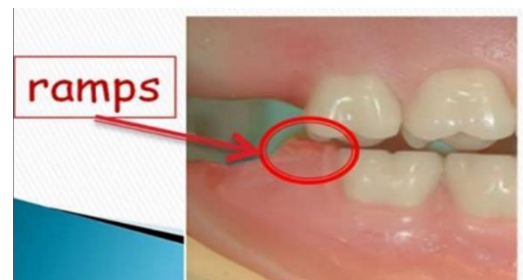- 1.Used for patient with poor neuromuscular coordination.
- 2.Used for patient with malrelation jaws.
- 3.Used for patient with cross bite or class III.
- 4.More comfortable.
- 5.Less time required in set up.
6. slightly more esthetic than neutrocentric occlusion.

*Disadvantages: \_*

- Use of compensatory curve may cause the same damaging effects as cuspal inclines.
- Occlusal adjustment are more difficult to accomplish

*Balance Occlusion For Non Anatomic Teeth May Be Accomplish By*

- Compensatory curve
- Tilting the second molar
- Placing the balancing ramp



## Factors influencing the selection of selection of occlusal scheme

### 1. Characteristics of occlusal scheme:

- Tooth form and arrangement
- Balanced or not

### 2. Characteristics of the patient:

- Height and width of the residual ridge
- Aesthetic demands of the patient
- Skeletal relations
- Neuromuscular control
- Tendency for parafunctional activity