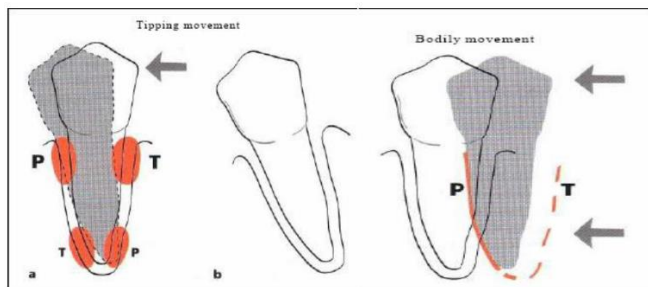


TRAUMA FROM OCCLUSION

الاستاذ باسمة غفوري علي

TYPES OF OCCLUSAL FORCES:

- Physiologically normal occlusal forces in chewing and swallowing: small and rarely exceeding 5 N. They provide the positive stimulus to maintaining the periodontium and the alveolar bone in a healthy and functional condition.
- Impact forces: mainly high but of short duration. The periodontium can sustain high forces during a short period; however, forces exceeding the viscoelastic buffer capacities of the periodontal ligament will result in fracture of tooth and bone.
- Continuous forces: very low forces (for example, orthodontic forces), but continuously applied in one direction are effective in displacing a tooth by remodeling the alveolus.
Forces in one direction: orthodontic forces bodily or tipping forces produce distinct zones of pressure and tension
- Jiggling forces: intermittent forces in two different directions (premature contacts on, for example, crowns, fillings) result in widening of the alveolus and in increased mobility



Periodontal Response to External Forces

Adaptive Capacity of the Periodontium to Occlusal Forces

The periodontal ligament has a cushioning effect on forces applied to teeth as means to accommodate forces exerted on the crown. **Due to the elastic nature of the periodontal ligament, all teeth with normal bone support present with physiologic mobility in all directions.**

Physiologic tooth mobility varies among individuals and within the dentition of the same individual. In the absence of excessive occlusal forces or the absence of reduced bone support induced by inflammatory periodontal disease, tooth mobility remains unchanged due to the fact that physiologic forces are not able to induce changes to the periodontal tissues. When there is an increase in occlusal forces, changes occur in the periodontium in order to accommodate for such forces. Changes in the periodontium depend on the **magnitude, direction, duration, and frequency of increased occlusal forces.**

When the *magnitude* of occlusal forces is increased, the periodontium responds with a **widening of the periodontal ligament space, an increase in the number and width of periodontal ligament fibers, and an increase in the density of alveolar bone.**

Changing the *direction* of occlusal forces causes a reorientation of the stresses and strains within the periodontium. The **principal fibers of the periodontal ligament are arranged so that they best accommodate occlusal forces along the long axis** of the tooth. *Lateral* (horizontal) and *torque* (rotational) forces are more likely to injure the periodontium.

The response of *alveolar bone* is also affected by the *duration and frequency* of occlusal forces. **Constant pressure on the bone is more injurious than intermittent forces. The more frequent the application of an intermittent force, the more injurious the force is to the periodontium.**

Trauma From Occlusion

Trauma from occlusion is defined as microscopic alterations of periodontal structures in the area of the periodontal ligament that become manifest clinically in the elevation of tooth mobility. An inherent “margin of safety” that is common to all tissues permits some variation in occlusion without adversely affecting the periodontium. However, when occlusal forces exceed the adaptive capacity of the tissues, tissue injury results. The resultant injury is termed *trauma from occlusion*, which is also known as *occlusal trauma*.

Thus trauma from occlusion refers to the *tissue injury* rather than the *occlusal force*. An occlusion that produces such an injury is called a *traumatic occlusion*. Excessive occlusal forces may also disrupt the *a*-function of the masticatory musculature and cause painful spasms, *b*-injure the temporomandibular joints, or *c*-produce excessive tooth wear. However, the term *trauma from occlusion* is generally used in connection with injury in the periodontium.

Classification of Trauma From Occlusion

Trauma from occlusion can be classified according to the injurious occlusal force(s) mode of onset (acute and chronic) or according to the capacity of the periodontium to resist to occlusal forces (primary and secondary).

Acute and Chronic Trauma From Occlusion

Acute trauma from occlusion refers to periodontal changes associated with an abrupt occlusal impact such as that produced by biting on a hard object (e.g., an olive pit). In addition, restorations or prosthetic appliances that interfere with or alter the direction of occlusal forces on the teeth may also induce acute trauma. Acute trauma results in tooth **pain, sensitivity to percussion, and increased tooth mobility. Acute trauma can also produce cementum tears.** If the force is dissipated by a shift in the position of the tooth or by the wearing away or correction of the restoration, then the injury heals, and the symptoms subside.

Otherwise, periodontal injury may worsen and develop into necrosis accompanied by periodontal abscess formation, or it may persist as a symptom-free chronic condition.

Chronic trauma from occlusion refers to periodontal changes associated with gradual changes in occlusion produced by tooth wear, drifting movement, and extrusion of the teeth in combination with parafunctional habits (e.g., bruxism, clenching) rather than as a sequela of acute periodontal trauma. Chronic trauma from occlusion is more common than the acute form and of greater clinical significance.

The criterion that determines if an occlusion is traumatic is whether it produces periodontal injury; the criterion is *not* based on how the teeth occlude. Any occlusion that produces periodontal injury is traumatic. **Malocclusion is not necessary to produce trauma; periodontal injury may occur when the occlusion appears normal.** The dentition may be anatomically and aesthetically acceptable but functionally injurious. Similarly, not all malocclusions are necessarily injurious to the periodontium.

Traumatic occlusal relationships are referred to by such terms as *occlusal disharmony*, *functional imbalance*, and *occlusal dystrophy*.

These terms refer to the effect of the occlusion on the periodontium rather than to the position of the teeth. Because trauma from occlusion refers to the tissue injury rather than the occlusion, an increased occlusal force is not traumatic if the periodontium can accommodate it.

Primary and Secondary Trauma From Occlusion

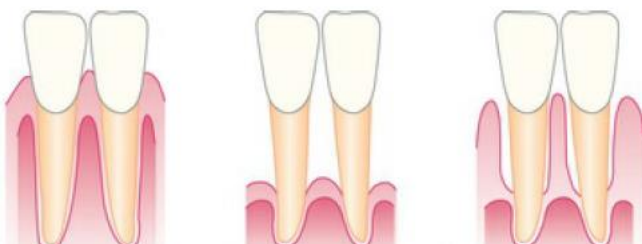
As mentioned previously, trauma from occlusion can also be classified according to the capacity of the periodontium to resist occlusal forces into primary and secondary trauma from occlusion. In other words, trauma from occlusion may be **caused by alterations in occlusal forces, a reduced capacity of the periodontium to withstand occlusal forces, or both.** When trauma from occlusion is the result of alterations in occlusal forces, it is called *primary trauma from occlusion*. When it results from the reduced ability of the tissues to resist the occlusal forces, it is known as *secondary trauma from occlusion*.

Primary trauma from occlusion occurs if trauma from occlusion is considered the primary etiologic factor in periodontal destruction and if the only local alteration to which a tooth is subjected is a result of occlusion. Examples include periodontal injury produced around teeth with a previously healthy periodontium after the following:

- (1) the insertion of a “high filling”.
- (2) the insertion of a prosthetic replacement that creates excessive forces on abutment and antagonistic teeth.
- (3) the drifting movement or extrusion of the teeth into spaces created by unreplaced missing teeth.
- or (4) the orthodontic movement of teeth into functionally unacceptable positions.

Most studies of the effect of trauma from occlusion involving experimental animals have examined the primary type of trauma. Changes produced by primary trauma do not alter the level of connective tissue attachment and do not initiate pocket formation. This is probably because the supracrestal gingival fibers are not affected and therefore prevent the apical migration of the junctional epithelium.

Secondary trauma from occlusion occurs when the adaptive capacity of the tissues to withstand occlusal forces is impaired by bone loss that results from marginal inflammation. This reduces the periodontal attachment area and alters the leverage on the remaining tissues. The periodontium becomes more vulnerable to injury, and previously well-tolerated occlusal forces become traumatic.



Traumatic forces can occur on (A) normal periodontium with normal height of bone, (B) normal periodontium with reduced height of bone, or (C) marginal periodontitis with reduced height of bone.

The first case is an example of primary trauma from occlusion, whereas the last two represent secondary trauma from occlusion.

It has been found in experimental animals that systemic disorders can reduce tissue resistance and that previously tolerable forces may become excessive. This could theoretically represent another mechanism by which tissue resistance to increased forces is lowered, thereby resulting in secondary trauma from occlusion.

Stages of Tissue Response to Increased Occlusal Forces

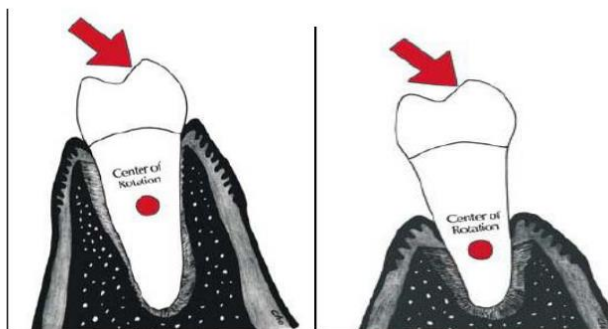
Tissue response occurs in three stages: injury, repair, and adaptive remodeling of the periodontium.

Stage I: Injury

Tissue injury is produced by excessive occlusal forces. The body then attempts to repair the injury and restore the periodontium.

This can occur if the forces are diminished or if the tooth drifts away from them. If the offending force is chronic, however, the periodontium is remodeled to cushion its impact. The ligament is widened at the expense of the bone, which results in angular bone defects without periodontal pockets, and the tooth becomes loose.

Under the forces of occlusion, a tooth rotates around a fulcrum or axis of rotation, which in single-rooted teeth is located in the junction between the middle third and the apical third of the clinical root and in multirooted teeth in the middle of the interradicular bone. This creates areas of pressure and tension on opposite sides of the fulcrum. Different lesions are produced by different degrees of pressure and tension. If jiggling forces are exerted, these different lesions may coexist in the same area.



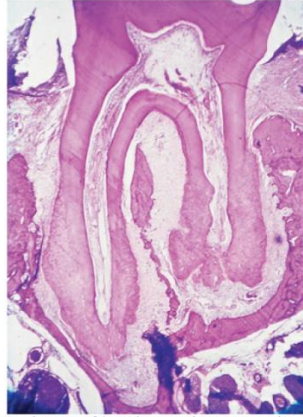


FIG. 25.4 Areas of tension and pressure in opposite sites of the periodontal ligament caused by experimentally induced orthodontic movement in a rat molar.

Slightly excessive pressure stimulates resorption of the alveolar bone, with a resultant widening of the periodontal ligament space.

Slightly excessive tension causes elongation of the periodontal ligament fibers and the apposition of alveolar bone. In areas of increased pressure, the blood vessels are numerous and reduced in size; in areas of increased tension, they are enlarged.

Greater pressure produces a gradation of changes in the periodontal ligament, starting with compression of the fibers, which produces areas of hyalinization. Subsequent injury to the fibroblasts and other connective tissue cells leads to necrosis of areas of the ligament. Vascular changes are also produced:

within 30 minutes, impairment and stasis of blood flow occur; at 2 to 3 hours, blood vessels appear to be packed with erythrocytes, which start to fragment; and between 1 and 7 days, disintegration of the blood vessel walls and release of the contents into the surrounding tissue occur. In addition, increased resorption of alveolar bone and resorption of the tooth surface occur.

Severe tension causes widening of the periodontal ligament, thrombosis, hemorrhage, tearing of the periodontal ligament, and resorption of alveolar bone.

Pressure severe enough to force the root against bone causes necrosis of the periodontal ligament and bone. **The bone is resorbed from viable periodontal ligament adjacent to necrotic areas and from marrow spaces; this process is called *undermining resorption*.**

The areas of the periodontium that are most susceptible to injury from excessive occlusal forces are the **furcations**.

Injury to the periodontium produces a temporary **depression** in **mitotic activity, in the rate of proliferation and differentiation of fibroblasts, in collagen formation, and in bone formation**.

These return to normal levels after the dissipation of the forces. The injury phase shows an increase in areas of resorption and a decrease in bone formation

Stage II: Repair

Repair occurs constantly in the normal periodontium, and trauma from occlusion stimulates increased reparative activity. The damaged tissues are removed, and new connective tissue cells and fibers, bone, and cementum are formed in an attempt to restore the injured periodontium

.Forces remain traumatic only as long as the damage produced exceeds the reparative capacity of the tissues. **The repair phase demonstrates decreased resorption and increased bone formation.**

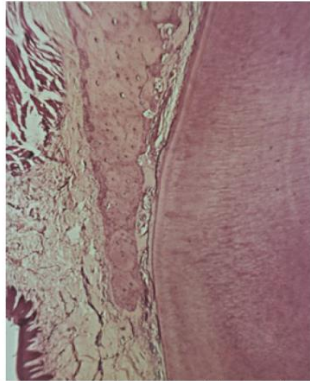


FIG. 25.5 Experimental occlusal trauma in rats. Note the area of necrosis of the marginal periodontal ligament and resorption and remodeling in the more apical periodontal sites.

When bone is resorbed by excessive occlusal forces, the body attempts to reinforce the thinned bony trabeculae with new bone. This attempt to compensate for lost bone is called **buttressing bone formation**, and it is an important feature of the reparative process associated with trauma from occlusion. It also occurs when bone is destroyed by inflammation or osteolytic tumors. Buttressing bone formation occurs within the jaw (central buttressing) and on the bone surface (peripheral buttressing).

During *central buttressing*, the endosteal cells deposit new bone, which restores the bony trabeculae and reduces the size of the marrow spaces. *Peripheral buttressing* occurs on the facial and lingual surfaces of the alveolar plate.

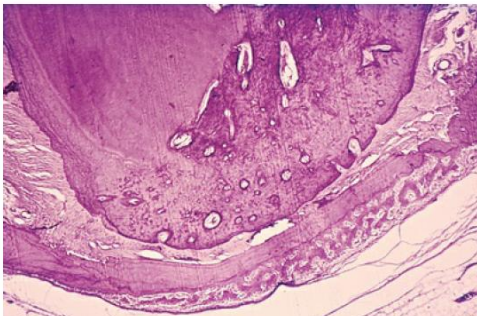


FIG. 25.6 Apical area of a premolar subjected to experimental occlusal trauma in a dog causing intrusion of the tooth and areas of necrosis in the periodontal ligament. Note the active bone formation on the outer aspect of the bone and the resorptive activity in the periphery of the necrotic site.

Depending on its severity, peripheral buttressing may produce a shelflike thickening of the alveolar margin, which is referred to as *lipping*, or a pronounced bulge in the contour of the facial and lingual bone. **Cartilage-like material sometimes develops in the periodontal ligament space as an aftermath of the trauma. The formation of crystals from erythrocytes has also been demonstrated.**

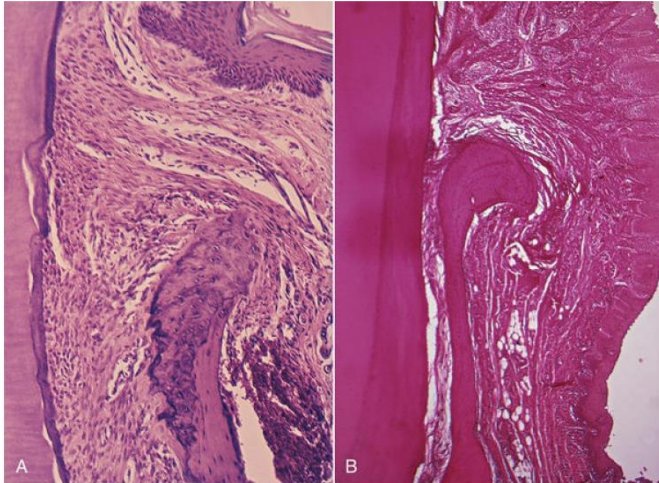


FIG. 25.7 (A) Widening of the periodontal ligament space in the cervical area and a change in the shape of the marginal alveolar bone as a result of chronic prolonged trauma from occlusion in rats. (B) Comparable changes in the shape of the marginal bone found in a human autopsy case.

Stage III: Adaptive Remodeling of the Periodontium

If the repair process cannot keep pace with the destruction caused by the occlusion, the periodontium is remodeled in an effort to create a structural relationship in which the forces are no longer injurious to the tissues. *This results in a widened periodontal ligament, which is funnel shaped at the crest, and angular defects in the bone, with no pocket formation. The involved teeth become loose.* Increased vascularization has also been reported.

After adaptive remodeling of the periodontium, resorption and formation of the bone return to normal.

Effects of Insufficient Occlusal Force

Insufficient occlusal force may also be injurious to the supporting periodontal tissues. Insufficient stimulation causes thinning of the periodontal ligament, atrophy of the fibers, osteoporosis of the alveolar bone, and a reduction in bone height. Hypofunction can result from an open-bite relationship, an absence of functional antagonists, or unilateral chewing habits that neglect one side of the mouth.

Reversibility of Traumatic Lesions

Trauma from occlusion is reversible. When trauma is artificially induced in experimental animals, the teeth move away or intrude into the jaw. When the impact of the artificially created force is relieved, the tissues undergo repair. Although trauma from occlusion is reversible under such conditions, it does not always correct itself, and therefore it is not always temporary or of limited clinical significance. **The injurious force must be relieved for repair to occur.** If conditions in humans do not permit the teeth to escape from or adapt to excessive occlusal force, periodontal damage persists and worsens.

The presence of inflammation in the periodontium as a result of plaque accumulation may impair the reversibility of traumatic lesions.

Effects of Excessive Occlusal Forces on Dental Pulp

The effects of excessive occlusal forces on the dental pulp have not been established. Some clinicians report the disappearance of pulpal symptoms after the correction of excessive occlusal

forces. Pulpal reactions have been noted in animals subjected to increased occlusal forces, but these did not occur when the forces were minimal and occurred over short periods.

Relationship Between Plaque-Induced Periodontal Diseases and Trauma From Occlusion

Numerous studies have been performed that have attempted to determine the mechanisms by which trauma from occlusion may affect periodontal disease.

Trauma from occlusion in humans, however, is the result of forces that act alternatively in opposing directions. These were analyzed in experimental animals with “jiggling forces,” which were usually produced by a high crown in combination with an orthodontic appliance that would bring the traumatized tooth back to its original position when the force was dissipated by separating the teeth. With another method, the teeth were separated by wooden or elastic material wedged interproximally to displace a tooth toward the opposite proximal side. After 48 hours, the wedge was removed, and the procedure was repeated on the opposite side.

These studies resulted in a combination of changes produced by pressure and tension on both sides of the tooth, with an increase in the width of the ligament and increased tooth mobility.

None of these methods caused gingival inflammation or pocket formation, and the results essentially represented different degrees of functional adaptation to increased forces. To mimic the problem in humans more closely, studies were then conducted on the effect produced by jiggling trauma and simultaneous plaque-induced gingival inflammation.

The accumulation of bacterial plaque that initiates gingivitis and results in periodontal pocket formation affects the marginal gingiva, but **trauma from occlusion occurs in the supporting tissues and does not affect the gingiva . The marginal gingiva is unaffected by trauma from occlusion because its blood supply is not affected**, even when the vessels of the periodontal ligament are obliterated by excessive occlusal forces.

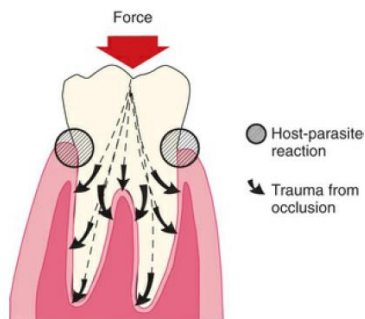


FIG. 25.9 The reaction between dental plaque and the host takes place in the gingival sulcus region. Trauma from occlusion appears in the tissues that are supporting the tooth.

It has been repeatedly proved that trauma from occlusion does not cause pockets or gingivitis and that it also does not increase gingival fluid flow. Furthermore, experimental trauma in dogs does not influence the bacterial repopulation of pockets after scaling and root planing. However, mobile teeth in humans harbor significantly higher proportions of *Campylobacter rectus* and *Peptostreptococcus micros* than do non mobile teeth.

1-Glickman's concept.

Glickman and Smulow proposed the theory in the early 1960s that a traumatogenic occlusion may act as a cofactor in the progression of periodontitis. This theory is known as the “co destructive theory.”

Glickman (1965, 1967) claimed that, if forces of an abnormal magnitude are acting on teeth harboring subgingival plaque, then the alley of the spread of a plaque-associated gingival lesion can be altered.

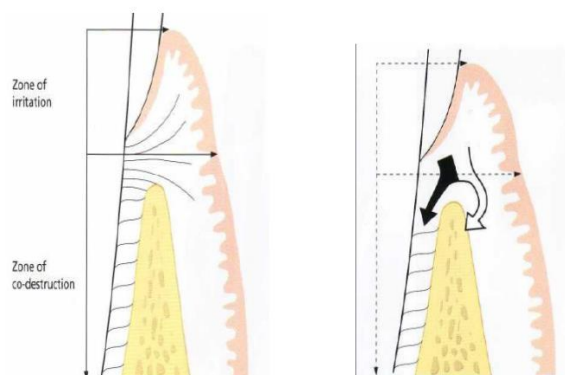
The periodontal structures can be divided into:

1. The zone of irritation.
2. The zone of codestruction.

The **zone of irritation** consists of the **marginal and interdental gingiva**. The soft tissue zone is surrounded by the hard tissue (the tooth) on one side and has no impact by occlusal forces. This means that gingival inflammation cannot be initiated by TFO but rather due to irritation from plaque.

The **zone of codestruction** consists of the **periodontal ligament, cementum, and alveolar bone** and is coronally delineated by the **transseptal and the dentoalveolar collagen fiber bundles**. The inflammatory lesion in the zone of irritation can, in teeth not subjected to trauma, propagate into the alveolar bone, while in teeth subjected to trauma from occlusion, the inflammatory infiltrate spreads directly into periodontal ligament.

In conclusion; As long as inflammation is confined to the gingiva, the inflammatory process is not affected by occlusal forces. When inflammation extends from the gingiva into the supporting periodontal tissues (i.e., when gingivitis becomes periodontitis), plaque-induced inflammation enters the zone that is influenced by occlusion, (*zone of co-destruction*).



2-Waerhaug's concept

Waerhaug and Glickman, both had examined autopsy specimens, but **Waerhaug** also measured the distance from the subgingival plaque to the periphery of the associated inflammatory cell infiltrate in the gingiva and the adjacent alveolar bone surface. He came to the conclusion that angular bony defects and also infrabony pockets occur equally often at periodontal sites which are unaffected by TFO like in traumatized teeth.

In other words, he refuted the hypothesis that *trauma from occlusion* played a role in the spread of a gingival lesion into the "zone of co-destruction". The loss of connective attachment and the resorption of bone around teeth are, according to Waerhaug, exclusively the result of inflammatory lesions associated with subgingival plaque. Waerhaug concluded that angular bony defects and infrabony pockets occur when the subgingival plaque of one tooth has reached a

more apical level than the microbiota on the neighboring tooth, and when the volume of the alveolar bone surrounding the roots is comparatively large.

ANIMAL STUDIES

Two groups have studied this topic experimentally (experimental periodontitis in animals), with conflicting results, probably because of the different methods used.

1---**The Eastman Dental Center group in Rochester**, New York, used squirrel monkeys, produced trauma by repetitive interdental wedging, and added mild to moderate gingival inflammation; experimental times were up to 10 weeks. **They reported that the presence of trauma did not increase the loss of attachment induced by periodontitis.**

2---**The University of Gothenburg group in Sweden** used beagle dogs, produced trauma by placing cap splints and orthodontic appliances, and induced severe gingival inflammation; experimental times were up to 1 year. **This group found that occlusal stresses increase the periodontal destruction induced by periodontitis.**

When trauma from occlusion is eliminated, a substantial reversal of bone loss occurs, except in the presence of periodontitis. This indicates that inflammation inhibits the potential for bone regeneration. Thus it is important to eliminate the marginal inflammatory component in cases of trauma from occlusion, because the presence of inflammation affects bone regeneration after the removal of the traumatizing contacts. It has also been shown in experimental animals that trauma from occlusion does not induce progressive destruction of the periodontal tissues in regions that are kept healthy after the elimination of preexisting periodontitis.

Trauma from occlusion also tends to **change the shape of the alveolar crest**. The **change in shape consists of a widening of the marginal periodontal ligament space**, a **narrowing of the interproximal alveolar bone**, and a **shelflike thickening of the alveolar margin**. Therefore although trauma from occlusion does not alter the inflammatory process, it changes the architecture of the area around the inflamed site. Thus in the absence of inflammation, the response to trauma from occlusion is limited to adaptation to the increased forces. In the presence of inflammation, however, the changes in the shape of the alveolar crest may be conducive to angular bone loss, and existing pockets may become intrabony.

Other theories that have been proposed to explain the interaction of trauma and inflammation include the following:

- Trauma from occlusion may alter the pathway of the extension of gingival inflammation to the underlying tissues. This may be favored by the reduced collagen density and the increased number of leukocytes, osteoclasts, and blood vessels in the coronal portion of increasingly mobile teeth. Inflammation may then proceed to the periodontal ligament rather than to the bone. Resulting bone loss would be angular, and pockets could become intrabony.
- Trauma-induced areas of root resorption uncovered by apical migration of the inflamed gingival attachment may offer a favorable environment for the formation and attachment of plaque and calculus and therefore may be responsible for the development of deeper lesions.
- Supragingival plaque can become subgingival if the tooth is tilted orthodontically or if it migrates into an edentulous area, which results in the transformation of a suprabony pocket into an intrabony pocket.

- Increased mobility of traumatically loosened teeth may have a pumping effect on plaque

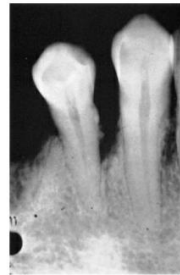

FIG. 25.11 Calculus and bone loss on the mesial surface of a canine that has drifted distally.

metabolites, thereby increasing their diffusion.

Clinical Signs of Trauma From Occlusion Alone

The most common clinical sign of trauma to the periodontium is *increased tooth mobility*. During the injury stage of trauma from occlusion, the destruction of periodontal fibers occurs, which increases tooth mobility. During the final stage, the accommodation of the periodontium to increased forces entails a widening of the periodontal ligament, which also leads to increased tooth mobility.

Although this tooth mobility is greater than the so-called normal mobility, it cannot be considered pathologic, because it is an adaptation and not a disease process. If it does become progressively worse, it can then be considered pathologic.

-Other causes of increased tooth mobility include advanced bone loss, inflammation of the periodontal ligament of periodontal or periapical origin, and some systemic causes (e.g., pregnancy). The destruction of surrounding alveolar bone, such as occurs with osteomyelitis or jaw tumors, may also increase tooth mobility. Other clinical signs of TFO may include Fremitus (sensitive), Pain, Tooth migration, Attrition, Muscle/joint pain and Fractures, chipping

Radiographic signs of trauma from occlusion may include the following:

1. Increased width of the periodontal space, often with thickening of the lamina dura along the lateral aspect of the root, in the apical region, and in bifurcation areas. These changes do not *necessarily* indicate destructive changes, because they may result from thickening and strengthening of the periodontal ligament and alveolar bone, thereby constituting a favorable response to increased occlusal forces.
2. A vertical rather than horizontal destruction of the interdental septum.
3. Radiolucency and condensation of the alveolar bone.
4. Root resorption, hypercementosis

Pathologic Tooth Migration

Pathologic migration refers to tooth displacement that results when the balance among the factors that maintain physiologic tooth position is disturbed by periodontal disease. Pathologic migration is relatively common. It may be an early sign of disease, or it may occur in association with gingival inflammation and pocket formation as the disease progresses.

Pathologic migration occurs most frequently in the anterior region, but posterior teeth may also be affected. The teeth may move in any direction, and the migration is usually accompanied by mobility and rotation. Pathologic migration in the occlusal or incisal direction is termed *extrusion*. All degrees of pathologic migration are encountered, and one or more teeth may be affected.

It is important to detect migration during its early stages and to prevent more serious involvement by eliminating the causative factors. Even during the early stage, some degree of bone loss occurs.

Pathogenesis

Two major factors play a role in maintaining the normal position of the teeth: the health and normal height of the periodontal attachment apparatus and the forces exerted on the teeth. The latter includes the forces of occlusion and pressure from the lips, cheeks, and tongue. Factors that are important in relation to the forces of occlusion include the following:

(1) tooth morphologic features and cuspal inclination; (2) the presence of a full complement of teeth; (3) a physiologic tendency toward mesial migration; (4) the nature and location of contact point relationships; (5) proximal, incisal, and occlusal attrition; and (6) the axial inclination of the teeth.

Alterations in any of these factors start an interrelated sequence of changes in the environment of a single tooth or group of teeth that may result in pathologic migration. Thus pathologic migration occurs under conditions that weaken the periodontal support, that increase or modify the forces exerted on the teeth, or both.

Weakened Periodontal Support

The inflammatory destruction of the periodontium in patients with periodontitis creates an imbalance between the forces that maintain the tooth in position and the occlusal and muscular forces the tooth ordinarily needs to bear. The tooth with weakened support is unable to maintain its normal position in the arch and moves away from the opposing force unless it is restrained by proximal contact.

The force that moves the weakly supported tooth may be created by factors such as occlusal contacts or pressure from the tongue.

It is important to understand that the abnormality of pathologic migration rests with the weakened periodontium; the force itself is not necessarily abnormal. Forces that are acceptable to an intact periodontium become injurious when periodontal support is reduced, as in the tooth with abnormal proximal contacts.

Abnormally located proximal contacts convert the normal anterior component of force to a wedging force that causes occlusal or incisal movement of the tooth. The wedging force, which can be withstood by the intact periodontium, causes the tooth to extrude when the periodontal support is weakened by disease. *As its position changes, the tooth is subjected to abnormal occlusal forces, which aggravate the periodontal destruction and the tooth migration.*

Pathologic migration may continue after a tooth no longer contacts its antagonist. Pressures from the tongue, the food bolus during mastication, and the proliferating granulation tissue provide the force.

Pathologic migration is also an early sign of localized aggressive periodontitis. Weakened by the loss of periodontal support, the maxillary and mandibular anterior incisors drift labially and extrude, thereby creating diastemata between the teeth.

Changes in the Forces Exerted on the Teeth

Changes in the magnitude, direction, or frequency of the forces exerted on the teeth can induce the pathologic migration of a tooth or group of teeth. These forces do not have to be abnormal to cause migration if the periodontium is sufficiently weakened. Changes in the forces may result from unreplaced missing teeth or other causes.

Unreplaced Missing Teeth

The drifting of teeth into the spaces created by unreplaced missing teeth often occurs. Drifting differs from pathologic migration in that it does not result from the destruction of the periodontal tissues.

However, it usually creates conditions that lead to periodontal disease, and thus the initial tooth movement is aggravated by a loss of periodontal support

Drifting generally occurs in a mesial direction in combination

with tilting or extrusion beyond the occlusal plane. The premolars frequently drift distally.

Although drifting is a common sequela when missing teeth are not replaced, it does not always occur

Failure to Replace First Molars

The pattern of changes that may follow the failure to replace missing first molars is characteristic. In extreme cases, it consists of the following:

1. The second and third molars tilt mesially, which results in a decrease in vertical dimension
2. The premolars move distally, and the mandibular incisors tilt or drift lingually. While drifting distally, the mandibular premolars lose their intercuspal relationship with the maxillary teeth, and they may tilt distally.
3. Anterior overbite is increased. The mandibular incisors strike the maxillary incisors near the gingiva or traumatize the gingiva.

4. The maxillary incisors are pushed labially and laterally

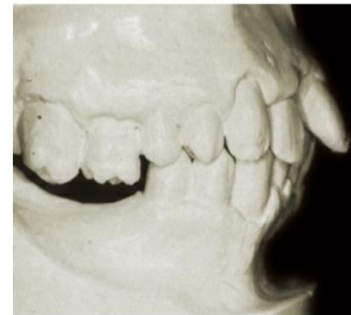

FIG. 25.15 Maxillary incisors pushed labially in a patient with bilateral unreplaced mandibular molars. Note the extrusion of the maxillary molars.

5. The anterior teeth extrude because the incisal apposition has largely disappeared.

6. Diastemata are created by the separation of the anterior teeth

The disturbed proximal contact relationships lead to food impaction, plaque accumulation that results in gingival inflammation, and pocket formation, which are followed by bone loss and tooth mobility. Occlusal disharmonies created by the altered tooth positions traumatize the supporting tissues of the periodontium and aggravate the destruction caused by the inflammation. The reduction in periodontal support leads to the further migration of the teeth and the mutilation of the occlusion.

Other Causes

Trauma from occlusion may cause a shift in tooth position either by itself or in combination with inflammatory periodontal disease. The direction of movement depends on the occlusal force.

Pressure from the tongue may cause drifting of the teeth in the absence of periodontal disease, or it may contribute to the pathologic migration of teeth with reduced periodontal support

When tooth support has been weakened by periodontal destruction, *pressure from the granulation tissue of periodontal pockets* has been mentioned as contributing to pathologic

migration. The teeth may return to their original positions after the pockets are eliminated, but if more destruction has occurred on one side of a tooth than on the other, the healing tissues tend to pull in the direction of less destruction.

Treatment Outcomes

1. Reduce/eliminate tooth mobility
2. Eliminate occlusal prematurity's & fremitus
3. Eliminate parafunctional habits
4. Prevent further tooth migration
5. Decrease/stabilize radiographic changes

Therapy

Primary Occlusal Trauma:

- Selective grinding
- Habit control
- Orthodontic movement
- inter occlusal appliance

Secondary Occlusal Trauma:

- Splinting
- Selective grinding
- Orthodontic movement

Unsuccessful Therapy

1. Increasing tooth mobility
2. Progressive tooth migration
3. Continued client discomfort
4. Premature contacts remain
5. No change in radiographs/worsening
6. Parafunctional habits remain
7. TMJ problems remain or worsen

conclusion

Experiments carried out in humans as well as animals, have produced convincing evidence that neither unilateral forces nor jiggling forces, applied to teeth with a healthy periodontium, result in pocket formation or in loss of connective tissue attachment. Trauma from occlusion cannot induce periodontal tissue breakdown.

Trauma from occlusion does, however, result in resorption of alveolar bone leading to an increased tooth mobility which can be of a transient or permanent character. This bone resorption

with resulting increased tooth mobility should be regarded as a physiologic adaptation of the periodontal ligament and surrounding alveolar bone to the traumatizing forces, i.e. to altered functional demands.

In teeth with progressive, plaque-associated periodontal disease, trauma from occlusion may, however, under certain conditions enhance the rate of progression of the disease, i.e. act as a co-factor in the destructive process. From a clinical point of view, this knowledge strengthens the demand for proper treatment of plaque associated periodontal disease. This treatment will arrest the destruction of the periodontal tissues even if the occlusal trauma persists. A treatment directed towards the trauma alone, however, i.e. occlusal adjustment or splinting, may reduce the mobility of the traumatized teeth and result in some regrowth of bone, but it will not arrest the rate of further breakdown of the supporting apparatus caused by plaque.