

Parasitology

Tapeworms (cestodes)

Objectives: to study the general characteristics of medically important tapeworms including their morphology, life cycle, pathogenesis and laboratory diagnosis.

General characters:

Tapeworms is a group of parasites considered to have limited distribution and have the following characters;

- All tapeworms utilize more than one host during their life cycle except *Hymenolepis nana* in which life cycle takes place in a single host.
- They have ribbon- like shape whose bodies are made up of many similar segments or proglottids, these segments are flattened dorsoventrally.
- The anterior end, the 'head', is known as the scolex and has well developed adhesive organ.
- Adult tapeworm inhabits the small intestine of vertebrates. While the larvae inhabit the tissues of vertebrates & invertebrates.
- All tapeworms are hermaphrodites, they have both male and female reproductive organs in the same segment.
- They have no gut, absorption of nutrients taking place through the outer protective layer known as integument (body wall).

Adult tapeworms produce minimal intestinal irritation and few systemic effects. All symptoms have been attributed to chemical effects (toxic byproducts) and

mechanical effects. The absorbed byproducts which secreted by the worm may create systemic intoxication, diarrhea and vomiting.

Mechanical action cause slight irritation in the intestinal mucosa, and considerable disturbances in the normal function of GIT which cause chronic indigestion. The worm utilize the host's nutrients which lead to hunger pain & loss of weight.

– Adult tapeworm composed of:

1– Scolex (head): the point of attachment to mucous membrane. The scolex could be armed or unarmed depend on the presence or absence of hooklets which are spine like structure.

2–Neck: the region just behind the head and considered as the region of growth, from the posterior end of the neck , the process of strobilization start.

3–Strobila: a chain of segments or proglottids composed of:

–immature proglottid posses undifferentiated sex organs.

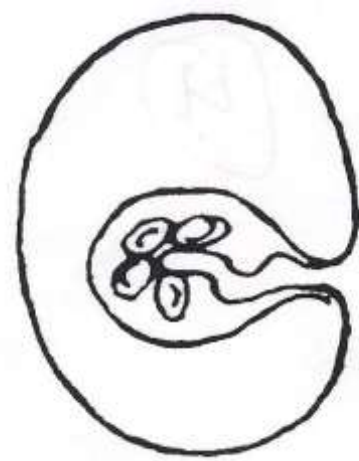
–mature proglottid contain well differentiated sex organs of both male and female .

–gravid proglottid ,all reproductive organs will be atrophy except the uterus which filled with eggs .

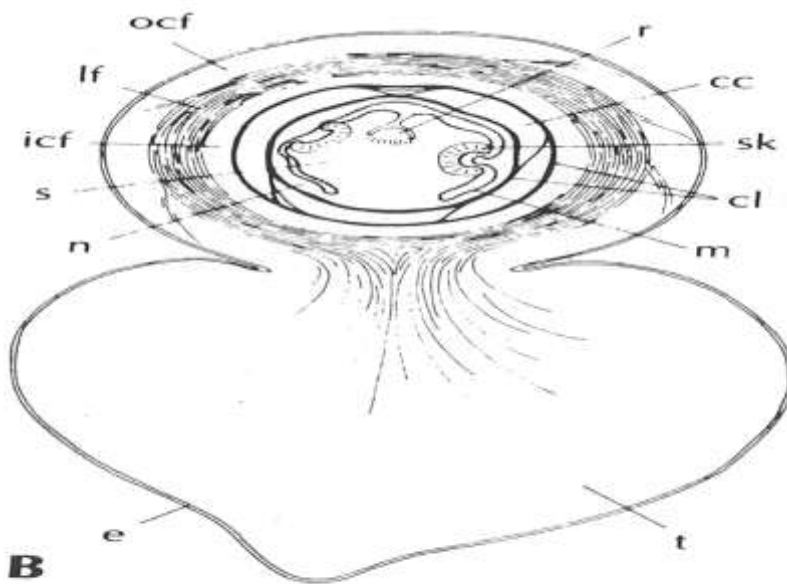
Type of Cestodes larvae :

A – Bladder larvae :

1. Cysticercus : a true bladder worm, It is oval in shape, about 5x10 mm has fluid- filled membranous bladder with invaginated scolex. e.g. larvae of *Taenia solium* & *Taenia saginata*.



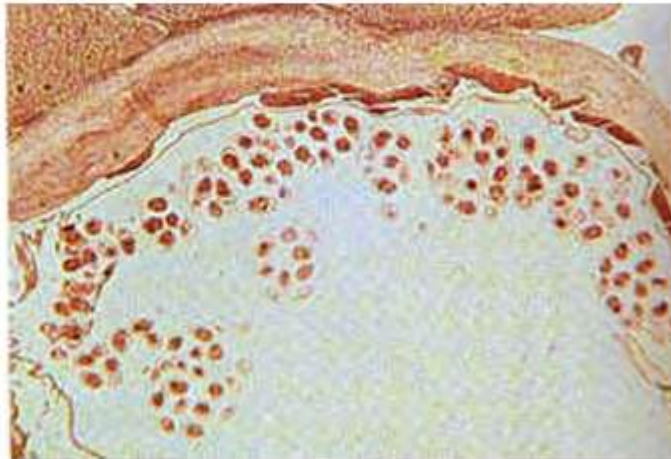
2. Cysticercoid ;is not a true bladder worm, it has bladder filled with parenchyma cells and invaginated scolex and a caudal appendage . e.g. larva of *Hymenolepis spp.*



3-Hydatid cyst: large bladder composed of two layers, outer laminated and inner germinal layers and filled with hydatid fluid . It is form multiple scolices and numerous daughter or brood capsules. e.g. larva of *Echinococcus spp.*

Hydatid cyst

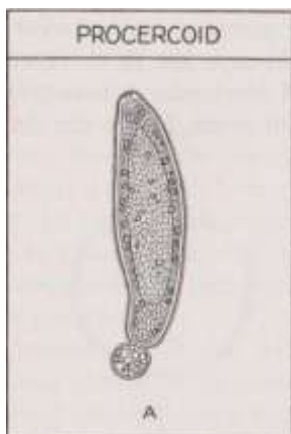
Hydatid cyst showing a row of brood capsules attached to the germinal layer.



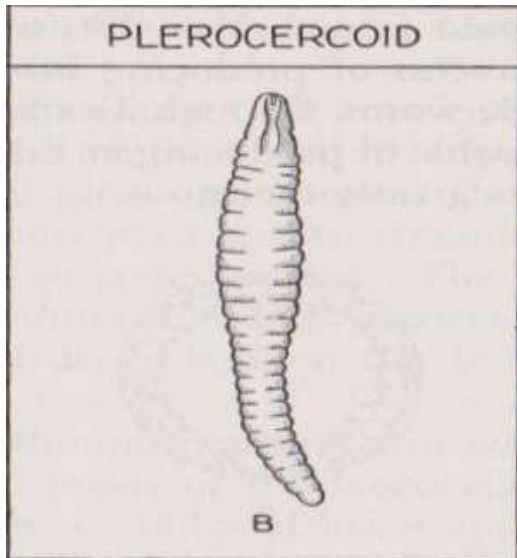
3. Coenurus : A bladder worm resembles Cysticercus except that its bladder generally is much larger and bears numerous scolices rather than one e.g. *larva of Taenia multiceps* .

B – Solid larvae:

1. Proceroid : sac – like solid body with cephalic invagination and caudal spherical appendage at its posterior end which contain 6 hooks e.g. *Diphylobothrium latum*.



2–Plerocercoid : chalky white solid structure with pseudo segmentation composed of caudal solid appendage and invaginated head in the neck
e.g. *Diphyllobothrium latum*.



–Diagnosis of adult tapeworm infection is achieved by finding characteristic eggs, Proglottids or both, involved in feces. Serological diagnosis is not helpful.

– ***Classification of Cestodes:***

– **Class Cestoidea include 2 orders:**

1–Order Cyclophyllidea

2–Order Pseudophyllidea

– ***Cyclophyllidea include ;***

1– *Taenia saginata* (beef tapeworm)

2– *T. solium* (pork tapeworm)

3- *T. multiceps* (gid worm)

4- *Echinococcus spp.* (hydatid worm)

5- *Hymenolepis nana* (dwarf tapeworm) } parasite of rodents

6- *H. diminuta* (rat tapeworm) } parasite of rodents

7- *D. caninum* (dog tapeworm)

Pseudophyllidea:- include only one species of medical importance,

Diphyllobothrium latum (broad or fish tapeworm) .

Taenia saginata

Morphology

The length of adult worm from 4-10 m , it may be over 12m in some situations.

Scolex: does not have a rostellum or hooks so

it's describe as an-unarmed scolex.

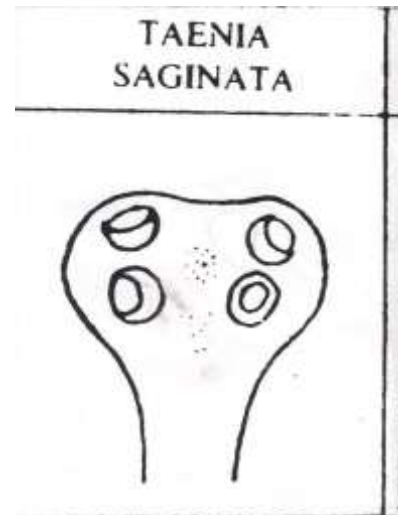It's quadrate in its cross section &

provided with 4 muscular suckers.

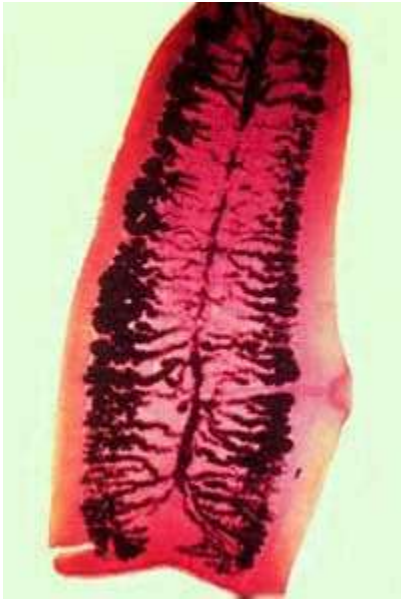
Strobila: 1000-2000 proglottids

1-immature segments ;they are small ,wider than long with not well differentiated reproductive organs .

2-mature segments ;almost square in shape with well differentiated sex organs of both male and female .



3-gravid segments ;longer than wide consist of median uterus with 15–30 lateral uterine branches with unilateral genital pore .



Gravid *T. saginata* segment 15–30

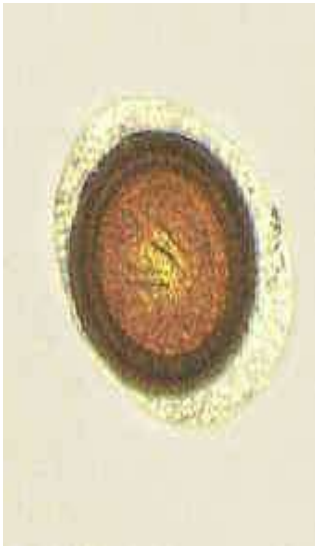lateral uterine branches

Habitat ;Adult worm inhabit upper part of the small intestine of man .

Egg: if you want to describe the egg of any

helminthic parasite you should look for size, shape, color, content (SS CC)

Size ; 36 –50 micron in diameter.



Shape; globular or spherical

Color: yellowish–brown

Contents: hooked ball embryo (oncosphere) with 6 hooks (hexacanth embryo) surrounded by thick, radially striated brown embryophore . The embryophore surround by egg shell which is extremely delicate & usually lost in intestine.

Larval stage: *Cysticercus bovis*, it is oval, fluid filled bladder larva with invaginated unarmed scolex.

–Life cycle:

Intermediate host: cattle

Final host: man

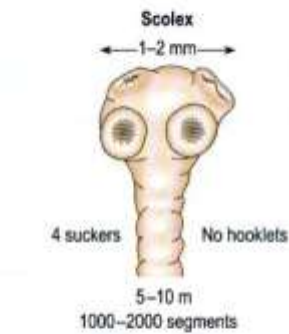
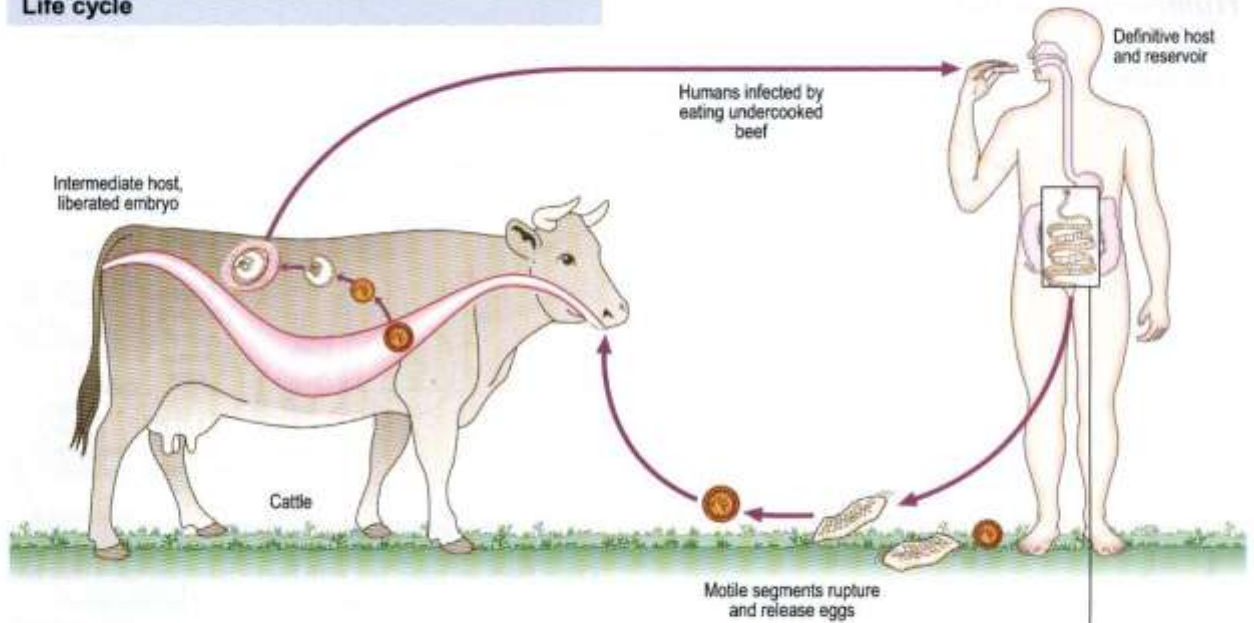
The cattle will be infected by ingestion the eggs while grassing on contaminated soil or contaminated drinking water. In the duodenum where the reaction is alkaline the embryo will be liberated & penetrate the intestinal wall by means of its hooks, then reach circulation & carried to different parts of the body & then develop to *Cysticercus bovis* .

The common sites of infection in cattle are: muscle of jaw, diaphragm, heart, shoulder and esophagus. Man will be infected by eating insufficiently cooked meat which contain *C. bovis*.

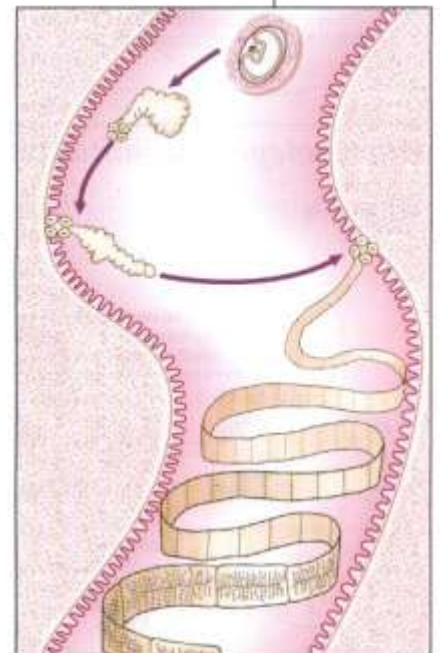
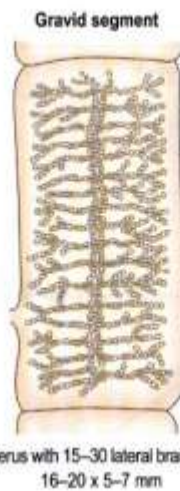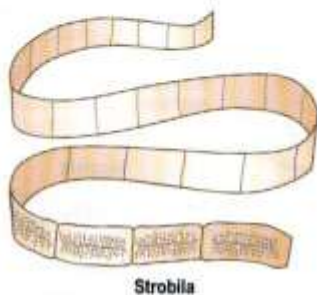
The meat will be digested & the larva will be released & the scolex become evaginated and attached itself to the mucous membrane & develop to an adult worm within 3 months.

Taenia saginata (beef tape worm)

Life cycle



Scolex evaginates in small intestine and attaches itself to mucosa of jejunum



Maturation time 8-10 weeks.
 Life span up to 25 years

Pathology and Clinical features

Usually there is no pathology as *Cysticercus bovis* is unknown in humans. Occasionally there is vague alimentary upset.

Laboratory diagnosis

Gravid segments, ova and scolex can be found in faeces. Uterine branches of the mature segments may be seen in a crush preparation between two glass slides, or by Indian ink preparation, as in *T. solium*. Ova are also found on the perianal skin (on clear adhesive tape slides).

Distribution

Taenia saginata is found in beef-eating areas, especially in the tropics.

– Pathogenesis, pathology & symptomatology:

The disease is called beef tapeworm infection or taeniasis. Usually single worm develop in the intestine of man but more than one worm has been reported.

Beef tapeworm infection usually asymptomatic, but because of the large size of the worm, it may responsible for acute intestinal obstruction and because of utilizing the host's nutrients it's responsible for anemia and hunger pin. Sometimes an individual segment may be lodge in the appendicial lumen & initiate appendicitis. The absorbed byproducts may create systemic intoxication (symptoms such as food poisoning) and diarrhea.

The most common symptom is the discomfort or embarrassment of the patient because gravid segment will crawl out of the anus irrespective of defecation & this will result in mental worried to the patient.

–Diagnosis:

The basic diagnosis is don from a stool sample it's difficult to differentiate between eggs of *T.saginata*, & *T.solium* . Their eggs are morphologically identical so they are called *Taenia* spp, eggs, also eggs can be detected by swabbing peri-anal area or by scotch tape slide technique.

Specific diagnosis can be done by counting the number of lateral uterine branches in gravid segment or finding the unarmed scolex with whole worm after successful medication.

–Treatment:

The highly effective drugs are:

Niclosamide, praziquantel and mebendazole.

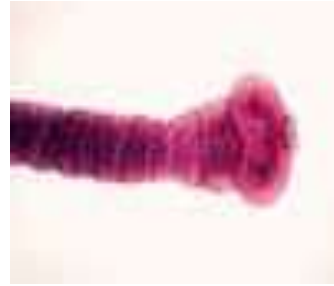Parasitology

Taenia solium (pork tapeworm)

Adult worm found in upper part of small intestine of humans, larval stage infects pigs and humans and causes cysticercosis in humans.

Normally adult worm is from 2 – 8 m.

Scolex: is globular in shape with 4 muscular suckers and two rows of hooks

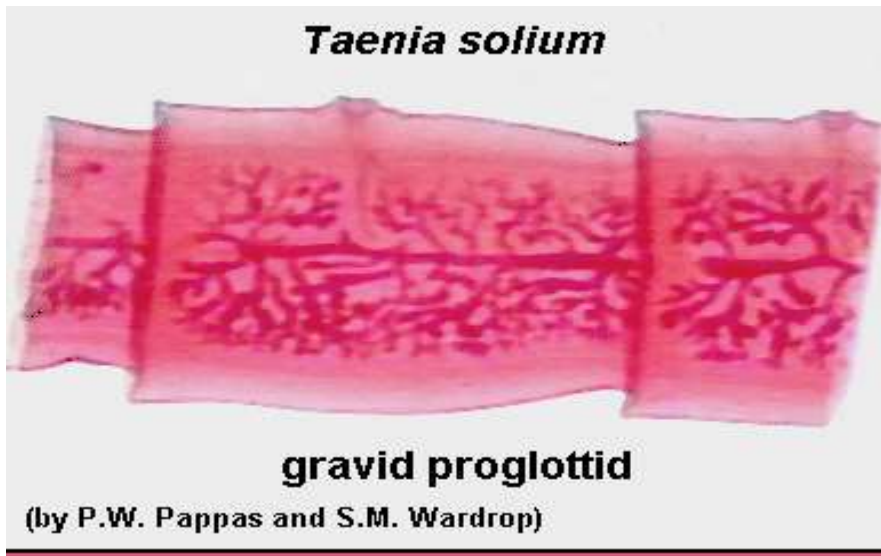


and rostellum, so it is called an armed scolex.



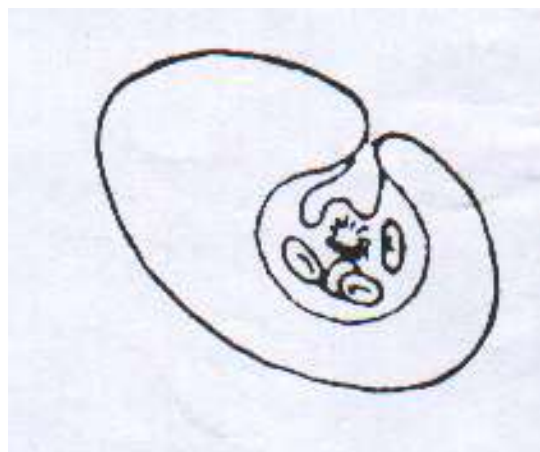
Strobila;800-1000 proglottides.

Gravid **segment:** It is longer than broad with median uterus and 7 – 13 lateral uterine branches.



Egg: *Taenia spp.* Egg Similar to that of *T. saginata*.

Larval stage: It is called *Cysticercus cellulosae*, which has a fluid filled bladder that is 0.5 – 1.5 cm in length with an armed invaginated scolex.



Cysticercus cellulosae of *T. solium*

Life cycle:

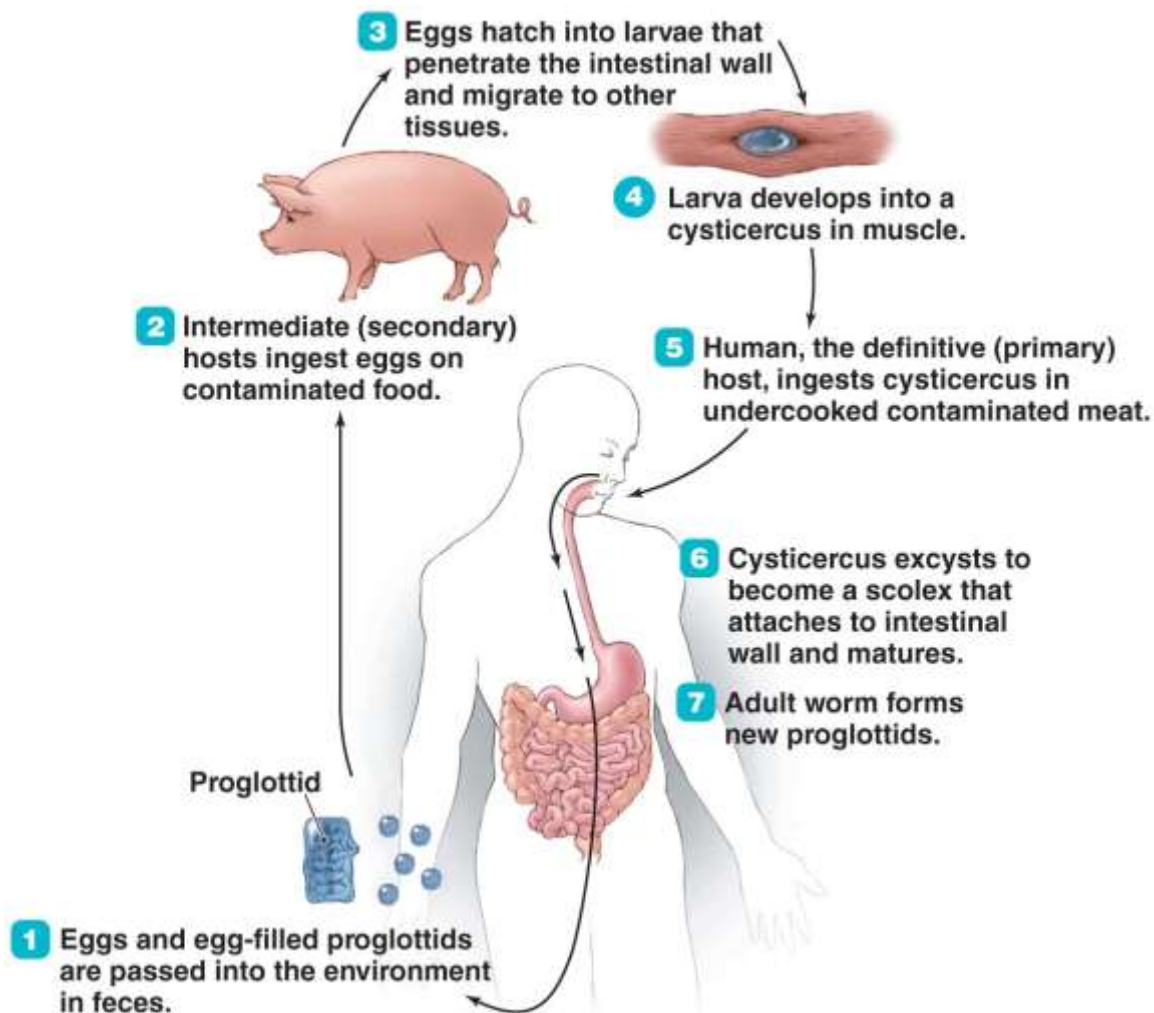
Intermediate host is the pig, but man some time acts as intermediate host and there will be a disease known as cysticercosis.

Pig will be infected by ingesting the eggs through contaminated food and water. In the small intestine where the reaction is alkaline eggs will be hatches and hexacanth embryo liberated which migrates through intestinal wall and reach blood circulation then reach different parts of the body and then it will be develop to *C. cellulosae* mainly in striated muscles .

Humans are infected either by ingestion of food contaminated with feces containing eggs (**hetero – infection**) or by **auto– infection** .

Autoinfection occur when human infected with adult worm can ingest eggs produced by that tapeworm , either through contaminated fingers (external autoinfection) or possibly , from proglottids carried into the stomach by reverse peristalsis (internal autoinfection) . Once eggs are ingested, oncosphere hatch in the intestine, invade intestinal wall , and migrate to striated muscles , as well as the brain , liver and other tissues , where they develop into *C. cellulosae* .

When humans ingest undercooked pork contain cysticerci the meat will be digested and invaginated scolex in cysticerci become evaginated and attached itself to the mucosa and develop to adult tapeworm and after 2 – 3 months, ova start appearing in stool sample .



Pathogenesis, pathology and symptomatology:

The disease is called Taeniasis or pork tapeworm infection .

Adult worm may cause slight irritation at the site of attachment in the mucosa , or it may cause intestinal obstruction . Ordinarily the worm produces no serious damage but at times it cause abdominal discomfort , hunger pain , chronic indigestion , persistent diarrhea or alternating of diarrhea and constipation .

In very rare cases , the scolex may perforate the intestinal wall and will initiate peritonitis .

Appendicitis also may occur due to migration of gravid segment in to the appendicial lumen .

The most frequent and severe disease caused by *T. solium* is cysticercosis . The severity of cysticercosis depends on location , size and number of the larvae in the tissues , as well as the host immune response .

The presence of growing larvae usually promote a typical cellular reaction around the parasite which lead to fibrosis and necrosis of the larvae and eventually calcification of the parasite .

The most frequent locations are subcutaneous and intramuscular tissues , then eye and brain . they also may occur in the liver , lung , heart and abdominal cavity . The size of the cyst depends on its age and its location .

The most serious type of cysticercosis is neurocysticercosis which can lead to epilepsy , lesion in the brain , blindness and tumor like growths .

Diagnosis :

Taenia spp. eggs in the stool sample diagnoses Taeniasis and not cysticercosis , and we cannot differentiate between *T.saginata* and *T. solium* infection.

Gravid segment in the feces diagnosis *T. solium* infection , by counting the number of lateral uterine branches (7 – 13) .

- If scolex is evacuated following medication an armed scolex differentiates this worm from *T. saginata* .

Serological tests are of little or no diagnostic value for detecting the adult worm

- In cysticercosis diagnosis primarily depend on confirming the presence of hooks in the scolex of *C. cellulosae* by histopathological examination of biopsy materials

Radiological tests e.g. X – ray , CT scans and MRI can also be used to detect the disease .

X – rays are used to identify calcified larvae in subcutaneous and muscle tissues and CT scans and MRI are used to find lesions in the brain and liver .

Serological tests are more helpful for identification of cysticercosis .

Taenia multiceps (gid worm)

Adult worm , from 40 – 60 cm in length , the scolex with double circle of hooks, it is found in the small intestine of dogs , wolves and foxes .

Larval stage is called *Coenurus cerebralis* is found in herbivores mammals

(sheep , goat and cattle), man infected accidentally larval stage produce a disease known as cerebral and ocular coenurosis .