

Possible cases of treponematoses in skulls from the oasis of Biskra, Algeria (Collection Dr Sanrey, Musée de l'Homme, Paris)

Amelie Alterauge¹, Martin Friess²¹ Department of Physical Anthropology, Institute of Forensic Medicine, University of Bern, Switzerland² Département Hommes, Nature, Sociétés et CNRS UMR 7206 & Muséum national d'Histoire naturelle, Musée de l'Homme, Paris, France

Introduction

The Musée de l'Homme (Paris, France) houses several collections of human crania that were assembled by French military surgeons during the 19th and 20th century. The collection of Dr. Auguste Nicolas Sanrey (*1848) contains 68 skulls from the oasis of Biskra (northeastern Algeria) (Fig. 1). The skulls were extracted from a local cemetery of unknown dating, but probably from the post-islamization period (8.-16. century AD) or later. Due to his service as surgeon major, Sanrey showed a strong interest in anthropometry and committed the skulls to the Société d'Anthropologie de Paris in the late 1870s. The skulls are labelled as "Berbers", meaning an ethnic group of primarily linguistic and cultural similarities in North Africa. The series probably contains the remains of sedentary farmers as well as pastoral nomads.

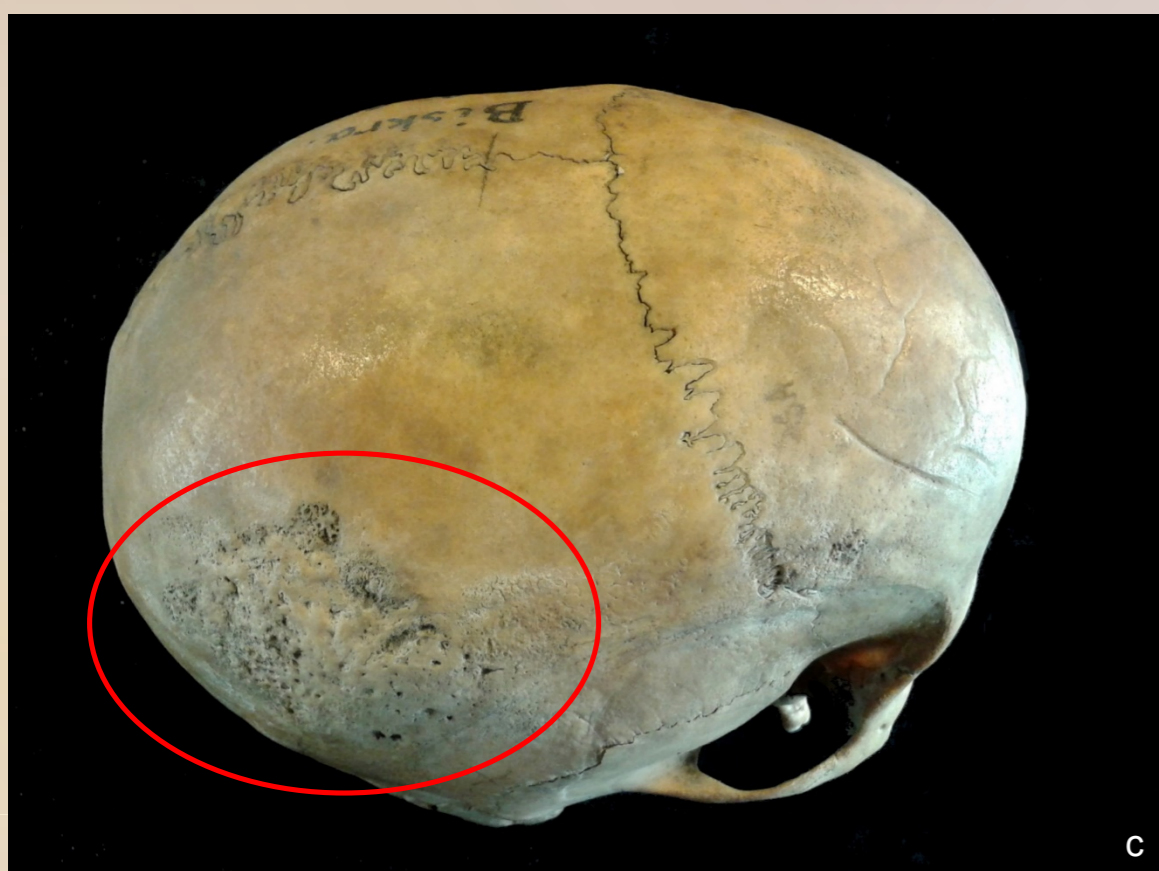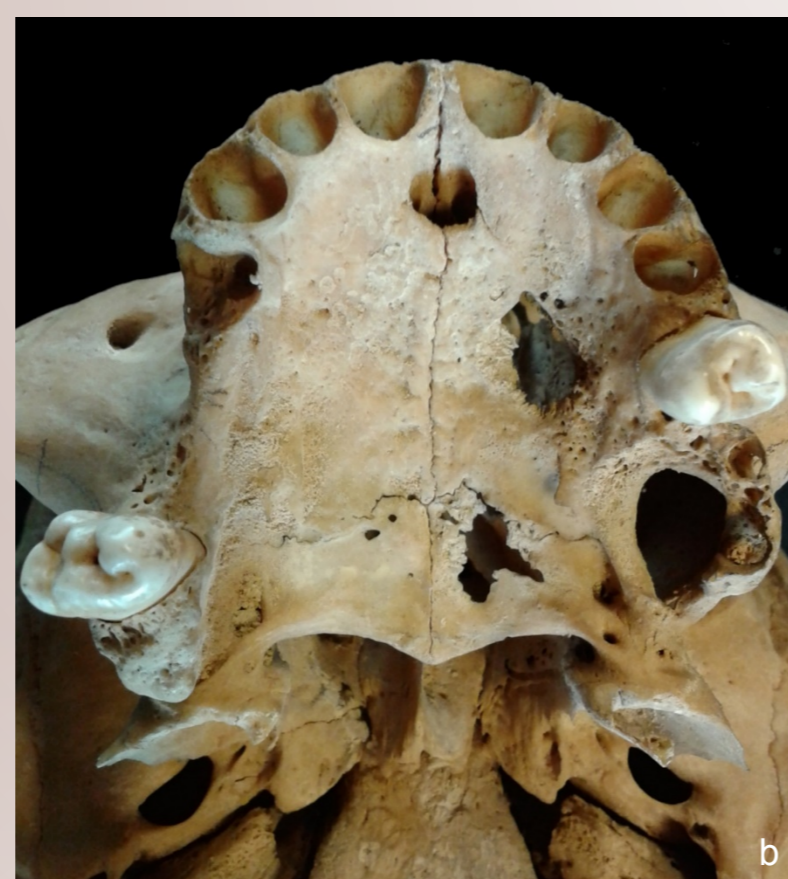
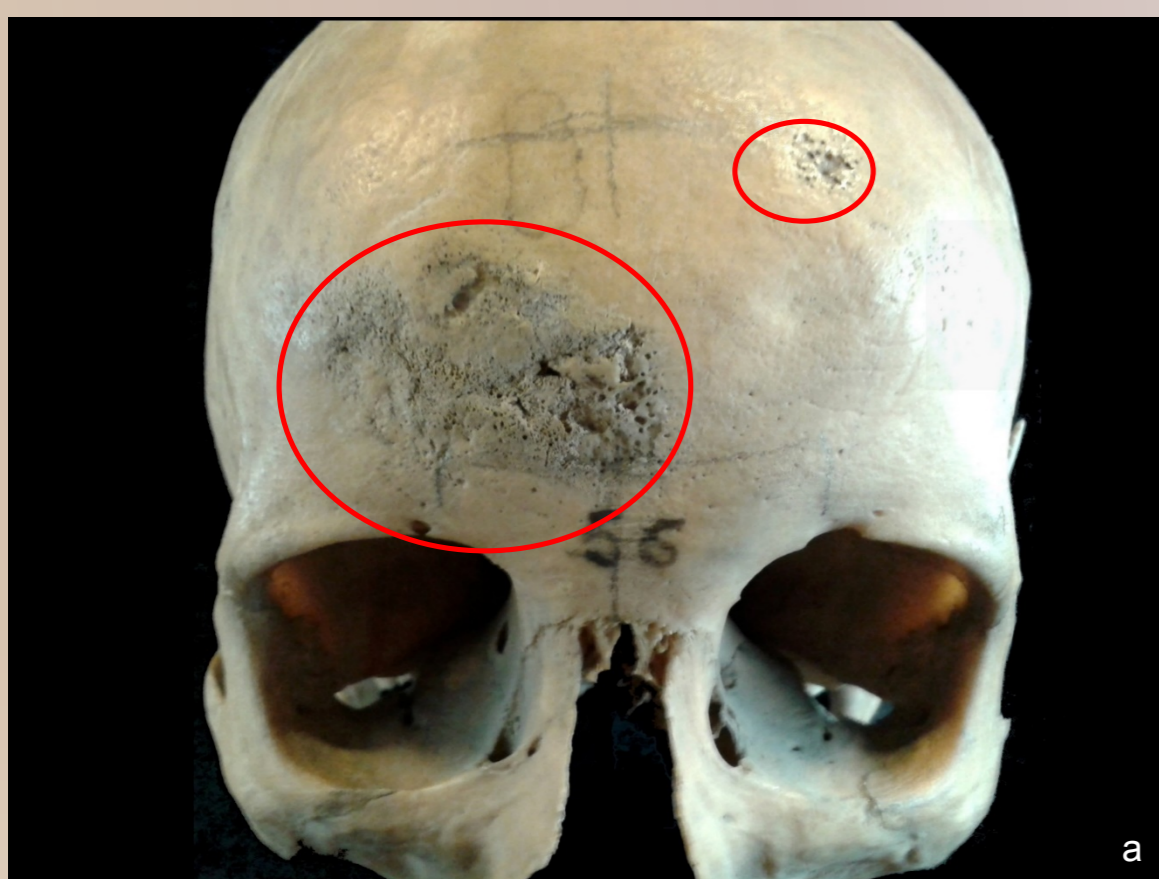


Fig. 3: Skull 33776 with pathological alterations.

a: Lesions on the frontal bone. The nasal bones were lost post-mortem.

b: Lytic perforations of the left hard palate.

c: Lesion on the right parietal bone.

Results

Skull 33776 belongs to an adult female (20-40 years).

It has several discrete lesions on the frontal and the right parietal bone (Fig. 3a, c). The outer cranial table shows confluent clustered pits next to circumvallate cavitations and radial scars. Some areas show irregular thickening with smooth surfaced reactive bone. Lytic perforations of the hard palate are also present (Fig. 3b).

Skull 33796 belongs to an adult male (20-40 years). Although the bone surface is partly eroded due to postmortem damage, it exhibits clearly pathological destruction of the outer table and diploë of the frontal bone (Fig. 4a, b). Sclerotic stellate scarring, cavitations and nodules cover a contiguous zone on the left frontal bone. Discrete sunken areas of bone gummas can be observed, too.

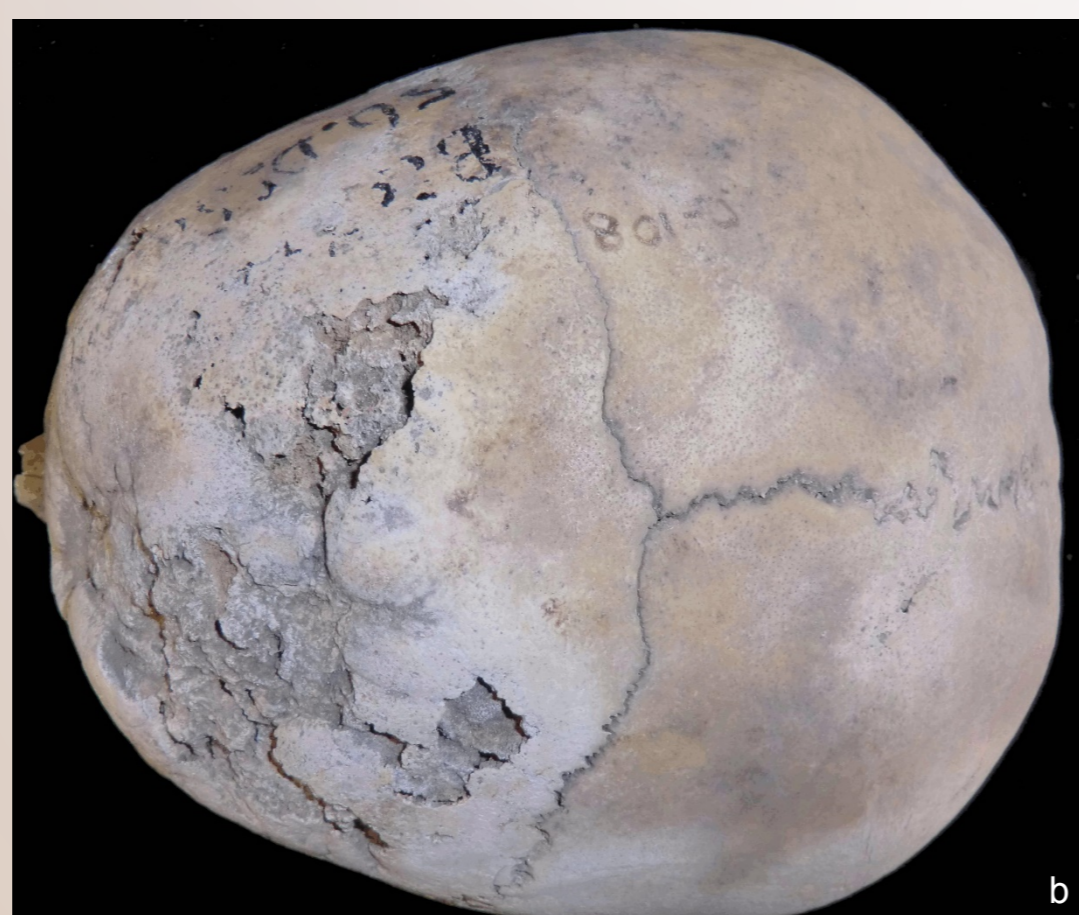
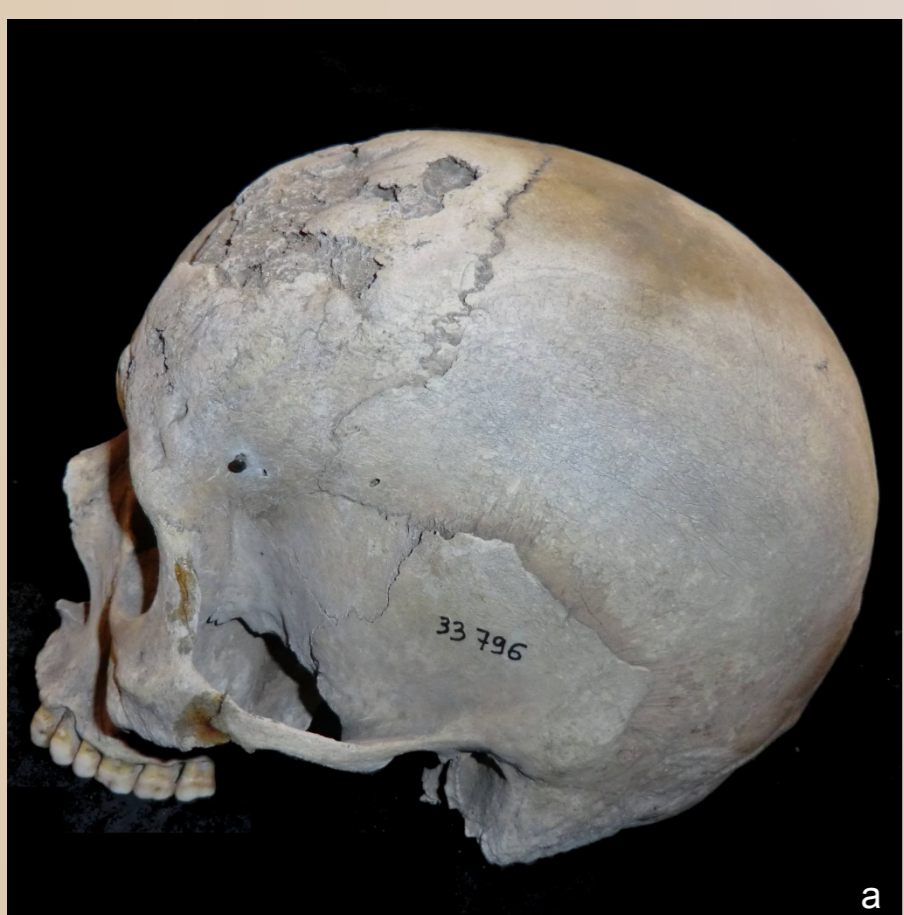

Fig. 4: Skull 33796 with extended lesion on the frontal bone

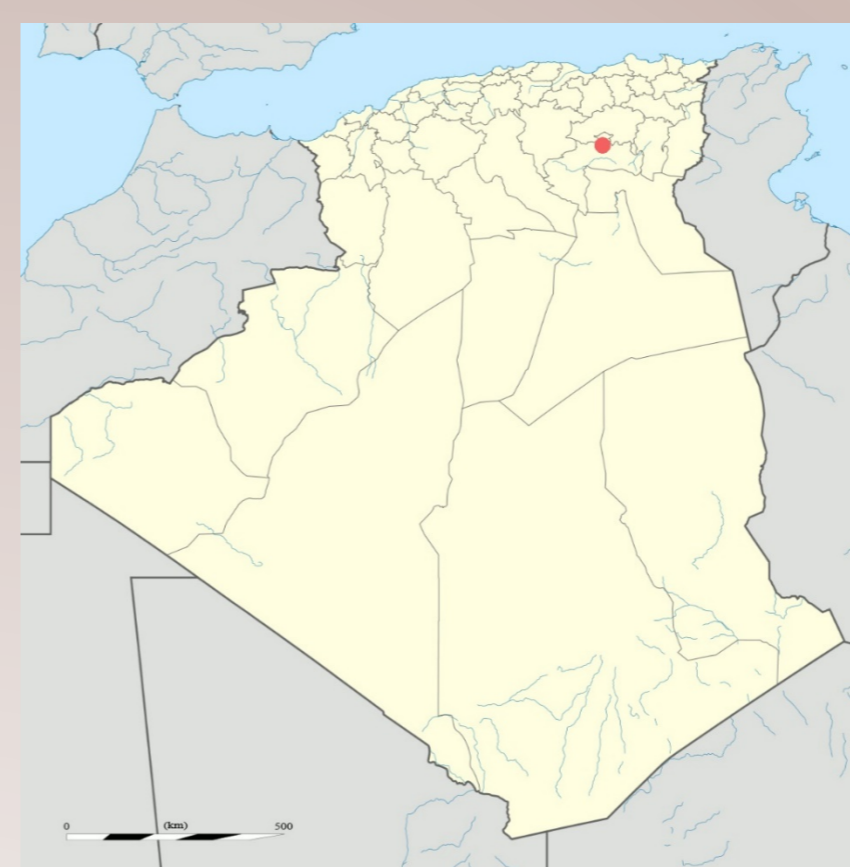

Fig. 1: Geographical location of the oasis of Biskra

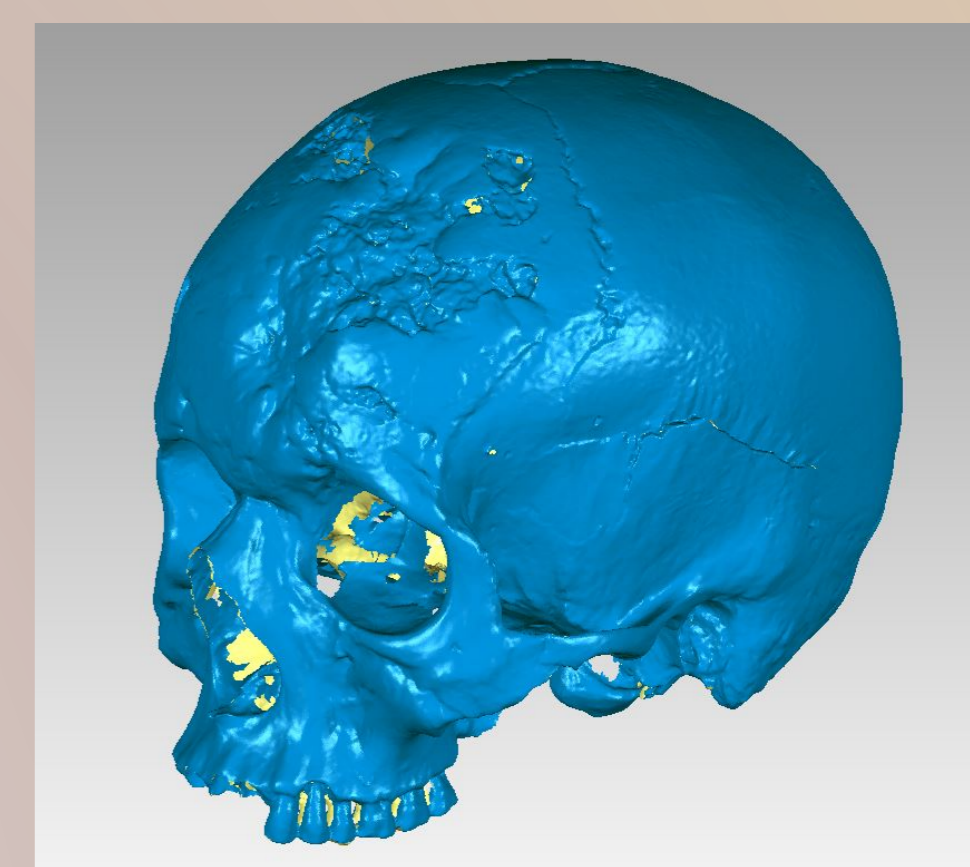


Fig. 2: 3D-surface scan of skull 33796

Material & Methods

Two skulls showed striking pathological alterations. The individuals' sex and age-at-death were estimated using morphological methods. The skulls were photographed and scanned with a 3D-surface scanner (Breuckmann smartSCAN) for digital archiving (Fig. 2).

Discussion

Due to the lack of other skeletal elements, and because X-raying or histology were not possible, the differential diagnosis is biased. However, the location and appearance of the lesions and age-at-death of the individuals may help to rule out various diagnostic possibilities (Tab. 1).

Tab. 1: Differential diagnosis on common paleopathological symptoms for skulls 33776 and 33796. Their presence in both skulls is expressed by "yes" (y) or "no" (n). If the result fits to a condition, a "+" is given, if not, a "-".

	33776	33796	Neo-plasms / tumors	Tuber-culosis	Leprosy	Osteo-myelitis	Mycosis	Paget's Disease	Treponematoses
Affection of the calvarium	y	y	+	+	-	+	+	+	+
Normal bone thickness	y	y	+	+	+	+	+	-	+
New bone formation	y	y	+	-	-	-	-	+	+
Involvement of the inner table	n	n	-	-	-	-	-	-	+
Perforation of the calvarium	n	n	-	-	+	-	-	+	+
Naso-palatine destruction	n	n	+	+	-	+	+	+	- / +
Bony excrescence	n	n	-	+	+	+	+	-	+
Perforation of the hard palate	y	n	-	+	-	+	-	+	+
Caries sicca	n	y	+	-	+	-	+	-	+

Both individuals' lesions are typical for treponematoses. Pinta and yaws should be excluded due to their geographic distribution and clinical features. Bejel (Treponarid) and venereal syphilis could have been probable causes and were endemic to the oasis of Biskra. Both diseases are caused by the bacterium *Treponema pallidum*. They are transmitted via direct or indirect contact with the infectious lesions, through close human interaction or shared eating and drinking utensils. Contemporary physicians held poor hygienic conditions and cultural habits responsible for the high frequency within the peasant and nomadic population.

Bone lesions usually appear in the tertiary stage of both diseases but are less common in bejel. Although morphologically indistinguishable, the severe affection of the cranial vault would make syphilis more likely than bejel. This would be the first paleopathological case of syphilis in Algeria. Further research should include ¹⁴C dating and computed tomography.

Author's correspondence

Amelie Alterauge
Institute of Forensic Medicine
Department of Physical Anthropology
Sulgenauweg 40
CH-3007 Bern
Switzerland
amelie.alterauge@irm.unibe.ch

References

- D. Daga, Documents pour servir à l'histoire de la syphilis chez les Arabes. Extrait des Archives générales de Médecine, Août / septembre 1864. P. Asselin, Paris, 1864.
F. Demoulin, Etude craniologique des algériens actuels. Bull. et Mém. de la Soc. d'Anthrop. de Paris, t. 8, série XIII, 1981, 145-164.
C. J. Hackett, Diagnostic Criteria of Syphilis, Yaws and Treponarid (Treponematoses) and of Some Other Diseases in Dry Bones (for Use in Osteo-Archaeology). Sitzungsberichte der Heidelberger Akademie der Wissenschaften, Math.-nat. Kl., Springer-Verlag, Berlin, Heidelberg, New York, 1976, 4. Abhandlung.
D. J. Ortner, Identification of Pathological Conditions in Human Skeletal Remains. Academic Press, San Diego, 2003, 2nd ed., 273-319.
R. Tardos & V.A. Tomari, Aspect actuel de la syphilis osseuse en Algérie. Journal de radiologie, d'électrologie et de médecine nucléaire t. 43, 1962, 288-297.
P. Topinard, Présentation de crânes. Bull. de la Soc. d'Anthrop. de Paris, t. 2, série II, 1879, 335-336.