

Title	Supracostal approach--an excellent exposure for renal and adrenal surgery
Author(s)	KATO, Haruaki; NISHIZAWA, Osamu
Citation	泌尿器科紀要 (2001), 47(7): 449-452
Issue Date	2001-07
URL	http://hdl.handle.net/2433/114573
Right	
Type	Departmental Bulletin Paper
Textversion	publisher

SUPRACOSTAL APPROACH AN EXCELLENT EXPOSURE FOR RENAL AND ADRENAL SURGERY

Haruaki KATO and Osamu NISHIZAWA

From the Department of Urology, Shinshu University School of Medicine

The supracostal extraperitoneal and extrapleural approach provides wide exposure during renal and adrenal operations without damaging the neurovascular bundles and spares the partial resection of rib. We performed renal and adrenal operations on 33 patients by this approach. The procedures were accomplished smoothly obtaining a broad surgical field without costal resection. Complications were rare and postoperative pain seemed to be mild. Hence, the supracostal approach is considered as a better method with excellent exposure to the kidney and adrenal and is anatomically comprehensive.

(Acta Urol. Jpn. 47: 449-452, 2001)

Key words: Kidney, Adrenal gland, Supracostal approach

INTRODUCTION

Although the laparoscopic approach to the adrenal as well as to the renal area is developing as a minimally invasive procedure, open surgery is still useful as a safety and reliable approach for the surgeons who are unfamiliar with laparoscopy. Furthermore, open surgery may be preferred when difficult resection is predicted or open biopsy is required for the choice of approach. For a better access to the retroperitoneal space, partial resection of 11th or 12th rib is commonly employed to minimize the costal obstacle. Turner-Warwick introduced the supracostal approach as a preferable alternative to rib resection technique¹⁾. Barry et al. showed satisfactory results along with their modification²⁾.

After learning this technique at Mansura in Egypt, we employed this technique in our hospital and obtained an excellent outcome. We would like to introduce this approach to the readers of this journal since this advantageous approach is not common in Japan.

PROCEDURE

The patient is positioned on the lateral side with hyperextension of the operative area. Selection of the appropriate approach, which may be above the 11th or 12th rib, depends on the relationship between the kidney and the rib. The skin incision starts from close to the edge of the erector spinae muscle along the upper border of the selected rib and extends anteriorly toward the lateral border of the rectus abdominis muscle. Then, the muscle layers are incised along the upper edge of the rib (the latissimus dorsi and the serratus posterior inferior muscle) and anteriorly, the external and the internal oblique muscle are then incised. The lumbodorsal fascia, which intermingles with the fibers of the transverse abdominis muscle, is incised at the tip of the rib to

reach the pararenal fat. This incision is extended forward after separating the peritoneum from the abdominal muscle, avoiding the intercostal or subcostal neurovascular bundle (Fig. 1A). By dividing the attachment of the lumbodorsal fascia from the tip of the rib, the edge of the diaphragm and

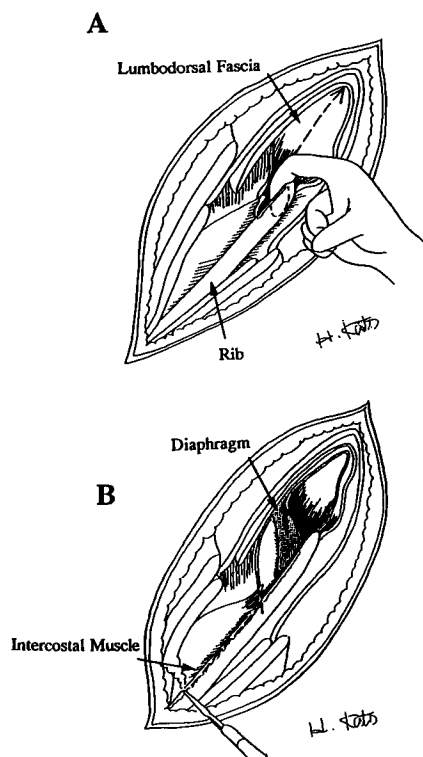


Fig. 1. A: The muscle layers are incised along the supracostal line. The lumbodorsal fascia is opened to enter into the retroperitoneal space. Dotted line indicates an incision on the lumbodorsal fascia. B: Following division of the lumbodorsal fascia, the diaphragm and the pleura are seen. The periosteum along the upper edge of the rib is then incised (dotted line).

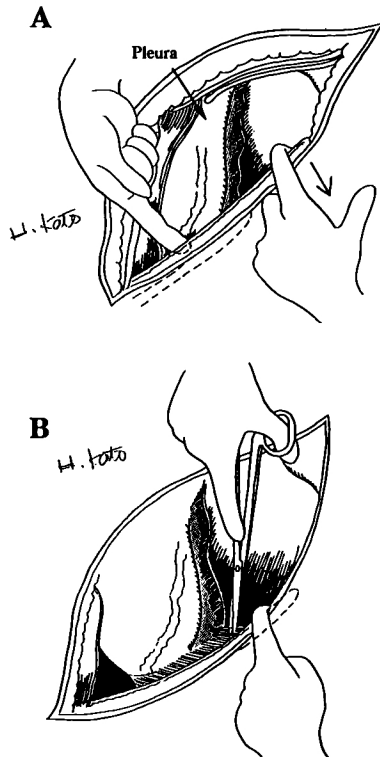


Fig. 2. A: The periosteum of inner side is separated bluntly from the rib by a finger tip to push down the pleura. B: Attachment of the lumbodorsal fascia to the rib is sharply cut to leave the nerve intact on the rib side.

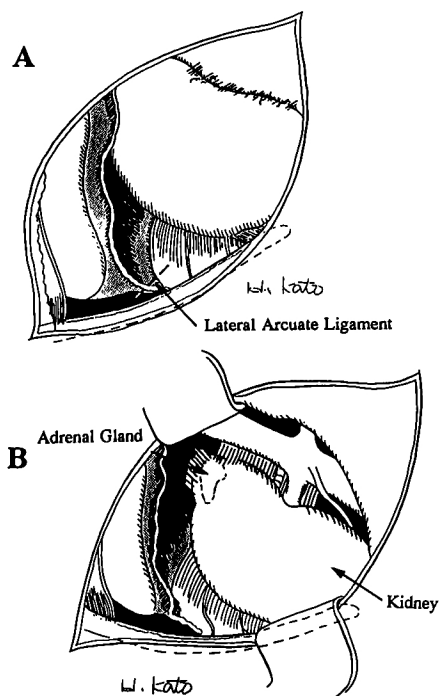


Fig. 3. A: The lateral arcuate ligament on the quadratus lumborum muscle is divided upward to provide an adequate suprarenal space. B: An excellent operative field is provided by a chest retractor. The renal vessels are in the center of the field.

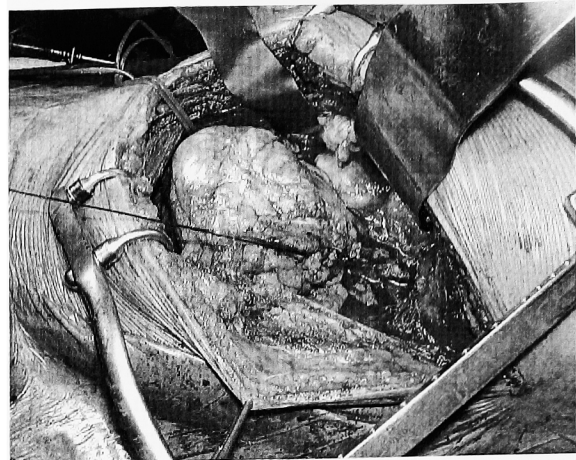


Fig. 4. An adequate surgical field is obtained by the supracostal approach above the 12th rib for a left radical nephrectomy. The lower edge of the wound indicates the 12th rib.

the pleura may be visible. Then the periosteum is incised along the upper edge of the rib (Fig. 1B) and separated from the inner surface of the rib using the raspatorium and the finger tip to push down the pleura following dissection of the external intercostal muscle (Fig. 2A). Fibrous attachment of the lumbodorsal fascia to the inner surface of the rib is sharply cut to leave the nerve intact by retracting the rib downward (Fig. 2B). The pleura is easily separated from the lower chest wall by extending these maneuvers towards the root of the rib. By separating the posterior leaf of the Gerota's fascia from the quadratus lumborum muscle, the lateral arcuate ligament of the diaphragm becomes evident, which is divided upward (Fig. 3A). Finally, the rib can be displaced downward freely and broad exposure of the surgical field is obtained by using a self-retaining chest retractor (Fig. 3B). Fig. 4 shows a surgical field obtained by the supracostal approach above the 12th rib. During the closure of the wound, the table is straightened to allow easy reapproximation. In the posterior aspect of the wound, the muscles above the rib are closed in single layer without reapproximation of the diaphragm. The anterior muscle layers from the rib tip are closed in the standard way.

RESULTS

We employed this technique in 33 cases, 17 of which were performed above the level of the 11th rib while 16 were above the level of the 12th rib. All the operations were completed uneventfully with wide exposure of the renal and adrenal areas. The series of operation included 5 cases of adrenalectomy for benign adenoma (mean operative time: 114 ± 15 mins and mean blood loss 129 ± 65 ml) and 13 cases of radical nephrectomy (mean operative time: 113 ± 25

mins and mean blood loss : 240 ± 152 ml). Among these, 3 cases required open biopsy before nephrectomy. A pin-whole injury to the pleura was encountered in 2 cases with 11th rib approach, which was closed primarily. In these 2 cases, since the pleural reflection unexpectedly underlay very near the tip of the 11th rib, we inadvertently injured it during dividing the attachment of the lumbodorsal fascia from the tip before separating the pleura from the back side of the 11th rib. Pneumothorax was not detected in any cases after the operation. Postoperative pain appeared to be mild and persistent neuralgia or abdominal muscle relaxation was never encountered in any patients.

DISCUSSION

The 11th or the 12th rib becomes free enough to pivot upon its single posterior joint when the intercostal muscles and lumbodorsal fascia are properly detached from the upper edge of the entire rib^{1,2)} Following these interventions, the ribs can be adequately displaced downward to provide a wider space for renal and adrenal operations. In addition, anatomical division of the intercostal tissues aids in the easy separation of the pleura from the chest wall and the pleura can also be pushed upward by dividing the lateral arcuate ligament. All these maneuvers provide enough space especially for handling of the adrenal gland and upper pole of the kidney.

In 1984, Riehle and Lavengood reported their technique of the transcostal approach by resection of the 11th rib³⁾ They described a detailed anatomy to prevent injury to the pleura and it is worth reading. However, the 11th intercostal nerve should be secured and isolated from the subcostal groove before incising the intercostal muscles, which might injure the vessels as well as the nerve. Conversely, the supracostal approach does not require the isolation of the neurovascular bundles since the supracostal incision line is away from the infracostal course of the bundles. Furthermore, the course of the nerve can be easily visualized from the inner side of the chest wall. For anatomical reasons, the incision line of the supracostal approach never crosses the intercostal or subcostal neurovascular bundle and an inadvertent injury to the neurovascular bundle is unlikely both during dissection of the muscles as well as during closure of the wound. The uninjured neurovascular bundles might be the cause of absence of post-

operative persistent neuralgia or mild pain in the operative area.

A description of the supracostal approach appeared in a textbook by Bartsch and Poisel⁴⁾ However, they entered the space between the pleura and the rib directly by dividing the lumbodorsal fascia. This procedure may cause pleural injury. To avoid this, we have employed the technique separating the pleura from above the inner periosteum of the rib.

The pin-hole injury to the pleura was encountered in only 2 of our cases. Of course, the pleura is more susceptible to injury when the 11th rib approach is chosen and it underlay near the tip of the rib. But the injury is preventable by identifying the attachment of the diaphragm near the tip of the rib. Furthermore, the pleural injury is not difficult to repair because the lower part of the pleura can be fully separated without any tension.

Reapproximation of the diaphragm is not necessary and the wound closure is simple, as only fixation of the muscles overlying the ribs is required.

Since the supracostal approach has many advantages, we recommend this approach in the patients who are candidates for open renal or adrenal surgery, especially when there is no likelihood of cancer invasion to adjacent organs.

ACKNOWLEDGMENT

The authors are grateful to Professor MA Ghoneim, Urology and Nephrology Center in Mansoura for providing us this technique and Dr. M Islam, a visiting doctor from Bangladesh, for his critical reading of the manuscript.

REFERENCES

- 1) Turner Warwick RT : The supracostal approach to the renal area. *Br J Urol* **37** : 671-672, 1965
- 2) Barry JM and Hodges CV : The supracostal approach to the kidney and adrenal. *J Urol* **114** : 666-669, 1975
- 3) Riehle RA and Lavengood R : The eleventh rib transcostal incision : thechnique for an extrapleural approach. *J Urol* **132** : 1089-1092, 1984
- 4) Bartsch G and Poisel S : Supracostal approach. In : *Approaches in Urologic Surgery*. Edited by Bartsch G and Poisel S. 1st ed., pp. 34-44, Georg Medical Publishers, Inc., New York, 1994

(Received on October 17, 2000)
(Accepted on December 25, 2000)

腎，副腎手術における肋骨上縁切開法による到達法

信州大学医学部泌尿器科学教室（主任：西澤 理教授）

加藤 晴朗，西澤 理

肋骨上縁切開法による腎および副腎への腹膜外，胸膜外到達法は，肋骨の切除や神経血管束の損傷を回避しながら，十分な視野の得られる優れた方法である。われわれはこの到達法を33例の腎および副腎手術で適用した。全例，肋骨の切除を必要とせず，安全に手術

を施行できた。合併症もほとんど認めず，術後の創痛も少ないように思われた。この方法は肋骨や神経血管束を温存しながら，良好な手術野が得られるので，開放手術の際，考慮すべき到達法の1つと考えられた。

（泌尿紀要 47：449-452，2001）