



CASE REPORT

Subcutaneous emphysema secondary to pulmonary cavity in absence of pneumothorax or pneumomediastinum

Deveshwar Pandey, Pramod Jaret, Rajesh Sharma, Amit Sharma, Surinder Thakur*

Department of Medicine, Indira Gandhi Medical College, Shimla 171001 (H.P.), India

Received 18 March 2006; accepted 26 April 2006

KEYWORDS

Subcutaneous emphysema;
Pneumomediastinum;
Air leak

Summary Subcutaneous emphysema is a common condition occurring after chest injury. It may also be observed in association with pneumothorax or pneumomediastinum as a result of pathological changes in the respiratory tract. Spontaneous subcutaneous emphysema in absence of pneumothorax or pneumomediastinum is rare. We report a case of spontaneous subcutaneous emphysema in isolation secondary to fibrocavitary lesion in the chest along with review of the literature. © 2006 Elsevier Ltd. All rights reserved.

Introduction

Subcutaneous emphysema is not an uncommon condition complicating blunt or penetrating trauma injury to laryngeal, tracheal, or bronchial tree. It may occur following chest tube insertion or tracheal intubation. Rarely, this condition has been observed as a result of pathological changes in the respiratory tract. We present a case of spontaneous subcutaneous emphysema in absence of pneumothorax and pneumomediastinum in a patient with pulmonary fibrocavitary disease secondary to pulmonary tuberculosis.

Case report

A 60-year-old male, labourer by occupation, presented with complaints of pain on right side of the chest, sudden in onset after a bout of coughing yesterday. It was followed by swelling over upper half of the chest, more on right side, spreading to neck and face over 6 h. There was no history of trauma, retrosternal pain, or shortness of breath. Patient had a history of productive cough for the past 1 month with sputum that was odourless, white colored with occasional streaking of blood. Patient had smoked for the past 20 years and had a history of pulmonary tuberculosis for which he was treated 3 years ago.

*Corresponding author. Tel.: +91 9816 072 444.
E-mail address: surindersml@yahoo.co.in (S. Thakur).

On examination, patient was conscious and oriented. There was swelling over the face, neck and upper half of the chest (Fig. 1). Pulse was 84 beats per minute, regular and blood pressure was 140/80 mm of Hg. JVP was not raised. There was no lymphadenopathy. On examination of the chest, there were no dilated veins. Crepitus was present over the chest and neck on palpation. There was no evidence of mediastinal shift. Review of other systems was unremarkable.

Investigations revealed hemoglobin of 13 g%, total leukocyte count of 8500/mm³, differential leukocyte count showed polymorphs 61%, lymphocytes 32%, monocytes 3%, eosinophils 4% and ESR 120 mm in 1st hour. Serum biochemistry was within normal limits. Sputum for AFB was positive. Chest X-ray revealed fibrocavitary changes in right upper zone with subcutaneous emphysema in the chest and neck (Fig. 2). Computed tomography (CT) of thorax revealed diffuse subcutaneous emphysema with cavity in right upper lobe communicating with right main bronchus and subcutaneous tissue with consolidation in bilateral lung fields (Fig. 3). There was no enhancement after I.V. contrast in these lesions. Patient was treated with high flow oxygen along with ATT—Category II regimen. There

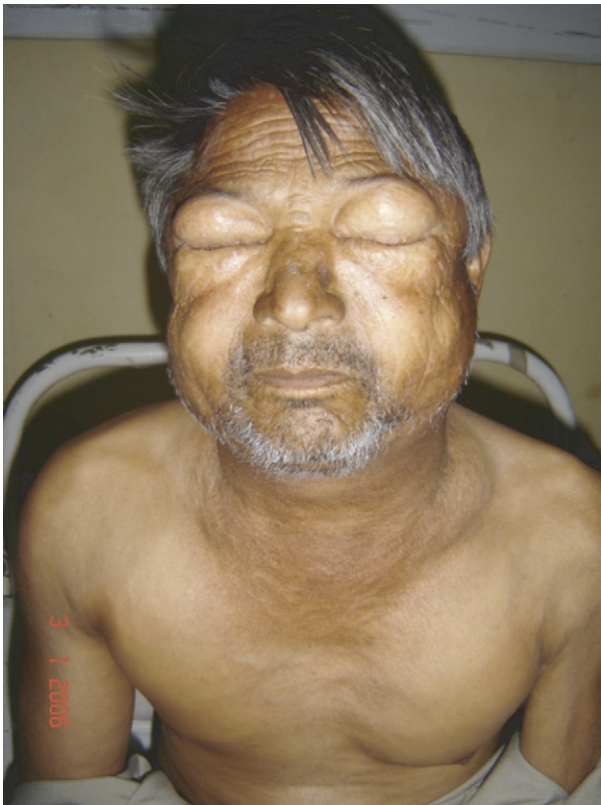

Figure 1 Subcutaneous emphysema involving the chest wall, face, neck, and eyelids.

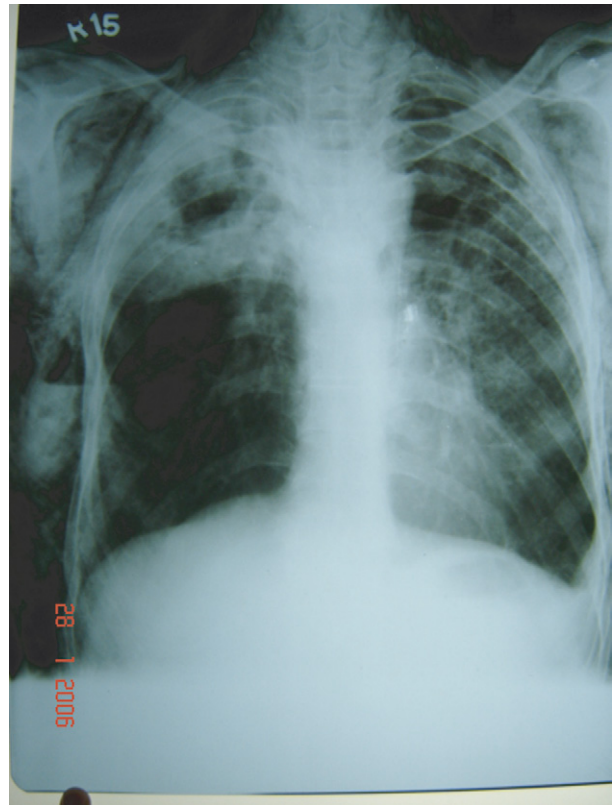


Figure 2 Chest X-ray revealing fibrocavitary lesion in the chest with subcutaneous emphysema in the chest and neck.

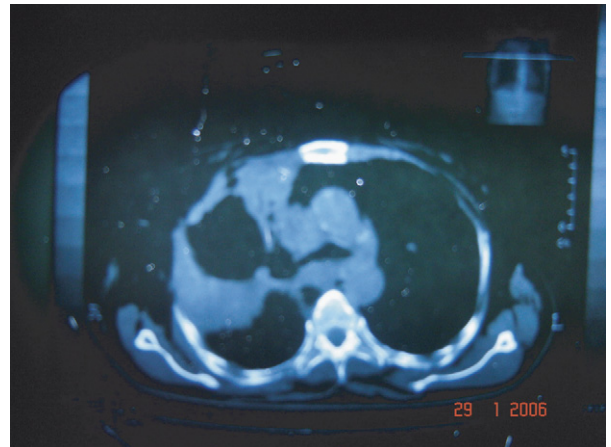


Figure 3 Plain CT chest showing broncho-cavitary-subcutaneous fistula.

was slight decrease in swelling and patient was discharged on request.

Discussion

The escape of air into subcutaneous tissue is known as subcutaneous emphysema. It is termed

traumatic if secondary to either blunt or penetrating external injury. The term secondary spontaneous subcutaneous emphysema is used where the leakage of air has arisen as a result of a recognizable coexisting structural abnormality in the lungs.

Subcutaneous emphysema involving face, neck and upper chest may mimic edema as in nephrotic syndrome, allergic, or angioneurotic edema. However, it can be easily diagnosed by the crunchy sensation and crepitation on palpation. Among the various theories analysed by Bloomberg,¹ preexisting weakness of either the alveolar or bronchial wall exists. The increased intrapulmonary pressure because of excessive and prolonged coughing causes rupture at a weakened point allowing escape of air in the tissue. Air escapes via peribronchial or perivascular channels to the mediastinum. In the mediastinum, air spreads into loose alveolar tissue, which can then enter into the neck and subcutaneous plane in all directions. Neck and chest wall are the usual anatomical locations of the subcutaneous emphysema, though rarely scalp, palm of the hands, soles of the feet may be involved.² Subcutaneous emphysema in the absence of pneumomediastinum or pneumothorax is rare, which makes our case interesting.

Pulmonary tuberculosis is a common condition complicated by air leaks. Most of the cases reporting air leaks are as a complication of miliary tuberculosis. Spontaneous pneumomediastinum associated with pulmonary cavitation has been reported by Qureshi,³ but pulmonary cavitation complicated by subcutaneous emphysema without pneumothorax or pneumomediastinum has not been reported to the best of our knowledge. Besides tuberculosis, staphylococcal pneumonia, measles, pneumocystis carinii, influenza pneumonia and pertussis are other infections causing subcutaneous emphysema, especially among children.⁴ It has also been reported as a complication of asthma with inhaled bronchodilators and nebulisation as an additional risk.^{5,6} Air is occasionally drawn into the fascial planes of the mediastinum from wounds in the neck, including tracheostomy and surgical procedures in the mouth, pharynx and upper gastrointestinal tract.

Radiological studies are essential to diagnose the primary cause and the extent of air leak. To diagnose pneumomediastinum, routine lateral view along with posteroanterior view should be taken, as 50% of cases that would otherwise be detected on lateral view may be missed.⁷ CT is helpful in the diagnosis as in our case, broncho-cavitary-subcutaneous fistula leading to subcutaneous emphysema was demonstrable on CT.

Subcutaneous emphysema carries no particular risk of its own. In most instances treatment is palliative and consists of treating the underlying disease and prevention of further air leak. Subcutaneous emphysema is self-limiting and resolution of the air leak occurs by resorption of aberrant air. However, the primary cause and the associated intra-thoracic air leak such as pneumothorax, pneumomediastinum or pneumopericardium may lead to serious complications. In such instances, therapeutic efforts are directed to the primary condition and associated intra-thoracic air leak.⁸ Patients with respiratory distress and hemodynamic instability may need tracheostomy and skin incisions over the neck and anterior chest wall.

References

1. Bloomberg WM. Generalized non-traumatic subcutaneous emphysema. *Can Med Assoc J* 1927;17(3):336-8.
2. Narchi S. Fever, facial swelling and dyspnoea. *Int Pediatr* 2003;18(2):92-4.
3. Qureshi SA. Spontaneous mediastinum associated with pulmonary cavitation. *Postgrad Med J* 1980;56:48-9.
4. Das M, Natchu UCM, Lodha R, Kabra SK. Pneumomediastinum and subcutaneous emphysema in acute miliary tuberculosis. *Indian J Pediatr* 2004;71:553-4.
5. Cohn RC, Steffan ME, Spohn WA. Retropharyngeal air accumulation as a complication of pneumomediastinum and a cause of airway obstruction in asthma. *Pediatr Emerg Care* 1995;11:298-9.
6. Roel JB, et al. Spontaneous pneumomediastinum caused by nebulization of bronchodilators in a young child. *Respir Med Extra* 2005;1(4):124-6.
7. Lillard RL, Allen RP. The extra-pleural air sign in pneumomediastinum. *Radiology* 1965;85:1093.
8. Seaton A, Seaton D, Leitch AG. Crofton and Douglas's respiratory diseases, vol. 2, 5th ed. Osney Mead, Oxford: Blackwell Science Limited; 2002. p. 1204-6