

Contents lists available at [ScienceDirect](http://ScienceDirect)

## Respiratory Medicine Case Reports

journal homepage: [www.elsevier.com/locate/rmcr](http://www.elsevier.com/locate/rmcr)

## Case report

## Unusual mode of presentation of intrathoracic bronchogenic cyst: A double location

Fouad Atoini <sup>a,\*</sup>, Aziz Ouarssani <sup>b</sup>, Yassine Ouadnoui <sup>c</sup>, Mohammed Smahi <sup>c</sup><sup>a</sup> Thoracic Surgery Department, Moulay Ismail Military Hospital, Faculty of Medicine and Pharmacy, Sidi Mohamed Ben Abdellah University, Fez, Morocco<sup>b</sup> Pulmonology Department, Moulay Ismail Military Hospital, Faculty of Medicine and Pharmacy, Sidi Mohamed Ben Abdellah University, Fez, Morocco<sup>c</sup> Thoracic Surgery Department, Hassan II university Hospital, Faculty of Medicine and Pharmacy, Sidi Mohamed Ben Abdellah University, Fez, Morocco

## A B S T R A C T

## Keywords:

Bronchogenic cyst  
Locations  
Diagnosis  
Infection  
Surgery

A 63 year old woman presenting chronic back pain and neuralgia had abnormal shadow on chest radiograph. She has a history of pulmonary tuberculosis treated in 1977. The chest-CT scan showed a soft tissue mass in the lower lobe of the right lung and a cystic mass in the paravertebral region. The patient had right lower lobectomy and complete excision of a paraoesophageal cyst. Both masses were bronchogenic cysts at histology. The patient had an uneventful discharge the seventh postoperative day. After 4 years and 7 months of follow-up with CT-scann, the patient was free of symptoms with no evidence of recurrent disease.

© 2015 The Authors. Published by Elsevier Ltd. This is an open access article under the CC BY-NC-ND license (<http://creativecommons.org/licenses/by-nc-nd/4.0/>).

## 1. Introduction

Bronchogenic cysts (BCs) are a congenital foregut duplication anomaly and represent about 18% of all mediastinal tumors. It can be found in the mediastinum or pulmonary parenchyma (15–23%) and rarely in extrathoracic locations [1–3]. In the mediastinum, Maier has classified the cyst into: right paratracheal, left paratracheal, subcarinal, above right mainstem bronchus, above left mainstem bronchus, right paraoesophageal, left paraoesophageal, intraparenchymal, and above aortic arch [4]. Bronchogenic cysts are usually asymptomatic and are discovered as an incidental finding. They may become symptomatic in case of compression when they increase in size or when they infect [1–3]. We report an exceptional case of double location of bronchogenic cyst (intrapulmonary and mediastinal) in a 63-year-old woman; the complete resection by thoracotomy gives good result.

## 2. Clinical case

A 63-year-old woman was admitted in our department for evaluation of chronic back pain and neuralgia. She had an abnormal shadow on the chest radiograph followed up since 1999. She has a

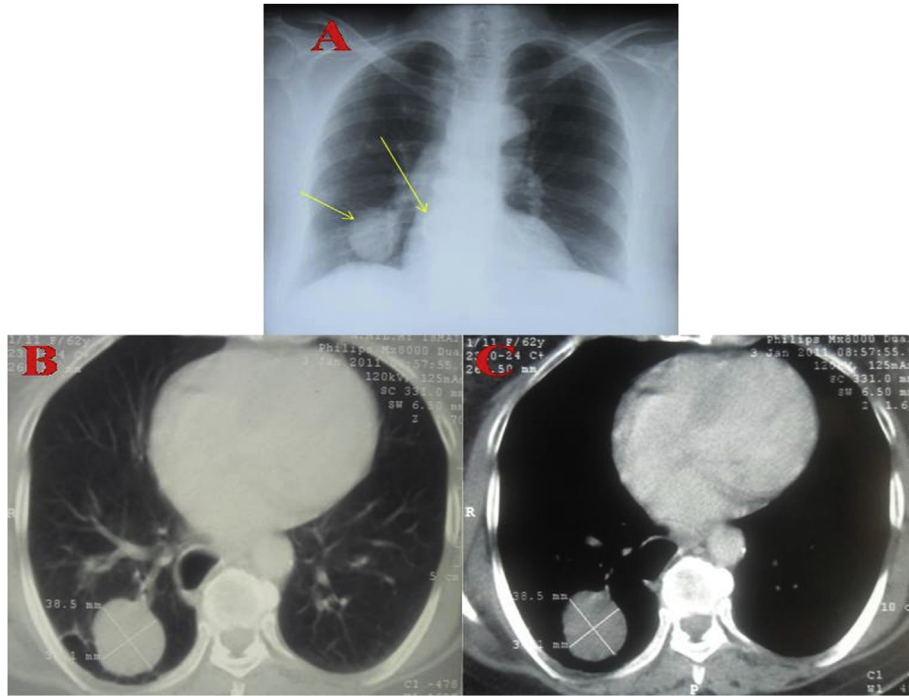
history of arterial hypertension for 5 years treated by association of diuretics and inhibitor of the conversion enzyme. The patient had not had BCG vaccination. In 1977, she was treated for pulmonary tuberculosis, which was diagnosed for fever, cough, weight loss and night sweats. Chest radiograph showed opacity in the right lower lobe. Tuberculosis skin test was positive, but sputum smear and culture for tuberculosis were negative. She was treated using streptomycin, isoniazid, pyrazinamide and rifampicine for 2 months and then isoniazid and rifampicine for 4 months. The response was good with disappearance of symptoms but the radiological aspect showed persistence of the lower lobe opacity. The patient was lost until its consultation for pain and the persistent opacity was not explored.

The chest radiograph at admission (Fig. 1A) showed a round well defined opacity in the right lower lobe and a paravertebral opacity, chest-CT scan showed a round well defined soft tissue mass measuring 38.5/31.3 mm localized on the right lower lobe and a 40 mm (in the greatest diameter) right paravertebral cystic mass (Fig. 1 B and C). The hydatid serology, research of mycobacterium tuberculosis in sputum and the histological finding of bronchial biopsy were negative.

Preoperative assessments were without anomaly and have included: blood cells account, electrolytes, glycemia, renal and hepatic tests, electrocardiography and transthoracic cardiac echography.

Under general anesthesia, and selective tracheal tube

\* Corresponding author. Tel.: +00212 661443846; fax: +00212 535517399.  
E-mail address: [f.atoini@gmail.com](mailto:f.atoini@gmail.com) (F. Atoini).



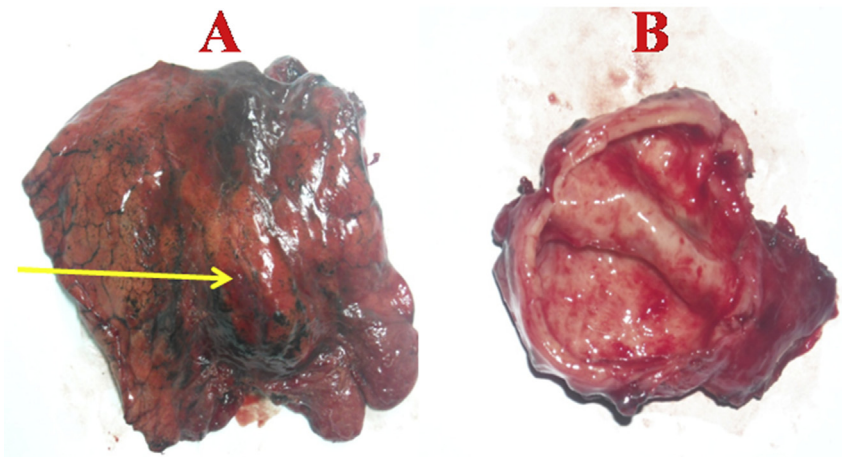
**Fig. 1.** A-chest radiograph showing two opacities in the parenchyma and paravertebral. B- Chest-CT on pulmonary window showing lung mass with soft tissue in the right lower lobe and cystic mass in the paravertebral lesion. C- Chest-CT on mediastinal window showing the lung mass in the right lower lobe and cystic mass in the paravertebral lesion near the esophagus.

intubation, the patient was placed in the lateral position. A right postero-lateral thoracotomy was performed in the sixth intercostal space. Exploration showed a round mass, covered by parenchyma, in the center of the lower lobe. In addition, there was a paraoesophageal cystic mass that was adherent to the vertebral body, oesophagus and lung. A lower lobectomy was performed, in addition to the complete excision of the paraoesophageal cyst (Fig. 2 A,B,C).

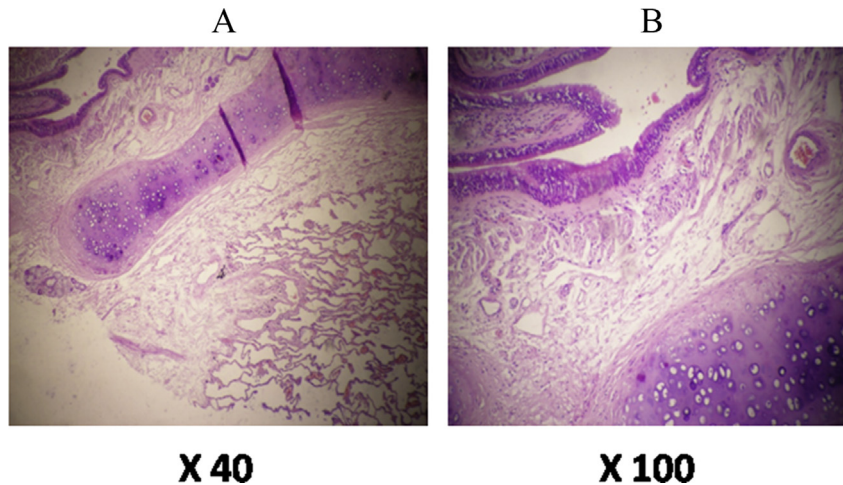
Gross examination of the lung mass found a cyst with a thin wall and chocolate content, surrounded with 2.5 cm normal parenchyma margins. The paraoesophageal cyst was whitish, cartilaginous in consistency and measuring 4.5/3 cm for both lesions, histology concluded to a bronchogenic cyst (Fig. 3). These cysts

were lined by a coating of respiratory type ciliated and pseudostratified, based on a fibrous shell, with a few mucus-secreting bronchial glands.

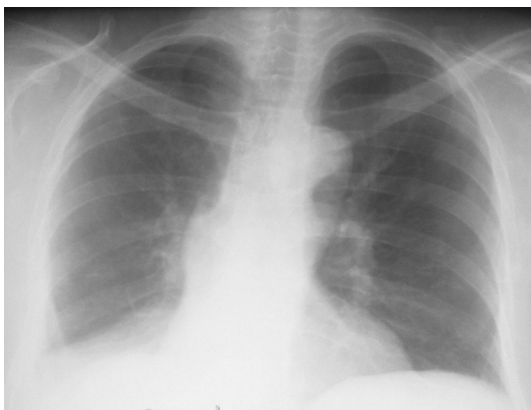
The postero-inferior drain was removed the 3rd postoperative day and the antero-apical drain was removed 6th postoperative day. No perioperative complication was noted. The patient had an uneventful discharge the 7th postoperative day. At 3 weeks, the patient reported a subjective resolution of the symptoms she suffered preoperatively. However, she presented post-thoracotomy pain that was managed successfully using analgesic oral paracetamol therapy. Chest radiograph was normal with 4 years and 7 months of follow-up and the patient is actually asymptomatic (Fig. 4).



**Fig. 2.** Resection specimen of both pulmonary and paraoesophageal cyst.



**Fig. 3.** Photomicrograph of the resected specimen showing cyst lined by coating respiratory type ciliated and pseudostratified associated with cartilaginous structures. A- HE x 40, B- HE x100.



**Fig. 4.** Postoperative chest radiograph don't show anomaly with good expansion of lung parenchyma (superior and middle lobe).

### 3. Comments

In this case, the medical history suggests that the lower lobe parenchymal cyst was complicated by myobacterial infection. The clinical improvement, after tuberculosis antibiotics, had lead misdiagnose of the cyst, or had precluded the cyst diagnosis.

The recent back pain and neuralgia, allowing the diagnosis, were secondary to the paraoesophageal cyst, which had increased in size and become symptomatic. We think that the backache was due to stretching of nerves in the parietal pleura.

Bronchogenic cysts (BCs) are a congenital lesion thought to result from abnormal budding of the ventral foregut that occurs between the 26th and 40th day of gestation. Depending on time of separation from the primary airways, BCs may present as mediastinal cysts close to the tracheobronchial tree or as pulmonary cysts within the lung parenchyma [4–7].

The most frequent thoracic location of BCs is the middle mediastinum near the carina, but the paratracheal, hilar and intraparenchymal location are not rare, more rarely, these lesions have been reported in the posterior and anterior mediastinum, and exceptionally in the diaphragm, intrapericardial or intracardiac. BCs are also described in extrathoracic location: cervical, skin, retroperitoneum [1–13]. Exceptionally, the bronchogenic cyst is bilateral [14], or double [15–17]. Paraoesophageal are uncommon location of

bronchogenic cyst that is difficult to differentiate from oesophageal duplications. Although the intraparenchymal and paraoesophageal described in this case, were lined by respiratory epithelium and cartilage suggesting that the source of the developmental error was within the tracheobronchial tree, rather than the embryonic foregut [18,19].

In this case the cyst was discovered at an advanced age, which suggests that he remained asymptomatic for a long time. Most often, the cyst is discovered at an early age, between 20 and 40 years, rarely is diagnosed in an elderly patient or pediatric population [1–7,12,13]. It can be found incidentally or occasionally symptoms, these vary according to the age of the presentation, the size of the cyst and its location. Symptoms are usually related to cyst infection or compression of adjacent structures. The most frequent symptoms are pain, cough, fever, and dyspnea, rarely the cyst is complicated by a superior vena cava obstruction, pneumothorax, dysphagia, severe hemoptysis, or malignancies [1–8,12,13].

Myobacterial infection of a bronchogenic cyst is exceptional. For systematic research, we used in Pubmed the terms (myobacterial infection, tuberculosis and bronchogenic cyst). In the 11 clinical cases that were found [20–30], clinical data was obtained by full text in 6 papers and in 2 by abstract. The diagnostic method was noted of a total of 9 cases of bronchogenic cyst infected by mycobacterium; in a paper two clinical cases was described [20]. In one case, the diagnosis was possible preoperatively, after bacteriological culture, by CT-guided fine-needle aspiration of the lesion [21]; in the other cases [20,22–27] the diagnosis was postoperative, by bacteriological culture of the tissue in 2 cases [22,23] and by histology in 5 cases [20,24–27].

Among 12 cases of infected bronchogenic cysts, Hernandez-Solis Alejandro and al. found mycobacterium tuberculosis in one case. The diagnosis was obtained preoperatively by bacteriological culture; this approach is important to give appropriate antimicrobial therapy and to facilitate surgical resection [31].

In imaging, differential diagnoses can be discussed. Chest radiograph usually shows a smooth, round mass in the mediastinum or lung, an air-fluid level can be seen [1]. CT-scan is very useful for pointing the exact location, and its relationship to the surrounding structures, in addition it helps to plan surgical therapy. The cyst appears sharply defined, thin-walled, with fluid attenuation content without enhancing. It is completely filled with air or with variable degrees of air-fluid level. The content of BCs can have a great variety of density, from the watery liquid to hemorrhagic



fluid, or to viscous mucoid material, depending on whether there is hemorrhage, rich in protein, fluid, or calcium; soft tissue mass can mimic tumors [32].

In our case, the correct diagnosis was difficult; many parenchymal and paravertebral or paraoesophageal pathologies were discussed including: recurrent tuberculosis, tuberculoma, aspergilloma, hydatid disease, fungal disease, benign or malignant tumor, paraoesophageal cyst, cystic nervous tumor, pulmonary sequestration, congenital cystic adenomatoid malformation, association with both pathologies was advocated. Thus, double location of BCs has been not discussed.

Thoracotomy was indicated with diagnosis and treatment intent. To treat BCs, there are various methods, including transbronchial aspiration essentially for acute cyst decompression and for non-surgical candidates [33] and resection by open thoracotomy, mediastinoscopy and video-assisted thoracoscopy (VATS) [34–37].

Surgery remains the treatment of choice, even if the BC is asymptomatic since the majority will ultimately become symptomatic or complicated. Therefore, early surgical intervention prevents future complications [1–7]. Resection must be complete because recurrence has been observed after incomplete surgical removal [38]. Lobectomy is the standard procedure; it was stated by many authors in the treatment of pulmonary BCs. Wedge resection is sufficient for peripheral small cysts. For extrapulmonary BCs resection depends on the degrees of adhesion; total resection is very important. If there are severe adhesions to vital structures, subtotal resection with de-epithelisation may be a good alternative; the residual epithelial layer should be destroyed by toxic agents (such an ethanol, silver nitrate) or electro-cauterization [39]. VATS is safe and feasible, and can be considered the primary therapeutic option in the management of mediastinal bronchogenic cyst with encouraging results [34–36], Jung HS and al [34]. showed a low rate of conversion and complications for VATS excision of BCs. History of pleural infection, severe adhesions to adjacent organs and major organ injury by surgery are factors associated with a higher chance of conversion to thoracotomy, therefore the size and the location of the cysts were not important considerations in selecting the surgical method.

#### 4. Conclusion

This case highlights persistent radiological image in treated pulmonary tuberculosis, chronic back pain, and neuralgia as unusual mode of presentation of bronchogenic cysts. Double location of BCs is exceptional, and definitive confident preoperative diagnosis is not always possible based on standard investigations. Definitive diagnosis could only be confirmed after complete surgical excision, by histological examination.

#### Conflict of interest

Authors declare no conflict of interest.

#### References

- [1] H.S. Liu, S.Q. Li, Z.L. Cao, Z.Y. Zhang, H. Ren, Clinical features and treatment of bronchogenic cyst in adults, *Chin. Med. Sci. J.* 24 (1) (2009) 60–63.
- [2] D.H. Lee, C.K. Park, D.Y. Kum, J.B. Kim, I. Hwang, Clinical characteristics and management of intrathoracic bronchogenic cysts: a single center experience, *Korean J. Thorac. Cardiovasc. Surg.* 44 (4) (2011) 279–284.
- [3] P. Cuyppers, P. De Leyn, L. Cappelle, L. Verougstraete, M. Demedts, G. Deneffe, Bronchogenic cysts: a review of 20 cases, *Eur. J. Cardiothorac. Surg.* 10 (6) (1996) 393–396.
- [4] H.C. Maier, Bronchogenic cysts of the mediastinum, *Ann. Surg.* 127 (1948) 476–502.
- [5] F. Limaïem, A. Ayadi-Kaddour, H. Djilani, et al., Pulmonary and mediastinal bronchogenic cysts: a clinicopathologic study of 33 cases, *Lung* 186 (2008) 55–61.
- [6] M.E. Ribet, M.C. Copin, B.H. Gosselin, Bronchogenic cysts of the lung, *Ann. Thorac. Surg.* 61 (6) (1996) 1636–1640.
- [7] M.E. Ribet, M.C. Copin, B. Gosselin, Bronchogenic cysts of the mediastinum, *J. Thorac. Cardiovasc. Surg.* 109 (5) (1995) 1003–1010.
- [8] T. Berrocal, C. Madrid, S. Novo, et al., Congenital anomalies of the tracheo-bronchial tree, lung, and mediastinum: embryology, radiology, and pathology, *Radiographics* 24 (2004) e17.
- [9] S. Subramanian, T. Chandra, J. Whitehouse, M. Suchi, M. Arca, M. Maheshwari, Bronchogenic cyst in the intradiaphragmatic location, *WJM* 112 (6) (2013) 262–264.
- [10] C.H. Lugo-Olivieri, G.J. Schwartzman, D.P. Beall, et al., Intraperi-cardial bronchogenic cyst: assessment with magnetic resonance imaging and transoesophageal echocardiography, *Clin. Imaging* 23 (1999) 81–84.
- [11] J.W. Roos-Hesselink, G.T. Verhoeven, J. Stoker, Bronchogenic cyst mimicking an intracardiac mass: diagnosis by magnetic resonance imaging and treatment by needle aspiration, *Heart* 75 (1996) 639.
- [12] J.H. Jiang, S.L. Yen, S.Y. Lee, J.H. Chuang, Differences in the distribution and presentation of bronchogenic cysts between adults and children, *J. Pediatr. Surg.* 50 (3) (2015) 399–401.
- [13] R. St Georges, J. Deslauriers, A. Duranceau, et al., Clinical spectrum of bronchogenic cysts of the mediastinum and lung in the adult, *Ann. Thorac. Surg.* 52 (1991) 6–13.
- [14] E. William, S. Mithchell, S. Felix, Bilateral bronchogenic cyst, *AJR Am. J. Roentgenol.* 157 (1991) 950.
- [15] T. Matsuoka, K. Sugi, E. Matsuda, K. Okabe, K. Hirazawa, T. Azuma, Intrapulmonary and mediastinal, double bronchogenic cysts; report of a case, *Kyobu Geka* 61 (2008) 419–422.
- [16] R. Zaimi, L. Fournel, E. Chambon, D. Gossot, Double bronchogenic cyst, *Rev. Mal. Respir.* 31 (9) (2014) 864–866.
- [17] M. Hashimoto, J. Hanaoka, H. Kitano, Y. Oshio, T. Igarashi, Y. Kataoka, T. Shiratori, K. Hayashi, K. Horimoto, Resection of double bronchogenic cysts within the anterior mediastinum: report of case, *Kyobu Geka* 67 (13) (2014) 1198–1200.
- [18] X. Yang, K. Partanen, A. Seppä, E. Berg, P. Pasanen, Paraesophageal bronchogenic cyst in the adult: can it be differentiated from intramural oesophageal cyst by different imaging? *Clin. Imaging* 18 (1994) 68–71.
- [19] K.K. Nobuhara, Y.C. Gorski, M.P. La Quaglia, R.C. Shamberger, Bronchogenic cysts and oesophageal duplications: common origins and treatment, *J. Pediatr. Surg.* 32 (1997) 1408–1413.
- [20] S.T. Liman, Y. Dogan, S. Topcu, N. Karabulut, N. Demirkan, Z. Keser, Mycobacterial infection of intraparenchymal bronchogenic cysts, *Respir. Med.* 100 (2006) 2060–2062.
- [21] H. Hu, X. Yi, L. Zhao, T. Gui, X. Fang, X. Sun, Atypical lung parenchymal bronchogenic cyst complicated by tuberculosis infection, *Can. Respir. J.* 95 (5) (2012) 301–302.
- [22] Y.S. Kwon, J. Han, K.H. Jung, J.H. Kim, W.J. Koh, Mycobacterium avium lung disease combined with a bronchogenic cyst in an immunocompetent young adult, *Korean J. Intern. Med.* 28 (1) (2013) 94–97.
- [23] S.H. Lin, L.N. Lee, Y.L. Chang, Y.C. Lee, L.W. Ding, P.R. Hsueh, Infected bronchogenic cyst due to mycobacterium avium in an immunocompetent patient, *J. Infect.* 51 (3) (2005) e131–e133.
- [24] L. EL Fekih, L. Boussouffara, H. Hassene, S. Fenniche, D. Belhabib, K. Ben Miled, T. Kilani, M.L. Megdiche, Bronchogenic cyst and pulmonary tuberculosis, *Tunis. Med.* 87 (6) (2009) 408–409.
- [25] S.A. Frye, J.M. Decou, Pediatric bronchogenic cyst complicated by atypical mycobacterium infection: a case report, *Cases J.* 2 (2009) 8070.
- [26] W.C. Houser, G.J. Dorff, D.Y. Rosenzweig, J.W. Aussem, Mycobacterial infection of a congenital bronchogenic cyst, *Thorax* 35 (4) (1980) 312–313.
- [27] V. Puchetti, F. Carolo, C. Canton, F. Orcalli, Bronchogenic cyst of the lung and pulmonary tuberculosis. Presentation of a case, *Chir. Ital.* 30 (3) (1978) 194–204.
- [28] S.K. Das, S.K. Saha, A. Das, A.K. Halder, I. Ghosh, tuberculosis in a bronchogenic cyst, *J. Indian Med. Assoc.* 107 (7) (2009) 458–459.
- [29] A. Matsumura, K. Nakahara, K. Ohno, J. Hashimoto, T. Mizuta, A. Akashi, K. Nakagawa, S. Takeda, M. Ohta, Y. Kawashima, A case report of intrapulmonary bronchogenic cyst with tuberculosis, *Nihon Kyobu Shikkan Gakkai Zasshi* 26 (8) (1988) 888–892.
- [30] I.V. Ogaï, E.M. Khalikova, L.E. Gedymin, Bronchogenic cyst of the lung in a patient with tuberculosis, *Probl. Tuberk.* 10 (1974) 85–87.
- [31] A. Hernández-Solís, H. Cruz-Ortiz, Gutiérrez-Díaz Ceballos ME, Cicero-Sabido R. Bronchogenic cysts. Importance of infection in adults. Study of 12 cases, *Cir. Cir.* 83 (2) (2015) 112–116.
- [32] Y.C. Chang, Y.L. Chang, S.Y. Chen, T.C. Wang, P.C. Yang, H.M. Liu, Y.C. Lee, Intrapulmonary bronchogenic cysts: computed tomography, clinical and histopathologic correlations, *J. Formos. Med. Assoc.* 106 (2007) 8–15.
- [33] R.F. Casal, C.A. Jimenez, R.J. Mehran, G.A. Eapen, D. Ost, M. Sarkiss, et al., Infected mediastinal bronchogenic cyst successfully treated by endobronchial ultrasound-guided fine-needle aspiration, *Ann. Thorac. Surg.* 90 (2010) 52–53.
- [34] J. Lesaffer, B. Heremans, P. De Leyn, D. Van Raemdonck, Video-assisted mediastinoscopic resection of a large symptomatic bronchogenic cyst, *Interact. Cardiovasc. Thorac. Surg.* 12 (6) (2011) 1071–1073.
- [35] H.S. Jung, D.K. Kim, G.D. Lee, H.J. Sim, S.H. Choi, H.R. Kim, Y.H. Kim, S.I. Park,

- Video-assisted thoracic surgery for bronchogenic cysts: is this the surgical approach of choice? *Interact. Cardiovasc. Thorac. Surg.* 19 (5) (2014) 824–829.
- [36] E. Martinod, F. Pons, J. Azorin, et al., Thoracoscopic excision of mediastinal bronchogenic cysts: results in 20 cases, *Ann. Thorac. Surg.* 69 (2000) 1525–1528.
- [37] W. Thomas, C. Thierry, B. Morris, et al., Video-assisted thoracoscopic surgery of mediastinal bronchogenic cysts in adults: a single-center experience, *Ann. Thorac. Surg.* 78 (2004) 987–991.
- [38] D.C. Rice, J.B. Putnam Jr., Recurrent bronchogenic cyst causing recurrent laryngeal nerve palsy, *Eur. J. Cardiothorac. Surg.* 21 (3) (2002) 561–563.
- [39] A. Kosar, C. Tezel, A. Orki, H. Kiral, B. Arman, Bronchogenic cysts of the lung: report of 29 cases, *Heart, lung circulation* 18 (2009) 214–218.