

BWH ANATOMICAL BASIS OF SURGERY COURSE
3. ABDOMINAL VISCERAL PROCEDURES

CONTENTS

1. EXPLORATORY LAPAROTOMY, LYSIS OF ADHESIONS (LOA).....	15
2. SMALL BOWEL RESECTION	29
3. COLON MOBILIZATION AND RESECTION	33
4. LEFT VISCERAL MEDIAL ROTATION (MATTOX MANEUVER)	25
5. OPEN CHOLECYSTECTOMY	39
6. MOBILIZATION OF THE LIVER	45
7. LIVER “WEDGE” RESECTION (PARTIAL HEPATECTOMY, NONANATOMIC)	47
8. HEPATECTOMY, ANATOMIC	49
9. PANCREATIC AND SPLENIC RESECTIONS	57
10. OPEN SPLENECTOMY	75
11. OPEN NEPHRECTOMY	83
12. Transperitoneal right adrenalectomy	88

BWH ANATOMICAL BASIS OF SURGERY COURSE

3. ABDOMINAL VISCERAL PROCEDURES

LAB OBJECTIVES

After successfully completing Laboratory 3, you will be able to do the following.

Knowledge objectives

1. Describe the disposition of the peritoneum within the abdominal cavity. Distinguish the greater and lesser peritoneal sacs and the supracolic and infracolic regions of the greater peritoneal sac. Describe the areas of fluid accumulation within the peritoneal space of a supine patient and an upright patient. Explain the importance of the peritoneal recesses, 'gutters', and 'pouches'.
2. Classify the abdominal organs as extraperitoneal, fixed ('secondarily retroperitoneal'), and intraperitoneal. Explain how opening and developing the avascular fusion planes posterior to the fixed organs restores their intraperitoneal status while preserving their neurovascular supply.
3. Explain four ways to reach the pancreas through omenta and peritoneal ligaments.
4. Explain the general notion of organ segments in the lung, liver, kidney, and spleen.

Skills objectives

1. Perform a small bowel resection with hand-sewn or stapled enteroenterostomy
2. Perform splenic and hepatic flexure colon mobilizations and open total, subtotal, and segmental colectomies (right hemi-, extended right hemi-, left hemi-, and sigmoid colectomies).
3. Perform right medial visceral rotation (Cattell-Brasch maneuver) and left medial visceral rotation (Mattox maneuver)
4. Perform open cholecystectomy and common bile duct exploration
5. Perform right and left liver mobilizations, anatomic and "wedge" hepatic resections
6. Perform duodenal mobilization (Kocher maneuver) and pylorus preserving and conventional pancreaticoduodenectomy (Whipple procedure)
7. Perform open distal pancreatectomy and splenectomy
8. Perform open nephrectomy

PREPARATION FOR LAB

- Review this guide.
- Watch the SCORE videos listed at the end of some procedures.

3. ABDOMINAL VISCERAL PROCEDURES

3.1 ABDOMINOPELVIC CAVITY AND PERITONEAL SAC

Abdominopelvic cavity.

The abdominal walls, diaphragm, and pelvic floor surround the **abdominopelvic cavity** (Figures 3-1, 3-2, and 3-3). The **musculoskeletal boundaries of the abdominopelvic cavity** include the diaphragm and costal margin superiorly; the muscles of the abdominal wall anteriorly and laterally; the spine and posterior abdominal muscles posteriorly; and the bony pelvis and muscles of the pelvic sidewalls and pelvic floor inferiorly. A **plane passing through the pelvic inlet** (pelvic brim) marks the arbitrary boundary between the abdominal and pelvic regions of the abdominopelvic cavity. Many organs, nerves, and vessels occupy both the abdominal and pelvic cavities, however. Portions of the small intestines and sigmoid colon move freely between the abdominal and pelvic cavities.

A continuous layer of **investing deep fascia** covers the external surface of the anterolateral abdominal wall muscles. A continuous layer of **lining deep fascia** covers the internal surfaces of the muscles surrounding the abdominopelvic cavity. The lining deep fascia changes its name according to the muscle covered (Figures 3-1, 3-2, and 3-3). The lining deep fascia is **transversalis fascia** on the internal surface of the transversus abdominis muscle, **diaphragmatic fascia** on the inferior surface of the diaphragm, **psoas fascia** on the psoas muscles, **iliacus fascia** on the iliacus muscles, and so on. The lining deep fascia is prolonged through openings in the abdominal wall as the tube of **internal spermatic fascia** (continuation of the transversalis fascia) surrounding the spermatic cord and as the **femoral sheath** (a cone consisting of transversalis fascia and iliacus fascia) surrounding the femoral vessels as they emerge onto the thigh.

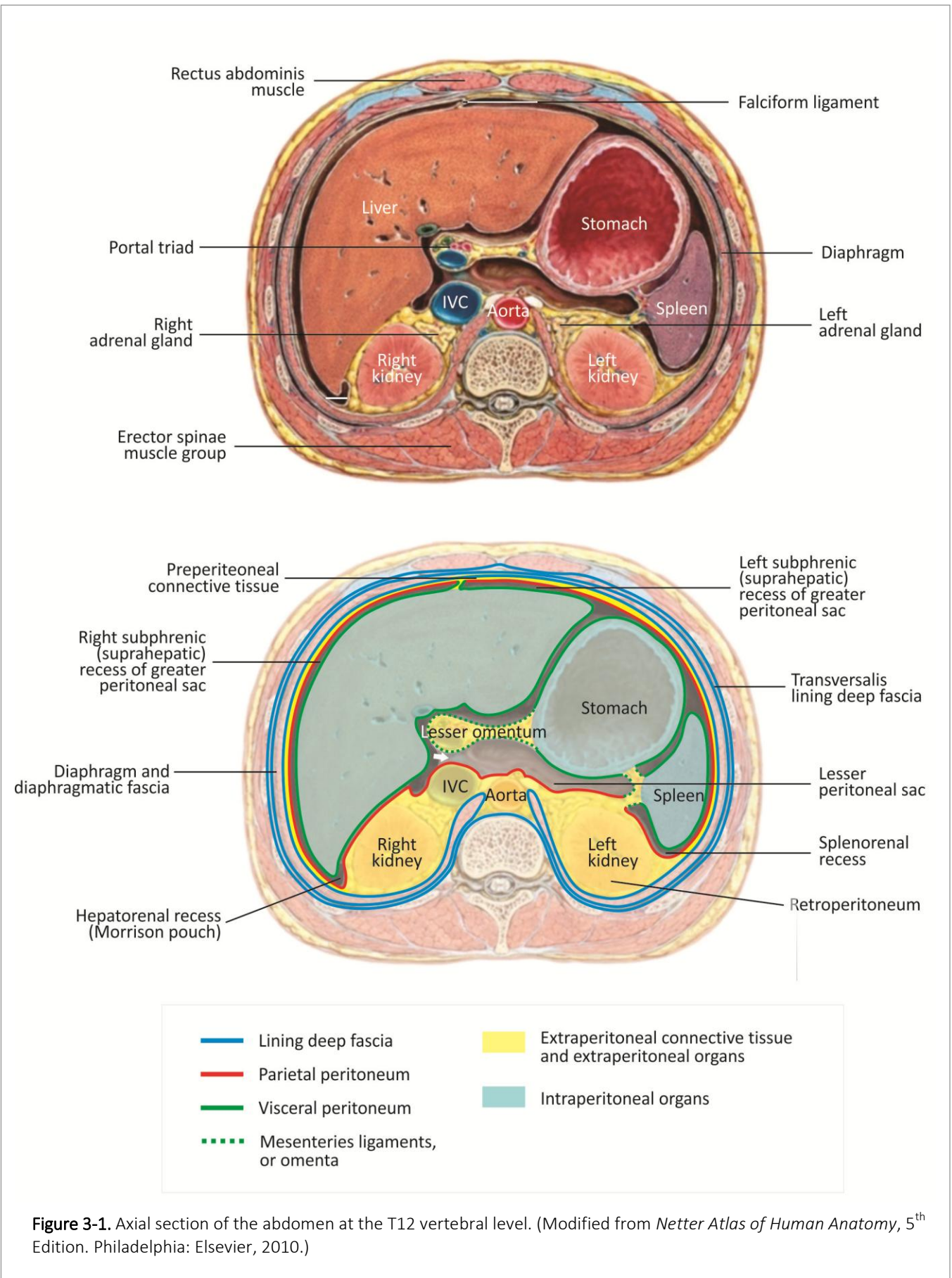


Figure 3-1. Axial section of the abdomen at the T12 vertebral level. (Modified from *Netter Atlas of Human Anatomy*, 5th Edition. Philadelphia: Elsevier, 2010.)

Peritoneal sac

The **peritoneum** is a continuous closed mesothelial sac within the abdominopelvic cavity (Figures 3-1, 3-2, and 3-3). The **peritoneal sac** encloses the **peritoneal space (cavity)**. The peritoneal space normally contains only a thin layer of lubricating serous fluid that eases sliding of the abdominopelvic viscera as they continuously change size and or position.

Different regions of the continuous peritoneal sac have different names. **Visceral peritoneum** is the portion of the peritoneal sac covering the external surfaces of the intraperitoneal abdominopelvic organs (Figures 3-1, 3-2, and 3-3). The **intraperitoneal abdominal viscera indent the outer surface of the peritoneal sac**, but lie outside the peritoneal space (cavity). **Parietal peritoneum** is the portion of the peritoneal sac lining the internal surfaces of the abdominopelvic walls, diaphragm, and pelvic floor, and forming the anterior boundary of the retroperitoneum.

Double-layered peritoneal **mesenteries, ligaments, and omenta**, continuous with both parietal and visceral peritoneum, suspend the intraperitoneal organs. **Nerves, blood vessels, and lymphatic vessels** travel **between the peritoneal layers** of the mesenteries, ligaments, and omenta to reach the intraperitoneal organs. An extension of retroperitoneal fat accompanies the neurovascular structures within the mesenteries, ligaments, and omenta.

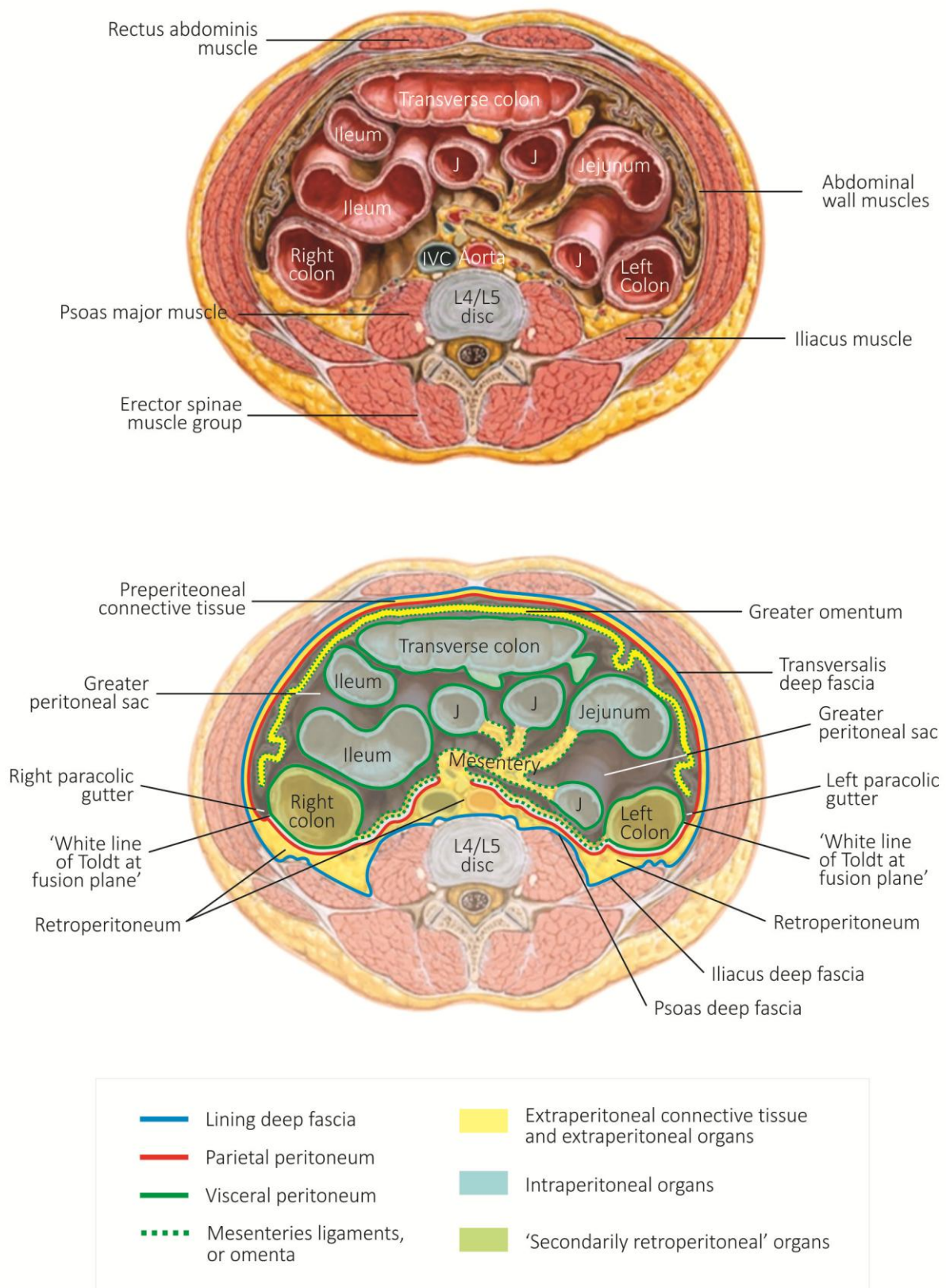


Figure 3-2. Axial section of the abdomen at the L4/L5 intervertebral disc. (Modified from *Netter Atlas of Human Anatomy*, 5th Edition. Philadelphia: Elsevier, 2010.)

Extraperitoneal regions of the abdominopelvic cavity

Extraperitoneal connective tissue fills the continuous space between the parietal peritoneum and the lining deep fascia on the inner surface of the abdominopelvic cavity (Figures 3-1, 3-2, and 3-3, yellow fat). Extraperitoneal connective tissue, consisting of adipocytes and collagen fibers, anchors the parietal peritoneum to the lining deep fascia of the abdominopelvic walls, fills spaces between the extraperitoneal viscera, and follows nerves and blood vessels into peritoneal ligaments and mesenteries.

The thinner region of extraperitoneal connective tissue anterior to the peritoneal sac is **preperitoneal connective tissue (fascia, fat)**. Preperitoneal connective tissue extends inferiorly into the **retropubic space** of Retzius. The thicker region of extraperitoneal connective tissue posterior to the peritoneal sac is the **retroperitoneum**. Retroperitoneal connective tissue extends into the pelvis to fill spaces around the infraperitoneal rectum and the pelvic urogenital organs. Preperitoneal, retroperitoneal, and infraperitoneal fat are continuous at undefined boundaries.

In some regions, collagen fibers in the extraperitoneal connective tissue condense to form demonstrable **named collagenous ligaments or fasciae** that support the kidneys and pelvic organs. Examples are the **anterior renal fascia** (of Gerota) and **posterior renal fascia** (of Zuckerkandl) surrounding the perirenal fat, the **transverse cervical ligament** (cardinal or Mackenrodt ligament), and the **ligament of Treitz**.

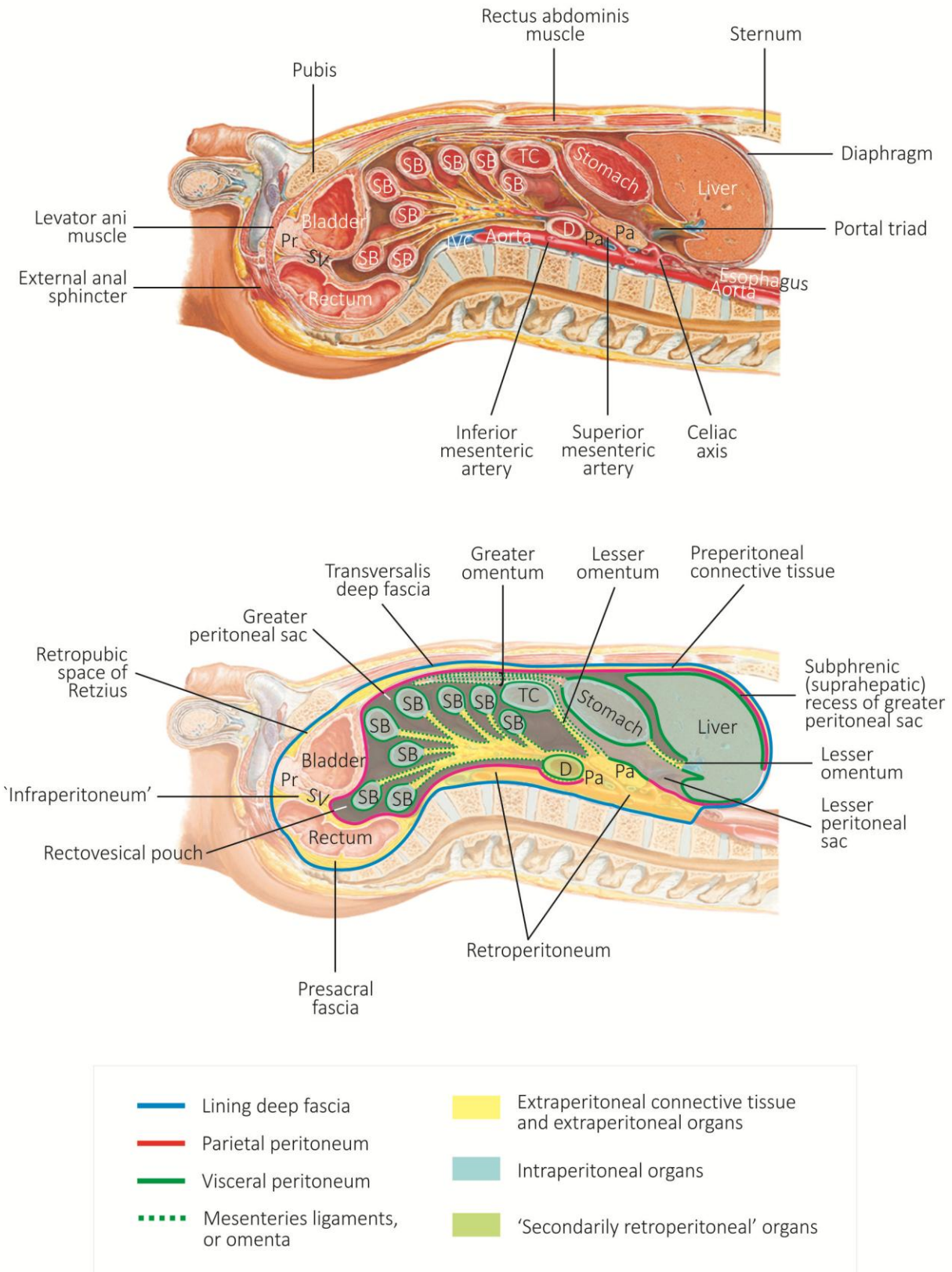


Figure 3-3. Parasagittal section of the abdomen. (Modified from Netter Atlas of Human Anatomy, 5th Edition. Philadelphia: Elsevier, 2010.)

3.2 DEVELOPMENT OF THE GASTROINTESTINAL TRACT AND MESENTERIES

Primitive gut tube

The **primitive gut tube** forms during the **second and third weeks of development** (Figure 3-4, next page).

The **glandular epithelium** lining the gut tube, and forming the parenchyma of the lungs, liver, gallbladder, and pancreas, develops from **embryonic endoderm**.

The **connective tissue and smooth muscle** of the gut tube, the **visceral peritoneum, mesenteries, and peritoneal ligaments** develop from **lateral plate splanchnic mesoderm**.

The **parietal peritoneum** lining the abdominal cavity develops from **lateral plate somatic mesoderm**.

The embryonic gut forms initially as a **straight tube** suspended within the dorsal mesentery and ventral mesentery (Figure 3-4). **Two basic developmental processes** alter this simple configuration.

Differential growth of some regions of the gastrointestinal tract, principally the small intestine, leads to elongation and rotation of the gut tube. Abnormalities associated with mistakes in this process are **intestinal nonrotations** or **malrotations**.

Exuberant growth of the gut epithelium initially fills the developing gut lumen. Patency of the definitive gut depends on **subsequent recanalization** of the tube. Abnormalities associated with mistakes in this process are gastrointestinal **stenoses** or **atresias**.

Gut tube divisions and arterial supply

By the **fifth week of development**, the foregut, midgut, and hindgut regions of the gastrointestinal tract are established (Figure 3-4, week 5). Each region is supplied by a single unpaired branch of the aorta.

The intra-abdominal portion of the **foregut region** includes the distal esophagus, stomach, and duodenum proximal to the entrance of the common bile duct. Foregut structures are typically supplied by branches of the **celiac axis** (trunk, artery). An important anatomic exception to this rule is the **right replaced hepatic artery**, a branch of the superior mesenteric artery.

The **midgut region** includes the duodenum distal to the entrance of the common bile duct, jejunum, ileum, right (ascending) colon, and transverse colon proximal to the splenic flexure. Midgut structures are typically supplied by branches of the **superior mesenteric artery**.

The **hindgut region** includes the splenic flexure, left (descending) colon, sigmoid colon, and proximal rectum. Hindgut structures are typically supplied by branches of the **inferior mesenteric artery**. The **middle and inferior rectal arteries**, direct or indirect branches of the internal iliac artery, supply the distal rectum.

Primitive mesenteries

Peritoneal mesenteries, ligaments, and omenta consist of two layers of peritoneum surrounding a core consisting of autonomic nerves, blood vessels, lymphatic vessels, and extraperitoneal connective tissue. In the 5-week embryo, the spleen and *all* regions of the gastrointestinal tract remain **intraperitoneal** (Figure 3-4) and mobile. The foregut, midgut, hindgut, spleen, and dorsal pancreatic bud are suspended from the dorsal body wall within the **dorsal mesentery**. The liver, gallbladder, and bile ducts, and are anchored to the anterior body within the **ventral mesentery**.

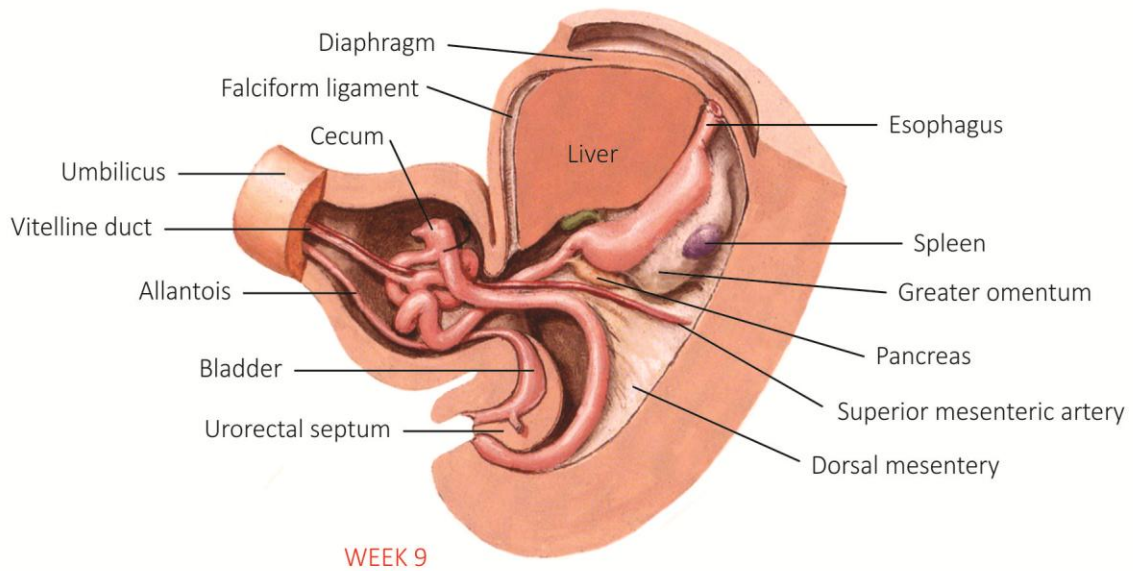
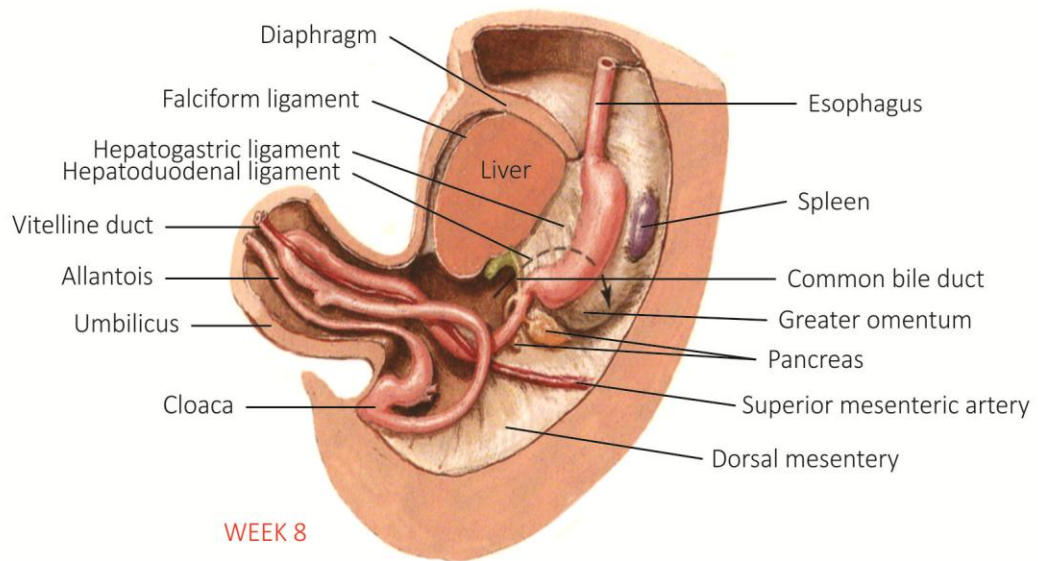
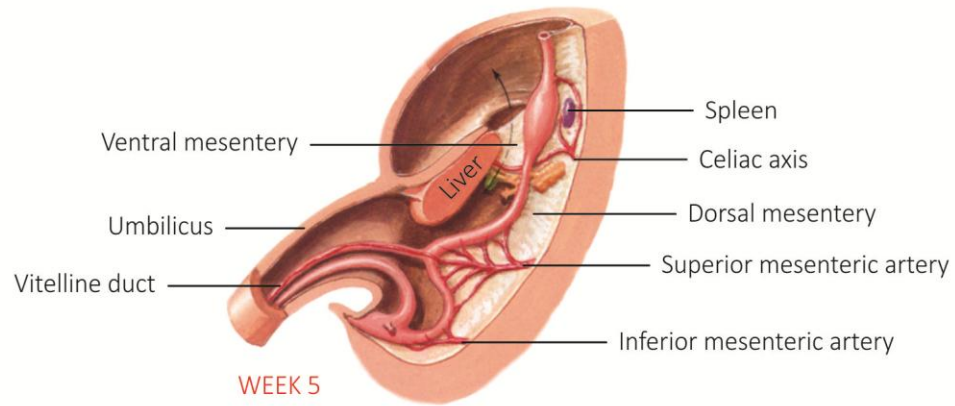


Figure 3-4. Development of the digestive system. (Modified from *Netter Atlas of Human Anatomy*, 5th Edition. Philadelphia: Elsevier, 2010.)

The simple primitive gut tube and mesenteries of the 5-week embryo subsequently undergo differential **elongation, rotation, and fusion** of some regions to the parietal peritoneum anterior to the retroperitoneum. Regardless of the complexity of subsequent developmental processes, the definitive gastrointestinal tract **retains its basic arterial supply** and the **peritoneal fusion planes can be reopened** and developed to restore mobility to the fixed (secondarily retroperitoneal) portions of the gastrointestinal tract.

Rotation, elongation, fusion, and confusion

During the 6th week of development, the **stomach rotates 90°** in its longitudinal axis. Following rotation, the lesser curvature of the stomach faces to the right, and the liver, gallbladder, and ventral mesentery (now the falciform ligament and lesser omentum) lie on the right side of the abdominal cavity. The greater curvature of the stomach faces left, and the spleen and splenic ligaments lie on the left side of the abdominal cavity (Figure 3-4, previous page). During this process, the **second, third, and fourth parts of the duodenum** and the **head, neck, body, and most of the tail of the pancreas** are pressed backward against the parietal peritoneum. The posterior leaf of the mesoduodenum and the visceral peritoneum on the posterior surfaces of the duodenum and pancreas fuse with the parietal peritoneum. This fusion plane can be reopened and developed (**Kocher maneuver**) to mobilize the pancreas and duodenum (Figure 3-5). The **spleen** retains its mobility and its ligaments. The **greater omentum**, an extended saccular region of the dorsal mesentery, hangs inferiorly from the greater curvature.

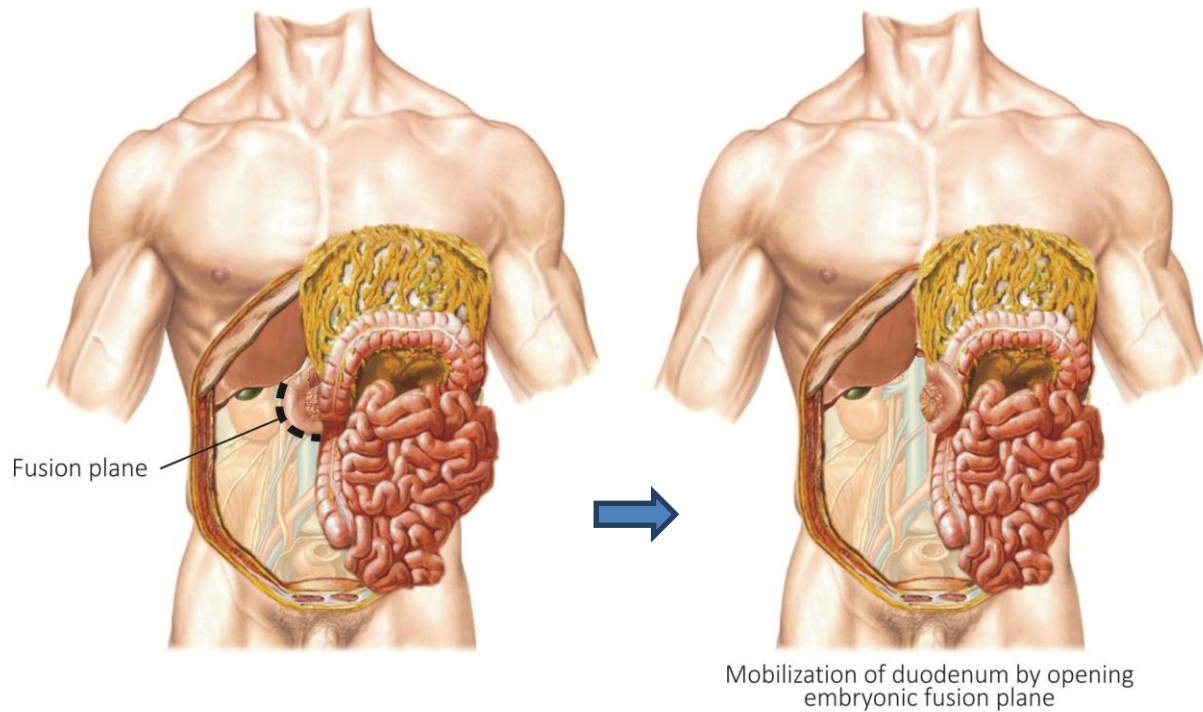


Figure 3-5. Mobilization of the duodenum and head of the pancreas. (Modified from *Netter Atlas of Human Anatomy*, 5th Edition. Philadelphia: Elsevier, 2010.)

At the same time, the **small and large intestines elongate dramatically, herniate anteriorly** into the umbilicus, and **rotate 270°** before returning to the confines of the abdominal cavity (Figure 3-4, previous page). Following rotation and return, the **jejunum and ileum** lie centrally, retaining their mesentery and their mobility. The **large intestine** forms a three-sided frame around the small intestines, and the **ascending (right) colon** and **descending (left) colon** are pressed backward against the parietal peritoneum. The ascending mesocolon, descending mesocolon, and the visceral peritoneum on the posterior surfaces of the ascending colon and descending colon fuse with the parietal peritoneum. The **transverse colon** retains its transverse mesocolon and its mobility. The **greater omentum** and the mesentery of the transverse colon (**transverse mesocolon**) also fuse during rotation and fixation of the embryonic gastrointestinal tract. The major portion of the greater omentum, between the stomach and transverse mesocolon, is the **gastrocolic ligament**, an important boundary within the abdominopelvic cavity.

White lines of Toldt

The **white lines of Toldt** mark the lateral limits of the fusion planes between the parietal peritoneum, the ascending colon, and the relict of the ascending mesocolon on the right, and between the parietal peritoneum, the descending colon, and the relict of the descending mesocolon on the left (Figure 3-6). Opening and developing these fusion planes restores mobility to the ascending colon and ascending mesocolon (**right medial mobilization**) and to the descending colon and descending mesocolon (**left medial mobilization**). The fusion planes are relatively '**bloodless planes**', since the major nerves, blood vessels, and lymphatic vessels run **within the peritoneal mesenteries and ligaments** and not between them. One notable exception occurs during the formation of extensive portocaval shunts posterior to the ascending and descending colon in portal hypertension.

Blood supply, venous drainage, lymphatic drainage, and innervation

The embryonic division of the gastrointestinal tract into foregut, midgut, and hindgut arterial provide the key to understanding its venous drainage, lymphatic drainage, and autonomic innervation. The spleen and gastrointestinal tract are supplied by **three unpaired branches of the aorta** (Figure 3-4). **Branches of the celiac axis** supply the **spleen** and **foregut structures** including the distal esophagus, stomach, first part of the duodenum, liver, gallbladder, pancreas, and spleen. **Branches of the superior mesenteric artery** supply **midgut derivatives** including the remainder of the duodenum, the jejunum, the ileum, the ascending colon, most of the transverse colon. **Branches of the inferior mesenteric artery** supply **hindgut derivatives** including the splenic flexure of the transverse colon, descending colon, sigmoid colon, and most of the rectum.

Venous blood from structures supplied by the three unpaired branches of the aorta drain through **portal tributaries** to the **portal vein and liver**.

Lymphatic vessels follow arteries to **mesenteric lymph nodes** and then to **pre-aortic nodal basins** surrounding the origins of the **celiac, superior mesenteric, and inferior mesenteric arteries**.

Autonomic nerve plexuses surrounding the origins of the celiac, superior mesenteric, and inferior mesenteric arteries provide parasympathetic visceral motor, sympathetic visceral motor, and visceral sensory innervation foregut, midgut, and hindgut regions of the gastrointestinal tract.

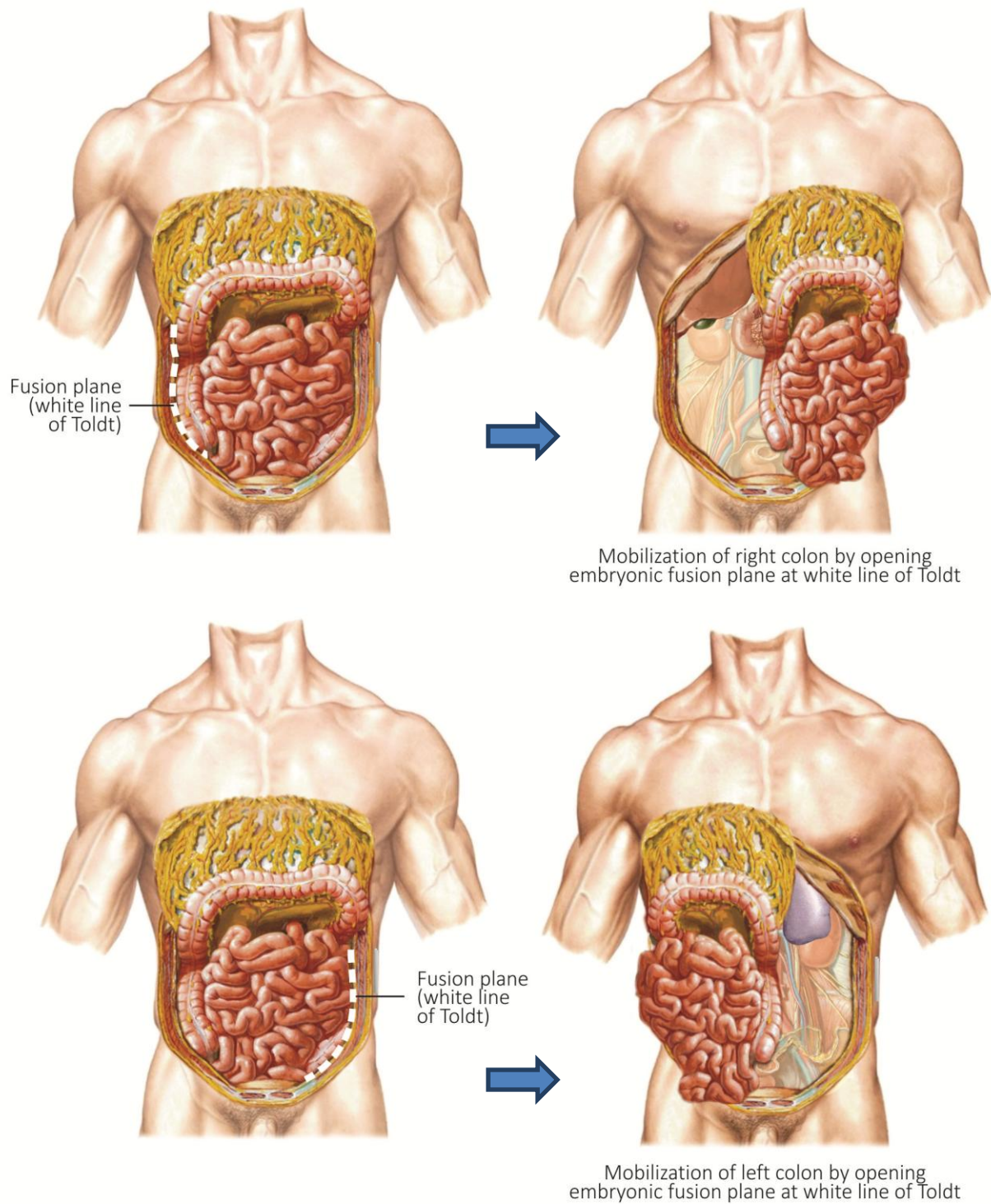


Figure 3-6. Mobilization of right and left colon by opening embryonic fusion plane (white line of Toldt). (Modified from *Netter's Atlas of Human Anatomy*, New York: Elsevier, 2010.)

3.4 OPENING THE ABDOMINOPELVIC CAVITY

Peritoneal adhesions may form between different areas of visceral peritoneum, or between visceral peritoneum and parietal peritoneum or mesenteries. In the gross lab, small adhesions can be gently removed using fingers or blunt-tipped scissors. If a perforation occurs during resolution of peritoneal adhesions, please notify your instructor who will show you a cool trick with a glove.

EXPLORATORY LAPAROTOMY, LYSIS OF ADHESIONS (LOA)

- ☞ *Beginning superiorly, use forceps or a hemostat to lift the posterior layer of the rectus sheath away from the underlying xiphoid process. Using the scissors or scalpel, make a 2 cm cut through the posterior layer of the sheath 1 cm lateral and to the left of the midline of the xiphoid process and linea alba (Figure 3-7, incision 1). Continue lifting the abdominal wall away from the viscera and, using the blunt-tipped scissors, continue incision inferiorly to the pubic symphysis. Reflect the edges of the midline incision until you can see the underlying abdominal viscera.*
- ☞ *Keeping the abdominal viscera in view, and the abdominal wall as far as possible from the viscera, complete the subcostal incisions 2 and 3 (Figure 3-7,) on the left side of the body only. Reflect the left abdominal wall flap laterally to the posterior axillary line.*
- ☞ *Turn the internal surface of the right abdominal wall flap outward, and identify the **falciform ligament** on the internal surface of the flap. Follow the falciform ligament inferiorly to the umbilicus, and superiorly to the anterior surface of the **liver** (Figure 3-8). Within the falciform ligament (a peritoneal ligament) identify the **round ligament** (the embryonic remnant of the umbilical vein).*
- ☞ *Lifting the right abdominal wall flap away from the viscera, complete incisions 4 and 5 (Figure 3-7). Reflect the right abdominal wall flap laterally to the posterior axillary line.*
- ☞ *Return to the **diaphragm**. Working from the thoracic surface, lift the diaphragm superiorly, away from the abdominal viscera. Use rib cutters to cut the xiphoid process in the midline; use scissors to divide the diaphragm from its xiphoid attachment superiorly to the anterior margin of the caval foramen (Figure 3-7, incision 6).*
- ☞ *Beginning at the xiphoid process, use blunt-tipped scissors to detach the **diaphragm** from the costal margin. Fold the cut edges of the costal cartilages laterally to permit better access to the abdominal cavity. If necessary, divide the costal cartilages with the rib cutters to prevent their intrusion into the dissection field.*
- ☞ *Enter the **preperitoneal connective tissue** and follow this plane posteriorly to the retroperitoneal connective tissue.*

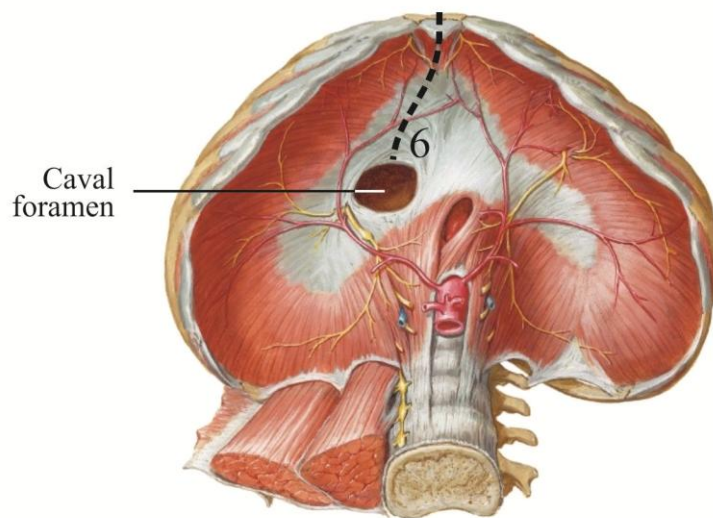
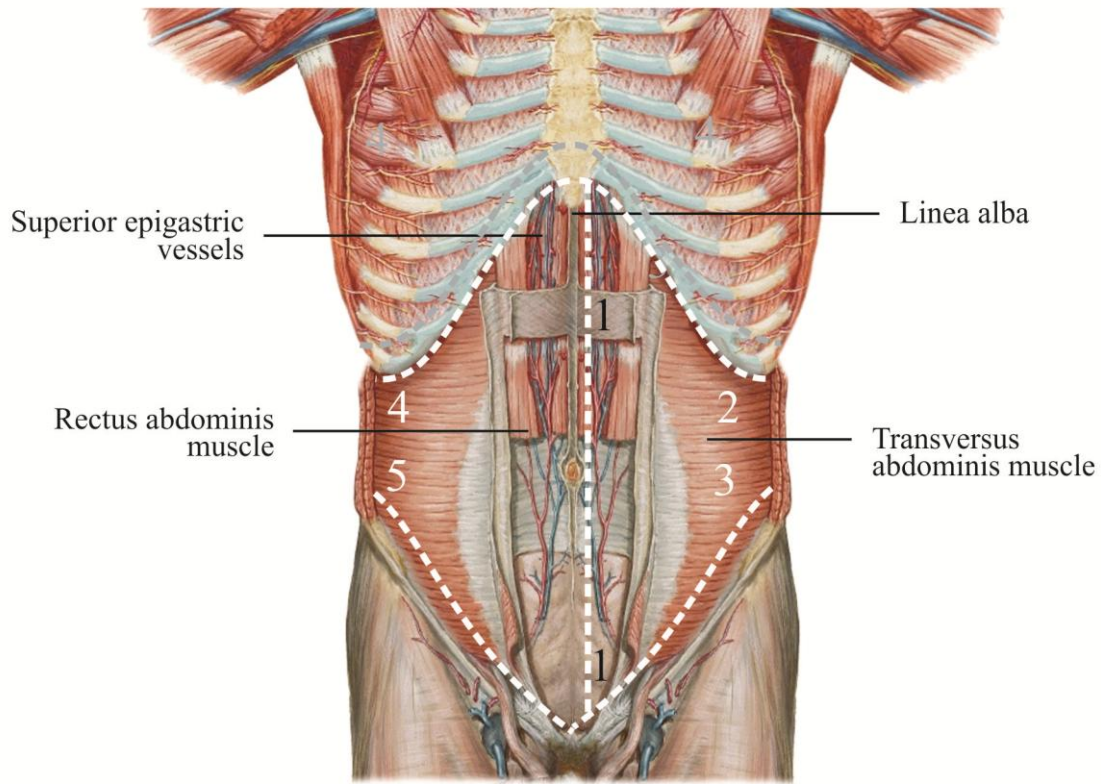


Figure 3-7. Incisions through the anterior abdominal wall and diaphragm. (Modified from *Netter's Atlas of Human Anatomy*, New York: Elsevier, 2006.)

Exploration of the greater peritoneal sac

The **greater peritoneal sac** includes the entire extent of the peritoneal sac *except* the lesser peritoneal sac (omental bursa) (Figures 3-1 through 6-3). The **lesser peritoneal sac** is the region posterior to the lesser omentum, liver and stomach. You will explore the lesser peritoneal sac later in this laboratory. The greater and lesser sacs communicate through the **epiploic foramen** (of Winslow).

The **gastrocolic ligament** separates the greater peritoneal sac into supracolic and infracolic regions (compartments) (Figure 3-8). The **supracolic region** of the greater peritoneal sac lies superior to the gastrocolic ligament. The **infracolic region** lies inferior to the gastrocolic ligament and transverse mesocolon.

- ☞ *Within the abdominal cavity, identify the **greater omentum** (Figure 3-8). The greater omentum is quite variable in size and thickness. The major, mobile portion of the greater omentum is the gastrocolic ligament.*
- ☞ *Identify the **supracolic region** of the greater peritoneal sac superior to the greater omentum (Figure 3-8, top). Within the supracolic region, identify the **liver, gallbladder** (if present), and **stomach**.*
- ☞ *Lift the inferior edge of the greater omentum superiorly. Since the greater omentum and transverse mesocolon are fused, the transverse colon will be reflected superiorly with the greater omentum. Identify the **transverse colon** on the internal surface of the greater omentum (Figure 3-8, bottom).*
- ☞ *Identify the **infracolic region** of the greater peritoneal sac inferior to the greater omentum and transverse mesocolon. Within the infracolic region, identify the myriad coils of **small bowel** centrally, and the **ascending, transverse, and descending colon** framing the small bowel laterally and superiorly (Figure 3-8, bottom).*
- ☞ *Follow the ascending colon superiorly to the **hepatic flexure** where the ascending colon becomes continuous with the transverse colon (Figure 3-8). Follow the descending colon superiorly to the **splenic flexure** where the transverse colon becomes continuous with the descending colon (Figure 3-8). On the left side, use your hand to follow the abdominal wall posteriorly until you can palpate the rounded, solid contours of the **spleen** (Figure 3-8). Gently draw the spleen anteriorly to better visualize its surface.*

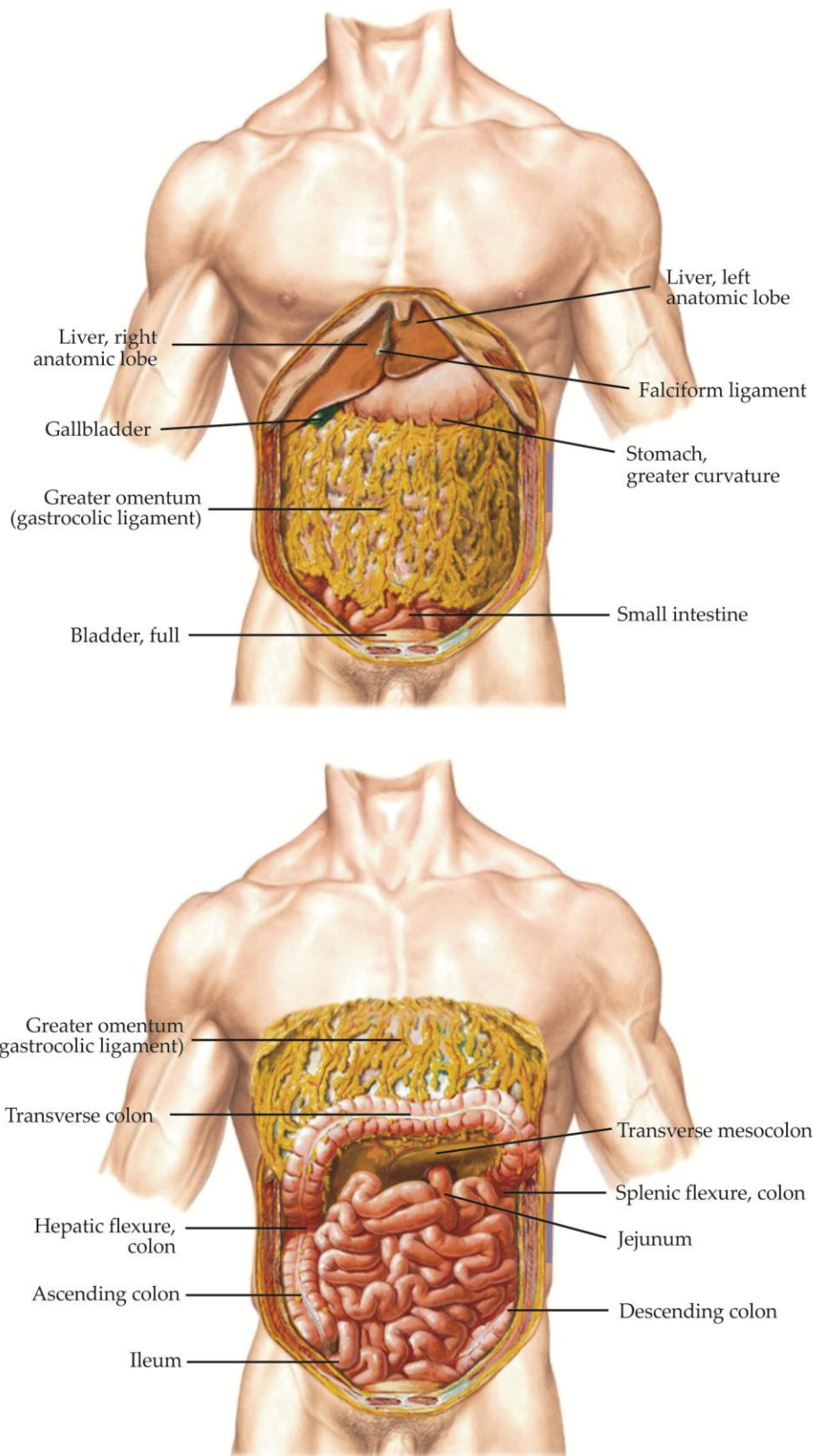


Figure 3-8. Supracolic region (top) and infracolic region (bottom) of the greater peritoneal sac. (Modified from *Netter's Atlas of Human Anatomy*, New York: Elsevier, 2006.)

Peritoneal pouches and gutters

The embalming fluid accumulated in the abdominal cavity of your donor offers an opportunity to study the areas of fluid accumulation within the peritoneal space and the pathways for the passage of peritoneal fluid or blood, or the spread of infection or tumor cells, within the peritoneal space. In the supine patient, the most dependent (lowest) regions of the peritoneal sac are the **hepatorenal recess (Morrison's pouch)** superiorly and the **rectovesical pouch** in males (Figure 3-9) or the **rectouterine pouch** (of Douglas) in females.

☞ *Lateral to the ascending and descending colon, identify the **left and right paracolic recesses** ('gutters'), which usually contain accumulations of embalming fluid (Figure 3-9). On the right side, follow the right paracolic gutter superiorly, reach behind the liver, and try to locate the **hepatorenal space (Morrison's pouch)** (Figure 3-9). Follow the left paracolic recess superiorly to the spleen. Although the gastrocolic ligament and transverse mesocolon present a median barrier to the passage of fluid or tumor cells between the supracolic and infracolic regions of the greater peritoneal sac, these regions are continuous laterally through the paracolic recesses.*

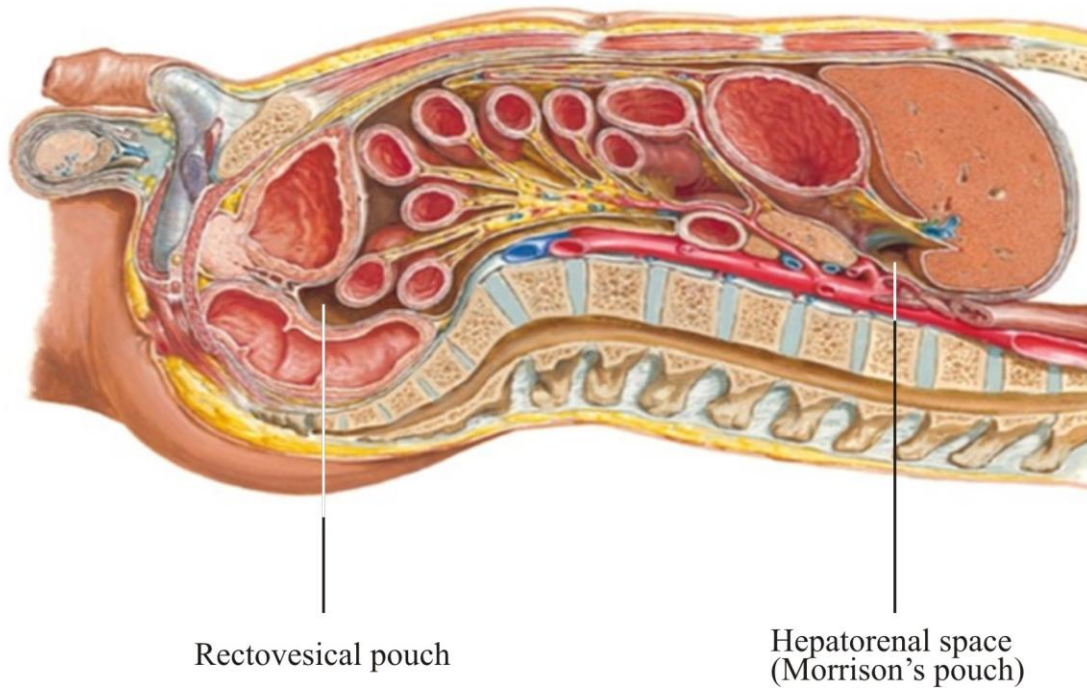


Figure 3-9. Peritoneal pouches. (Modified from *Netter's Atlas of Human Anatomy*, New York: Elsevier, 2006.)

Supracolic region of the greater peritoneal sac

- ☞ *Return to the falciform **ligament** (Figure 3-10). Superiorly, the two layers of the falciform ligament diverge and reflect onto the inferior surface of the diaphragm. On the left side of the body, use your hand to follow the left layer of the falciform ligament to its continuation as the **left coronary ligament of the liver**, then follow the peritoneal attachment of the liver to the diaphragm laterally and identify the **left triangular ligament** (Figure 3-10).*
- ☞ *On the right side, use your hand to follow the right layer of the falciform ligament to its continuation as the **right coronary ligament**, then follow the peritoneal attachment of the liver to the diaphragm laterally and identify the **right triangular ligament** (Figure 3-10).*
- ☞ *Gently lift the anterior margin of the liver, and identify the **gallbladder**, if present (Figure 3-9). Identify the **lesser omentum**, a double fold of peritoneum stretching between the inferior surface of the liver and the stomach and first part of the duodenum (Figure 3-10).*
- ☞ *Follow the lesser omentum to the **lesser curvature** of the stomach. Follow the greater omentum to the **greater curvature** of the stomach. Identify the **cardia, fundus, body** and **pyloric region** of the stomach (Figure 3-7). Superior to the cardia, identify the abdominal portion of the **esophagus**. Palpate the thick **pyloric sphincter** just proximal to the duodenum.*
- ☞ *Distal to the pyloric sphincter, identify the **first part of the duodenum** (Figure 3-10). The second, third, and fourth parts of the duodenum are fixed to the posterior abdominal wall; you will see them later in your dissection as they pass posterior to the mesentery of the transverse colon.*
- ☞ *Between the diaphragm and liver, identify the **left and right subphrenic (suprahepatic) recesses**.*

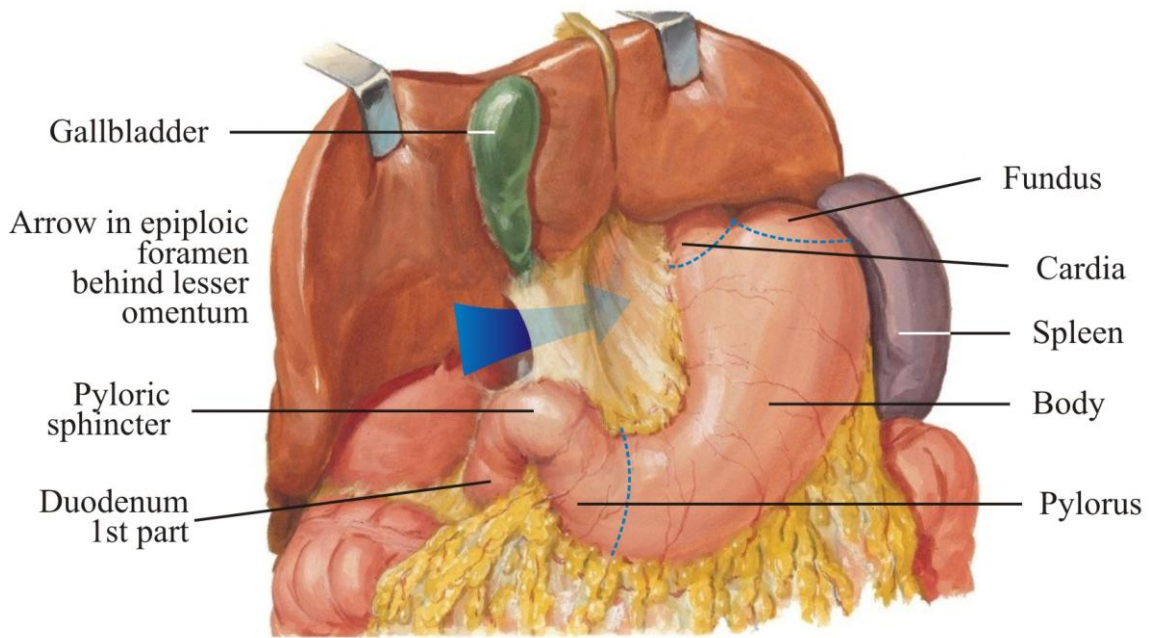
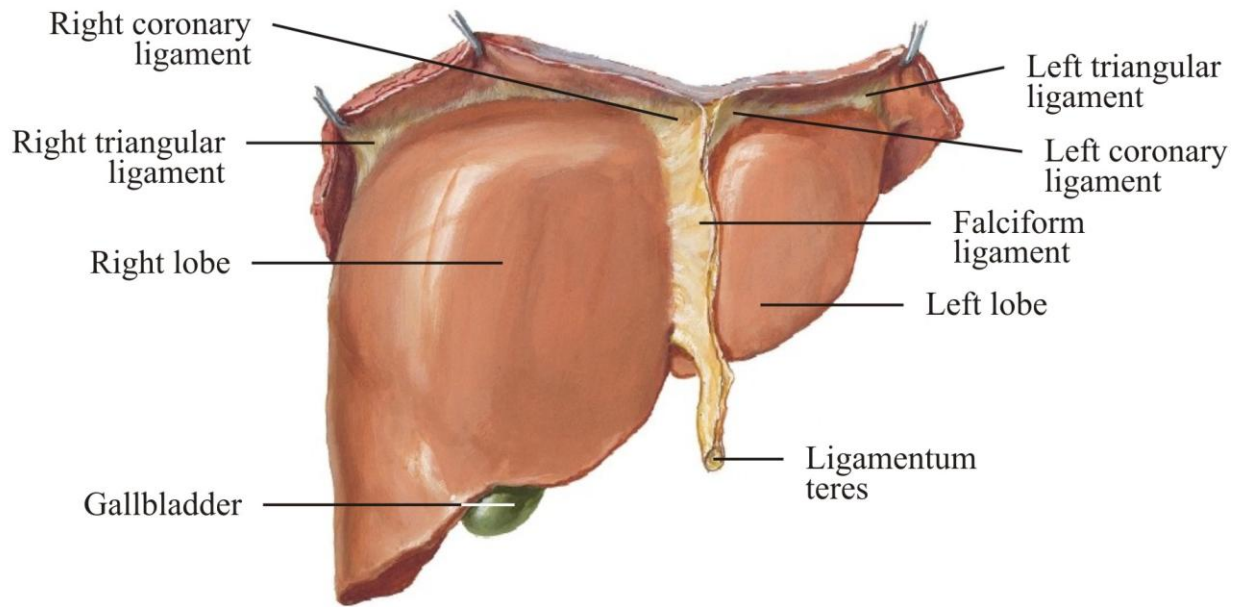


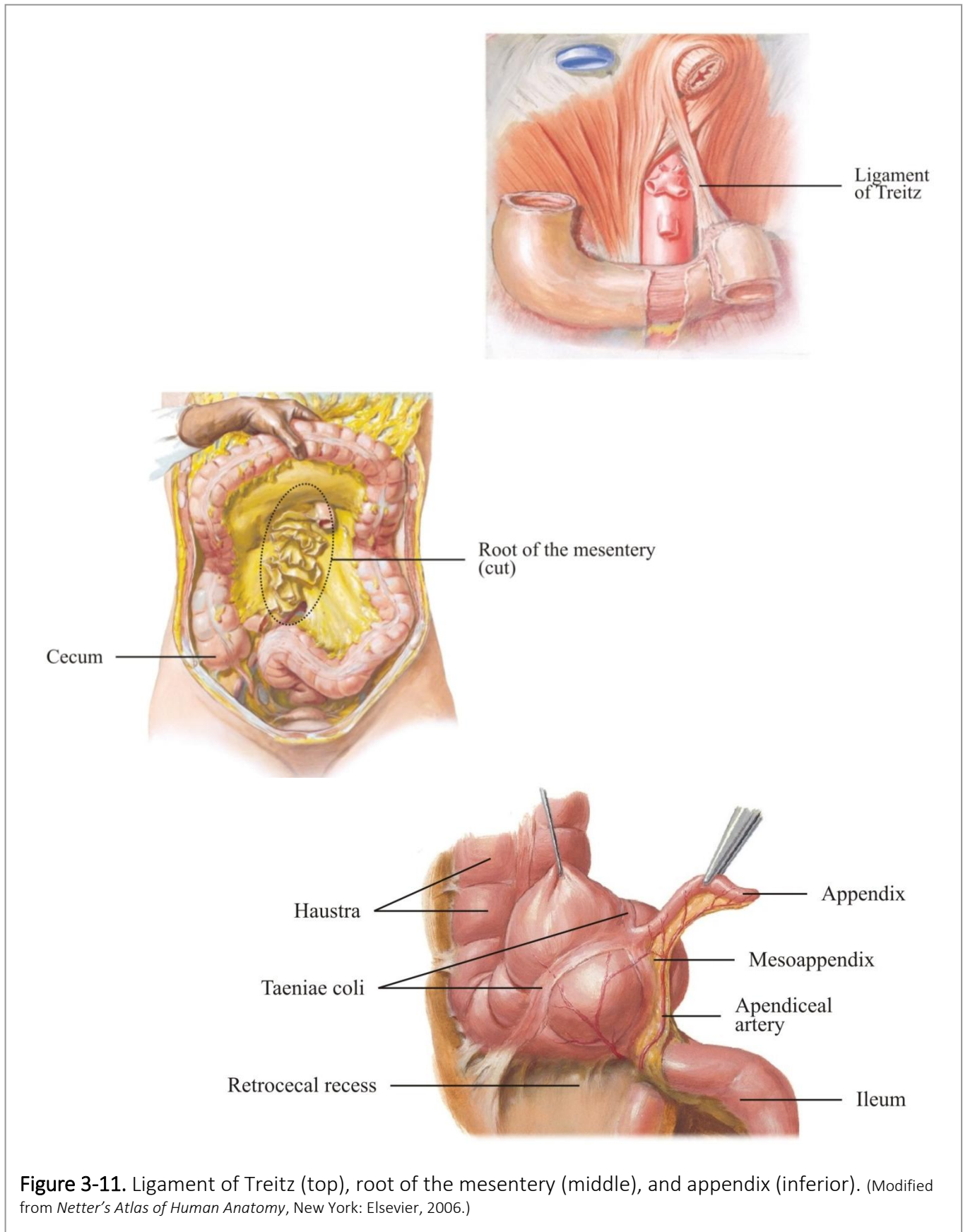
Figure 3-10. Liver and stomach. The arrow is passing through the epiploic foramen (of Winslow). (Modified from *Netter's Atlas of Human Anatomy*, New York: Elsevier, 2006.)

Infracolic region of the greater peritoneal sac

- ☞ Release any adhesions you encounter during your exploration of the infracolic region, but reserve dissection until later.
- ☞ Again, lift the inferior edge of the greater omentum and reflect it superiorly. Lift the small intestine, carefully separating any adhesions, and identify the **mesentery**, the double layer of peritoneum suspending the small intestines from the posterior body wall. Identify the **mesenteric surface** of the small intestine, where the mesenteric vessels and visceral motor and sensory nerves reach the small intestine, and the free **antimesenteric surface**.
- ☞ Follow the small intestine proximally to the junction of the **jejunum** and the duodenum, where the jejunum is suspended from the posterior abdominal wall by the **ligament of Treitz** (Figure 3-11, but do not try to replicate the dissection shown). Palpate the **ligament of Treitz** within the extraperitoneal connective tissue surrounding the jejunum, and follow the ligament superiorly to its attachment. The ligament of Treitz marks the boundary between the upper and lower gastrointestinal tracts.
- ☞ Follow the jejunum distally to the **ileum**, gently liberating the small intestine from any adhesions you encounter. The small intestine should now lie freely mobile within the peritoneal sac, anchored only by its mesentery. At the root of the mesentery, the peritoneal layers of the mesentery diverge and reflect onto the retroperitoneum as parietal peritoneum. Follow the mesentery to the **root of the mesentery** along an oblique line between the first part of the jejunum and the cecum (Figure 3-11, but do not try to replicate this dissection).
- ☞ Run the small bowel.

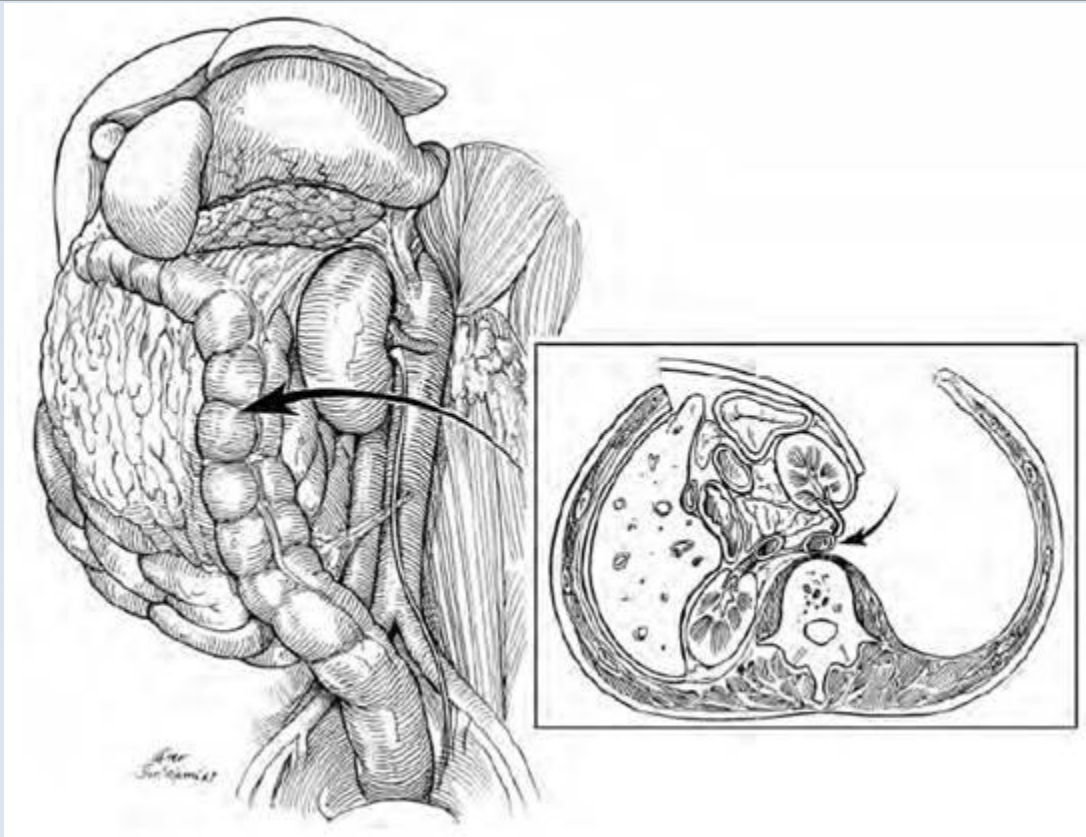
Appendix

- ☞ Follow the ileum to the **cecum** (Figure 3-11). Lift the cecum, and identify the **retrocecal recess**. On the convoluted surface of the cecum, identify the **taeniae coli**, the conspicuous bands of outer longitudinal smooth muscle, and the bulging **haustra** (Figure 3-12). In the colon, the outer longitudinal layer of the muscularis externa divides into the three taenia coli. The wall of the colon between the taeniae expands as the haustra (sacculations), which have only circularly arranged smooth muscle.
- ☞ Follow the taeniae coli inferiorly to their convergence at the **appendix** (or the site of its surgical removal) (Figure 3-11). The appendix may extend inferiorly from the cecum into the peritoneal cavity or it may lie within the retrocecal recess posterior to the cecum (retrocecal appendix). Straighten the appendix, and identify the **mesoappendix**, a fold of peritoneum between the appendix and the parietal peritoneum over the retroperitoneum. Within the mesoappendix, identify the **appendiceal artery**.
- ☞ Return to the **descending colon**. Little tags of fat, the **epiploic appendices**, may adorn the surface of the colon within the visceral peritoneum.

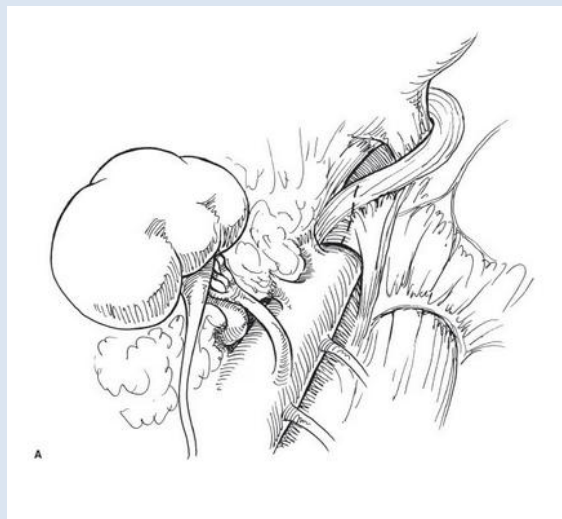


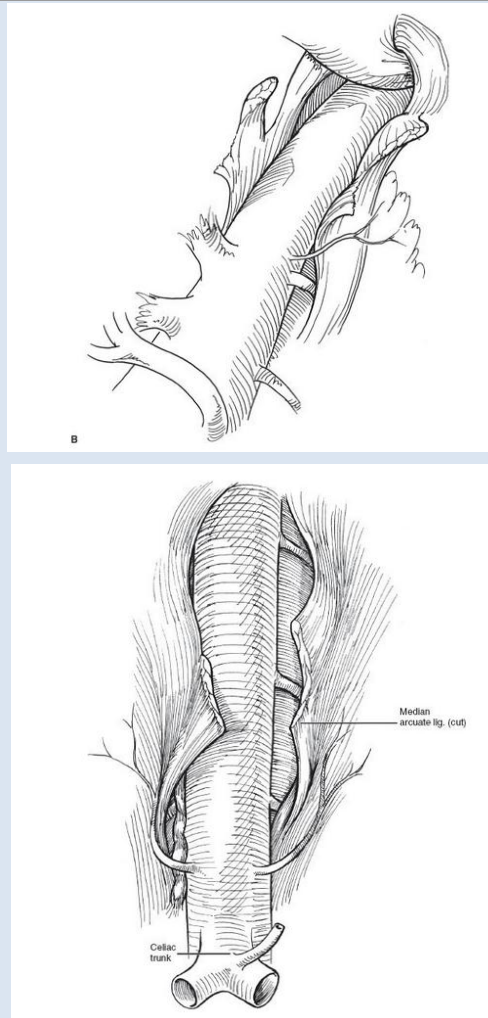
LEFT VISCERAL MEDIAL ROTATION (MATTOX MANEUVER)

- ☞ Depending on the mechanism (blunt v. penetrating) and extent of injuries, laparotomy through a generous midline incision should be followed by four-quadrant packing
- ☞ Left colon mobilization
 - o Beginning at the sigmoid colon, place medial retraction on the descending colon and incise the white line of Toldt heading superiorly toward the splenic flexure as discussed above (see "left colon and splenic flexure mobilization")
- ☞ Splenic mobilization
 - o Rather than coming across the splenic flexure at this point, as you will do in the left hemicolectomy dissection below, continue to incise the peritoneum to the left of the spleen to free it from its lateral attachments
 - o Insinuate your fingers posterior to the spleen and left kidney and you will be able to rotate the spleen, pancreas, and left kidney medially if you are in the correct plane—your hand should lie directly on the posterior abdominal wall musculature
 - if exposure of the aorta is the goal, then the left kidney should be elevated to medialize the renal artery and vein
 - However, if the left kidney is the target for exposure, the left kidney should be left in situ and other organs mobilized as above
 - o To further illustrate the relations of the spleen (not necessary as part of the Mattox maneuver) ...
 - Identify and divide the **phrenicocolic** and **phrenicosplenic** ligaments. Both ligaments are peritoneal reflections containing connective tissue but no blood vessels. Reach behind the **spleen** and draw it anteriorly. Rolled up lap pads may be placed posterior to the spleen to elevate it further. By palpation, identify the **tail of the pancreas** directly adjacent to the hilum of the spleen.
 - Identify the **splenorenal ligament** (lienorenal ligament) between the spleen and left kidney, and the **splenic vessels** within the splenorenal ligament entering the hilum of the spleen. Identify the **gastrosplenic ligament** between the spleen and stomach. Identify the **short gastric branches** of the splenic artery within the gastrosplenic ligament.
- ☞ Finding the correct plane may be more challenging in a cadaver, but in clinical situations where left medial visceral rotation is warranted, the retroperitoneal hematoma will typically separate the appropriate planes, facilitating rapid, blunt, manual dissection by the operator



☞ Further exposure of the descending thoracic aorta for clamp placement can be achieved by dividing the median arcuate ligament and left crus of the diaphragm





Valentine JR and Wind GG. Anatomic exposures in vascular surgery. Lippincott Williams & Wilkins, 2003.

📺 Mattox maneuver, suprarenal aortic control:

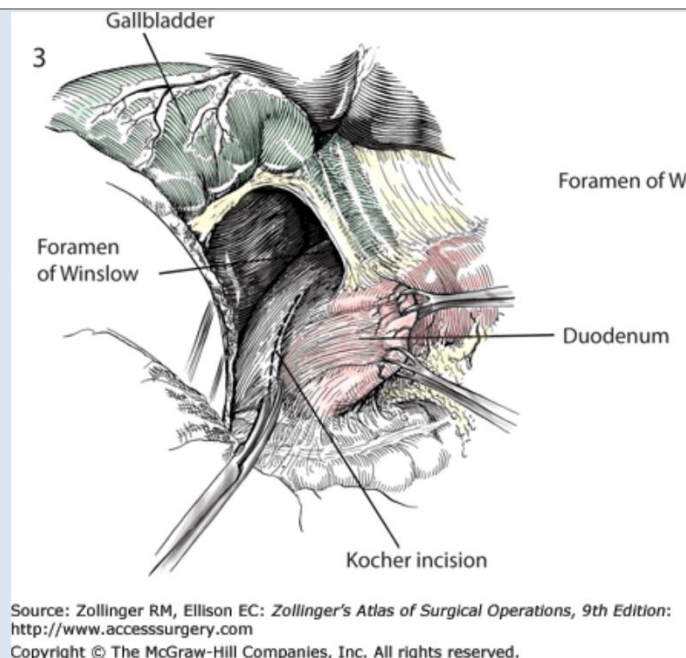
<http://www.surgicalcore.org/videoplayer/510000039/50>

RIGHT MEDIAL VISCERAL ROTATION (CATTELL-BRAASCH MANEUVER)

Hirschberg and Mattox recommend dividing the right-sided medial visceral rotation into 3 steps

☞ *Classic Kocher maneuver (duodenal mobilization)*

o *Incise the posterior peritoneum immediate lateral to the 2nd portion of the duodenum*



- o Bluntly dissect underneath the duodenal C-loop and pancreatic head and elevate these to place tension on their attachments
- o Incise the peritoneum along the 1st portion of the duodenum to the hepatoduodenal ligament, being sure not to injure the common bile duct and other portal triad structures
- o Incise the inferior peritoneum along the 3rd portion of the duodenum
- o On the posterior surface of the neck of the pancreas, identify the **superior mesenteric vessels** and the **uncinate process** of the pancreas where it extends posterior to the superior mesenteric vessels.

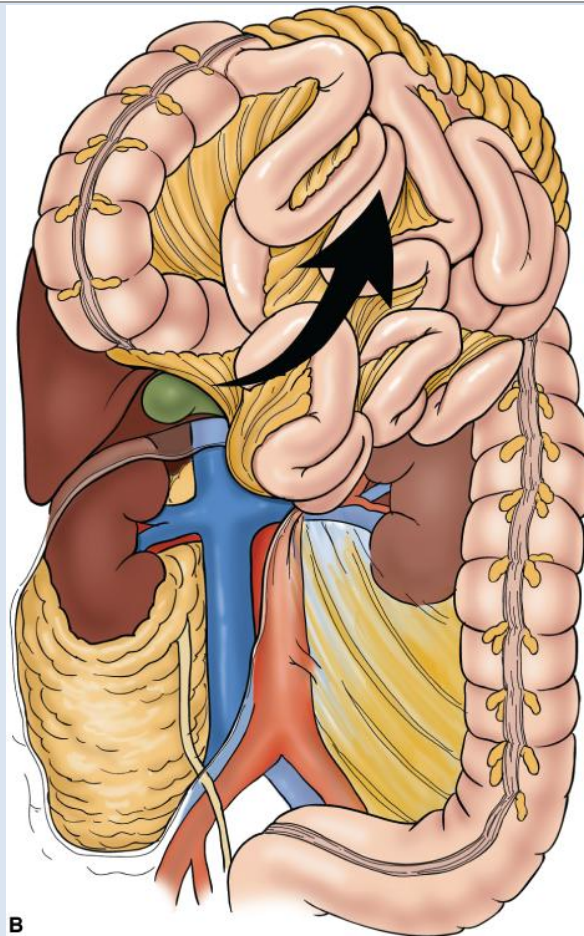
☞ Right colon mobilization

- o Continue the dissection used to liberate the lateral duodenum inferiorly toward the white line of Toldt to free the right colon
- o As discussed below (“COLON MOBILIZATION AND RESECTION”), be wary of injuring the right ureter as you rapidly mobilize the colon and remain in the plane anterior to the kidney and adrenal gland
- o Be sure not to avulse the right colic vein off the superior mesenteric vein (SMV) with over-exuberant retraction once the right colon has been liberated from its secondarily retroperitoneal fixation

☞ Mobilization of the small bowel mesentery

- o Flip up the cecum and small bowel to the right and cranially
- o Incise the attachments of the small bowel mesentery to the posterior peritoneum, traveling from the medial aspect of the cecum to the ligament of Treitz

☞ The large and small bowel can now be eviscerated, exposing the right retroperitoneum (zones I and II)



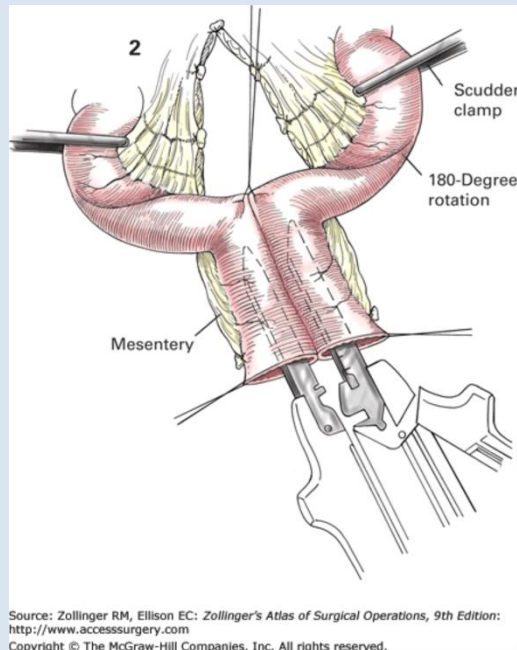
B

Source: Mattox KL, Moore EE, Feliciano DV: *Trauma, 7th Edition*:
www.accesspharmacy.com
Copyright © The McGraw-Hill Companies, Inc. All rights reserved.

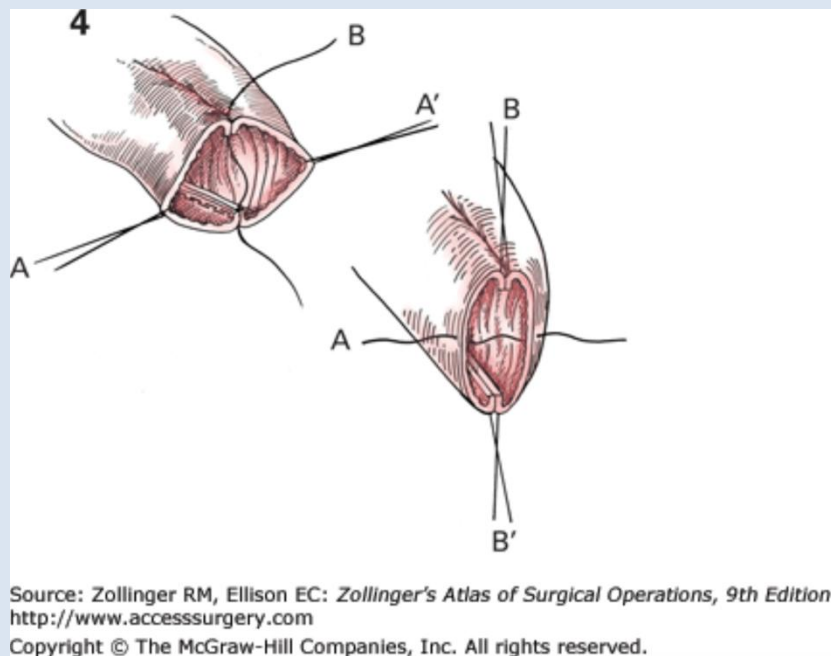
SMALL BOWEL RESECTION

- ☞ *Midline incision*
- ☞ *Determine points for division of the small bowel to achieve adequate proximal and distal margins (e.g. 5-10cm for ischemia or 10cm for small bowel adenocarcinoma.)*
- ☞ *Immediately adjacent to the mesenteric wall of the small bowel at the identified sites of division, use a Schnidt or Kelly clamp to create a window in an avascular region of the mesentery.*
- ☞ *Pass the bottom jaw of the GIA stapler through the mesenteric window and divide the small bowel segment proximally*
- ☞ *Achieve hemostasis of the staple line with Bovie electrocautery or figure-of-8 suture if necessary*
- ☞ *Divide the mesentery with the advanced energy device or with sequential clamp-and-tie technique (wide mesenteric resection to the root of the mesentery is required for small bowel adenocarcinoma)*
- ☞ *Divide the small bowel at the distal margin and mark the specimen's directionality*
- ☞ *Stapled side-to-side functional end-to-end anastomosis:*
 - o *Align small bowel staple lines*

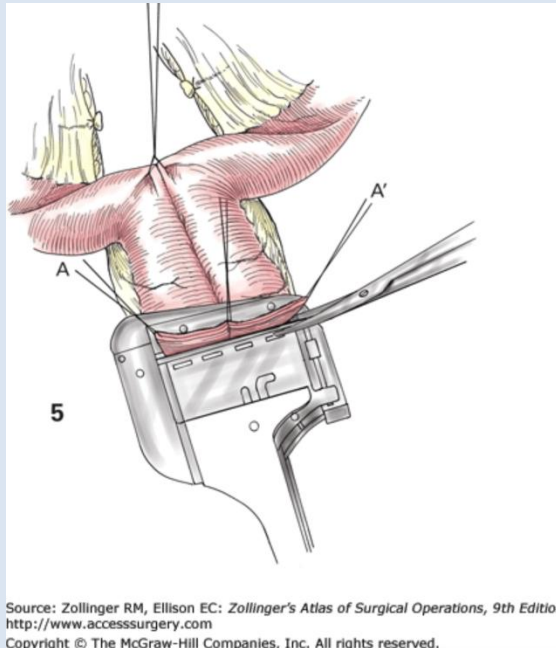
- o Create enterotomy on each loop of small bowel by removing apposing ends of staple lines
- o Insert 1 limb of GIA stapler in each loop of small bowel and fire to create common channel



- o Use Allis clamps or silk sutures to align lumen of common enterotomy



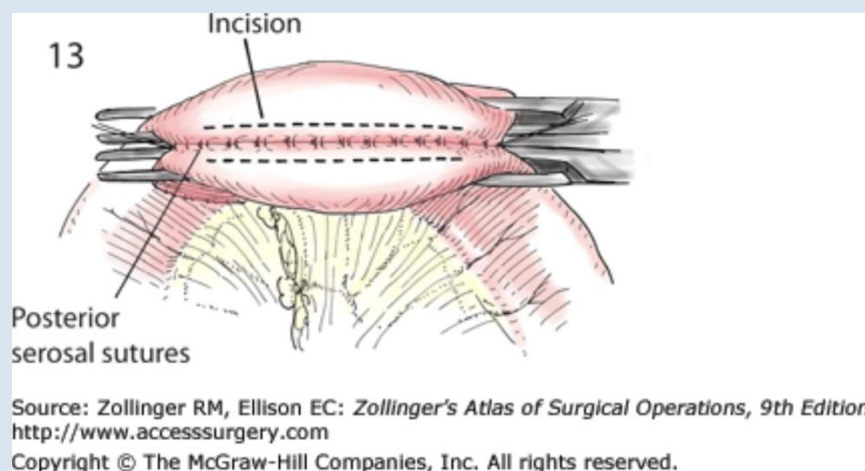
- o Close common enterotomy using additional GIA or TA stapler



- o Place 3-0 silk/Vicryl seromuscular “crotch” stitch to take tension off common channel staple line

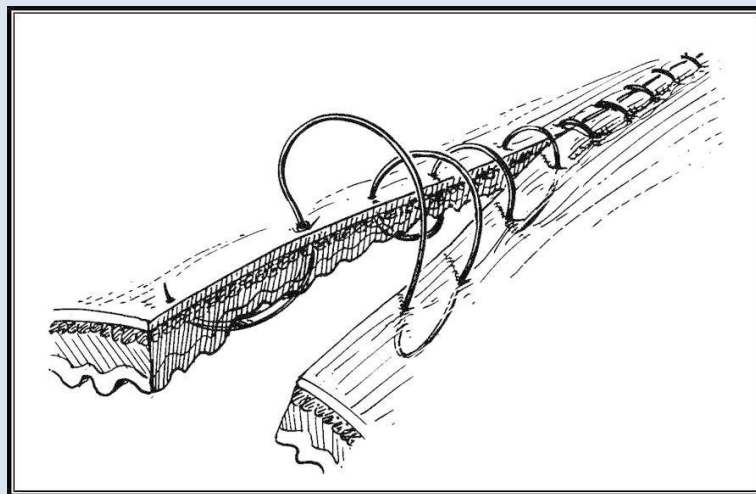
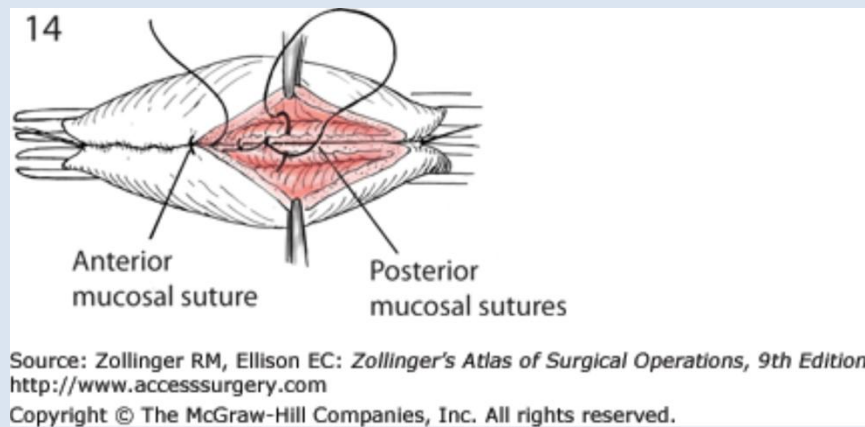
☞ Double layer hand-sewn anastomosis:

- o Align small bowel staple lines
- o Place a row of posterior (outer layer) 3-0 silk seromuscular (Lembert) sutures leaving sufficient room for subsequent layers of suture line
- o Use Bovie electrocautery to create parallel enterotomies



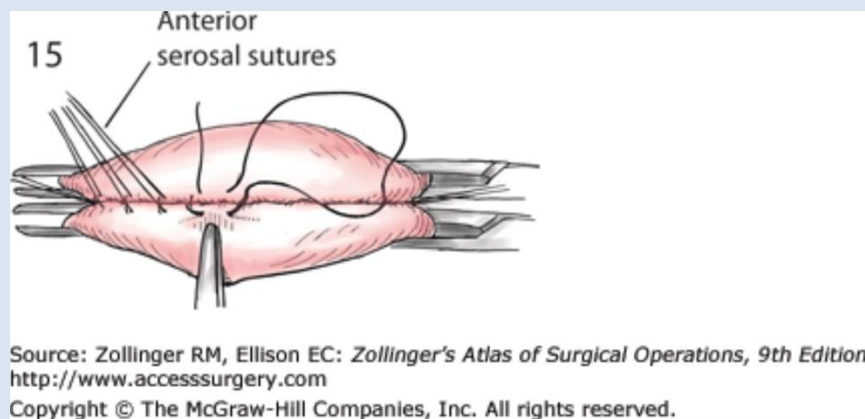
- o Use 3-0 Vicryl suture to create running, full thickness inner layer being sure to (1) include mucosa for mucosal apposition, (2) take adequate bites of the serosa and submucosal strength layer, (3) change needle angle at the corners to properly align bowel, (4) use simple running or Connell

stitches for the anterior inner layer (“in the bar, out the bar, across the street”—see below), and (5) to leave adequate space to place anterior outer layer without narrowing anastomosis

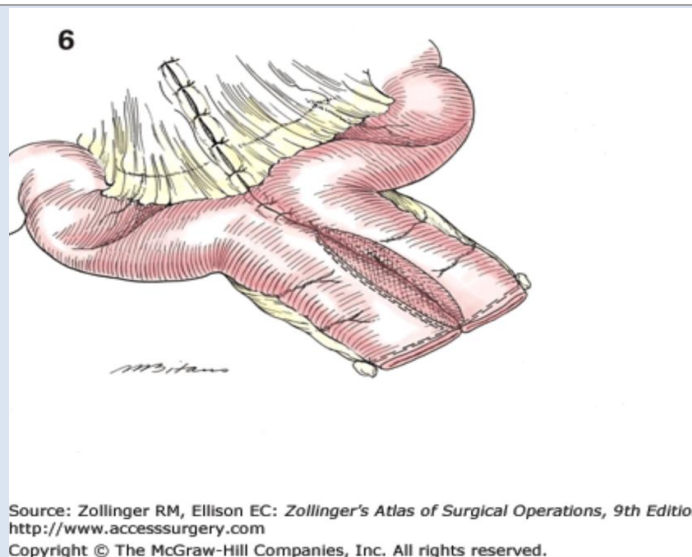


Connell suture pattern

o Place anterior (outer layer) 3-0 silk seromuscular (Lembert) sutures



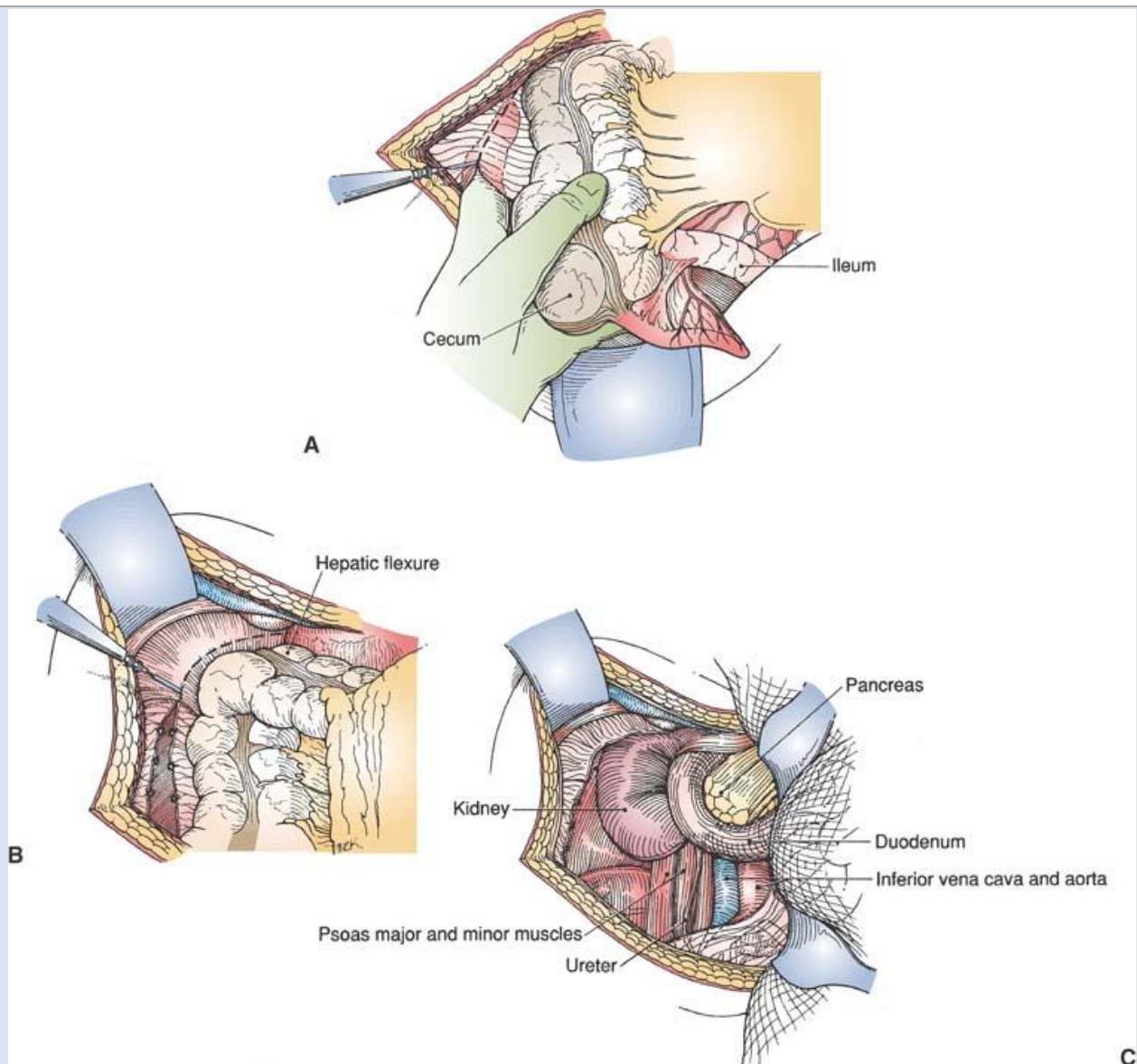
☞ Close mesenteric defect with running 3-0 silk/Vicryl suture



☞ *Realign small bowel to ensure that mesentery is not torsed*

RIGHT COLON AND HEPATIC FLEXURE MOBILIZATION, RIGHT HEMICOLECTOMY

- ☞ *Midline or paramedian incision*
- ☞ *After placement of a self-retaining retractor and thorough inspection of the peritoneal cavity, pack the small bowel in the left abdomen*
- ☞ *With medial traction on the cecum, lift and incise the lateral peritoneal reflection (White line of Toldt) with the electrocautery (NOTE: mobilization will be affected if visceral rotations were performed previously)*
- ☞ *Insinuate index and middle finger into the defect thus created and place tension on White line to allow further division with electrocautery*
- ☞ *Continue superiorly in this fashion, being sure to avoid (1) injury to the right ureter, (2) not to stray into the retroperitoneum under Gerota's fascia, and (3) injury to the duodenum, until the dense attachments of the hepatic flexure are reached*
- ☞ *Cautiously reduce the duodenum back into the retroperitoneum if it is adherent to the transverse colon/mesocolon and is elevated during dissection*
- ☞ *Divide the hepatic flexure with an advanced energy device or electrocautery with application of clamp-and-tie technique for larger vessels*



Scott-Connor CEH and Dawson DL. *Essential Operative Techniques and Anatomy*. Lippincott, Williams & Wilkins, Philadelphia. 2014.

- ☞ *Division of the terminal ileum: Create a window in the avascular portion of the mesentery 10cm proximal to ileocecal valve and divide with GIA in a fashion similar to small bowel resection (see "SMALL BOWEL RESECTION" above)*
- ☞ *Proximal vascular ligation*
 - o *Divide the mesentery at the site of ileal division down to the root of the ileocolic vessels (if performing an oncologic resection) with an advanced energy device or sequential clamp-and-tie technique*
 - o *Doubly ligate and divide the ileocolic vessels*
- ☞ *Distal vascular ligation*

- o Create a window in the avascular portion of the mesentery distal to the right-most branch of the middle colic artery*
 - o Divide the mesentery down to the takeoff of these right-most middle colic vessels off the main middle colic trunks (if performing an oncologic resection) with an advanced energy device or sequential clamp-and-tie technique*
 - o Doubly ligate and divide the right colic vessels at their roots*
 - o Complete the mesenteric division to connect the sites of division of the proximal and distal vascular pedicles*
- ☞ *Divide the transverse colon distal to the right-most branch of the middle colic vessels*

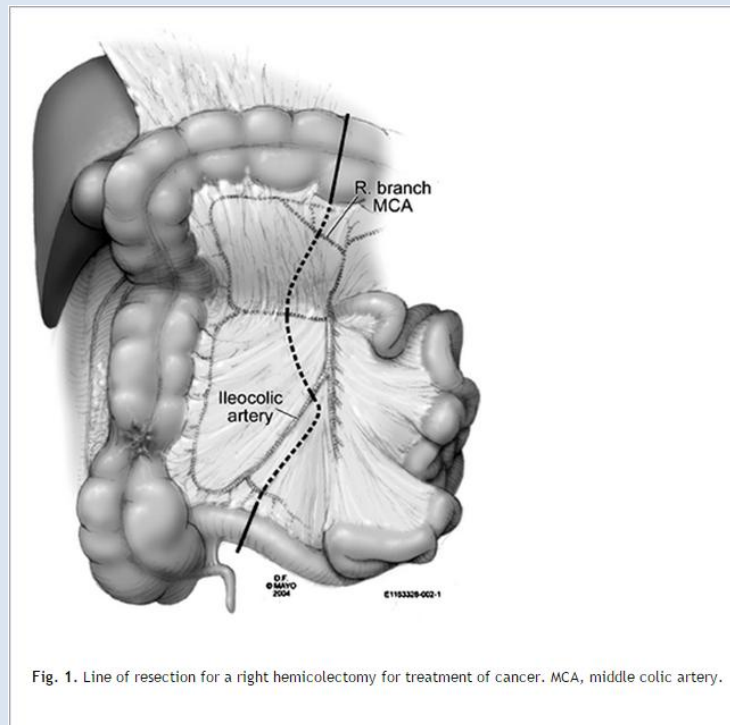
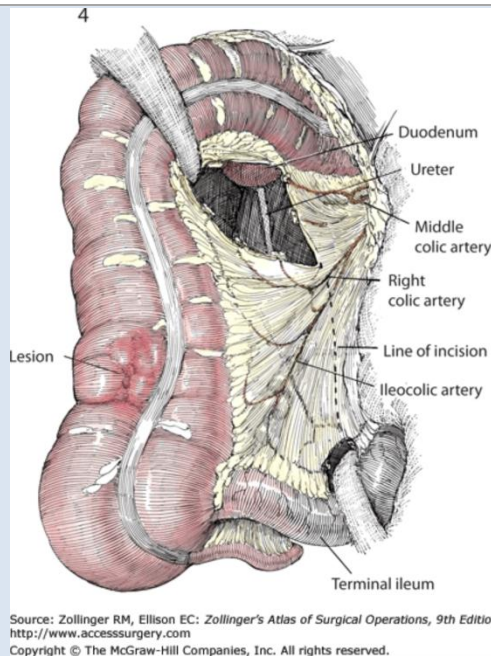


Fig. 1. Line of resection for a right hemicolectomy for treatment of cancer. MCA, middle colic artery.

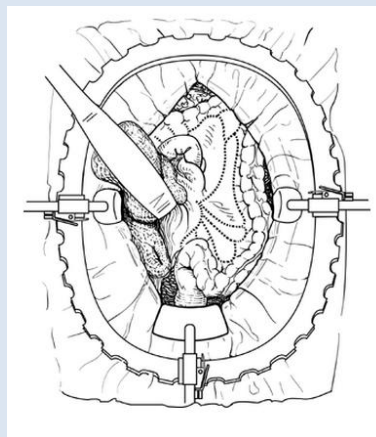
Source: Fischer et al: Mastery of Surgery, 6th Ed. 2007.



- ☞ Perform hand-sewn or stapled ileocolic anastomosis
- ☞ +/- Ileostomy creation

LEFT COLON AND SPLENIC FLEXURE MOBILIZATION, LEFT HEMICOLECTOMY

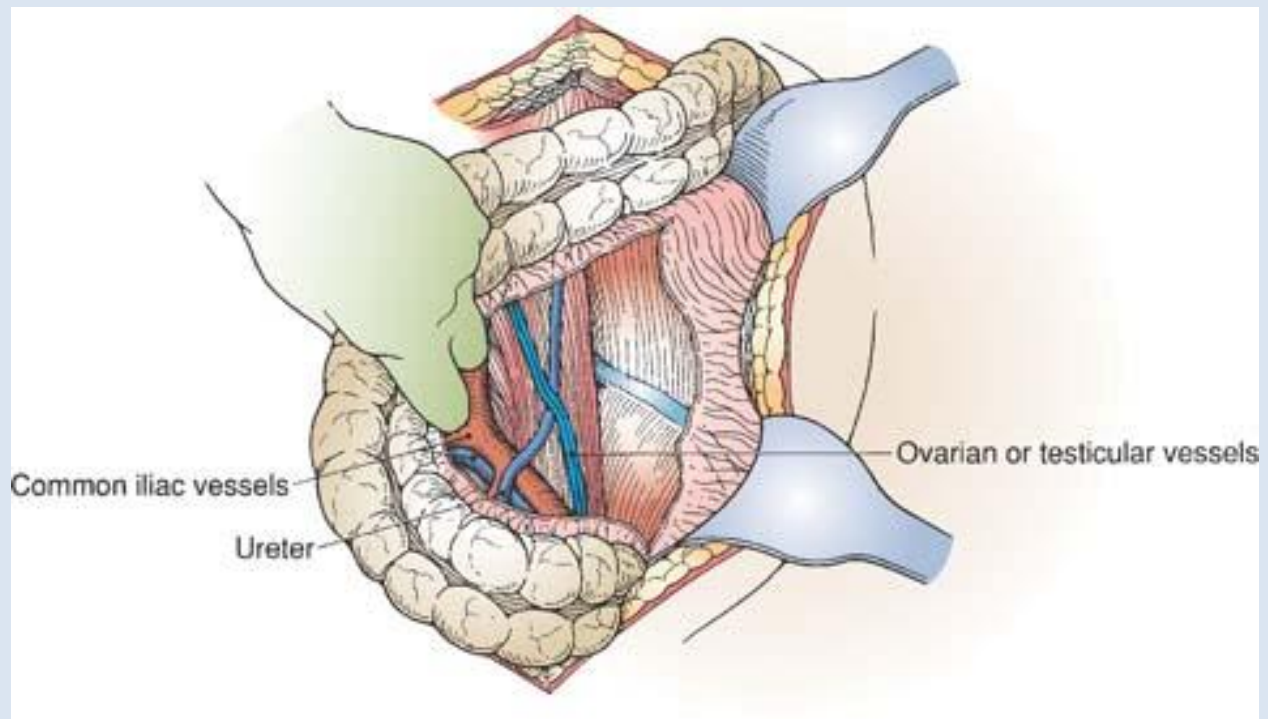
- ☞ Patients may be placed in modified lithotomy depending on the distal extent of planned resection
- ☞ Midline incision
- ☞ After placement of a self-retaining retractor and thorough inspection of the peritoneal cavity, pack the small bowel in the right abdomen

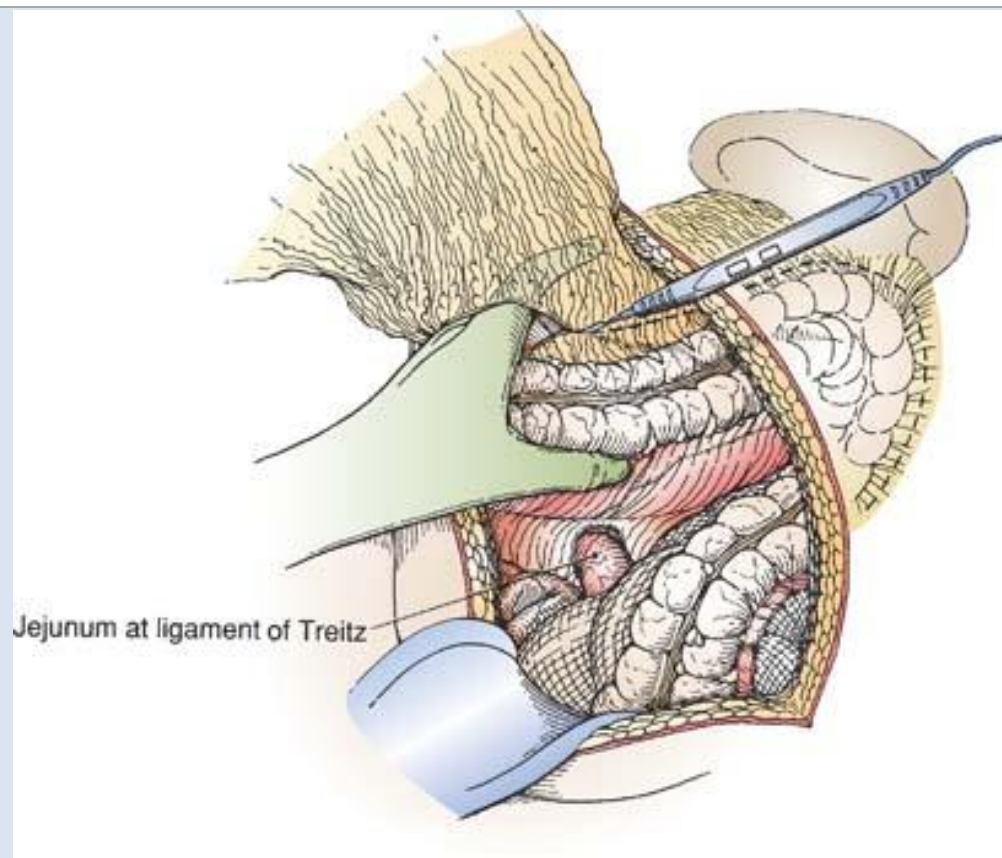


Source: Fischer et al: *Mastery of Surgery, 6th Ed. 2007.*

- ☞ With medial traction on the sigmoid/left colon, lift and incise the lateral peritoneal reflection (White line of Toldt) with the electrocautery (NOTE: mobilization will be affected if visceral rotations were performed previously)

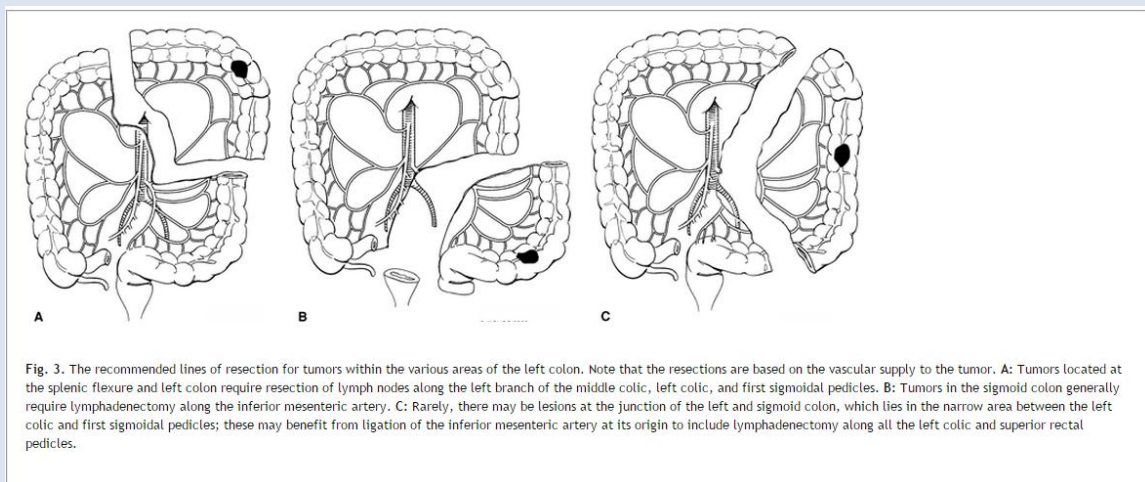
- ☞ *Insinuate index and middle finger into the defect thus created and place tension on White line to allow further division with electrocautery*
- ☞ *Continue superiorly in this fashion, being sure to avoid (1) injury to the left ureter and gonadal vessels (the left gonadal vein drains into the left renal vein rather than directly into the IVC), (2) not to stray into the retroperitoneum under Gerota's fascia, and (3) placement of excessive tension on the splenic flexure which may result in a tear in the splenic capsule and parenchyma, until the dense attachments of the splenic flexure are reached*
- ☞ *Incise the greater omentum with electrocautery just medial to the splenic flexure and approach the flexure from the medial to lateral direction, switching to advanced energy device or using the clamp-and-tie technique as the vessels with the splenic flexure are encountered*





Scott-Connor CEH and Dawson DL. *Essential Operative Techniques and Anatomy*. Lippincott, Williams & Wilkins, Philadelphia. 2014.

- ☞ Determine the extent of resection based on tumor location to ensure adequate lymphadenectomy and 5cm proximal and distal bowel margins (for oncologic resections)



Source: Fischer et al: *Mastery of Surgery*, 6th Ed. 2007.

- ☞ Perform vascular ligations, mesenteric resection, colonic resection, and hand-sewn or stapled anastomosis as discussed above for right hemicolectomy

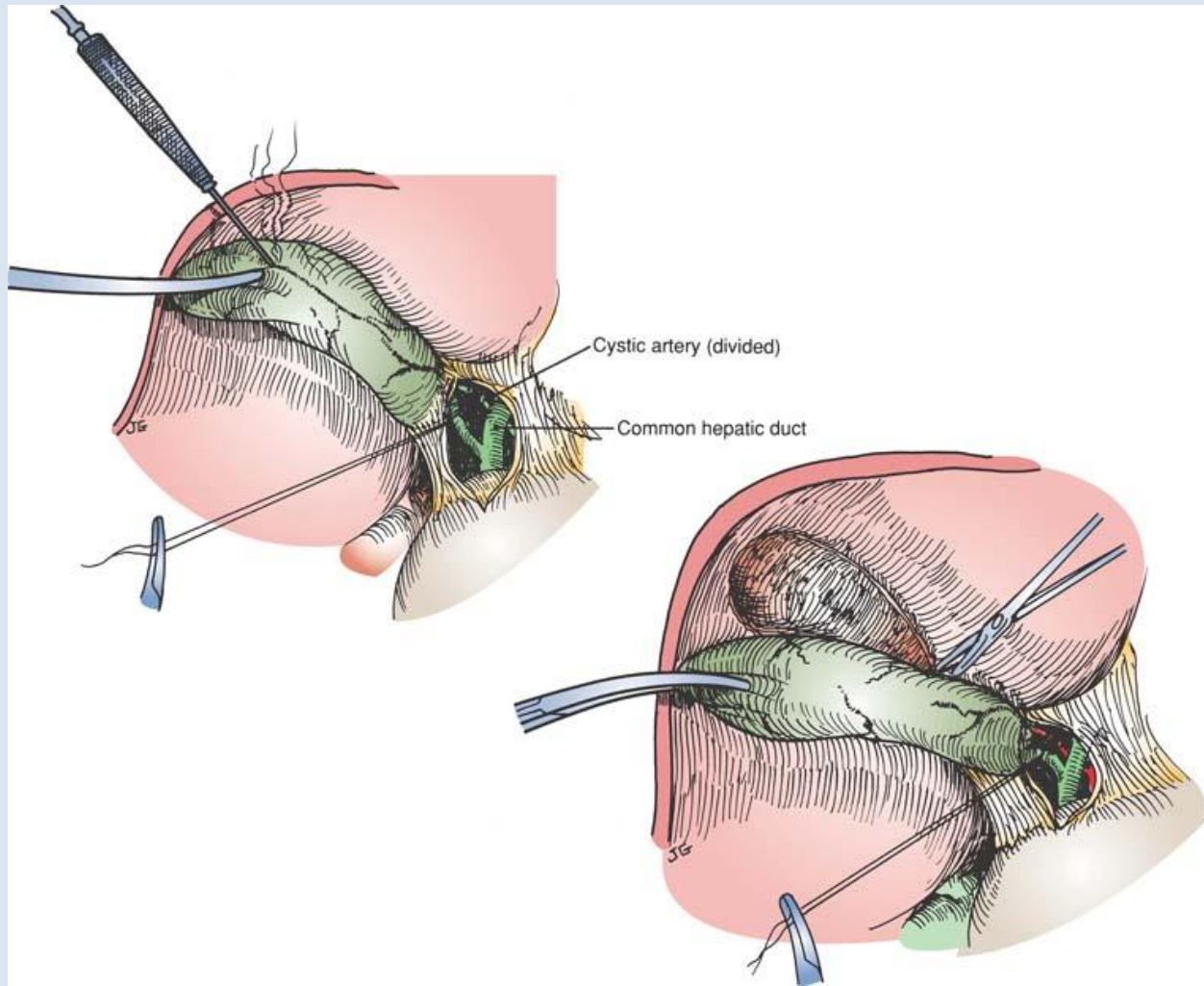
☞ Right hemicolectomy: <http://www.surgicalcore.org/videoplayer/510000160/9>

[HEPATOBIILIARY DIDACTICS -- PENDING

OPEN CHOLECYSTECTOMY

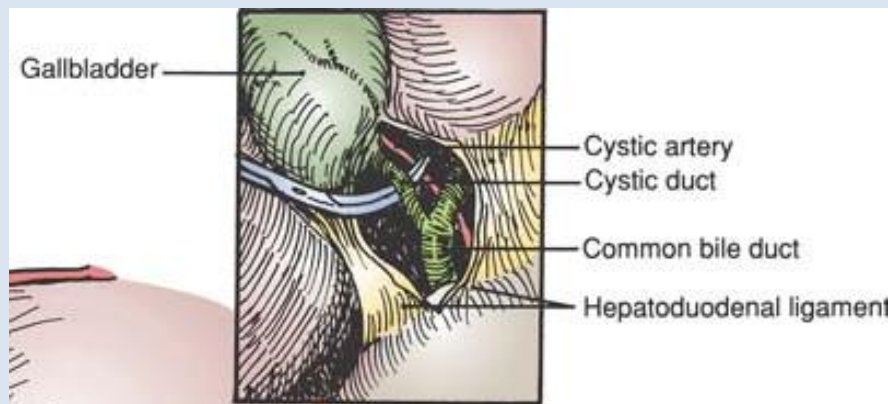
Procedure

- ☞ Right subcostal (Kocher) or upper midline incision
- ☞ Ensure that the anesthesiologist has placed a nasogastric or orogastric tube and that it is on suction to decompress the stomach so that it remains out of the operative field
- ☞ Place a self-retaining retractor and pack the small bowel out of the right upper quadrant
- ☞ Bluntly or sharply separate omental adhesions to the gallbladder depending on thickness and adherence
- ☞ Incise the peritoneum overlying the gallbladder fundus with electrocautery
- ☞ Liberate the gallbladder from the liver bed with gentle traction and cautery in a retrograde fashion ("top down"—fundus to infundibulum)



Scott-Connor CEH and Dawson DL. Essential Operative Techniques and Anatomy. Lippincott, Williams & Wilkins, Philadelphia. 2014

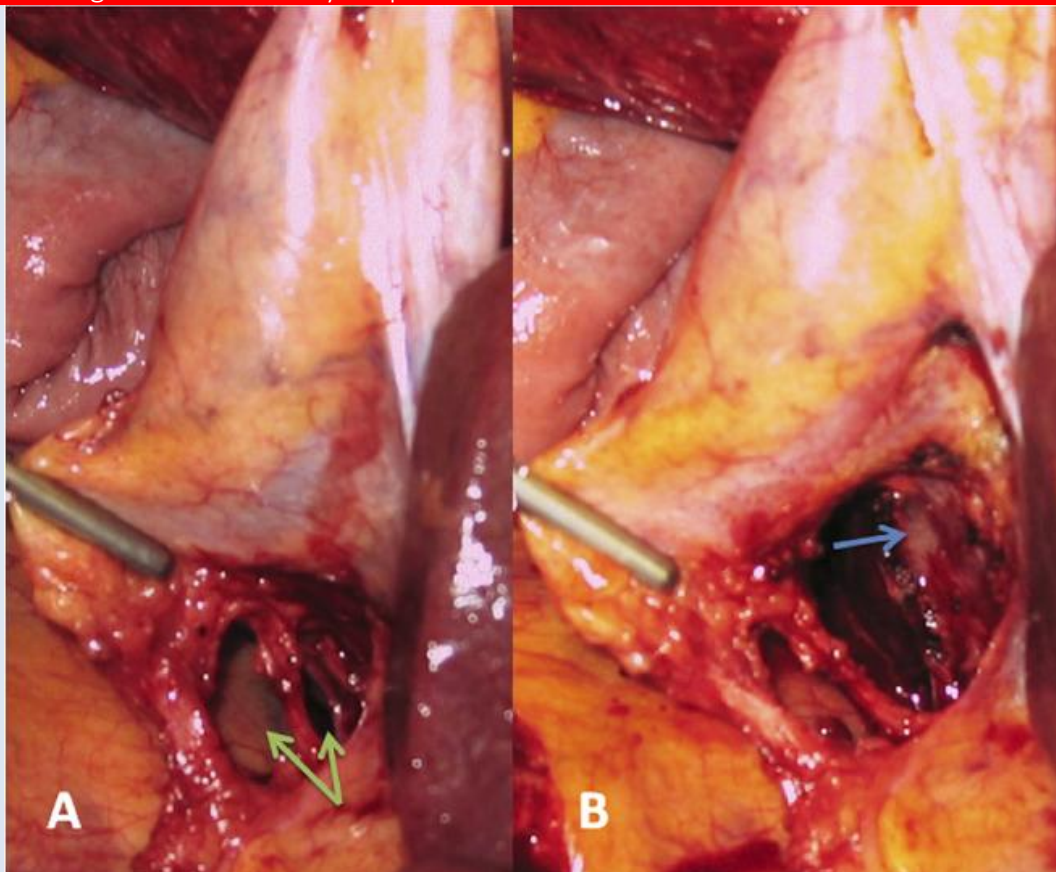
☞ Dissect out the cystic duct and artery, being sure to exclude right hepatic or common structures



Scott-Connor CEH and Dawson DL. Essential Operative Techniques and Anatomy. Lippincott, Williams & Wilkins, Philadelphia. 2014

CRITICAL VIEW OF SAFETY

1. Dissection of triangle of Calot
2. Duct and artery seen entering gallbladder
3. Separation of gallbladder from cystic plate

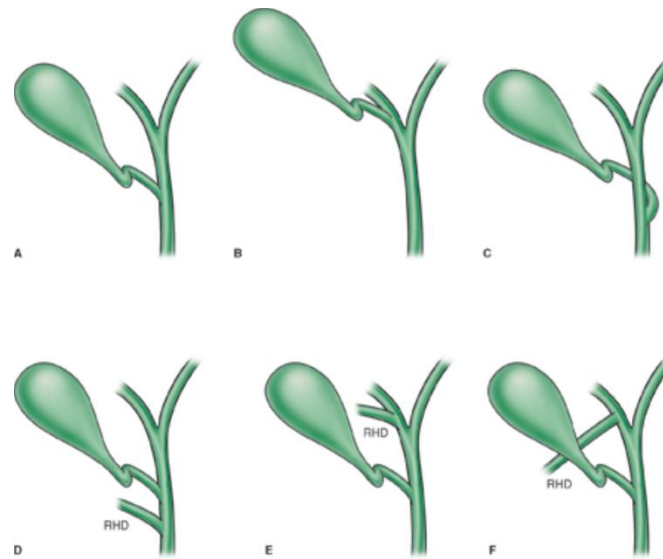


Strasberg et al. JACS 2010;211(1):132-8.

☞ Divide the artery and duct in succession by encircling with silk or Vicryl ties

☞ Oversew the cystic duct stump with a suture ligature

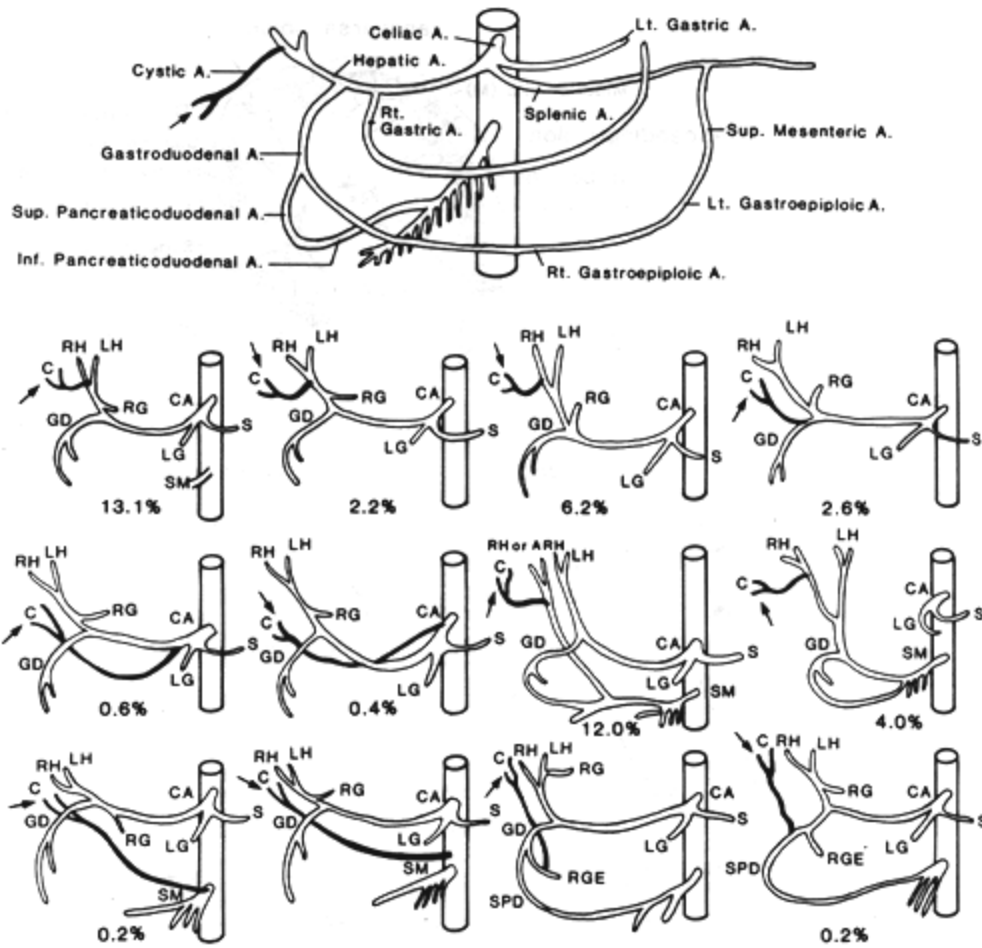
In addition to the standard anatomy depicted above, general surgical residents must be familiar with the following variations in biliary tree and vascular anatomy.



Source: Zinner MJ, Ashley SW: *Maingot's Abdominal Operations*, 12th Edition: www.accesssurgery.com

Copyright © The McGraw-Hill Companies, Inc. All rights reserved.

Biliary anatomy variations. A. Normal anatomy. B. Cystic duct insertion on right hepatic duct. C. Anterior or posterior spiral insertion of cystic duct. D. E. and F.



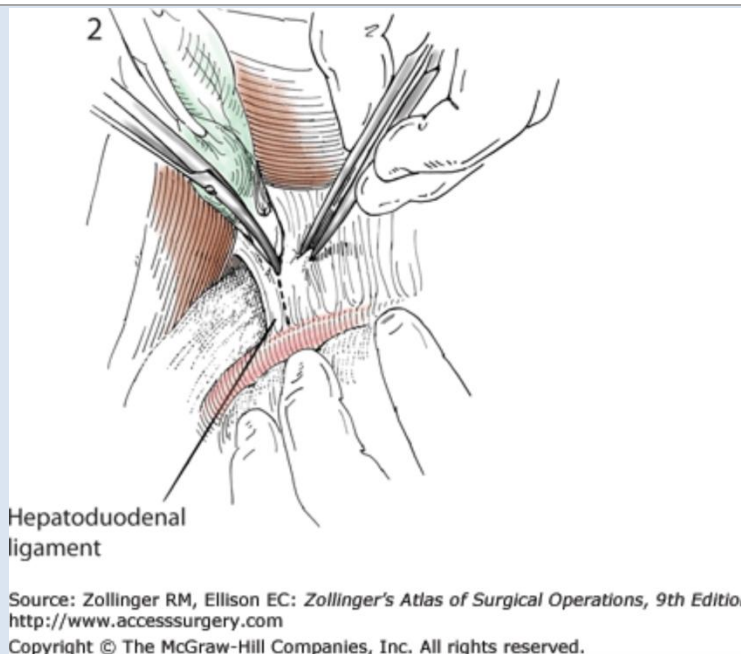
Redrawn from Daseler, E.H., Anson, B.J., Hambley, WC. and A.F. Reimann. The cystic artery and constituents of the hepatic pedicle. A study of 500 specimens. Surg. Gynecol. Obstet 85:47-63, 1947

Advanced endoscopic and interventional radiologic techniques have largely supplanted surgical common bile duct exploration. However in cases where these resources are not available or fail to achieve their end, as well as for the purposes of the American Board of Surgery Certifying Examination, general surgery residents should be familiar with the procedure.

OPEN COMMON BILE DUCT EXPLORATION (CBDE)

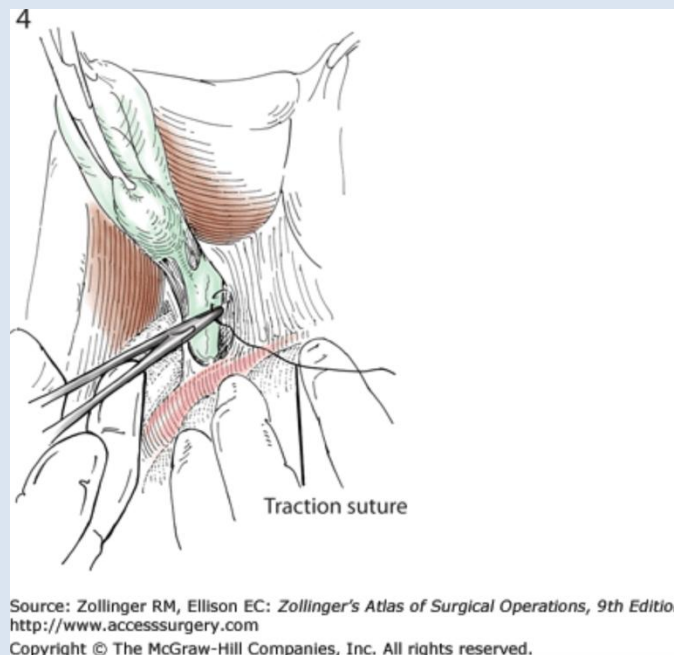
Procedure

- ☞ *Right subcostal (Kocher) or upper midline incision*
- ☞ *Exposure as performed for open cholecystectomy (see above)*
- ☞ *The hepatoduodenal ligament is incised and the cystic duct traced back to the common bile duct*



☞ Fine 4-0 silk traction sutures are placed a few millimeters from one another in the anterior wall of the common bile duct immediately inferior to the cystic duct-common hepatic duct junction, being sure not to injure the main blood supply along the lateral walls (3 o'clock and 9 o'clock)

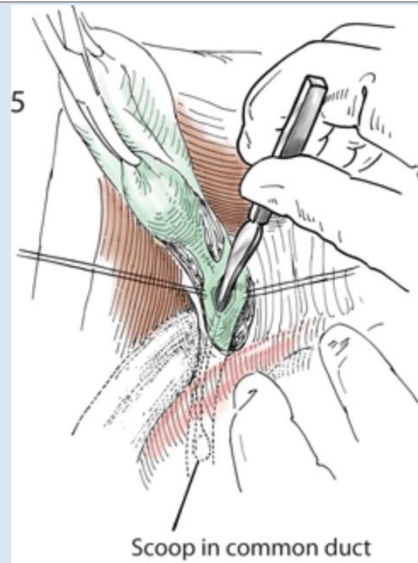
o Alternatively, if the cystic duct is sufficiently dilated to permit a choledochoscope, traction sutures may be placed here and the common duct explored via a cystic ductotomy



☞ A 1cm vertical choledochotomy is made between the stay sutures

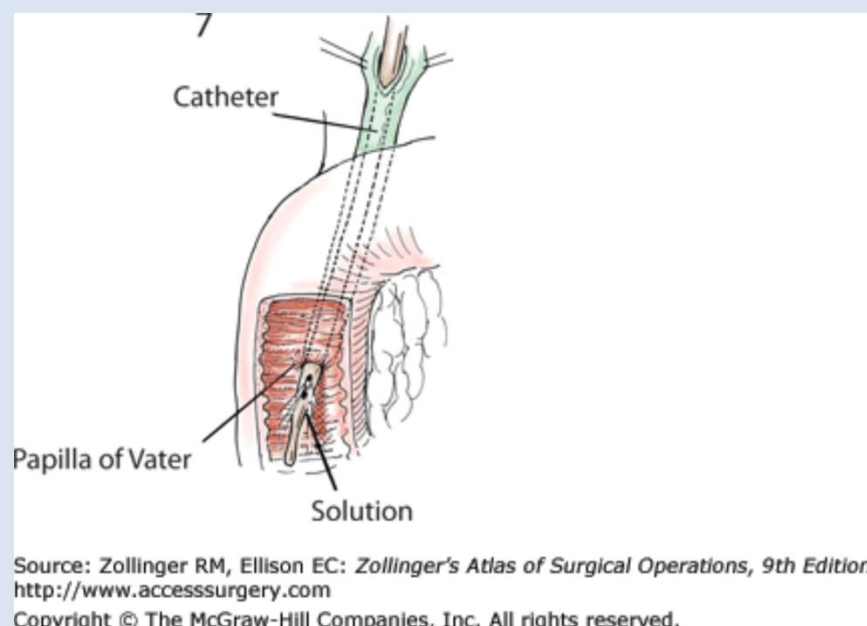
☞ Cholangiography is performed

☞ The common duct is interrogated with choledochoscope and dilators, scoops, or Fogarty balloon catheter are used to retrieve choledocholiths

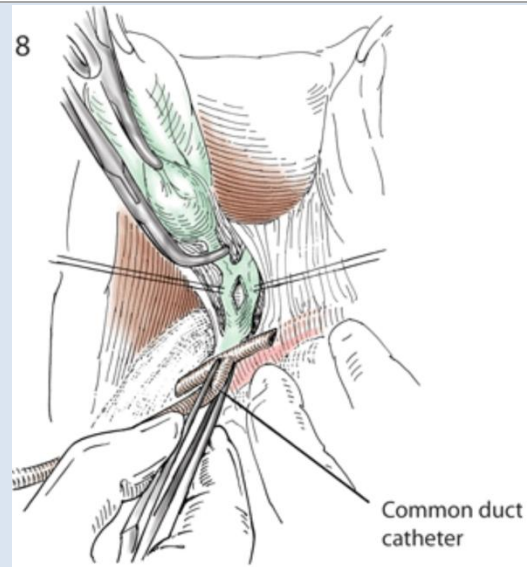


Source: Zollinger RM, Ellison EC: *Zollinger's Atlas of Surgical Operations, 9th Edition*:
<http://www.accesssurgery.com>
 Copyright © The McGraw-Hill Companies, Inc. All rights reserved.

- ☞ Irrigate with saline both proximally and distally with 12-14 Fr catheter which should be passed gently through the papilla of Vater to ensure patency



- ☞ A 14-16Fr T-tube is prepared by shortening the arms and removing a wedge opposite the main stem to ensure greater flexibility at that location at the time of removal
- ☞ A 4-0 PDS pursestring suture is placed around the choledochotomy for closure
- ☞ The tube is placed through the choledochotomy, the pursestring tied down, and traction silk sutures removed



Source: Zollinger RM, Ellison EC: *Zollinger's Atlas of Surgical Operations, 9th Edition*:
<http://www.accesssurgery.com>
 Copyright © The McGraw-Hill Companies, Inc. All rights reserved.

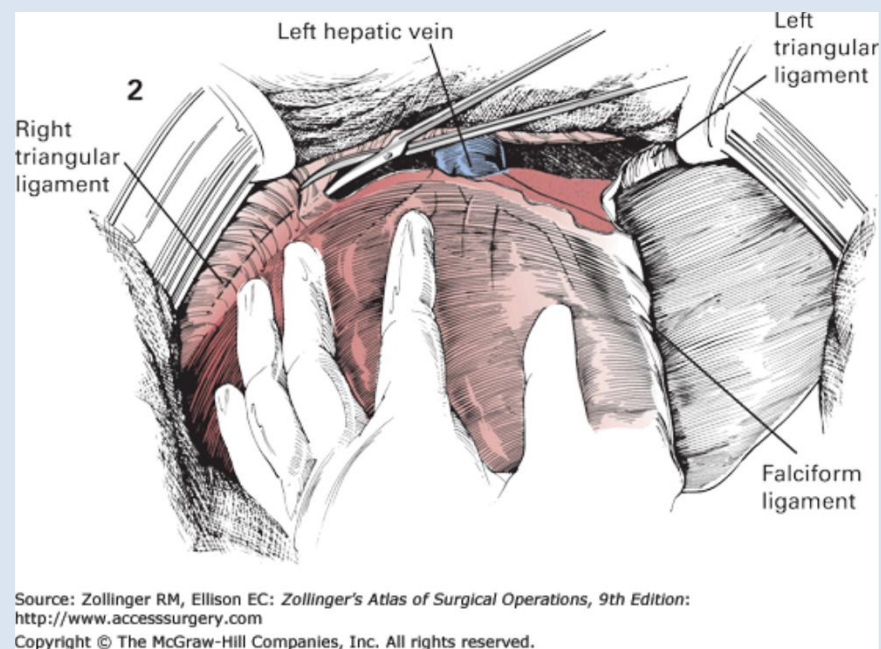
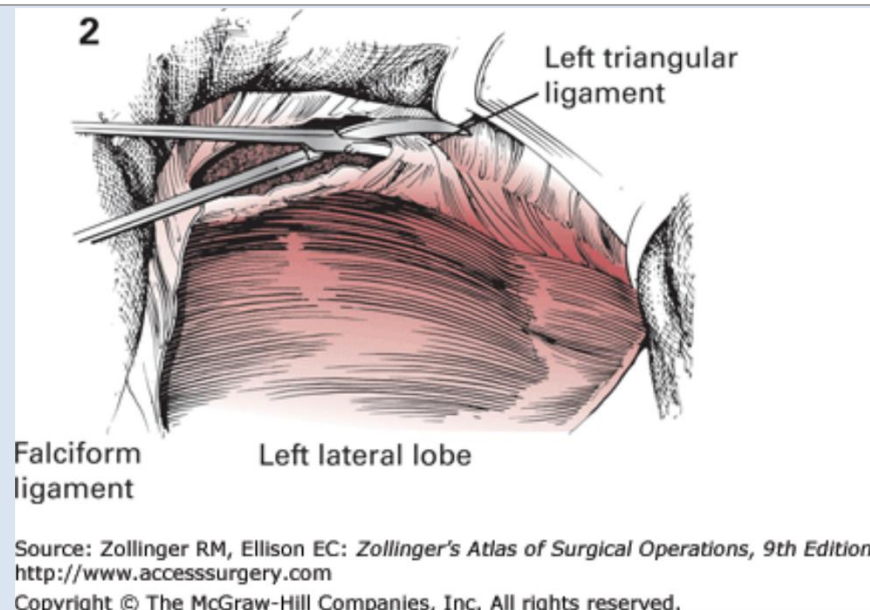
- ☞ Saline is injected through the T-tube to test the closure and cholangiography performed
- ☞ The gallbladder is removed if not already done
- ☞ A closed suction drain is left in place

📺 Laparoscopic common bile duct exploration:

<http://www.surgicalcore.org/videoplayer/510000116/1>

MOBILIZATION OF THE LIVER

- ☞ Place your hand between the diaphragm and liver, and depress the liver. Starting at the **falciform ligament**, use the blunt-tipped scissors or fingers to divide the **left coronary** and **left triangular ligaments**.
- ☞ The right liver can be mobilized by similar division of the **right coronary** and **right triangular ligaments**.

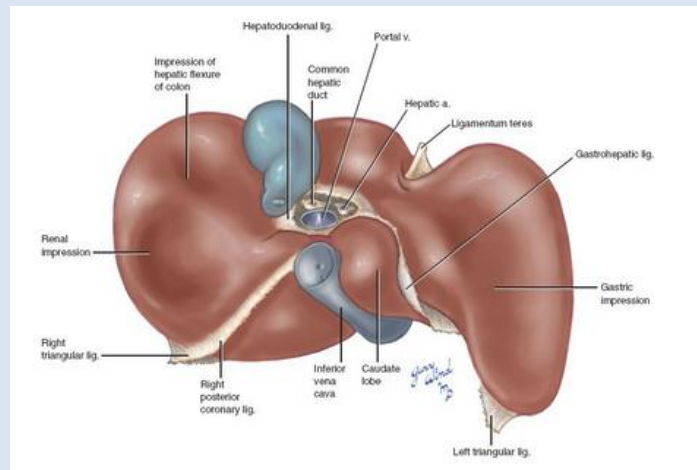


☞ For the purposes of dissection in the cadaver lab: Detach the **inferior vena cava** from the caval foramen of the diaphragm. Draw the liver anteriorly, and identify the openings of the **hepatic veins** within the vena cava. Identify the **bare area** of the liver where no peritoneum intervenes between liver and diaphragm. Preserve the **retrohepatic veins**.

📺 Left liver lobe mobilization: <http://www.surgicalcore.org/videoplayer/510000038/50>

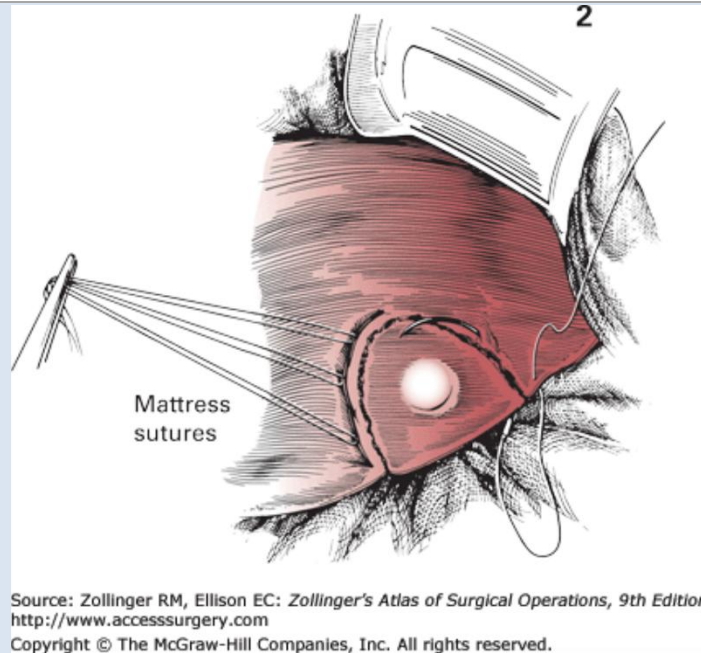
LIVER “WEDGE” RESECTION (PARTIAL HEPATECTOMY, NONANATOMIC)

- ☞ *Extended right subcostal or upper midline incision*
- ☞ *Inspect the peritoneal cavity for evidence of tumor spread*
- ☞ *Divide the falciform ligament between clamps and tie off*
- ☞ *Depending on the location of the target lesion(s), further mobilize the liver by dividing the left triangular ligament (avoiding injury to hepatic veins-IVC junction) and the right triangular and coronary ligaments (avoiding injury to the retrohepatic IVC)*

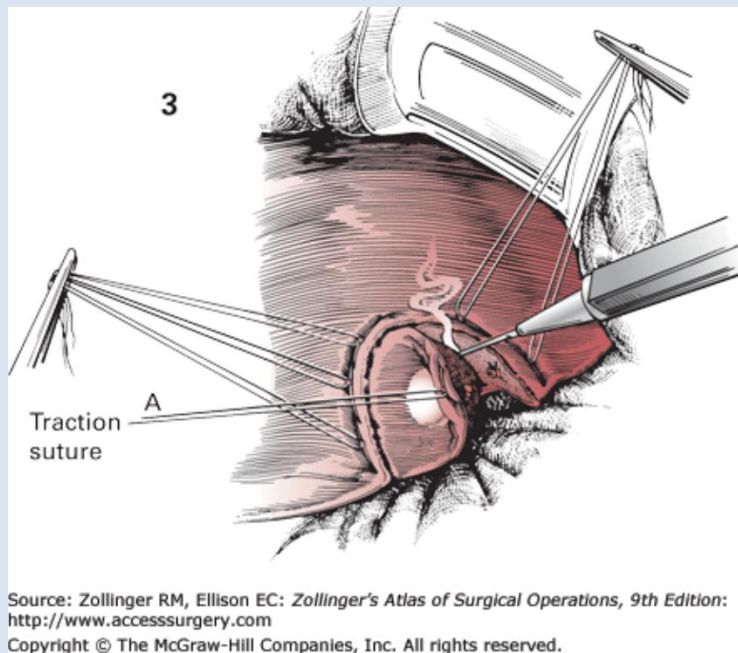


Valentine JR and Wind GG. Anatomic exposures in vascular surgery. Lippincott Williams & Wilkins, 2003.

- ☞ *Use Aloka US to systematically image the segments of the liver in search of lesions not identified on preoperative imaging*
- ☞ *Once a target lesion’s anatomy (size, relations to major intrahepatic biliary and vascular structures) has been determined to be amenable to “wedge” local resection, outline a 1-2cm margin around the tumor with the Bovie electrocautery on very high coag setting*
- ☞ *If a transcollation energy device is available (e.g. Aquamantys®), this can be used in conjunction with Metzenbaum scissors or a 2nd advanced energy device (e.g. Ligasure™ Dolphin Tip) to divide the coagulated hepatic tissue and resect the specimen*
- ☞ *If no such device will be used ...*
 - o *Prior to resection, hemostasis can be achieved by deeply placing a row of catgut (e.g. 1-0 Chromic on a large, blunt BP needle) mattress sutures along the periphery of the marked line of resection and tying these down enough to compress the hepatic parenchyma without lacerating Glisson’s capsule*

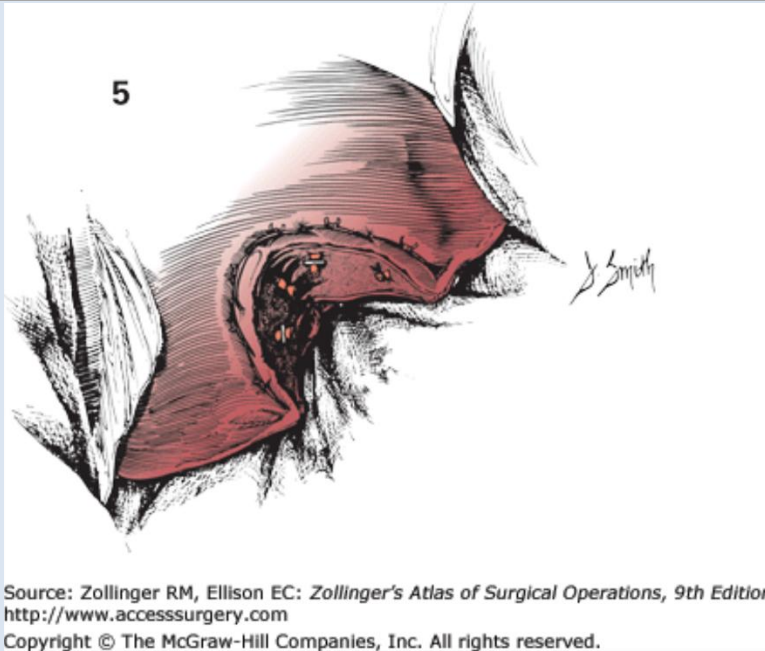


o Electrocautery can be used to divide the hepatic parenchyma



o Visible vessels and bile ducts should be individually ligated

☞ Pack the resection cavity with Surgicel or Thrombin-soaked gelfoam for several minutes prior to closing the abdomen

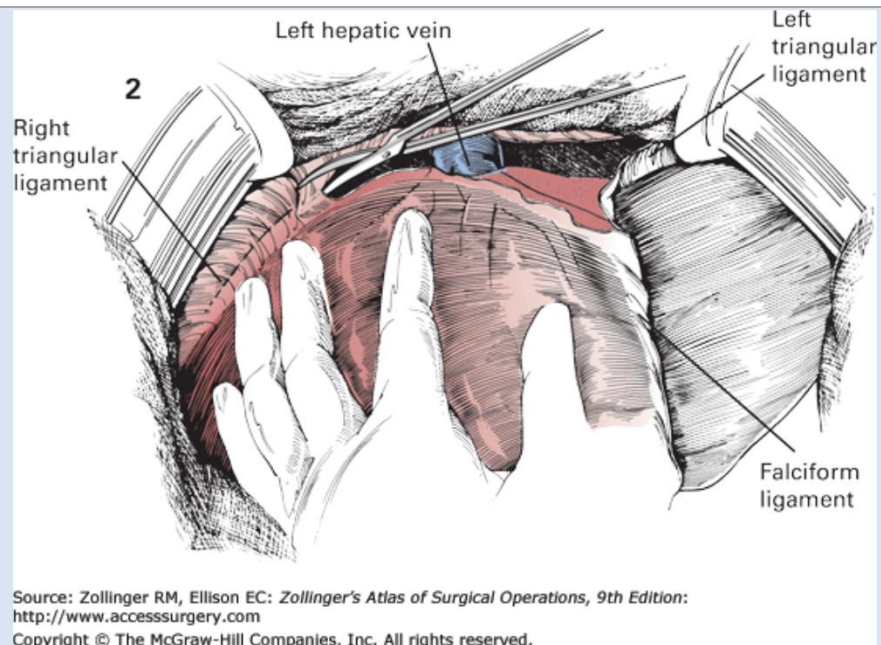


☞ A closed suction drain may be placed depending on size of resection and bile ducts encountered

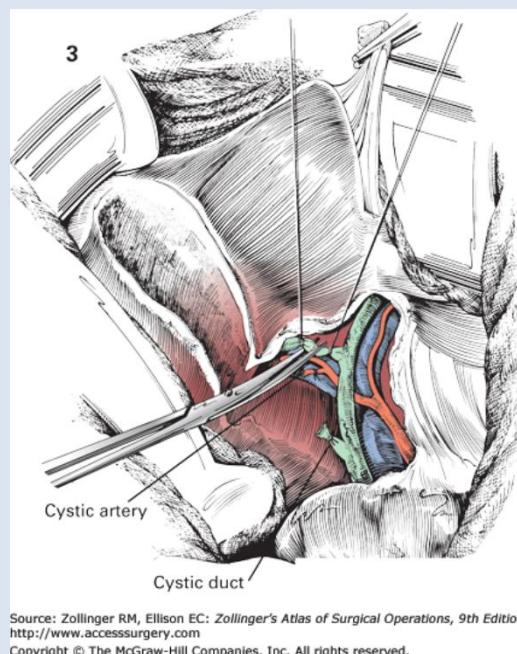
HEPATECTOMY, ANATOMIC

Procedure: Right hepatic lobectomy

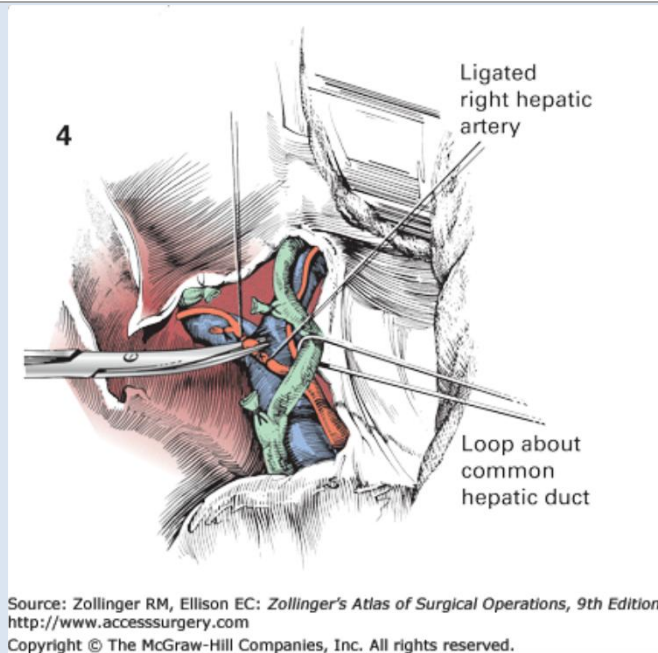
- ☞ Extended right or bilateral subcostal incision, or midline incision
- ☞ Inspect the peritoneal cavity for evidence of tumor spread
- ☞ Divide the falciform ligament between clamps and tie off
- ☞ Divide the right triangular and coronary ligaments (avoiding injury to the retrohepatic IVC or right hepatic veins)



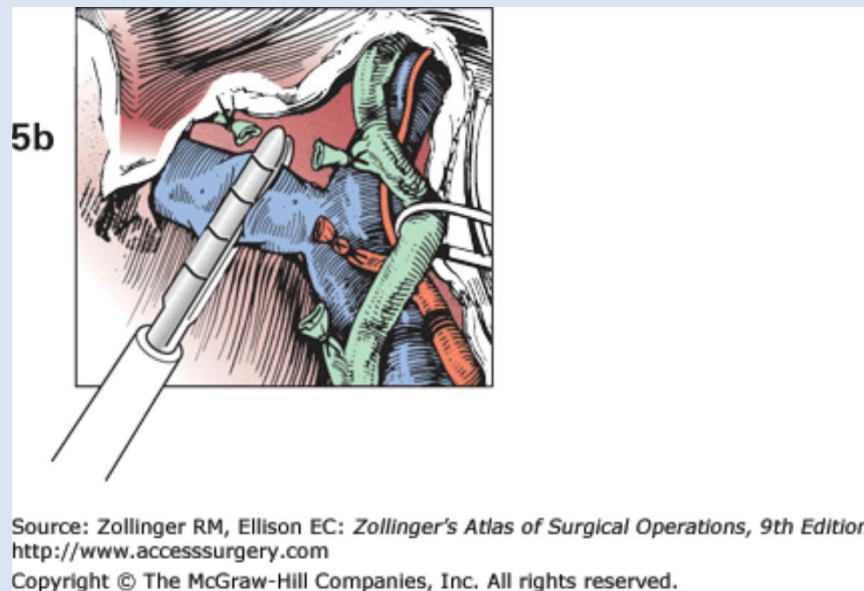
- ☞ Perform an open cholecystectomy (see above)
- ☞ Use Aloka US to systematically image the segments of the liver in search of lesions not identified on preoperative imaging
- ☞ The liver hilum is dissected out to define the right and left bile ducts and arteries
- ☞ The right bile duct is ligated and divided. An additional suture ligature is placed to minimize the risk of bile leak



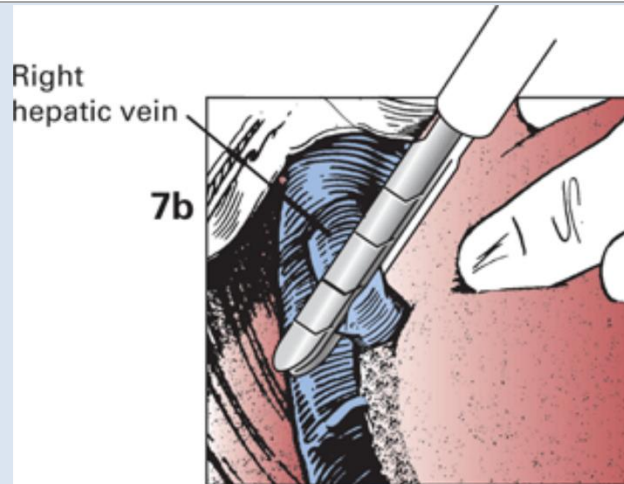
- ☞ The right hepatic artery is ligated and divided



- ☞ The portal vein bifurcation into its main left and right branches is further defined
- ☞ The right portal vein is divided with vascular load GIA stapler or clamped, divided, and each end oversewn with hemostatic running 4-0 Prolene suture (the proximal, "staying" end may be further reinforced with a horizontal mattress suture)

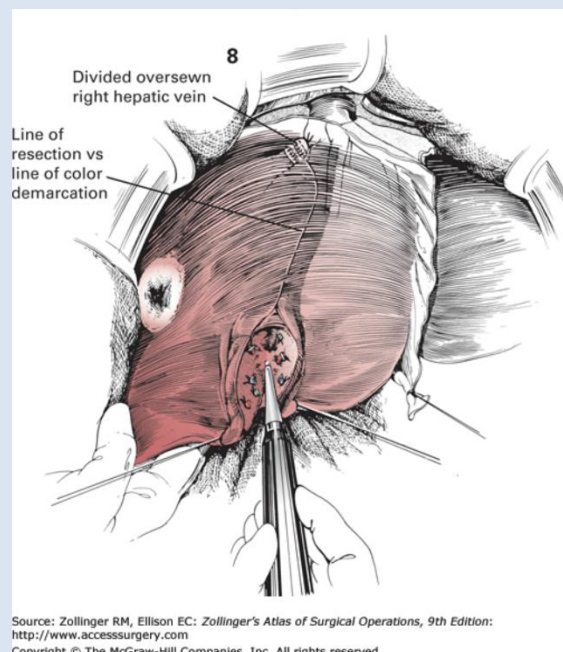


- ☞ The remaining left portal triad is cautiously dissected off of the liver near the planned point of division of the lobes
- ☞ After ensuring that it has been adequately freed from the diaphragm, the right lobe of the liver is rotated medially, small venous branches to the lobe are ligated, and caval ligaments overlying the right hepatic vein are divided to expose the right hepatic vein
- ☞ The right hepatic vein is divided with vascular load GIA or between clamps and oversewn as described for the right portal vein above



Source: Zollinger RM, Ellison EC: *Zollinger's Atlas of Surgical Operations, 9th Edition*:
<http://www.accesssurgery.com>
 Copyright © The McGraw-Hill Companies, Inc. All rights reserved.

- ☞ Ligation of the blood supply leads to demarcation of the right lobe of the liver and indicates the line of division of the two lobes



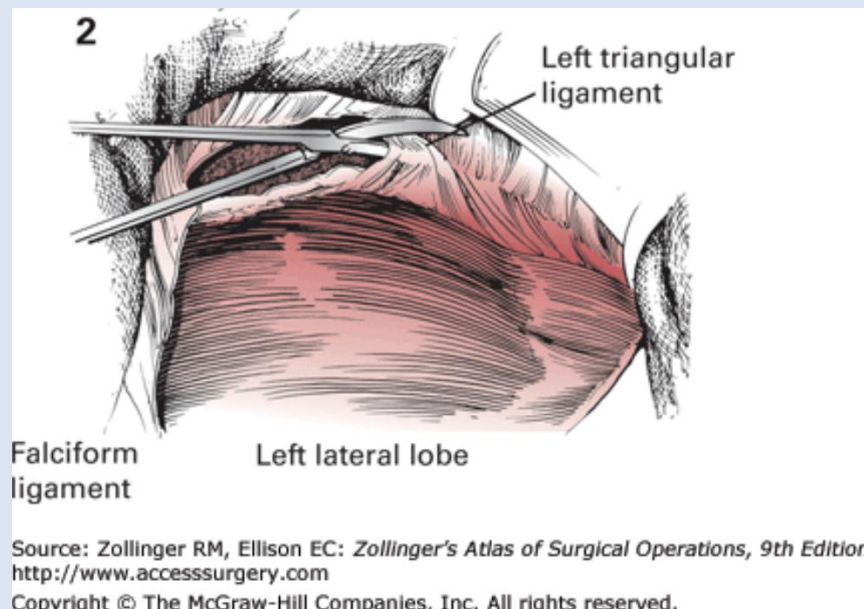
Source: Zollinger RM, Ellison EC: *Zollinger's Atlas of Surgical Operations, 9th Edition*:
<http://www.accesssurgery.com>
 Copyright © The McGraw-Hill Companies, Inc. All rights reserved.

- ☞ If a transcollation energy device is available (e.g. Aquamantys®), this can be used in conjunction with Metzenbaum scissors, a 2nd advanced energy device (e.g. Ligasure™ Dolphin Tip), or a vascular stapler to divide the coagulated hepatic tissue
- ☞ If no such device will be used ...
 - o Prior to resection, hemostasis can be achieved by deeply placing a row of catgut (e.g. 1-0 Chromic on a large, blunt BP needle) mattress sutures parallel and to the left of the resection margin and tying these down enough to compress the hepatic parenchyma without lacerating Glisson's capsule
 - o Division of hepatic parenchyma
 - o Ligation of visible vessels

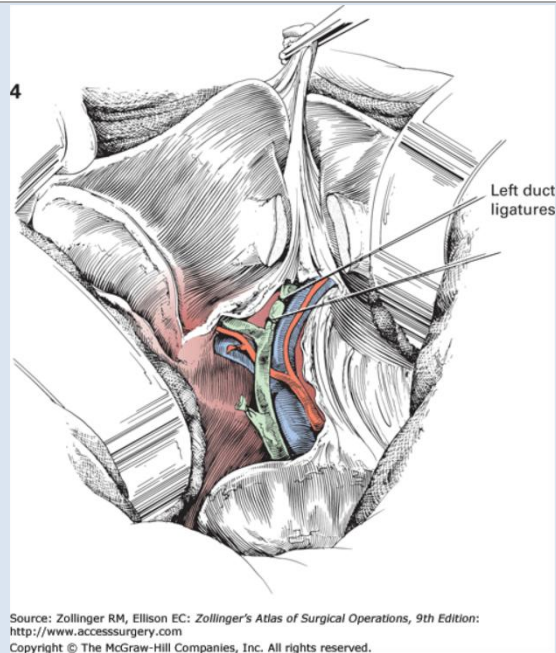
- ☞ *The right lobe is removed*
- ☞ *Bleeding and bile leakage from the raw liver surface are addressed with suture ligature, electrocoagulation, and/or hemostatic materials*
- ☞ *Omentum may be tacked to the liver by laying it along the cut edge and securing it in place by tying Chromic sutures over it (similar to a Graham patch)*
- ☞ *A closed suction drain should be left in place*

Procedure: Left hepatic lobectomy

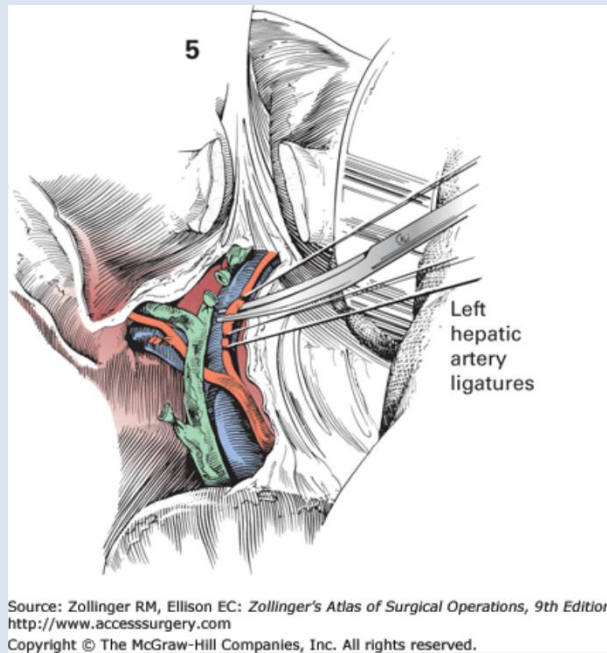
- ☞ *Extended right or bilateral subcostal incision, or midline incision*
- ☞ *Inspect the peritoneal cavity for evidence of tumor spread*
- ☞ *Divide the falciform ligament between clamps and tie off*
- ☞ *Divide the left triangular ligament (avoiding injury to hepatic vein-IVC confluence)*



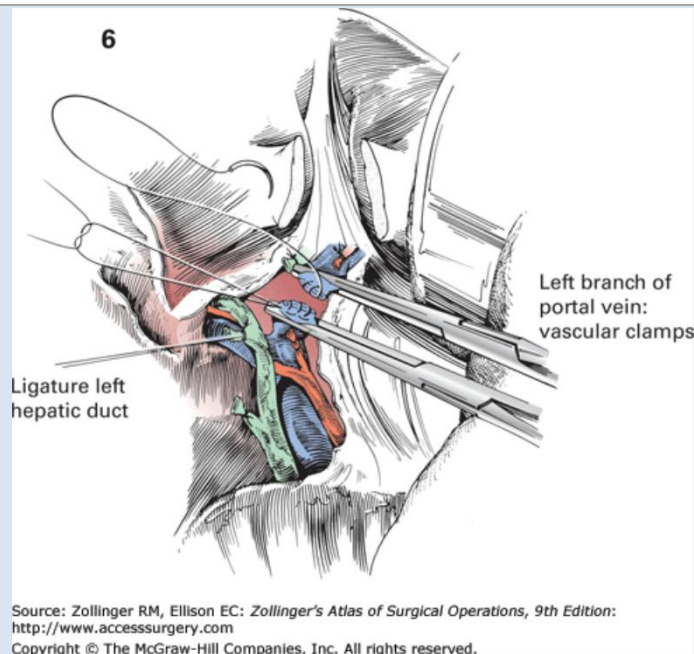
- ☞ *Perform open cholecystectomy (see above)*
- ☞ *Use Aloka US to systematically image the segments of the liver in search of lesions not identified on preoperative imaging*
- ☞ *The liver hilum is dissected out to define the right and left bile ducts and arteries*
- ☞ *The left bile duct is ligated and divided. An additional suture ligature is placed to minimize the risk of bile leak*



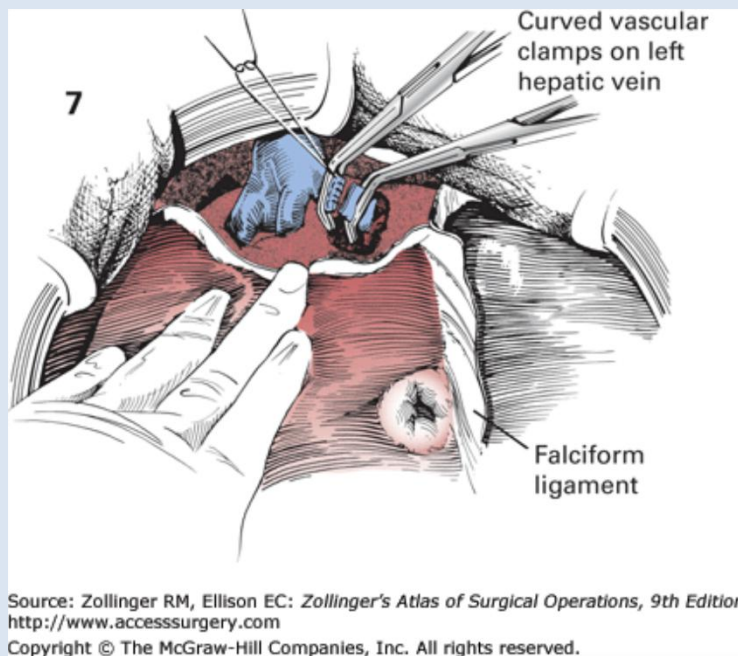
☞ *The left hepatic artery is ligated and divided*



- ☞ *The portal vein bifurcation into its main left and right branches is further defined (if the caudate lobe is to be spared, the caudate branch of the vein must be preserved)*
- ☞ *The left portal vein is divided with vascular load GIA stapler or clamped, divided, and each end oversewn with hemostatic running 4-0 Prolene suture (the proximal, "staying" end may be further reinforced with a horizontal mattress suture)*



- ☞ The remaining left portal triad is cautiously dissected off of the liver near the planned point of division of the lobes
- ☞ After ensuring that it has been adequately freed from the diaphragm, lift the left lateral segments (II and III) to expose the ligamentum venosum. Divide this.
- ☞ Free the left hepatic vein from the liver substance
- ☞ The left hepatic vein is divided with the vascular load GIA or between clamps and oversewn as described for the right hepatic vein above

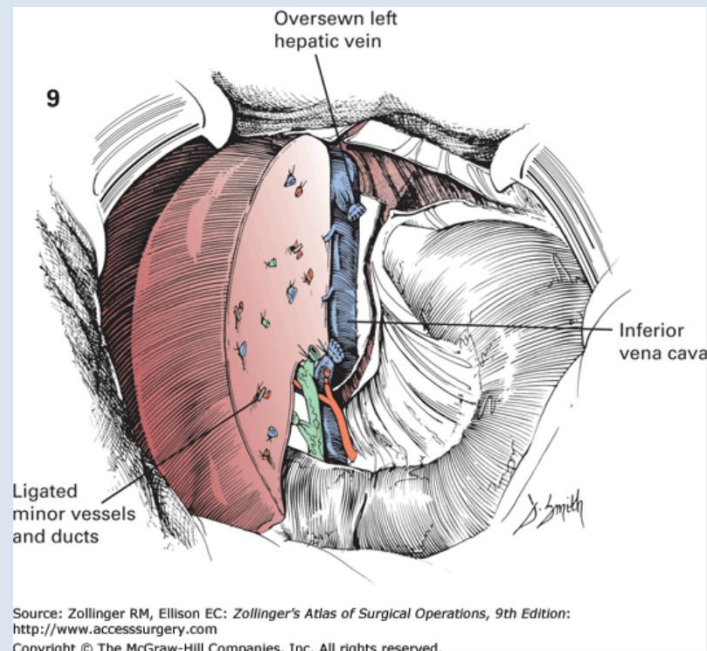


- ☞ Ligation of the blood supply leads to demarcation of the left lobe of the liver and indicates the line of division of the two lobes

- ☞ If a transcatheter energy device is available (e.g. Aquamantys®), this can be used in conjunction with Metzenbaum scissors, a 2nd advanced energy device (e.g. Ligasure™ Dolphin Tip), or a vascular stapler to divide the coagulated hepatic tissue
- ☞ If no such device will be used ...
 - o Prior to resection, hemostasis can be achieved by deeply placing a row of catgut (e.g. 1-0 Chromic on a large, blunt BP needle) mattress sutures parallel and to the right of the resection margin and tying these down enough to compress the hepatic parenchyma without lacerating Glisson's capsule
 - o Division of hepatic parenchyma

Ligation of visible vessels

- ☞ The left lobe is removed
- ☞ Bleeding and bile leakage from the raw liver surface are addressed with suture ligation, electrocoagulation, and/or hemostatic materials



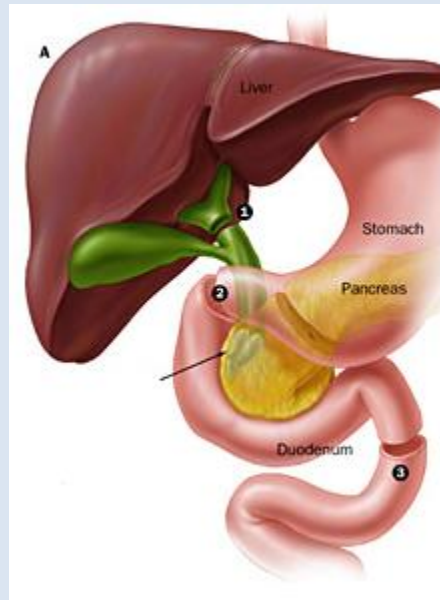
- ☞ Omentum may be tacked to the liver by laying it along the cut edge and securing it in place by tying Chromic sutures over it (similar to a Graham patch)
- ☞ A closed suction drain should be left in place

☞ Left hepatic lobectomy: <http://accesssurgery.mhmedical.com.ezp-prod1.hul.harvard.edu/MultimediaPlayer.aspx?MultimediaID=5481691>

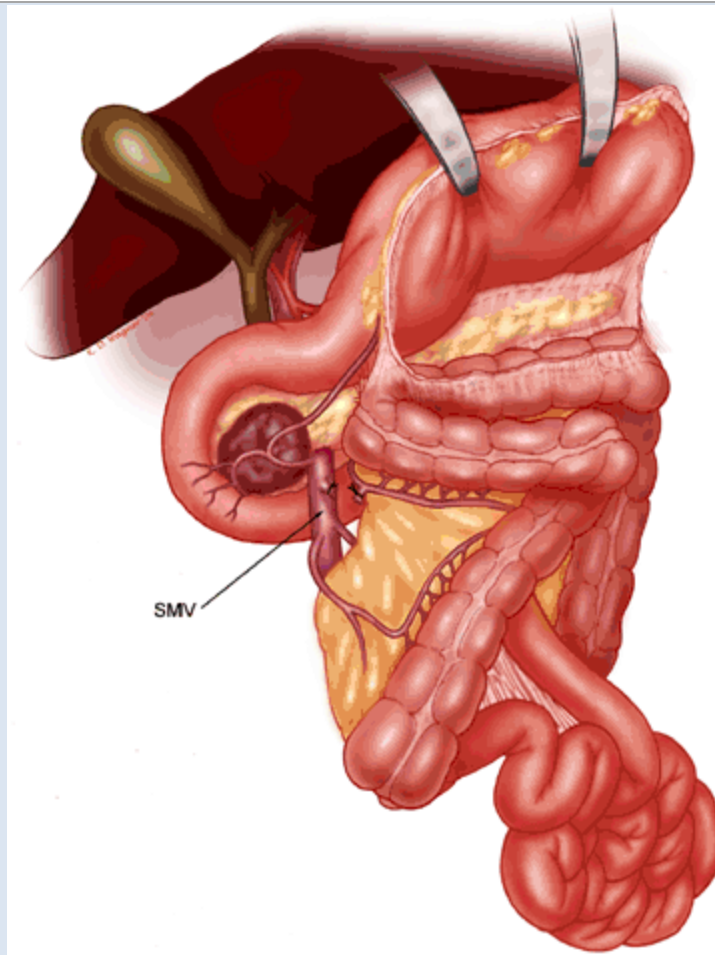
☞ Laparoscopic right hepatic lobectomy: <http://www.surgicalcore.org/videoplayer/510000130/4>

[PANCREAS DIDACTICS--PENDING]**PANCREATODUODENECTOMY (WHIPPLE PROCEDURE)****PANCREATODUODENECTOMY (WHIPPLE PROCEDURE)**

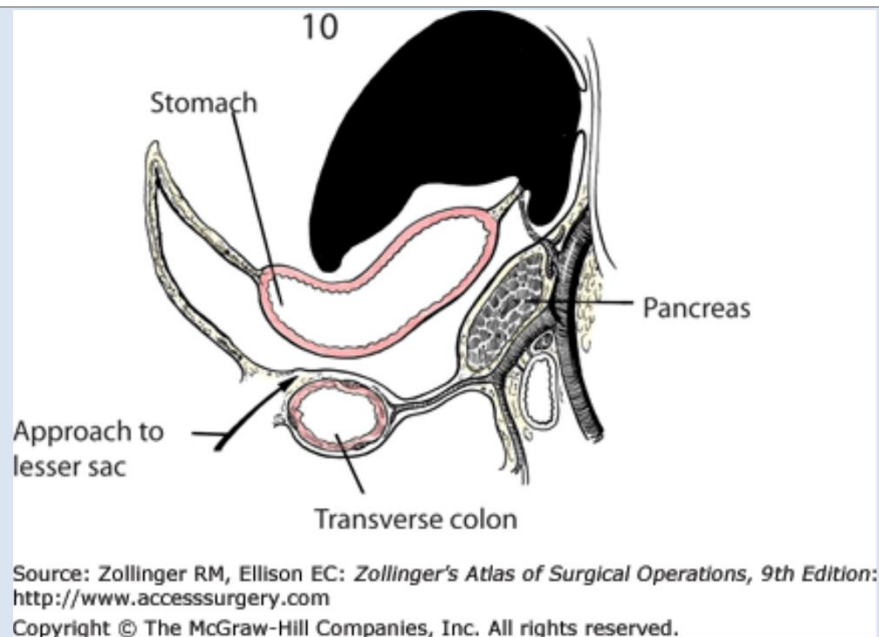
Procedure: Part I – Resection



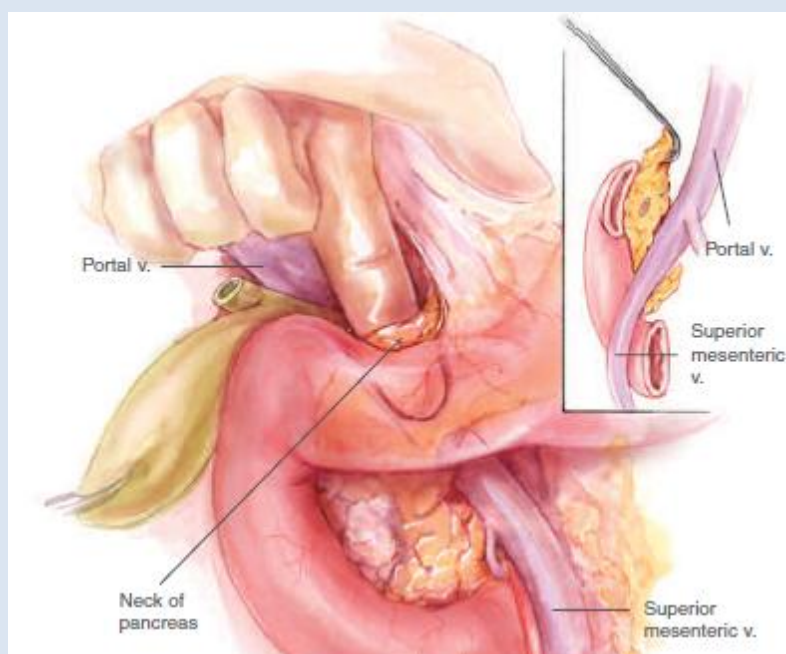
- ☞ *Bilateral subcostal (“chevron”) or generous upper midline incision*
- ☞ *Explore the abdomen thoroughly for evidence of peritoneal or hepatic spread*
- ☞ *Place a self-retaining retractor (e.g. Bookwalter)*
- ☞ *Mobilize the hepatic flexure to free your view of the duodenum (see “right colon and hepatic flexure mobilization, right hemicolectomy” above)*



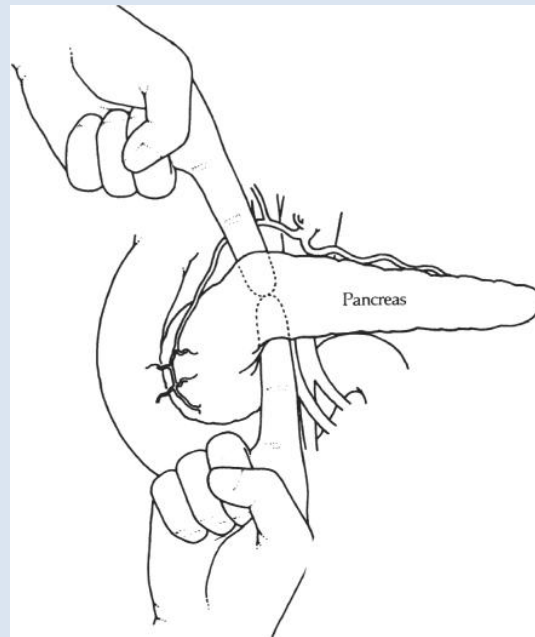
- ☞ Perform the Kocher maneuver (see “RIGHT MEDIAL VISCERAL ROTATION (CATTELL-BRAASCH MANEUVER” above) to mobilize the duodenum
 - o Mobilization of the 3rd portion of the duodenum is particularly challenging given its short mesentery, but will be necessary to remove the specimen
- ☞ Bluntly dissect the posterior pancreas from the underlying IVC and R renal vessels with your finger
 - o Be cautious not to avulse the middle colic vessels which often cross along the superior aspect of the 2nd portion of the duodenum
- ☞ Incise the gastrocolic ligament (greater omentum) to enter the lesser sac and visualize the anterior pancreas



- ☞ Divide the right gastroepiploic vessels and suture ligate with 2-0 silk
- ☞ Perform an open cholecystectomy (see "OPEN CHOLECYSTECTOMY" above)
 - o When ligating the cystic duct, bear in mind that its ostium may be incorporated into the hepaticojejunostomy during the reconstructive phase of the operation
- ☞ Dissect out and preserve the proper and common hepatic arteries
- ☞ Identify the gastroduodenal artery, divide it, and suture ligate with 3-0 Prolene (sometimes a 2-0 silk tie is added to further reinforce the ligature); this exposes the portal vein
- ☞ Bluntly dissect along the anterior aspect of the portal vein (just underneath the pancreatic neck) in a superior-->inferior direction and along the anterior aspect of the SMV in an inferior-->superior direction to create a tunnel

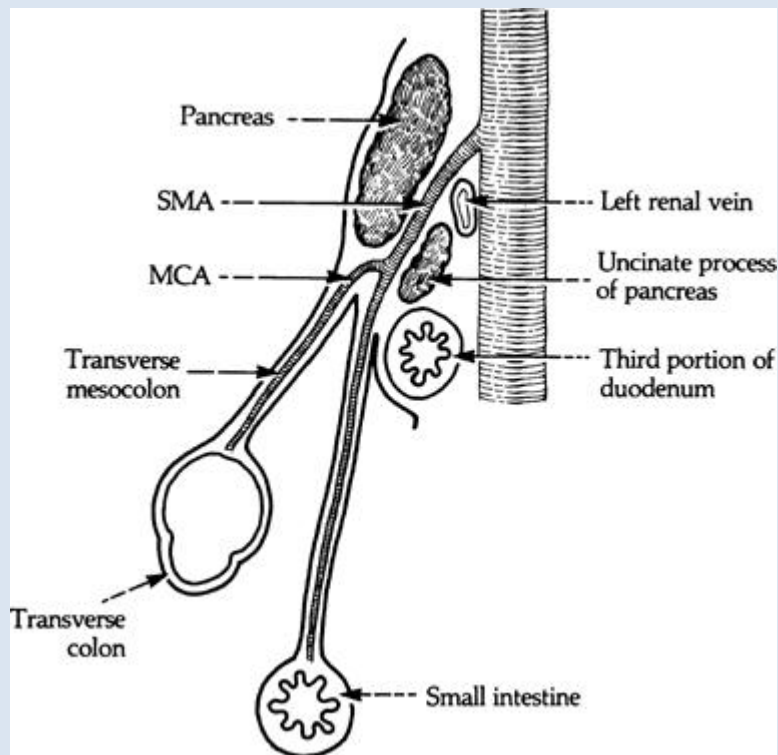


Cameron JL, Sandone C. *Atlas of Gastrointestinal Surgery*. BC Decker, Ontario. 2007.

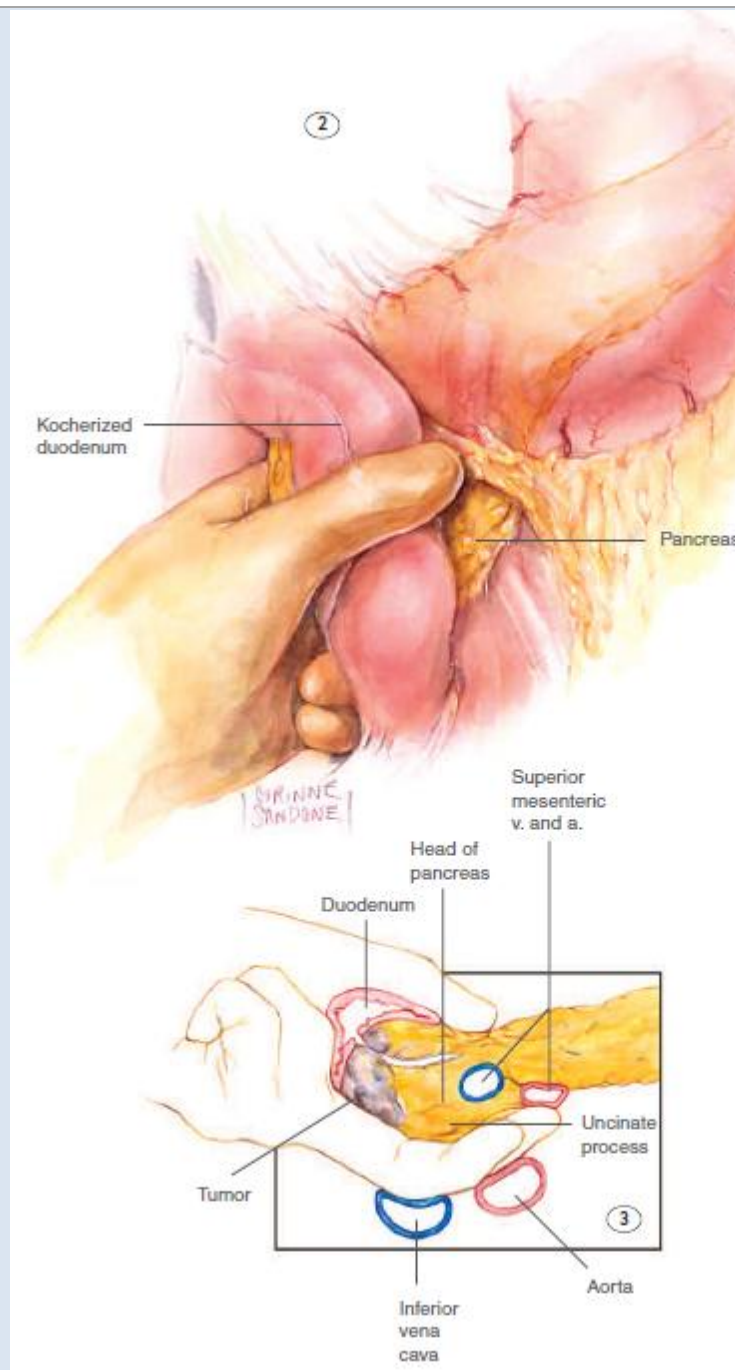


Fischer JE. *Mastery of Surgery*. Lippincott Williams & Wilkins, Philadelphia. 2012.

☞ Assess for resectability of the pancreatic head, in particular focusing on involvement of the vasculature

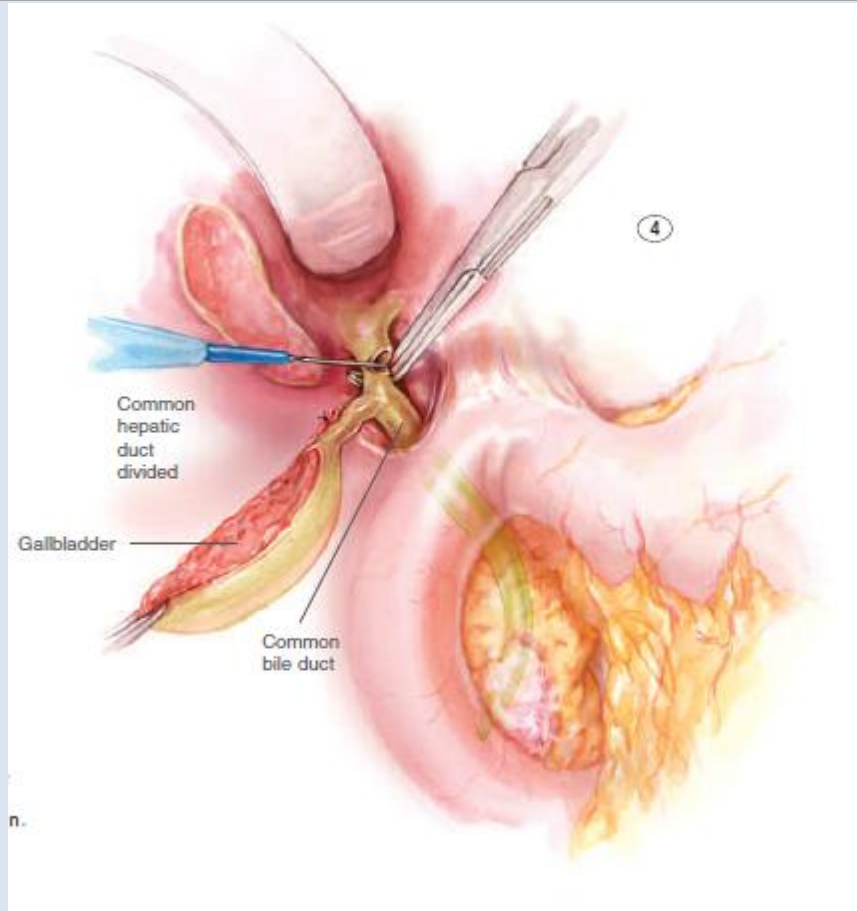


Fischer JE. *Mastery of Surgery*. Lippincott Williams & Wilkins, Philadelphia. 2012.



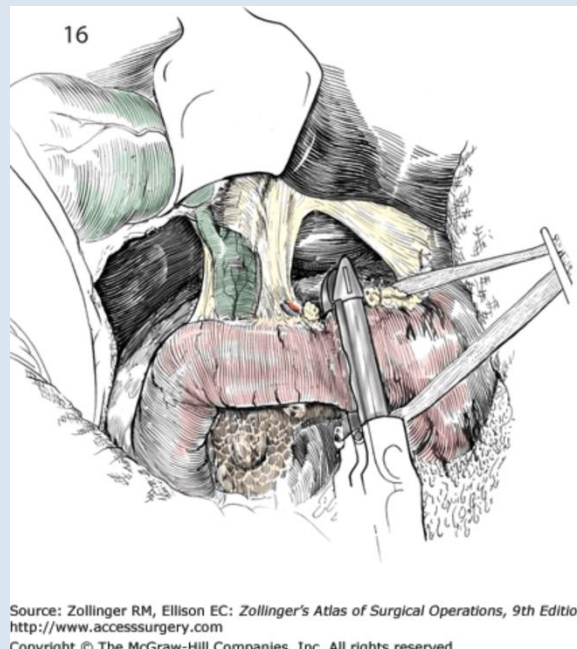
Cameron JL, Sandone C. *Atlas of Gastrointestinal Surgery*. BC Decker, Ontario. 2007.

☞ Once the pancreatic head has been determined to be resectable, divide the common bile duct with cautery; control bile spillage with a bulldog clamp or temporary suture ligature (this region of the duct will be trimmed off)



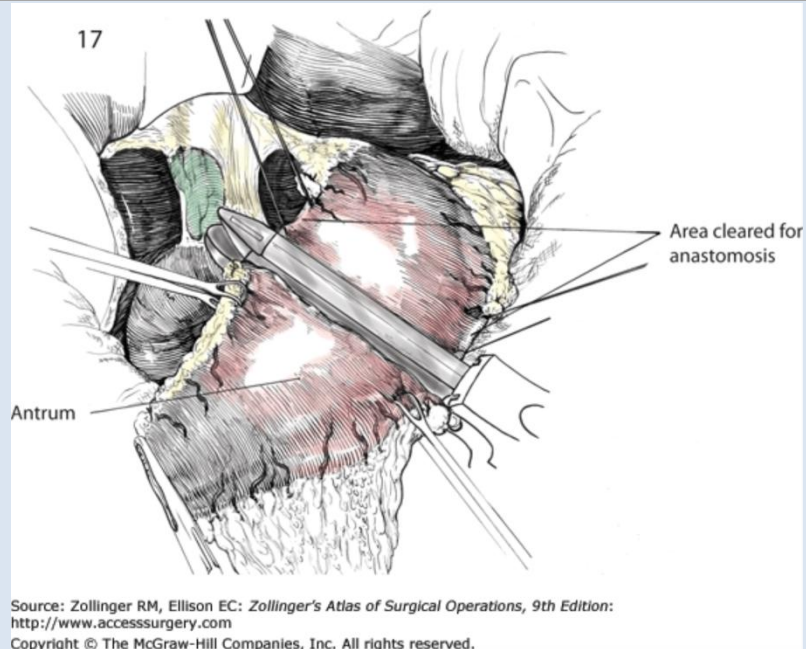
Cameron JL, Sandone C. *Atlas of Gastrointestinal Surgery*. BC Decker, Ontario. 2007.

☞ Divide the duodenum with a GIA 80mm blue load (3.5mm height) stapler if a pylorus-preserving Whipple is being performed or divide the antrum if a classic Whipple is being performed



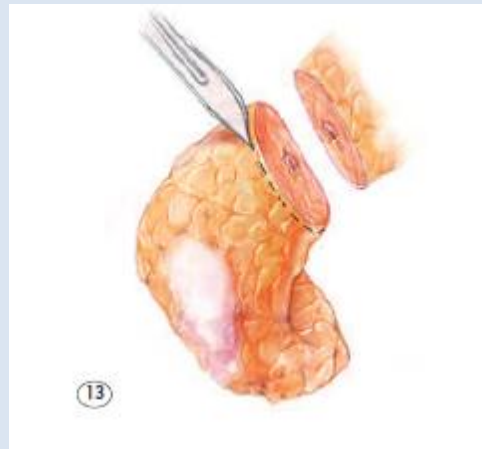
Source: Zollinger RM, Ellison EC: *Zollinger's Atlas of Surgical Operations, 9th Edition*: <http://www.accesssurgery.com>
 Copyright © The McGraw-Hill Companies, Inc. All rights reserved.

Site of transection for pylorus-preserving Whipple



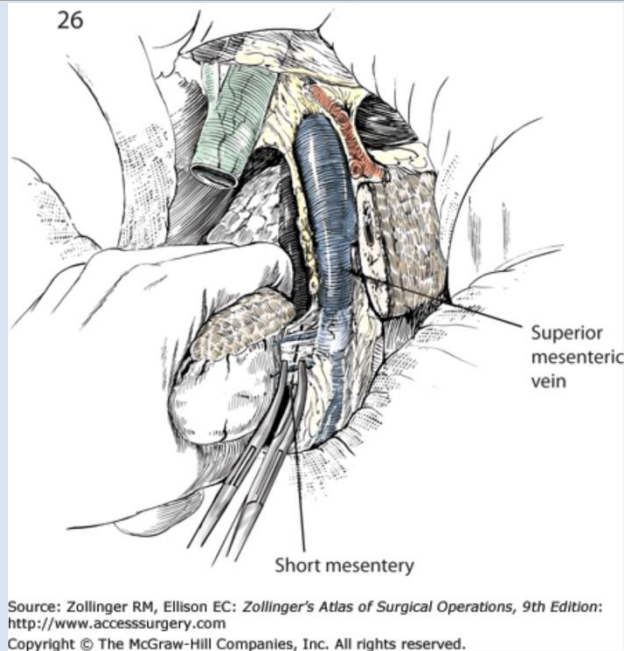
Site of transection for classic Whipple

- ☞ Pack the stomach to the left abdomen to increase visualization of the pancreas
- ☞ Place 2-0 silk stay sutures in the superior pancreas
- ☞ Transect the pancreatic neck with cautery just to the left of the mesenteric vessels and portal vein, then send 2mm shave margins of the remaining neck for frozen section to evaluate pancreatic margins

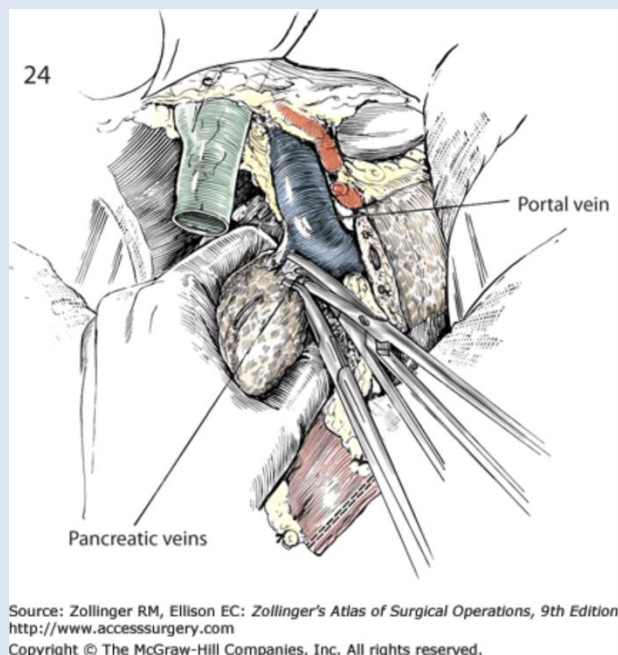


Cameron JL, Sandone C. *Atlas of Gastrointestinal Surgery*. BC Decker, Ontario. 2007.

- ☞ Divide the jejunum 10cm distal to the ligament of Treitz, then divide its mesentery with an advanced energy device (e.g. Ligasure™ Atlas)
- ☞ Free the 3rd and 4th portion of the duodenum—use caution not to avulse the short mesentery

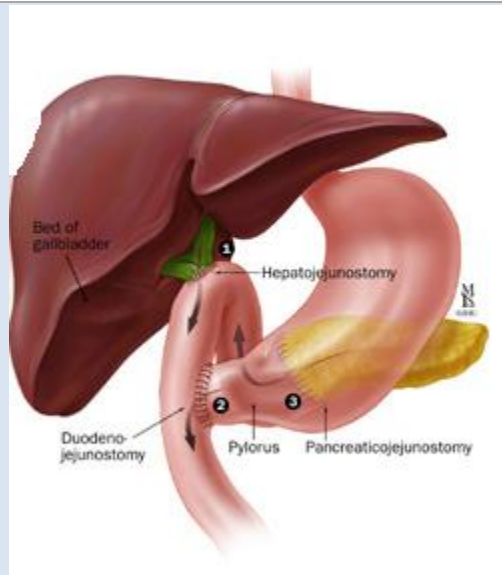


- ☞ *The specimen is now wrapped around the mesenteric vessels—pancreas anteriorly and 3rd and 4th portion of the duodenum posteriorly—so sweep the duodenum and attached jejunum underneath the vessels to bring these anteriorly*
- ☞ *Finally, the pancreatic head and neck must be completely dissected off of the mesenteric vessels—clamp and tie off small vessels and use cautery and/or an advanced energy device to dissect the remaining plane between the pancreas and the superior mesenteric vessels*

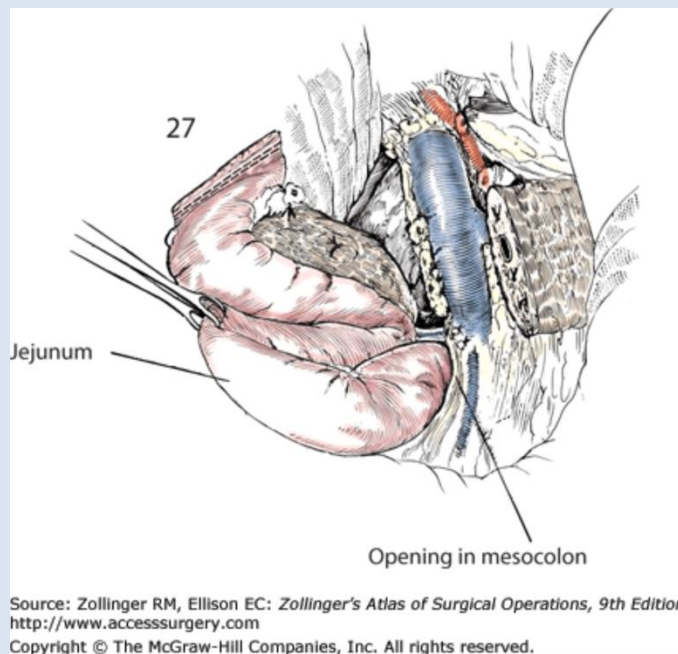


- ☞ *Pass off the specimen and be sure to take additional pancreatic margins if the initial shave margins were positive*

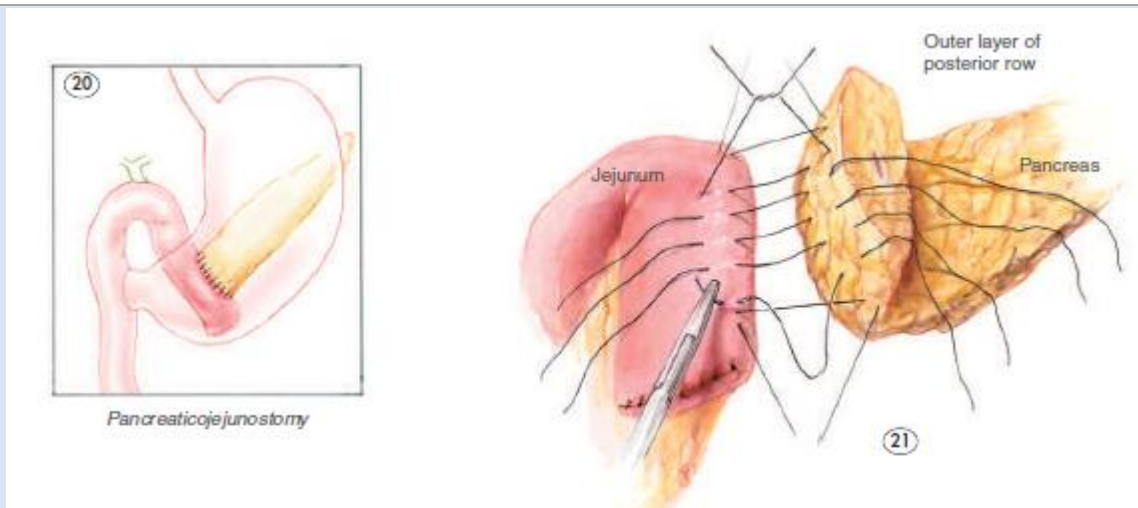
Procedure: Part II—Reconstruction



- ☞ The jejunal stump at the site of the distal transection margin of the bowel is opened and a 5Fr pediatric feeding tube is tunneled through the jejunum for 20cm, secured at each end with a 3-0 Chromic suture, and an interrupted 3-0 silk seromuscular Witzel tunnel created around the exit site
- ☞ A window is created in the transverse mesocolon just to the left of the middle colic vessels, and the jejunum brought through in a retrocolic fashion
 - o Further division of the jejunal mesentery may be required to mobilize it sufficiently to reach the gallbladder fossa/close to the liver hilum to prevent undue tension on the choledocho-/hepatico-jejunosotomy

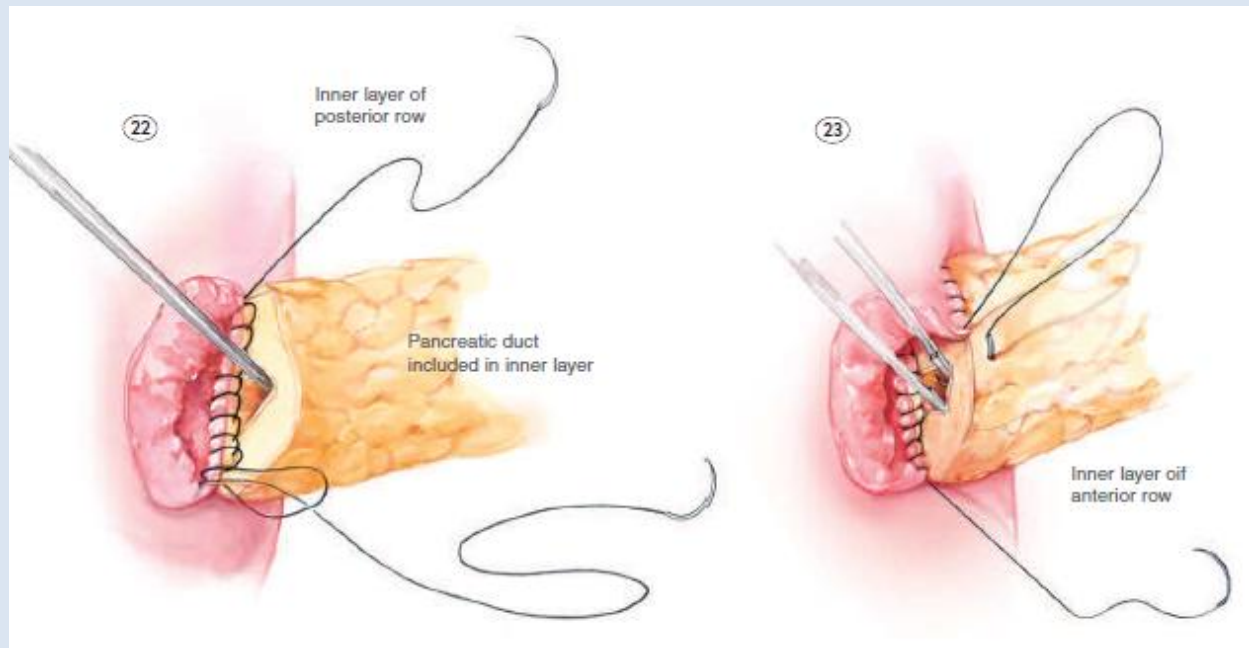


- ☞ An end-to-end or end-to-side 2-layer pancreaticojejunostomy is created in a general fashion similar to that described for hand-sewn enteroenterostomy above (see the "Double layer hand-sewn anastomosis" section of "SMALL BOWEL RESECTION" above)
 - o An interrupted 3-0 silk seromuscular posterior layer is placed



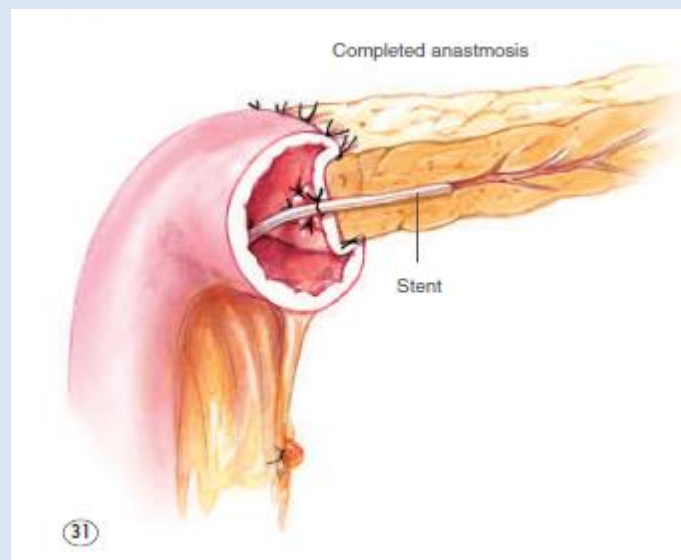
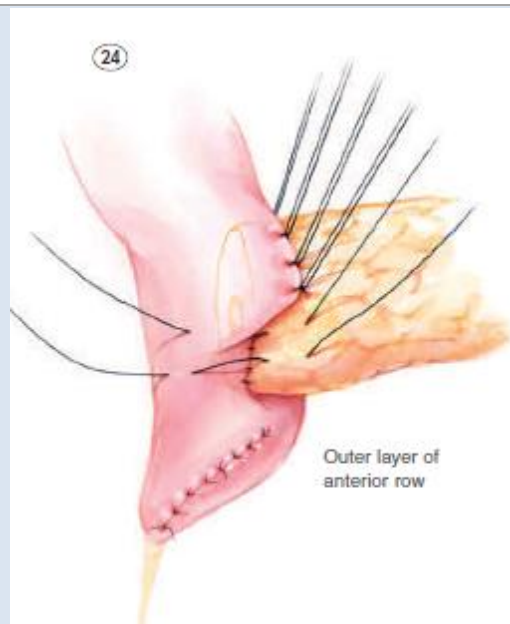
Cameron JL, Sandone C. *Atlas of Gastrointestinal Surgery*. BC Decker, Ontario. 2007.

- o A 4-0 PDS pancreatic duct-to-intestinal mucosa internal layer is constructed—the 5Fr pediatric feeding tube’s tip is threaded into the pancreatic duct prior to completion of the anterior-most inner sutures



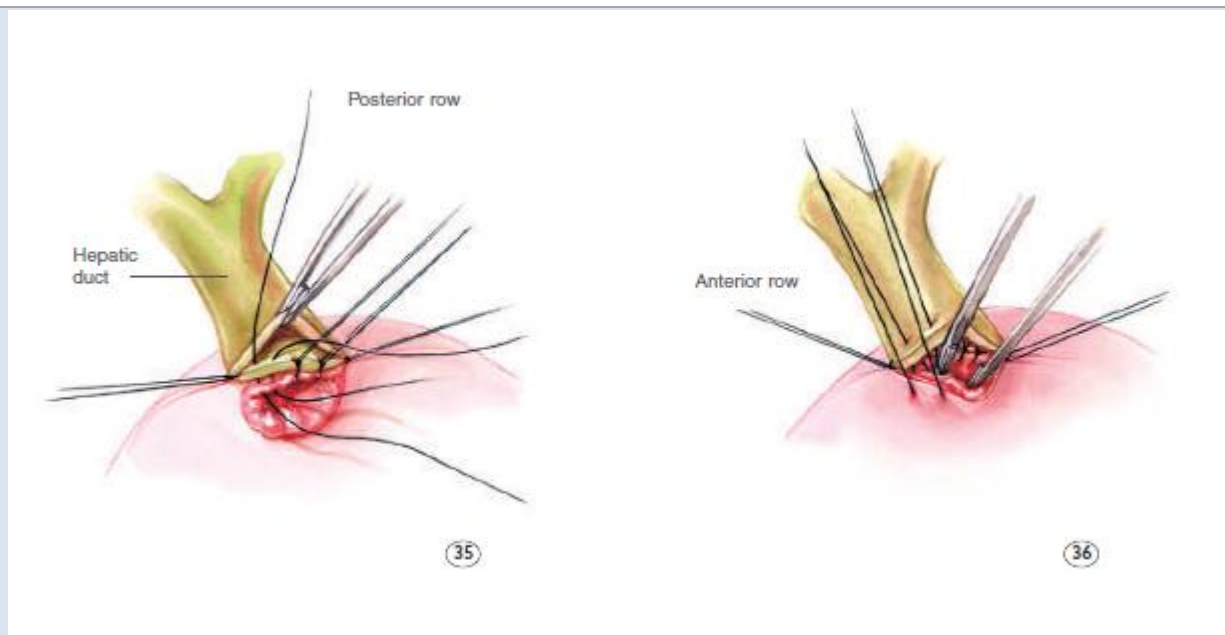
Cameron JL, Sandone C. *Atlas of Gastrointestinal Surgery*. BC Decker, Ontario. 2007.

- o An interrupted 3-0 silk seromuscular anterior layer is placed



Cameron JL, Sandone C. *Atlas of Gastrointestinal Surgery*. BC Decker, Ontario. 2007.

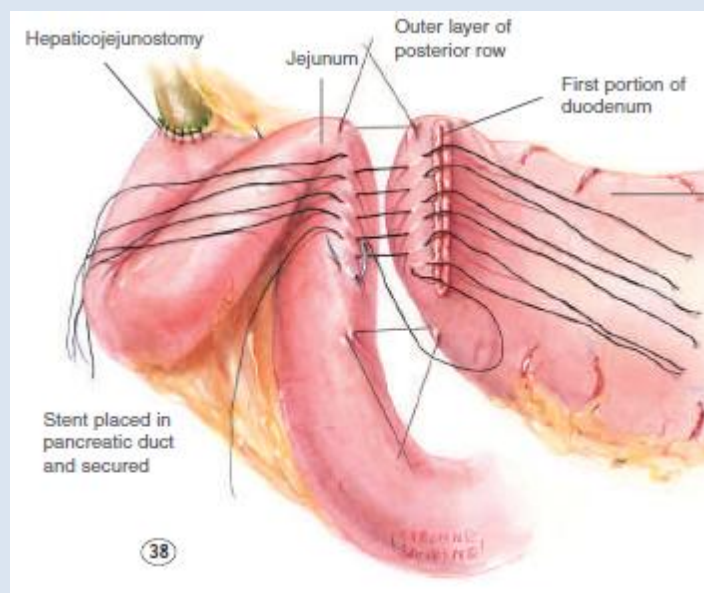
- ☞ *Approximately 10cm distal to the pancreaticojejunostomy a 2nd enterotomy is created to construct the tension-free choledocho-/hepaticojejunostomy*
 - o The bile duct is trimmed back approximately 2cm*
 - o A 1cm enterotomy is made*
 - o Tightly spaced interrupted 4-0 or 5-0 PDS sutures are used (~15-16) to construct an end of hepatic duct-to-side of jejunal anastomosis*

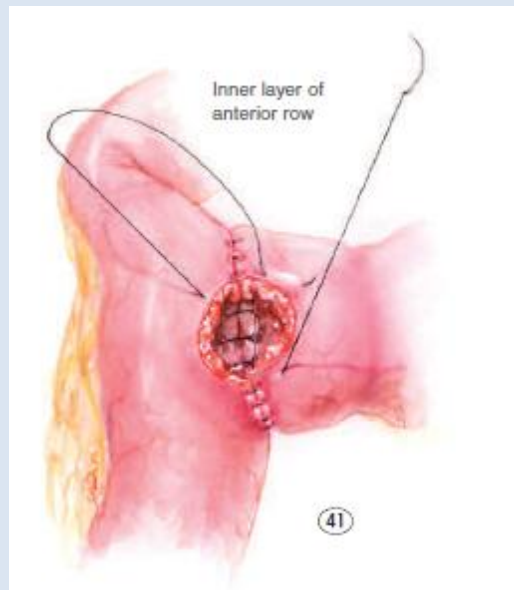
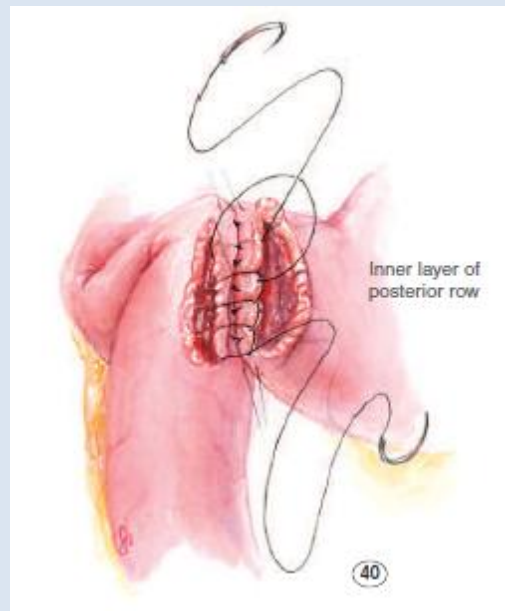
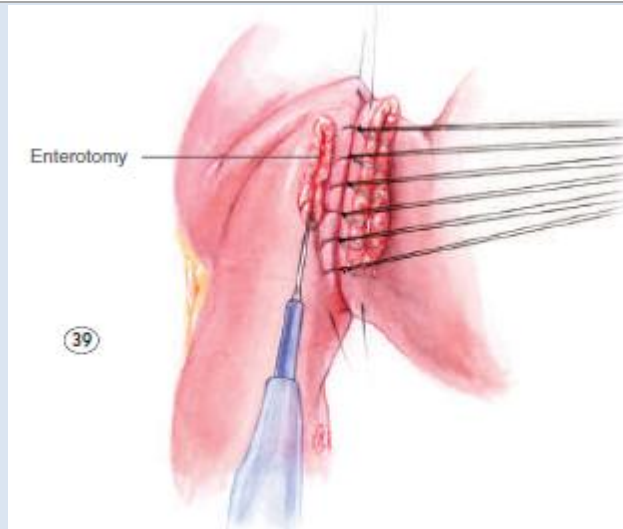


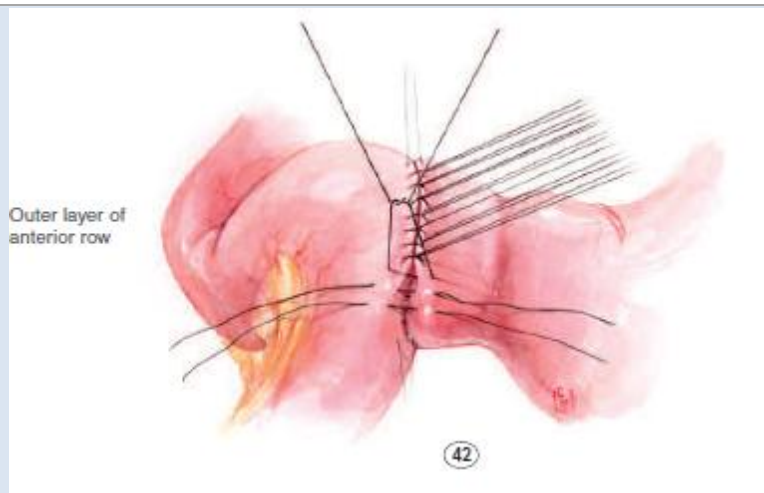
Cameron JL, Sandone C. *Atlas of Gastrointestinal Surgery*. BC Decker, Ontario. 2007.

o Occasionally, additional seromuscular sutures are used to tack the jejunum to the gallbladder bed to diminish tension on the biliary-enteric anastomosis

- ☞ The loop of jejunum traversing the transverse mesocolon is tacked to the mesocolon with 3-0 Vicryl seromuscular sutures
- ☞ The pediatric feeding tube serving as the pancreatic stent is brought out the anterior abdominal wall and the bowel tacked there with interrupted 3-0 silk
- ☞ Further 15-20cm distally, a hand-sewn, 2-layer, end-to-side gastro- or duodenojejunostomy (depending on whether the pylorus was preserved) is created with a 3-0 silk outer layer and 3-0 Vicryl inner layer







Cameron JL, Sandone C. *Atlas of Gastrointestinal Surgery*. BC Decker, Ontario. 2007.

- ☞ A 14Fr Whistle tip catheter may be used to place a jejunostomy tube 20cm distal to the gastro- or duodenojejunostomy
- ☞ Closed suction drains are placed posterior to the hepaticojejunostomy and anterior to the pancreaticojejunostomy, respectively
- ☞ The abdomen is closed in the standard fashion

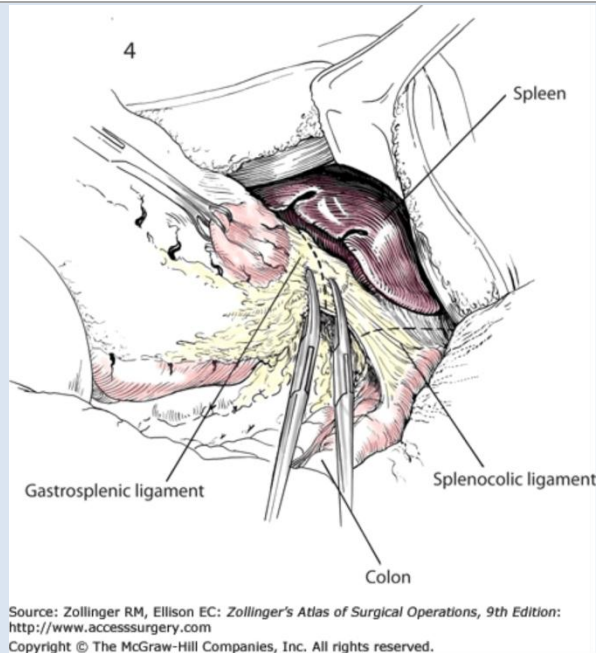
📺 Whipple pancreaticoduodenectomy video:

<http://portal.surgicalcore.org/videoplayer/510000134/5>

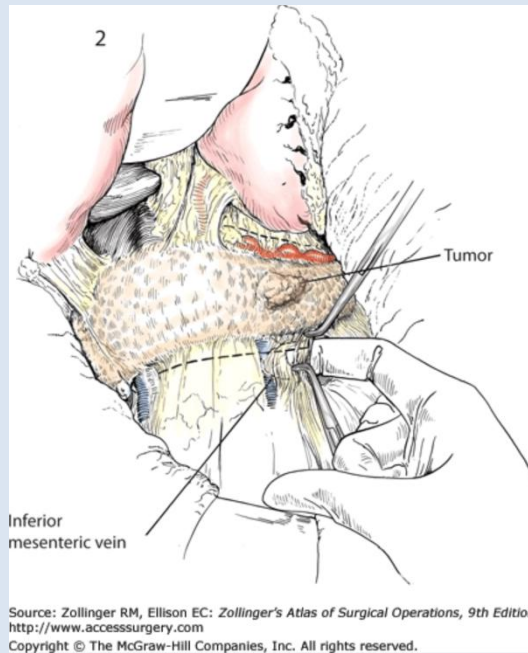
OPEN DISTAL PANCREATECTOMY

Procedure

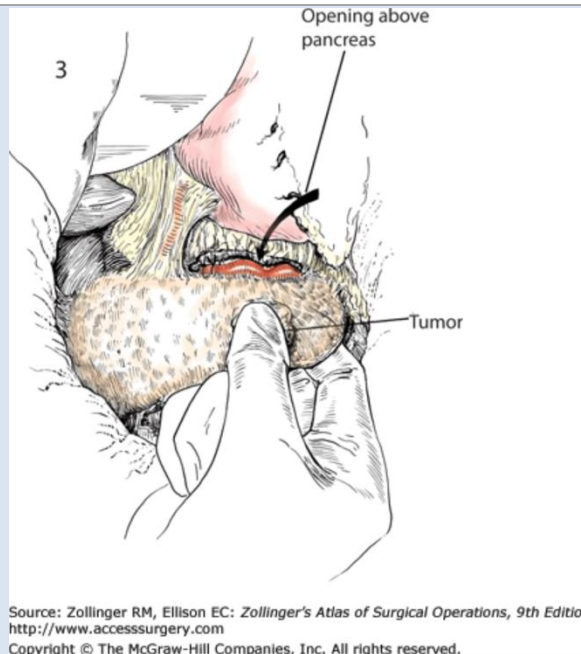
- ☞ Extended left or bilateral subcostal incision, or generous upper midline incision
- ☞ Explore the abdomen for evidence of metastases
- ☞ Place a self-retaining retractor for exposure
- ☞ Incise the greater omentum to enter the lesser sac and begin dividing the omentum heading to the left and cranially (toward the short gastric vessels)
- ☞ Divide the short gastric vessels all the way up to the diaphragm using the clamp-and-tie technique or an advanced energy device and retract the stomach cephalad to better visualize the underlying lesser sac structures



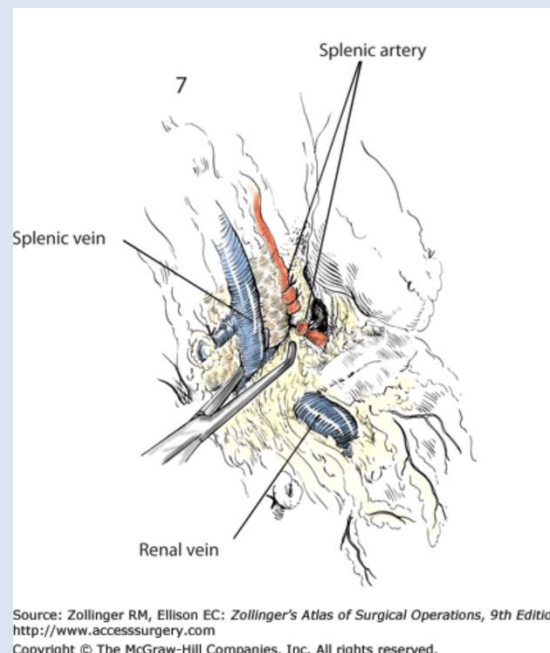
☞ *Incise the peritoneum along the inferior and superior border of the pancreas*



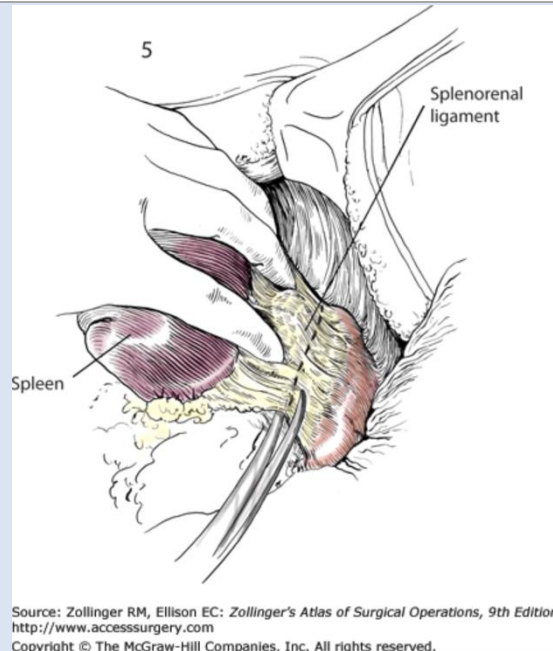
☞ *Dissect posterior to the pancreas to free the body up to the neck and superior mesenteric vessels*



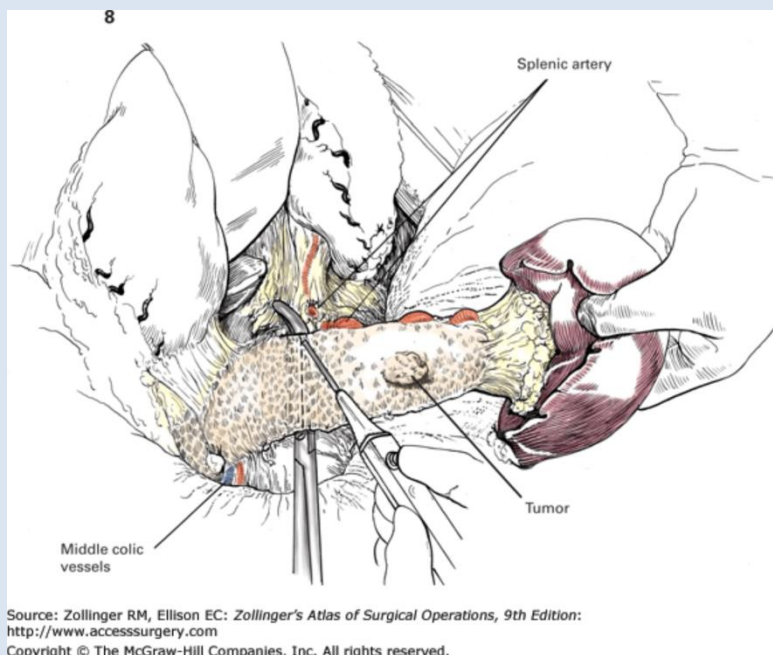
- ☞ Locate the celiac artery, incise the peritoneum over the proximal splenic artery, and clear this circumferentially
- ☞ Divide the splenic artery with a vascular load (2.5mm staple height) GIA or suture ligate with 3-0 Prolene
- ☞ Clear the splenic vein from any connective tissue and trace it distally (toward the portal vein), separating it gently from the posterior pancreas



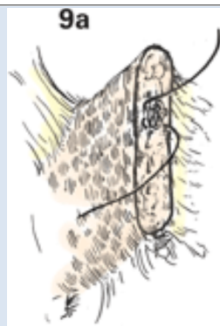- ☞ Divide the splenic vein at its confluence with the SMV separately with a 2nd vascular load GIA or ligate
- ☞ If the spleen is to be removed, it can be retracted medially and freed from its lateral attachments and the splenorenal ligament divided



- ☞ Dissect the tail of the pancreas from its retroperitoneal attachments with electrocautery and/or an advanced energy device (e.g. Ligasure™)
- ☞ Traction sutures may be placed at the pancreatic neck
- ☞ Divide the pancreas at the neck with cautery; send off the specimen; be sure to send a shave margin for frozen sectioning

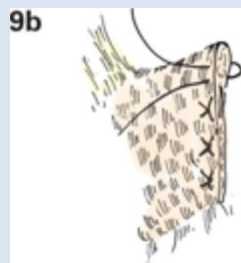


- ☞ Oversew the pancreatic duct with 4-0 PDS (nonabsorbable monofilament is used in some cases)

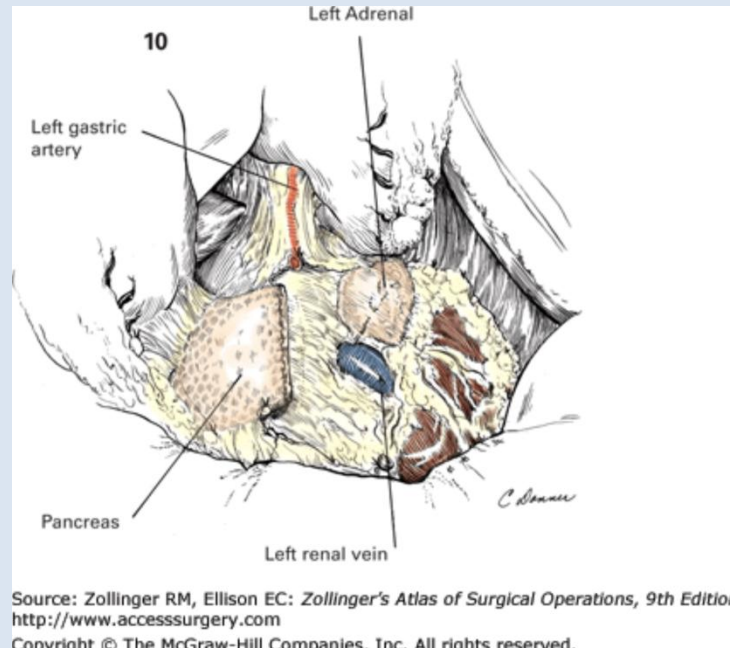


Source: Zollinger RM, Ellison EC: *Zollinger's Atlas of Surgical Operations, 9th Edition*:
<http://www.accesssurgery.com>
 Copyright © The McGraw-Hill Companies, Inc. All rights reserved.

☞ Close the cut end of the pancreatic neck using overlapping, horizontal 3-0 Prolene mattress sutures



Source: Zollinger RM, Ellison EC: *Zollinger's Atlas of Surgical Operations, 9th Edition*:
<http://www.accesssurgery.com>
 Copyright © The McGraw-Hill Companies, Inc. All rights reserved.



Source: Zollinger RM, Ellison EC: *Zollinger's Atlas of Surgical Operations, 9th Edition*:
<http://www.accesssurgery.com>
 Copyright © The McGraw-Hill Companies, Inc. All rights reserved.

☞ The falciform ligament may be mobilized and used to buttress the oversewn cut edge of the neck with interrupted 3-0 Vicryl sutures

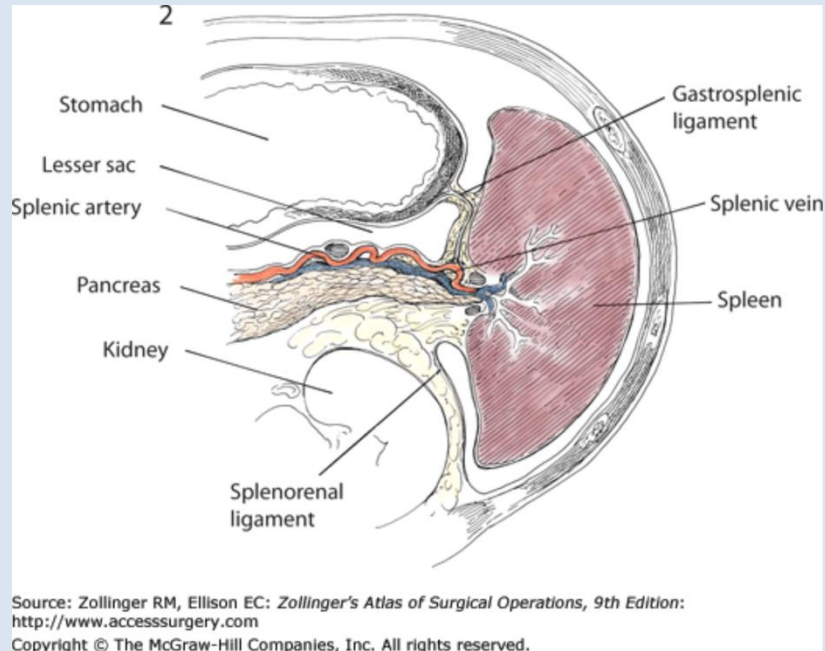
☞ A closed suction drain (e.g. 19Fr Blake) should be left with its tip adjacent to the cut edge of the pancreas

📺 Laparoscopic distal pancreatectomy: <http://www.surgicalcore.org/videoplayer/510000129/5>

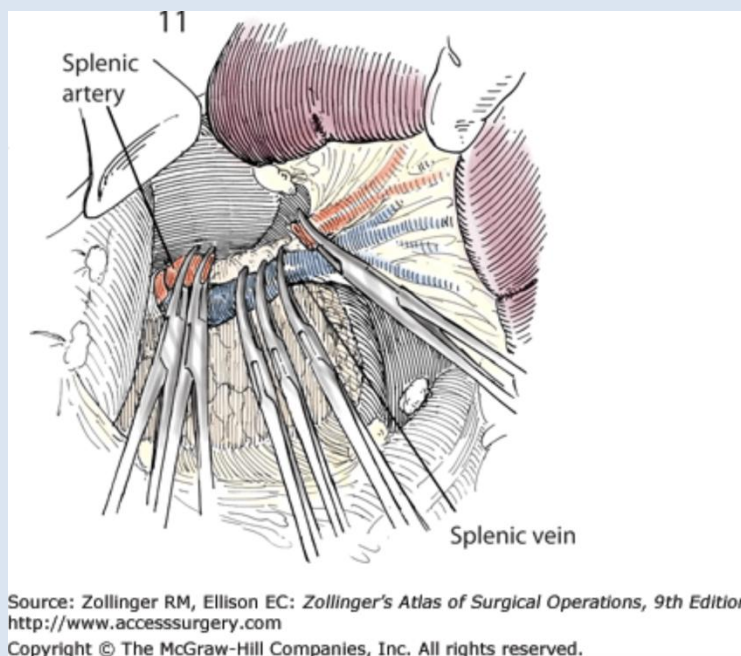
[SPLEEN DIDAC TICS]

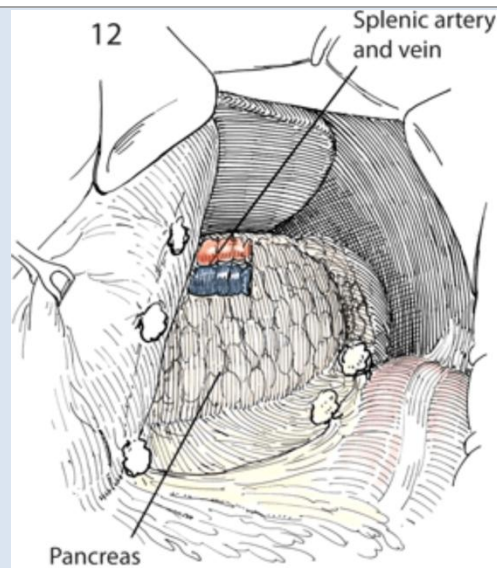
OPEN SPLENECTOMY

Procedure



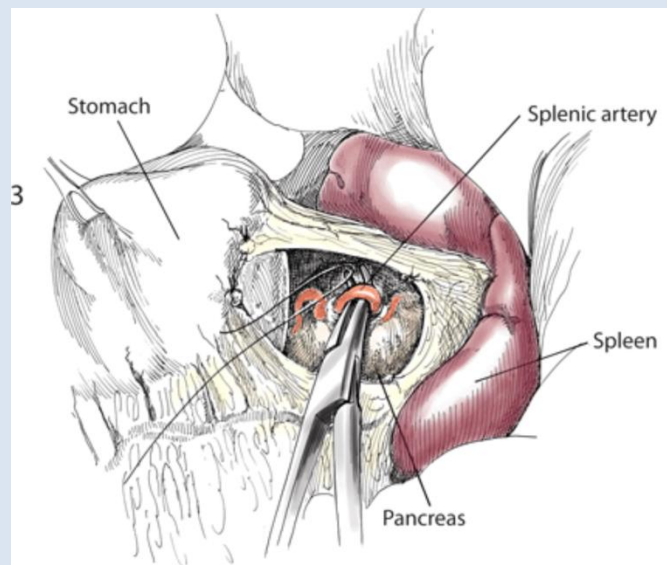
- ☞ Generous upper midline incision or left subcostal incision
- ☞ The gastrocolic or gastrosplenic ligament is incised and the short gastrics ligated as above (see "OPEN DISTAL PANCREATECTOMY")
- ☞ The splenic artery and vein can be dissected and ligated as described above (see "OPEN DISTAL PANCREATECTOMY")





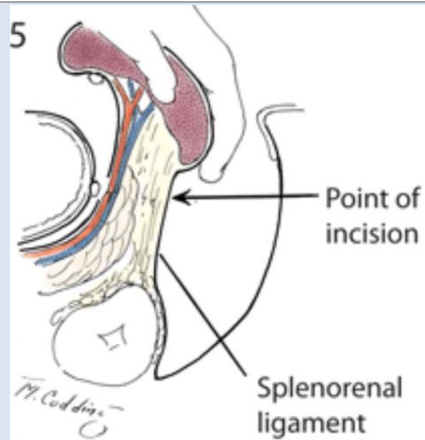
Source: Zollinger RM, Ellison EC: *Zollinger's Atlas of Surgical Operations, 9th Edition*:
<http://www.accesssurgery.com>
 Copyright © The McGraw-Hill Companies, Inc. All rights reserved.

- ☞ Depending on the indication for splenectomy, the surgeon may opt instead for rapid initial ligation of the main vascular pedicle as this corrects the bleeding tendency, and then divide the short gastrics and splenic mobilization

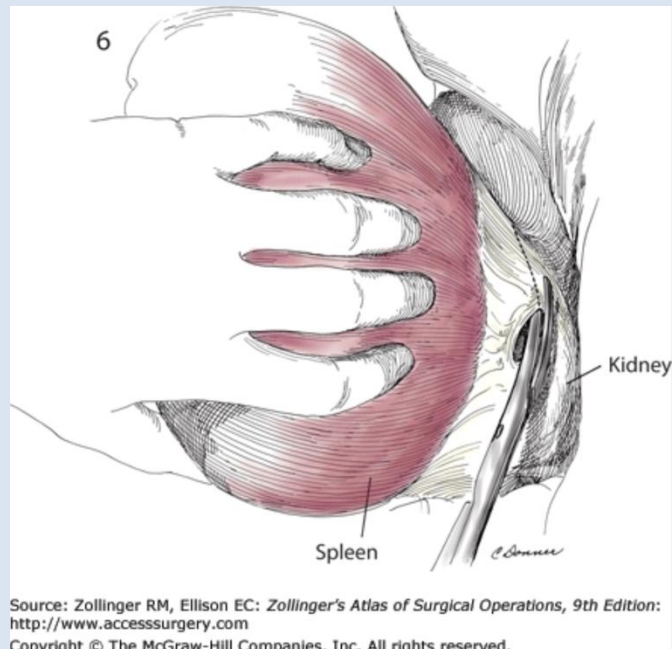


Source: Zollinger RM, Ellison EC: *Zollinger's Atlas of Surgical Operations, 9th Edition*:
<http://www.accesssurgery.com>
 Copyright © The McGraw-Hill Companies, Inc. All rights reserved.

- ☞ The spleen is medialized (cautiously so as not to avulse the capsule) and attachments to the left hemidiaphragm and laterally are freed
- ☞ The splenorenal ligament is divided (the splenic artery and vein contained therein were ligated above) and the spleen removed



Source: Zollinger RM, Ellison EC: *Zollinger's Atlas of Surgical Operations, 9th Edition*: <http://www.accesssurgery.com>
 Copyright © The McGraw-Hill Companies, Inc. All rights reserved.



Source: Zollinger RM, Ellison EC: *Zollinger's Atlas of Surgical Operations, 9th Edition*: <http://www.accesssurgery.com>
 Copyright © The McGraw-Hill Companies, Inc. All rights reserved.

☞ Depending on the indication, a search for accessory splenules may be undertaken systematically: splenic hilum --> splenorenal ligament --> greater omentum --> retroperitoneum adjacent to the tail of the pancreas --> splenocolic ligament --> small and large bowel mesenteries

📺 Laparoscopic splenectomy: <http://www.surgicalcore.org/videoplayer/510000151/6>

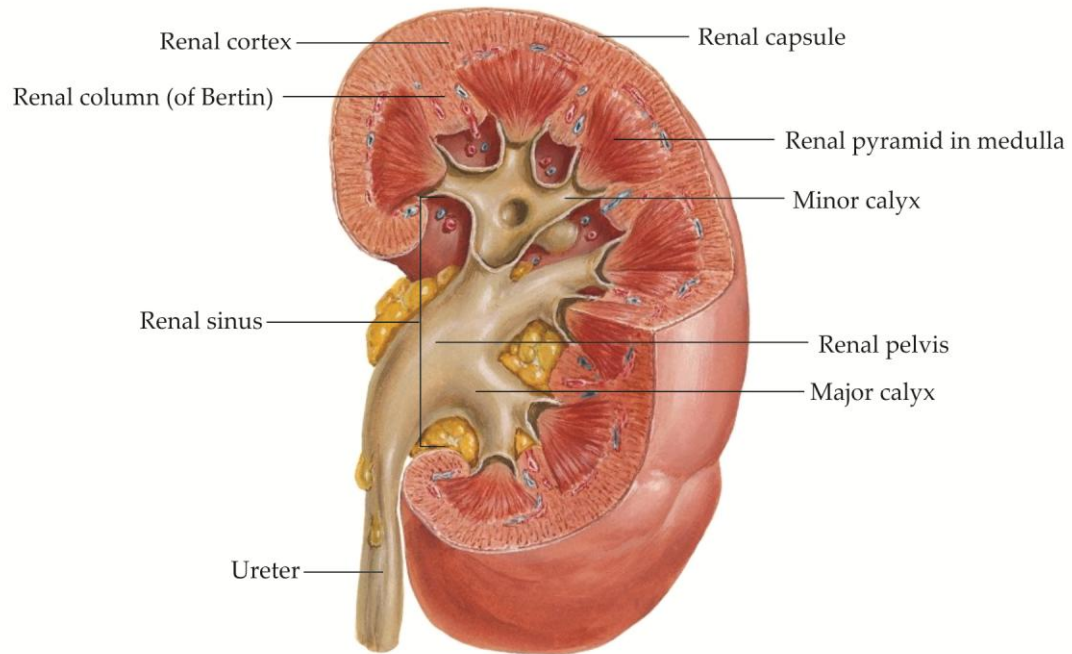


Figure 3-5. Organization of the kidney. (Modified from *Netter Atlas of Human Anatomy*, 5th Edition. Philadelphia: Elsevier, 2010.)

KIDNEYS AND URETERS

Location

The **left and right kidneys** are located within the retroperitoneum, posterior to the peritoneal sac (Figure 3-&). The kidney hila face medially and slightly anteriorly. The **upper pole of the left kidney** reaches the eleventh rib. The **upper pole of the right kidney**, displaced inferiorly by the liver, reaches the twelfth rib.

A layer of **perirenal fat** surrounds each kidney (Figure 3-&). The **perirenal fascia**, a membranous condensation of collagen fibers within the retroperitoneal fat, surrounds both kidneys, the aorta, and the inferior vena cava, separating the perirenal fat surrounding the kidney from the **pararenal fat** outside the perirenal fascia.

Function

Renal metabolic functions include excretion of excess water and the end-products of metabolism, thereby maintaining a constant electrolyte and water balance. **Renal endocrine functions** include the synthesis and release of renin, erythropoietin, and 1,25-di-hydroxycholecalciferol, the active form of Vitamin D.

Organization

The kidney is surrounded by a **capsule** consisting of collagen and elastic fibers and smooth muscle (Figure 3-&). The medial surface of the kidney is indented as the fat-filled **renal sinus**. The minor and major calyces and renal pelvis of the **urinary collecting system** occupy the renal sinus.

The kidney parenchyma consists of an **inner medulla** adjacent to the collecting system in the renal sinus, and an **outer cortex**, deep to the renal capsule.

The **renal medulla** is formed by **renal pyramids** with apices draining into the **minor calyces** of the collecting system. The **renal cortex** includes the subcapsular portion and the **renal columns (of Bertin)** which extend inward between the renal pyramids.

The **renal tubule** consists of a single layer of epithelium and includes the glomerular capsular space, proximal convoluted tubule, loop of Henle, distal convoluted tubule, connecting tubule, and collecting duct. The collecting ducts widen to form the papillary ducts with orifices on the **papilla** of each renal pyramid (area cribrosa). Urine emerging at the area cribrosa drains through the **minor calyces, major calyces**, and **renal pelvis** before reaching the proximal **ureter**.

Development

Three paired kidney systems develop sequentially from the nephrogenic cord of the intermediate mesoderm in the embryo.

The **pronephros** appears in the cervical region at the beginning of the 4th week of development. The pronephros helps initiate formation of the mesonephros, then regresses.

The **mesonephros** appears at the end of the 4th week of development, forming a series of mesonephric nephrons, each consisting of a renal capsule and a capillary tuft. The mesonephric nephrons briefly function, and then disappear. The **mesonephric ducts** persist in males as the genital ducts (efferent ducts, epididymis, ductus deferens, seminal vesicles, and ejaculatory ducts) and in females as vestigial structures. The distal parts of the mesonephric ducts persist in both sexes and contribute to the formation of the **ureteric bud**.

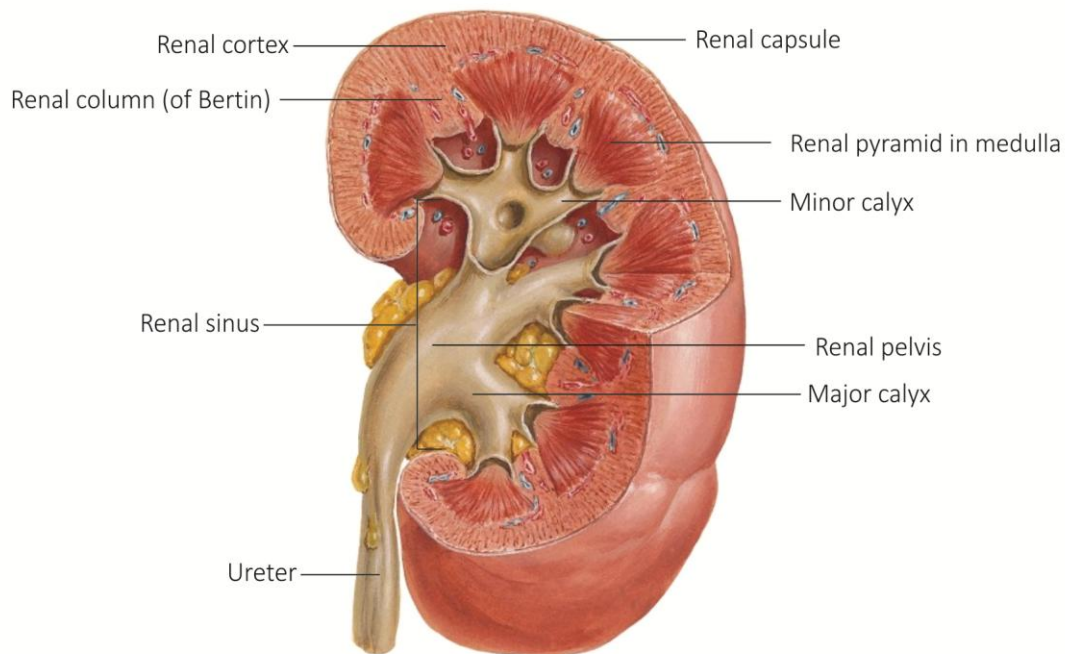
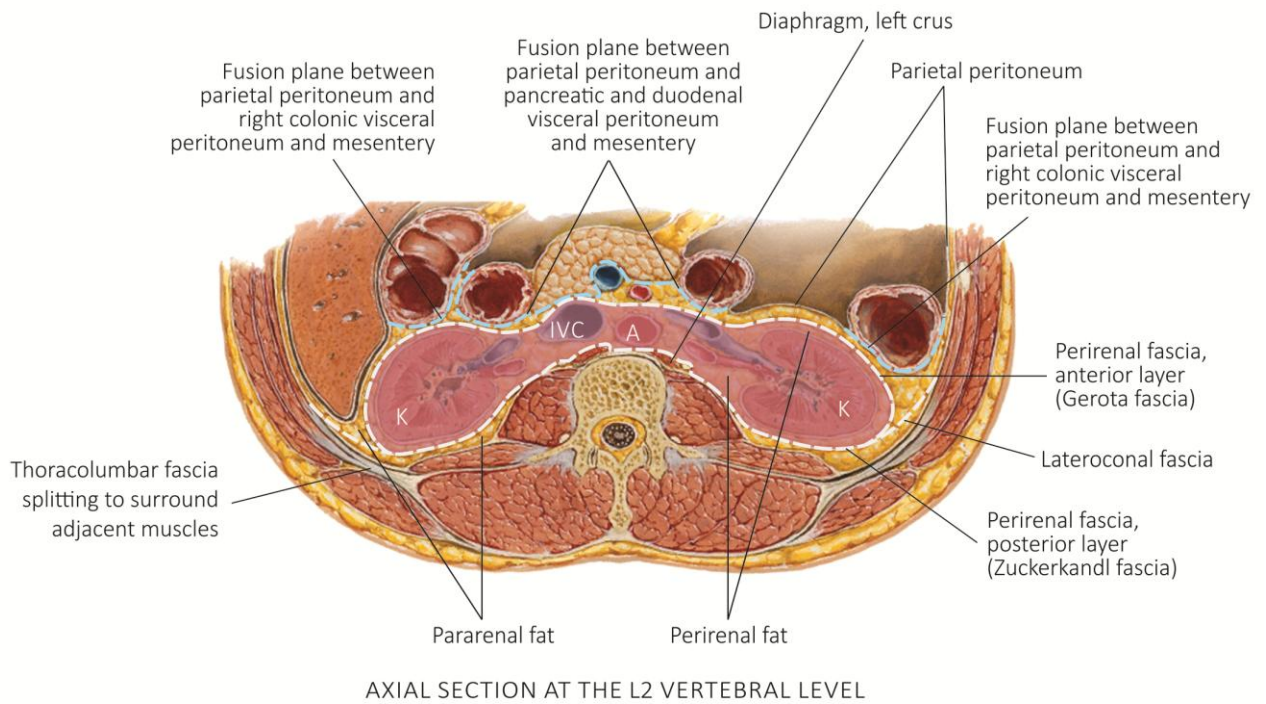


Figure 3-&. Location and organization of the kidney and perirenal fascia. (Modified from *Netter Atlas of Human Anatomy*, 5th Edition. Philadelphia: Elsevier, 2010.)

The **metanephros**, the definitive kidney, appears in the pelvis during the 5th week of gestation as the mesonephros regresses. **Collecting tubules** from the ureteric bud penetrate the metanephros. A metanephric caps forms around the end of each collecting tubules, then elaborates as Bowman's capsule, the proximal convoluted tubules, loop of Henle, and distal convoluted tubules. Vascular endothelium, attracted to the developing Bowman's capsules, forms glomeruli. The glomeruli and Bowman's capsules comprise the **nephron**.

As the embryo lengthens, the definitive **metanephric kidneys** 'ascend' from the pelvis to the posterior abdominal wall. As they ascend, the kidneys typically rotate 90°, so that the renal pelvis face medially, and they obtain their blood supply from a succession of progressively higher segmental arteries that supplied the regressing mesonephros. The metanephric kidneys begin to function during the 9th week of development, but additional nephrons continue to form until the 9th month. **Renal congenital anomalies** include renal agenesis; pelvic kidneys; duplication of the renal pelvis and ureters with ectopic drainage into the urethra, vagina, ductus deferens, seminal vesicles, or prostate; renal fusion to form horseshoe or cake kidneys. **Horseshoe kidneys** are commonly arrested in their ascent at the inferior mesenteric artery.

Accessory renal arteries, such as the accessory right renal inferior polar artery, are persistent branches of the segmental mesonephric arteries appropriated by the kidney during its ascent. Accessory renal arteries are often end-arteries, and their division can devascularize the portion of the kidney supplied by the anomalous artery, an important consideration in harvesting donor kidneys for transplantation.

Arterial supply and venous drainage

Approximately 20% of total cardiac output is delivered to the kidneys through the paired **renal arteries** (Figure 8.6). **Accessory renal arteries**, most commonly arising from the aorta to supply the inferior pole, are found in approximately 30% of cases.

The paired **renal veins** lie anterior to the renal arteries at the renal hilum. Both renal veins drain directly into the vena cava. On the left, the gonadal and adrenal veins drain into the left renal vein. On the right, the gonadal and adrenal veins drain directly into the aorta.

At the renal hilum, the renal arteries divide into **anterior and posterior divisions** that branch to supply the **five renal vascular segments** (Figure 8.6). The **posterior division** of the renal artery becomes the **posterior segmental artery** and supplies the posterior segment of the kidney. The larger **anterior division** of the renal artery divides into the **superior segmental artery, anterior superior segmental artery, anterior inferior segmental artery, and inferior segmental artery**. Each segmental branch of the renal arteries supplies a single renal vascular segment.

The [relatively] **bloodless line of Brödel** marks the boundary between the renal vascular segments supplied by the anterior and posterior branches of the renal arteries (Figure 8.6). The segmental arteries subsequently divide into **lobar arteries, interlobar branches, arcuate arteries, and interlobular arteries**.

Lymphatic drainage

Lymph from the kidneys drains to **para-aortic nodes** adjacent to the renal arteries.

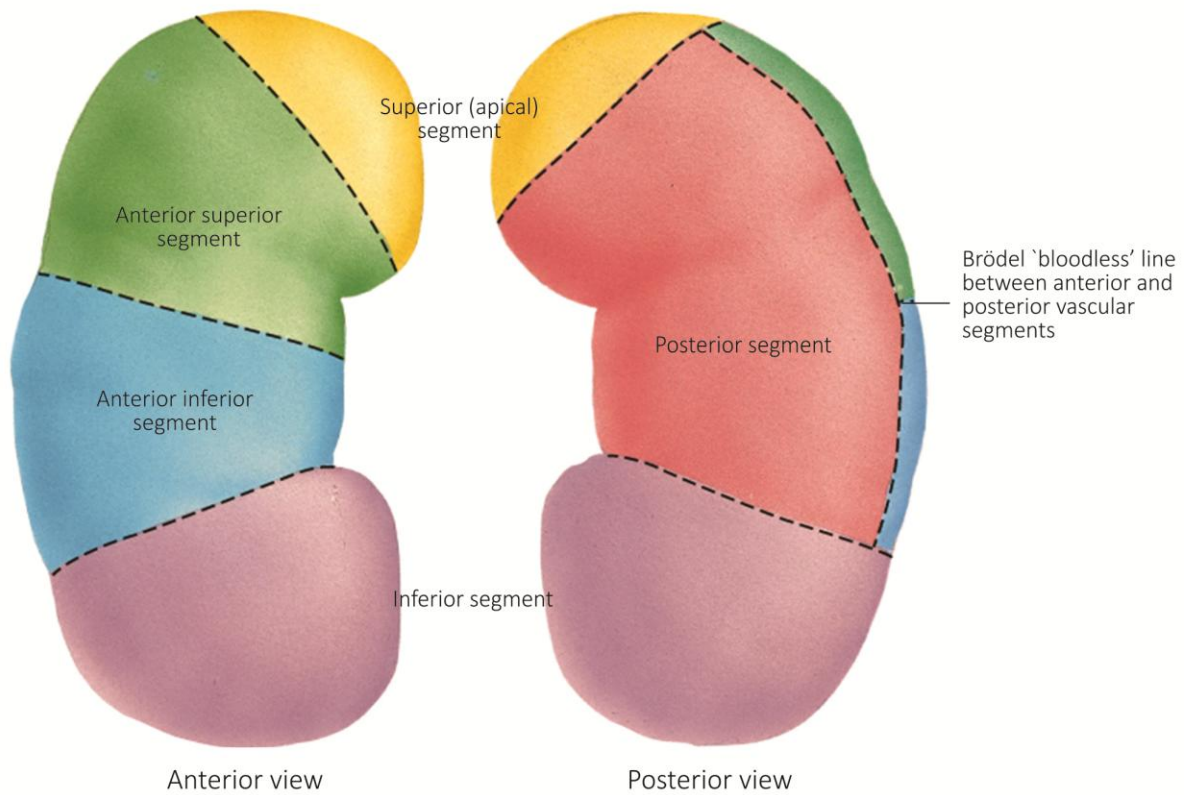
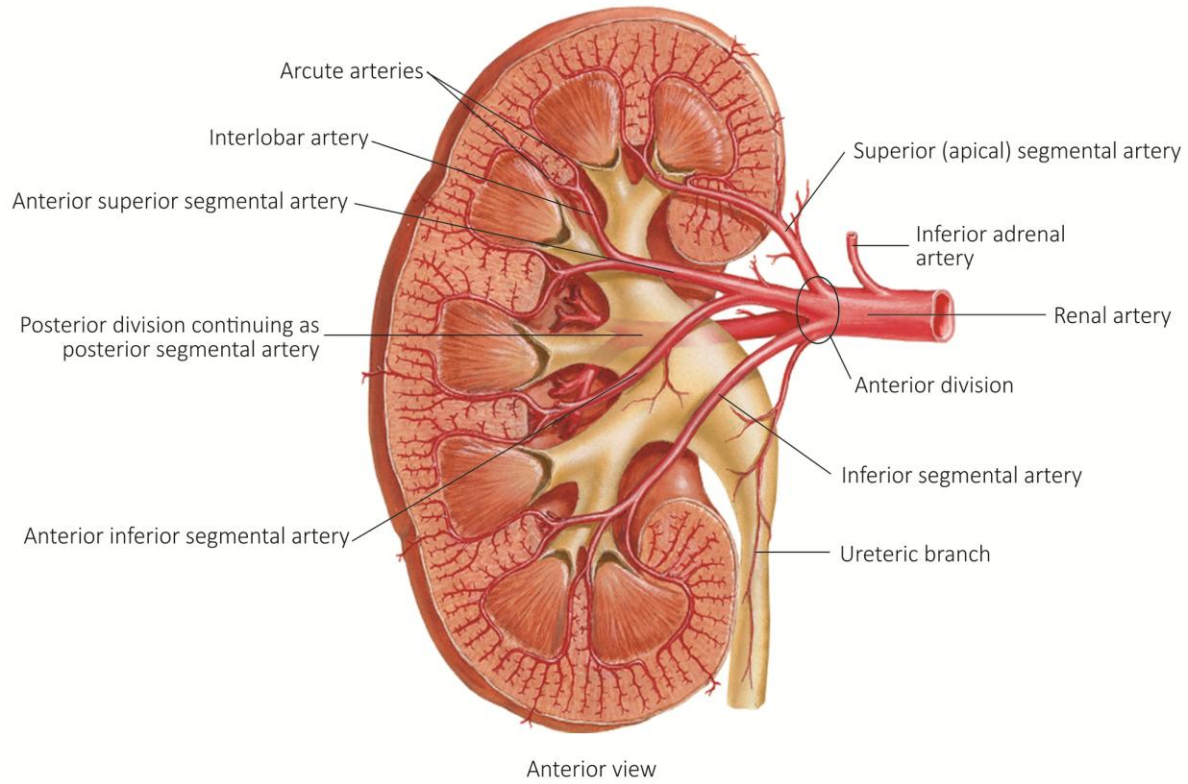


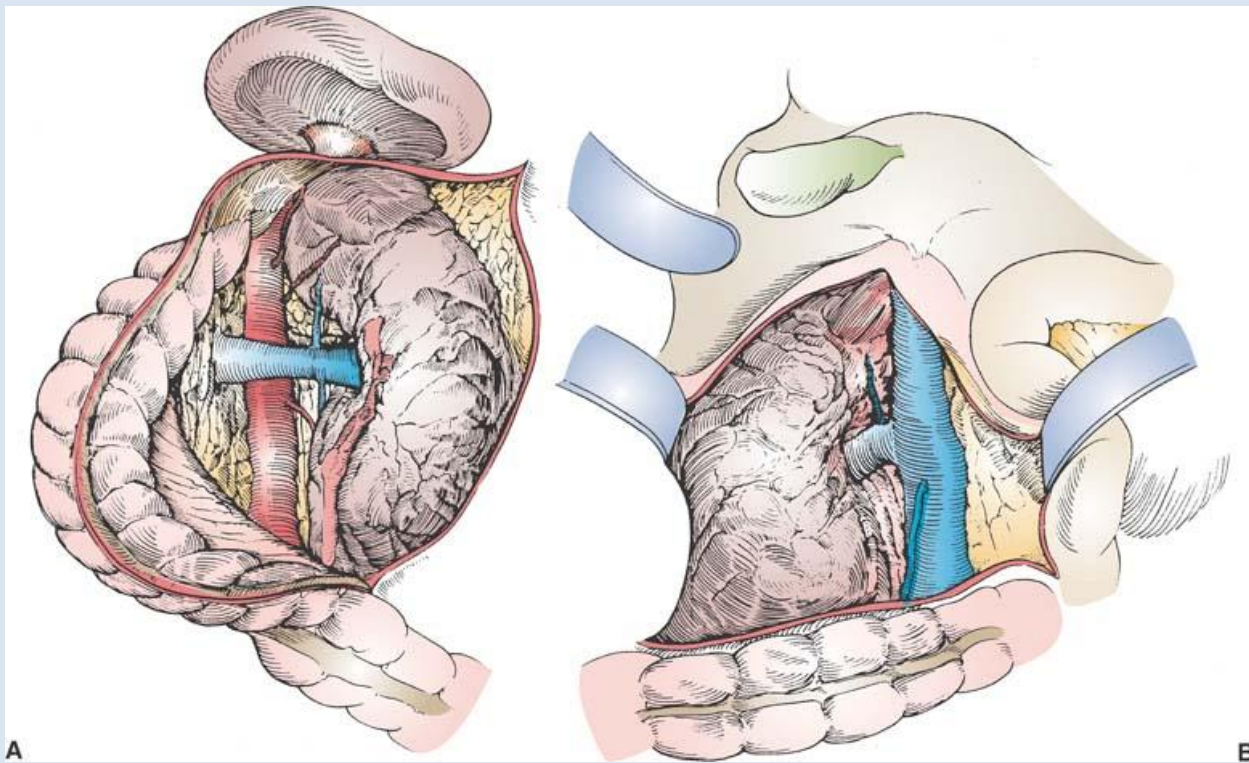
Figure 3-6. Renal blood supply and vascular segments. (Modified from *Netter Atlas of Human Anatomy*, 5th Edition. Philadelphia: Elsevier, 2010.)

OPEN NEPHRECTOMY

Nephrectomy should be in the tool kit of any general surgery resident as it is not infrequently encountered on the Trauma service. The most common scenario is a perinephric retroperitoneal (zone II) hematoma.

Procedure

- ☞ Perform left or right medial visceral rotation as discussed above to expose the renal vessels and Gerota's fascia on the side of the renal/renovascular injury



Scott-Connor CEH and Dawson DL. *Essential Operative Techniques and Anatomy*. Lippincott, Williams & Wilkins, Philadelphia. 2014

- ☞ Incise Gerota's fascia laterally and use your hand to elevate the kidney out of its bed
- ☞ Slide a vascular clamp across the pedicle to gain vascular control
- ☞ Palpate the contralateral kidney to assess its size and contour, and assess urine output after hilar clamping prior to nephrectomy
- ☞ Suture ligate the renal artery
- ☞ Tie off or suture ligate the renal vein
- ☞ Tie off the ureter
- ☞ Remove the resected kidney

ADRENAL (SUPRARENAL) GLANDS

Location and anatomic relations

The **right adrenal gland**, roughly pyramidal in shape, is located at the apex of the superior pole of the right kidney and lateral or posterolateral to the inferior vena cava (Figure 8-4, next page). The **left adrenal gland**, slightly longer and roughly crescent-shaped, is located on the anteromedial surface of the superior pole of the left kidney.

Organization

The paired **adrenal glands** consist of an outer **cortex** and an inner **medulla** (Figure 8-3). A thick collagenous **capsule** surrounds the adrenal cortex; connective tissue **trabeculae** extend from the capsule into the inner cortex.

Adrenal cortical cells produce mineralocorticoids, glucocorticoids, and sex hormones. The adrenal medulla consists of aggregations of **chromaffin cells** (pheochromocytes) embedded in a reticular meshwork and associated with venous sinusoids. Most chromaffin cells synthesize and store the catecholamines **adrenaline** (epinephrine); a smaller number of chromaffin cells synthesize and store **noradrenaline** (norepinephrine). Stimulation of chromaffin cells by **preganglionic sympathetic neurons** initiates catecholamine release into the venous sinusoids. Processes of preganglionic neurons from lower thoracic spinal cord segments reach the adrenal gland through a large **adrenal plexus** on the medial surface of the gland.

Development

Development of the adrenal cortex begins during the 5th week of development when the **fetal adrenal cortex** arises from coelomic epithelium medial to the urogenital ridge. The **definitive adrenal cortex** arises from a second wave of coelomic epithelial cells that surround the fetal cortex. The fetal cortex remains large until the second week of postnatal life, then undergoes progressive involution.

Development of the adrenal medulla occurs through migration of neural crest cells to the medial surface of the fetal adrenal cortex and subsequent differentiation of the neural crest cells into **chromaffin cells**. The **adrenal capsule** forms around the definitive adrenal cortex by the 9th week of development.

Small **accessory suprarenal glands**, consisting primarily of adrenocortical tissue, may be found in the perirenal fat surrounding the main adrenal glands and kidneys. **Cortical bodies** may also be found in the broad ligament of the uterus or spermatic cord. **Para-aortic bodies** (organs of Zuckerkandl) consist of aggregations of chromaffin cells associated with sympathetic ganglia around the aorta.

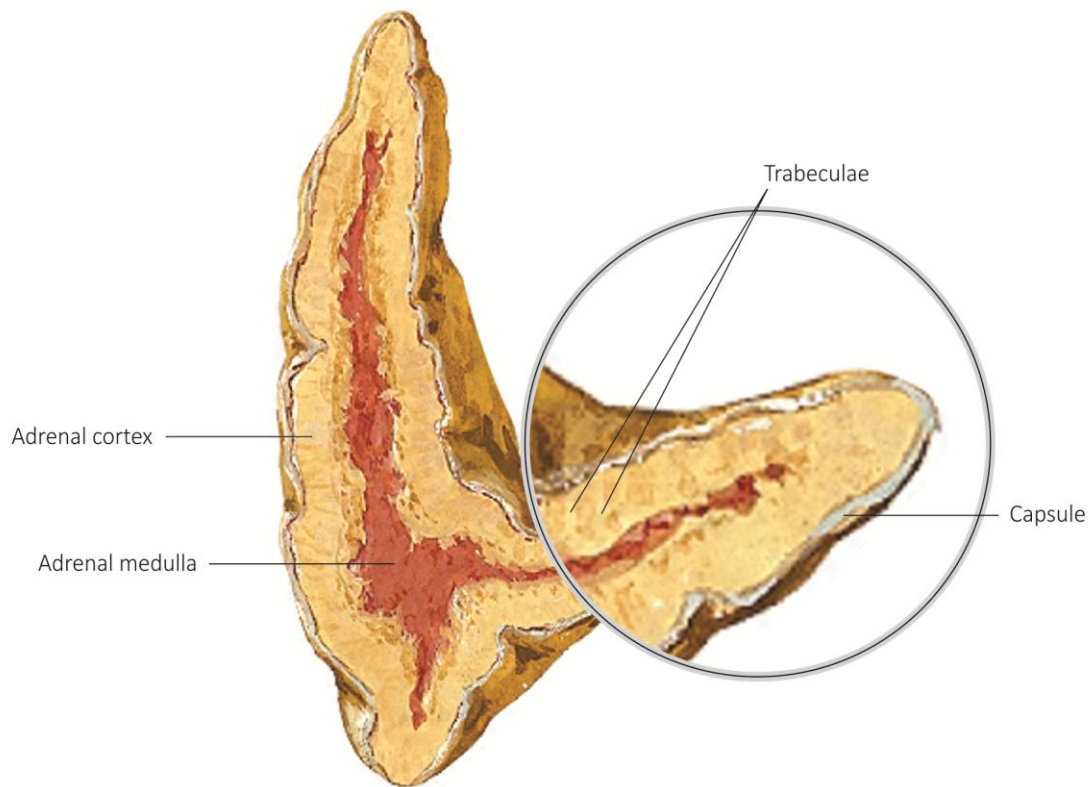


Figure 8-3. Organization of the adrenal gland. (Modified from *Netter Atlas of Human Anatomy*, 5th Edition. Philadelphia: Elsevier, 2010.)

Arterial supply and venous drainage

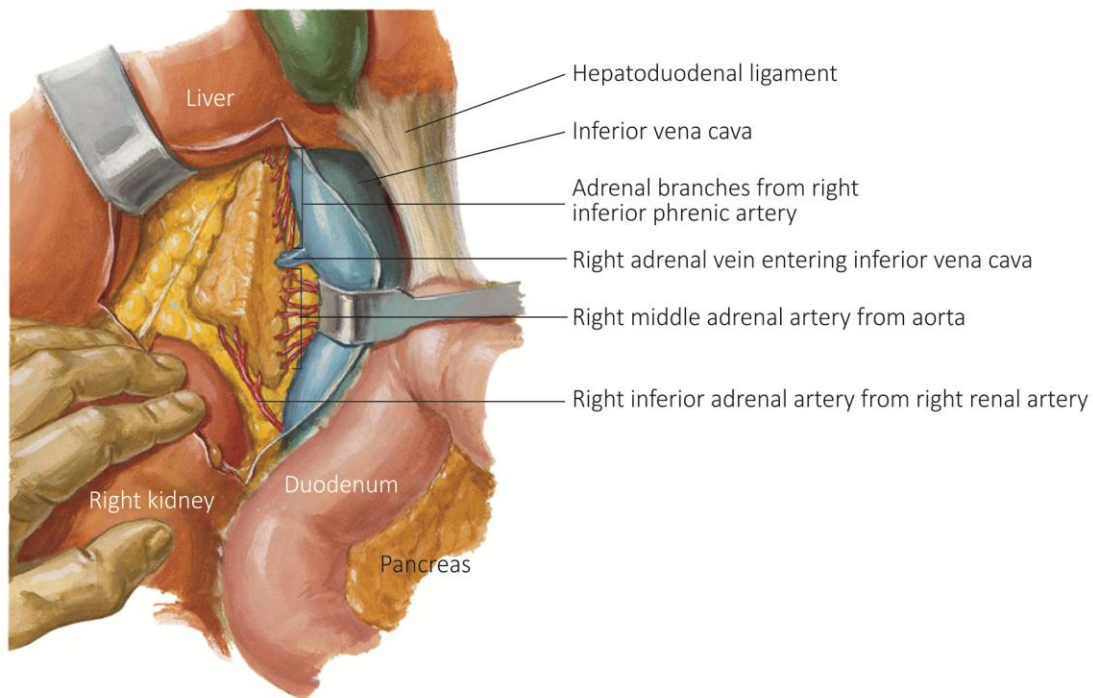
Although the adrenal vascular supply is variable, each adrenal gland is typically **supplied by three adrenal arteries**, and **drained by a single adrenal vein**. The **superior adrenal arteries reach the gland as multiple branches of the** inferior phrenic artery, the first branch of the abdominal aorta. The **middle adrenal artery** arises directly from the aorta, and the **inferior adrenal artery** arises from the renal artery. The **right adrenal vein** drains directly into the inferior vena cava. The **left adrenal vein** drains into the superior aspect of the left renal vein.

Lymphatic drainage

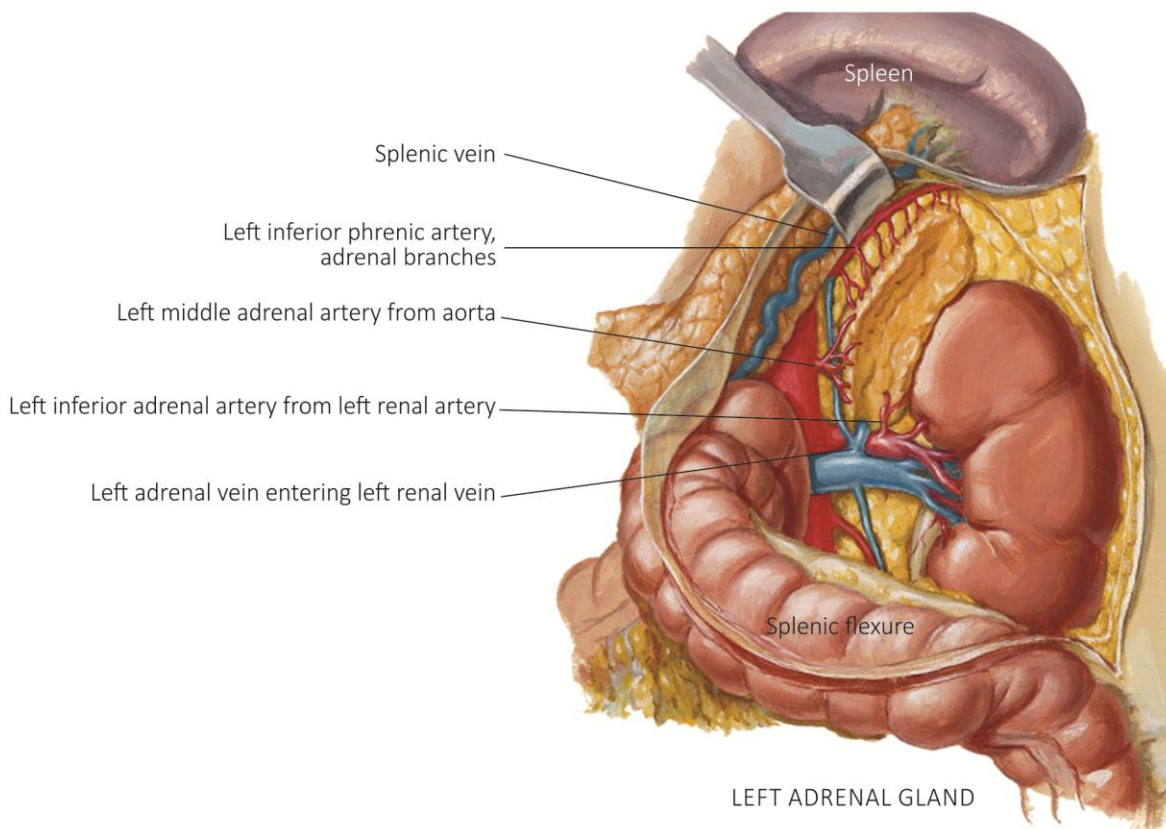
Lymph from both cortex and medulla drains to lymphatic vessels at the adrenal hilum and then to the para-aortic lymph nodes.

Innervation

Processes of preganglionic neurons from lower thoracic spinal cord segments reach the adrenal gland through a large **adrenal plexus** on the medial surface of the gland.



RIGHT ADRENAL GLAND



LEFT ADRENAL GLAND

Figure 8-4. Arterial supply and venous drainage of the right and left adrenal glands. (Modified from *Netter Atlas of Human Anatomy*, 5th Edition. Philadelphia: Elsevier, 2010.)

TRANSPERITONEAL RIGHT ADRENALECTOMY

The proximity of the right adrenal gland to the vena cava, and the drainage of the short right adrenal vein into the posterior surface of inferior vena cava, usually necessitate retraction of the vena cava to the left during right adrenalectomy. The right middle adrenal artery passes posterior to the inferior vena cava.

- ☞ Reflect the **hepatic flexure of the colon** inferiorly.
- ☞ Mobilize the duodenum. Identify the **inferior vena cava**.
- ☞ Divide the **right triangular ligament** and reflect the liver superiorly.
- ☞ By palpation, identify the **right kidney** and its superior pole and the **right adrenal gland**. Identify and open the **Gerota fascia** and expose the right adrenal gland. Mobilize the relatively avascular **lateral border** of the right adrenal gland.
- ☞ Identify the short **right adrenal vein** as it enters the posterior aspect of the inferior vena cava. Secure the right adrenal vein.
- ☞ Identify the **right inferior phrenic artery and its small superior adrenal branches**. Identify the **middle adrenal artery** arising from the aorta and usually passing posterior to the inferior vena cava. Identify the inferior adrenal artery arising from the right renal artery.
- ☞ Secure small arterial branches and remove the right adrenal gland. Identify adjacent para-aortic lymph nodes.