

The QT Interval in Clinical Practice

SECTION 1: The History of Cardiac Electrophysiology and the ECG

The first section of The QT Interval in Clinical Practice will review human cardiac electrophysiology as measured by the surface electrocardiogram or ECG (abbreviated as EKG from the German spelling).


We will also review the primary deflections in the ECG - that is, the P, Q, R, S and T waves. Finally, we will review the primary ECG intervals or segments of the tracing - the PR & QRS - and lastly, the QT and JT intervals.

First Electrocardiograms:

Electrocardiography is not a new field of medicine. It began in the 19th century when physiologists and physicians recognized that the beating heart generates an electrical field that changes during each contraction of cardiac muscle and which can be recorded and displayed.

In 1895, the Dutch physician, Willem Einthoven, coined the term “electrocardiogram” for his recordings of the heart’s electrical field. He assigned labels for the major deflections on the tracings as P, Q, R, S and T. In 1901, he made the first **practical** ECG recordings from humans, using a galvanometer, shown next.

Early Electrocardiogram – 1912:




As you can see, “practical” may be an over-statement. This early drawing shows the type of equipment that was required to obtain these first ECG tracings. To capture the signal, the subject or patient had to immerse each arm and one foot in buckets of a saline solution in order to detect the heart’s electrical signal that reached the skin.


100 Years of Progress:

The massive instrument from 1912 has now been replaced with much smaller devices. Among the smallest is the one shown in the top right panel that has only two sensing pads and is the size of a credit card. It captures and transmits the ECG signal to a mobile device such as a smartphone. There the ECG can be analyzed, displayed and further transmitted by email. Also, smart watches, shown on the lower right, can monitor ECG signals. These devices are now marketed to clinical practitioners as well as to consumers who may wish to monitor their ECGs.

1912

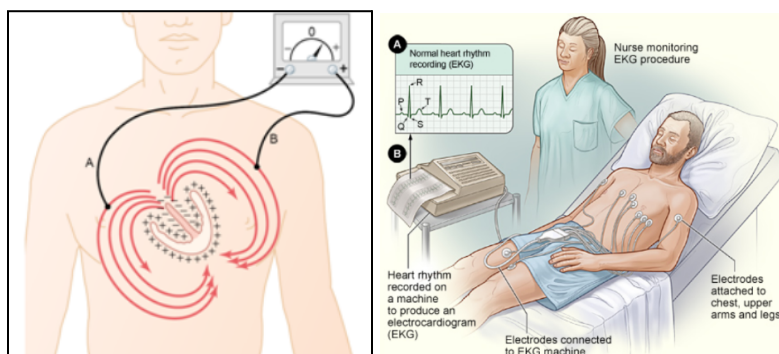


2022



Modern Diagnostic 12-Lead ECG:

The medical standard for diagnostic electrocardiography is the 12-lead ECG, as shown at the right below.



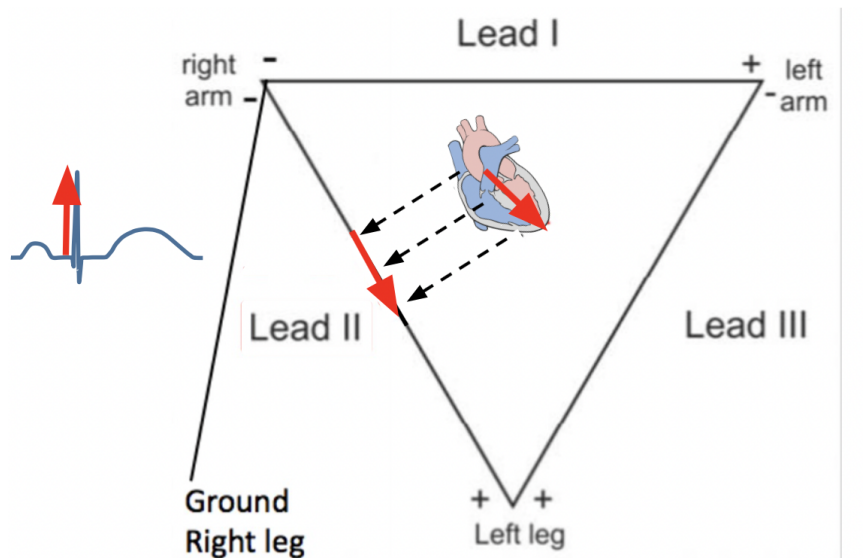
The panel on the left is a schematic drawing showing the heart muscle as it contracts and generates waves of electrical activity. The concentric red lines represent the electrical fields that are generated by the electrical charge as it moves through the heart muscle to the thorax, eventually reaching the surface of the body. The meter represents how this electrical field can be detected on the skin. In this schematic, the two wires form a “one lead” recording.

The right panel displays the use of a modern 12-lead ECG recording instrument. Ten specially designed metal electrodes are placed in contact with the skin at standard locations. An electrode is placed on each arm and leg and in each of six standard positions that span the left side of the chest. Preferably, the patient should be supine and at rest for at least five minutes before the ECG is recorded. This standard 12-lead ECG instrument simultaneously records the electrical potential across twelve different paired combinations of the ten electrodes, hence the term 12-lead ECG.

Einthoven's Triangle:

A full explanation of the biophysics of ECGs is beyond the scope of this presentation, however an understanding of how the signals are recorded can help one to understand how to interpret ECG tracings.

All modern ECGs are standardized according to what is known as Einthoven's triangle, shown here.



The upper corners of the triangle are equivalent to the electrodes on the right and left arms. The lower corner of the triangle is defined as the electrode on the patient's left leg. All measurements of electrical potential across each pair of electrodes are termed bipolar. By convention, "Lead I" is a recording of the electrical potential across the two electrodes placed on the left arm (positive) and right arm (negative). "Lead II" records from the electrodes on the right arm and the left leg and "Lead III" records from the left arm relative to the left leg.

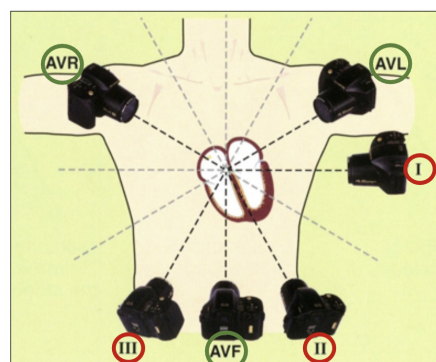
An important electrocardiographic concept is that of the "vector" which is a measure of the direction and magnitude of an electrical potential at any point in time. For example, when an electrical wave crosses the AV node and moves into the ventricles of the heart it travels in a downward and leftward direction.

The red arrow in the center of the triangle depicts the vector for the direction of movement of a depolarizing wave passing through the heart - in this case, traveling down the ventricular septum. The magnitude of the electrical potential is shown by the length of the arrow. It is important to understand that the signal recorded on the skin for each of the leads will be slightly different because each will be influenced differently by how efficiently they move through the person's body to reach different points on the skin.

One way to think of a vector is as if it were a "shadow" of the electrical event that is reflected in each direction to the body surface. The Lead II ECG tracing on the left side here shows a red upward arrow that corresponds to the part of the signal from the initial septal depolarization.

Limb Leads: Record 6 "Views":

Using the signals from the four limb electrodes, the ECG instrument calculates and displays the conventional bipolar leads I, II and III as marked in red circles and the ECG machine can calculate three additional unipolar leads. These three are called the "augmented" leads - as marked in green circles (aVR, aVL and aVF for right arm, left arm and foot).



As shown in the drawing, these six limb leads are equivalent to continuously recording six “snapshots” of the electrical signal taken from different angles, all in the vertical plane of the person’s torso.

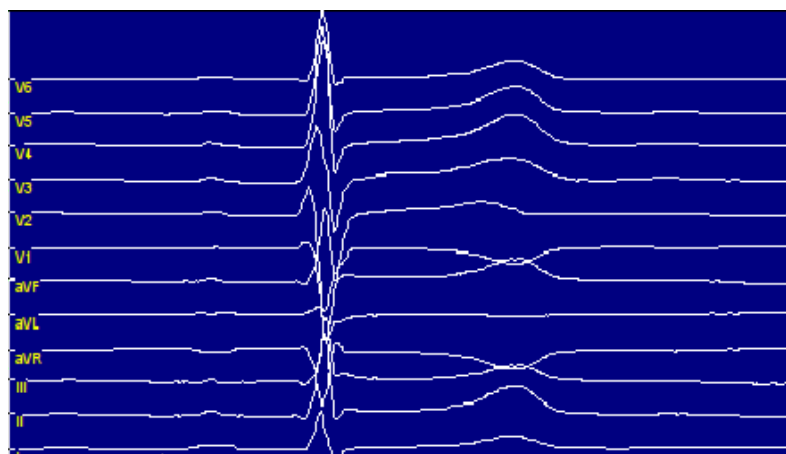
Chest Leads: Record “Transverse” Plane:

In order to examine the heart’s electrical activity recorded from the horizontal plane (aka transverse or axial), six additional unipolar leads, referred to as “chest or precordial leads” (designated V_1 through V_6), are recorded from electrodes placed on the anterior and left anterolateral chest wall. These sites were chosen because of their close proximity to the major mass of heart muscle and because they have been found to provide useful information that is not always found in the limb or augmented leads - for example, in patients with heart attacks, these leads can help identify which coronary artery may have become occluded and caused the heart attack.

In summary, the standard 12-lead ECG records 6 limb leads (3 bipolar and 3 augmented) and 6 unipolar precordial leads.

Each ECG Lead is Different:

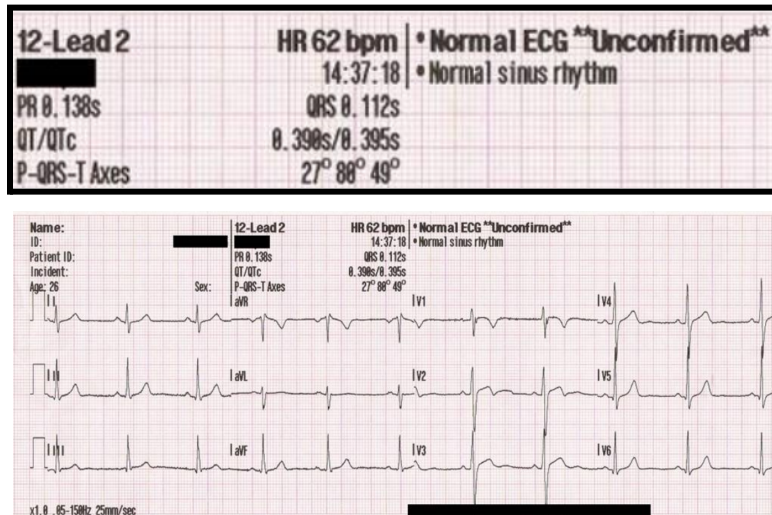
Here is a screenshot from an advanced ECG system that can align simultaneous signals from all of the twelve leads for each heartbeat.



This shows the substantial differences in the waveforms for the twelve different leads that are caused by the different “silhouettes” detected at different electrodes placed on the skin.

Standard 12-Lead ECG Report:

This is a printed copy of a standard 12-lead ECG. Most ECG instruments adhere to this standardized format for display of the data.



First, it is important to notice in the lower left corner that the recording was made at a paper speed of 25 mm/sec and a sensitivity of 5 mm/mV. This is the convention for displaying most ECGs but it can be changed to record at faster paper speeds or greater electrical sensitivity if one seeks to amplify the tracing and increase the accuracy of visual measurements.

Reading from left to right and top to bottom, three sets of leads are shown, starting with I, II and III followed by aVR, aVL, aVF, then V₁, V₂, V₃, and on the far right, V₄, V₅, V₆. Many instruments will also display an additional longer tracing across the bottom of the page as a “rhythm strip” (customarily Lead II). As the name implies, this longer strip is used to facilitate analysis of the overall heart’s rhythm.

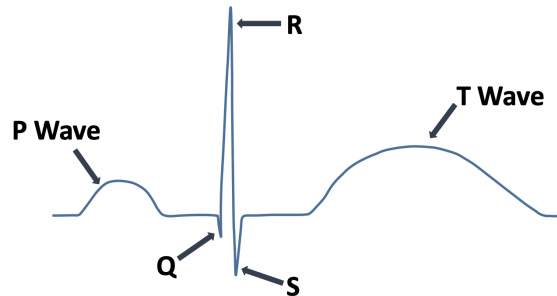
Most ECG manufacturers include in the instrument computer programs that can make an initial machine-generated interpretation for the report. Almost all instruments calculate the heart rate and selected intervals such as PR, QRS and QT. Many instruments print a machine-generated initial diagnostic interpretation for the clinician to consider and verify or edit.

In this example, the machine’s interpretation is “normal ECG” but it is labeled “unconfirmed” to indicate the need for interpretation by a qualified ECG diagnostician. Also, many instruments can be customized and allow the user to select what information is to be displayed. Most large

ECG systems in use today will also send the report to a central data storage center for a cardiologist to review and make the final interpretation for the medical record.

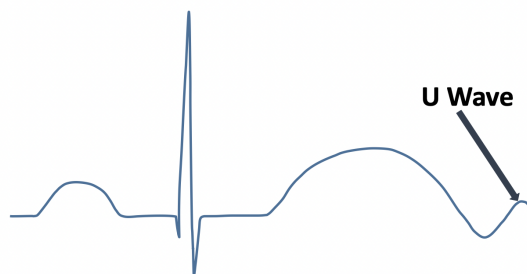Major ECG Deflections:

This chart shows a typical Lead II tracing obtained from a normal heartbeat.



The beat has a series of deflections that Einthoven named P, Q, R, S and T. The P deflection or P wave is generated by the electrical depolarization of the atria. The next three deflections (Q, R and S) are generated by depolarization of the ventricles and are combined to form the QRS complex. Depending on the individual and the lead being recorded, the Q or S waves may be very small or perhaps not present. The T wave represents repolarization of the ventricles. Atrial repolarization is small and not normally visible in surface recordings.

This chart shows an additional deflection, the “u” wave.



U waves are often not visible, but if present they are usually more likely seen in the precordial leads. There has been extensive debate about the origin and significance of the u wave but that is a topic beyond the scope of this presentation. Importantly, when present, the u wave can make the identification of the **end** of the T wave difficult and will be discussed in subsequent slides.

Major ECG Intervals/Segments:

There are several important intervals within the P, Q, R, S and T to consider when interpreting the ECG.

The PR interval is the time required for the electrical signal to move through the atria and AV node to reach the ventricles. In some cases, the PR is actually a “PQ” interval but it is usually still referred to as the PR interval.

The QRS duration is the time from the start of the Q wave (or R wave if a Q wave is not present) to the end of the S wave (also called the J point). The time from the earliest deflection of the QRS complex to the end of the T wave is called the QT interval.

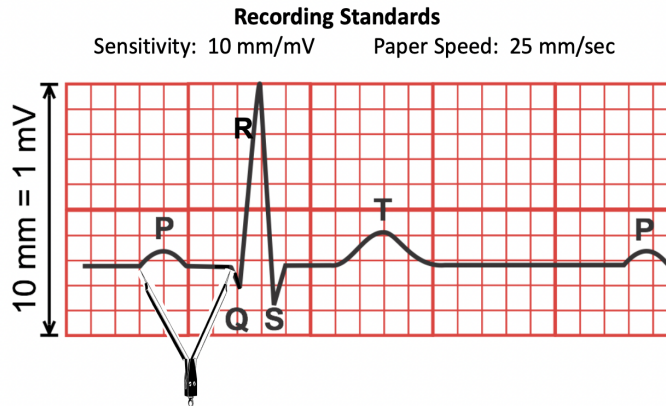
The PR interval is normally from 120 to 200 msec in duration. The QRS duration is normally from 60 to 110 msec. Durations of 120 msec or more are considered abnormally prolonged.

It is important to know that the duration of the QT interval is influenced by the heart rate and, as will be discussed, the QT interval shortens at faster heart rates. The normal QT interval is also influenced by the person’s age, biological sex and many other factors which will be discussed in forthcoming segments.

Measuring Intervals:

ECG analysis includes careful calculation of these intervals and this analysis begins with verification of the paper speed and the sensitivity of the recording. As mentioned earlier, ECG recordings are normally made at a paper speed of 25 mm/sec and with a sensitivity of 10 mm/mv. Faster paper speeds or higher sensitivity can be used to amplify signals and facilitate the accuracy of manual measurement of intervals.

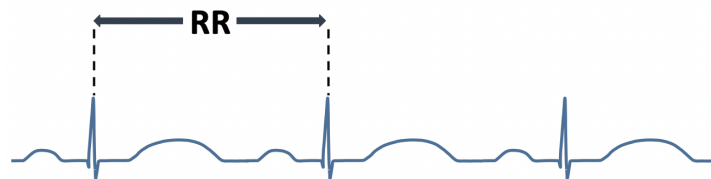
Standard ECG paper has a 1 mm square grid (often termed the small boxes) and is overlaid with a more bold 5mm grid (often termed big boxes). At a paper speed of 25 mm/second, each second in time recorded horizontally is either 5 large boxes or 25 small boxes in length. Therefore, each small, 1 mm box horizontally is equivalent to 40 msec and each large box horizontally is 200 msec in duration.



For example, in this tracing, the PR (or PQ) interval is ~3.75 small boxes in length. This means that the PR interval is (3.75 x 40 msec) or 150 msec, a value within the range of normal. As shown in the chart, these measurements are usually made using mechanical calipers, sometimes even using a magnifying glass. Electronic calipers and digital methods are often used to speed up measurements and increase their accuracy.

Measuring Heart Rate:

Heart rate is measured in beats (or cardiac cycles) per minute but ECG tracings are often no longer than a few seconds, so if the heart rate appears to be stable, it is more practical to simply measure the intervals between two or more beats and convert that value to beats per minute using either the first equation which has the RR interval measured in mm, or the second equation in which the RR interval has been converted to seconds.



$$\text{Heart Rate} = 1500/\text{RR (in mm)}$$

$$\text{Heart Rate} = 60/\text{RR (in seconds)}$$

This is the end of Section 1 and we hope you will proceed to the next section which discusses How to Accurately Measure the QT Interval.