

PECTUS EXCAVATUM

Citation for published version (APA):

de Loos, E. R. (2022). *PECTUS EXCAVATUM: improvements in surgical care*. [Doctoral Thesis, Maastricht University]. Ridderprint. <https://doi.org/10.26481/dis.20220407el>

Document status and date:

Published: 01/01/2022

DOI:

[10.26481/dis.20220407el](https://doi.org/10.26481/dis.20220407el)

Document Version:

Publisher's PDF, also known as Version of record

Please check the document version of this publication:

- A submitted manuscript is the version of the article upon submission and before peer-review. There can be important differences between the submitted version and the official published version of record. People interested in the research are advised to contact the author for the final version of the publication, or visit the DOI to the publisher's website.
- The final author version and the galley proof are versions of the publication after peer review.
- The final published version features the final layout of the paper including the volume, issue and page numbers.

[Link to publication](#)

General rights

Copyright and moral rights for the publications made accessible in the public portal are retained by the authors and/or other copyright owners and it is a condition of accessing publications that users recognise and abide by the legal requirements associated with these rights.

- Users may download and print one copy of any publication from the public portal for the purpose of private study or research.
- You may not further distribute the material or use it for any profit-making activity or commercial gain
- You may freely distribute the URL identifying the publication in the public portal.

If the publication is distributed under the terms of Article 25fa of the Dutch Copyright Act, indicated by the "Taverne" license above, please follow below link for the End User Agreement:

www.umlib.nl/taverne-license

Take down policy

If you believe that this document breaches copyright please contact us at:

repository@maastrichtuniversity.nl

providing details and we will investigate your claim.

PECTUS EXCAVATUM
improvements in surgical care

Erik de Loos

© Erik de Loos, Cadier en Keer, 2022

No part of this book may be reproduced or transmitted in any form or by any means, without prior permission in writing by the author, or when appropriate, by the publishers of the publications.

Cover design: Stephanie Phillippaerts | Medical-illustration

Layout: Publiss, the Netherlands

Printing: Ridderprint, the Netherlands

ISBN: 978-94-6458-003-7

Publication of this thesis was financially supported by:



PECTUS EXCAVATUM

improvements in surgical care

PROEFSCHRIFT

ter verkrijging van de graad van doctor aan de Universiteit Maastricht,
op gezag van de Rector Magnificus, prof. dr. Pamela Habibović
volgens het besluit van het College van Decanen,
in het openbaar te verdedigen
op donderdag 7 april 2022 om 13:00 uur

door

Erik Robert de Loos
geboren op 2 februari 1980
te Pijnacker

Promotor

Prof. dr. J.G. Maessen

Copromotoren

Dr. Y.L.J. Vissers (Zuyderland medisch centrum)

Dr. K.W.E Hulsegewé (Zuyderland medisch centrum)

Beoordelingscommissie

Prof. dr. N.D. Bouvy (voorzitter)

Prof. dr. W.G. van Gemert

Prof. dr. P.R. De Leyn (UZ Leuven, België)

Prof. dr. M. Poeze

Dr. W.P. Zuidema (Amsterdam UMC)

Table of contents

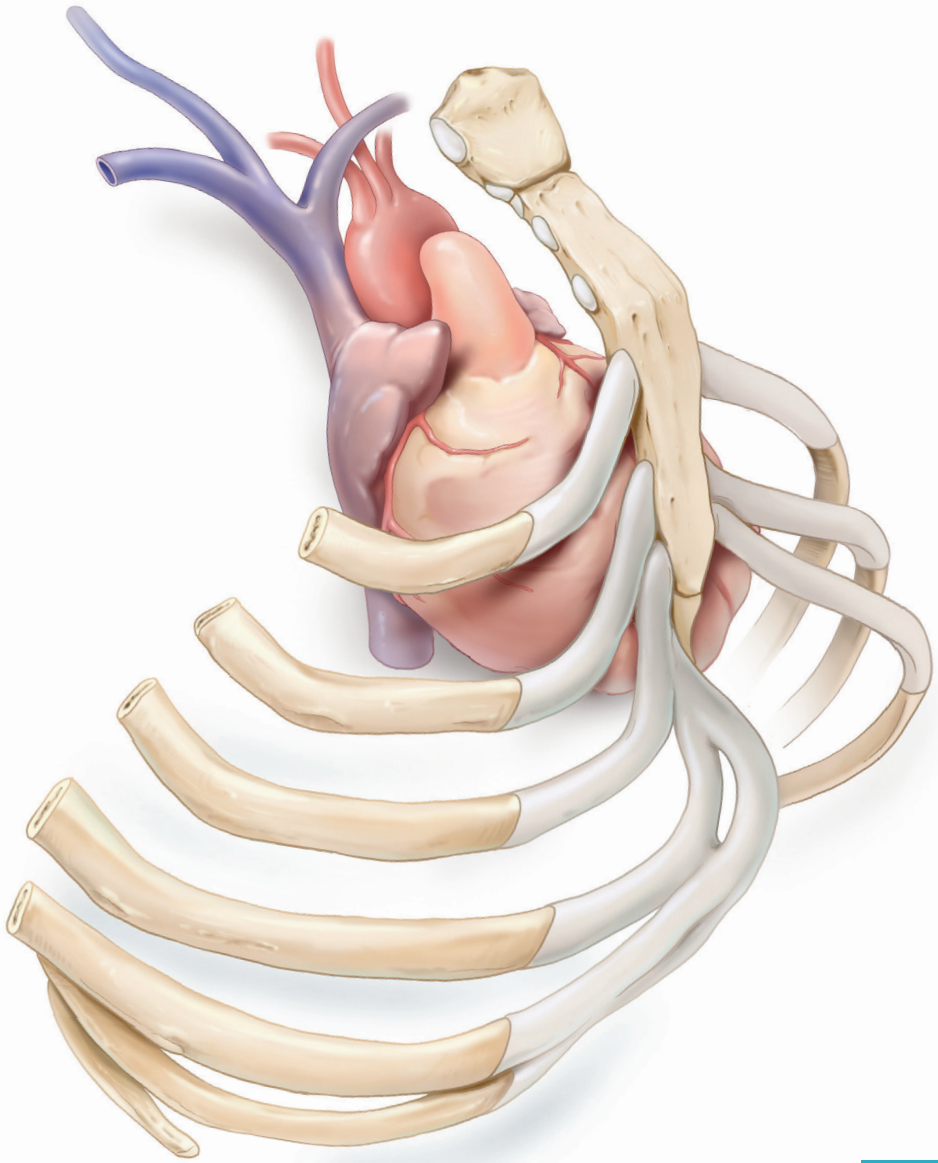
Chapter 1	General introduction and thesis outline	7
Chapter 2	Visual diagnosis of pectus excavatum: an inter-observer and intra-observer agreement analysis	23
Chapter 3	Minimally invasive repair of pectus excavatum by the Nuss procedure: the learning curve	41
Chapter 4	Nuss procedure for pectus excavatum: a comparison of complications between young and adult patients	65
Chapter 5	Sternal elevation by the crane technique during pectus excavatum repair: a quantitative analysis	81
Chapter 6	Intercostal nerve cryoablation versus thoracic epidural for postoperative analgesia following pectus excavatum repair: a systematic review and meta-analysis	101
Chapter 7	Does the use of locking plates or mesh and wires influence the risk of symptomatic non-union of the sternal osteotomy after modified Ravitch?	129
Chapter 8	Safety and feasibility of rigid fixation by SternaLock Blu plates during the modified Ravitch procedure: a pilot study	145
Chapter 9	Suture anchor repair of pectoralis major muscle dehiscence after modified Ravitch	159
Chapter 10	General discussion and future perspectives	167
Chapter 11	Summary	183
	Samenvatting	188
Chapter 12	Impact paragraph	193
Chapter 13	Dankwoord	199
Chapter 14	About the author	213
	List of publications	214
	Curriculum vitae	221

Adapted from:

De Loos ER, Höppener PF, Busari JO, Kragten JH, Hulsewé KWE, Vissers YLJ.

Pectus excavatum, not just a cosmetic problem.

Ned Tijdschr Geneeskd. 2020;164:D4509.



1

General introduction and thesis outline

GENERAL INTRODUCTION

Pectus excavatum, also known as funnel chest, is a common anterior chest wall disorder which negatively affects patients' well-being. Unfortunately, the general knowledge on this condition is still limited, even among health care professionals. This is best illustrated by the prevailing idea that pectus excavatum mainly leads to cosmetic complaints. Although this disorder could indeed elicit a major negative influence on the patients' self-image with corresponding psychosocial consequences, it is also frequently associated with physical and cardiopulmonary impairment.

Pectus excavatum has many phenotypes which require different strategies for evaluation and treatment. As a brief introduction, four patient cases illustrative for the diversity of pectus excavatum will be discussed. All patients consented for the use of their images.

Patient A is a 17-year-old male drama school student. The patient has a history of funnel chest since childhood. Over the past years, he experienced an increasing psychosocial burden, expressed by a diminished body image and shame in public places such as swimming pools. During physical examination, pectus excavatum with thoracolumbar kyphosis and protruding cartilage of the lower costal margins (i.e., "flaring", Figure 1) was observed. The associated Haller index was 2.6 on two-view plain radiographs. The external impression was 14 millimeters (Figure 2). Both conservative treatment with physiotherapy and posture advices, and operative correction were discussed as possible interventions. The patient and his parents opted for surgical treatment. Minimally invasive repair of pectus excavatum (MIRPE) by the Nuss bar procedure was performed. The postoperative course was uneventful. The patient was satisfied with the final result (Figure 3) and expressed subjective improvement of his social-emotional status. After 3-year follow up, the Nuss bar was removed.

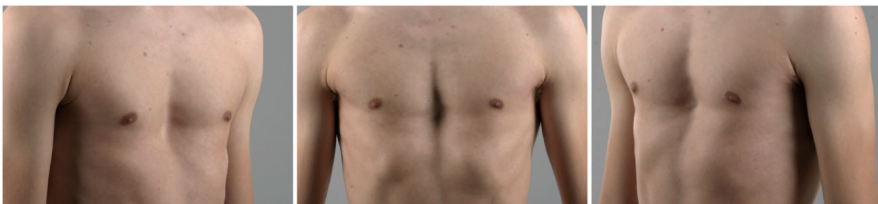


Figure 1: Patient A. Cup-shaped pectus excavatum with flaring, preoperative situation.

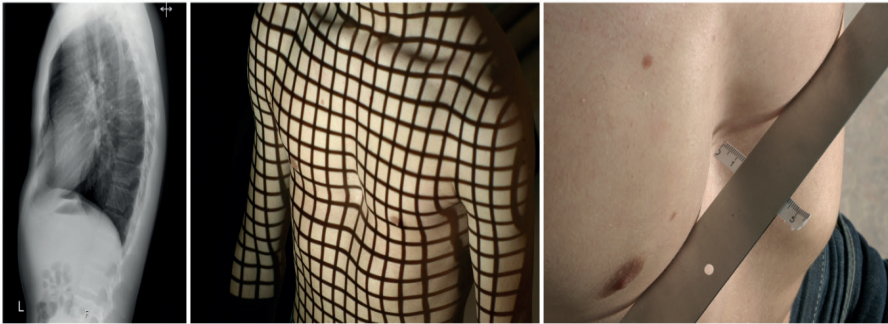


Figure 2: Patient A. Preoperative lateral plain chest radiograph, 3D grid stereogram and analogous measurement of external pectus depth.

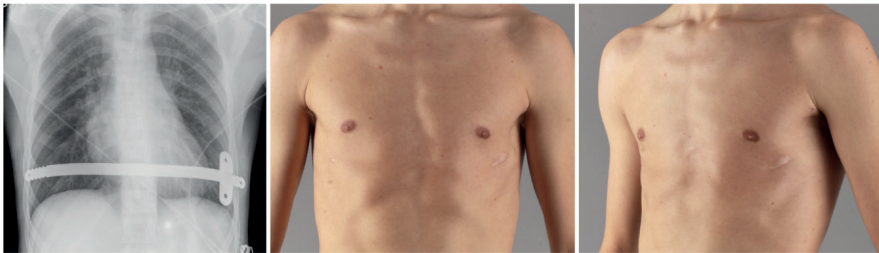


Figure 3: Patient A. Postoperative anteroposterior chest radiograph and result after MIRPE.

Patient B is a 20-year-old young man with a pectus excavatum and autism spectrum disorder. He suffered from idiopathic exercise intolerance, mainly while playing soccer, and was initially managed conservatively by an orthopedic surgeon. Via an extensive web search, the patient eventually linked his complaints to pectus excavatum, whereupon he requested his general practitioner for referral to our center. During clinical examination, a cup-shaped asymmetric pectus excavatum was visible (Figure 4). No other postural distortion was observed. A computed tomography (CT) scan of the chest was obtained, revealing a severe pectus excavatum (Haller index 3.6) with cardiac compression due to the posteriorly displaced sternum. The external pectus depth was 20 millimeters (Figure 5). After shared decision making, operative repair was scheduled. The deformity was corrected by the Nuss bar procedure (Figure 6). Following surgery, exercise tolerance substantially improved. After a prosperous recovery and uneventful course, the bar was removed after 3 years. To date, the patient is completely free of complaints and able to exercise without limitations.

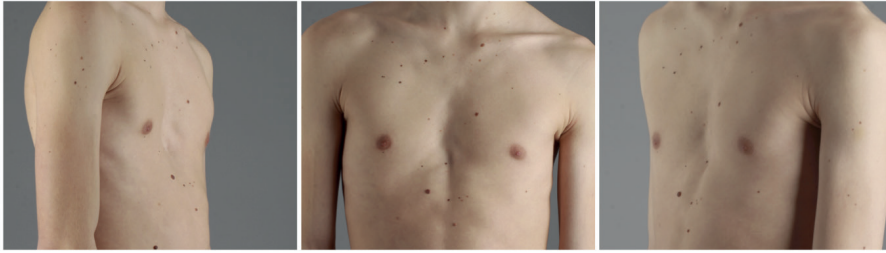

Figure 4: Patient B. Cup-shaped pectus excavatum with asymmetry of rib cartilage, preoperative situation.




Figure 5: Patient B. Preoperative CT, 3D grid stereogram and digital measurement of external pectus depth.

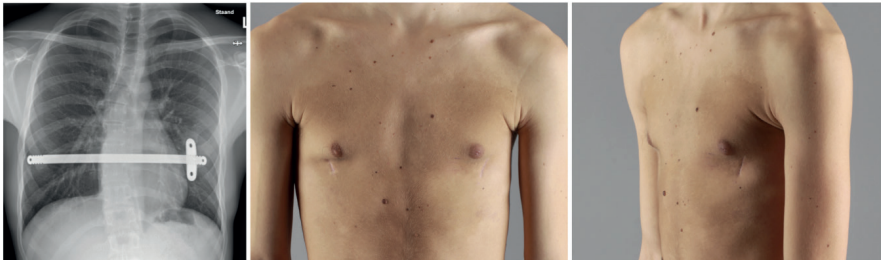

Figure 6: Patient B. Postoperative anteroposterior chest radiograph and optical result after MIRPE.

Patient C, a 39-year-old fire fighter, has a history of pectus excavatum since adolescence. During the last years, he experienced progressive anterior chest pain which was provoked by bending over. He had strong feelings of shame, hindering social contacts. During physical examination, a severe pectus excavatum was revealed (Figure 7), with a prominent xiphoid process, painful on palpitation. On CT, a deep pectus excavatum (Haller index 3.0) with sternal and xiphoidal tilt was observed (Figure 8). Subsequent cardiac magnetic resonance

imaging (MRI) demonstrated right ventricular compression, without valve abnormalities. The measured external pectus depth was 35 millimeters. Considering the patient's high chest wall rigidity associated with age, it was decided to perform an open repair by the modified Ravitch procedure. The postoperative recovery was uneventful, and the patient was contented with the cosmetic result (Figure 9). Moreover, physiologic symptoms resolved. He resumed work and sports activities.

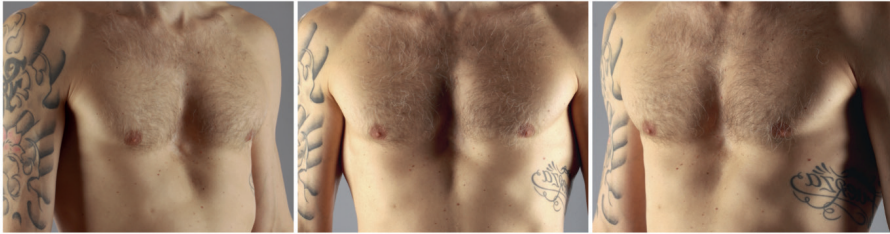

Figure 7: Patient C. Pectus excavatum, preoperative situation.

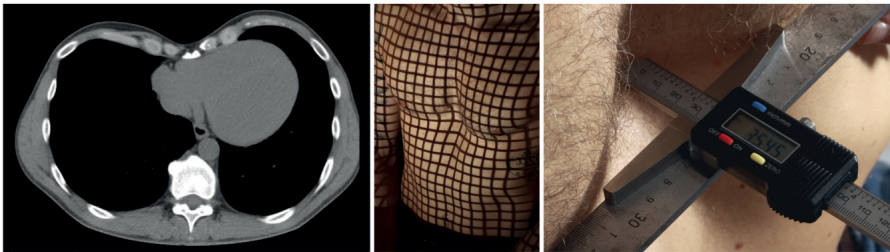


Figure 8: Patient C. Preoperative CT, 3D grid stereogram and digital measurement of external pectus depth.

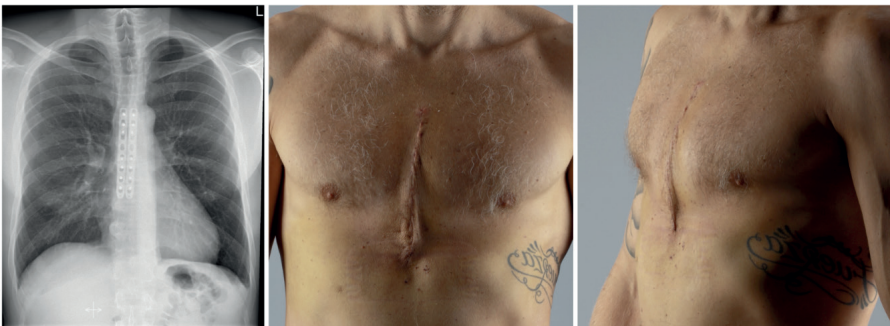


Figure 9: Patient C. Postoperative anteroposterior chest radiograph and optical result after modified Ravitch.

Patient D, a 27-year-old female law student initially visited the outpatient department of plastic surgery with a request for breast augmentation. The consulting plastic surgeon noted a dysmorphic chest with hypoplastic breasts and pectus excavatum, referring her for correction of the chest wall deformity first. During anamnesis, the patient complained of frequent palpitations and exercise intolerance. Inspection confirmed the plastic surgeon's findings and moreover revealed asymmetry of the rib cartilage (Figure 10). On chest CT, cardiac compression by the posteriorly displaced sternum was present with a Haller index of 2.6 (Figure 11). A successful Nuss procedure was performed. Upon recovery, a breast augmentation was performed by the plastic surgeon. After 3 years, the Nuss bar was explanted (Figure 12). The patient was satisfied with the cosmetic result and noted that her general condition had improved, and palpitations had been absent after surgery.

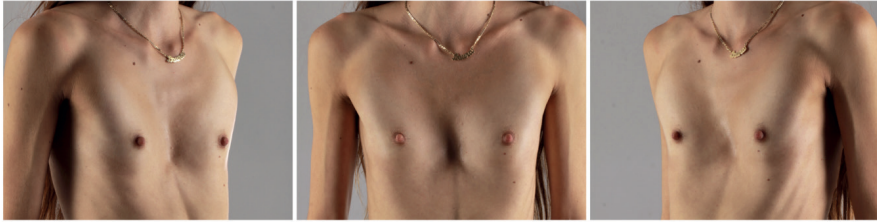

Figure 10: Patient D. Saucer-shaped pectus excavatum with breast hypoplasia, preoperative situation.

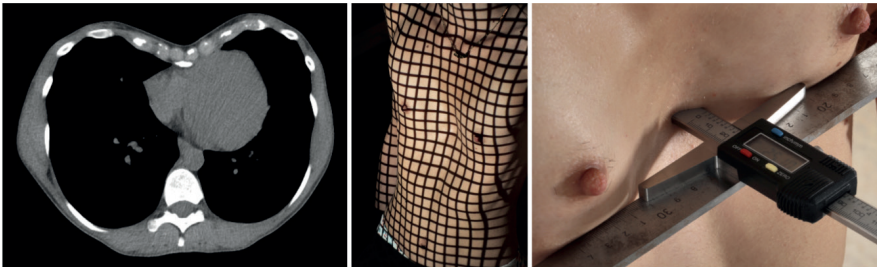

Figure 11: Patient D. Preoperative CT, 3D grid stereogram and digital measurement of external pectus depth.

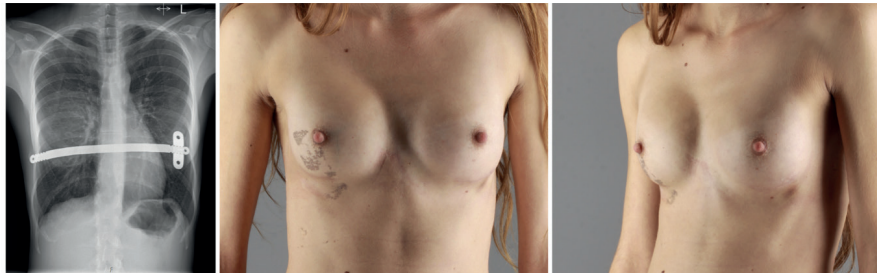


Figure 12: Patient D. Postoperative anteroposterior chest radiograph and optical result after MIRPE and breast augmentation.

Pectus excavatum

Pectus excavatum is the most common congenital chest wall deformity [1]. In popular terms, the condition is also referred to as sunken chest syndrome, cobbler's chest, or funnel chest. It occurs in 1:300-400 live births [2] of whom the majority are male [3]. Moreover, pectus excavatum is a progressive disorder with typical rapid aggravation during puberty and has a familiar predisposition. In 10-40% of cases, two or more family members are affected. Pectus excavatum is associated with connective tissue disorders such as Marfan and Ehlers-Danlos syndrome [4]. Marfan syndrome or marfanoid phenotype symptoms are present in approximately 15% of patients with a funnel chest [5].

Pathophysiology of pectus is caused by a growth disturbance of the rib cartilage [4]. Due to an aberrant growth pattern, progressive dorsal displacement of the sternum occurs, commonly accompanied by sternal tilt or torsion. This results in a typical, often asymmetrical, indentation of the anterior chest wall. In most patients, there is an accompanying excessive growth of the 8th to 10th rib causing anterior prominence of the lower costal margin as seen in Patient A. This phenomenon is referred to as winging or flaring. Pectus excavatum is also associated with posture distortions or deformities such as kyphoscoliosis. In females, hypoplastic breast growth can occur, as observed in Patient D. The extent and depth of the excavation varies amongst patients.

Pectus excavatum can be asymptomatic, but often results in a variety of complaints. These can be of cosmetic, psychosocial, or physical origin. Regarding the latter, due to the posterior sternal displacement, cardiac compression or deviation frequently occurs. Compression most often affects the right ventricle, and the right atrium to a lesser extent. Deviation often concerns a leftward displacement of the heart. This results in a functional compromise, causing symptoms as dyspnea and palpitations [6, 7]. Patients with pectus excavatum are often complaint-free in rest, but experience exercise intolerance compared to peers. Moreover, some patients notice a decline in endurance from the age of 40 to 50 years. Symptoms at a later age are caused by a decline in flexibility of the chest wall, decreasing the heart's capability to rotate and increasing the pressure on the right ventricle [8]. Finally, this can result in heart valve disease and heart failure, which however seldomly occurs.

Cosmetic and psychosocial consequences of pectus excavatum are frequently underestimated. Patients with a funnel chest often have a disturbed body image, and lowered body esteem. This results in a negative self-image, and decrease in quality of life and self-confidence [9].

Referral

Analysis and treatment are not indicated in every patient with pectus excavatum, especially not in young children. Referral to a specialized center is usually advised from the age of 10 years among patients suffering from pectus related cosmetic burden, exercise intolerance or those with a severe pectus. Conservative treatment is usually more successful at younger age. Moreover, surgical correction is easier (due to lesser chest wall rigidity) and the post-operative course smoother than in older patients.

Analysis

Pectus excavatum is a clinical diagnosis, in which the typical indentation of the anterior chest wall is easily recognized. The deformity can be present in a variety of shapes and severity. A frequently used morphological subdivision is that of Cartoski and colleagues, who describe deformities such as cup-shaped and saucer-shaped ones [10]. Another commonly used division is that of Park et al., who describe the deformities according to their (a)symmetry, encompassing terms as Grand Canyon type pectus excavatum [11]. However, definitions and consensus on nomenclature and severity are lacking. The severity of pectus excavatum is classically expressed by the Haller index, which reflects the ratio between the transverse diameter and the anterior-posterior distance of the chest wall [12]. In a general sense, a higher index reflects a more severe pectus. A Haller index of >2.5 - 3.25 is considered as a severe pectus. This cut off value is often used as lower limit of indication for surgical correction.

When pectus excavatum is clinically recognized or suspected, a plain radiograph with lateral chest view can confirm the diagnosis. Two-dimensional medical photography is frequently used for documentation and enables comparison over time. Upon indication, CT and/or MRI scans are performed. CT scan is a suitable modality to visualize pectus morphology, quantify its severity and assess the relation between the depressed sternum and underlying heart. MRI provides, in contrast to CT, information on the functional cardiac effects of cardiac impression, especially in relation to right ventricle function and possible heart valve dysfunction. A recent development is the use of three-dimensional imaging in the diagnostic work up.

Treatment

Analysis and treatment of pectus excavatum preferably take place in a multidisciplinary setting. Hereby, input of specialized pediatricians (since the majority of patients are adolescents), cardiologists and surgeons are crucial. The patient plays a central role in the

decision to proceed with operative treatment. In minors, the opinion of the patient's parents is pivotal in the process of shared decision making. In the Netherlands, as in the rest of the Western world, surgical treatment is performed not earlier than the age of 12 to 14 years. For a long time, treatment of pectus excavatum has been valued as cosmetic care without reimbursement by health care insurance, which has been changed fairly recent now the importance in physiological changes as well as psychosocial impact of pectus excavatum are recognized.

Depending on the severity and type of complaints, as well as the patient's preference, conservative or operative treatment can be indicated. Among indications for surgical repair are exercise intolerance, psychosocial burden, cardiac compression with or without heart valve abnormalities, and a Haller index of $>2,5-3.25$ [13].

Conservative treatment of pectus excavatum consists of postural advices and muscle strengthening exercises. Furthermore, in young patients, an attempt to correct the deformity by applying negative pressure using a vacuum device (i.e., the vacuum bell) can be made. This technique could be a good alternative to operative treatment, especially in patients who are not (yet) eligible for surgery, for example due to minimal pectus depth, young age or patient's preference for non-operative therapy. However, this technique seems particularly suitable for children younger than 11 years and having a modest pectus depth of less than 1,5cm [14]. The major disadvantage of vacuum therapy is the required application for many hours per day, resulting in lack of compliance. The reported success rates vary from 13 to 44%, however long term results are not available yet [15].

The first surgical corrections for pectus excavatum were performed in 1911 by Meyer [16] and in 1913 by Sauerbruch. In 1949, Mark Ravitch, an American pediatric surgeon, describes an open technique in which the affected rib cartilage is resected and a correctional osteotomy of the sternum is performed [17]. Later, techniques for sternal fixation have been improved, using cerclage wires or meshes for stabilization of the osteotomy. With gaining popularity of angular stable plate osteosynthesis in the field of fracture surgery, this technique is recently adopted by pectus surgeons as latest modification in the Ravitch procedure. In the late 1980's, a new minimal invasive technique was introduced, wherein a metal correctional bar was placed retrosternally. With this so-called Nuss bar, the depressed sternum is instantly corrected to a neutral position [18]. Later, videothoracoscopy was added to the procedure, enabling bar placement under visual guidance. Nowadays, this procedure is referred to as the thoracoscopic Nuss bar procedure or minimally invasive repair of pectus excavatum (MIRPE) and considered as gold standard for the treatment of pectus excavatum. To improve

safety and feasibility of MIRPE, especially in severe cases, the current trend is to employ sternal elevation methods like the crane technique during intraoperative correction of the deformity and retrosternal passage of the correctional bar [19].

At advanced age, MIRPE is less often feasible due to progressive chest wall rigidity and therefore a Ravitch procedure may be preferred in this situation. However, hard cut-off values for age limits are not available, resulting in inter-surgeon strategy differences and practice variation among pectus centers.

Despite MIRPE is performed under general anesthesia and is carried out with use of small incisions, most patients experience the postoperative phase as rather painful. With instant correction of the depressed sternum, large forces are applied on the anterior chest wall. The length of hospital stay after corrective surgery is therefore predominantly determined by the need for invasive analgesia, mostly administered by epidural catheter or intravenous opioid perfusion during several days. Physiotherapy and pain management play a central role during postoperative recovery. With the aim of improving perioperative analgesia and associated enhanced recovery, both non-invasive and invasive alternative strategies have been explored such as music therapy [20] and cryo-analgesia [21].

Postoperative results

Surgical correction of symptomatic pectus excavatum results in an objective improvement in quality of life, self-image and self-esteem and increases physical and social activities [22-24]. Moreover, cardiac function and exercise tolerance improve after operative treatment [6, 22, 25, 26]. Due to the sternal correction, cardiac compression is relieved and stroke volume and cardiac output enlarged. The increase in forced expiratory volume (FEV₁) is more gradual and is particularly significant after bar removal [8]. From a cosmetic point of view, MIRPE results in a normal chest wall contour in the vast majority of patients. In only few cases, a slight residual pectus is present[8].

Complications

One of the most common complications after operative correction is incisional wound infection, occurring in approximately 1,5% of cases [8]. After the modified Ravitch procedure, non-union of the sternal osteotomy or pectoralis dehiscence can occur. After minimally invasive repair, bar dislocation can be observed in approximately 4% of patients [8]. This complication imposes considerable morbidity and often requires revisional surgery. Recurrence of pectus excavatum after Nuss bar removal is rarely reported in 1% of cases.

AIMS AND HYPOTHESIS

The above stated overview of pectus excavatum and its treatment describes several uncertainties as well as chances for improvement. The aim of this thesis is therefore to describe and evaluate improvements in various aspects of surgical care in patients with pectus excavatum.

Thesis outline

Analysis and treatment of pectus excavatum are generally concentrated in specialized pectus centers. Despite this, general consensus and hard guidelines on its definition, preoperative work-up and treatment strategies are still lacking. **Chapter 2** focusses on the diagnosis of pectus excavatum: it compares the visual assessment of pectus excavatum by different pectus specialists, based on three-dimensional (3D) images, and reports on its inter- and intra-observer variability.

Implementation of new techniques is usually accompanied by a learning curve. Little is known on this subject in relation to the treatment of pectus excavatum. **Chapter 3** reports on the learning curve of minimally invasive repair of pectus excavatum by the Nuss procedure.

Since its introduction, the Nuss procedure and its subsequent modifications quickly gained popularity over the classical open correctional techniques. During the first decades, MIRPE was predominantly used in a pediatric population. The years thereafter, it was progressively employed for adult patients, despite the initial criticism based on questionable feasibility, expected higher morbidity and complication rates associated with the increased chest wall rigidity compared to pediatric patients. **Chapter 4** therefore compares the complications after MIRPE between adolescent and adult patients.

One of the most important recent developments in MIRPE is the use of sternal elevation techniques. Its application strives to an intraoperative reduction of sternal depression, therewith reducing surgical risks, improving safety, and expanding the spectrum of indications for minimally invasive pectus repair. The crane technique is a popular sternal elevation technique and is advocated to be used routinely (19). Pectus depth is reduced by elevation of the sternum by a steel wire or bone clamp attached to a table mounted retractor. **Chapter 5** describes a quantitative analysis of the use of the crane technique during MIRPE, evaluating its effect with the use of three-dimensional surface images.

Perioperative analgesia is key in surgical treatment of pectus excavatum and plays a dominant role in patient recovery and satisfaction. Moreover, length of hospital stay is

primarily determined by adequacy of postoperative pain management. Currently, epidural catheters are widely used and seen as gold standard in pain treatment. There is however room for improvement, especially concerning more long-term (weeks instead of days) pain relief. **Chapter 6** is a systematic review and meta-analysis on the use of cryoablation of intercostal nerves for perioperative analgesia after minimally invasive repair of pectus excavatum.

Although the vast majority of pectus patients are treated with MIRPE nowadays, there still is a place for open pectus repair for the very deep or dysmorphic pectus, or in older patients. Over the years, many modifications have been made to the open pectus repair, originally described by Ravitch in 1949. One of the most important evolutions is the adaptation in fixation techniques of the sternal correctional osteotomy. In **Chapter 7**, fixation of the sternal osteotomy by cerclage wires and retrosternal mesh support is compared to the use of angular stable locking compression plates. Although there are many advantages of plate fixation, one of the major downsides can be the need for plate removal. In an aim to reduce the hardware removal rate, a further adjustment of the modified Ravitch technique was undertaken, using thinner, anatomically contoured sternal locking plates. **Chapter 8** describes a pilot and first results.

Besides the more common complications, some rare entities may be encountered after treatment of specific patients. **Chapter 9** reports on dehiscence of the pectoralis major muscles after open correction of pectus. A novel technique for repair, using bone suture anchors, is described.

This thesis ends with a general discussion in **Chapter 10**, elaborating on the aforementioned research subjects. A broader perspective on perioperative care in pectus excavatum patients is given, as well as a preview for future research in this field.

REFERENCES

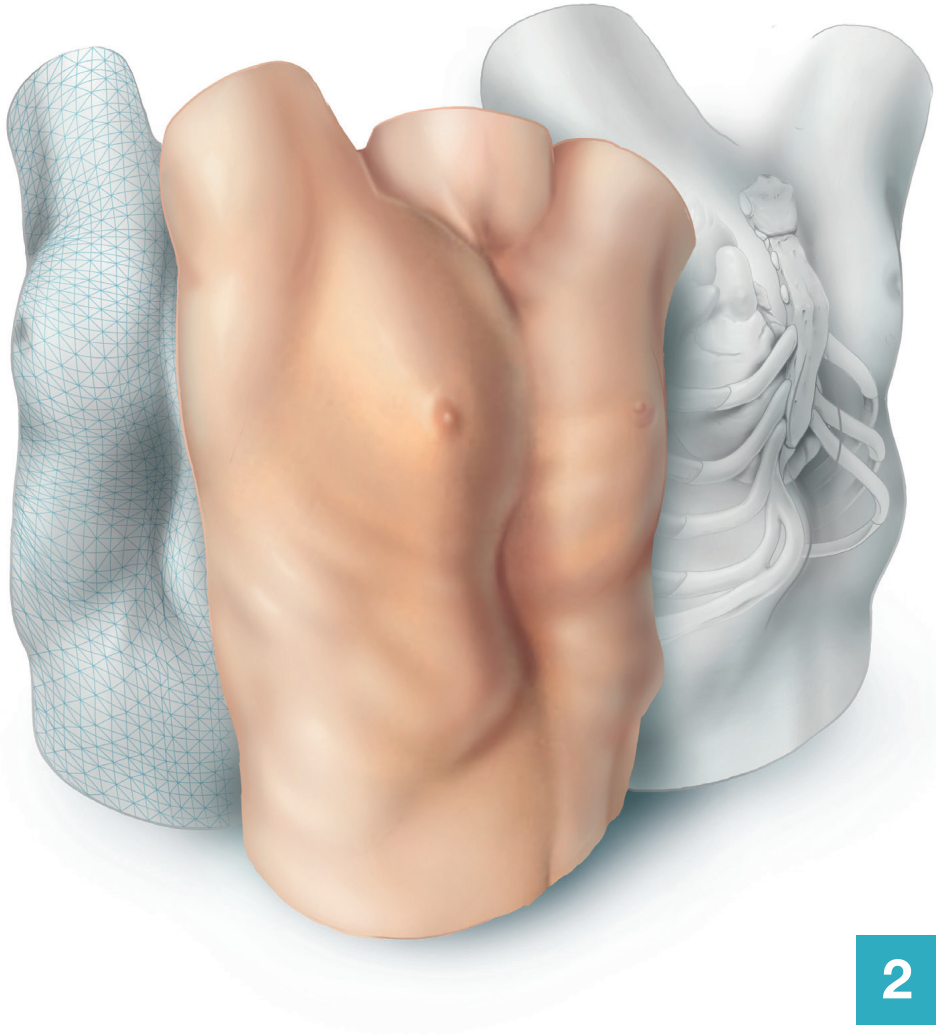
1. Fokin AA, Steuerwald NM, Ahrens WA, Allen KE. Anatomical, histologic, and genetic characteristics of congenital chest wall deformities. *Semin Thorac Cardiovasc Surg.* 2009;21(1):44-57.
2. Chung CS, Myriantopoulos NC. Factors affecting risks of congenital malformations. I. Analysis of epidemiologic factors in congenital malformations. Report from the Collaborative Perinatal Project. *Birth Defects Orig Artic Ser.* 1975;11(10):1-22.
3. Brochhausen C, Turiel S, Müller FK, Schmitt VH, Coerdts W, Wihlm JM, et al. Pectus excavatum: history, hypotheses and treatment options. *Interact Cardiovasc Thorac Surg.* 2012;14(6):801-6.
4. Koumbourlis AC. Pectus excavatum: pathophysiology and clinical characteristics. *Paediatr Respir Rev.* 2009;10(1):3-6.
5. Golladay ES, Char F, Mollitt DL. Children with Marfan's syndrome and pectus excavatum. *South Med J.* 1985;78(11):1319-23.
6. Maagaard M, Heiberg J. Improved cardiac function and exercise capacity following correction of pectus excavatum: a review of current literature. *Ann Cardiothorac Surg.* 2016;5(5):485-92.
7. Abu-Tair T, Turiel S, Hess M, Wiethoff CM, Staatz G, Lollert A, et al. Impact of Pectus Excavatum on Cardiopulmonary Function. *Ann Thorac Surg.* 2018;105(2):455-60.
8. Nuss D, Obermeyer RJ, Kelly RE. Nuss bar procedure: past, present and future. *Ann Cardiothorac Surg.* 2016;5(5):422-33.
9. Steinmann C, Krille S, Mueller A, Weber P, Reingruber B, Martin A. Pectus excavatum and pectus carinatum patients suffer from lower quality of life and impaired body image: a control group comparison of psychological characteristics prior to surgical correction. *Eur J Cardiothorac Surg.* 2011;40(5):1138-45.
10. Cartoski MJ, Nuss D, Goretsky MJ, Proud VK, Croitoru DP, Gustin T, et al. Classification of the dysmorphism of pectus excavatum. *J Pediatr Surg.* 2006;41(9):1573-81.
11. Park HJ, Jeong JY, Jo WM, Shin JS, Lee IS, Kim KT, et al. Minimally invasive repair of pectus excavatum: a novel morphology-tailored, patient-specific approach. *J Thorac Cardiovasc Surg.* 2010;139(2):379-86.
12. Haller JA, Jr., Kramer SS, Lietman SA. Use of CT scans in selection of patients for pectus excavatum surgery: a preliminary report. *J Pediatr Surg.* 1987;22(10):904-6.
13. Nuss D, Kelly RE, Jr. Indications and technique of Nuss procedure for pectus excavatum. *Thorac Surg Clin.* 2010;20(4):583-97.
14. Patel AJ, Hunt I. Is vacuum bell therapy effective in the correction of pectus excavatum? *Interact Cardiovasc Thorac Surg.* 2019 (epub ahead of print).
15. St-Louis E, Miao J, Emil S, Baird R, Bettolli M, Montpetit K, et al. Vacuum bell treatment of pectus excavatum: An early North American experience. *J Pediatr Surg.* 2019;54(1):194-9.
16. Meyer L. Zur surgical treatment of the anborn T-trichterbrust. *Verh Call Med Gest.* 1911;42:364-73.
17. Ravitch MM. The Operative Treatment of Pectus Excavatum. *Ann Surg.* 1949;129(4):429-44.
18. Nuss D, Kelly RE Jr, Croitoru DP, Katz ME. A 10-year review of a minimally invasive technique for the correction of pectus excavatum. *J Pediatr Surg.* 1998;33(4):545-52.
19. Haecker FM, Krebs T, Kocher GJ, Schmid RA, Sesia SB. Sternal elevation techniques during the minimally invasive repair of pectus excavatum. *Interact Cardiovasc Thorac Surg.* 2019;29(4):497-502.

20. Billar RJ, Kühlmann AYR, Schnater JM, Vlot J, Tomas JJP, Zijp GW, et al. Interventions with Music in PECTus excavatum treatment (IMPECT trial): a study protocol for a randomised controlled trial investigating the clinical effects of perioperative music interventions. *BMJ Open*. 2020;10(7):e036380.
21. Morikawa N, Laferriere N, Koo S, Johnson S, Woo R, Puapong D. Cryoanalgesia in Patients Undergoing Nuss Repair of Pectus Excavatum: Technique Modification and Early Results. *J Laparoendosc Adv Surg Tech A*. 2018;28(9):1148-51.
22. Kelly RE, Jr., Cash TF, Shamberger RC, Mitchell KK, Mellins RB, Lawson ML, et al. Surgical repair of pectus excavatum markedly improves body image and perceived ability for physical activity: multicenter study. *Pediatrics*. 2008;122(6):1218-22.
23. Lomholt JJ, Jacobsen EB, Thastum M, Pilegaard H. A prospective study on quality of life in youths after pectus excavatum correction. *Ann Cardiothorac Surg*. 2016;5(5):456-65.
24. Krasopoulos G, Dusmet M, Ladas G, Goldstraw P. Nuss procedure improves the quality of life in young male adults with pectus excavatum deformity. *Eur J Cardiothorac Surg*. 2006;29(1):1-5.
25. Handels NA KH, de Loos E, Höppener PF. Long-term results of surgical correction of symptomatic pectus excavatum in seniors: improvements in cardiovascular function and quality of life. *Ital J Cardiovasc Surg*. 2017;24:131-6.
26. Malek MH, Berger DE, Housh TJ, Marelich WD, Coburn JW, Beck TW. Cardiovascular function following surgical repair of pectus excavatum: a metaanalysis. *Chest*. 2006;130(2):506-16.

Daemen JHT*, **de Loos ER***, Geraedts TCM, van Veer H, van Huijstee PJ, Elenbaas
TWO, Hulsewé KWE, Vissers YLJ.

J Pediatr Surg. 2021 (epub ahead of print).

*equal contribution status



Visual diagnosis of pectus excavatum:

an intra-observer and
inter-observer agreement analysis

ABSTRACT

Background

Among patients suspected of pectus excavatum, visual examination is a key aspect of diagnosis and, moreover, guides work-up and treatment strategy. This study evaluated the inter-observer and intra-observer agreement of visual examination and diagnosis of pectus excavatum among experts.

Methods

Three-dimensional surface images of consecutive patients suspected of pectus excavatum were reviewed in a multi-center setting. Interactive three-dimensional images were evaluated for the presence of pectus excavatum, asymmetry, flaring, depth of deformity, cranial onset, overall severity, and morphological subtype through a questionnaire. Observers were blinded to all clinical patient information, completing the questionnaire twice per subject. Agreement was analyzed by kappa statistics.

Results

Fifty-eight subjects with a median age of 15.5 years (interquartile range: 14.1-18.2) were evaluated by 5 (cardio)thoracic surgeons. Pectus excavatum was visually diagnosed in 55% to 95% of cases by different surgeons, revealing considerable inter-observer differences (kappa: 0.50; 95%-confidence interval [CI]: 0.41-0.58). All other items demonstrated inter-observer kappa's of 0.25-0.37. Intra-observer analyses evaluating the presence of pectus excavatum demonstrated a kappa of 0.81 (95%-CI: 0.72-0.91), while all other items showed intra-observer kappa's of 0.36-0.68.

Conclusions

Visual examination and diagnosis of pectus excavatum yields considerable inter-observer and intra-observer disagreements. As this variation in judgement could impact work-up and treatment strategy, objective standardization is urged.

INTRODUCTION

Among congenital anterior chest wall anomalies, pectus excavatum is the most common in the Western world. The condition is characterized by an inward displacement of the sternum and adjacent costal cartilage with a worldwide incidence of 1 to 8 per 1000 persons [1]. Patients may suffer from a wide variety of symptoms. This most commonly involves physical complaints, such as exercise intolerance, dyspnea, and chest pain, but also psychological distress due to body image disturbances [2-5]. The morphological presentation of pectus excavatum is as diverse as its symptomatology, resulting from the combination and degree of phenotypical features present. Attempts to cluster morphological variations have led to categorization in descriptive subtypes, as proposed by Cartoski and colleagues [6]. For example, the most common type is a cup-shaped pectus excavatum, describing a localized depression with limited peripheral effects (i.e., usually deep with steep sides) [7]. Other features generally considered include the presence and degree of asymmetry and flaring, as well as the position of the deepest point. Key point in the diagnosis of pectus excavatum is the initial assessment through visual examination and subsequent qualitative description of phenotypical features. However, this is prone to inter-observer and intra-observer differences and could potentially influence clinical decision making in terms of work-up and treatment strategy. In extremis, patients may be offered or withheld from further analyses and treatment by different observers. To date, no studies have methodologically evaluated inter-observer and intra-observer agreement regarding the visual examination and diagnosis of pectus excavatum.

The aim of this study is to evaluate the inter-observer and intra-observer agreement of visual examination and diagnosis of pectus excavatum among experts. Assessments were based on interactive three-dimensional (3D) images of patients suspected of pectus excavatum.

MATERIALS AND METHODS

Study design

We conducted a prospective cohort study wherein 3D images from a single center were reviewed in a multi-center setting. Prior to start, the study was approved by the local ethics and clinical research committee (Medical Ethics Review Committee Zuyderland, ID: METCZ20200089, approval date: May 8th, 2020). The need for informed consent was waived. This report was written in compliance with the Strengthening the Reporting of Observational Studies in Epidemiology guidelines [8].

Participants

Subjects

We reviewed all consecutive patients who were referred for suspected pectus excavatum to one of the tertiary referral centers for chest wall disorders (Department of Surgery, Division of General Thoracic surgery, Zuyderland Medical Center, Heerlen, the Netherlands), and who received a thoracic 3D image between August 2019 and August 2020. Patients who underwent prior chest wall surgery or suffered from any form of light hypersensitivity were excluded. The latter was due to the flickering light emitted during 3D image acquisition that could provoke seizures.

Observers

Three-dimensional images of patients suspected of pectus excavatum were visually reviewed by 5 experienced pectus surgeons (4 general thoracic surgeons and one cardiothoracic surgeon) from 4 different tertiary referral centers in 2 countries (two surgeons from Zuyderland Medical Center, Heerlen, the Netherlands; and one surgeon from: University Hospitals Leuven, Leuven, Belgium; Catharina Hospital, Eindhoven, the Netherlands; and Haga Hospital, The Hague, the Netherlands). Single surgeon experience in consulting and surgical treatment of pectus excavatum ranged from 4 to 12 years with a mean annual surgical volume of 50 to 70 cases.

Sample size estimation

Since this is the first study to analyze observer agreement regarding the visual examination and diagnosis of pectus excavatum, it was not possible to determine the number of subjects and observers required. However, in order to provide a representative cohort, we chose to include all single institution patients consulting for suspected excavatum over a 1-year time period. In addition, the number of 5 observers was chosen arbitrarily.

Measurements and variables

Patient charts were reviewed for baseline patient characteristics including sex, age, body mass index and preoperative Haller index derived from either computed tomography or two-view plain chest radiographies [9, 10].

Three-dimensional images (see example Figure 1) were acquired by the Artec Leo (Artec3D, Luxembourg, Luxembourg) according to the imaging protocol described elsewhere [11].

Interactive (i.e., rotatable, and translatable) 3D images were utilized to assess observer agreement since repeated live patient examinations by experts from different centers over a one-year time-period was not practically feasible.

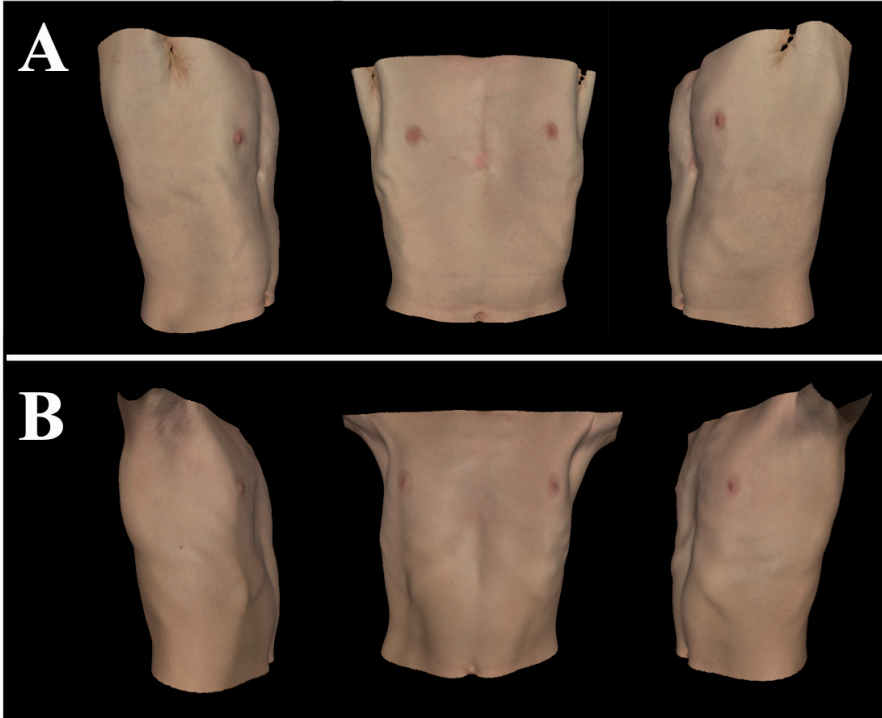


Figure 1: Three-dimensional images of (A-B) two distinct subjects that were judged to suffer from pectus excavatum by 3 of 5 observers, demonstrating inter-observer differences.

Observers were asked to visually examine 3D images on the basis of a 7-item questionnaire composed by the researchers (see Table 1). Observers were blinded to all clinical information (e.g., symptomatology and Haller index), as well as to the results of other observers and prior evaluations. The first question addressed whether the patient had pectus excavatum. If yes, agreement to 5 statements concerning the presence and severity of phenotypical pectus excavatum features was evaluated through binominal judgement (i.e., agree or disagree). Evaluated features were based on the pectus characteristics described by Cartoski et al., [6] and encompassed the depth of deformity, its cranial onset point, the presence of asymmetry, flaring and overall severity. The use of these characteristics was further rationalized by Kelly [12] who emphasized that their preoperative notion affects surgical strategy. In addition, evaluation of the overall severity was rationalized by the fact that clinical evaluation

algorithms, such as those described by Nuss and Kelly [13] and Frantz et al., [14] stratify patients based on the subjective overall severity of their deformity. Both the depth of the deformity and overall severity were evaluated with the difference being that severity was used as a comprehensive judgement of the pectus excavatum (including its disfiguring aspect) while depth solely referred to the visual depth of the excavation. We deliberately chose to, if possible, use binominal judgement options since offering more options would inevitably lead to a reduction in agreement. The last item to score encompassed the subtype of dysmorphology (i.e., cup-shaped, saucer-shaped, trench-like, or other), according to the most common subtypes described by Kelly and colleagues [7]. Observers were not asked to judge surgical treatment eligibility or candidacy as this is a multifactorial decision, often and not solely based on visual examination alone. All observers completed the questionnaire twice per subject, the second time in a random order compared to the first run-through, while bearing at least one week in between.

Table 1: The 7-item questionnaire used to structure visual examination of interactive 3D images of patients suspected of pectus excavatum.

Item	Question	Answer options
1	Does the presented patient suffer from pectus excavatum?	Yes / No
2	Would you describe the deformity as deep?	Yes / No
3	Does the deformity exhibit a high cranial onset point?	Yes / No
4	Is the deformity asymmetric?	Yes / No
5	Is flaring present?	Yes / No
6	Would you judge the overall severity as severe?	Yes / No
7	How would you categorize the deformity?	Cup-shaped / Saucer-shaped / Trench-like / Any other

Statistical analysis

Statistical analyses were performed by SPSS statistics (IBM Corp. IBM SPSS Statistics for MacOS, Version 27.0, Armonk, NY, USA). Normally distributed continuous variables were depicted as mean and standard deviation (SD). If skewed, the median, interquartile range (IQR) and range were used. Categorical variables were denoted as frequencies and percentages.

To evaluate inter-observer agreement, nominal questionnaire ratings from the first assessment round were submitted to Cohen's kappa statistics for all observer pairs. The weighted (i.e., based on the number of subjects evaluated) arithmetic mean of all observer pairs was, according to Light [15], employed as measure of overall agreement. Additionally,

the inter-observer agreement per observer was based on the weighted arithmetic mean of all observer pairs encompassing the observer of interest. Two-sided 95% confidence intervals (CI) were calculated. Since further work-through of the questionnaire (after the first question) was halted in the absence of pectus excavatum, inter-observer agreement concerning the remaining statements could only be determined on the basis of patients identified as pectus excavatum by both observers of the observer pair. Intra-observer agreement was evaluated in a similar fashion but using repeated assessments by the same surgeon.

Post-hoc sensitivity analyses were performed to evaluate potential agreement differences based on the quantitative severity of pectus excavatum, measured through the Haller index. Patients were stratified applying a Haller index threshold of 3.25, that is generally considered indicative for treatment [9, 10]. In the case where both answer options were not represented in the comparison (e.g., if one of the two surgeons judges all patients as pectus excavatum), the variable was treated as constant and as such, it was not possible to determine Cohen's kappa. If so, the percentage of agreement was applied.

Kappa coefficients were interpreted as follows: a coefficient between 0.00-0.20, 0.21-0.40, 0.41-0.60, 0.61-0.80 and 0.81-1.00 respectively corresponded to slight, fair, moderate, substantial, and almost perfect agreement [16].

RESULTS

Three-dimensional images of 58 consecutive patients referred for suspected pectus excavatum were judged by 5 experienced chest wall surgeons. During the accrual period, only 1 patient denied participation. Included patients were predominantly male (86%) with an overall median age of 15.5 years (IQR: 14.1-18.2; range: 9.1-59.9) and a mean BMI of 19.3 kg/m² (SD: 2.5). The median Haller index was 3.36 (IQR: 2.82-4.04; range: 2.12-10.21). No missing data was present.

Inter-observer agreement

During the first assessment round, patients were judged to suffer from pectus excavatum in 55% (n=32/58) to 95% (n=55/58) of cases by different surgeons, demonstrating considerable inter-observer differences. The overall inter-observer coefficient of agreement regarding the presence of pectus excavatum was 0.50 (95% CI: 0.41-0.58; see Table 2). This indicates a moderate level of agreement. Figure 1 shows two examples of subjects that were judged to

suffer from pectus excavatum by 3 out of 5 observers. The largest share in disagreement was produced by observer E, revealing a kappa of 0.25 (95% CI: 0.16-0.33). In contrast, observer A to observer D demonstrated an inter-observer agreement between 0.47 and 0.61 (see Table 2), evaluating the presence of pectus excavatum.

Table 2: Inter-observer agreement regarding the visual assessment and diagnosis of patients suspected of pectus excavatum.

	Overall, kappa (95% CI)	Observer A vs B-E, kappa (95% CI)	Observer B vs A & C-E, kappa (95% CI)	Observer C vs A-B & D-E, kappa (95% CI)	Observer D vs A-C & E, kappa (95% CI)	Observer E vs A-D, kappa (95% CI)
Pectus excavatum	0.50 (0.41-0.58)	0.61 (0.47-0.74)	0.60 (0.46-0.73)	0.55 (0.41-0.69)	0.47 (0.31-0.63)	0.25 (0.16-0.33)
Deep deformity	0.37 (0.30-0.44)	0.45 (0.34-0.57)	0.27 (0.18-0.37)	0.43 (0.32-0.55)	0.40 (0.29-0.52)	0.23 (0.10-0.35)
High cranial onset	0.37 (0.30-0.45)	0.40 (0.29-0.52)	0.40 (0.28-0.53)	0.28 (0.17-0.39)	0.46 (0.34-0.57)	0.29 (0.15-0.44)
Asymmetry	0.25 (0.16-0.34)	0.31 (0.19-0.43)	0.21 (0.07-0.35)	0.20 (0.05-0.34)	0.34 (0.20-0.49)	0.16 (0.00-0.32)
Flaring	0.41 (0.30-0.52)	0.47 (0.31-0.64)	0.45 (0.30-0.60)	0.37 (0.20-0.54)	0.41 (0.26-0.56)	0.31 (0.08-0.53)
Severe	0.37 (0.30-0.44)	0.45 (0.34-0.56)	0.25 (0.15-0.35)	0.49 (0.38-0.60)	0.45 (0.34-0.55)	0.14 (0.01-0.26)
Subtype	0.34 (0.28-0.40)	0.39 (0.29-0.48)	0.28 (0.19-0.36)	0.31 (0.21-0.42)	0.37 (0.27-0.47)	0.33 (0.23-0.44)

CI, confidence interval.

Judgements regarding the depth of deformity, cranial onset point, and overall severity yielded fair to moderate agreement among raters with an overall kappa of respectively 0.37 (95% CI: 0.30-0.44), 0.37 (95% CI: 0.30-0.45) and 0.37 (95% CI: 0.30-0.44). In addition, slight to fair concordance (kappa: 0.25; 95% CI: 0.16-0.34) was observed among observers when evaluating the presence of thoracic asymmetry. Similar to the visual diagnosis of pectus excavatum, observer E yielded the lowest inter-observer agreement for the depth of deformity (0.23; 95% CI: 0.10-0.35), overall severity (kappa: 0.14; 95% CI: 0.01-0.26), as well as the presence of asymmetry (0.16; 95% CI: 0.00-0.32) and flaring (kappa: 0.31; 95% CI: 0.08-0.53).

Among patients judged to have pectus excavatum observers classified the subtype of morphology yielding an overall kappa of 0.34 (95% CI: 0.28-0.40), expressing fair agreement.

Inter-observer agreement between the two thoracic surgeons from the same center (i.e., observer A and observer D) ranged from 0.41 to 0.73 across all items scored. Despite these kappa levels demonstrated to be above average for all items scored (see Table 2), they were not superior to all individual observer pairs. For example, regarding the diagnosis of pectus excavatum, observer A and observer D demonstrated an inter-observer kappa of 0.73, while observer A and observer B (both from another center) demonstrated a kappa of 0.82.

Intra-observer agreement

The time between repeated assessments ranged from 7 to 26 days per observer. The overall intra-observer agreement regarding the presence of pectus excavatum was 0.81 (95% CI: 0.72-0.91; see Table 3), indicating substantial to almost perfect agreement. The kappa was lowest for observer B and E, who respectively gave 4 and 8 subjects an opposite judgement during the second compared to the first assessment round. For observer E this meant judging 41% as pectus excavatum, compared to 55% during the first round of assessment. Examples of patients for whom this was the case are shown in Figure 2.

Table 3: Intra-observer agreement regarding the visual assessment and visual diagnosis of patients suspected of pectus excavatum.

	Overall, kappa (95% CI)	Observer A vs A, kappa (95% CI)	Observer B vs B, kappa (95% CI)	Observer C vs C, kappa (95% CI)	Observer D vs D, kappa (95% CI)	Observer E vs E, kappa (95% CI)
Pectus excavatum	0.81 (0.72-0.91)	0.88 (0.65-1.00)	0.68 (0.38-0.97)	0.77 (0.53-1.00)	1.00 (1.00-1.00)	0.73 (0.56-0.90)
Deep deformity	0.68 (0.59-0.78)	0.62 (0.40-0.84)	0.56 (0.32-0.79)	0.79 (0.62-0.96)	0.88 (0.71-1.00)	0.43 (0.11-0.76)
High cranial onset	0.51 (0.39-0.62)	0.46 (0.21-0.72)	0.49 (0.25-0.74)	0.50 (0.23-0.77)	0.43 (0.18-0.67)	0.82 (0.59-1.00)
Asymmetry	0.36 (0.23-0.48)	0.41 (0.18-0.63)	0.33 (0.02-0.65)	0.26 (-0.01-0.52)	0.33 (0.05-0.61)	0.56 (0.18-0.94)
Flaring	0.41 (0.25-0.58)	0.35 (0.00-0.70)	0.37 (0.05-0.69)	0.29 (-0.21-0.78)	0.54 (0.29-0.79)	0.62 (0.14-1.00)
Severe	0.65 (0.55-0.75)	0.76 (0.58-0.94)	0.47 (0.22-0.73)	0.76 (0.57-0.94)	0.60 (0.36-0.84)	0.68 (0.40-0.95)
Subtype	0.55 (0.46-0.64)	0.47 (0.29-0.65)	0.47 (0.27-0.66)	0.54 (0.34-0.73)	0.66 (0.50-0.82)	0.67 (0.43-0.91)

CI, confidence interval.

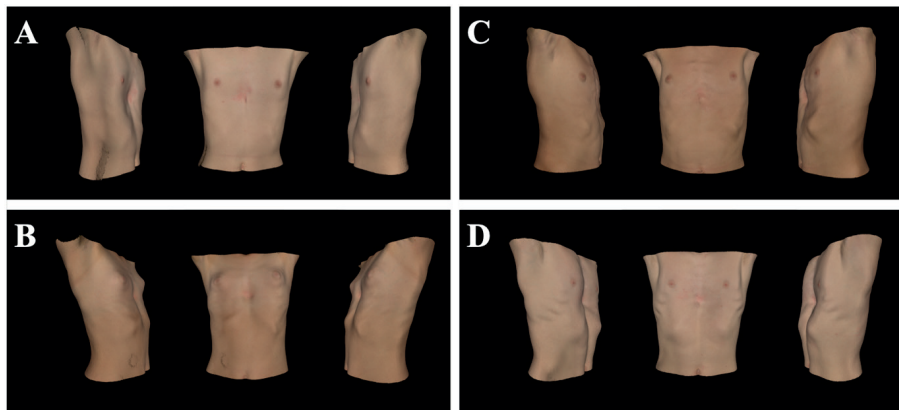


Figure 2: Three-dimensional images of (A-D) four distinct subjects that showed conflicting judgements regarding the presence of pectus excavatum upon repeated assessment (i.e., intra-observer disagreement) by observer E.

Moderate intra-observer agreement was observed for judgements regarding the cranial onset point, the presence of flaring (0.41; 95% CI: 0.25-0.58) and the classification in morphological subtypes (0.55; 95% CI: 0.46-0.64). In addition, the repeated assessment of severity and depth of deformity yielded an overall agreement of respectively 0.65 (95% CI: 0.55-0.75) and 0.68 (95% CI: 0.59-0.78), both depicting substantial agreement.

Post-hoc sensitivity analysis

Among included patients, 52% (n=30/58) had a Haller index larger than or equal to 3.25. Scoring these patients, a higher median inter-observer agreement percentage of 97% (IQR: 77-100) was observed compared to patients with a Haller index <3.25 (median: 84%; IQR: 55-90), indicating improved inter-observer agreement among patients with a Haller index ≥ 3.25 . This trend was also observed for all other items except the classification of pectus morphology (Table 4).

Table 4: Intra-observer and inter-observer agreement regarding the visual assessment and visual diagnosis of patients suspected of pectus excavatum, stratified by the preoperative Haller index.

	Inter-observer agreement		Intra-observer agreement	
	Haller index ≥ 3.25 (n=30)	Haller index <3.25 (n=28)	Haller index ≥ 3.25 (n=30)	Haller index <3.25 (n=28)
Pectus excavatum, percentage of agreement, median (IQR)	97 (77-100)	84 (55-90)	100 (92-100)	93 (86-98)
Deep deformity, kappa (95% CI)	0.36 (0.27-0.45)	0.24 (0.12-0.36)	0.67 (0.40-0.95)	0.50 (0.29-0.72) ^a
High cranial onset, kappa (95% CI)	0.41 (0.30-0.51)	0.28 (0.16-0.40)	0.44 (0.30-0.59)	0.39 (0.19-0.59)
Asymmetry, kappa (95% CI)	0.36 (0.23-0.49)	0.04 (-0.08-0.17) ^b	0.22 (0.05-0.38)	0.30 (0.11-0.48)
Flaring, kappa (95% CI)	0.47 (0.34-0.60)	0.32 (0.17-0.47)	0.49 (0.28-0.70)	0.29 (0.08-0.49)
Severe, kappa (95% CI)	0.35 (0.26-0.44)	0.28 (0.16-0.41) ^b	0.58 (0.44-0.72)	0.71 (0.54-0.89) ^a
Subtype, kappa (95% CI)	0.30 (0.22-0.37)	0.36 (0.26-0.46)	0.53 (0.41-0.64)	0.56 (0.42-0.69)

IQR, interquartile range; CI, confidence interval. ^aThe intra-observer kappa regarding the depth of deformity and severity were not incorporated for observer D while kappa could not be determined due to not all answer options being represented. ^bThe inter-observer kappa regarding the presence of asymmetry and severity was not incorporated for a single observer pair (observer B vs observer E) while kappa could not be determined due to not all answer options being represented.

A similar increased percentage of intra-observer agreement was observed judging the presence of pectus excavatum among patients with a Haller index ≥ 3.25 (median: 100%; IQR: 92-100) compared to patients with a Haller index < 3.25 (median: 93%; IQR: 86-98). However, this was not uniformly reproduced since only 3 out of 6 items demonstrated superior kappa coefficients judging patients with a Haller index ≥ 3.25 (Table 4).

DISCUSSION

In the current study we evaluated the inter-observer and intra-observer agreement of visual examination and diagnosis of pectus excavatum. Experienced (cardio)thoracic pectus surgeons from different referral centers assessed interactive 3D images of patients suspected of pectus excavatum in a blinded and standardized manner through a 7-item questionnaire.

Three-dimensional images were utilized since live and repeated visual examination of 58 patients over a 1-year time period, by observers from different centers, was practically unfeasible. Evaluability of the 3D images was subjectively rated as fair to excellent by the observers. Three-dimensional images were made by the Artec Leo imaging system that has previously been validated for anterior chest wall images, demonstrating sub-millimeter accuracy and reproducibility [17]. In past years, the role of 3D imaging in the work-up and follow-up of pectus excavatum is expanding progressively. It is being employed to determine pectus severity, through a derivative of the gold standard Haller index, without exposure to potentially harmful ionizing radiation [18], but also to visually document the deformity [11] and follow-up after both conservative and surgical treatment [19].

Overall, judgements among 5 distinct surgeons demonstrated slight to moderate agreement across all items addressed by the questionnaire. Despite these considerable inter-observer differences across all items, disagreements regarding the presence of pectus excavatum were deemed clinically most significant and demonstrated moderate agreement (kappa: 0.50). Pectus excavatum was diagnosed in 55% of cases by observer E and 95% of cases by observer D, while the frequency of diagnosis ranged from 85% to 91% for observer A to observer C.

Inter-observer differences were observed to be less pronounced among patients with a Haller index ≥ 3.25 compared to those with a Haller index < 3.25 . Still, (during first run-through) between 32% and 89% of patients with a Haller index < 3.25 were diagnosed as having pectus excavatum. Moreover, pectus excavatum was defined as absent in up to 23% of cases with a Haller index ≥ 3.25 . Visual examination thus seems not able to uniformly differentiate between disease and no disease.

In the Netherlands and Belgium, where this study was conducted, as well as globally, a strict definition of pectus excavatum other than an inward depression of the sternum and adjacent costal cartilage is lacking. Moreover, strict criteria for clinical significance are not available. Furthermore, there are no definitions nor general consensus to define pectus features. For example, when should one define a pectus as deep and which degree of asymmetry and flaring must be classified as aberrant? On the other hand, even a mild pectus excavatum may require diagnosis to enter into a follow-up program designated to evaluate progression with age, since a history of progression is drafted as one of the criteria for treatment [12].

Both Nuss and Kelly [13] and Frantz [14] reported a similar clinical evaluation algorithm of pectus excavatum. The primary assessment includes physical examination, whereafter patients are stratified based on severity. Patients judged to have severe pectus excavatum undergo chest computed tomography, pulmonary function testing and cardiac evaluation while those with mild or moderate deformities are enrolled into an exercise and posture program with follow-up every 6 to 12 months [13, 14]. Therefore, the primary evaluation of severity by the observer is key and determines subsequent proceedings. However, since the overall assessment of severity only demonstrated fair to moderate inter-observer agreement (κ : 0.37; 95% CI: 0.30-0.44), the work-up appears to be susceptible to observer subjectivity and may result in different strategies for the same patient being evaluated. In addition, given the overall substantial though imperfect intra-observer agreement (κ : 0.65; 95% CI: 0.55-0.75) regarding severity, patients evaluated repeatedly by the same observer may be offered a different work-up.

Other phenotypical pectus excavatum features assessed for agreement encompass the depth of deformity, its cranial onset point, as well as the presence of asymmetry and flaring. Since all of these features demonstrated considerable inter-observer and intra-observer disagreement in conjunction with the fact that they affect surgical strategy rather than diagnosis, strategies are likely to differ between observers and upon repeated evaluation. The importance of preoperative notion of the presence of asymmetry, flaring, asymmetry, and extent of depression is also stressed by Kelly and colleagues and emphasized to affect surgical strategy [12]. For example, extremely deep pectus excavatum may necessitate the use of sternal elevation techniques and multiple bars during the Nuss procedure. Park and colleagues, moreover, advocate for the use of patient-specific, morphology-tailored Nuss bars, whereby disagreements regarding the presence or absence of asymmetry could also result in different treatment strategies [20]. In addition, flaring may prompt concomitant correctional procedures, such as cartilage resection [21] or retraction by the flare-buster technique [22].

Given the presented substantial inter-observer and intra-observer disagreement regarding the visual evaluation of patients suspected of pectus excavatum, objective parameters, definitions, and standardization in diagnosing pectus excavatum are urged. The Haller index is a quantitative measure that is routinely employed by 80% of experts to determine severity. However, its use is limited by the fact that it is, as a sole two-dimensional measure, not able to comprehensively reflect the extent of deformity (e.g., a wide chest with relative shallow pectus exhibits a similar Haller index as a barrel-shaped chest with focal deep pectus) as well as the different features assessed by the observers. This issue has also been stressed by Martinez-Ferro [23]. He emphasized the need for more comprehensive methods to quantify pectus excavatum and proposed the perfect index to be a combination of different pectus excavatum aspects. Quantification of these aspects, as evaluated by the observers in the current study (e.g., depth, asymmetry, flaring and so on), could provide the basis for such an index.

Three-dimensional images acquired of the patient's chest could provide a future way to standardization and objectively evaluate the morphology of pectus excavatum. Since 3D images are digital objects and encompass all information on the external pectus morphology, they can be used to quantify characteristics of pectus excavatum in an automated and standardized manner, eliminating inter-observer and intra-observer bias. However, for these quantitative measures to be used in the clinical setting, they require a meaning. This could be achieved by evaluating a large cohort of pectus excavatum patients and determining a "mean pectus excavatum". Like the idea of birth-weight-curves one can subsequently determine whether a patient has a below average (e.g., mild) or above average (e.g., severe) pectus. The number of standard deviations from the mean can, moreover, be used to further distinguish between for example sever and extremely severe deformities.

LIMITATIONS

The current study is limited by the fact that it is unknown how the involved surgeons, who may in theory be under- or overperformers, performed with respect to peers. Another limitation is that we were not able to determine the sample size required prior to start. In addition, given that patients were recruited from a tertiary referral center for chest wall disorders, the included cohort may not be representative for other centers.

The utilized questionnaire was not validated and did solely provide binominal answer options for the first 6 items. Yet, to date, no validated questionnaires exist to visually examine and score pectus excavatum severity.

The utilized 3D images are not fully comparable to live examination, where palpation, pose alterations and movement may potentially improve judgement. Nevertheless, their evaluability was rated as fair to excellent by the observers. In addition, the light position of the rendering software might influence the interpretation of the images and as such severity. In addition, 3D images were acquired during breath hold in the end-inspiratory phase. Therefore, visual assessment may yield a less intrusive presentation of the pectus excavatum deformity because the Haller index is known to be significantly lower during inspiration compared to expiration [24].

CONCLUSION

Visual examination and diagnosis of pectus excavatum by experienced (cardio)thoracic pectus surgeons yields considerable inter-observer and intra-observer disagreements. As this variation in judgement could impact work-up and treatment strategy, objective standardization of visual assessment is urged. Three-dimensional images could play a role in this process.

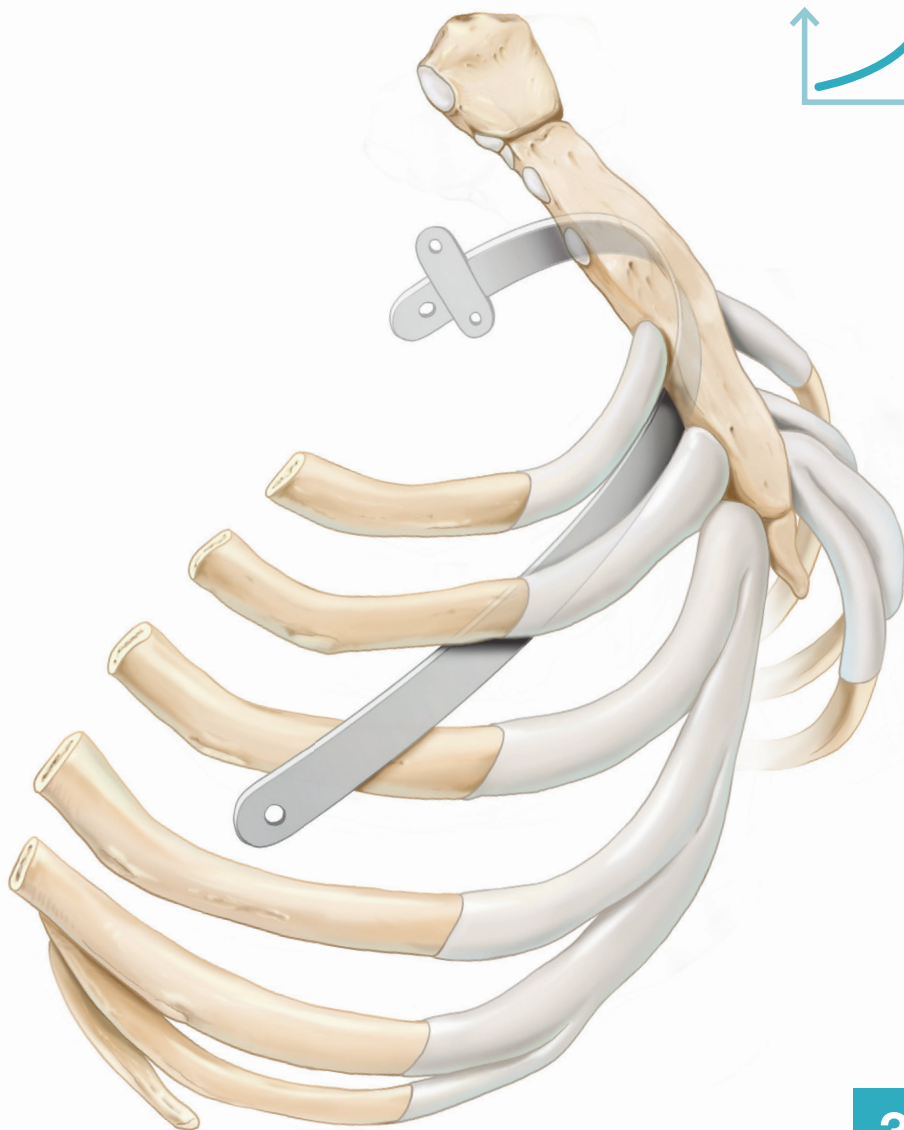
REFERENCES

1. Brockhausen C, Tural S, Müller FK, Schmitt VH, Coerdts W, Wihlm JM et al. Pectus excavatum: history, hypotheses and treatment options. *Interact Cardiovasc Thorac Surg*. 2012;14:801-6.
2. Ewert F, Syed J, Kern S, Besendörfer M, Carbon RT, Schulz-Drost S. Symptoms in Pectus Deformities: A Scoring System for Subjective Physical Complaints. *Thorac Cardiovasc Surg*. 2017;65:43-9.
3. Fonkalsrud EW, Dunn JC, Atkinson JB. Repair of pectus excavatum deformities: 30 years of experience with 375 patients. *Ann Surg*. 2000;231:443-8.
4. Kelly RE, Jr., Shamberger RC, Mellins RB, Mitchell KK, Lawson ML, Oldham K et al. Prospective multicenter study of surgical correction of pectus excavatum: design, perioperative complications, pain, and baseline pulmonary function facilitated by internet-based data collection. *J Am Coll Surg*. 2007;205:205-16.
5. Miller KA, Woods RK, Sharp RJ, Gittes GK, Wade K, Ashcraft KW et al. Minimally invasive repair of pectus excavatum: A single institution's experience. *Surgery* 2001;130:652-9.
6. Cartoski MJ, Nuss D, Goretsky MJ, Proud VK, Croitoru DP, Gustin T et al. Classification of the dysmorphology of pectus excavatum. *J Pediatr Surg*. 2006;41:1573-81.
7. Kelly RE, Quinn A, Varela P, Redlinger RE, Nuss D. Dysmorphology of Chest Wall Deformities: Frequency Distribution of Subtypes of Typical Pectus Excavatum and Rare Subtypes. *Arch Bronconeumol*. 2013;49:196-200.
8. von Elm E, Altman DG, Egger M, Pocock SJ, Gøtzsche PC, Vandenbroucke JP. The Strengthening the Reporting of Observational Studies in Epidemiology (STROBE) statement: guidelines for reporting observational studies. *Lancet* 2007;370:1453-7.
9. Khanna G, Jaju A, Don S, Keys T, Hildebolt CF. Comparison of Haller index values calculated with chest radiographs versus CT for pectus excavatum evaluation. *Pediatr Radiol*. 2010;40:1763-7.
10. Haller JA, Jr., Kramer SS, Lietman SA. Use of CT scans in selection of patients for pectus excavatum surgery: a preliminary report. *J Pediatr Surg*. 1987;22:904-6.
11. Daemen JHT, Loonen TGJ, Coorens NA, Maessen JG, Maal TJJ, Hulstewé KWE et al. Photographic documentation and severity quantification of pectus excavatum through three-dimensional optical surface imaging. *J Vis Commun Med*. 2020;43:190-7.
12. Kelly RE, Jr. Pectus excavatum: historical background, clinical picture, preoperative evaluation and criteria for operation. *Semin Pediatr Surg*. 2008;17:181-93.
13. Nuss D, Kelly RE, Jr. Indications and technique of Nuss procedure for pectus excavatum. *Thorac Surg Clin*. 2010;20:583-97.
14. Frantz FW. Indications and guidelines for pectus excavatum repair. *Curr Opin Pediatr*. 2011;23:486-91.
15. Light RJ. Measures of response agreement for qualitative data: Some generalizations and alternatives. *Psychol Bull*. 1971;76:365-77.
16. Landis JR, Koch GG. The measurement of observer agreement for categorical data. *Biometrics* 1977;33:159-74.
17. Daemen JHT, Loonen TGJ, Verhulst AC, Maal TJJ, Maessen JG, Vissers YLJ et al. Three-Dimensional Imaging of the Chest Wall: A Comparison Between Three Different Imaging Systems. *J Surg Res*. 2020;259:332-41.

18. Daemen JHT, Loonen TGJ, Lozekoot PWJ, Maessen JG, Maal TJJ, Hulswé KWE et al. Optical imaging versus CT and plain radiography to quantify pectus severity: a systematic review and meta-analysis. *J Thorac Dis.* 2020;12:1475-87.
19. Lain A, Garcia L, Gine C, Tiffet O, Lopez M. New Methods for Imaging Evaluation of Chest Wall Deformities. *Front Pediatr.* 2017;5:257.
20. Park HJ, Lee SY, Lee CS, Youm W, Lee KR. The Nuss procedure for pectus excavatum: evolution of techniques and early results on 322 patients. *Ann Thorac Surg.* 2004;77:289-95.
21. Bosgraaf RP, Aronson DC. Treatment of flaring of the costal arch after the minimally invasive pectus excavatum repair (Nuss procedure) in children. *J Pediatr Surg.* 2010;45:1904-6.
22. Park HJ, Kim KS. The sandwich technique for repair of pectus carinatum and excavatum/carinatum complex. *Ann Cardiothorac Surg.* 2016;5:434-9.
23. Martinez-Ferro M. Indexes for Pectus Deformities. In Kolvekar S, Pilegaard H (eds): *Chest Wall Deformities and Corrective Procedures.* Cham: Springer International Publishing 2016; 35-60.
24. Birkemeier KL, Podberesky DJ, Salisbury S, Serai S. Breathe in... breathe out... stop breathing: does phase of respiration affect the Haller index in patients with pectus excavatum? *Am J Roentgenol.* 2011;197:W934-9.

De Loos ER*, Daemen JHT*, Pennings AJ, Maessen JG, Hulsewé KWE, Vissers YLJ.
J Thorac Cardiovasc Surg. 2020 (epub ahead of print).

*equal contribution status



3

Minimally invasive repair of pectus excavatum by the Nuss procedure:

the learning curve

ABSTRACT

Objectives

To define the learning process of minimally invasive repair of pectus excavatum by the Nuss procedure through assessment of consecutive procedural metrics.

Methods

A single-center retrospective observational cohort study was conducted of all consecutive Nuss procedures performed by individual surgeons without previous experience between June 2006 and December 2018. Surgeons were proctored during their initial 10 procedures. The learning process after the proctoring period was evaluated using non risk-adjusted cumulative sum (i.e., observed minus expected) failure charts of complications. An acceptable and unacceptable complication rate of 10% and 20% were used. Logarithmic trend lines were used to assess over-time performance regarding operation time.

Results

Two-hundred twenty-two consecutive Nuss procedures by 3 general thoracic surgeons were evaluated. Cumulative sum charts showed an average performance from the first procedure after being proctored onward for all surgeons, whereas surgeon B demonstrated a statistically significant complication rate equal to or less than 10% after 59 cases. Post-hoc sensitivity analyses using a stricter acceptable and unacceptable complication rate of 6% and 12% also showed an average performance for all surgeons. Although, the median time between consecutive procedures ranged from 7 to 35 days, no frequency–outcome relationship was observed. In addition, surgeons required the same average operation time throughout their entire experience.

Conclusions

After a 10-procedure proctoring period, repair of pectus excavatum by the Nuss procedure is a safe procedure to adopt and perform without a typical (complication based) learning curve while performing at least 1 procedure per 35 days.

INTRODUCTION

Pectus excavatum is the most common congenital anterior chest wall deformity and affects 1 in 300 to 400 live births [1-3]. Surgical correction of the deformity can either be performed by the modified Ravitch or Nuss procedure. The latter is considered minimally invasive and is characterized by small incisions, minimal blood loss, and short operative time [4] without the need for cartilage resection. In addition, the procedure has similar postoperative morbidity in comparison with the modified Ravitch procedure [5]. Since the 21st century, the Nuss procedure has rapidly gained popularity and has been introduced in numerous centers around the world, becoming the gold standard treatment; it became standard care in our center from June 2006 onwards. Adopting new procedures is associated with a learning process, including the Nuss procedure, as described by Ong and colleagues [6], Kelly and colleagues [7], and Castellani and colleagues [8]. However, to date and to the best of our knowledge, no studies have methodologically examined and described the specific characteristics of the learning process of the Nuss procedure. Detailed knowledge of the specifics of this learning curve may have important implications for centers preparing to start a Nuss program. This information may, moreover, be of importance for other centers already performing this procedure because the presence of a volume- and/or frequency-outcome effect may provide arguments for centralization. The objective was to define the learning process of the Nuss procedure through assessment of consecutive procedural metrics of individual surgeons. The primary outcome measure to define the learning process was the occurrence of complications.

METHODS

Study design and setting

We conducted a single-center retrospective observational cohort study. This study was performed in Zuyderland Medical Center, Heerlen, the Netherlands. Data were retrospectively collected from the electronic patients' records. Records were available from 2005. The study protocol was approved by the local medical ethics and clinical research committee (Medical Ethics Review Committee Zuyderland Medical Center, Heerlen, the Netherlands; ID: METCZ20180140, date of approval: November 26, 2018). The need for individual patient consent was waived. To ensure quality and transparency the report was written in compliance with the Strengthening the Reporting of Observational Studies in Epidemiology (STROBE) guidelines for cohort studies [9].

Participants

Minimally invasive repair of pectus excavatum was first introduced in June 2006 and became the procedure of choice in the following months. Between June 2006 and December 2018, consecutive patients undergoing the Nuss procedure in Zuyderland Medical Center (Heerlen, the Netherlands) were eligible for inclusion. Patients who underwent previous corrective surgery were excluded. Consecutive procedural metrics of individual surgeons without previous experience in performing the Nuss procedure were evaluated. All surgeons were routinely proctored during their initial 10 procedures by a thoracic surgeon skilled in the Nuss procedure. In the current study, solely the learning process after the proctoring period was evaluated and thus excluding the first 10 cases from analysis. Surgeons who performed fewer than 10 procedures after proctoring were also excluded since their post proctoring experience was deemed too short. All procedures were assisted by another surgeon or surgical resident.

Surgical technique

Video 1 shows the surgical technique in short. A thoracic epidural catheter is placed for postoperative analgesia and prophylactic cefazoline is administered. The patient is intubated using a double-lumen endotracheal tube, selectively excluding the right main bronchus from ventilation. The deepest point, edges of the excavation, and intercostal entry and exit points are identified and marked. With the use of a template, the correctly sized bar is chosen and bent according to the desired curvature. Two- to three-centimeter bilateral transverse skin incisions are made just lateral to the entry and exit points, whereafter subcutaneous pockets were created in the prefascial plane. After a 30° thoracoscope is introduced through a right axillary trocar, the introducer is entered in the selected intercostal space and passed across the mediastinum under thoracoscopic guidance and in close contact with the sternum. After preliminary correction, the introducer is retracted to insert the definitive pre-bent bar. The bar is flipped and secured by a left-sided stabilizer that is inserted perpendicular to the surgical incision and rotated inside the pocket to be slid onto the bar. The stabilizer was initially attached to the bar using wire cerclage (until late 2017), and later substituted by FiberWire (Arthrex, Naples, Fla; until late 2018) and Hi-Fi sutures (CONMED, Utica, NY; until the end of the enrollment period) in an effort to diminish localized symptoms (e.g., soft-tissue irritation) by using softer and braided materials. The right end was fixated by a pericostal polydioxanone suture until mid-2017. In case of insufficient correction or inadequate stability, 2 bars or bilateral stabilizers are applied. Residual intrathoracic air is evacuated through a thoracic drain under water seal and positive pressure ventilation. No

chest tube is left in situ. With the exception of the stabilizers' fixation material, the surgical technique remained identical throughout the entire enrollment period.

A postoperative plain chest radiograph is made to confirm bar position and assess the presence of pneumo- or hemothorax. The epidural catheter is removed on the third postoperative day. Patients are discharged upon achievement of adequate pain control and sufficient mobilization. Standard outpatient visits are scheduled 2 weeks, 3 months, and every year post surgery. Standard policy is to remove the bar 3 years following surgery.

Measurements and variables

Data of Nuss procedures performed between June 2006 and December 2018 were extracted from the electronic patient records between January and February 2019 by a single researcher (A.P.). Completeness and validity were audited by a second researcher (Y.V.) through random case selection. Extracted variables encompassed baseline patient characteristics (age, sex, and preoperative Haller index [see Figure E1 for the measurement method]) and procedural characteristics (number of bars inserted, operation time from incision to wound closure, postoperative length of hospital stay, intra- and postoperative complications). Definitions and time windows of complications are shown in Table E1 and were graded according to the Clavien–Dindo classification (CDC) [10]. Solely clinically relevant complications associated with surgical–technical aspects of the Nuss procedure were considered; those related to, for instance, epidural use, were thus not examined. Complications were prospectively registered; those that occurred during clinical stay were daily discussed and subsequently logged. In addition, patients postoperatively visited the outpatient clinic at aforementioned set intervals where complications were also registered. The primary outcome measure to define the learning process associated with the Nuss procedure was the occurrence of intra- and postoperative complications. Secondary parameters characterizing the learning curve included operation duration, blood loss, and length of hospital stay.

Statistical analyses

Standard statistical analyses were performed using SPSS statistics (IBM SPSS Statistics for MacOS, Version 26.0; IBM Corp, Armonk, NY). Continuous variables were denoted as mean and standard deviation, or median and interquartile range in the presence of skewness. Between surgeon differences were assessed by one-way analysis of variance and the Kruskal–Wallis test. Categorical variables were denoted as frequency and percentage and assessed for inter-surgeon differences using the χ^2 test.

To assess the individual surgeons' learning process, non-risk-adjusted cumulative sum (i.e., observed minus expected; CUSUM) failure charts were constructed for the primary outcome measure. CUSUM curves and control boundaries were constructed in Microsoft Excel (Microsoft Corp, Redmond, WA) according to the formulas shown in the Appendix E1 applying statistical principles adapted from Rogers and colleagues [11]. For every failed procedure (i.e., the occurrence of any complication as defined in Table E1) the CUSUM graph was incremented by 1 minus the acceptable complication rate (p_0), whereas the graph was decremented by p_0 for every successful procedure (i.e., absence of complications). The acceptable complication rate was based on previously reported series after the introduction of stabilizers that range from 5% to 26% with an overall mean of 14% [12-19] (Table E2). Since it was not possible to judge all reported complications for significance, an acceptable complication rate of 10% was chosen ($p_0 = 0.10$). The unacceptable complication (p_1) rate was set to 0.20. Crossing of the upper 95% control boundary by the CUSUM curve indicated a significant increase from p_0 to p_1 , whereas crossing of the lower 95% boundary conversely indicated a statistically significant complication rate equal to or lower than p_0 . If a CUSUM graph crossed the lower boundary, it was reset to prevent build-up of credit that can disguise an increase to the unacceptable level [20]. CUSUM curves moving between control limits indicated an average performance. In addition, the comparison of curves of distinct surgeons is merely visual.

The over-time performance regarding the duration of operation, blood loss, and length of hospital stay was assessed using logarithmic regression. Logarithmic regression lines were used because procedures differ among centers (e.g., use of sternal elevation techniques, extent of mediastinal dissection, and techniques to obtain adequate thoracoscopic exposure [e.g., intermittent apnea, single-lung ventilation, or carbon-dioxide insufflation]) that each have their own postoperative protocol and discharge policy as a result of which no average accepted surgery duration and hospital stay can be determined.

RESULTS

Between June 2006 and December 2018, 330 patients operated by 8 individual surgeons underwent repair of pectus excavatum by the Nuss procedure. In total, 108 patients were excluded due to the following reasons: operated by 5 surgeons who performed fewer than 10 procedures after being proctored each ($n = 49$), proctored cases of the other 3 surgeons ($n = 30$), missing Haller index or operation time data ($n = 26$), and previous corrective surgery ($n = 3$).

Eventually, 222 patients operated between December 2008 and 2018 were enrolled. Of these, 190 (86%) were male, with a median age of 17 years (interquartile range, 15-20) and mean preoperative Haller index of 3.9 (standard deviation, 1.3; Table 1). The indication for surgery was multifactorial in all patients, of whom 122 (55%) experienced some degree of cosmetic complaints, whereas 187 (84%) patients described physical complaints. Included patients were operated by 3 distinct surgeons, all of whom were (after their proctoring period) general thoracic surgeons, with 3 (surgeon A and surgeon B) and 4 (surgeon C) years' experience in video-assisted thoracoscopic surgery. There was no structural learning by observation required before being proctored; however, all surgeons incidentally scrubbed on as assistant during their residency. Surgeon B was proctored by surgeon A, who performed 14 procedures at that time (excluding proctored cases), whereas surgeon A himself was proctored by an experienced pectus surgeon from another center. After 3 years of experience and 49 procedures (excluding proctored cases), surgeon B supervised surgeon C during her early learning process. All procedures were assisted by another surgeon or surgical resident and a scrub nurse.

Table 1: Patient, surgeon, and procedural characteristics after an initial proctoring period of 10 procedures.

	Surgeon A	Surgeon B	Surgeon C	P value	All
No. of patients	27	169	26		222
Operation period	Dec 2008 – Jul 2015	Feb 2012 – Dec 2018	Mar 2016 – Dec 2018		Dec 2008 – Dec 2018
Proctored by	Other	Surgeon A	Surgeon B		-
Male, n (%)	21 (78)	149 (88)	20 (77)	0.15	190 (86)
Age, years, median (IQR)	19 (16-24)	17 (15-19)	18 (15-19)	0.081	17 (15-20)
Preoperative Haller index, mean (SD)	3.8 (0.9)	3.9 (1.4)	3.8 (1.1)	0.83	3.9 (1.3)
Number of bars, n (%)				0.31	
One	27 (100)	157 (93)	25 (96)		209 (94)
Two	0 (0)	12 (7)	1 (4)		19 (6)
Stabilizers, n (%)				0.003 ^a	
Left side only	18 (67)	79 (47)	9 (35)	0.057	106 (48)
Right side only	2 (7)	1 (0.6)	0 (0)	0.014 ^b	3 (1)
Both sides	7 (26)	89 (52)	17 (65)	0.010 ^b	113 (51)
Operation time, minutes, median (IQR)	30 (20-40)	30 (25-40)	31 (26-36)	0.66	30 (25-39)
Blood loss, mL, median (IQR)	10 (5-10)	5 (3-10)	5 (5-10)	0.015 ^a	5 (5-10)
Length of hospital stay, days, median (IQR)	5 (4-6)	4 (4-5)	4 (4-5)	0.059	4 (4-5)
Time between consecutive procedures, days, median (IQR)	15 (1-72)	7 (0-19)	35 (7-63)	<0.001 ^a	9 (0-28)

n, number; *SD*, standard deviation; *IQR*, interquartile range; *mL*, milliliter. ^a Statistically significant at $p < 0.05$.

^b Statistically significant at $p < 0.017$ after Bonferroni correction.

Primary outcome: complications

Overall, complications occurred in 20 participants (9%) (Table 2) whose frequency did not significantly differ between surgeons ($P = 1.00$). The majority were bar-related complications and encompassed displacement requiring reoperation ($n = 6$; CDC grade III_b), a protruding bar for which additional bending of the bars' end was performed under general anesthesia ($n = 3$; CDC grade III_b), and bar removal within 1 year following initial surgery ($n = 2$; CDC grade III_b). The latter were due to overcorrection and one case in which the bar migrated through the sternum. Other complications included superficial incisional surgical-site infections that were treated antibioticly or opened at the bedside in 5 patients (CDC grade I-II), pneumonia ($n = 2$; CDC grade II), pneumothorax requiring thoracic drainage ($n = 1$; III_b) and organ/space surgical site infection ($n = 1$ empyema; CDC grade III_b). There was no mortality.

Table 2: Complications.

	Surgeon A	Surgeon B	Surgeon C	P value	All
No. of patients	27	169	26		222
Complications, n (%)	1 (4)	17 (10)	2 (8)	1.00	20 (9)
Superficial incisional SSI	0 (0)	4 (2)	1 (4)		5 (2)
Deep incisional SSI	0 (0)	0 (0)	0 (0)		0 (0)
Organ/space SSI	0 (0)	1 (0.6)	0 (0)		1 (0.5)
Pneumonia	0 (0)	2 (1)	0 (0)		2 (0.9)
Pneumothorax requiring intervention	0 (0)	1 (0.6)	0 (0)		1 (0.5)
Pleural effusion requiring intervention	0 (0)	0 (0)	0 (0)		0 (0)
Reoperation for bleeding	0 (0)	0 (0)	0 (0)		0 (0)
Additional bending bar	0 (0)	3 (2)	0 (0)		3 (1)
Displacement requiring intervention	1 (4)	4 (2)	1 (4)		6 (3)
Early bar removal	0 (0)	2 (1)	0 (0)		2 (0.9)

n, number; SSI, surgical site infection.

CUSUM charts were constructed for all enrolled surgeons after their proctoring period (Figure 1). None demonstrated a typical learning curve, characterized by an initial incline followed by a horizontal run, and decline with increasing experience [20]. All surgeons showed at least an average performance with an initial decline in complications after their proctoring period, whereas the CUSUM curve of surgeon B crossed the lower 95% boundary after 59 cases; indicating a statistically significant complication rate equal to or less than 10%. After crossing of the lower boundary by surgeon B, the CUSUM graph and boundary lines were reset to assess whether the subsequent inclining trend led to an unacceptable

complication rate (Figure 1). After reset, an average experience was observed with a second crossing of the lower 95% boundary after 153 cases whereafter again an average experience was observed.

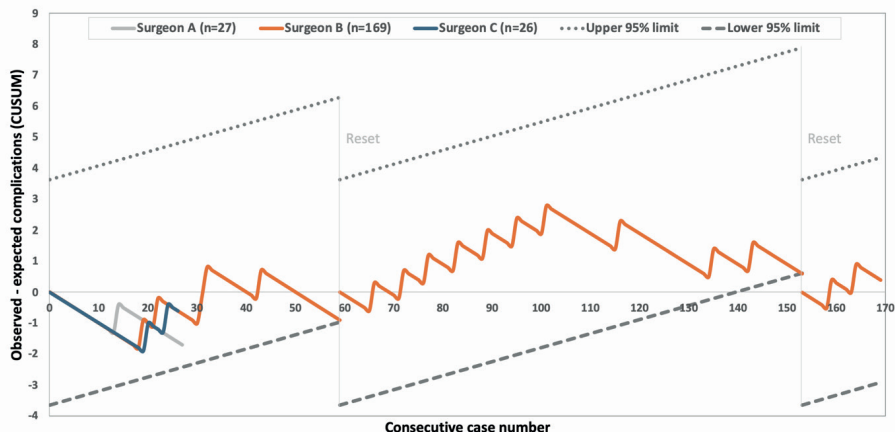


Figure 1: Non-risk-adjusted cumulative sum (i.e., observed minus expected; CUSUM) failure charts (with 95% boundary limits) of complications for 3 individual surgeons, using an acceptable and unacceptable complication rate of 10% and 20%. The CUSUM curve was reset for surgeon B after 59 and 153 cases to eliminate the effect of built-up credit that may disguise an increment to the unacceptable level.

Despite the fact that the median time between consecutive surgeries ranged from 7 to 35 days and significantly differed among individual surgeons ($P < .001$), no relation was found between the frequency of consecutive procedures and complication rate ($P = 1.00$ between individual surgeons), nor the shape of the learning curve that overlapped for all 3 surgeons. In addition, no relation was found between specific complications (e.g., bar-related issues) and the time they occurred during the surgeons' experiences.

Post-hoc sensitivity analyses using an acceptable complication rate of 8% and 6% with a corresponding unacceptable rate of 16% and 12% showed at least an average performance for all surgeons. In other words, using more strict unacceptable complication rates did not lead to crossing of the upper 95% boundary limit that indicates a complication rate greater than 16% and 12%, respectively; see Figure 2A and B.

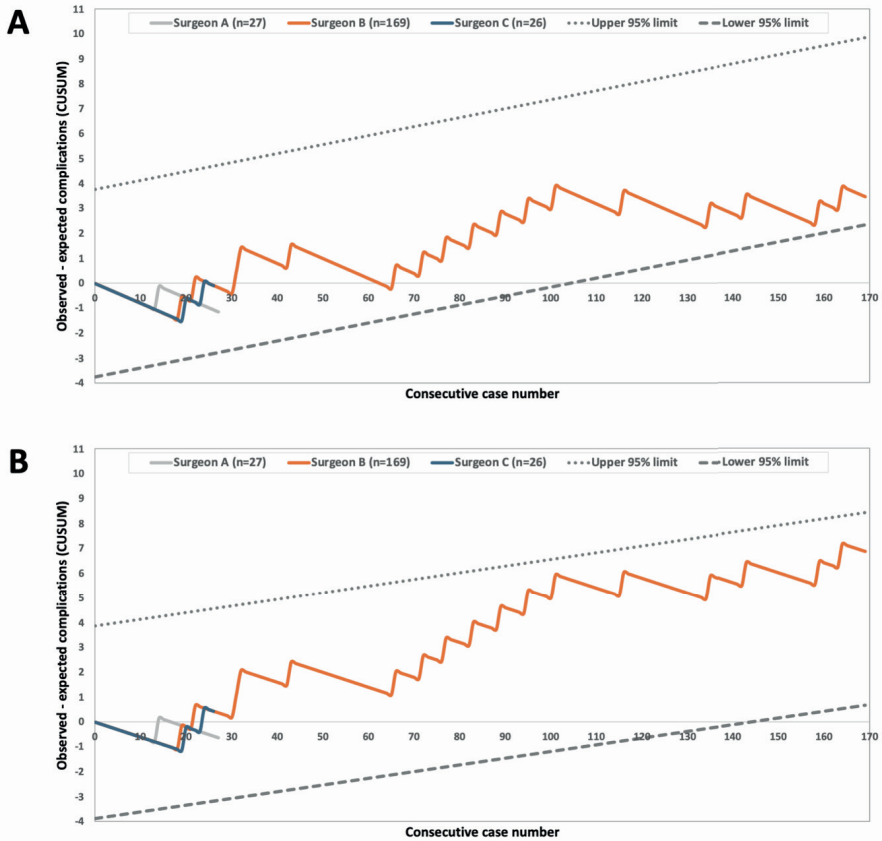


Figure 2: Post-hoc non-risk-adjusted cumulative sum (i.e., observed minus expected; CUSUM) failure charts (with 95% boundary limits) of complications for 3 individual surgeons using an acceptable and unacceptable complication rate of, respectively, (A) 8% and 16% and (B) 6% and 12%.

Secondary outcomes

Median operation times ranged from 30 to 31 minutes (Table 1) and were not different between surgeons ($P = .72$). The logarithmic trend graphs of surgeon A ($P = .68$), surgeon B ($P = .32$), and surgeon C ($P = .88$) revealed that they all required the same average operation time during their experience (Figure 3A-C). The median amount of blood loss showed a narrow range from 5 to 10 mL, whereas the maximum 75th percentile was 10 mL. Despite statistically significant differences between surgeons ($P = .015$), no trend lines were constructed because analyzing such small differences in blood loss would yield no clinical value in conjunction with the fact that blood loss was estimated during surgery and thus

being highly prone to imprecisions. The length of hospital stay demonstrated a decreasing trend for all surgeons. However, this trend was also observed over the enrollment period. Probably this was the result from standardization of postoperative care and enhanced recovery policies rather than the consequence from increasing surgeon experience. As aforementioned, the time between consecutive procedures significantly differed between surgeons; however, no relation was found between frequency and operation time nor length of hospital stay.

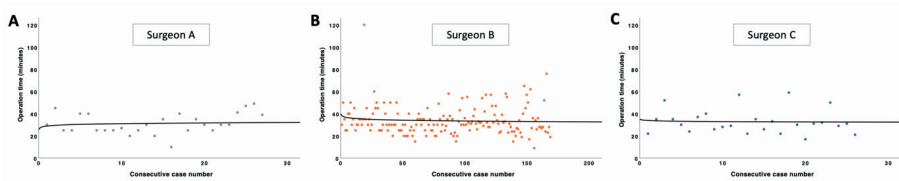


Figure 3: Scatterplot of operation duration over time with logarithmic regression line for (A) surgeon A ($P = .68$), (B) surgeon B ($P = .32$), and (C) surgeon C ($P = .88$), demonstrating a similar average operation time for all surgeons during their entire experience.

The key findings have been emphasized in Figure 4.

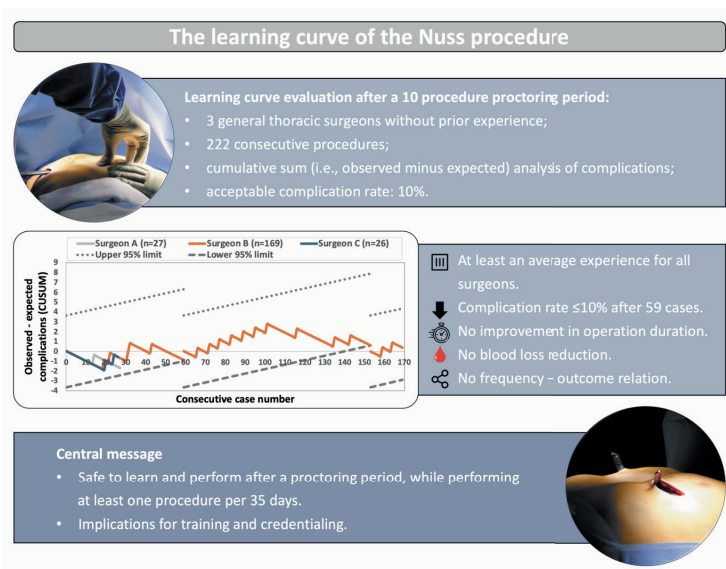


Figure 4: Key findings regarding the learning curve of the Nuss procedure after a 10-procedure proctoring period. Using an acceptable complication rate of 10%, all surgeons demonstrated at least an average experience regarding complications, whereby operation time and blood loss showed no improvement with experience. The Nuss procedure was thus deemed safe to learn and perform after a proctoring period. CUSUM, Cumulative sum.

DISCUSSION

In this single-center retrospective observational cohort study, we analyzed the learning process of minimally invasive repair of pectus excavatum through assessment of consecutive procedural metrics of individual surgeons over a 10-year time period. Two hundred twenty-two Nuss procedures by 3 surgeons performing their first procedures after a proctoring period were evaluated, focusing on intra- and postoperative complications. The overall complication rate of the current series (9%) was within the range of other series, reporting a complication rate between 5% and 26% [12-19] and thus indicating an overall performance similar to peers. CUSUM analyses demonstrated no typical learning curves for all individual surgeons regarding the occurrence of complications. On the contrary, all surgeons revealed an average performance from the first procedure after their proctoring period onward, whereas surgeon B even demonstrated a statistically significant complication rate equal to or lower than 10% after 59 cases. This should not be interpreted as the point, whereafter, surgeons are able to perform the Nuss procedure with lower-than-expected complications since surgeon B “merely” demonstrated an average experience after reset (Figure 1). If the CUSUM graph would have not been reset, a definitive crossing of the lower boundary by the CUSUM curve of surgeon B is observed after 108 cases. This indicates a lower-than-expected complication rate from that point on (Figure 5) with a complication rate that dropped from 11% to 8%. Yet, this is solely based on the experience of a single surgeon and should therefore be confirmed by future analyses.

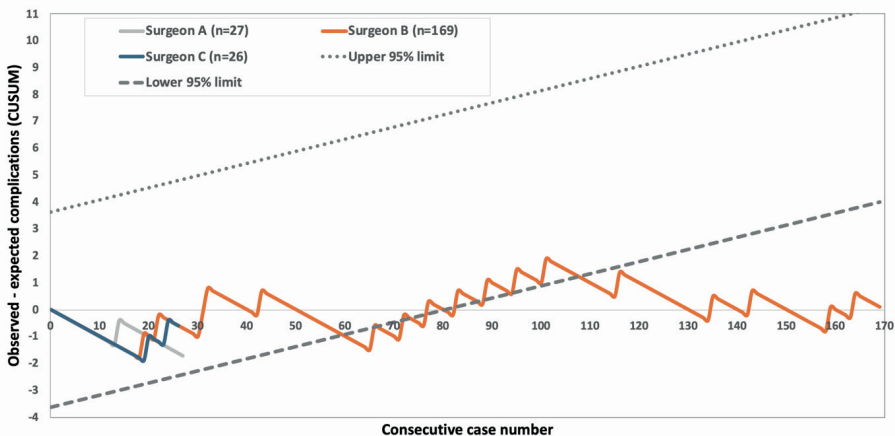


Figure 5: Non-risk-adjusted cumulative sum (i.e., observed minus expected; CUSUM) failure charts (with 95% boundary limits) of complications for 3 individual surgeons, using an acceptable and unacceptable complication rate of 10% and 20% without reset after crossing of the lower 95% limit by the CUSUM graph.

Interpreting CUSUM graph lines, it has to be kept in mind that all surgeons were proctored by an experienced thoracic surgeon during their initial 10 procedures. Such a dedicated proctoring program during the initial experience may facilitate a safe environment to learn the Nuss procedure but may also provide a continuing experience with acceptable complication rates, as observed in the current series. These results can therefore not be applied to centers aiming to start their Nuss procedure program without dedicated supervision.

All procedures were assisted by another surgeon or surgical resident, which may in theory have avoided complications. Yet, the task of the assistant was limited to creation of the left-sided subcutaneous pocket and application of the stabilizer, whereas the operating surgeon was always in charge and made all calls. The assistants' influence on outcomes was therefore assumed to be minimal.

Evaluated surgeons were likely to perform more difficult cases with improving experience, potentially introducing selection bias. This was not confirmed by the preoperatively measured Haller index that showed no increasing trend with experience and was comparable between surgeons ($P = .83$). Although not statistically significant, surgeon B more often implanted multiple bars to correct the deformity (7% vs 0% and 4% for surgeon A and surgeon C) of which 83% of cases were operated further down the learning curve (i.e., after 100 cases).

The relationship between frequency of exposure and outcome is an extensively discussed topic because it may advocate centralization in high-volume tertiary referral centers. Although the longest median time between consecutive procedures was 35 days for surgeon C, we found no relation between frequency and outcome of individual surgeons.

The most common complication was displacement of the bar requiring reoperation in 6 (3%) participants, which was at the lower end (range, 2%-7%) of previously reported series [12-19]. Castellani and colleagues [8] and Ong and colleagues [6] both argued that the bar displacement rate is closely related to the learning curve. Yet, we found no declining trend with increasing experience. In our opinion, declining displacement rates since the early introduction of the Nuss procedure is primarily caused by modifications and optimization of the technique itself, as demonstrated by Kelly and colleagues [7] who found the rate to decrease from 13% to 1% following the introduction of metallic stabilizers, pericostal polydioxanone sutures, as well as using short bars with correct configuration. In our series stabilizers were used in all participants, while we secured the bar additionally using polydioxanone sutures until late 2017. Another factor known to be associated with a 15- to

25-times increased displacement risk is an eccentric long canal type pectus excavatum (i.e., Grand Canyon type) [12]. Yet, we found no Grand Canyon types among participants that suffered from bar displacement.

In an effort to diminish localized symptoms (e.g., soft-tissue irritation), softer and braided materials were employed to attach the stabilizer to the bar during the enrollment period. Initially, wire cerclages were used, of which the drawbacks are well-documented. Park and colleagues [12] observed a considerable wound seroma rate of 4.5% using a 5-point wire cerclage fixation, whereas Uemura and colleagues [21] even reported wire removal due to skin irritation in 2% of patients. However, in our series, no cerclage wires were removed due to irritation. Following the switch to FiberWire and Hi-Fi sutures, we observed no increase in displacement rates. In addition, in case of using a unilateral left-sided stabilizer, the right end was initially fixated by a pericostal polydioxanone suture; however, with advancing insights the pericostal suture was left (mid-2017) since it was hypothesized to yield no additional stability were in the event of inadequate stability, we applied bilateral stabilizers. Both the switch to softer, braided materials for stabilizer fixation and leaving fixation of the bars' right end was deemed safe since 5 of the 6 bar displacements that required reoperation occurred before these alterations.

In the current study, we chose the absence of complications during or after the Nuss procedure (i.e., a safe procedure) as primary outcome measure because it is the most common method to evaluate surgical and interventional procedures [22]. Nevertheless, a learning curve based on patient-reported outcomes (e.g., cosmetic result and patient satisfaction) may also be of interest whereas pectus excavatum is in part a cosmetic disorder with inherent psychosocial burden and should therefore be subject of future research.

The main limitation of the current study is its retrospective design and inherent bias. Bias due to missing data was present, prompting exclusion of 26 participants due to missing Haller index or operation time and especially affecting cases during the early enrollment period. Another limitation is the aforementioned potential bias due to selection of patients and the use of non-risk-adjusted CUSUM charts. However, it was not possible to construct risk-adjusted charts since no models exist to preoperatively determine the prior chance on complications during or after the Nuss procedure. The number of analyzed surgeons with a high caseload was low and unlikely to comprise the full extent of surgeon diversity and learning curves. The objective of future studies should therefore be to analyze reproducibility of constructed learning curves.

CONCLUSIONS

In conclusion, minimally invasive repair of pectus excavatum by the Nuss procedure is a safe procedure to adopt and perform after a 10-procedure proctoring period without a typical (complication based) learning curve, performing at least 1 procedure per 35 days. Future studies should corroborate the reproducibility of this single-center experience and focus on patient-reported outcomes.

REFERENCES

1. Brochhausen C, Turial S, Muller FKP, Schmitt VH, Coerdts W, Wihlm J-M, et al. Pectus excavatum: history, hypotheses and treatment options. *Interact Cardiovasc Surg.* 2012;14:801-6.
2. Chung CS, Myriantopoulos NC. Factors affecting risks of congenital malformations. I. Analysis of epidemiologic factors in congenital malformations. Report from the collaborative perinatal project. *Birth Defects Orig.* 1975;11:1-22.
3. Coskun ZK, Turgut HB, Demirsoy S, Cansu A. The prevalence and effects of pectus excavatum and pectus carinatum on the respiratory function in children between 7-14 years old. *Indian J Pediatr.* 2010;77:1017-9.
4. Mao YZ, Tang S, Li S. Comparison of the Nuss versus Ravitch procedure for pectus excavatum repair: an updated meta-analysis. *J Pediatr Surg.* 2017;52:1545-52.
5. Lam MW, Klassen AF, Montgomery CJ, LeBlanc JG, Skarsgard ED. Quality-of-life outcomes after surgical correction of pectus excavatum: a comparison of the Ravitch and Nuss procedures. *J Pediatr Surg.* 2008;43:819-25.
6. Ong CC, Choo K, Morreau P, Auldist A. The learning curve in learning the curve: a review of Nuss procedure in teenagers. *ANZ J Surg.* 2005;75:421-4.
7. Kelly RE, Goretsky MJ, Obermeyer R, Kuhn MA, Redlinger R, Haney TS, et al. Twenty-one years of experience with minimally invasive repair of pectus excavatum by the Nuss procedure in 1215 patients. *Ann Surg.* 2010;252:1072-81.
8. Castellani C, Schalamon J, Saxena AK, Höellwarth ME. Early complications of the Nuss procedure for pectus excavatum: a prospective study. *Pediatr Surg Int.* 2008;24:659-66.
9. Vandembroucke JP, von Elm E, Altman DG, Gøtzsche PC, Mulrow CD, Pocock SJ, et al. Strengthening the reporting of observational studies in epidemiology (STROBE): explanation and elaboration. *PLoS Med.* 2007;4:e297.
10. Clavien PA, Barkun J, de Oliveira ML, Vauthey JN, Dindo D, Schulick RD, et al. The Clavien-Dindo classification of surgical complications: five-year experience. *Ann Surg.* 2009;250:187-96.
11. Rogers CA, Reeves BC, Caputo M, Ganesh JS, Bonser RS, Angelini GD. Control chart methods for monitoring cardiac surgical performance and their interpretation. *J Thorac Cardiovasc Surg.* 2004;128:811-9.
12. Park HJ, Lee SY, Lee CS. Complications associated with the nuss procedure: analysis of risk factors and suggested measures for prevention of complications. *J Pediatr Surg.* 2004;39:391-5.
13. Kelly RE Jr, Shamberger RC, Mellins RB, Mitchell KK, Lawson ML, Oldham K, et al. Prospective multicenter study of surgical correction of pectus excavatum: design, perioperative complications, pain, and baseline pulmonary function facilitated by internet-based data collection. *J Am Coll Surg.* 2007;205:205-16.
14. Pilegaard HK, Licht PB. Early results following the Nuss operation for pectus excavatum—a single-institution experience of 383 patients. *Interact Cardiovasc Thorac Surg.* 2008;7:54-7.
15. Fallon SC, Slater BJ, Nuchtern JG, Cass DL, Kim ES, Lopez ME, et al. Complications related to the Nuss procedure: minimizing risk with operative technique. *J Pediatr Surg.* 2013;48:1044-8.
16. Papic JC, Finnell SM, Howenstein AM, Breckler F, Leys CM. Postoperative opioid analgesic use after Nuss versus Ravitch pectus excavatum repair. *J Pediatr Surg.* 2014;49:919-23.
17. Pilegaard HK. Nuss technique in pectus excavatum: a mono-institutional experience. *J Thorac Dis.* 2015;7:S172-6.

18. Sacco Casamassima MG, Gause C, Goldstein SD, Karim O, Swarup A, Mclltrot K, et al. Patient satisfaction after minimally invasive repair of pectus excavatum in adults: long-term results of nuss procedure in adults. *Ann Thorac Surg.* 2016;101:1338-45.
19. Garzi A, Prestipino M, Rubino MS, Di Crescenzo RM, Calabr'o E. Complications of the "nuss procedure" in pectus excavatum. *Transl Med UniSa.* 2020;22:24-7.
20. Holzhey DM, Jacobs S, Walther T, Mochalski M, Mohr FW, Falk V. Cumulative sum failure analysis for eight surgeons performing minimally invasive direct coronary artery bypass. *J Thorac Cardiovasc Surg.* 2007;134:663-9.
21. Uemura S, Nakagawa Y, Yoshida A, Choda Y. Experience in 100 cases with the Nuss procedure using a technique for stabilization of the pectus bar. *Pediatr Surg Int.* 2003;19:186-9.
22. Biau DJ, Resche-Rigon M, Godiris-Petit G, Nizard RS, Porcher R. Quality control of surgical and interventional procedures: a review of the CUSUM. *Qual Saf Health Care.* 2007;16:203-7.

SUPPLEMENTARY DATA

Video 1:

Available at: [https://www.jtcvs.org/article/S0022-5223\(20\)33303-1/fulltext](https://www.jtcvs.org/article/S0022-5223(20)33303-1/fulltext)

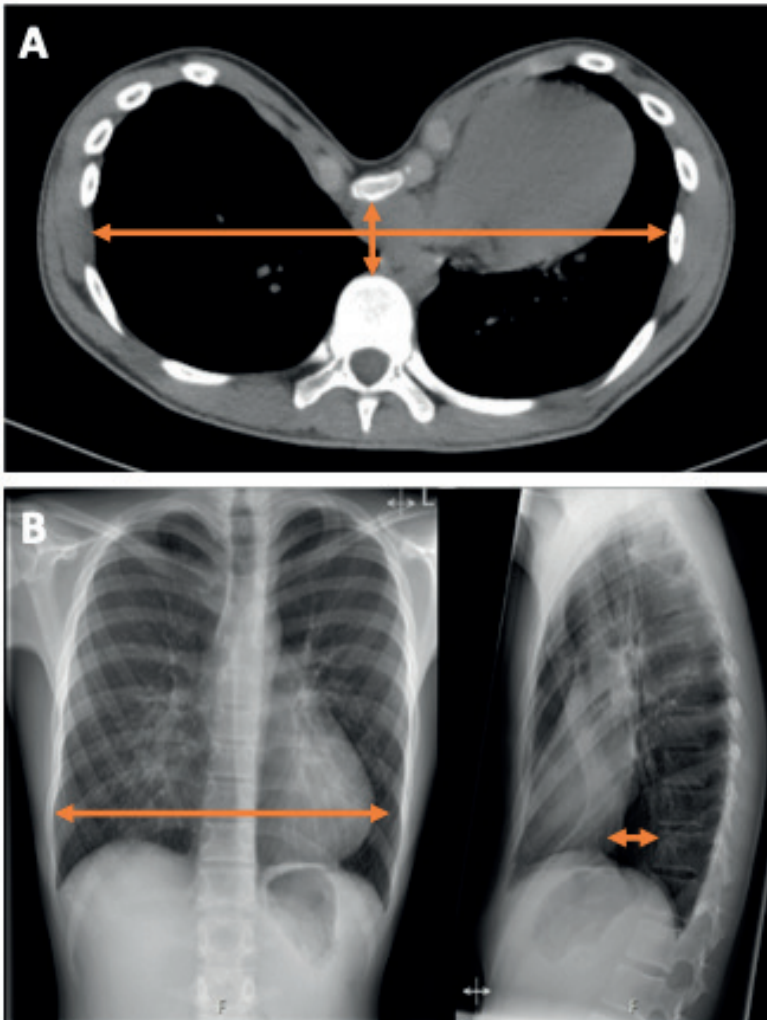


Figure E1: Haller index. The Haller index: calculated from either (A) computed tomography or (B) 2-view plain chest radiographies by dividing the widest intrathoracic transverse diameter by the anteroposterior distance between the posterior sternal surface and anterior vertebral surface at the level of most severe depression. A Haller index value larger than or equal to 3.25 is considered as indication for corrective surgery [E1].

Appendix E1 Cumulative sum analysis

The statistical principles were adapted from Rogers and colleagues [E4]. Cumulative sum (i.e., observed minus expected; CUSUM) charts and boundary lines were constructed and required the following input:

- The acceptable complication rate (p_0) that was set to 0.10 in the current series and based on the complication rates depicted in Table E2.
- The unacceptable complication rate (p_1) that was set to 0.20 (i.e., twice the acceptable complication rate).
- The type-I error (α); i.e., the probability of assuming that the complication rate has increased to p_1 when it has not. In the current series, an α of 0.05 was selected to construct 95% upper boundaries.
- The type-II error (β); i.e., the probability of assuming that the complication rate has not increased when it has. In the current series, a β of 0.05 was selected to construct 95% lower boundaries.

The CUSUM of the i^{th} Nuss procedure was in the absence of a complication defined by:

$$(1) \text{CUSUM}_n = \sum_{i=0}^n (X_i - p_0)$$

whereby $X_i = 0$ indicates the absence and $X_i = 1$ the presence of a complication. The lower boundary (l_0) that depicts a failure rate equal to or lower than p_0 was defined by:

$$(2) l_0 = i * \left(\frac{\ln\left(\frac{1-p_0}{1-p_1}\right)}{\ln\left(\frac{p_1(1-p_0)}{p_0(1-p_1)}\right)} - p_0 \right) - \left(\frac{\ln\left(\frac{1-\alpha}{\beta}\right)}{\ln\left(\frac{p_1(1-p_0)}{p_0(1-p_1)}\right)} \right)$$

The upper boundary (l_1) depicts an increase from p_0 to p_1 and was defined by:

$$(3) l_1 = i * \left(\frac{\ln\left(\frac{1-p_0}{1-p_1}\right)}{\ln\left(\frac{p_1(1-p_0)}{p_0(1-p_1)}\right)} - p_0 \right) + \left(\frac{\ln\left(\frac{1-\beta}{\alpha}\right)}{\ln\left(\frac{p_1(1-p_0)}{p_0(1-p_1)}\right)} \right).$$

Table E1: Definitions of complications.

Complication	Definition
Superficial incisional SSI	Infection occurring within 30 days following surgery that only involves the skin or subcutaneous tissue with at least one of the following: purulent drainage; positive culture of the superficial incision or fluid; or at least one of the following symptoms (in combination with a positive culture or the wound being deliberately opened): pain or tenderness, localized swelling, redness or heat [E2].
Deep incisional SSI	Infection occurring within 1 year after surgery that involves the deep soft tissues, appears be related to the procedure and at least one of the following: purulent drainage from the deep incision; spontaneous dehiscent or deliberately opening of the wound with at least one of the following symptoms (in combination with a positive or absent culture): temperature >38 degrees, and pain or tenderness; an abscess or other evidence of a deep incisional infection found during reoperation, on direct examination, radiologic examination or histopathologic examination [E2].
Organ/space SSI (e.g., empyema)	Infection occurring within 1 year after surgery, related to the operative procedure, involving any anatomy part (e.g., spaces or organs), and at least one of the following: purulent drainage from a transcutaneous drain; positive culture from fluid or tissue in the organ/space; an abscess or other evidence of an organ/space confining infection found during reoperation, on direct examination, radiologic examination or histopathologic examination [E2].
Pneumonia	The presence of a new lung infiltrate plus clinical evidence that the infiltrate is of an infectious origin, which include the onset of fever, purulent sputum, leukocytosis, and decline in oxygenation [E3], within 30 days following initial surgery.
Pneumothorax requiring intervention	Radiographically confirmed pneumothorax that occurs within 30 days after surgery and is symptomatic (dyspnea, tachypnea, decline in oxygenation et cetera) requiring intervention (e.g., needle aspiration, chest tube drainage).
Empyema	Empyema was scored according to the above-mentioned organ/space SSI definition.
Pleural effusion requiring intervention	Radiographically proven and symptomatic (e.g., dyspnea, tachypnea) pleural effusion within 30 days after surgery requiring intervention (e.g., needle aspiration, chest tube drainage).
Reoperation for bleeding	Postoperative bleeding within 30 days after surgery requiring reoperation.
Additional bending bar end	Localized pain or tenderness, or skin irritation that is attributable to protrusion of the bars' end(s), occurring within 3 months after surgery and requiring addition bending under general anesthesia.
Displacement requiring reoperation	Radiographically confirmed displacement of the metal bar(s) or stabilizer(s) requiring reoperation within 3 months follow initial surgery.
Early bar removal	Removal of the bar(s) for any cause within 1 year following initial surgery (e.g., due to overcorrection).

SSI, surgical site infection.

Table E2: Complications of the Nuss procedure with the use of stabilizer(s).

Study	Complication rate
Park et al., (2004) [E5]	16%
Kelly et al., (2007) [E6]	10% ^a
Pilegaard et al., (2008) [E7]	15%
Fallon et al., (2013) [E8]	26% ^b
Papic et al., (2014) [E9]	10%
Pilegaard et al., (2015) [E10]	5%
Saco Casamassima et al., (2018) [E11]	14% ^c
Garzi et al., (2020) [E12]	12% ^d
Mean	14%

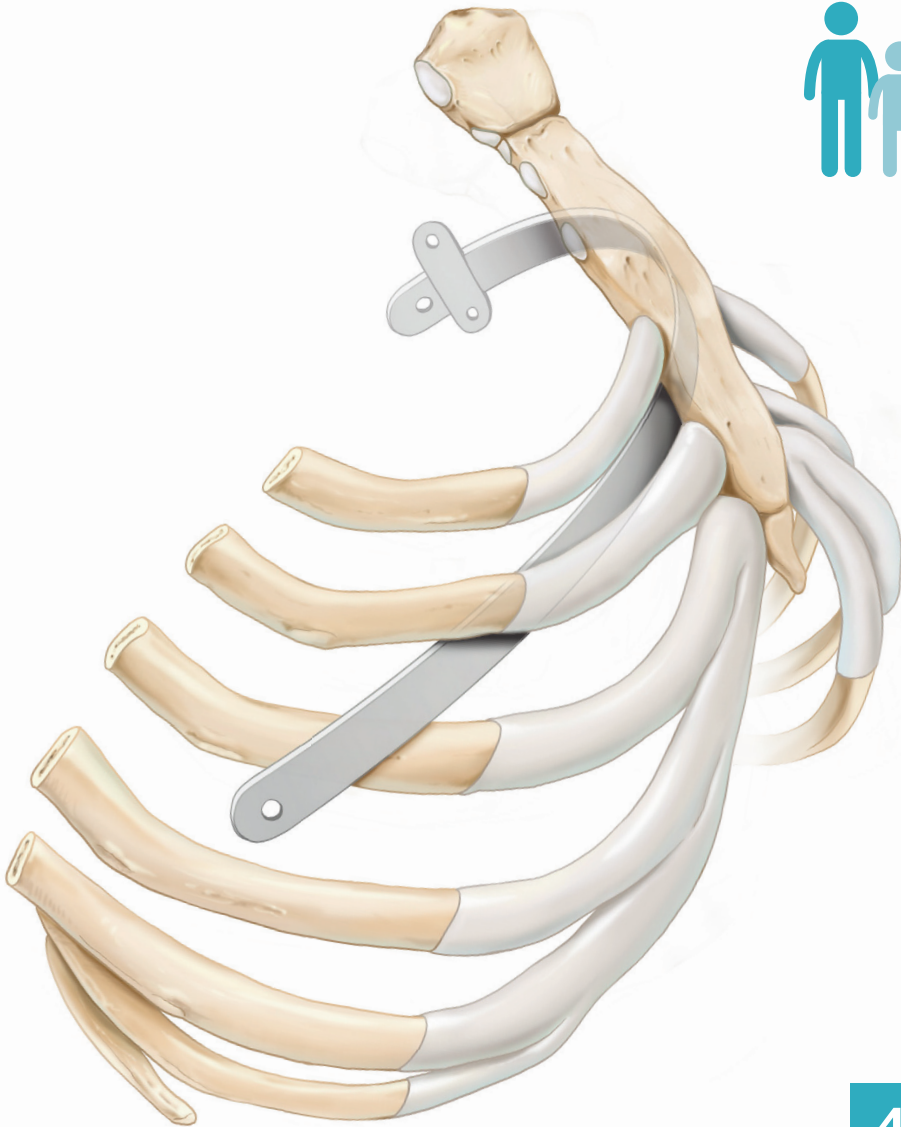^a Excluding pleural effusion, atelectasis, skin rash and Horner's syndrome because they were considered not clinically significant. ^b Minor and major complications combined, introducing potential overestimation upon occurrence of multiple complications in one patient. ^c Excluding pneumothoraxes, pleural effusion and hemothorax that did not require intervention, noninfectious wound drainage, broken wire, rib fracture, upper sternal depression while the bar was in situ, overcorrection in carinatum deformity and prolonged chest pain because they were considered not clinically significant. ^d Excluding pericardium opening, hypotension on waking, pleural effusion, lung thickenings and minor neurological deficits because they were considered not clinically significant.

E-REFERENCES

- E1. Haller JA, Colombani PM, Humphries CT, Azizkhan RG, Loughlin GM. Chest wall constriction after too extensive and too early operations for pectus excavatum. *Ann Thorac Surg.* 1996;61:1618-25.
- E2. Horan TC, Gaynes RP, Martone WJ, Jarvis WR, Emori TG. CDC definitions of nosocomial surgical site infections, 1992: a modification of CDC definitions of surgical wound infections. *Am J Infect Control.* 1992;20:271-4.
- E3. Kalil AC, Metersky ML, Klompas M, Muscedere J, Sweeney DA, Palmer LB et al. Management of Adults With Hospital-acquired and Ventilator-associated Pneumonia: 2016 Clinical Practice Guidelines by the Infectious Diseases Society of America and the American Thoracic Society. *Clin Infect Dis.* 2016;63:e61-e111.
- E4. Rogers CA, Reeves BC, Caputo M, Ganesh JS, Bonser RS, Angelini GD. Control chart methods for monitoring cardiac surgical performance and their interpretation. *J Thorac Cardiovasc Surg.* 2004;128:811-9.
- E5. Park HJ, Lee SY, Lee CS. Complications associated with the nuss procedure: analysis of risk factors and suggested measures for prevention of complications. *J Pediatr Surg.* 2004;39:391-95.
- E6. Kelly RE, Jr., Shamberger RC, Mellins RB, Mitchell KK, Lawson ML, Oldham K et al. Prospective multicenter study of surgical correction of pectus excavatum: design, perioperative complications, pain, and baseline pulmonary function facilitated by internet-based data collection. *J Am Coll Surg.* 2007;205:205-16.
- E7. Pilegaard HK, Licht PB. Early results following the Nuss operation for pectus excavatum – a single-institution experience of 383 patients. *Interact Cardiovasc Thorac Surg.* 2008;7:54-57.
- E8. Fallon SC, Slater BJ, Nuchtern JG, Cass DL, Kim ES, Lopez ME et al. Complications related to the Nuss procedure: minimizing risk with operative technique. *J Pediatr Surg.* 2013;48:1044-8.
- E9. Papic JC, Finnell SM, Howenstein AM, Breckler F, Leys CM. Postoperative opioid analgesic use after Nuss versus Ravitch pectus excavatum repair. *J Pediatr Surg.* 2014;49:919-23.
- E10. Pilegaard HK. Nuss technique in pectus excavatum: a mono-institutional experience. *J Thorac Dis.* 2015;7:S172-S76.
- E11. Sacco Casamassima MG, Gause C, Goldstein SD, Karim O, Swarup A, McClrot K et al. Patient Satisfaction After Minimally Invasive Repair of Pectus Excavatum in Adults: Long-Term Results of Nuss Procedure in Adults. *Ann Thorac Surg.* 2016;101:1338-45.
- E12. Garzi A, Prestipino M, Rubino MS, Di Crescenzo RM, Calabrò E. Complications of the "Nuss Procedure" In Pectus Excavatum. *Transl Med UniSa.* 2020;22:24-27.

De Loos ER*, Pennings AJ*, van Roozendaal LM, Daemen JHT, van Gool MH, Lenderink T, van Horck M, Hulsewé KWE, Vissers YLJ.
Ann Thorac Surg. 2021;112(3):905-911.

*equal contribution status



4

Nuss procedure for pectus excavatum:

a comparison of complications between
young and adult patients

ABSTRACT

Background

The Nuss procedure is the gold standard surgical treatment for pectus excavatum in young patients. Its use in adults has also been described, although it may be associated with increased postoperative morbidity resulting from higher chest wall rigidity. This study aimed to examine the risk of complications after the Nuss procedure in adult patients compared with young patients with pectus excavatum.

Methods

This single-center retrospective cohort study evaluated all patients who underwent the Nuss procedure between 2006 and 2018. Patients were stratified by age as young (≤ 24 years old) and adult (> 24 years old). The primary end point was the occurrence of perioperative or postoperative complications, subdivided into major (Clavien-Dindo class III_a or higher) and minor (less severe than Clavien-Dindo class III). Between-group differences were analyzed using the Mann-Whitney U and Chi-square test with post hoc analysis.

Results

A total of 327 participants were included, 272 in the young group (median age, 16 years; interquartile range [IQR], 15 to 18 years; range, 11 to 24 years) and 55 in the adult group (median age, 32 years; IQR, 27 to 38 years; range, 25 to 47 years). The median Haller index was similar between groups (young, 3.7; IQR, 3.2 to 4.4 vs adult, 3.6; IQR, 3.0 to 4.3; $P=0.44$). The median follow-up was 34 and 36 months, respectively. The incidence of major complications was comparable between young and adult participants ($P=0.43$). Minor complications occurred more often among adults (young, 4% vs adult, 11%; $P=0.002$). Chronic postoperative pain was the only minor complication with a significant difference in incidence (young, 1% vs adult, 7%; $P=0.008$).

Conclusions

The Nuss procedure is a safe surgical treatment for pectus excavatum both in young and adult patients. The risk of major complications is comparable. However, adults more often have chronic pain.

INTRODUCTION

Pectus excavatum is the most common congenital chest wall deformity, characterized by depression of the sternum and adjacent costal cartilage. It occurs in approximately 1 in 400 to 1000 persons and is more prevalent among boys and men [1]. Pectus excavatum often becomes more severe during the adolescent growth spurt. It may cause physical symptoms related to pulmonary- and cardiac impairment, as well as psychological stress resulting from diminished self-esteem and an impaired body image perception [2-4]. In past decades several operative and nonoperative techniques have been developed to correct the deformity. The most frequently performed surgical techniques are the modified Ravitch procedure and minimally invasive Nuss procedure. The modified Ravitch procedure is an open repair, in which the affected rib cartilage is resected and the sternal deformity is corrected by wedge osteotomy [5, 6]. During the Nuss procedure, 1 or multiple retrosternal metal bars are implanted to instantaneously correct the thoracic deformity [7]. This technique has gained widespread popularity because of its minimal invasive approach, as evidenced by small skin incisions, no need for cartilage resection, short operative time, minimal blood loss [8] and comparable postoperative morbidity [9] with respect to the modified Ravitch procedure. The Nuss procedure is currently considered the gold standard treatment technique among adolescents. Its use in adult patients has also been described as feasible even though it is more difficult because of increased chest wall rigidity and potentially increased postoperative morbidity. The aim of this single-center retrospective cohort study was to examine the risk of complications after the Nuss procedure in adult patients compared with young patients with pectus excavatum. In particular, chronic pain and bar displacement were hypothesized to occur more frequently among adult patients given their increased chest wall rigidity.

MATERIALS AND METHODS

Study design

This retrospective single-center cohort study was conducted at Zuyderland Medical Center, Heerlen, the Netherlands. Zuyderland Medical Center is a large teaching hospital and tertiary referral center for pectus and chest wall surgery. All participants' characteristics were retrospectively collected from the electronic patient records. Before the study began, it was approved by the local Ethical Committee for Scientific Research (METC Zuyderland, ID: METCZ20180140, date of approval: December 6th, 2018). The study was conducted in accordance with the Declaration of Helsinki and reported in compliance with the current

Strengthening the Reporting of Observational Studies in Epidemiology (STROBE) guidelines for observational studies [19].

Patient work-up

Patients were screened in a multidisciplinary setting, consisting of outpatient clinic visits to a thoracic surgeon, pediatrician and, if required cardiologist. Standard workup included 2-view chest radiographs or chest computed tomography, in addition to visual documentation of the deformity by a medical photographer. Additional computed tomography (if not already performed) and magnetic resonance imaging scans were acquired when indicated to assess cardiac impression or to exclude additional diagnoses.

Methods

All consecutive patients undergoing the Nuss procedure for correction of symptomatic pectus excavatum at our center between June 2006 and December 2018 were retrospectively analyzed. Patients with confirmed connective tissue disorders (e.g., Marfan or Ehlers Danlos syndrome) and patients with previous surgical interventions for pectus were excluded. The study population was divided into 2 groups: young patients and adult patients. Young patients were defined as patients 24 years old or younger, according to the definition of the World Health Organization [20], and adult patients were defined as those older than 24 years of age. The following baseline and perioperative variables were recorded: age, sex, preoperative symptoms, Haller index, operation time, number of bars inserted, bar length, number of stabilizers used, and length of hospital stay. The primary end point was the occurrence of perioperative and postoperative complications, with special attention paid to chronic pain and bar displacement. Complications were defined as stated in Table 1 and were graded using the Clavien-Dindo Classification (CDC) to be subdivided into major (CDC III_a or higher) and minor complications (less severe than CDC III) [21].

Table 1: Definitions of complications.

Complication	Definition
Bar displacement requiring reoperation	Radiographically confirmed displacement of the stabilizer(s) or metal bar(s) requiring surgical intervention within 3 months following surgery.
Additional bar bending	Localized pain or tenderness, or skin irritation that is attributable to protrusion of the end of the bar(s), occurring within 3 months after surgery, and requiring additional bending of the bar under general anesthesia.
Bar removal within 3 years for chronic pain	Removal of the implanted metal bar(s) within 3 years due to chronic pain that is unresponsive to additional pain therapies as given by a dedicated pain team.
Bar removal for any other cause within 1 year	Removal of the implanted metal bar(s) for any cause other than chronic pain within 1 year after initial surgery.
Reoperation for bleeding	Postoperative bleeding requiring reoperation within 30 days after initial surgery.
Pneumothorax requiring intervention	A radiographically confirmed pneumothorax that is symptomatic (dyspnea, decline in oxygenation, tachypnoea) requiring intervention (e.g., chest tube drainage), within 30 days after surgery.
Empyema	Pleural or thoracic cavity confining infection occurring within 1 year following surgery with at least one of the following: purulent drainage from a transcutaneous drain, positive culture, or an infection found during reoperation, on examination, radiologic examination or histopathologic examination [29].
Wound infection	The presence of purulent drainage, a positive culture and/or the need for surgical wound drainage or reoperation within 30 days following surgery [29]. Wound infections were, moreover, divided based on their treatment; surgical drainage or antibiotic treatment.
Pneumonia	The presence of a new radiographic infiltrate, in combination with fever, purulent sputum, a decline in oxygenation and leukocytosis within 30 days following surgery [30].
Chronic pain without bar removal	Persistent postoperative thoracic pain after three months that is not controlled by standard analgesia and requires consultation of a dedicated pain team for relief. Relief of symptoms was assessed through patient reported outcomes. (Patients without chronic pain were not consulted by a dedicated pain team).

Surgical technique

The surgical technique of the Nuss procedure has been extensively described elsewhere [22]. The patient was placed in supine position. Prophylactic cefazoline was administered. The operation was performed using epidural and general anesthesia with single-lung ventilation. The right lung was excluded from ventilation to allow thoracoscopic guidance without the need for carbon dioxide insufflation or intermittent apnea. External pectus dimensions, including the deepest point, were skin marked. By using a template, the adequate pectus bar size was selected and bent to the desired curvature. Through an

axillary 10-mm trocar, a 30-degree thoracoscope was introduced into the right pleural cavity. Through 2 small bilateral incisions, subcutaneous pockets were created in the prefascial plane. Under thoracoscopic guidance, the introducer was inserted into the pleural cavity from the right side and passing the anterior mediastinal soft tissue in close contact with the sternum to be again passed through the left thoracic wall. After preliminary correction of the deformity using the introducer, the definitive prebent correctional metal bar (Biomet Microfixation, Jacksonville, Florida, USA) was placed in the retrosternal space under thoracoscopic guidance. Standard policy was to place a single left-sided stabilizer because the bar is ordinarily removed from left side, thus requiring solely unilateral re-exploration, and minimizing surgical trauma. Where needed to achieve adequate stability, bilateral stabilizers were used. Stabilizers were attached to the bar with steel wires, polydioxanone sutures or FiberWire. A second bar was used in case of insufficient correction by a single bar, for example, in elongated (trench-type) pectus or when pressure distribution was indicated in severe sternal depression.

Postoperative course

A postoperative chest radiograph was acquired to confirm bar positioning and assess signs of pneumo- or hemothorax. Postoperative pain management consisted of epidural or continuous intravenous medication during the first 3 postoperative days. Physiotherapy started on the first day postoperative in all patients. Patients were discharged when sufficient mobilization and adequate pain control were achieved. Standard follow-up consisted of outpatient clinic visits at 2 weeks, 3 months, and 1, 2 and 3 years postoperatively. Standard policy was to remove the bar after 3 years.

Statistical analyses

Statistical analyses were performed using SPSS (IBM Corp. IBM SPSS Statistics for Windows, Version 24.0, Armonk, NY, USA). Continuous data were summarized as mean value and standard deviation (SD), whereas the median and interquartile range (IQR) were used in the presence of skewness. Between-group differences were assessed using the independent samples t-test, or the non-parametric Mann-Whitney U test. Categorical variables were submitted to the Chi-square test with post hoc analyses through the Fisher exact test and Bonferroni correction, or the Fisher exact test alone. A P-value <0.05 was considered statistically significant. Missing data were omitted from analyses and were reported as such.

RESULTS

A total of 330 patients underwent the Nuss procedure during the enrollment period; 3 of these patients were excluded because of prior surgical interventions for pectus excavatum. Baseline patients' characteristics are shown in Table 2. A total of 327 patients were included and were subdivided in a young group (n = 272; median age, 16 years; IQR, 15 to 18 years; range, 11 to 24 years) and an adult group (n = 55; median age, 32 years; IQR, 27 to 38 years; range, 25 to 47 years). The age distribution for the study group is depicted in Figure 1. Both groups had a similar sex distribution (86% males in the young group vs 87% in the adult group). The median length of postoperative follow-up was 34 months (IQR, 14 to 39 months) for the young group and 36 months (IQR, 24 to 46 months) for the adult group. The most frequently reported preoperative symptoms included exercise intolerance and psychosocial symptoms, and the psychosocial symptoms were more frequently observed in the young group ($P < 0.001$) (Table 2). Participants in the adult group had heart palpitations more often than did participants in the young group ($P = 0.002$). All other reported symptoms did not significantly differ between the groups. The median severity of pectus excavatum, measured with the Haller index, was comparable: 3.7 (IQR, 3.2 to 4.4, n = 227) for the young group vs 3.6 (IQR, 3.0 to 4.3; n = 50) for the adult group ($P = 0.44$).

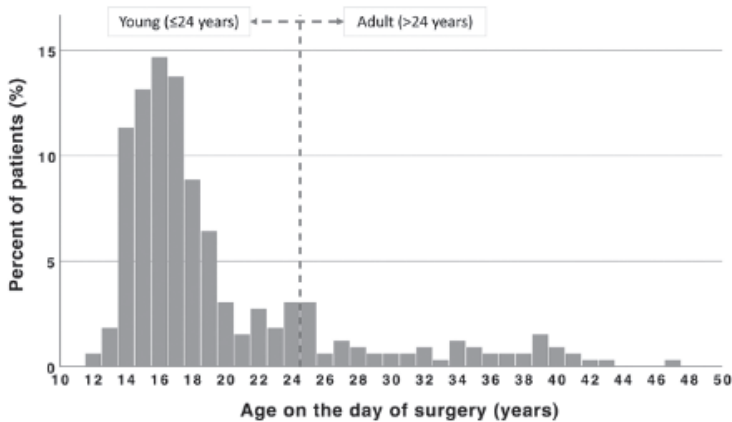


Figure 1: Distribution of age in all included patients (n=327).

Table 2: Baseline patient characteristics.

	Young (n=272)	Adult (n=55)	P-value
Age in years, median (IQR; range)	16 (15–18; 11–24)	32 (27–38; 24–57)	<0.001 ^a
Gender, n (%)			>0.99
Male	233 (86)	48 (87)	
Female	39 (14)	7 (13)	
Preoperative symptoms, n (%)			
Exercise intolerance	177 (65)	40 (73)	0.35
Psychosocial complaints	154 (57)	15 (27)	<0.001 ^a
Dyspnea at rest	58 (21)	12 (22)	>0.99
Angina pectoris	50 (18)	10 (18)	>0.99
Chest pain other than angina pectoris	33 (12)	11 (20)	0.13
Palpitations	45 (17)	19 (35)	0.004 ^a
Fatigue	10 (4)	2 (4)	>0.99
Haller index, median (IQR)	3.7 (3.2–4.4); n=227	3.6 (3.0–4.3); n=50	0.44

n, number; *IQR*, interquartile range; *mL*, milliliter. ^aConsidered statistically significant at $P < 0.05$.

The duration of the Nuss procedure was significantly longer among adults, with a median operation time of 35 minutes (IQR, 30 to 45 minutes) compared with 30 minutes (IQR, 25 to 40 minutes) for the young group ($P=0.004$) (Table 3). During the procedure, 2 bars were significantly more often required for appropriate correction in the adult group (15%) compared with the young group (4%; $P=0.002$). Stabilizers were used in all participants, with no significant difference in the number of stabilizers needed to obtain adequate bar stability ($P=0.45$).

Table 3: Per- and post-operative characteristics.

	Young (n=272)	Adult (n=55)	P-value
Bars inserted, n (%)			0.007 ^a
One bar	261 (96)	47 (85)	
Two bars	11 (4)	8 (15)	
Bar length in inches, median (IQR)			
Cranial bar	11 (10–11); n=270	12 (11–12)	<0.001 ^a
Caudal bar	11 (10–11)	11 (11–11)	0.055
Stabilizers, n (%)			0.45
One sided	160 (59)	36 (65)	
Both sides	11 (41)	19 (35)	
Operation time in minutes, median (IQR)	30.0 (25.0–40.0); n=271	35.0 (30.0–45.0); n=53	0.004 ^a
Length of hospital stay in days, median (IQR)	5.0 (4.0–6.0)	5.0 (4.0–6.0)	0.17

n, number; *IQR*, interquartile range; *mL*, milliliter. ^aConsidered statistically significant at $P < 0.05$.

An overview of all complications is presented in Table 4. Complications occurred in 24% (n=13) of adults compared to 11% (n=30) of young participants (P=0.012), with only the incidence of minor complications significantly higher among adult participants (P=0.002). Post hoc analyses of minor complications showed a significantly higher incidence of chronic pain (>3 months after surgery) among adult participants (7%; n=4 vs 1%; n=2 in young participants; P=0.008) that was relieved after consultation with a dedicated pain team (accorded to patients' reported outcomes). Chronic pain unresponsive to medical treatment and urging bar removal was classified as major complication (CDC III_b) and occurred in 2% (n=6) of the young patients and in 7% (n=4) of the adult participants. In these patients, time to bar removal was less than 1 year in 1 adult and between 2 and 2 and one-half years for the other 9 patients. Premature removal did not lead to pectus recurrence. Major complications, including chronic pain requiring bar removal, were not statistically different between groups, (P=0.43). Bar displacement requiring surgical revision (CDC III_b) occurred in 4% of young participants and in 3% of adult participants, with all but 1 displacement occurring within 1 month after the initial surgery.

Other major complications encompassed protruding bars for which additional bending with the patient under general anesthesia was necessary (CDC III_b), pneumothorax requiring chest tube drainage (CDC III_a), empyema needing surgical evacuation, and bar removal within 1 year for any cause other than chronic pain (CDC III_b) (Table 4). The last complication resulted from overcorrection in a young participant and from transsternal migration of the bar in an adult participant. The most severe bleeding complication occurred in a young participant that required reoperation with evacuation of 2.5-liter hemothorax caused by bleeding from an intercostal artery (CDC IV). There was no mortality. Both young and adult participants were discharged after a median stay of 5 days (IQR, 4 to 6 days; P=0.17).

Table 4: Complications.

	Young (n=272)	Adult (n=55)	P-value
Major complications, n (%)	20 (7)	7 (13)	0.43
Bar displacement requiring reoperation	7 (3)	2 (4)	
Additional bar bending	3 (1)	0 (0)	
Bar removal within 3 years for chronic pain	6 (2)	4 (7)	
Bar removal for any other cause within 1 year	1 (0.4)	1 (2)	
Reoperation for bleeding	1 (0.4)	0 (0)	
Pneumothorax requiring intervention	1 (0.4)	0 (0)	
Empyema	1 (0.4)	0 (0)	
Minor complications, n (%)	10 (4)	6 (11)	0.002 ^a
Wound infection	6 (2)	0 (0)	0.59
Pneumonia	2 (1)	2 (4)	0.13
Chronic pain without bar removal	2 (1)	4 (7)	0.008 ^b

n, number. ^aConsidered statistically significant at $P < 0.05$, ^bConsidered statistically significant at $P < 0.017$ following Bonferroni correction.

COMMENT

The aim of this retrospective cohort study was to examine the risk of complications after the Nuss procedure in adult patients compared to young patients. Overall, complications occurred more frequently among adults and resulted from the significantly higher incidence of minor complications, mostly related to chronic pain. Our results did not show a higher incidence of major complications (including bar displacement) among adults. However, the young group was much larger than the adult group (272 vs 55).

Currently, the Nuss technique is reserved not only for adolescents but also increasingly in adults. Despite varying age groups, several other series demonstrated the feasibility and safety of this operation in adult patients. Our results reinforce these findings by providing additional evidence on the feasibility and safety, but they also stress the differences in postoperative morbidity between young patients and adults. Compared with other series that used different age limits, we divided patients into a young group (≤ 24 years of age) and an adult group (> 24 years of age) according to the definition used by the World Health Organization defined [20]. Moreover, we chose this age because the skeletal system is fully matured (in size and density) by the age of 24 [23].

One of the known major failures of the Nuss procedure is bar displacement. The cause of bar displacement can be multifactorial, but poor bar stabilization or inadequate fixation of the bar seems to be the most common cause [22]. In our study, the percentage of bar displacements in adults (4%) and in young patients (3%) was not statistically different. The

surgical technique and number of stabilizers used was also similar between both groups. Thus, despite higher chest wall rigidity, adult patients did not have a higher incidence of bar displacement after the Nuss procedure, thus rejecting our hypothesis. However, 2 bars were significantly more often used among adults, thereby potentially diminishing displacement rates because of an altered distribution of forces. The bar displacement rates in our series were consistent with those of Pawlak and colleagues [17], who found bar displacement in 1%, 4% and 2% of patients in different age groups of 7 to 14 years, 15 to 20 years, and older than 21 years. Jaroszewski and colleagues [16] reported similar displacement rates of 2% and 7% among patients aged between 18 to 29 and 30 to 72 years, respectively. In a study by Sacco Casamassima and colleagues, [18] a displacement rate of 4% among patients with a median age of 31 years was reported.

Chronic pain lasting over 3 months and relieved by additional analgesia (after consultation with a dedicated pain team) was the most common minor complication and occurred significantly more often among adults. Two other studies mentioned pain as an outcome measure. One of these studies, by Sacco Casamassima and colleagues [18], looked at long-term patient satisfaction in 98 adults with a median age of 31 years and found that 10% of responders had severe pain after the Nuss procedure. Hanna and associates [12] found that patients had either no pain or moderate pain that did not require analgesia; however, their median age of 20 years was comparable to our group of young patients. A possible explanation for the increased pain among older patients could be that greater force (up to 250 Newton) is needed to correct the sternal deformity [24], thus causing increased stress on the underlying ribs and subsequently more pain [25]. Moreover, increased pain among adults may raise the risk of pneumonia secondary to hypoventilation and insufficient coughing [26]. However, we found no significant difference in the incidence of pneumonia among young patients and adults ($P = .13$).

Length of hospital stay was similar in both groups (median, 5 days). This outcome is in line with the previously reported series of Jaroszewski and colleagues [16] and Sacco Casamassima and associates [18]; both these studies reported a hospital length of stay of 3 to 4 days.

Placement of 2 bars was needed in 15% of adult patients. This corresponds to the findings from other series that reported placement of multiple bars in 10% to 19% of cases [12, 14, 18], although other investigators reported the use of multiple bars in up to 63% of cases [17]. In contrast, our young population required two bars in only 4% of cases. This difference

between young and adult patients could not be explained by the pectus severity because there was no difference between their median Haller indices ($P = .44$). However, it may be explained by the higher chest wall rigidity in adult patients that may more often require multiple bars to obtain an adequate correction, as also demonstrated by Pilegaard and colleagues who required double bars in 70% of participants aged 30 years and above [13].

With the aim of widening the indication for minimally invasive repair and preventing invasive procedures in adults, modifications of the Nuss procedure are being investigated [27]. Jaroszewski and associates used forced sternal elevation using a bone clamp and retractor to decrease the forces required to insert and rotate bars. On failure to lift the sternum, they performed a hybrid approach, including sternal osteotomy and/or chondroplasty [16]. The latter approach may in theory decrease sternocostal stress and potentially minimize postoperative pain and decrease the need for additional bars to correct the deformity. Although, we performed no hybrid procedures or sternal elevation and used only 1 support bar in 85% of adults, we significantly more often observed prolonged postoperative pain among adults. The use of adjunctive techniques to decrease stress and postoperative morbidity is an interesting concept and should be subject of future research through comparative (randomized) studies. However, on the basis of our most recent experience, we advocate the routine use of sternal elevation techniques during the Nuss procedure because they improve visualization and safety and may also reduce rotational forces, as also stressed by Haecker and colleagues [28].

The main limitations of this study are its retrospective design and inherent bias, in addition to the difference in study group size (272 vs 55). The difference in study group size was caused by the decreasing frequency of corrective surgical procedures performed with increasing age of patients. In addition, missing data predominantly affected the preoperative Haller index, which could not be calculated because preoperative imaging was not always available from patients treated during the early experience.

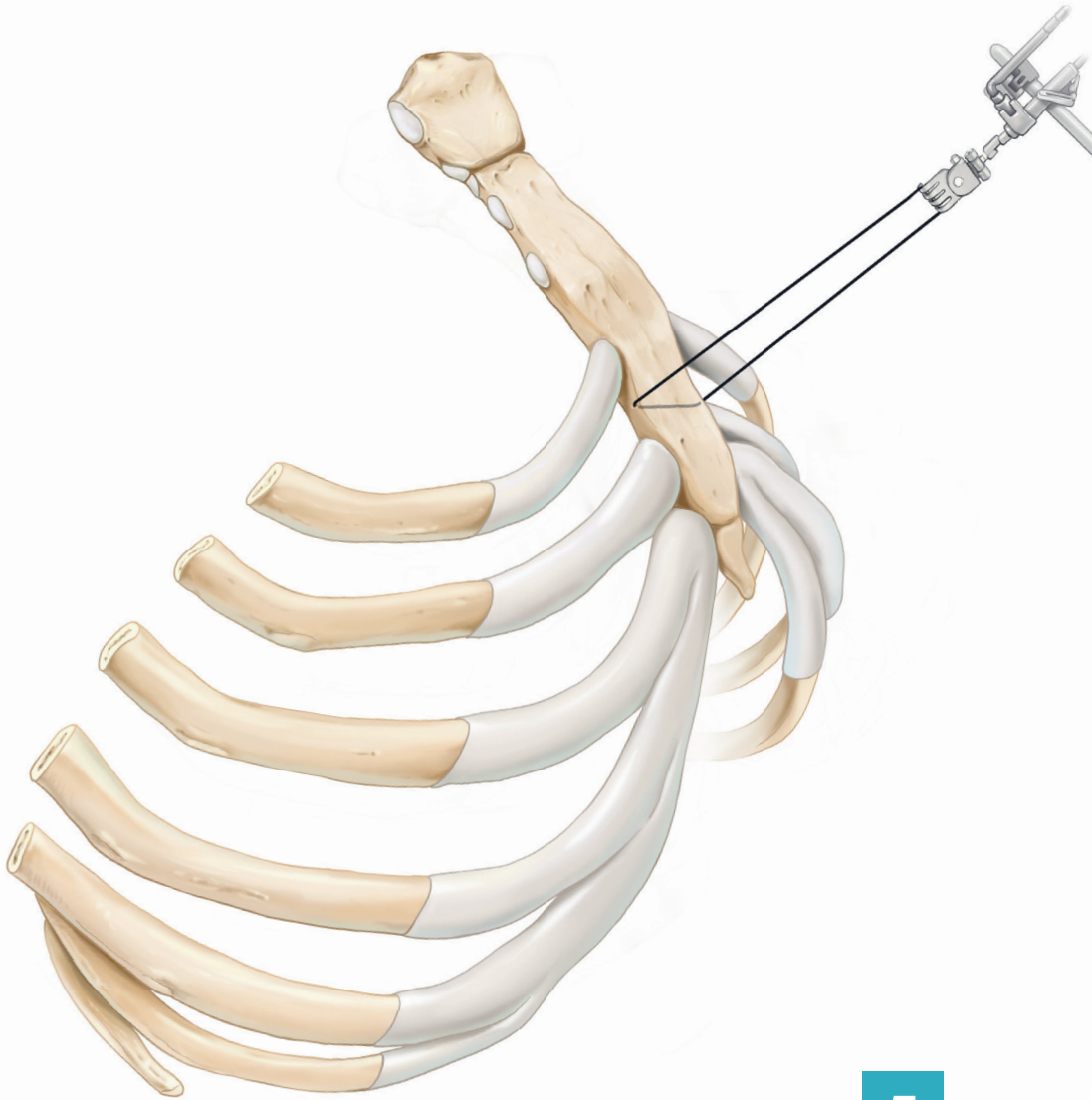
In conclusion, this study confirms that the Nuss procedure is a safe surgical treatment technique for pectus excavatum in both young and adult patients. Although the risk of prolonged pain after surgery is more common in the adult population, adult patients are not more prone to other complications in comparison with younger patients.

REFERENCES

1. Fokin AA, Steuerwald NM, Ahrens WA, Allen KE. Anatomical, histologic, and genetic characteristics of congenital chest wall deformities. *Semin Thorac Cardiovasc Surg.* 2009;21:44-57.
2. Krasopoulos G, Dusmet M, Ladas G, Goldstraw P. Nuss procedure improves the quality of life in young male adults with pectus excavatum deformity. *Eur J Cardiothorac Surg.* 2006;29:1-5.
3. Lawson ML, Cash TF, Akers R, Vasser E, Burke B, Tabangin M et al. A pilot study of the impact of surgical repair on disease-specific quality of life among patients with pectus excavatum. *J Pediatr Surg.* 2003;38:916-18.
4. Roberts J, Hayashi A, Anderson JO, Martin JM, Maxwell LL. Quality of life of patients who have undergone the Nuss procedure for pectus excavatum: Preliminary findings. *J Pediatr Surg.* 2003;38:779-83.
5. Ravitch MM. The Operative Treatment of Pectus Excavatum. *Ann Surg.* 1949;129:429-44.
6. De Loos ER, Hulsewé KWE, van Loo ERJ, Kragten JA, Höppener PF, Busari JO et al. Does the use of locking plates or mesh and wires influence the risk of symptomatic non-union of the sternal osteotomy after modified Ravitch? *J Thorac Dis* 2020 Jul;12(7):3631-3639.
7. Nuss D, Kelly RE, Croitoru DP, Katz ME. A 10-year review of a minimally invasive technique for the correction of pectus excavatum. *J Pediatr Surg.* 1998;33:545-52.
8. Mao YZ, Tang S, Li S. Comparison of the Nuss versus Ravitch procedure for pectus excavatum repair: an updated meta-analysis. *J Pediatr Surg.* 2017;52:1545-52.
9. Lam MW, Klassen AF, Montgomery CJ, LeBlanc JG, Skarsgard ED. Quality-of-life outcomes after surgical correction of pectus excavatum: a comparison of the Ravitch and Nuss procedures. *J Pediatr Surg.* 2008;43:819-25.
10. Jaroszewski D, Notrica D, McMahon L, Steidley DE, Deschamps C. Current management of pectus excavatum: a review and update of therapy and treatment recommendations. *J Am Board Fam Med.* 2010;23:230-9.
11. Nuss D, Kuhn MA, Obermeyer RJ. Our approach: MIS repair of pectus excavatum. *Contemp Surg.* 2007;63:444-51.
12. Hanna WC, Ko MA, Blitz M, Shargall Y, Compeau CG. Thoracoscopic Nuss procedure for young adults with pectus excavatum: excellent midterm results and patient satisfaction. *Ann Thorac Surg.* 2013;96:1033-6.
13. Pilegaard HK. Extending the use of Nuss procedure in patients older than 30 years. *Eur J Cardiothorac Surg.* 2011;40:334-37.
14. Pilegaard HK, Licht PB. Early results following the Nuss operation for pectus excavatum – a single-institution experience of 383 patients. *Interact Cardiovasc Thorac Surg.* 2008;7:54-57.
15. Yoon YS, Kim HK, Choi YS, Kim K, Shim YM, Kim J. A modified Nuss procedure for late adolescent and adult pectus excavatum. *World J Surg.* 2010;34:1475-80.
16. Jaroszewski DE, Ewais MM, Chao CJ, Gotway MB, Lackey JJ, Myers KM et al. Success of Minimally Invasive Pectus Excavatum Procedures (Modified Nuss) in Adult Patients (≥30 Years). *Ann Thorac Surg.* 2016;102:993-1003.
17. Pawlak K, Gąsiorowski Ł, Gabryel P, Gałęcki B, Zieliński P, Dyszkiewicz W. Early and Late Results of the Nuss Procedure in Surgical Treatment of Pectus Excavatum in Different Age Groups. *Ann Thorac Surg.* 2016;102:1711-16.

18. Sacco Casamassima MG, Gause C, Goldstein SD, Karim O, Swarup A, McIltrout K et al. Patient Satisfaction After Minimally Invasive Repair of Pectus Excavatum in Adults: Long-Term Results of Nuss Procedure in Adults. *Ann Thorac Surg.* 2016;101:1338-45.
19. von Elm E, Altman DG, Egger M, Pocock SJ, Gøtzsche PC, Vandenbroucke JP. The Strengthening the Reporting of Observational Studies in Epidemiology (STROBE) statement: guidelines for reporting observational studies. *J Clin Epidemiol.* 2008;61:344-9.
20. WHO. Adolescent health and development. 2019 [date last accessed: 08-07-2020]; Available from: http://www.searo.who.int/entity/child_adolescent/topics/adolescent_health/en/.
21. Clavien PA, Barkun J, de Oliveira ML, Vauthey JN, Dindo D, Schulick RD et al. The Clavien-Dindo Classification of Surgical Complications: Five-Year Experience. *Ann Surg.* 2009;250:187-96.
22. Nuss D, Obermeyer RJ, Kelly RE. Nuss bar procedure: past, present and future. *Ann Cardiothorac Surg.* 2016;5:422-33.
23. Henry YM, Fatayerji D, Eastell R. Attainment of peak bone mass at the lumbar spine, femoral neck and radius in men and women: relative contributions of bone size and volumetric bone mineral density. *Osteoporos Int.* 2004;15:263-73.
24. Weber PG, Huemmer HP, Reingruber B. Forces to be overcome in correction of pectus excavatum. *J Thorac Cardiovasc Surg.* 2006;132:1369-73.
25. Nagasao T, Miyamoto J, Tamaki T, Ichihara K, Jiang H, Taguchi T et al. Stress distribution on the thorax after the Nuss procedure for pectus excavatum results in different patterns between adult and child patients. *J Thorac Cardiovasc Surg.* 2007;134:1502-7.
26. Özcan PE, Şentürk E. Pneumonia After Thoracic Surgery. *Postoperative Care in Thoracic Surgery* 2017:207-17.
27. Ewais MM, Chaparala S, Uhl R, Jaroszewski DE. Outcomes in adult pectus excavatum patients undergoing Nuss repair. *Patient Relat Outcome Meas.* 2018;9:65-90.
28. Haecker FM, Krebs T, Kocher GJ, Schmid RA, Sesia SB. Sternal elevation techniques during the minimally invasive repair of pectus excavatum. *Interact Cardiovasc Thorac Surg.* 2019;29:497-502.
29. Horan TC, Gaynes RP, Martone WJ, Jarvis WR, Emori TG. CDC definitions of nosocomial surgical site infections, 1992: a modification of CDC definitions of surgical wound infections. *Am J Infect Control.* 1992;20:271-4.
30. Kalil AC, Metersky ML, Klompas M, Muscedere J, Sweeney DA, Palmer LB et al. Management of Adults With Hospital-acquired and Ventilator-associated Pneumonia: 2016 Clinical Practice Guidelines by the Infectious Diseases Society of America and the American Thoracic Society. *Clin Infect Dis.* 2016;63:e61-e111.

De Loos ER, Daemen JHT, Coorens NA, Maessen JG, Vissers YLJ, Hulsewé KWE.
JTCVS Tech. 2021 Jul 17;9:167-175.



5

Sternal elevation by the crane technique
during pectus excavatum repair:

a quantitative analysis

ABSTRACT

Introduction

The crane technique is used to facilitate sternal elevation to provide safe mediastinal passage during the Nuss procedure. The aim was to objectively quantitate the elevation of the crane by three-dimensional chest images acquired during the Nuss procedure.

Methods

A prospective cohort study was conducted. Patients undergoing the Nuss procedure were eligible. Sternal elevation was achieved by the crane technique providing a simultaneous lift of the anterior chest wall and reduction of the pectus excavatum depth. Both effects were evaluated. Three-dimensional surface images were acquired prior to incision, following sternal lift and after bar implantation, and quantitatively compared. Reduction of the external pectus excavatum depth was expressed as percentage.

Results

Thirty patients were included. Ninety percent were male with a median age of 15.5 years (interquartile range [IQR]: 14.5-17.4), Haller index of 3.56 (IQR: 3.09-4.65) and external pectus depth of 18mm (IQR: 11-23). Sternal elevation by the crane provided a median 78% (IQR: 63-100) reduction of the deformity, corresponding with a residual depth of 3mm (IQR: 0-7). The percentual reduction diminished with increasing depth of the sternal depression (correlation: -0.86). Besides reducing the deformity, the crane caused an elevation of the anterior chest over a large surface area with a maximum lift of 26mm (IQR: 19-32).

Conclusions

The crane is an effective sternal elevation technique providing 78% reduction of the sternal depression, though its effect lessens with increasing depth. In addition, it produces an elevation of the anterior chest over a large surface area.

INTRODUCTION

Pectus excavatum is the most common congenital anterior chest wall deformity with an incidence of 1 in 400 newborns [1, 2]. Symptoms encompass cosmetic discomfort with associated psychosocial burden and physiologic symptoms originating from cardiopulmonary impairment. The latter is caused by the inwardly deviated sternum, compressing the heart, and predominantly affecting right ventricular function [3-6]. The current surgical treatment of choice is the Nuss procedure. It is preferred over the conventional modified Ravitch procedure because it is a less invasive procedure [7]. In the Nuss procedure a substernal bar is implanted to correct the deformity [8]. Despite being considered minimally invasive, the retrosternal dissection required to pass the Nuss bar through the mediastinum is a potentially hazardous maneuver. In patients with severe pectus excavatum, visualization across the mediastinum may be compromised. In addition, retrosternal passage of the introducer is more difficult and carries higher risk, and cardiac and aortic injuries have been described [9]. Although these complications are rare with an estimated incidence of less than 0.1%, when they do occur, they are fatal in up to one-third of patients [9]. Sternal elevation techniques may facilitate safe mediastinal passage (i.e., minimize pericardial trauma and risk of cardiac injury) by expanding the retrosternal space and improving thoracoscopic exposure.

A recent review by Haecker and colleagues found no (near)-fatal events among 4536 patients undergoing the Nuss procedure with sternal elevation. Therefore, the routine use of sternal elevation techniques was recommended [10].

Among the various methods for intraoperative elevation of the sternum, the crane technique is most frequently employed [10]. This method utilizes a trans-sternal wire suture attached to an external table-mounted retractor device to generate sternal lift. Although the crane technique is regarded effective [11, 12], objective parameters such as maximum elevation or the lift required to allow a safe turn of the bar are missing in the literature, as underlined by Haecker et al. [10]. In addition, it is unknown whether patients with a varying severity of pectus excavatum equally benefit from sternal elevation.

The aim of this study was to evaluate the quantitative effect of the crane technique using intraoperatively acquired three-dimensional images of the chest.

METHODS

Study design

A single-center, prospective cohort study was conducted at Zuyderland Medical Centre (Heerlen, the Netherlands). Patients acted as their own control. The study was approved by the local research and ethics committee (METCZ; ID: 20200071; approval date: April 14th, 2020) and subsequently submitted to the Clinicaltrials.gov registry (ID: NCT04418583; approval date: May 20th, 2020). Written informed consent was obtained prior to inclusion. The report was written in compliance with the Strengthening the Reporting of Observational Studies in Epidemiology statement [13].

Patients

All consecutive patients with pectus excavatum undergoing surgical treatment by the Nuss procedure at our clinic (Zuyderland Medical Center, Heerlen, the Netherlands) were eligible for inclusion. Those with prior thoracic surgery were excluded.

Crane technique

The crane technique has previously been described by Park et al. [11]. In short, a surgical stainless-steel wire suture (Surgical Steel, Ethicon, Johnson&Johnson, New Brunswick, New Jersey, USA) is transversally passed through the anterior sternal cortex at the deepest point of the pectus (Figure 1A-B). Suture placement is performed under thoracoscopic guidance. In addition, careful interpretation of tactile feedback is used to envision the needle's trajectory and detect deviations. The Thompson rail clamp with unilateral crossbar, micro-adjustable clip-on handle, and rake blade (Thompson Surgical Instruments, Traverse City, MI, USA) is mounted to the operating table. The suture is attached to the Thompson retractor system in order to lift the suture along with the depressed sternum (Figure 1C). To prevent the wire suture from coming loose during elevation, the ligated portion is bent and twisted along the suture itself (Figure 1C). In addition, bending of the steel wire was minimized and the wire itself was not grasped with any surgical instrument to prevent introduction of weak spots. The anterior chest wall was lifted until the point at which maximum correction of the pectus deformity was achieved. (Figure 1D and Video 1). In patients for whom this was not possible, lift was continued until no additional anterior lift was visually obtained while winding the micro-adjustable handle of the crane system. Following sternal elevation, the Nuss procedure is continued as described by Pilegaard [14]. The retractor is dismantled after

correct bar placement including the assembly of one or more stabilizers. No procedural adjustments (regarding the Nuss procedure itself or bar configuration) were made after the routine introduction of the crane in early 2020 compared to the preceding period.

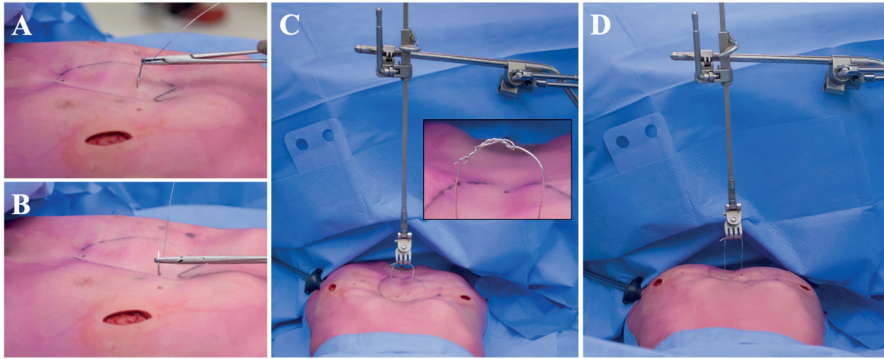


Figure 1: Intraoperative view of the crane technique. (A-B) A wire suture is passed through the anterior sternal cortex at the point of most severe depression. (C) The wire suture is attached to a table-mounted retractor system, following which (D) sternal elevation is achieved.

Measurements and variables

Baseline patient characteristics including gender, age, body mass index (BMI), preoperative Haller index and preoperative complaints, were obtained from the electronic patient records. Three 3D images were acquired at different time-points during the Nuss procedure, namely: (1) prior to skin incision, (2) following application of the crane and sternal lift, and (3) after Nuss bar placement and dismantling of the retractor. Before acquisition, line markings were made on the sterile drape and skin interface for image alignment purposes. All images were acquired by the Artec Leo (Artec3D, Luxembourg, Luxembourg) imaging system. This is a handheld device that digitizes real-world objects using structured light and triangulation. Images were obtained by moving the imaging device around the anterior chest wall during apnea to avoid the introduction of motion artifacts. An anterior chest wall image is obtained in less than 6 seconds [15]. Raw images were processed using Artec Studio 14.0 (Artec3D, Luxembourg, Luxembourg) in conjunction with the processing protocol described elsewhere [16].

The force exerted by the crane simultaneously lifts the anterior chest wall and reduces the sternal depression, as shown in Figure 2A-B. This simultaneous effect was denoted as the combined elevation as reflected by the green line in Figure 2A. The external depth was

calculated in the sagittal direction with respect to a craniocaudal tangent of the anterior chest wall (Figure 3) by an automatic algorithm developed in MATLAB (version R2019a, The Mathworks Inc., Natick, MA, USA). Sagittal measurements were chosen over transversal measurements since the latter may overestimate depth in females due to the breasts. The pectus reduction was quantified by subtraction of the 3D image derived external pectus excavatum depth, just prior to incision and following crane application (Figure 2B).

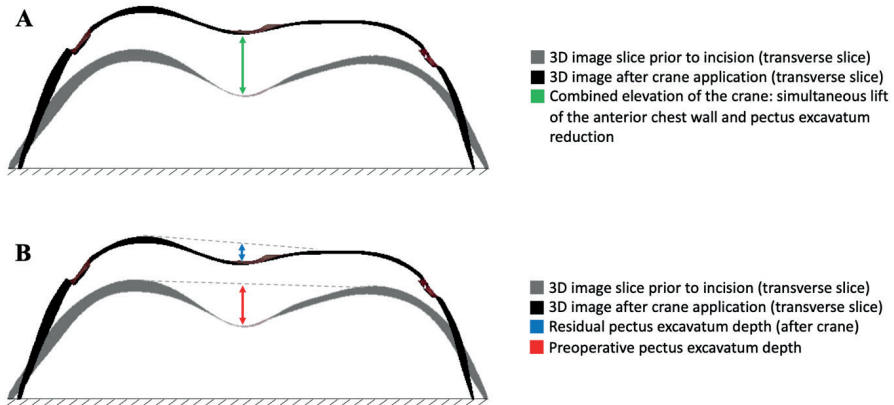


Figure 2: Aligned transverse slice of the 3D image prior to incision and after crane application, demonstrating (A) the combined elevation achieved by the crane (i.e., simultaneous lift of the anterior chest wall and pectus excavatum reduction), and (B) the reduction of the external pectus excavatum depth by the crane. Of note: subfigure B is merely for visual explanation since the pectus reduction is measured in the sagittal direction.

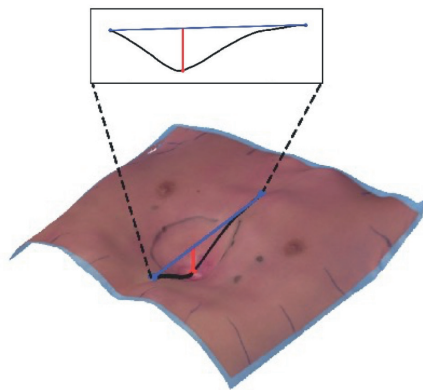


Figure 3: Measurement method of the 3D image derived external depth, calculated in the sagittal direction with respect to a craniocaudal tangent of the anterior chest wall.

Lift of the anterior chest wall was defined as the crane's combined elevation (in other words, simultaneous lift of the entire anterior chest wall and decrease of sternal depression; Figure 2A) minus the pectus excavatum reduction. To determine the combined elevation, 3D images just prior to incision (Figure 4A) were compared with those made after crane application (Figure 4B). Following rigid image alignment by manual selection of the line markings (Figure 4C-D), the maximum distance (at the point of deepest excavation) between the corresponding image points was retrieved by Artec Studio 14.0 (Artec3D, Luxembourg, Luxembourg). Color-coded surface distance maps were used to visualize differences in mm relative to the preoperative situation (Figure 4E).

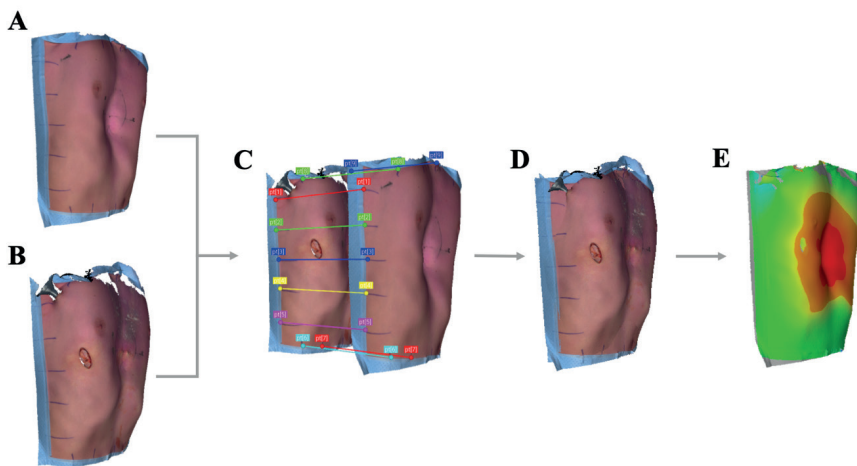


Figure 4: Method of 3D image alignment and creation of surface distance maps. (A) Three-dimensional image acquired prior to skin incision and (B) after crane application. (C-D) Rigid alignment by manual section of the line markings. (E) Resulting surface distance map, demonstrating the chest wall elevation after crane application relative to the preoperative image.

In order to compare the effect of the crane with the final result after definitive correction, 3D images prior to incision were compared to the 3D images after Nuss bar implantation. Similarly, the maximum distance as well as the mean of signed distances were determined. These respectively depicted the maximum combined elevation at the deepest point and average lift of the entire chest wall facilitated by the crane and Nuss bar.

Statistical analysis

All statistical analyses were performed by SPSS statistics (IBM Corp. IBM SPSS Statistics for MacOS, Version 27.0, Armonk, NY, USA). Continuous variables were reported as mean and

standard deviation (SD). In the presence of skewness, the median, interquartile range (IQR) and range were used. Nominal variables were reported as frequency and percentage.

Reduction of the external pectus excavatum depth by the crane technique was expressed as percentage. The relationship between the external depth and reduction was assessed by Pearson's or Spearman's rank correlation coefficient. In addition, the relationship between the preoperative Haller index and reduction was evaluated.

In order to compare the maximum and average combined elevation of the entire anterior chest wall caused by the crane and Nuss bar, measurements were submitted to the paired samples t-test or Wilcoxon signed rank test in the presence of skewness. A p-value lower than 0.05 was considered statistically significant.

Given that no prior quantitative data regarding the effect of the crane technique was available, no sample size estimation could be performed; therefore, a sample size of 30 was chosen as a reasonable estimate.

RESULTS

Between May 2020 and December 2020, 31 patients underwent the Nuss procedure with sternal elevation by the crane technique of whom 30 were included. One patient was excluded due to sterility issues of the retractor system. Ninety percent were male with a median age of 15.5 years (IQR: 14.5-17.4; range: 13.2-26.9) and mean BMI of 19.0 kg/m² (SD: 2.1). The median preoperative Haller index was 3.56 (IQR: 3.09-4.65; range: 2.38-10.21). Preoperative symptoms predominantly encompassed exercise intolerance (57%) and body image disturbances (67%).

The median preoperative external pectus excavatum depth was 18mm (IQR: 11-23; range: 9-42). After sternal elevation by the crane, the external depth was reduced to 3mm (IQR: 0-7; range: 0-18), indicating a reduction of 52% to 100% (median: 78%; IQR: 63-100) in all patients. In addition, a negative relationship was observed between the preoperative external depth and reduction achieved by the crane, characterized by a statistically significant Spearman's correlation coefficient of -0.86 ($p < 0.001$; Figure 5A). In other words, the percentage of pectus reduction by the crane decreases with increasing pectus depth. Likewise, the preoperative external depth demonstrated a correlation of 0.85 ($p < 0.001$; Figure 5B) with the absolute reduction in millimeters. No significant correlation was found between the Haller index and reduction achieved by the crane (Spearman's correlation coefficient: -0.35; $p = 0.061$).

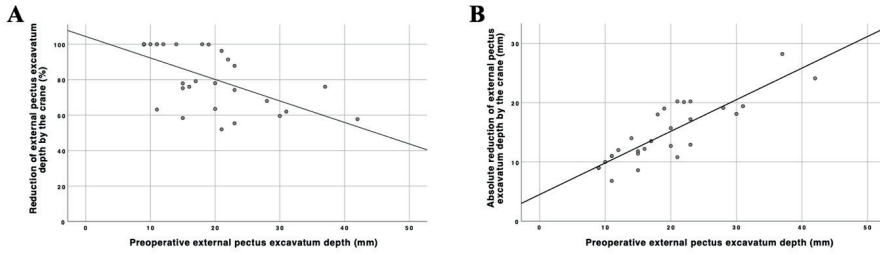


Figure 5: Two scatter plots with corresponding linear regression lines demonstrating (A) the percentual reduction of the external pectus excavatum depth and (B) the absolute reduction of the external pectus excavatum depth by the crane technique versus the preoperative external pectus excavatum depth.

5

Comparison of 3D images acquired just prior to incision and after crane application revealed a median maximum combined elevation of the anterior thoracic wall (at the point of most severe depression, indicated by the green arrow in Figure 2A) of 39mm (IQR: 33-48; range: 25-115). Besides the above-mentioned reduction in external pectus depth, the crane thus provides a maximum elevation of the anterior chest wall of 26mm (IQR: 19-32; range: 6-91).

The Nuss bar achieved a higher combined elevation than the crane at the deepest point of the pectus (median: 44mm; IQR: 37-58; range: 26-93 versus crane median: 39mm; IQR: 33-48; range: 25-115; $p=0.021$). In contrast, the crane facilitated a higher average elevation of the entire thoracic wall (median: 9mm; IQR: 6-11; range: 1-14 versus bar median: 4mm; IQR: 3-6; range: 0.4-12; $p<0.001$). Thus, the crane facilitates a more diffuse lift of the entire anterior chest compared to the final bar. This was visually confirmed by the surface distance maps in Figure 6.

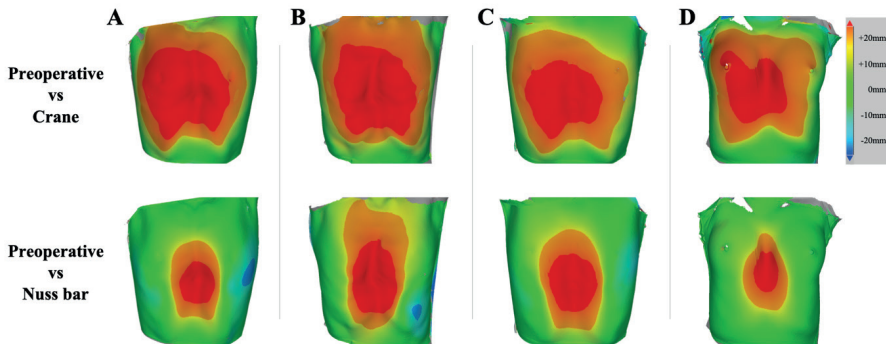
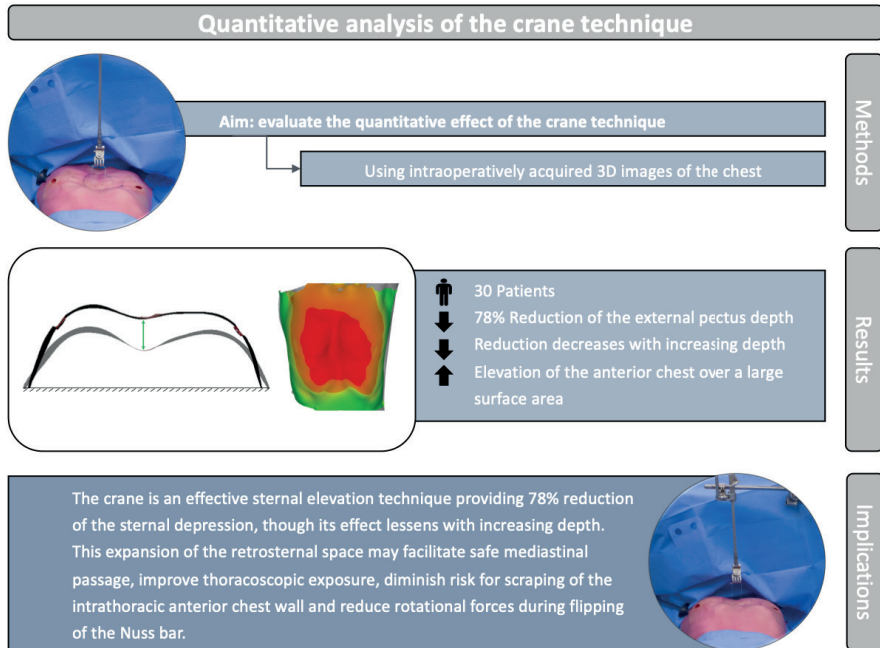


Figure 6: Color-coded surface distance maps (in millimeters) of (A-D) 4 distinct patients. The top row reveals the differences between the preoperative situation and after crane application, while the bottom row reveals the differences between the preoperative situation and after Nuss bar implantation.

The median duration of surgery, from skin incision to closure, was 34 minutes (IQR: 27-43; range: 22-75). No intraoperative or postoperative crane related complications occurred.

The key findings have been emphasized in Figure 7.



3D: Three-dimensional

Figure 7: Key findings regarding the quantitative analysis of the crane technique, used for sternal elevation during the Nuss procedure. The aim was to evaluate the quantitative effect of the crane technique. Using 3D images, a median 78% reduction of the external pectus depth was observed among 30 patients. Though, its effect was observed to lessen with increasing depth.

DISCUSSION

The current study is the first to objectively assess the quantitative effect of the crane technique on the anterior thoracic wall using intraoperatively acquired three-dimensional images of the chest.

Sternal lift by the crane technique was found to facilitate a median pectus depth reduction of 78%, ranging from 52% to 100% per individual patient and diminishing with increasing pectus depth. This corresponded with a median reduction of 13mm (IQR: 11-19), while at the same time, a maximum anterior chest wall elevation of 26mm (IQR: 19-32) was achieved.

This higher elevation of the chest wall compared to reduction of the deformity at its deepest point is likely to be caused by the higher rigidity of deformity (i.e., sternum and adjacent costal cartilage) in comparison to the remainder of the thoracic wall.

Comparing the combined chest wall elevation by the crane to that achieved by the final bar, the former was observed to affect a significantly larger surface of the thoracic wall ($p < 0.001$; see Figure 6). This difference is explained by the forces applied. The trans-sternal steel wire in conjunction with the Thompson retractor produce a unidirectional upward force, counteracted by the elasticity of the chest wall and gravitational forces of the body weight (Figure 8A). The same chest wall elasticity applies to the Nuss bar, although the bar itself also exerts inwardly directed forces at the hinge points (Figure 8B) and the position of the stabilizers causing relative bilateral chest wall depressions, as indicated by the blue areas in Figure 6A-C.

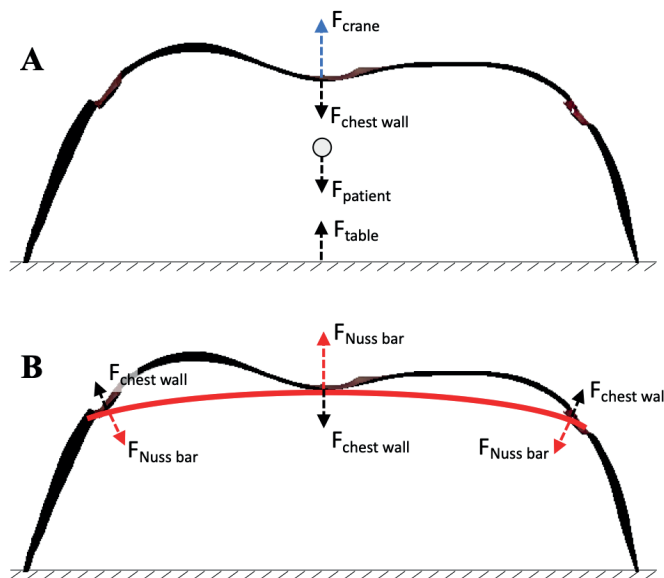


Figure 8: A simplified representation of the direction of forces being exerted during (A) sternal elevation by the crane technique and (B) definitive correction by the metal Nuss bar which is depicted in red. Of note: this is a simplified representation wherein the vector's length does not correlate with the amount of force being exerted.

Despite the fact that the crane technique facilitates a more diffuse lift than the implanted Nuss bar, the bar generates a significantly higher combined lift at the deepest point of the pectus ($p=0.021$). This is the result from the bars' convex shape to achieve an anatomical position of the sternum and adjacent costal cartilage over time [14]. In contrast, the goal of the crane is solely to provide a temporary elevation of the sternum for safe retrosternal passage.

A correlation of -0.86 was shown between the reduction of the external pectus excavatum depth by the crane and the preoperative external pectus excavatum depth. Yet, no meaningful correlation was observed with the Haller index (-0.35 ; $p=0.061$). This may be because the Haller index is affected by the thoracic shape (e.g., barrel versus flat shaped).

Although, the routine use of sternal elevation during the Nuss procedure is recommended by Haecker et al. [10], elevation is potentially more beneficial in deep deformities in terms of risk reduction of serious adverse events. In the present study we found the relative elevation to decrease with increasing pectus excavatum depth. Nevertheless, a minimum reduction of 52% was observed. Even for the four patients with a Haller index larger than 7.00 (up to 10.21). Thus, despite the relatively lower percentual reduction in deep deformities, sternal elevation by the crane technique is advocated given that even a minimum reduction of 52% can drastically increase the retrosternal space which facilitates safer mediastinal passage (as observed in Figure 5B), but also reduces rotational forces during flipping (rotation during placement) of the Nuss bar. It thus also facilitates minimally invasive repair by the Nuss procedure in cases with extreme sternal depression, which would otherwise have undergone a modified Ravitch procedure.

Besides the crane technique, various other methods exist to achieve sternal elevation. Amongst them is the vacuum bell. This cup-shaped device generates lift through sub-atmospheric pressure and does not require skin incision or puncture. However, the vacuum bell can cause hematoma and is only described to be effective in patients with low BMI and shallow deformities [17]. Moreover, in European countries there is a trend towards using shorter bars [14], requiring more medially placed incisions, complicating vacuum bell use. One may also manually lift the sternum. Though, this is more invasive as it requires an additional subxiphoidal skin incision as well as elevation or removal of the xiphoid process [18, 19]. The same effect can be achieved by a substernal spade-like device attached to a stabilizer system following xiphoidectomy [20].

Less invasive techniques include the use of a percutaneous sternal bone clamp with retractor system [21] or a handheld horseshoe-shaped sternal elevator which is inserted through the standard antero-lateral incision [22]. Similarly, one can use two Langenbeck retractors to manually lift the chest wall without additional surgical skin trauma [23]. The crane technique, used in the current series, has the advantage of minimal surgical trauma due to the use of steel wire requiring only two skin punctures and the use of a retractor system by which continuous and steady elevation is ensured. In addition, the crane method does not interfere with flipping of the Nuss bar, in contrast to, for example, the technique using the Langenbeck retractors. Nevertheless, given the variety of sternal elevation techniques, future studies should aim to compare and determine the optimal technique based on the trade-off between efficacy and additional surgical trauma. The optimal technique may differ among patient groups. For example different techniques may be more effective for older compared to young patients due to a higher chest wall rigidity, enlarging the forces needed to obtain sternal elevation [24]. The same may apply for cup-shaped versus saucer-shaped deformities, but also for redo compared to primary surgery.

Although the crane technique has no absolute contraindications, the presence of a large amount of pre-sternal subcutaneous fat tissue may challenge wire suture placement and thus pose a relative contraindication. However, given that pectus patients are predominantly slender with limited amounts of subcutaneous tissue, this is rather rare than common. In addition, sternal tilt could complicate suture placement in severe cases. In such cases, as well as in obese patients, longitudinal placement may be attempted instead of the usual transverse placement (Figure 1C).

As mentioned in the methods section, several fail-safe mechanisms were incorporated to deal with potential weaknesses of the crane technique. Employing these mechanisms, we observed no crane related complications in the present study (e.g., cardiac puncture during suture placement). Neither did Haecker et al., found any cardiac complications among 3047 patients who underwent the Nuss procedure with sternal elevation by the crane technique [10]. In other words, the risk of cardiac injury during transsternal suture placement is negligible.

A limitation of the crane technique is that it requires additional actions during surgery, as well as additional costs of the surgical steel wires and a one-time investment in a retractor system. However, the operation time in the current series (34 minutes; IQR: 27-43) compared to a published retrospective study of our group including 222 patients (median: 30 minutes; IQR: 25-39) with comparable Haller indices (mean: 3.9 compared to a median of 3.56 in the

current series) from the same center yielded a median difference of only 4 minutes [25]. This minor increase may be deemed negligible given the potential benefits of the crane technique.

The validity of measurements is a direct derivative of the validity of the imaging system employed. In the current series, all 3D images were acquired by the handheld Artec Leo which has previously been shown to be accurate and reproducible for acquisition of anterior chest wall images [15]. However, errors could theoretically still be introduced by the semi-manual alignment of images.

We did not measure the upward force delivered by the crane. This may also be regarded as limitation. As previously mentioned, a variable amount of force was applied (i.e., the anterior chest wall lift was continued until the sternal part of the deformity was fully reduced or until no additional anterior lift was visually obtained while winding the micro-adjustable handle) to maximize expansion of the retrosternal space. Given that the crane's goal is to expand the retrosternal space to allow safe mediastinal passage in conjunction with the fact that the required forces to achieve sternal lift increase with age [24, 26] and severity (Haller index >5.0) [26], our aim was not to evaluate the amount of sternal lift at a certain force, but to evaluate the achievable amount of lift. Moreover, in clinical practice, a pectus surgeon will not halt lifting at a certain attained force during surgery while an even greater lift with potentially safer mediastinal passage can be achieved.

The sum of forces (see Figure 8A) which determines lift also encompasses the strength of the retractor system utilized. In the current study we used a retractor with unilateral rail clamp. A system with bilateral rail clamps and crossbar may theoretically be more rigid and thus provide a higher elevation under the assumption that an even higher elevation is achievable without cutting out of the steel wire through the sternal cortex. In theory, the amount of upward force produced by a retractor system may even lift the entire torso of the operating table and affect measurements. Nevertheless, in the current series we matched images based on the line markings and thus only considered relative changes of the anterior chest wall.

Evaluating the percentual reduction achieved by the crane technique, linear measurements were used. Yet, given the variety of pectus presentations (e.g., symmetric versus asymmetric), volumetric differences may have been more informative. However, we deliberately refrained from the use of volumetric changes since the excavation in pectus excavatum has no strict objectifiable borders, which become even more vague after lift by the crane technique.

The presumed clinical benefits primarily relate to improved safety through decreased risk of injury to the heart and great vessels and diminished risk for scraping of the intrathoracic anterior chest wall where the internal mammary arteries are at risk for injury. Moreover, reduction of rotational forces during flipping of the Nuss bar that may prevent stripping of the intercostal muscles.

The primary aim of sternal elevations techniques is to facilitate safe mediastinal passage (i.e., minimize pericardial trauma and risk of cardiac injury) by expanding the retrosternal space and improving thoroscopic exposure. On the other hand, it potentially also broadens the eligibility criteria for the Nuss procedure to more severe and complex cases.

Our results demonstrate the efficacy of the crane technique on intraoperative elevation of the sternum of patients having surgery for pectus excavatum by the Nuss bar technique. Whether this technique also translates into benefits for clinical results warrants further investigation.

CONCLUSION

The crane provides an effective technique for sternal elevation during the Nuss procedure, facilitating a 78% reduction of the external pectus excavatum depth, though its effect lessens with increasing depth. Besides a temporary reduction of the deformity, the crane causes a diffuse elevation of the entire anterior chest wall.

REFERENCES

1. Chung CS, Myriantopoulos NC. Factors affecting risks of congenital malformations. I. Analysis of epidemiologic factors in congenital malformations. Report from the Collaborative Perinatal Project. *Birth Defects Orig Artic Ser.* 1975;11:1-22.
2. Fokin AA, Steuerwald NM, Ahrens WA et al. Anatomical, histologic, and genetic characteristics of congenital chest wall deformities. *Semin Thorac Cardiovasc Surg.* 2009;21:44-57.
3. Kowalewski J, Brocki M, Dryjanski T et al. Pectus excavatum: Increase of right ventricular systolic, diastolic, and stroke volumes after surgical repair. *J Thorac Cardiovasc Surg.* 1999;118:87-92.
4. Gürkan U, Aydemir B, Aksoy S et al. Echocardiographic assessment of right ventricular function before and after surgery in patients with pectus excavatum and right ventricular compression. *Thorac Cardiovasc Surg.* 2014;62:231-5.
5. Oezcan S, Attenhofer Jost CH, Pfyffer M et al. Pectus excavatum: echocardiography and cardiac MRI reveal frequent pericardial effusion and right-sided heart anomalies. *Eur Heart J.* 2012;13:673-9.
6. Malek MH, Berger DE, Housh TJ et al. Cardiovascular Function Following Surgical Repair of Pectus Excavatum. *Chest* 2006;130:506-16.
7. Mao YZ, Tang S, Li S. Comparison of the Nuss versus Ravitch procedure for pectus excavatum repair: an updated meta-analysis. *J Pediatr Surg.* 2017;52:1545-52.
8. Nuss D, Kelly RE, Croitoru DP et al. A 10-year review of a minimally invasive technique for the correction of pectus excavatum. *J Pediatr Surg.* 1998;33:545-52.
9. Hebra A, Kelly RE, Ferro MM et al. Life-threatening complications and mortality of minimally invasive pectus surgery. *J Pediatr Surg.* 2018;53:728-32.
10. Haecker FM, Krebs T, Kocher GJ et al. Sternal elevation techniques during the minimally invasive repair of pectus excavatum. *Interact Cardiovasc Thorac Surg.* 2019;29:497-502.
11. Park HJ, Jeong JY, Jo WM et al. Minimally invasive repair of pectus excavatum: a novel morphology-tailored, patient-specific approach. *J Thorac Cardiovasc Surg.* 2010;139:379-86.
12. Jeong JY, Lee J. Use of needlescope and crane technique to avoid cardiac injury in Nuss procedure. *Ann Thorac Surg.* 2014;98:386-7.
13. von Elm E, Altman DG, Egger M et al. The Strengthening the Reporting of Observational Studies in Epidemiology (STROBE) statement: guidelines for reporting observational studies. *Lancet* 2007;370:1453-7.
14. Pilegaard HK. Short Nuss bar procedure. *Ann Cardiothorac Surg.* 2016;5:513-8.
15. Daemen JHT, Loonen TGJ, Verhulst AC et al. Three-Dimensional Imaging of the Chest Wall: A Comparison Between Three Different Imaging Systems. *J Surg Res.* 2020;259:332-41.
16. Daemen JHT, Loonen TGJ, Coorens NA et al. Photographic documentation and severity quantification of pectus excavatum through three-dimensional optical surface imaging. *J Vis Commun Med.* 2020;43:190-7.
17. Togoro SY, Tedde ML, Eisinger RS et al. The Vacuum Bell device as a sternal lifter: An immediate effect even with a short time use. *J Pediatr Surg.* 2018;53:406-10.
18. Gould JL, Sharp RJ, Peter SD et al. The Minimally Invasive Repair of Pectus Excavatum Using a Subxiphoid Incision. *Eur J Pediatr Surg.* 2017;27:2-6.
19. St Peter SD, Sharp SW, Ostlie DJ et al. Use of a subxiphoid incision for pectus bar placement in the repair of pectus excavatum. *J Pediatr Surg.* 2010;45:1361-4.

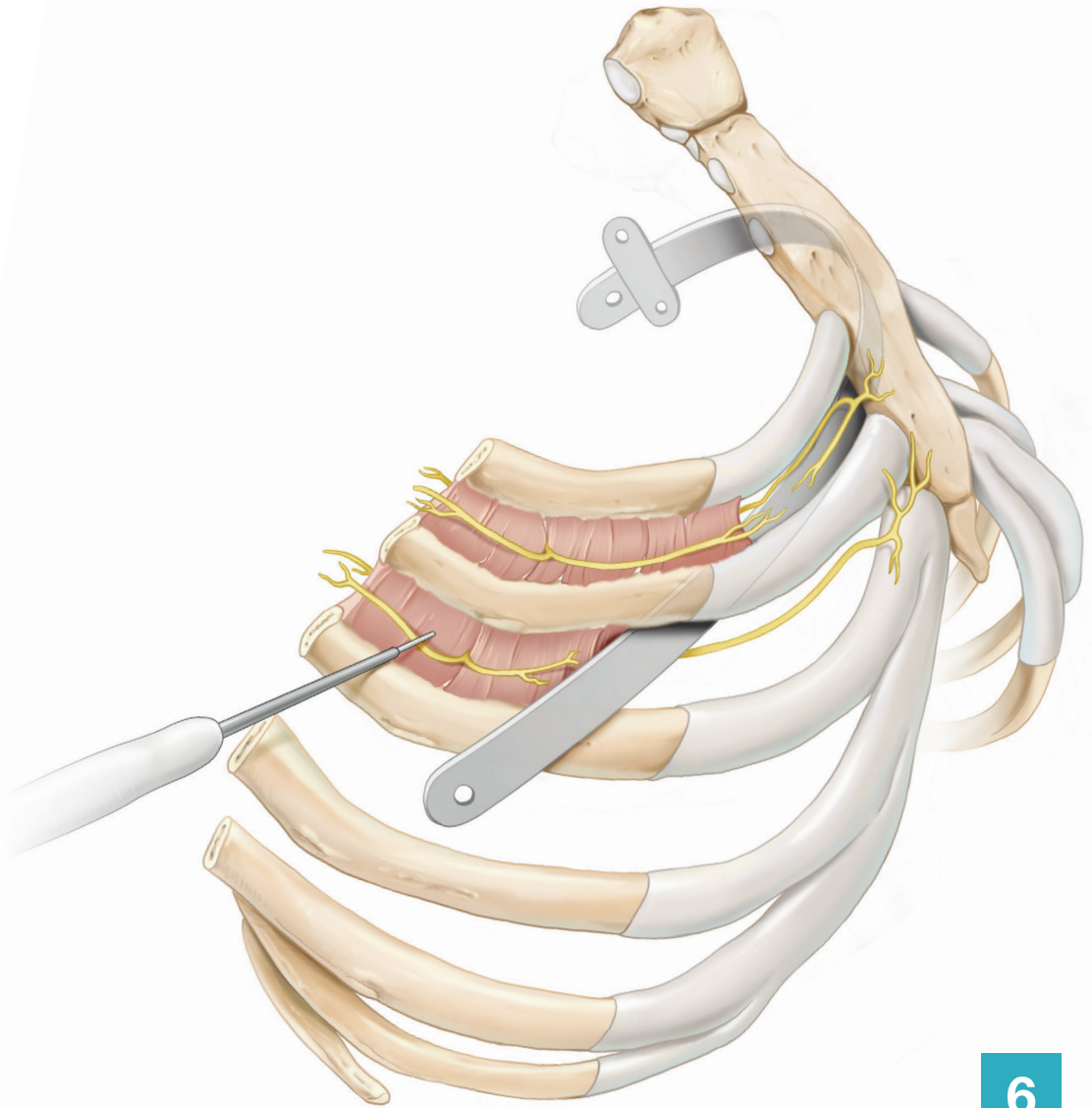
20. Johnson WR, Fedor D, Singhal S. A novel approach to eliminate cardiac perforation in the nuss procedure. *Ann Thorac Surg.* 2013;95:1109-11.
21. Jaroszewski DE, Johnson K, McMahon L et al. Sternal elevation before passing bars: a technique for improving visualization and facilitating minimally invasive pectus excavatum repair in adult patients. *J Thorac Cardiovasc Surg.* 2014;147:1093-5.
22. Takagi S, Oyama T, Tomokazu N et al. A new sternum elevator reduces severe complications during minimally invasive repair of the pectus excavatum. *Pediatr Surg Int.* 2012;28:623-6.
23. Tedde ML, de Campos JR, Wihlm JM et al. The Nuss procedure made safer: an effective and simple sternal elevation manoeuvre. *Eur J Cardiothorac Surg.* 2012;42:890-1.
24. Weber PG, Huemmer HP, Reingruber B. Forces to be overcome in correction of pectus excavatum. *J Thorac Cardiovasc Surg.* 2006;132:1369-73.
25. De Loos ER, Daemen JHT, Pennings AJ et al. Minimally invasive repair of pectus excavatum by the Nuss procedure: the learning curve. *J Thorac Cardiovasc Surg.* 2020 (epub ahead of print).
26. Fonkalsrud EW, Reemtsen B. Force required to elevate the sternum of pectus excavatum patients. *J Am Coll Surg.* 2002;195:575-7.

SUPPLEMENTARY DATA

Video 1: Intraoperative view of sternal elevation by the crane technique. This video is available online.
(<https://youtu.be/F-7edCo92ko>)

Daemen JHT*, **de Loos ER***, Vissers YLJ, Bakens MJAM, Maessen JG, Hulsewé KWE.
Interact CardioVasc Thorac Surg. 2020;31(4):486-498.

*equal contribution status



6

Intercostal nerve cryoablation versus thoracic epidural for postoperative analgesia following pectus excavatum repair:

a systematic review and meta-analysis

ABSTRACT

Objectives

Minimally invasive pectus excavatum repair via the Nuss procedure is associated with significant postoperative pain that is considered as the dominant factor affecting the duration of hospitalization. Postoperative pain after the Nuss procedures is commonly controlled by thoracic epidural analgesia. Recently, intercostal nerve cryoablation has been proposed as an alternative method with long-acting pain control and shortened hospitalization. The subsequent objective was to systematically review the outcomes of intercostal nerve cryoablation in comparison to thoracic epidural after the Nuss procedure.

Methods

Six scientific databases were searched. Data concerning the length of hospital stay, operative time and postoperative opioid usage were extracted. If possible, data were submitted to meta-analysis using the mean of differences, random-effects model with inverse variance method and I^2 test for heterogeneity.

Results

Four observational and 1 randomized study were included, enrolling a total of 196 patients. Meta-analyses demonstrated a significantly shortened length of hospital stay [mean difference -2.91 days; 95% confidence interval (CI) -3.68 to -2.15 ; $P < 0.001$] and increased operative time (mean difference 40.91 min; 95% CI 14.42 – 67.40 ; $P < 0.001$) for cryoablation. Both analyses demonstrated significant heterogeneity (both $I^2 = 91\%$; $P < 0.001$). Qualitative analysis demonstrated the amount of postoperative opioid usage to be significantly lower for cryoablation in 3 out of 4 reporting studies.

Conclusions

Intercostal nerve cryoablation during the Nuss procedure may be an attractive alternative to thoracic epidural analgesia, resulting in shortened hospitalization. However, given the low quality and heterogeneity of studies, more randomized controlled trials are needed.

INTRODUCTION

Pectus excavatum is the most common congenital anterior chest wall deformity with an estimated incidence of 1 in 300–400 live births [1–3]. Surgical correction of the deformity by the Nuss procedure is currently considered as the gold standard treatment because of its minimally invasive character, minimal blood loss, short operative time, and no need for resection of cartilage [4]. However, the instantaneous reshaping of the chest wall by the Nuss bar is also associated with significant and lengthy postoperative pain. Controlling this postoperative pain is the primary factor that affects the duration of hospitalization [5]. Possible pain therapies include thoracic epidural analgesia, intravenous patient-controlled analgesia (PCA), regional blocks and multimodal anaesthesia [6]. A web-based survey among primarily paediatric hospitals found thoracic epidural to be the primary analgesic modality in 91% of institutions while PCA was predominantly used upon epidural failure [7]. Despite the routine use of epidural analgesia, 35% of patients receiving the Nuss procedure experience a failed catheterization attempt or dysfunctional catheter that is removed within 24 h [8]. The assumption that routine epidural catheter placement offers the optimal pain treatment strategy may therefore be questioned [8]. An alternative method of pain relief is cryoablation or freezing of the intercostal nerves. This technique was first introduced in 1974 to prevent post-thoracotomy pain [9] while its use during the Nuss procedure was not described until 2016 [10]. Cryoablation is performed by application of a long-shafted probe that is cooled to approximately -60° , causing Wallerian degeneration of the nerve axons and thereby preventing pain transmission [11]. The advantage of cryoablation is that its analgesic effect lasts until complete axonal regeneration after 4 weeks [12]. Furthermore, this technique lacks the effects of epidural anaesthesia on sensory and motor functions of the lower limbs and the risk of complications such as urinary retention and infection and also lacks common side effects of morphinomimetics such as nausea and dizziness. Cryoablation may accordingly be superior to conventional analgesic methods to control the significant and lengthy pain after the Nuss procedure. Up until now, several small sample size series have compared cryoablation and thoracic epidural analgesia to control pain after the Nuss procedure. To support clinical decision-making, evidence should ideally arise from well-designed and comprehensive literature reviews. To date no such review has been published. The subsequent aim of this review is to systematically assess all randomized and non-randomized studies that compare cryoablation of the intercostal nerves and thoracic epidural as primary analgesic method after the Nuss procedure with length of hospital stay as the primary outcome. Secondary outcomes include the operative time, use of adjunct analgesic medication or methods, total opioid usage, postoperative pain scores and complications.

METHODS

Protocol and registration

Prior to start, a review protocol was drawn. This systematic review was written in compliance with the PRISMA statement [13].

Eligibility criteria

Types of participants

Participants of any race, gender, age, and body mass index who underwent minimally invasive repair of pectus excavatum by the Nuss procedure were eligible for inclusion.

Types of interventions

Studies that compared thoracic epidural analgesia with intercostal nerve cryoablation during the Nuss procedure for minimally invasive repair of pectus excavatum were considered. Studies involving co-interventions or adjunct pain medication were not excluded, provided that they were well documented.

Outcome measures

The primary outcome was postoperative length of hospital stay. Secondary outcomes and their corresponding definitions are mentioned below.

Types of studies

Both observational and randomized studies were examined for eligibility.

Search and study selection

Potentially eligible studies were identified by searching electronic scientific databases and trial registries. Only studies reported in English were considered. No publication date restrictions were imposed. The search terms were only applied to the title and abstract fields. The search strategy was first constructed for the PubMed database (searched through the National Library of Medicine) and subsequently adapted for the EMBASE (OvidSP), Web of Science (ISI Web of Knowledge), CINAHL (EBSCOhost) and Cochrane Library (Cochrane Library) databases (see the search queries in Supplementary Material, Data S1–S5). Identical queries were used to search the PROSPERO, WHO-ICTRP and Clinicaltrials.gov registries. An additional manual-related articles and cross-reference search was conducted to identify

reports that were not found through the aforementioned searches. This additional search also served as an indicator of the quality and completeness of the database search strategy. All searches were performed by a trained researcher (J.H.T.D.). The last search was performed on January 9th, 2020. Duplicates were discarded using the Mendeley find duplicates function (Mendeley Desktop v1.19.4 for MacOS, Mendeley Ltd, Elsevier, Amsterdam, the Netherlands). The remaining non-duplicate articles were judged for eligibility based on their title and abstract. Thereafter, full text of potentially eligible articles was read and assessed according to the predefined eligibility criteria. Studies meeting these criteria were included for systematic review, and if possible, meta-analysis. Study selection was performed in a standardized, unblinded manner by 2 independent reviewers (J.H.T.D. and M.J.A.M.B.). Inter-reviewer disagreements were, if not solvable between reviewers, resolved by the consultation of E.R.d.L.

Data collection and data items

Data were extracted by 1 reviewer (J.H.T.D.) and validated by a second reviewer (M.J.A.M.B.). Inter-reviewer disagreements were, if not solvable between reviewers, resolved by the consultation of E.R.d.L. Studies reporting continuous variables as mean and standard deviation (SD) were extracted as such. Variables reported as median and interquartile range or standard error of the mean were converted prior to extraction. Methods of conversion were reported elsewhere [14, 15]. If needed, values were derived from the available graphs. Information was extracted from each included paper on: (i) general study characteristics: study design, country, enrolment period and length of follow-up; (ii) study population characteristics: age, gender, body mass index, preoperative pectus excavatum severity index (e.g. Haller index or Correction index); (iii) characteristics of the intervention: brand of the cryoablation device used, cryoablation temperature and duration, the number of levels of intercostal nerves that were ablated, medication used for epidural analgesia, number of Nuss bars placed and use of sternal elevation techniques (e.g., the crane method [16]); (iv) primary outcome measure: postoperative length of hospital stay; and (v) secondary outcome measures: operative time (i.e., from incision to closure), blood loss, postoperative pain scores, time to removal of epidural catheter, use of additional pain medication, time to oral pain medications alone, total opioid usage [in morphine milligram equivalents (MME)], discharge opioid prescription, time to return of normal chest wall sensation (only for the cryoablation group) and complications. Adverse events that occurred during initial surgery or within 30 days after the procedure were considered to be complications.

Risk of bias in individual studies

The presence of bias within randomized controlled trials was evaluated by the updated Cochrane risk-of-bias tool for randomized trials (RoB 2) [17]. The RoB 2 tool produces a risk-of-bias judgement based on a 5-point scale that includes: low risk of bias, moderate risk, serious risk, critical risk, or no information. Non-randomized studies were evaluated by the Cochrane risk-of-bias tool for non-randomized studies of interventions (ROBINS-I), which judges studies on a 3-point scale, namely low risk of bias, some concerns or high risk [18].

Summary measures and synthesis of results

Quantitative synthesis of primary and secondary outcome measures was solely performed if studies were deemed sufficiently homogeneous. If not, data were reported as such. For the quantitative synthesis of continuous data, the difference in means (MD) was used to assess variables measured on the same scale among all studies. The standardized mean difference was chosen if studies reported their outcomes using different scales. An MD or standardized mean difference <0 favours intercostal nerve cryoablation over thoracic epidural analgesia. Meta-analyses were performed by Review Manager (RevMan v5.3 for Macintosh, Cochrane Collaboration, Oxford, UK) using a random-effects model with inverse variance method and I^2 test for heterogeneity. $P < 0.05$ was considered as statistically significant. An I^2 value of $>50\%$ in conjunction with a P-value of ≤ 0.10 indicated the presence of statistically significant heterogeneity among included studies. Outcomes were reported in forest plots. Subgroup analyses were not prespecified but performed if needed.

Risk of bias across studies

The probability of publication bias was explored both visually by a funnel plot [standard error by (standardized) mean difference] and statistically by Egger's linear regression test and Begg's and Mazumdar's rank correlation test. $P \leq 0.10$ was considered as statistically significant. Publication bias analyses were performed by Jamovi (Jamovi v0.9 for Macintosh, MAJOR software package add-on; <https://www.jamovi.org>, Sydney, Australia) since Cochrane's Review Manager does not provide the above-mentioned statistical tests.

RESULTS

Study selection

See the PRISMA flow diagram in Figure 1. The PubMed (n=64), EMBASE (n=342), Web of Science (n=1536), Cochrane Library (n=21) and CINAHL (n=20) database searches provided

a cumulative 1983 studies. The PROSPERO (n = 140), WHO-ICTRP (n = 62) and Clinicaltrials.gov (n = 44) registries provided an additional 246 studies. No records were identified through the cross-reference and related articles searches. No unpublished data were obtained. Of the 2229 citations, 221 duplicates were discarded. Title and abstract of the remaining 2008 studies were screened for eligibility, whereupon another 1999 records were discarded. The full text of the 9 remaining articles was read and thoroughly assessed for eligibility. Of these, 4 did clearly not meet the above-mentioned eligibility criteria and were excluded. Reasons for exclusion were as follows: no comparison to thoracic epidural analgesia (n = 2); not all controls received thoracic epidural analgesia (n = 1); the intercostal nerve cryoablation surgical technique was only reported (n = 1). The remaining 5 studies were considered eligible for systematic review, qualitative syntheses and pooling by quantitative synthesis (i.e., meta-analysis).

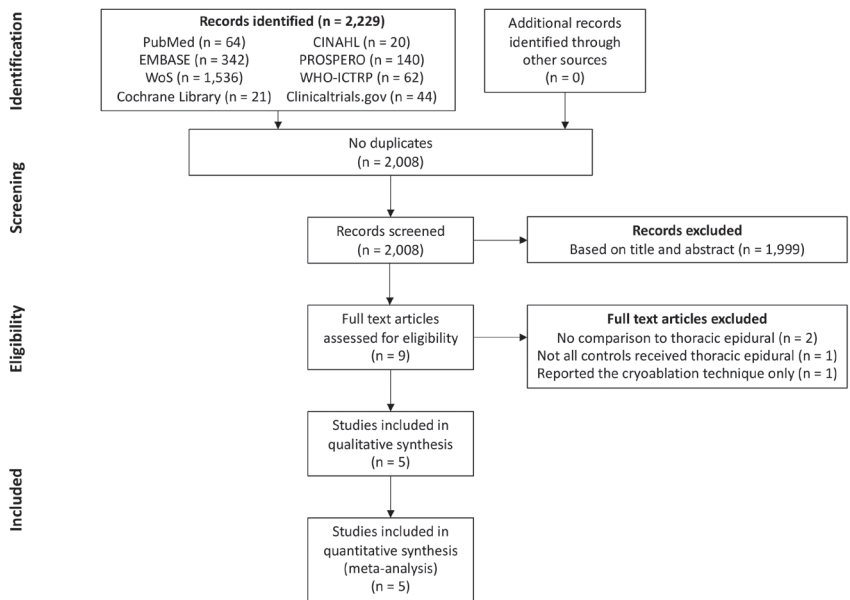


Figure 1: PRISMA flow diagram of the study selection procedure.

Study characteristics

Methods

Of the included papers, 1 was a single-centre randomized controlled trial, 3 were retrospective observational (2 single-centre and 1 multi-centre), and 1 study performed

a single-centre, single-arm prospective observational study and compared its results to a retrospective cohort (see Table 1). Studies were all conducted in the USA and enrolled patients between March 2013 and September 2018. The mean length of follow-up ranged from no follow-up after hospital discharge to 19.6 and 12 months for the thoracic epidural and cryoablation group, respectively.

Table 1: Study and baseline characteristics.

Author	Country	Study design	Treatment arm	Enrolment period	Number of participants, n	Male, n (%)	Age, mean (years)	BMI, mean (kg/m ²)	Preoperative Correction index	Preoperative Correction index	Length of FU (months)
Dekonenko et al. (2019)	USA	Data from a previous randomized controlled trial	EPI	May-2013 – Aug-2016	32	29 (90.6%)	15.0 (SD:1.6)	18.7 (SD:1.7)	3.6 (SD:0.7)	29.0 (SD:2.3)	0
		Single-arm, single-centre prospective observational study	CRYO	Nov-2017 – Sept-2018	35	29 (82.4%)	15.7 (SD:2.3)	18.4 (SD:2.3)	4.5 (SD:1.4)	37.3 (SD:13.1)	0
Graves et al. (2019)	USA	Single-centre randomized controlled trial	EPI	May-2016 – Mar-2018	10	8 (80%)	16.1 (SD:2.0)	19.8 (no SD)	3.7 (SD:0.6)	NR	12 (no SD)
			CRYO	May-2016 – Mar-2018	10	9 (90%)	20.9 (SD:4.3)	20.3 (no SD)	4.2 (SD:0.5)	NR	12 (no SD)
Harbaugh et al. (2018)		Single-centre retrospective observational study	EPI	Apr-2015 – Jul-2016	13	11 (85%)	17.0 (SD:1.7)	NR	3.3 (SD:1.0)	NR	NR
			CRYO	Jul-2016 – Aug-2017	19	19 (100%)	15.7 (SD:1.6)	NR	4.3 (SD:1.0)	NR	NR
Graves et al. (2017)	USA	Single-centre retrospective observational study	EPI	NR	15	NR	NR	NR	NR	NR	NR
			CRYO	Jun-2015 – Apr-2016	10	8 (80%)	16.8 (SD:6.2)	NR	4.8 (SD:1.4)	NR	7.6 (SD:2.2)
Keller et al. (2016)	USA	Multi-centre retrospective observational study	EPI	Mar-2013 – Jan-2016	26	23 (88%)	15.3 (SD:1.6)	NR	3.8 (SD:1.0)	NR	19.6 (SD:8.0)
			CRYO	Mar-2013 – Jan-2016	26	20 (77%)	15.6 (SD:1.5)	NR	4.2 (SD:1.4)	NR	5.3 (SD:2.8)

EPI, thoracic epidural; CRYO, cryoablation; SD, standard deviation; NR, not reported; BMI, body mass index; FU, follow-up.

Participants

In total, 196 participants were included, of which 100 (51%) in the thoracic epidural and 96 (49%) in the cryoablation group (see Table 1). Individuals were predominantly male (gender was reported for 147 of the 181 participants). The mean age of participants in the cryoablation group ranged from 15.6 to 20.9 years. The mean age of the thoracic epidural group was not reported by Graves et al. [22] and ranged from 15.0 to 17.0 years for the

remaining studies. The mean body mass index ranged from 18.7 to 19.8 kg/m² and 18.4 to 20.3 kg/m² for the epidural and cryoablation group, respectively. All participants underwent minimally invasive repair of their pectus excavatum by the Nuss procedure. The study of Harbaugh et al. [21] was the only one to include 2 participants with previous pectus repair in the thoracic epidural group. The preoperative mean Haller index in the epidural group was not reported by Graves et al. [22] and ranged from 3.3 to 3.8 for the other studies. In comparison, the mean Haller index in the cryoablation group ranged from 4.2 to 4.8. This difference was only found to be statistically significant for the study of Harbaugh et al. [21] and Dekonenko et al. [19]. In addition, Dekonenko et al. [19] also reported a statistically significant difference regarding preoperative Correction index [epidural: 29.0% (SD 2.3) vs cryoablation: 37.3% (SD 13.1)].

Interventions

For cryoablation, all studies utilized an Atricure (Atricure Inc., OH, USA) cryosurgical system. Cryoablation temperature was set to -60° [20–23], and each nerve was ablated for 120 s [19–23], followed by a thaw cycle of several to 5 s [19, 22] (see Table 2). Dekonenko et al. [19] and Keller et al. [23] always applied cryoablation to levels T4-7 and T3-7, respectively. Harbaugh et al. [21] and Graves et al. [22] always ablated 4–5 intercostal nerves depending on the level of incision, whereas the more recent study of Graves et al. [20] ablated 5 intercostal nerves (i.e. 1 at the level of incision and 2 above and below).

Only Graves et al. [20] reported the location of thoracic epidural catheter placement, namely between T5-6 or T6-7. Among all reporting studies, epidural infusion consisted of bupivacaine in combination with an opioid (hydromorphone or fentanyl) [20, 21, 23]. In the epidural group, 3 participants received multiple bars, whereas in the cryoablation group, 2 participants received 2 bars and the Crane method was used in 4 patients [19, 21, 23].

Table 2: Interventional characteristics.

Author	Treatment arm	Type of cryoablation device	Temperature cryoablation (°C)	Duration of cryoablation (seconds)	Duration of thaw cycle (seconds)	Number of ablated nerves	Level of thoracic epidural	Medication used for epidural analgesia	Number of Nuss bars implanted
Dekonenko et al. (2019)	EPI	-	-	-	-	-	NR	NR	1 bar in every case
	CRYO	CryolCE probe (Atricure Inc., OH, USA)	NR	120	3-5	T4-T7, bilaterally	-	-	1 bar in every case
Graves et al. (2019)	EPI	-	-	-	-	-	T5-6 or T6-7	0.1% ropivacaine and 2ug/cc fentanyl	NR
	CRYO	Atricure cryosurgical system (Atricure Inc., OH, USA)	-60	120	NR	5 intercostal nerves, bilaterally depending on the level of incision.	-	-	NR
Harbaugh et al. (2018)	EPI	-	-	-	-	-	NR	0.0625 or 0.125% bupivacaine and hydromorphone 5mcg/ml	3 cases with more than 1 bar
	CRYO	Atricure cryolCE (Atricure Inc., OH, USA)	-60	120	NR	4-5 intercostal nerves bilaterally, depending on the level of incision.	-	-	1 bar in every case
Graves et al. (2017)	EPI	-	-	-	-	-	NR	NR	NR
	CRYO	CryolCE probe (Atricure Inc., OH, USA)	-60	120	Few seconds	4-5 intercostal nerves bilaterally, depending on the level of incision.	-	-	NR
Keller et al. (2016)	EPI	-	-	-	-	-	NR	Hydromorphone with or without bupivacaine	1 bar in every case
	CRYO	CryolCE probe (Atricure Inc., OH, USA)	-60	120	-	T3-T7, bilaterally	-	-	2 cases with 2 bars

EPI, thoracic epidural; CRYO, cryoablation; NR, not reported.

Outcomes

All included studies reported the length of postoperative hospital stay on the same scale among both groups. Secondary outcomes were at least reported by 1 study each (see Table 3).

Table 3: Primary and secondary outcome measures.

Author	Treatment arm	Postoperative LOHS (days)	Operative time (minutes)	Blood loss (milliliter)	Time to removal of epidural catheter	Time to oral pain medications (hours)	Time to oral pain medications alone (hours)	Postoperative total opioid usage (oral morphine milligram equivalents)	Complications	Time to return of normal sensation
Dekonenko et al. (2019)	EPI	4.5 (SD:0.8)	62.7 (SD:21.7)	NR	NR	68.1 (SD:4.8)	68.1 (SD:25.1)	420 (no SD)	0	-
	CRYO	1.1 (SD:0.2)	101.0 (SD:35.6)	NR	NR	4.2 (SD:2.2)	20.3 (SD:13.0)	60 (no SD)	1 pneumothorax	NR
Graves et al. (2019)	EPI	5.0 (SD:0.5)	76.8 (SD:12.2)	NR	NR	NR	NR	684.0 (SD:191.8)	1 pneumothorax	-
	CRYO	3.0 (SD:0.5)	145.3 (SD:10.0)	NR	NR	NR	NR	268.0 (SD:165.2)	0	At 3 months: 6/10; at 1 year: all
Harbaugh et al. (2018)	EPI	6.0 (SD:1.7)	109.0 (SD:70.6)	NR	NR	NR	NR	2.1 (SD:1.9) ^a	1 reoperation, secondary to hemothorax. 1 pneumothorax.	-
	CRYO	3.3 (SD:0.8)	141.0 (SD:54.5)	NR	NR	NR	NR	2.3 (SD:2.0) ^a	2 reoperations due to bar displacement, 2 hemothorax or with numbness pneumothorax, 1 slipped bar postoperatively and 1 superficial site infection.	Gradual return at 2-4 months. Two patients up to 9 months postoperatively
Graves et al. (2017)	EPI	6.3 (SD:1.3)	NR	NR	NR	NR	NR	NR	NR	-
	CRYO	2.0 (SD:0.8)	NR	NR	NR	NR	NR	NR	1 bilateral pleural effusion	At 2 months: 5/10. at 3 months: 6/10. at 4 months: 8/10. In 2 cases: persistent numbness at 8 and 9 months
Keller et al. (2016)	EPI	5.8 (SD:0.9)	94.3 (SD:23.6)	12.4 (SD:10.3)	Between 2 and 3 days	NR	95.0 (SD:23.0)	119.8 (SD:95.1) ^b	0	-
	CRYO	3.5 (SD:0.8)	114.2 (SD:27.9)	16.9 (SD:8.7)	-	NR	45.1 (SD:17.0)	49.0 (SD:32.7) ^b	3 displaced bars	-

^a In oral morphine equivalents per kilogram; ^b Total intravenous opioid usage only; EPI, thoracic epidural; CRYO, cryoablation; LOHS, length of hospital stay; SD, standard deviation; NR, not reported.

Risk of bias within studies

Of the non-randomized studies, 2 were judged to possess a serious risk of bias [22, 23], whereas the remaining 2 were judged as moderate risk [19, 21]. The largest share in bias arose due to potential confounding (see Figure 2). For the randomized study of Graves et al. [20], some concerns of bias were present in the measurement of outcomes.

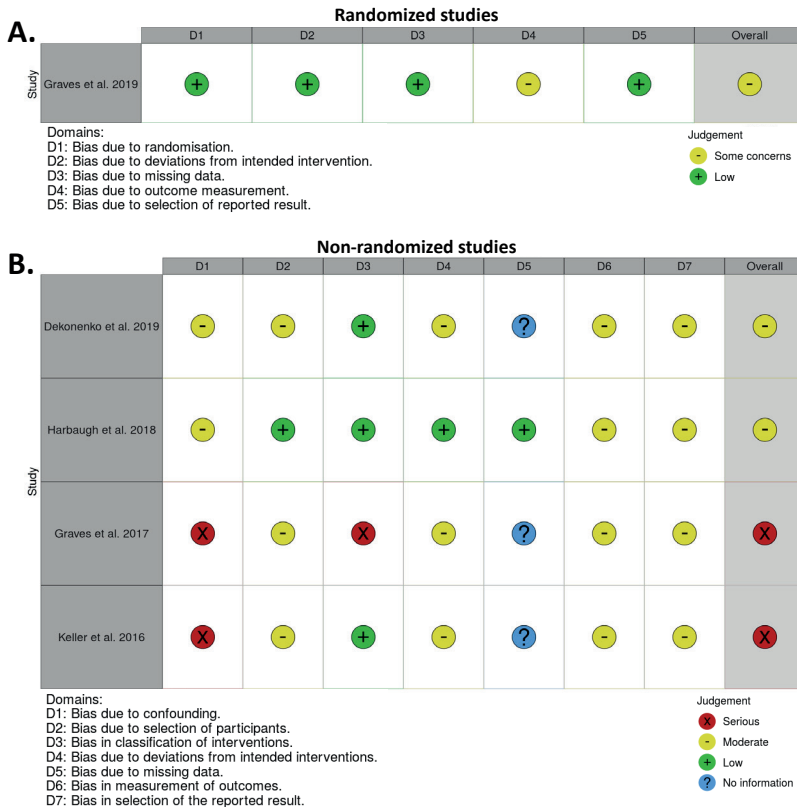


Figure 2: Risk-of-bias assessment within (A) randomized studies and (B) non-randomized studies.

Synthesis of results

Qualitative synthesis

Blood loss during surgery was only reported by Keller et al. [23]. Estimated blood loss was slightly lower for the thoracic epidural group [12.4 ml (SD 10.3) vs 16.9 ml (SD 8.7) for the cryoablation group], however, the method by which these values were estimated was

not reported. Postoperative pain scores appraised on the numeric rating scale did not significantly differ between groups [19–21]. Keller et al. [23] only reported pain scores for the cryoablation group (see Figure 3). Epidural catheters were removed between 2 and 3 days after surgery by Keller et al. [23], while removal times were not reported by any other study. Supplementary pain medication provided directly after surgery demonstrated substantial heterogeneity among included studies (Supplementary Material, Data S6). Additional PCA pumps with hydromorphone were given to all participants of both groups by Graves et al. [20], whereas Harbaugh et al. [21] used PCA in 4 (30.8%) patients in the epidural, and 13 (68.4%) patients in the cryoablation group due to inadequate pain control. Moreover, an additional intercostal nerve block was given to 2 patients in the cryoablation group [21]. In the study of Keller et al. [23], 7 (26.9%) participants received additional local subcutaneous infusion catheters in the epidural group, in contrast to 24 (92.3%) participants in the cryoablation group. No exact rationale was provided for this abundant usage of local infusion catheters by Keller et al. [23]. Two studies reported the time to oral pain medications alone to be 2- to 3-fold lower for cryoablation ($P < 0.01$ and $P < 0.001$) [19, 23]. Total postoperative opioid usage was reported by 4 out of 5 studies [19–21, 23]. Despite diverging definitions, 3 studies demonstrated a statistically significant difference in opioid usage that favoured cryoablation [19, 20, 23]. For the study of Dekonenko et al. [19], total opioid usage during inpatient stay was obtained from the available graph and was 420.0 MME for the thoracic epidural and 60.0 MME for the cryoablation group. This difference was statistically significant ($P < 0.001$). The most recent study of Graves et al. [20] also found statistically significant reduced mean opioid usage in the cryoablation group [268.0 MME (SD 165.2) vs 684.0 MME (SD 191.8) for the epidural group; $P < 0.001$]. Keller et al. [23] only reported the mean total intravenous opioid usage and revealed similar results [49.0 (SD 32.7) vs 119.8 MME (SD 95.1) for the cryoablation and epidural group; $P = 0.001$]. Harbaugh et al. [21] was the only one to find no statistically significant mean difference in postoperative opioid usage. Graves et al. [20] reported the recovery of chest sensation in all patients, 1 year after cryoablation. Gradual return typically occurred between 2 and 4 months [20–22]. However, some degree of numbness at 8 and 9 months was also reported in 1 and 3 patients, respectively [21, 22]. None of the included studies reported on the motor function and sensibility following epidural analgesia. Eleven (11.0%) complications occurred in the cryoablation group, in comparison to 3 (3.1%) complications in the thoracic epidural group. None of these complications could be directly related to the technical performance of the analgesic therapies. The majority of complications in the cryoablation group were bar displacements ($n = 6$; 6.0%) (see Table 3).

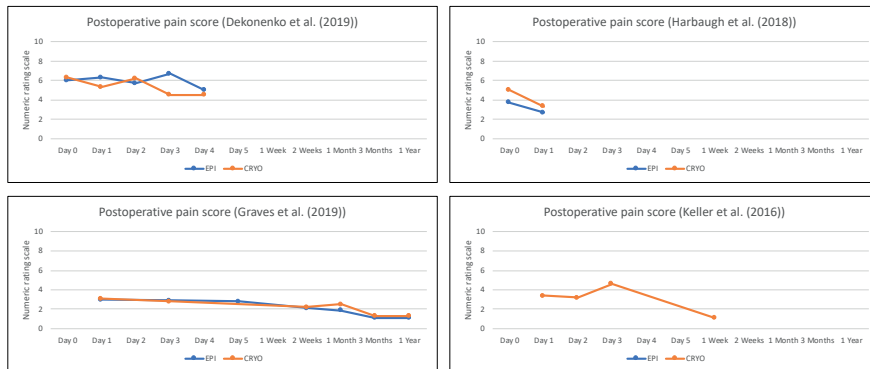


Figure 3: Mean postoperative pain scores (reported on the numeric rating scale) of the thoracic epidural and cryoablation group over time. EPI: thoracic epidural; CRYO: cryoablation.

Quantitative synthesis

Data regarding the length of postoperative hospital stay and duration of surgery were recorded by 5 and 4 studies, respectively. For both variables, identical definitions were used among studies. The mean length of hospital stay ranged from 4.5 to 6.3 days following thoracic epidural and 1.1 to 3.5 days following cryoablation. All individual study results demonstrated statistically significant shorter hospitalization in favour of cryoablation [19–23]. This trend was reproduced by meta-analysis that demonstrated cryoablation to be associated with a significantly shorter mean length of hospitalization [Figure 4A; MD -2.91 , 95% confidence interval (CI) -3.68 to -2.15 ; $P < 0.001$]. However, meta-analysis also detected a significant level of heterogeneity ($I^2 = 91\%$; $P < 0.001$). Post hoc subgroup analysis was performed to assess the effect of the use of concomitant analgesic methods on the length of hospital stay and heterogeneity. Subgroup analysis revealed a statistically significant difference among studies that did ($n = 3$) and did not ($n = 2$) use additional modalities of analgesia (PCA, intercostal nerve block or local infusion catheters) ($I^2 = 91.1\%$; $P < 0.001$). The subgroup using additional analgesic techniques demonstrated a lower decrease in hospitalization for the cryoablation group (Figure 4B; MD -2.19 , 95% CI -2.50 to -1.89 ; $P < 0.001$), compared to the subgroup without additional analgesic methods (MD -3.76 , 95% CI -4.63 to -2.90 ; $P < 0.001$). In addition, no heterogeneity was detected among studies in the subgroup that used concomitant analgesic methods ($I^2 = 0.0\%$; $P = 0.38$).

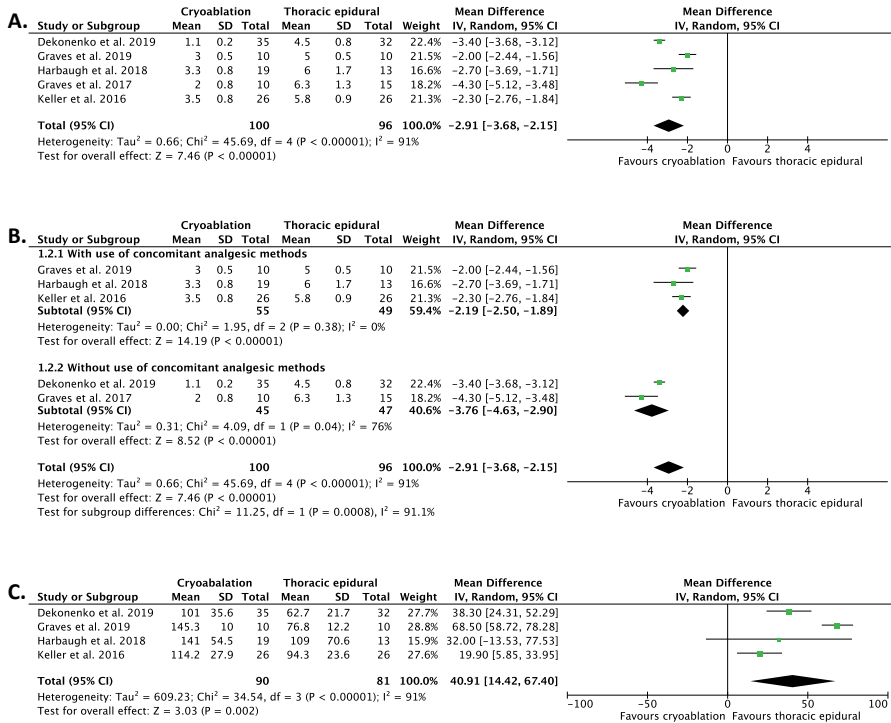


Figure 4: Meta-analyses (random-effects model with inverse variance method) demonstrating the effect of cryoablation and thoracic epidural on (A) the length of hospital stay, (B) the length of hospital stay among subgroups that did and did not use additional methods of analgesia and (C) the operative time. CI, confidence interval; IV, inverse variance; SD, standard deviation.

The mean operative time ranged from 62.7 to 109.0 min for the epidural group and 101.0 to 145.3 min for the cryoablation group. The difference in operative time reached statistical significance in 3 [19, 20, 23] out of 4 [19–21, 23] studies, favouring thoracic epidural analgesia. Pooled analysis demonstrated a statistically significant increased operative time among participants who received cryoablation during surgery (Figure 4C; MD 40.91, 95% CI 14.42 to 67.40; P=0.002). However, again meta-analysis detected a significant level of heterogeneity (I²=91%; P < 0.001).

Risk of bias across studies

A contour-enhanced funnel plot of the primary outcome was constructed (see Figure 5). On inspection potential asymmetry was seen in the bottom left side of the plot, indicating the potential presence of publication bias. However, as this is a region of high significance,

publication bias is less likely [24]. This was statistically confirmed by the Begg's and Mazumdar's rank correlation test ($P = 1.00$) and Egger's linear regression test ($P = 0.61$).

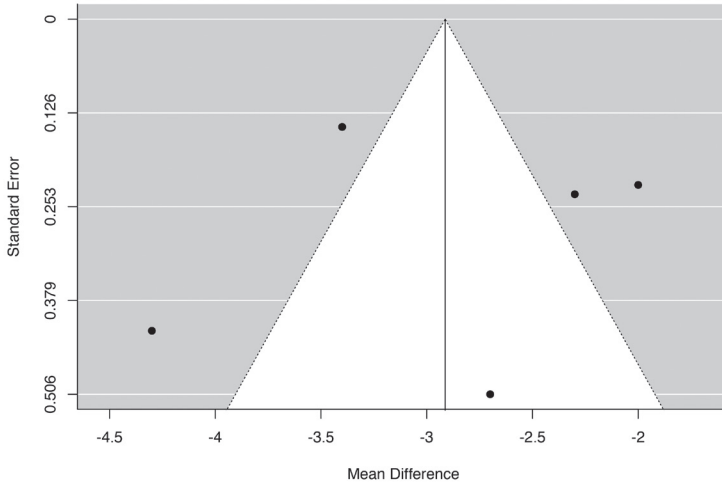


Figure 5: A standard error by mean difference plot of the primary outcome to detect the presence of publication bias.

DISCUSSION

This systematic review and meta-analysis compared cryoablation of the intercostal nerves and thoracic epidural analgesia as primary analgesic method after the Nuss procedure with length of hospital stay as primary outcome. Four non-randomized and 1 randomized study were included, enrolling a total of 196 patients. Characteristics of included patients corresponded with previously reported series on the Nuss procedure [25, 26]. Quantitative analyses showed cryoablation of the intercostal nerves to be associated with a significantly reduced length of hospital stay of 2.91 days compared to thoracic epidural analgesia. However, a significant level of heterogeneity was detected ($I^2 = 91.0\%$; $P < 0.001$). This heterogeneity potentially arose from differences in the use of additional pain therapies, given that the majority of cryoablation patients in 3 out of 5 studies received additional PCA pumps, local infusion catheters or intercostal nerve blocks [20, 21, 23]; resulting in a relatively longer length of hospitalization. This was confirmed by subgroup analysis, which demonstrated a statistically significant longer length of hospital stay among studies that used additional pain therapies compared to those that did not ($I^2 = 91.1\%$; $P < 0.001$). However, it has to be remarked that the number of studies included per subgroup was

rather low (3 and 2, respectively). Although the use of additional pain therapies may explain the observed heterogeneity, it is unknown whether additional pain therapies are necessary given the diversity of their use. Nevertheless, it should be noted that all patients have their individual pain perception and susceptibility. A tailor-made approach for additional pain relief could therefore be warranted. Future research should critically evaluate whether adjunct pain therapies are indicated since these may have a direct effect on the duration of hospitalization.

Despite shorter hospitalization in favour of cryoablation, no significant differences in pain scores were found among both groups (Figure 3) [19–21]. However, given that the general postoperative aim is to reduce the patients' pain experience to an acceptable level, pain scores are unlikely to differ. The length of hospitalization and use of opiates were subsequently considered to be the most important determinants in the comparison of pain management techniques. Besides a reduction in hospitalization, postoperative opioid requirement was found to be significantly lower among cryoablation patients in 3 out of 4 individual studies [20, 21, 23]. Dekonenko et al. [19] and Graves et al. [20], moreover, reported the differences in postoperative opioid usage to become larger following adjustment for the length of hospital stay.

The shortened hospitalization associated with cryoablation may not only improve patient recovery but could also cut healthcare costs; however, to compare the cost-effectiveness of both techniques, all expenses including ancillary costs should be evaluated in future research. The overall increased operation time associated with cryoablation was 40.91 min and ranged from 19.90 to 68.50 min per study [19–21, 23]. This increase partially resulted from the freeze–thaw cycles lasting around 2 min per nerve (4–5 nerves were ablated bilaterally). The remaining part may be attributed to anatomic preparation and cryoprobe positioning, whereby the wide range of times was most likely due to variations in techniques and experience that is likely to improve over time. On the contrary, the time needed for epidural catheterization has previously been reported to be 11 min [27], while the total time needed to obtain adequate pain relief may be lengthened due to epidural catheter(-ization) failure that is known to occur in 35% of patients receiving the Nuss procedure [8]. Another disadvantage of epidural is the frequent need for urinary catheterization, subsequently impairing patient mobility and lengthening recovery.

Complications occurred in 11.0% and 3.1% of cases in the cryoablation and thoracic epidural group, respectively. None of these complications could be directly related to the analgesic

therapy procedures. The most common complication in the cryoablation group was displacement of the Nuss bar (6.0%). This was comparable to the upper limit of previously reported series (after the introduction of stabilizers) that found displacement rates of 1.8–5.8% [26, 28–30]. Keller et al. [23] suggested that bar displacement following cryoablation might result from enhanced pain control resulting in increased physical activity. Pain thus may be protective of bar displacement due to reduced activity. However, this hypothesis was not supported by the fact that no difference in pain scores was found in this review. Nevertheless, a technically well-performed procedure and patient education and selection remain key to prevent bar displacement, while bar instability, early excessive exercise, operation at a young age and Grand Canyon type pectus excavatum [28] are known risk factors for displacement, regardless of the analgesic method used.

Zobel et al. [31] investigated the resolution of chest numbness and incidence of neuropathic pain following cryoablation and found numbness of patients aged 21 or below to resolve within 3.4 months without neuropathic pain. In our series, normal chest sensation returned between 2 and 4 months after surgery while numbness persisted in 4 patients up to 8 to 9 months after cryoablation. No patients experienced chronic neuralgia. Nevertheless, 1 patient experienced transitory neuropathic pain [22] while another patient returned to the emergency department because of neuropathic pain [23]. In the latter, Keller et al. [23] had not prescribed a neuropathic analgesic on discharge like the other patients had. Keller et al. [23] was the only one to prescribe gabapentin after discharge whereas it was standardly provided by 2 studies during hospital stay [19, 23]. Recapitulating, we can assume that the incidence of neuropathic pain in young patients, as included in this study, is low.

Limitations

The main limitations of this review include the low number of included studies and participants, the fact that only one randomized trial was included, the overall methodological quality that ranged from some concerns to serious risk of bias, the use of data conversion methods and the heterogeneity among included studies. In addition, despite the funnel plot asymmetry and statistical analyses were not indicative for publication bias, its presence cannot be completely excluded while the tests used are known to be underpowered if less than 10 studies are included.

CONCLUSION

Cryoablation of the intercostal nerves during the Nuss procedure may be an attractive alternative to thoracic epidural analgesia with reduced length of hospital stay of 2.91 days. However, given the overall low methodological quality and heterogeneity of studies, well-designed randomized controlled trials are necessary to corroborate the current evidence.

REFERENCES

1. Brochhausen C, Turial S, Müller FKP, Schmitt VH, Coerdts W, Wihlm J-M et al. Pectus excavatum: history, hypotheses and treatment options. *Interact Cardiovasc Thorac Surg*. 2012;14:801-06.
2. Chung CS, Myrianthopoulos NC. Factors affecting risks of congenital malformations. I. Analysis of epidemiologic factors in congenital malformations. *Birth Defects Orig Artic Ser*. 1975;11:1-22.
3. Coskun ZK, Turgut HB, Demirsoy S, Cansu A. The Prevalence and Effects of Pectus Excavatum and Pectus Carinatum on the Respiratory Function in Children between 7–14 Years Old. *Indian J Pediatr*. 2010;77:1017-19.
4. Mao YZ, Tang S, Li S. Comparison of the Nuss versus Ravitch procedure for pectus excavatum repair: an updated meta-analysis. *J Pediatr Surg*. 2017;52:1545-52.
5. Schlatter MG, Nguyen LV, Tecos M, Kalbfell EL, Gonzalez-Vega O, Vlahu T. Progressive reduction of hospital length of stay following minimally invasive repair of pectus excavatum: A retrospective comparison of three analgesia modalities, the role of addressing patient anxiety, and reframing patient expectations. *J Pediatr Surg*. 2019;54:663-69.
6. Singhal NR, Jerman JD. A review of anesthetic considerations and postoperative pain control after the Nuss procedure. *Semin Pediatr Surg*. 2018;27:156-60.
7. Muhly WT, Maxwell LG, Cravero JP. Pain management following the Nuss procedure: a survey of practice and review. *Acta Anaesthesiol Scand*. 2014;58:1134-9.
8. St Peter SD, Weesner KA, Sharp RJ, Sharp SW, Ostlie DJ, Holcomb GW. Is epidural anesthesia truly the best pain management strategy after minimally invasive pectus excavatum repair? *J Pediatr Surg*. 2008;43:79-82.
9. Nelson KM, Vincent RG, Bourke RS, Smith DE, Blakeley WR, Kaplan RJ et al. Intraoperative Intercostal Nerve Freezing to Prevent Postthoracotomy Pain. *Ann Thorac Surg*. 1974;18:280-85.
10. Kim S, Idowu O, Palmer B, Lee SH. Use of transthoracic cryoanalgesia during the Nuss procedure. *J Thorac Cardiovasc Surg*. 2016;151:887-88.
11. Evans PJD. Cryoanalgesia. *Anaesthesia* 1981;36:1003-13.
12. Moorjani N, Zhao F, Tian Y, Liang C, Kaluba J, Maiwand MO. Effects of cryoanalgesia on post-thoracotomy pain and on the structure of intercostal nerves: a human prospective randomized trial and a histological study. *Eur J Cardiothorac Surg*. 2001;20:502-07.
13. Moher D, Liberati A, Tetzlaff J, Altman DG, PRISMA Group. Preferred Reporting Items for Systematic Reviews and Meta-Analyses: The PRISMA Statement. *Ann Intern Med*. 2009;151:264-69.
14. Altman DG, Bland JM. Standard deviations and standard errors. *BMJ* 2005;331:903-03.
15. Wan X, Wang W, Liu J, Tong T. Estimating the sample mean and standard deviation from the sample size, median, range and/or interquartile range. *BMC Med Res Methodol*. 2014;14:135.
16. Park HJ, Chung W-J, Lee IS, Kim KT. Mechanism of bar displacement and corresponding bar fixation techniques in minimally invasive repair of pectus excavatum. *J Pediatr Surg*. 2008;43:74-78.
17. Sterne JAC, Savovic J, Page MJ, Elbers RG, Blencowe NS, Boutron I et al. RoB 2: a revised tool for assessing risk of bias in randomised trials. *BMJ* 2019;366:14898.
18. Sterne JA, Hernan MA, Reeves BC, Savovic J, Berkman ND, Viswanathan M et al. ROBINS-I: a tool for assessing risk of bias in non-randomised studies of interventions. *BMJ* 2016;355:i4919.
19. Graves C, Idowu O, Lee S, Padilla B, Kim S. Intraoperative cryoanalgesia for managing pain after the Nuss procedure. *J Pediatr Surg*. 2017;52:920-24.

20. Harbaugh CM, Johnson KN, Kein CE, Jarboe MD, Hirschl RB, Geiger JD et al. Comparing outcomes with thoracic epidural and intercostal nerve cryoablation after Nuss procedure. *J Surg Res.* 2018;231:217-23.
21. Dekonenko C, Dorman RM, Duran Y, Juang D, Aguayo P, Fraser JD et al. Postoperative pain control modalities for pectus excavatum repair: A prospective observational study of cryoablation compared to results of a randomized trial of epidural vs patient-controlled analgesia. *J Pediatr Surg.* 2019; doi: 10.1016/j.jpedsurg.2019.09.02.
22. Graves CE, Moyer J, Zobel MJ, Mora R, Smith D, O'Day M et al. Intraoperative intercostal nerve cryoablation During the Nuss procedure reduces length of stay and opioid requirement: A randomized clinical trial. *J Pediatr Surg.* 2019;54:2250-56.
23. Keller BA, Kabagambe SK, Becker JC, Chen YJ, Goodman LF, Clark-Wronski JM et al. Intercostal nerve cryoablation versus thoracic epidural catheters for postoperative analgesia following pectus excavatum repair: Preliminary outcomes in twenty-six cryoablation patients. *J Pediatr Surg.* 2016;51:2033-38.
24. Sterne JA, Sutton AJ, Ioannidis JP, Terrin N, Jones DR, Lau J et al. Recommendations for examining and interpreting funnel plot asymmetry in meta-analyses of randomised controlled trials. *BMJ* 2011;343:d4002.
25. Dzielicki J, Korlacki W, Janicka I, Dzielicka E. Difficulties and limitations in minimally invasive repair of pectus excavatum — 6 years experiences with Nuss technique. *Eur J Cardiothorac Surg.* 2006;30:801-04.
26. Kelly RE, Goretsky MJ, Obermeyer R, Kuhn MA, Redlinger R, Haney TS et al. Twenty-one years of experience with minimally invasive repair of pectus excavatum by the Nuss procedure in 1215 patients. *Ann Surg.* 2010;252:1072-81.
27. Koenig T, Neumann C, Ocker T, Kramer S, Spies C, Schuster M. Estimating the time needed for induction of anaesthesia and its importance in balancing anaesthetists' and surgeons' waiting times around the start of surgery. *Anaesthesia* 2011;66:556-62.
28. Park HJ, Lee SY, Lee CS. Complications associated with the nuss procedure: analysis of risk factors and suggested measures for prevention of complications. *J Pediatr Surg.* 2004;39:391-95.
29. Pilegaard HK, Licht PB. Early results following the Nuss operation for pectus excavatum – a single-institution experience of 383 patients. *Interact Cardiovasc Thorac Surg.* 2008;7:54-57.
30. Nuss D, Obermeyer RJ, Kelly RE. Nuss bar procedure: past, present and future. *Ann Cardiothorac Surg.* 2016;5:422-33.
31. Zobel MJ, Ewbank C, Mora R, Idowu O, Kim S, Padilla BE. The incidence of neuropathic pain after intercostal cryoablation during the Nuss procedure. *Pediatr Surg Int.* 2020;36:317-24.

SUPPLEMENTARY MATERIALS

Supplementary Data S1: PubMed

Overview

Database	PubMed
Platform	National Library of Medicine
Date of search	January 9 th , 2020
Number of results	64

Syntax guide

Mesh	Medical subject headings
tiab	Words in title or abstract
*	Truncation

Search	Query	Items found
#1	"funnel chest"[Mesh]	2,353
#2	funnel chest*[tiab] OR pectus excavatum*[tiab] OR funnel breast*[tiab] OR chonechondrosternon[tiab] OR funnel thorax[tiab] OR foveated chest*[tiab] OR foveated thorax[tiab] OR koilosternia[tiab]	2,657
#3	"sternum"[Mesh]	9,155
#4	sternum*[tiab]	6,842
#5	"thoracic wall"[Mesh]	4,211
#6	thorax wall*[tiab] OR thoracic wall*[tiab] OR chest wall*[tiab]	18,781
#7	#1 OR #2 OR #3 OR #4 OR #5 OR #6	33,647
#8	Nuss[tiab] OR bar[tiab] OR MIRPE[tiab] OR minimal* invasive repair[tiab]	332
#9	#7 OR #8	33,804
#10	"Cryosurgery"[Mesh]	12,719
#11	"Freezing"[Mesh]	23,689
#12	Cryoablation*[tiab] OR cryosurger*[tiab] OR cryoanage*[tiab] OR cryoprobe*[tiab] OR freez*[tiab] OR cryoneuro*[tiab] OR cryocoagulation*[tiab] OR cryogen*[tiab]	81,204
#13	#10 OR #11 OR #12	99,445
#14	#9 AND #13	64

Supplementary Data S2: EMBASE**Overview**

Database	EMBASE
Platform	EMBASE
Date of search	January 9 th , 2020
Number of results	342

Syntax guide

/exp	EMtree keyword with explosion
:ab,ti	Words in title or abstract
*	Truncation

Search	Query	Items found
#1	'funnel chest'/exp	3,810
#2	'thorax wall'/exp	13,784
#3	'chest wall*':ab,ti OR 'thorax wall*':ab,ti OR 'thoracic wall*':ab,ti	67,009
#4	'funnel breast*':ab,ti OR 'funnel chest*':ab,ti OR chonechondrosternon:ab,ti OR 'foveated chest*':ab,ti OR 'foveated thorax':ab,ti OR 'funnel thorax':ab,ti OR koilosternia:ab,ti OR 'pectus excavatum':ab,ti	3,324
#5	#1 OR #2 OR #3 OR #4	32,862
#6	'nuss procedure'/exp	263
#7	'nuss operation'/exp	12
#8	'nuss technique'/exp	15
#9	'nuss repair'/exp	11
#10	'Nuss':ab,ti OR 'bar':ab,ti OR 'MIRPE':ab,ti OR 'minimal* invasive repair':ab,ti	30,433
#11	#6 OR #7 OR #8 OR #9 OR #10	30,451
#12	#5 OR #11	62,345
#13	'cryoablation'/exp	6,773
#14	'cryosurgery'/exp	11,078
#15	'cryoneurolysis'/exp	19
#16	'cryoablation*':ab,ti OR 'cryosurger*':ab,ti OR 'cryoanalge*':ab,ti OR 'cryoprobe*':ab,ti OR 'freez*':ab,ti OR 'cryoneuro*':ab,ti OR 'cryocoagulation':ab,ti OR 'cryogen*':ab,ti	95,883
#17	#13 OR #14 OR #15 OR #16	104,335
#18	#12 AND #17	342

Supplementary Data S3: Web of Science

Overview		
Database	Web of Science	
Platform	ISI Web of Knowledge	
Date of search	January 9 th , 2020	
Number of results	21	
Syntax guide		
*	Truncation	
Search	Query	Items found
#1	TOPIC: (funnel breast* OR funnel chest* OR chonechondrosternon OR foveated chest* OR foveated thorax OR funnel thorax OR koilosternia OR pectus excavatum OR sternum* OR chest wall* OR thorax wall* OR thoracic wall* OR Nuss OR Bar OR MIRPE OR minimal* invasive repair) <i>Indexes=SCI-EXPANDED, SSCI, A&HCI, ESCI Timespan=All years</i>	304,062
#2	TOPIC: (cryoablation* OR cryosurger* OR cryoanalge* OR cryoprobe* OR freez* OR cryoneuro* OR cryocoagulation OR cryogen*) <i>Indexes=SCI-EXPANDED, SSCI, A&HCI, ESCI Timespan=All years</i>	149,958
#3	#1 AND #2 <i>Indexes=SCI-EXPANDED, SSCI, A&HCI, ESCI Timespan=All years</i>	1,536

Supplementary Data S4: Cochrane Library

Overview		
Database	Cochrane Library	
Platform	Cochrane Library	
Date of search	January 9 th , 2020	
Number of results		
Syntax guide		
ti,ab,kw	Words in title, abstract or author keywords	
*	Truncation	
Search	Query	Items found
#1	(funnel breast* OR funnel chest* OR chonechondrosternon OR foveated chest* OR foveated thorax OR funnel thorax OR koilosternia OR pectus excavatum OR sternum* OR chest wall* OR thorax wall* OR thoracic wall* OR Nuss OR Bar OR MIRPE OR minimal* invasive repair):ti,ab,kw	8,327
#2	(cryoablation* OR cryosurger* OR cryoanalge* OR cryoprobe* OR freez* OR cryoneuro* OR cryocoagulation OR cryogen*):ti,ab,kw	3,526
#3	#1 AND #2	21

Supplementary Data S5: CINAHL

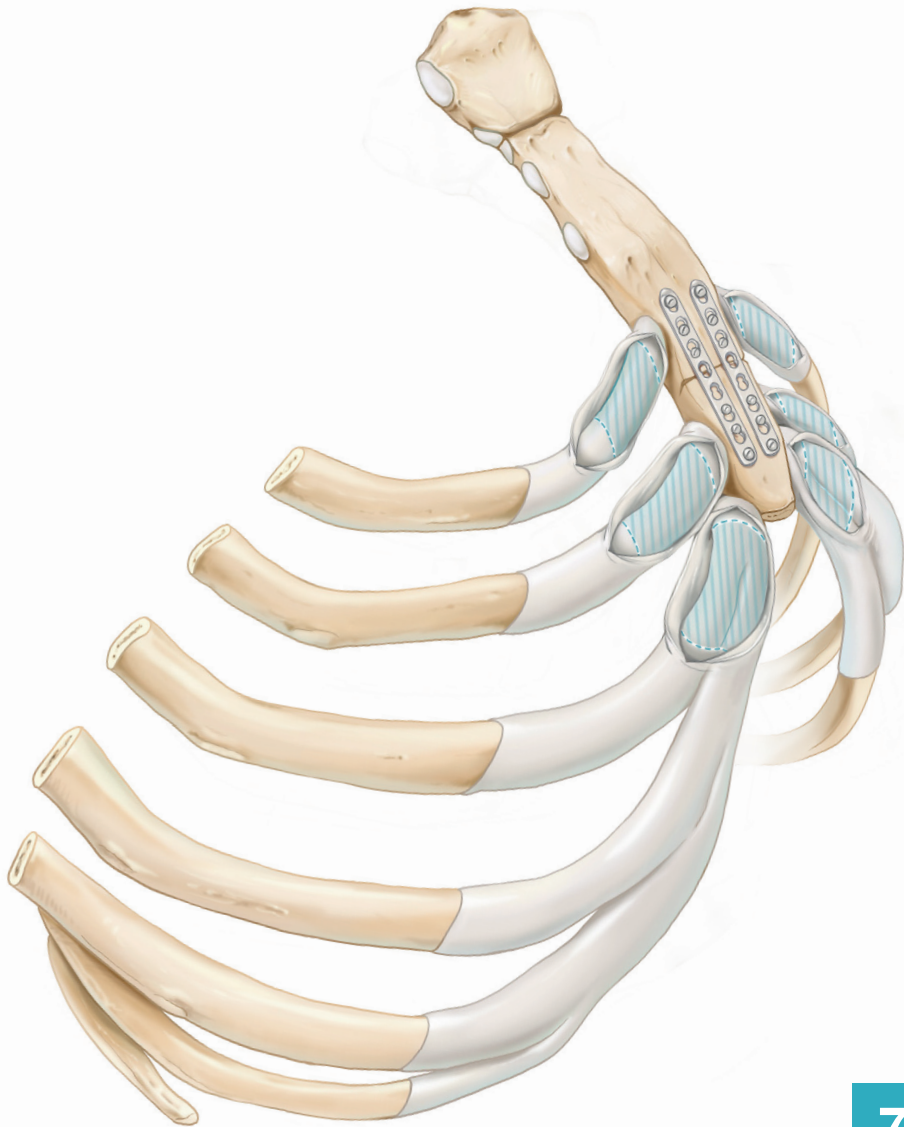
Overview		
Database	CINAHL	
Platform	EBSCOhost	
Date of search	January 9 th , 2020	
Number of results	20	
Syntax guide		
TI	Words in title	
AB	Words in abstract	
*	Truncation	
Search ID#	Query	Items found
S1	TI (funnel breast* OR funnel chest* OR chonechondrosternon OR foveated chest* OR foveated thorax OR funnel thorax OR koilosternia OR pectus excavatum OR sternum* OR chest wall* OR thorax wall* OR thoracic wall* OR Nuss OR Bar OR MIRPE OR minimal* invasive repair)	3,150
S2	AB (funnel breast* OR funnel chest* OR chonechondrosternon OR foveated chest* OR foveated thorax OR funnel thorax OR koilosternia OR pectus excavatum OR sternum* OR chest wall* OR thorax wall* OR thoracic wall* OR Nuss OR Bar OR OR MIRPE OR minimal* invasive repair)	7,281
S3	S1 OR S2	9,360
S4	TI (cryoablation* OR cryosurger* OR cryoanalge* OR cryoprobe* OR freez* OR cryoneuro* OR cryocoagulation OR cryogen*)	2,507
S5	AB (cryoablation* OR cryosurger* OR cryoanalge* OR cryoprobe* OR freez* OR cryoneuro* OR cryocoagulation OR cryogen*)	3,775
S6	S5 OR S6	5,185
S7	S3 AND S6	20

Supplementary Data S6: Supplementary pain medication

Author	Treatment arm	Adjunct pain medication/therapy (directly after CRYO or following EPI removal)	Discharge prescription
Dekonenko et al. (2019)	EPI	Acetaminophen (15 mg/kg, max 1 g, every 6 h), ibuprofen (10 mg/kg, max 600 mg, every 6 h), extended release oxycodone (10 mg, max 40 mg, every 12 h), and oxycodone as needed for breakthrough pain (0.05–0.15 mg, max 10 mg/dose, every 3 h)	NR
	CRYO	gabapentin (300 mg, max 900 mg, every 8 h), acetaminophen (15 mg/kg, max 1 g, every 6 h), ibuprofen (10 mg/kg, max 600 mg, every 6 h), extended-release oxycodone (10 mg, max 10 mg, every 12 h), and as needed oxycodone (5 mg, max 7.5 mg, every 4 h)	NR
Graves et al. (2019)	EPI	Hydromorphone PCA, standing IV acetaminophen, and 48h standing ketorolac. Once patients were tolerating a diet, they were converted to: oral oxycodone, acetaminophen, and ibuprofen	Acetaminophen, ibuprofen and oxycodone
	CRYO	Hydromorphone PCA, standing IV acetaminophen, and 48h standing ketorolac. Once patients were tolerating a diet, they were converted to: oral oxycodone, acetaminophen, and ibuprofen	Acetaminophen, ibuprofen and oxycodone
Harbaugh et al. (2018)	EPI	Ketorolac or ibuprofen on a scheduled basis and diazepam or cyclobenzaprine as needed. In addition, PCA was used in 4 patients due to inadequate pain control.	Ibuprofen and acetaminophen with oxycodone and diazepam (if taken in the hospital)
	CRYO	Ketorolac or ibuprofen on a scheduled basis and diazepam or cyclobenzaprine as needed. In addition, PCA was used in 13 patients due to inadequate pain control. In addition, two received intercostal nerve block.	Ibuprofen and acetaminophen with oxycodone and diazepam (if taken in the hospital)
Graves et al. (2017)	EPI	NR	NR
	CRYO	Oral acetaminophen or intravenous hydrocodone	NR
Keller et al. (2016)	EPI	Directly postoperative narcotics and 48 to 72h intravenous ketorolac. Diazepam when needed. Upon adequate intake patients were transitioned to scheduled ibuprofen and oral narcotics as needed. Seven patients also received local infusion catheters with 0.2% ropivacaine, infused at a rate of 3-6mL/hour, and removed on postoperative day two or three.	Around the clock ibuprofen, oral narcotics and diazepam as needed.
	CRYO	Directly postoperative narcotics and 48 to 72h intravenous ketorolac. Diazepam when needed. Gabapentin from day postoperative day 2. Upon adequate intake patients were transitioned to scheduled ibuprofen and oral narcotics as needed. Twenty-four patients also received local infusion catheters with 0.2% ropivacaine, infused at a rate of 3-6mL/hour, and removed on postoperative day two or three.	Around the clock ibuprofen, daily 300mg gabapentin, oral narcotics and diazepam as needed.

EPI, thoracic epidural; CRYO, cryoablation; h, hour; NR, not reported; PCA, patient-controlled analgesia.

De Loos ER, Hulsewé KWE, Van Loo ERJ, Kragten JA, Höppener PF, Busari JO, Vissers YLJ.
J Thorac Dis. 2020; 12(7):3631-3639.



7

Does the use of locking plates or mesh and wires influence the risk of symptomatic non-union of the sternal osteotomy after modified Ravitch?

ABSTRACT

Background

Patients with pectus excavatum which is unsuitable for minimally invasive repair are usually treated by modified Ravitch procedure. For fixation of the sternal osteotomy, mesh and wires are mostly used. To decrease non-union risk, we introduced a technique with double locking plate fixation of the osteotomy and compared this to fixation using mesh and wires.

Methods

Patients undergoing a modified Ravitch procedure for pectus excavatum between 2006 and 2016 were included. From 2006 to 2012, the sternum was fixated with mesh and wires. From 2012 to 2016, locking compression plates (LCP) were used. Baseline parameters, symptomatic non-union and total number of complications were retrospectively compared. Statistical analysis was performed using Mann-Whitney or Fisher's exact test. Data are presented as means +/- SD.

Results

Forty-four patients were included. In 18 patients, the sternum was fixed with mesh and wires, in 26 patients with LCP. Mean follow-up was 35 months in the mesh and 30 months in the LCP group, $p=0.71$. Haller index was similar in both groups (mesh 3.8 ± 1.3 vs. LCP 3.9 ± 1.1 , $p=0.81$). Symptomatic non-union occurred in 17% ($n=3$) in the mesh group and did not occur after LCP, $p=0.062$. Total number of complications was 33% ($n=6$) in the mesh group and 15% ($n=4$) after LCP, $p=0.27$.

Conclusions

After modified Ravitch procedure, union of the sternal osteotomy is challenging. In this retrospective cohort study, a lower incidence of symptomatic non-union was observed after fixation of the sternum with locking compression plates, with a trend towards statistical significance.

INTRODUCTION

Pectus excavatum is a common deformity of the anterior thoracic wall. Pectus excavatum represents 90% of the congenital chest wall deformities and is associated with connective tissue diseases as Marfan syndrome or Ehlers-Danlos syndrome [1]. The severity of the pectus is classically calculated by the Haller index, which divides the distance at the widest point of the inner chest by that between the sternum and the vertebral column [2].

Anterior chest wall deformities can lead to a variety of symptoms, including adverse cosmetic and psychological effects and physiological impairment. In pectus excavatum, shortness of breath, palpitations and reduced exercise intolerance are frequently reported complaints, caused by cardiac impression due to the depressed sternum. Surgical correction may improve cardiovascular function and quality of life [3].

Elderly patients with an untreated pectus excavatum form a special category. Until recently, symptomatic pectus excavatum in seniors was considered non-existent. Nowadays, symptomatic pectus excavatum in seniors is more and more seen as a clinically relevant cardiovascular disease [4, 5]. In selected cases, surgical correction results in long term increase of cardiovascular function and quality of life [6].

In the past decades, many techniques have been developed for operative correction of pectus excavatum. The most well-known is the Ravitch procedure, which was introduced in 1949. In the original Ravitch procedure, perichondrium and all deformed costal cartilage are removed, and the xiphoid process is detached. A transverse cuneiform osteotomy is performed at the sternomanubrial junction and the corrected position is maintained by mattress sutures of braided silk. The periosteum is then sutured with black silk [7]. Over the years, small modifications to the original operation have been reported, such as preservation of the perichondrium [8, 9] and preserving of the attachment of the xiphoid. The technique currently used, is unchanged in essence and includes a transverse correction osteotomy of the sternum after resection of all affected costal cartilage. For reinforcement, Kirschner wires, cerclage wires, struts or non-absorbable meshes are used. However, all these techniques provide only relative stability. This can lead to complications such as pain and non- or malunion of the osteotomy due to instability.

Discomfort and disability due to sternal healing problems are common findings after sternotomy. Risks of post-sternotomy instability after cardiac surgery have been reported in up to 8% of patients [10]. It is likely that the incidence of symptomatic pseudarthrosis

is substantially higher after Ravitch than medial sternotomy for cardiac surgery due to extensive tissue dissection and added instability after cartilage resection. Furthermore, forces on the corrected sternum after pectus repair are expected to be greater than those after cardiac surgery due to the aberrant form of the chest wall. However, to the best of our knowledge, no data has been published on the incidence of non-union after Ravitch.

To achieve rigid fixation of the sternal osteotomy in Ravitch, plate fixation could be an alternative to conventional techniques. Locking compression plates are nowadays considered to be the gold standard for plate osteosynthesis in fracture surgery. This stable plate-screw connection leads to excellent stability of the implant and reduces the risk of primary or secondary loss of reduction and screw loosening. Theoretically, this leads to less post-operative pain and a decrease in the risk of non- or mal-union.

The aim of this retrospective cohort study is to evaluate the use and outcome of a new fixation method of the sternal osteotomy in the modified Ravitch procedure using locking compression plates. We compare this technique to the standard fixation method, during which cerclage wires with non-absorbable retrosternal mesh support are used. We present the following article in accordance with the STROBE guideline checklist [11].

PATIENTS AND METHODS

Patient work-up

Zuyderland Medical Center is a large non-university teaching hospital in the south of the Netherlands and serves as a tertiary referral center for pectus and thoracic wall surgery. All pectus patients are seen in a multidisciplinary setting, including participation of specialized general thoracic surgeons, pediatricians, and cardiologists. Standard work-up includes chest x-rays and imaging by a medical photographer (Figure 1). Besides normal photographs, the depth of the excavation is measured with a ruler (Figure 2) and a 3-D grid-projection (grid stereogram) is made (Figure 1b) [12]. On indication, CT- and MRI-scans are performed (Figure 3). Cardiac workup includes electrocardiography, echocardiography, and dynamic cardiac MRI. When palpitations are part of the symptomatology, holter recordings are done. If necessary, pulmonary function tests including trifold forced inspiration tests are conducted [13]. Indications for surgical intervention are: a. impression of the pectus on the right ventricle of the heart established by echocardiography or MRI, b. exercise intolerance, c. arrhythmias, d. psychosocial problems due to aesthetic complaints.

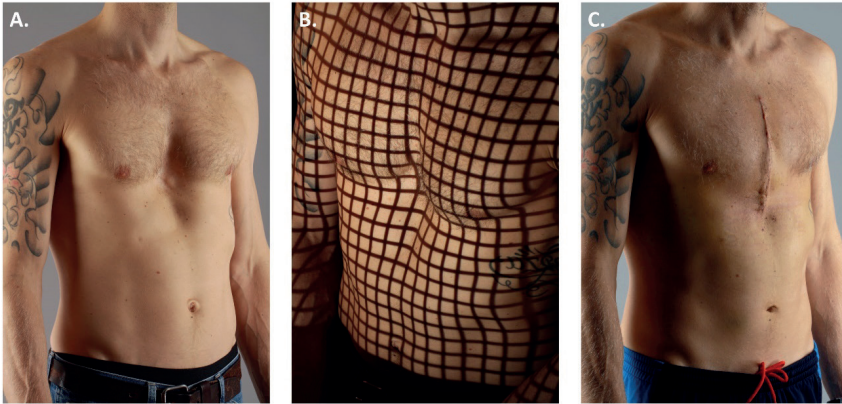


Figure 1: Preoperative imaging (a), 3D grid stereogram (b) and postoperative imaging (c) by medical photographer.



Figure 2: Preoperative depth measurement of excavation.

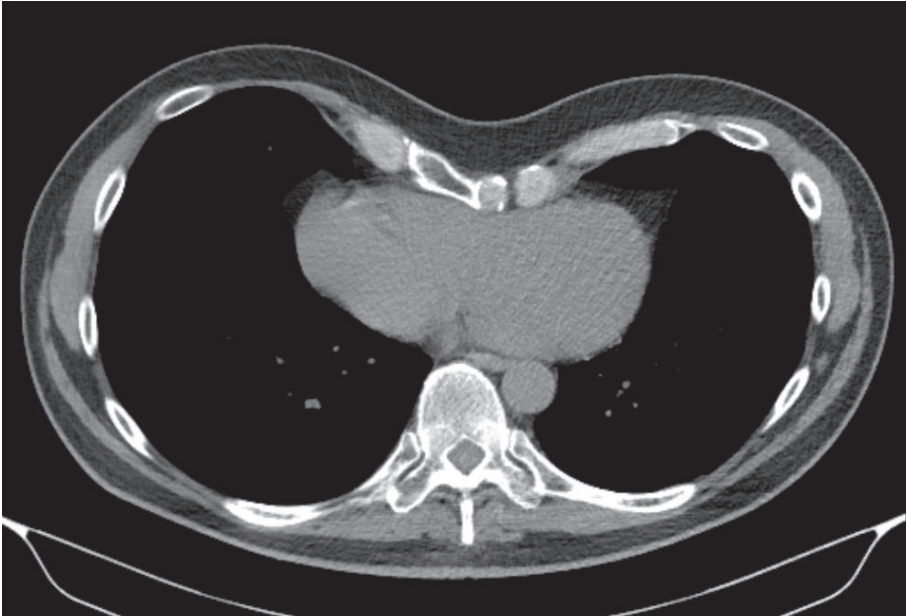


Figure 3: Preoperative CT-scan with cardiac impression due to depressed sternum.

The vast majority of our patients is young, suffers from a symptomatic pectus excavatum with exercise intolerance and is treated with a minimally invasive thoracoscopic Nuss bar procedure (MIRPE). Some younger patients are unsuitable for MIRPE and therefore are treated with a modified Ravitch procedure. This could be due to prior pleurodesis or thoracic surgery, or morphological deformities as extreme bending or torsion of the sternum (e.g., banana shape deformity) warranting open correction, or on specific patient request. In seniors with a symptomatic pectus excavatum, decision between MIRPE and open repair is based on expected chest wall rigidity and patient preference.

Methods

All patients undergoing a modified Ravitch procedure for pectus excavatum at our institution between March 2006 and September 2016 were included in this retrospective cohort study. Selection of the two surgical techniques was based on historical grounds. From March 2006 to March 2012, the sternum was fixated with cerclage wires and non-absorbable retrosternal mesh support as standard of care. From March 2012 to September 2016, locking compression plates were used for fixation. In the latter group, no additional retrosternal mesh was used. Data were extracted from the electronic patient files. The study

was approved by the local ethics and clinical research committee, waiving the need for individual patient consent (METC Zuyderland, ID: METCZ20200049).

The following baseline and perioperative parameters were recorded: age, gender, cardiac impression, Haller index, operation time, blood loss, hospital stay. The standard follow-up consisted of taking history and physical examination. There was no mandatory follow-up regime with regards to frequency and duration. Visits to the outpatient clinic were scheduled according to physicians' judgement and patients' preferences. When clinical signs of non-union were present, for example excessive pain or subjective instability, a CT-scan was performed for definitive diagnosis of non-union.

Thus, symptomatic non-union was defined as clinical symptoms of excessive pain or instability after at least 6 months follow-up, combined with confirmation of the non-union by CT scan. All post-operative complications were analyzed. Primary outcome measure was symptomatic non-union of the sternal osteotomy. Secondary outcome was the total number of complications.

Surgical technique

The patient was placed in supine position. The operation was performed under epidural and general anaesthesia with double lung ventilation. Antibiotic prophylaxis was used. Longitudinal midline or inframammary incisions were used for the approach. Full thickness subcutaneous flaps were created. The pectoralis muscles were dissected and lifted off the sternum and anterior thoracic wall. In all deformed ribs, the perichondrium was elevated, and deformed rib cartilage was removed with preservation of the perichondrium. The sternum was lifted, and a transverse wedge osteotomy was made on the upper margin of the sternal deformity. The sternum was then anatomically reduced. In the mesh support group, the sternal osteotomy was fixated with cerclage wires and non-absorbable retrosternal mesh support (Marlex®, Bard medical, IJsselstein, the Netherlands) (Figure 4). In the locking compression plate group, the osteotomy was rigidly fixated by two 3.5 millimeter 6 to 8-hole metaphyseal or diaphyseal titanium locking compression plates (LCP, DePuy Synthes, Johnson&Johnson, Amersfoort, the Netherlands) (Figure 5). Finally, the wound was closed in layers after low-vacuum drain placement.

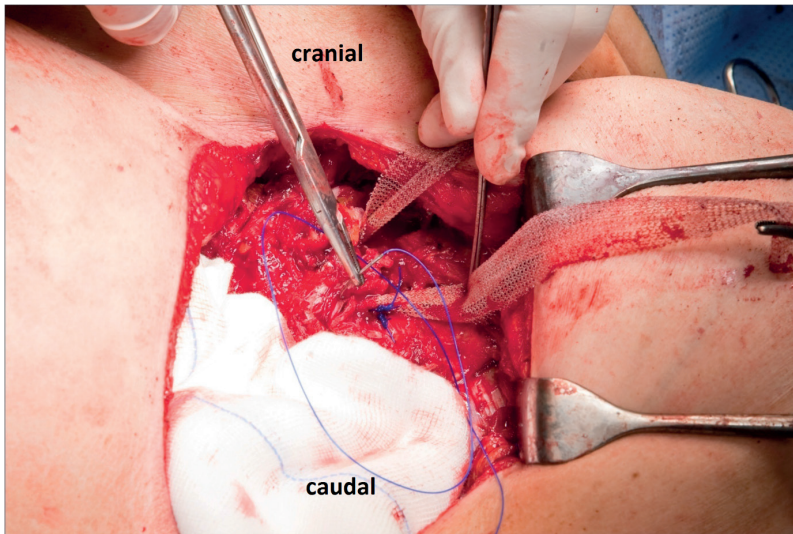


Figure 4: Intra-operative result: retrosternal mesh support.

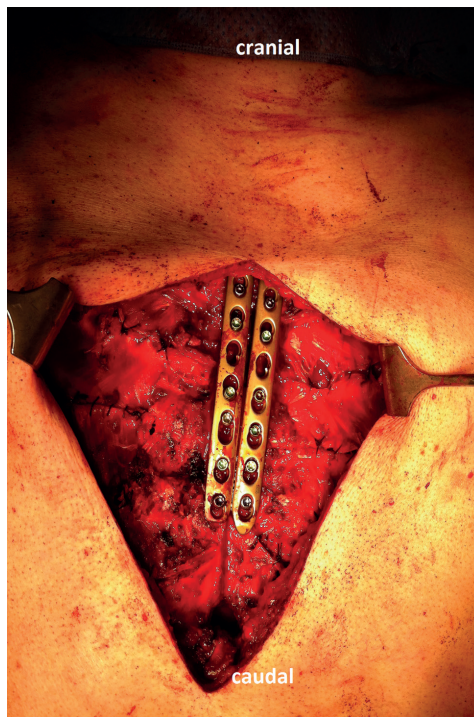


Figure 5: Intra-operative result: locking compression plate osteosynthesis.

Statistics

For statistical analysis SPSS version 23 was used (IBM Corp. Released 2015. IBM SPSS Statistics for Windows, Version 23.0. Armonk, NY: IBM Corp). Differences between groups were tested for significance using Mann-Whitney test or Fisher's exact test where appropriate. A p-value of <0.05 was considered statistically significant. Data are presented as means +/- SD. Missing data and data lost to follow-up were omitted from the analyses.

RESULTS

Baseline and perioperative characteristics are listed in Table 1. A total of 44 patients (28 men, 16 women) were included. One patient was lost to follow-up after two months. Median age was 56 years in the mesh group (range 19-72) and 48 years in the locking compression plate group (range 20-72), $p=0.028$. The depth of the pectus measured as Haller index was similar in both groups (mesh 3.8 ± 1.3 vs. locking compression plates 3.9 ± 1.1 , $p=0.81$).

In 18 patients (41%) the sternum was fixed with mesh support and in 26 patients (59%) with locking compression plates. The mean follow-up was 35 months in the mesh group (range 8-83) and 30 months in the locking compression plate group (range 2-73), $p=0.71$. There was no significant difference between groups with regard to the presence of cardiac impression, operation time, blood loss or hospital stay (Table 1).

Table 1: Baseline characteristics.

	mesh n=18			locking compression plate n=26			
	mean	range	SD	mean	range	SD	p
age (years)	56 (median 56)	19-72	11	46 (median 48)	20-72	15	0.028*
gender	male	12 (67%)		16 (62%)			0.76#
	female	6 (33%)		10 (38%)			
cardiac impression	18 (100%)			22 (85%)			0.13
Haller index	3.8	2.1-6.5	1.3	3.9	1.9-6.4	1.1	0.81*
operation time (min)	141	60-210	39.5	147	56-180	33	0.48*
blood loss (ml)	275	0-500	263	227	0-600	152	0.78*
hospital stay (days)	7.8	5-12	2.0	7.1	4-12	1.8	0.25*
follow-up (months)	35	8-83	24.8	30	2-73	19	0.71*

Differences between groups were tested for significance using *Mann-Whitney test or #Fisher's exact test where appropriate. A p-value of <0.05 was considered statistically significant.

Symptomatic non-union occurred in three patients in the mesh group (17%) compared to zero in the locking compression group, $p=0.062$. Patients presented with pain or tenderness of the sternum, and all had radiological signs of non-union on CT. During follow-up, no failures of the osteosynthesis were recorded in the locking compression plate group (Figure 6-7). On patient request, plates were uneventfully removed in 6/26 cases (23%). All these patients were bothered by implant prominence and therefore asked for hardware removal. No implants had to be removed due to infection or pain. The total number of complications other than hardware removal or non-union was 33% in the mesh group ($n=6$) and 15% in the locking compression plate group ($n=4$), $p=0.27$ (see Table 2). More specifically, in the mesh group: one patient presented with an incisional hernia, one patient with chronic pain, two patients with pneumonia, one patient with pericardial effusion, and one patient with atrial fibrillation. In the locking plate group: one patient presented with pectoral muscle dehiscence, one patient with seroma and two patients with wound infections.

Table 2: Postoperative complications.

	mesh n=18	locking compression plate n=26	p
symptomatic non-union	3 (17%)	0 (0%)	0.062
hardware removal	0	6 (23%)	0.067
complications other than above	6 (33%)	4 (15%)	0.27

Differences between groups were tested for significance using Fisher's exact test. A p-value of <0.05 was considered statistically significant.

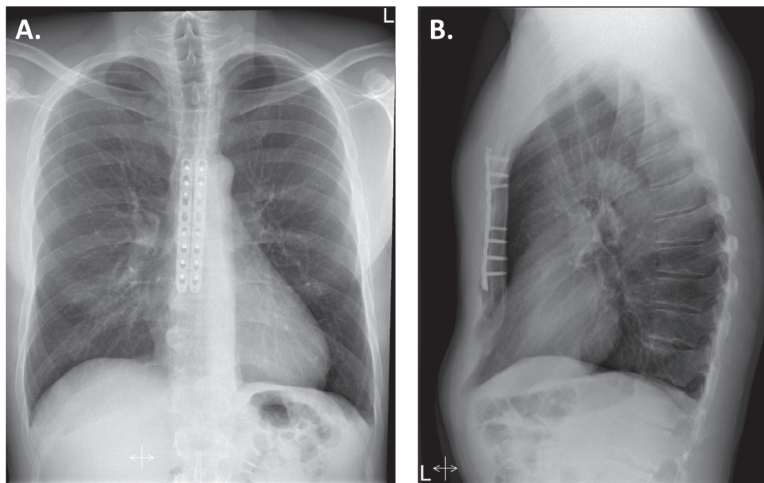


Figure 6: Postoperative chest X-ray after locking compression plate osteosynthesis.

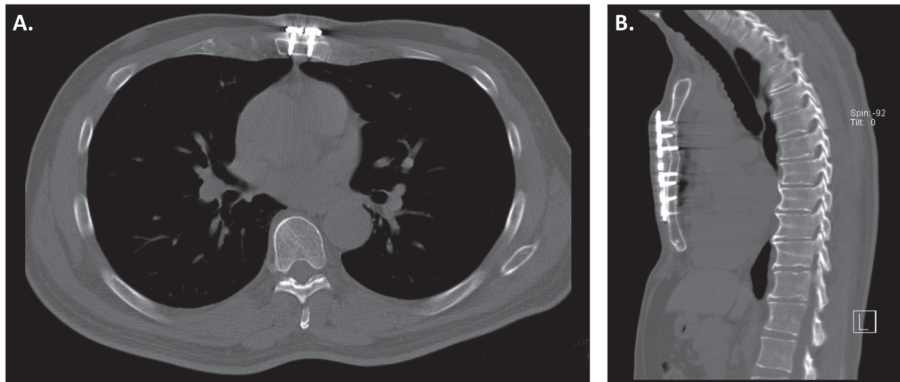


Figure 7: Postoperative CT-scan after locking compression plate osteosynthesis.

DISCUSSION

In this retrospective cohort study in patients with pectus excavatum undergoing repair by a modified Ravitch procedure, a lower incidence of symptomatic non-union was observed after fixation of the sternum with locking compression plates, with a trend towards statistical significance.

Challenges in the Ravitch technique are preservation of the corrected position of the sternum and achieving union of the osteotomy. Many modifications have been developed to create more stability. Temporary metal bars such as Rehbein pins or Nuss bars are frequently used for extra retrosternal support. Fonkalsrud describes good results with a less invasive technique including minimal cartilage resection and retrosternal support with an Adkins strut, which was routinely removed within 6 months [14]. Other surgeons use a non-absorbable Marlex mesh. Fixation of the osteotomy can be done with Kirschner wires, cerclage wires or trans-osseous sutures. Limitations of these techniques are the provided relative stability, increasing the risk of mal-union or non-union, as well as the need for implant removal in case of temporary fixation which leads to a high reoperation rate. A recent article describes a 100% failure rate of using a combination of steel wires and substernal STRATOS bars in 12 patients, all requiring reoperation [15].

To enable physiological bone healing, stability at the site of the osteotomy is important, whereas the Ravitch procedure by itself creates a situation of instability of the sternum. Therefore, an alternative to conventional techniques could be the use of locking compression plates, as these are known for their excellent stability in the field of fracture surgery. These plates are manufactured in a wide variety of shapes and diameters for use

in different body areas. The key concept is the plate design which provides a low-profile footprint and combination holes for both standard and locking screw placement. Angular stability is created by the rigid fixation of the tread on the head of a locking screw in the treaded part of the combination hole in the plate. Until now, literature on the use of plate fixation in sternal osteotomies for pectus repair is limited to a few case reports. Raff et al. reported the use of a sternal plate in a revision operation of a patient with sternal erosion of a Nuss bar [16]. Pasrija et al. used the combination of a sternal H-plate and 4 rib plates in correction of a recurrent pectus excavatum in a 39-year-old patient [17]. Puma et al. describe a surgical technique with two longitudinal thin titanium struts [18]. Ours is the first cohort study retrospectively comparing groups with various fixation regimes for the sternal osteotomy in modified Ravitch procedures.

Non-union can be assessed in various ways. Radiological evidence of non-union consists of widening of the fracture gap and hypertrophic or absent callus formation. Due to the retrospective nature of our series, radiological bone healing was not standardly assessed in all patients. However, in general non-union will only be treated if clinical sequelae occur, with pain and local tenderness being the most reported complaints. Therefore, we think it is more relevant to focus on clinically evident failure of bone healing.

Per definition, non-union occurs when consolidation fails after six months. One patient in our series was lost to follow-up after two months. All other patients were followed at least 8 months.

Although often multifactorial, the most important factors leading to non-union and pseudarthrosis are instability, disturbed vascularity, and infection. There were no significant differences in comorbidities related to mal-union, such as cardiovascular disease and diabetes. Moreover, the number of smokers was similar in both groups. Therefore, we assume that there are no relevant confounders for the observed difference in non-union.

The plates we used up to now are rather bulky. This thick material provides optimal strength to bear the high forces on chest wall and sternum. A disadvantage, however, is that the plates lie superficially underneath the pectoralis muscles and thin overlying subcutaneous tissues and are sometimes palpable, especially in lean patients. Six patients experienced burden from implant prominence and have therefore asked for hardware removal. No implants had to be removed due to infection or pain. In the future it may be possible to use firm but less thick plates to fixate the osteotomy of the sternum. Recently, specific sternal plates have become available, which could be an interesting alternative to conventional LCP.

To the best of our knowledge, this is the first comparative study using locking compression plates in the modified Ravitch procedure. In our experience, anatomical reduction of the sternal correction osteotomy on the plates is easy to achieve. The double locking plate technique provides excellent stability. Theoretically, this leads to less post-operative pain and a decrease in the risk of non- or mal-union. Our data suggest a lower incidence of symptomatic non-union with a trend towards statistical significance in the group treated with LCPs. However, further experience is necessary to support this new technique.

There are several limitations to this retrospective cohort study. Complications were only identified on clinical presentation. Therefore, potential asymptomatic non-unions could have been missed, resulting in an underestimation of the total number of non-unions. However, re-intervention is only mandatory in presence of symptoms of non-union, like pain, discomfort, or hardware failure. The non-union rate reported in our study may thus represent clinically relevant non-unions only. Another disadvantage of the retrospective aspect of our study is the variance in follow-up. According to our protocol, postoperative patients are seen in our outpatient department after 2 and 6 weeks, 3, 6, 12, 18 and 24 months. In practice, actual follow-up ranged from 2 to 83 months, potentially biasing our results. There was only one patient with a follow-up of less than 8 months. Thus, the vast majority of patients had a follow-up of more than 6 months, which is the minimum required for diagnosing non-union.

Furthermore, this is a relatively small single center retrospective experience accumulated over many years, during which time there could have been a number of opportunities for selection bias and other factors which might have modified results. On the other hand, previously published series describing open repair of pectus excavatum are relatively small. Therefore, we think that our study attributes to provide an insight on incidence and preventive strategies for non-union in modified Ravitch procedures.

In our goal to achieve absolute stability, we used relatively thick conventional locking compression plates. Adding mechanical stability led to a reduction in symptomatic non-union. However, the price paid is the occurrence of implant related symptoms, relative frequently leading to reoperation for removal of the osteosynthesis material. Therefore, we recently started using less thick specific sternal plates for angular stable fixation of the sternal correction osteotomy. Long-term follow-up is necessary to investigate symptomatic non-union rate and need for implant removal. If results of less thick and smaller plates prove to be favourable, percentage of re-operation for hardware removal and herewith the total complication rate could further be reduced.

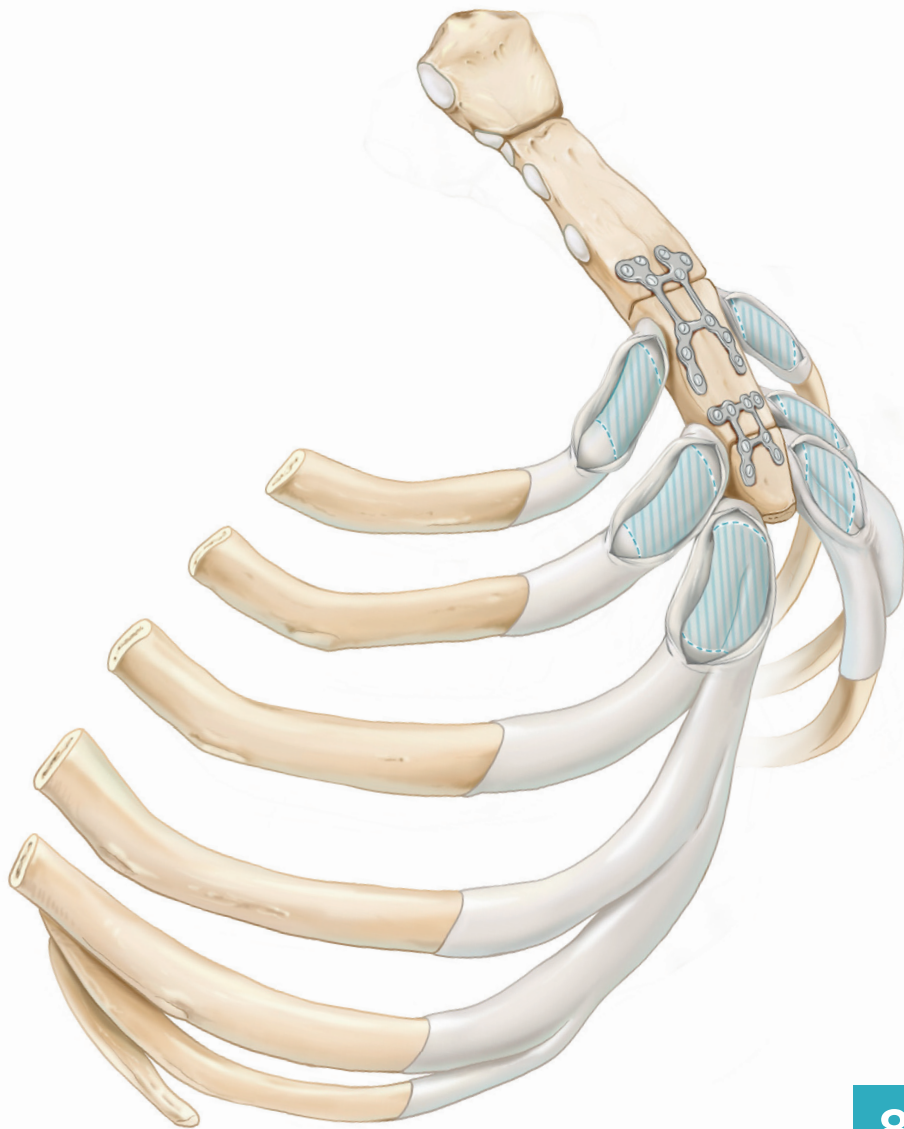
CONCLUSION

In conclusion, double locking plate fixation of the sternal osteotomy is a feasible alternative in the modified Ravitch procedure. In this retrospective cohort study, we noted promising initial clinical results with the use of locking compression plates instead of mesh and wires for sternal fixation. Our data suggest a lower incidence of symptomatic non-union with a trend towards statistical significance in the group treated with locking compression plates.

REFERENCES

1. Koumbourlis AC. Pectus excavatum: pathophysiology and clinical characteristics. *Paediatr Respir Rev.* 2009;10(1):3-6.
2. Haller JA, Jr., Kramer SS, Lietman SA. Use of CT scans in selection of patients for pectus excavatum surgery: a preliminary report. *J Pediatr Surg.* 1987;22(10):904-6.
3. Handels N, Kragten JA, de Loos E, et al. Long-term results of surgical correction of symptomatic pectus excavatum in seniors: improvement in cardiovascular function and quality of life. *Ital J Vasc Endovasc Surg.* 2017;24:131-6.
4. Kragten HA, Siebenga J, Höppener PF, et al. Symptomatic pectus excavatum in seniors (SPES): a cardiovascular problem?: A Prospective cardiological study of 42 senior patients with a symptomatic pectus excavatum. *Neth Heart J.* 2011 Feb;19(2):73-8.
5. Winkens RA, Guldmond FI, Höppener PF, et al. Symptomatic pectus excavatum in seniors: an exploratory study on clinical presentation and incidence in daily practice. *ISRN Family Med.* 2013 Feb 25;2013:373059.
6. Handels NA, Kragten HA, de Loos ER, et al. Long-term results of surgical correction of symptomatic pectus excavatum in seniors: Improvement in cardiovascular function and quality of life. *Ital J Vasc Endovasc Surg* 2017;24(4):131-6.
7. Ravitch MM. The Operative Treatment of Pectus Excavatum. *Ann Surg.* 1949;129(4):429-44.
8. Baronofsky ID. Technique for the correction of pectus excavatum. *Surgery.* 1957;42(5):884-90.
9. Welch KJ. Satisfactory surgical correction of pectus excavatum deformity in childhood; a limited opportunity. *J Thorac Surg.* 1958;36(5):697-713.
10. Robicsek F, Fokin A, Cook J, et al. Sternal instability after midline sternotomy. *Thorac Cardiovasc Surg.* 2000;48(1):1-8.
11. Von Elm E, Altman DG, Egger M, et al. The Strengthening in Reporting of Observational Studies in Epidemiology (STROBE) Statement: Guidelines for Reporting Observational Studies. *PLoS Med* 2007;4(10): e296.
12. van Dijk H, Hoppener PF, Siebenga J, et al. Medical photography: a reliable and objective method for documenting the results of reconstructive surgery of pectus excavatum. *J Vis Commun Med.* 2011;34(1):14-21.
13. Höppener PF, Kragten HA, Winkens R. Cardiological aspects of Symptomatic Pectus Excavatum in Adults. In: Saxena AK, editor. *Chest Wall Deformities.* Springer; 2017. p 261-278.
14. Fonkalsrud EW, Mendoza J. Open repair of pectus excavatum and carinatum deformities with minimal cartilage resection. *Am J Surg* 2006;191(6):779-84.
15. Sharma PK, Willems TP, Touw DJ, et al. Implant Failure: STRATOS System for Pectus Repair. *Ann Thorac Surg.* 2017;103(5):1536-43.
16. Raff GW, Wong MS. Sternal plating to correct an unusual complication of the Nuss procedure: erosion of a pectus bar through the sternum. *Ann Thorac Surg.* 2008;85(3):1100-1.
17. Pasrija C, Wehman B, Singh DP, et al. Recurrent Pectus Excavatum Repair via Ravitch Technique With Rib Locking Plates. *Eplasty.* 2014;14:ic46.
18. Puma F, Vannucci J, Santoprete S. External longitudinal titanium support for the repair of complex pectus excavatum in adults. *Eur J Cardiothorac Surg.* 2012;42(6):e166-8.

De Loos ER, Andel PCM, Daemen JHT, Maessen JG, Hulsewé KWE, Vissers YLJ.
J Thorac Dis. 2021;13(5):2952-2958.



8

Safety and feasibility of rigid fixation
by SternaLock Blu plates during
the modified Ravitch procedure:

a pilot study

ABSTRACT

Background

Patients with anterior chest wall deformities unsuitable for minimally invasive repair are commonly treated by the modified Ravitch procedure. Although rigid plate fixation of the sternal osteotomy has previously shown to facilitate adequate sternal union, its use is troubled by an implant removal rate of up to 23% due to local complaints or complications associated with bulky plates. In contrast, the use of thinner and therefore biomechanically weaker plates may result in a higher incidence of non- or mal-union. In this pilot study, we evaluate the feasibility, efficacy, and safety of rigid sternal fixation by thin pre-shaped anatomical locking plates during the modified Ravitch procedure.

Methods

Between June 2018 and December 2019, all consecutive patients who underwent anterior chest wall deformity repair by the modified Ravitch procedure in our tertiary referral centre were included. Data was collected retrospectively. All pectus types were included. The sternal osteotomy was fixated using thin SternaLock Blu plates. Patients were followed for at least one year.

Results

Nine patients were included. The group consisted of six male and three female patients, with a median age of 20 years (interquartile range: 16-35). Median duration of follow-up was 25 months (interquartile range: 16-28). No intraoperative complications occurred. No patients presented with symptomatic non- or mal-union. Plate removal was performed in one patient for atypical pain without relief. No other post-operative complications occurred.

Conclusions

Based on these pilot results, thin SternaLock Blu plates are deemed to be safe and effective in providing adequate rigid fixation of the sternal osteotomy during the modified Ravitch procedure. Compared to literature, the need for plate removal within 25 months after surgery was reduced.

INTRODUCTION

Surgical treatment of congenital anterior chest wall deformities originated in the early 20th century and is, following adaptations, nowadays known as the modified Ravitch procedure [1]. Pectus excavatum is the most common congenital anterior chest wall deformity and accounts for up to 90% of all deformities [2]. Other less common anomalies include pectus carinatum and arcuatum (i.e., Currarino-Silverman syndrome). During the modified Ravitch repair, the affected costal cartilage is resected while preserving the perichondrium, followed by correction of the sternal deformity through a cuneiform osteotomy. Although less invasive surgical alternatives, such as the Nuss (for pectus excavatum), Abramson (for pectus carinatum) and sandwich (for pectus arcuatum) are currently considered as surgical treatment of first choice, the modified Ravitch procedure may still be indicated based on patient's age, severity or type of the deformity, prior thoracic surgery, experience of the surgical team and patient's preference [3].

In the modified Ravitch procedure, numerous methods and techniques have been proposed for sternal fixation after osteotomy, including cerclage or Kirschner wires, non-absorbable meshes and struts [4]. Yet, these only provide relative stability and are therefore associated with a risk of non-union (i.e., pseudoarthrosis), mal-union and postoperative pain. Symptomatic non-union is observed in up to 17% of patients undergoing the modified Ravitch procedure with a non-absorbable mesh [4]. In addition, instability of the sternum reinforced by wire cerclages has been reported in 8% of cases after conventional cardiac surgery through a midsternal approach [5]. Consequently, we have advocated for rigid sternal fixation through Locking Compression Plates (LCP) and previously reported on its efficacy in 26 consecutive patients after a modified Ravitch procedure. In this study we found no cases of symptomatic non- or mal-union after a mean follow-up of 30 months [4]. Despite this apparent benefit, the disadvantage of the use of LCP is that they are bulky and may as a consequence be prominent underneath the thin sternal subcutaneous layer, necessitating hardware removal in 23% of pectus patients [4]. Kalberer et al. suggested an even higher LCP removal rate after osteosynthesis of sternal fractures [6]. Implant removal is moreover associated with surgical wound infections in up to 12% of cases [7] and may even result in non-union if performed too early. Thinner and anatomical contoured locking plates are possibly effective in reducing the need for plate removal. SternaLock Blu (SternaLock Blu, Zimmer Biomet, Warsaw, Indiana, USA) is primarily used for fixation after median sternotomy with excellent outcomes [8,9] and may therefore also be suitable for fixation of the sternum after correction of anterior chest wall deformities. However, until now, it is unknown whether

the use of thinner, biomechanically weaker plates prevents the occurrence of non- and mal-union when used for fixation of the correction osteotomy in the modified Ravitch procedure.

The subsequent objective of this pilot study is to evaluate our preliminary single-center results regarding the feasibility, efficacy, and safety of rigid sternal fixation by SternaLock Blu plates during the modified Ravitch procedure.

We present the following article in accordance with the STROBE reporting checklist [10] (available at <http://dx.doi.org/10.21037/jtd-21-284>).

METHODS

Study design

A single-center retrospective observational pilot study was conducted. Prior to start, the study was approved by the local ethics and clinical research committee (Medical Ethics Review Committee Zuyderland, ID: METCZ20200049, approval date: June 8th, 2020), waiving the need for individual patient consent. The study was conducted in accordance with the Declaration of Helsinki (as revised in 2013).

Participants

All consecutive patients who underwent a modified Ravitch procedure for pectus excavatum, carinatum or arcuatum between June 2018 and December 2019 at Zuyderland Medical Center (Heerlen, the Netherlands) were included. In June 2018 we started using SternaLock Blu plates. December 2019 was chosen as end of the enrolment period to provide a minimum follow-up of one year. No distinction was made between pectus types since the common goal of the Ravitch procedure is to achieve an anatomical position of the sternum. Patients who were not eligible for minimally invasive repair by the Nuss (for pectus excavatum), Abramson (for pectus carinatum) or sandwich (for pectus arcuatum) procedure were included (e.g., due to the extreme severity of deformity, patient's age, or preference). Patients with prior thoracic surgery were excluded.

Preoperative evaluation, surgical technique, and follow-up

Patients were provided consultation at the outpatient clinic of our tertiary referral center for chest wall disorders. Preoperative evaluation included a chest computed tomography (CT) scan to evaluate the severity of the deformity (Figure 1A). For patients suffering from pectus

excavatum, the Haller index was determined, and the presence of cardiac compression evaluated. Additional assessment of cardiorespiratory function was performed upon indication.

Surgery was performed under epidural and general anaesthesia with a single-lumen endotracheal tube. The patient was positioned supine and prophylactic cefazolin was administered. Following skin markings and identification of the deepest point (Figure 1B), a midline skin incision was made over the sternal deformity (Figure 1C). The pectoralis muscles were bilaterally dissected to expose the sternum and affected rib cartilage (Figure 1D). All deformed cartilage segments were resected while preserving the perichondrium (Figure 1E-F). A xiphoidectomy was performed in order to lift the sternum and avoid postoperative prominence (Figure 1G). Subsequently, a wedge osteotomy was made at the cranial margin of the sternal deformity using an osteotome. If necessary, to achieve a neutral sternal position, a second osteotomy was performed (Figure 1H). The wedge cuts were made in such fashion to facilitate optimal bone contact between the separated surfaces and allow proper sternal union. The SternaLock Blu system (SternaLock Blu, Zimmer Biomet, Warsaw, Indiana, USA) was used for fixation of the sternal osteotomy with plates and self-drilling locking screws (Figure 1I). No additional support methods were employed (e.g., rib plates or retrosternal support by struts). After fixation, the perichondrium was approximated (Figure 1J), and bilateral low-vacuum drains were placed. The pectoralis major muscles, subcutaneous tissue and skin were closed in layers (Figure 1K). A postoperative anteroposterior plain radiograph was acquired to rule out the presence of a pneumothorax (Figure 1L). In addition, a lateral plain radiograph was obtained during the first postoperative days in order to evaluate the postoperative result (Figure 1L). Patients were discharged following drain removal (less than 35cc per 24 hours), adequate pain control and mobilization. Standard follow-up consisted of an outpatient clinic visit after two weeks. Additional visits were scheduled on demand through shared decision making.

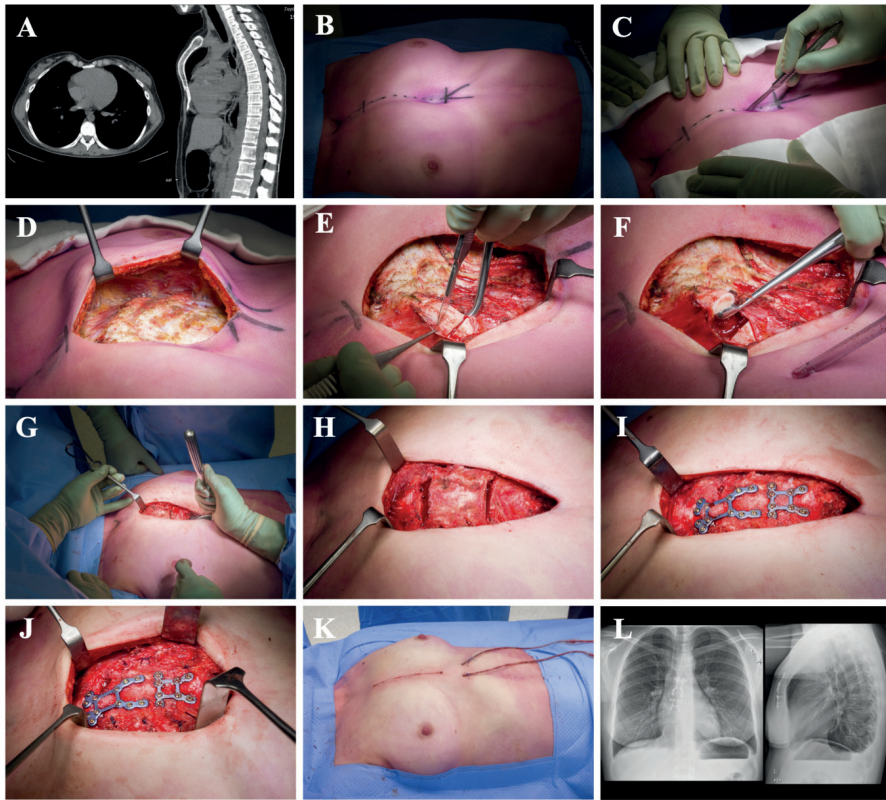


Figure 1: Surgical technique of the modified Ravitch procedure. (A) Preoperative evaluation by computed tomography. (B) Identification of the deepest point and incisional site. (C) Skin incision. (D) Bilateral pectoralis muscle dissection to expose the sternum and affected rib cartilage. (E-F) Resection of the deformed cartilage with preservation of the perichondrium. (G) Xiphoidectomy and sternal elevation. (H) Sternal osteotomies. (I) Fixation of the sternal osteotomies by the SternaLock Blu system. (J) Approximation of the perichondrium. (K) Placement of low-vacuum drains and closure in layers. (L) Postoperative result.

Variables and data acquisition

Patient charts were retrospectively reviewed for (1) baseline patient characteristics (sex, age, type of deformity and for pectus excavatum the Haller index and presence or absence of cardiac compression), (2) operation characteristics (duration, blood loss and intraoperative complications) and (3) postoperative characteristics (length of hospital stay, complications [graded by the Clavien-Dindo classification] [11] and length of follow-up). Symptomatic non-union was defined as the presence of symptoms (i.e., pain or subjective instability) in combination with a CT confirmed non-union at least 6 months after surgery. Implant removal due to complaints (e.g., pain or prominence) was only acknowledged as such, if symptoms resolved after removal.

Statistical analyses

Statistical analyses were performed using SPSS Statistics (IBM Corp. IBM SPSS Statistics for MacOS, Version 27.0, Armonk, New York, USA). Continuous variables were depicted as median, interquartile range (IQR) and range. Categorical variables were denoted as frequencies and percentages. Missing data was reported as such.

RESULTS

Between June 2018 and December 2019, nine consecutive patients underwent a modified Ravitch procedure with application of the SternaLock Blu system. Six out of nine patients were male (67%) with a median age of 20 years (IQR: 16-35; range: 13-59). The group consisted of four patients (45%) with pectus excavatum, three (33%) with pectus carinatum and two (22%) with pectus arcuatum. The indication to perform a modified Ravitch procedure instead of a minimally invasive approach was age in 2 out of 4 pectus excavatum patients and extreme severity in the remaining 2. In addition, reasoning for an open approach encompassed a combination of severity and potential inability to redress the deformity by the Abramson method in all pectus carinatum patients while the modified Ravitch procedure was favoured due to age in all pectus arcuatum patients. The Haller index among patients with pectus excavatum ranged from 3.0-4.9, compared to 2.2-2.9 (n=1 missing) after surgery. The median length of surgery was 104 minutes (IQR: 99-142; range: 89-171) with a median blood loss of 50 mL (IQR: 35-200; range: 20-300). No intra-operative complications occurred. Postoperative lateral plain radiographs demonstrated an anatomical position of the sternum in all patients (n=1 missing). Patients were discharged after a median of five days (IQR: 5-7; range: 4-8). Baseline patient characteristics are summarized in Table 1.

Table 1: Baseline patient characteristics.

Characteristics	SternaLock Blu (n = 9)		
	Median or n (%)	IQR	Range
Age (years)	20	16-35	13-59
Male	6 (67)		
Pectus type			
Pectus excavatum	4 (44)		
Pectus carinatum	3 (3)		
Pectus arcuatum	2 (22)		
Haller index			3.0-4.9

n, number; *IQR*, interquartile range

One-year follow-up was available for all patients. Median duration of follow-up was 25 months (IQR: 16-28; range: 15-29). No patients presented with symptomatic non-union or mal-union. In addition, no recurrent cases were observed. In one 46-year-old male patient, plates were removed due to atypical pain complaints (CDC-III_b). However, symptoms did not improve upon removal, making an association with the osteosynthesis materials unlikely. Additional cardiac and pulmonary evaluation did not reveal any abnormalities and symptoms were classified as idiopathic. No secondary surgical or other complications occurred. Peri- and postoperative outcomes are summarized in Table 2.

Table 2: Peri- and postoperative outcomes.

Characteristics	Sternalock Blu (n = 9)		
	Median or n (%)	IQR	Range
Length of surgery (minutes)	104	99-142	89-171
Blood loss during surgery (mL)	50	35-200	20-300
Hospital stay (days)	5	5-7	4-8
NRS			
Postoperative	2	0-5	0-10
Discharge	2	0-3	0-3
Follow-up (months)	25	16-28	15-29
Post-operative complications	0 (0)		
Seroma	0		
Wound dehiscence	0		
Wound infection	0		
Pectus recurrence	0		
Re-admission	0		
Non-union	0		
Mal-union	0		
Plate removal	1 (11)		
Pain	1*		
Plate prominence	0		

IQR, Interquartile range; SD, Standard deviation; mL, milliliters; NRS, Numeric Rating Scale

**Plate removal had no effect on pain.*

DISCUSSION

The aim of this pilot study was to evaluate the feasibility, efficacy, and safety of rigid sternal fixation by the SternaLock Blu system during the modified Ravitch procedure. We started using these thinner, pre-shaped anatomical locking plates in June 2018 because of the relatively high plate removal rate of 23% using locking compression plates in an earlier cohort [4]. This high removal rate was attributed to the bulkiness and subsequent prominence of

locking compression plates, causing complaints. This is in accordance with a series reporting a plate removal rate of 27% in fifteen patients who received locking compression plate fixation after sternotomy with a mean follow-up of 57 months [6].

Using SternaLock Blu plates in the current series, the hardware was removed in only one patient suffering from thoracic pain. However, because his symptoms persisted afterwards and no physical substrate was found by extensive cardiopulmonary evaluation, the pain was concluded not to be plate related. This emphasizes the need for careful patient selection before advancing to plate removal. In addition, if plate removal is indicated based on plate prominence, removal is advised to be postponed until adequate union is likely (at least 6 months after initial surgery) and moreover confirmed by cross-sectional imaging.

Based on the comparison with available literature, the thinner SternaLock plates seem to be associated with reduced need for removal due to plate prominence and associated burden compared to the bulkier locking compression plates. In turn, this may prevent secondary surgical complications such as non-union and surgical site infections following removal [7]. However, it has to be noted that the follow-up of both LCP groups was considerably longer (respectively 30 and 57 months) than the SternaLock Blu group from the current series (median: 25 months).

Since publications on the use of sternal plates in Ravitch procedures are limited to the previously mentioned reports by our center, we also reviewed literature on the use of SternaLock Blu plates after cardiac sternotomy. In a study by Raman and colleagues [8], a hardware removal rate of 11% (n=8/70) was found. Of these plate removals, 6 plates were removed within seven to 82 days after surgery due to screw back out, pull through, wound infection and a non-infected wound sinus. The median follow-up of our current study was long enough (i.e., median follow up of 25 months) to observe these complications, however, none occurred. Nevertheless, all patients studied by Raman et al. were preoperatively determined to be at high risk for sternal wound complications. In contrast, the pectus population is generally younger with fewer comorbidities than patients undergoing cardiac surgery [8].

In this study, we did not routinely acquire postoperative CT scans to assess the presence of non- or mal-union cases. We solely assessed symptomatic (e.g., pain, discomfort, or hardware failure) cases by means of CT since asymptomatic cases do generally not require re-intervention. Though, we acknowledge that this may lead to a potential underestimation of the true occurrence of non- and mal-union. In the present series, no cases of symptomatic

non-union or mal-union were detected during the median follow-up of 25 months. This is comparable to our previous experience in 26 pectus excavatum patients treated with locking compression plate fixation as part of a modified Ravitch procedure, where no cases of symptomatic non- or mal-union were detected after a mean follow-up of 30 months [4]. We therefore suggest the thinner SternaLock Blu plates to be an effective alternative for sternal fixation, providing sufficient rigidity as demonstrated by the absence of symptomatic non-union and mal-union cases. However, it should be noted that the risks on plate failure differ among pectus types. Especially pectus excavatum is theoretically at higher risk for failure.

Based on a large series (n=426) by Masaoka et al., complications during the modified Ravitch procedure occur in approximately 6% of cases [12]. Potential complications are primarily wound- (i.e., seroma and wound dehiscence) and respiratory-related (i.e., pneumothorax, pneumonia, pleural effusion, and atelectasis). Masaoka et al. created a bridge consisting of resected costal cartilage to support the sternum, thus performing a metal-free Ravitch procedure, while Fonkalsrud in a series of 912 patients with metal strut support revealed a complication rate of 8% [13]. In comparison, in a smaller series using cerclage wires with non-absorbable retrosternal mesh support (n=18) or locking compression plates (n=26), a complication rate (other than hardware removal and non-union) of respectively 33% and 15% is described [4]. In the current series, using SternaLock Blu plates for rigid fixation of the sternal osteotomy among nine patients, no complications were observed.

LIMITATIONS

To the best of our knowledge, the current study is the first to investigate the use of SternaLock Blu plates for rigid sternal fixation during the modified Ravitch procedure. Nonetheless, this study is subject to limitations. Retrospective cohort studies are inherently susceptible to bias due to missing data. Yet, only one postoperative lateral radiograph was missing, as a result of which the postoperative Haller index could not be determined in one patient. In addition, it should be noted that the study's findings concern pilot data obtained during adaption of the use of SternaLock Blu plates. Moreover, conducting a pilot study is inherently associated with a small sample size, limiting evidential value. In addition, potential underestimation of asymptomatic non- and mal-union cases is possible, given that cross-sectional imaging was only performed in the presence of symptoms.

Currently, more minimally invasive procedures, such as the Nuss procedure, are favoured over the modified Ravitch procedure due to smaller incisions, lesser blood loss and

shorter operative time [14]. Likewise, a minimally invasive treatment (i.e., the Abramson procedure) or conservative treatment (i.e., bracing, or dynamic compression therapy) is favoured for pectus carinatum [15]. Since the common goal has been to minimize surgical trauma, the modified Ravitch procedure has gradually declined in relative incidence, as also demonstrated by Zuidema et al. [16]. This may have led to selection bias given that, in particular, more severe cases are selected for the modified Ravitch procedure. This explains the small and heterogenous study population of this study which may limit extrapolation of results to other patient cohorts. Future comparative research should focus to expand and strengthen the current evidence with adequate power.

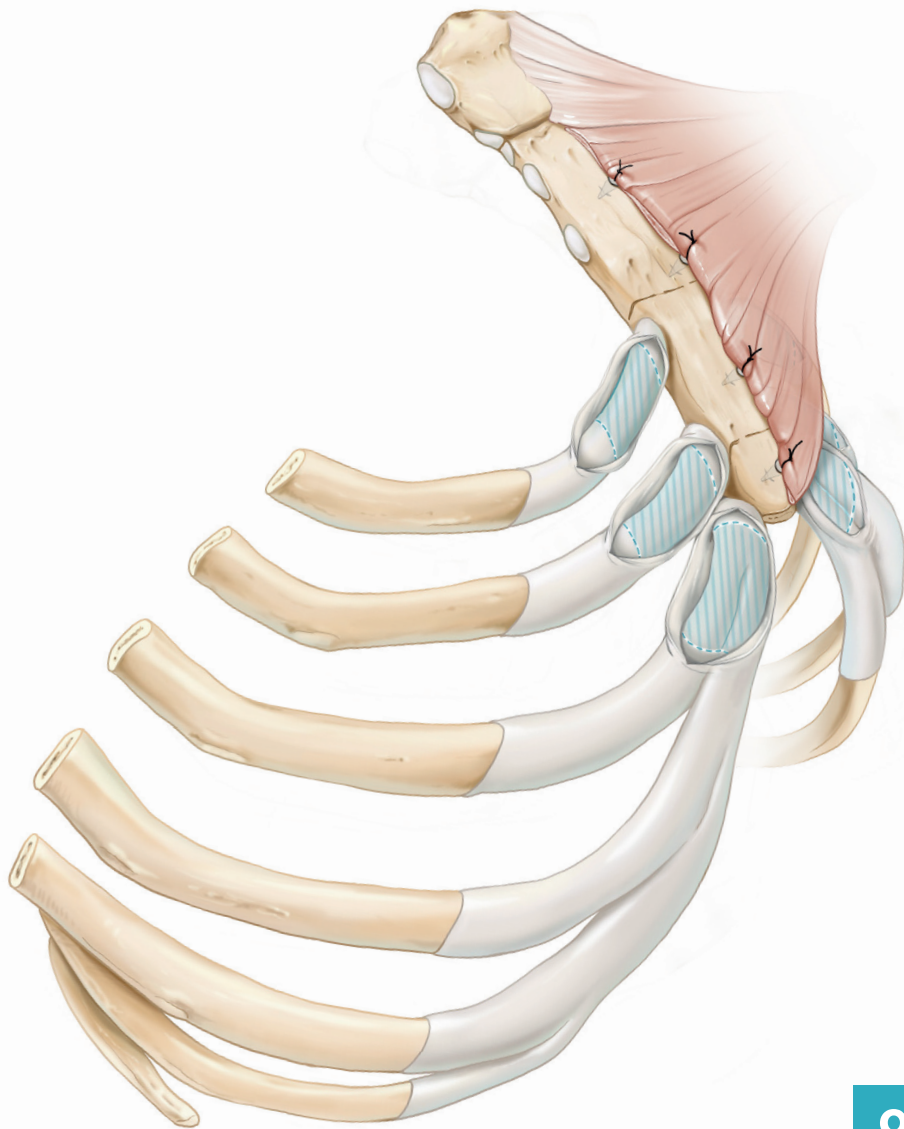
CONCLUSIONS

Based on our first experience, SternaLock Blu plates are suggested to be a safe and feasible method for rigid sternal fixation during the modified Ravitch procedure. Moreover, in the absence of non-union and mal-union cases, they are suggested to provide adequate sternal stability. Furthermore, SternaLock Blu plates are potentially associated with reduced need for hardware removal compared to bulkier locking compression plates. Future comparative studies are needed to strengthen the evidence.

REFERENCES

1. Ravitch MM. The operative treatment of pectus excavatum. *Ann Surg.* 1949;129(4):429–44.
2. Fokin AA, Steuerwald NM, Ahrens WA, et al. Anatomical, Histologic, and Genetic Characteristics of Congenital Chest Wall Deformities. *Semin Thorac Cardiovasc Surg.* 2009;21(1):44–57.
3. Ersen E, Demirkaya A, Kiliç B, et al. Minimally invasive repair of pectus excavatum (MIRPE) in adults: Is it a proper choice? *Wideochir Inne Tech Maloinwazyjne.* 2016;11(2):98–104.
4. De Loos ER, Hulsewé KWE, van Loo ERJ, et al. Does the use of locking plates or mesh and wires influence the risk of symptomatic non-union of the sternal osteotomy after modified Ravitch? *J Thorac Dis.* 2020;12(7):3631–9.
5. Robicsek F, Fokin A, Cook J, et al. Sternal instability after midline sternotomy. *Thorac Cardiovasc Surg.* 2000;48(1):1–8.
6. Kalberer N, Frima H, Michelitsch C, et al. Osteosynthesis of sternal fractures with double locking compression plate fixation: a retrospective cohort study. *Eur J Orthop Surg Traumatol.* 2020;30(1):75–81.
7. Backes M, Schep NW, Luitse JS, et al. High Rates of Postoperative Wound Infection Following Elective Implant Removal. *Open Orthop J.* 2015;9(1):418–21.
8. Raman J, Lehmann S, Zehr K, et al. Sternal closure with rigid plate fixation versus wire closure: a randomized controlled multicenter trial. *Ann Thorac Surg.* 2012;94(6):1854–1861.
9. Allen KB, Thourani VH, Naka Y, et al. Randomized, multicenter trial comparing sternotomy closure with rigid plate fixation to wire cerclage. *J Thorac Cardiovasc Surg* 2017;153:888–96.e1.
10. von Elm E, Altman DG, Egger M, et al. The Strengthening the Reporting of Observational Studies in Epidemiology (STROBE) statement: guidelines for reporting observational studies. *J Clin Epidemiol.* 2008;61(4):344–9.
11. Dindo D, Demartines N, Clavien PA. Classification of surgical complications: A new proposal with evaluation in a cohort of 6336 patients and results of a survey. *Ann Surg.* 2004;240(2):205–13.
12. Masaoka A, Kondo S, Sasaki S, et al. Thirty years' experience of open-repair surgery for pectus excavatum: Development of a metal-free procedure. *Eur J Cardiothorac Surg.* 2012;41(2):329–34.
13. Fonkalsrud EW. 912 Open pectus excavatum repairs: Changing trends, lessons learned: One surgeon's experience. *World J Surg.* 2009;33(2):180–90.
14. Mao YZ, Tang ST, Li S. Comparison of the Nuss versus Ravitch procedure for pectus excavatum repair: an updated meta-analysis. *J Pediatr Surg.* 2017;52(10):1545–52.
15. Emil S. Current Options for the Treatment of Pectus Carinatum: When to Brace and When to Operate? *Eur J Pediatr Surg.* 2018;28(4):347–54.
16. Zuidema WP, van der Steeg AFW, Oosterhuis JWA, et al. Trends in the Treatment of Pectus Excavatum in the Netherlands. *Eur J Pediatr Surg.* 2020;Online ahead of print.

De Loos ER, Daemen JHT, Janssen N, Hulsewé KWE, Vissers YLJ.
Innovations (Phila). 2021;16(5):485-487.



9

Suture anchor repair of pectoralis major muscle dehiscence after modified Ravitch

ABSTRACT

During repair of pectus excavatum by the modified Ravitch procedure, the major pectoral muscles are detached from their sternal insertion to obtain adequate surgical exposure. Following repair, the muscles are approximated in midline and reinserted through scarring. Dehiscence of the major pectoral muscles after the modified Ravitch procedure is a rare phenomenon, not previously reported in literature. We report on two cases and describe an effective treatment method using sternal suture anchors with good long-term results.

INTRODUCTION

Although the Nuss procedure is perceived as the procedure of choice in adolescents with pectus excavatum, the open modified Ravitch procedure may still be indicated. Indications include complex deformities, increased rigidity of the thoracic cage, experience of the surgical team and revision surgery. During open repair, the affected costal cartilage is resected while the sternum is remodeled through a cuneiform osteotomy and subsequent fixation [1]. In order to obtain adequate surgical exposure sternal detachment of the major pectoral muscles is required. Ensuing repair, the muscles are approximated whereby adequate sternal insertion through scarring is usually sufficient to maintain function. We report the first 2 cases of pectoral major muscle dehiscence following modified Ravitch procedures treated by suture anchor repair.

DESCRIPTION

Case A

A 20-year-old male underwent a modified Ravitch procedure because of a residual and symptomatic distal pectus excavatum component (Haller index: 3.4) after Nuss repair four years earlier. During this Ravitch repair the major pectoral muscles were released at their sternal attachment, affected costal cartilage was removed and the sternal osteotomy was fixated using locking plates and screws. Following repair, the pectoral muscles were approximated in midline by running absorbable braided sutures (Vicryl 1.0, Ethicon Inc., Johnson&Johnson, Summerville, New Jersey, USA). Three years after Ravitch repair, the patient presented with intermittent complaints of anterior thoracic pain and traction associated with exercise. CT showed no signs of non-union or mal-union of the sternum. Physical examination revealed the pectoral muscles to move as a single active functional unit (Supplemental video). The patient was reoperated. Intraoperative findings confirmed adequate midline healing of the pectoral muscles, but without sternal reinsertion. Repair with the use of suture anchors was performed according to the surgical technique described in detail below. No pectoralis loading was advised for 6 weeks. Postoperative follow up showed adequate pectoral muscle function with complete elimination of symptoms up to 40 months after surgery (Video 1).

Case B

A 72-year-old male with previous hybrid correction of pectus excavatum elsewhere (cranial cuneiform sternal osteotomy and STRATOS bar implant [MedXpert GmbH, Eschbach,

Germany] at the age of 70 years) underwent a modified Ravitch procedure due to implant failure, incomplete prior repair (residual Haller index: 3.0) and residual complaints (thoracic pain and dyspnea). Similar to Case A, the major pectoral muscles were dissected in the midline and detached from the sternum and ribs. Following Ravitch repair using the technique described in Case A, pectoral muscles were approximated by absorbable braided sutures (Vicryl 1.0). The postoperative course was complicated by a surgical site infection. Fifteen months following surgery, asymptomatic dehiscence of the major pectoral muscles was observed. Three years after the last operation, the patient underwent reoperation for symptomatic plate prominence and a subxiphoidal incisional hernia. Intraoperative view revealed total dehiscence with pectoral muscle retraction (Figure 1a). Repair with the use of suture anchors was performed according to the surgical technique described in detail below. Similar to Case A, no pectoralis loading was advised for 6 weeks. Follow up showed adequate pectoral muscle reinsertion and function up to 41 months after surgery.

SURGICAL TECHNIQUE

Surgery was performed under general anaesthesia with the use of a single lumen endotracheal tube. Prophylactic cephazolin was administered preoperatively. Patients were placed in supine position with their arms at the side. After prepping and draping of the surgical field, the midline sternal incision was retaken. The sternal body was subsequently dissected and the priorly implanted plates were removed. Next, the laterally retracted pectoralis muscles were identified (Figure 1a). After adhesiolysis of the anterior chest wall, the pectoralis muscles were mobilized in the subcutaneous plane and brought to its original midline position. Bilateral bone anchor positions were determined on the anterior surface of the sternum, just lateral to prior plate location. The anterior cortex was predrilled perpendicularly with the corresponding stop drill and four bilateral suture anchors (DePuy Mitek GII Titanium Anchor, Johnson&Johnson, Summerville, New Jersey, USA) were inserted (Figure 1b-c). Subsequently, with means of the anchor sutures, the pectoralis muscles were reinserted on the sternal body using a mattress suturing technique. Thereafter, the pectoralis muscles were approximated in midline by a running absorbable braided suture (Vicryl 1.0; Figure 1d). The incision was closed in layers and sterile dressings were applied (Figure 1e).

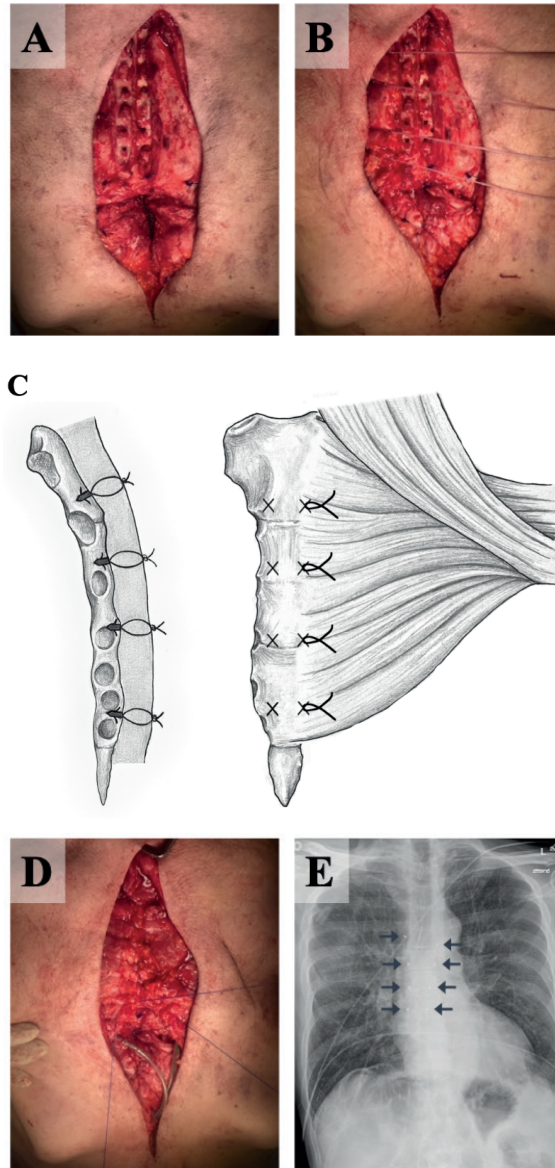


Figure 1: Intraoperative view revealing (a) total dehiscence of the major pectoral muscles with retraction, (b) muscle mobilization and reinsertion by 4 bilateral suture anchors, (c) schematic drawing demonstrating suture anchor position, (d) midline approximation by monofilament sutures, and (e) postoperative plain radiograph.

DISCUSSION

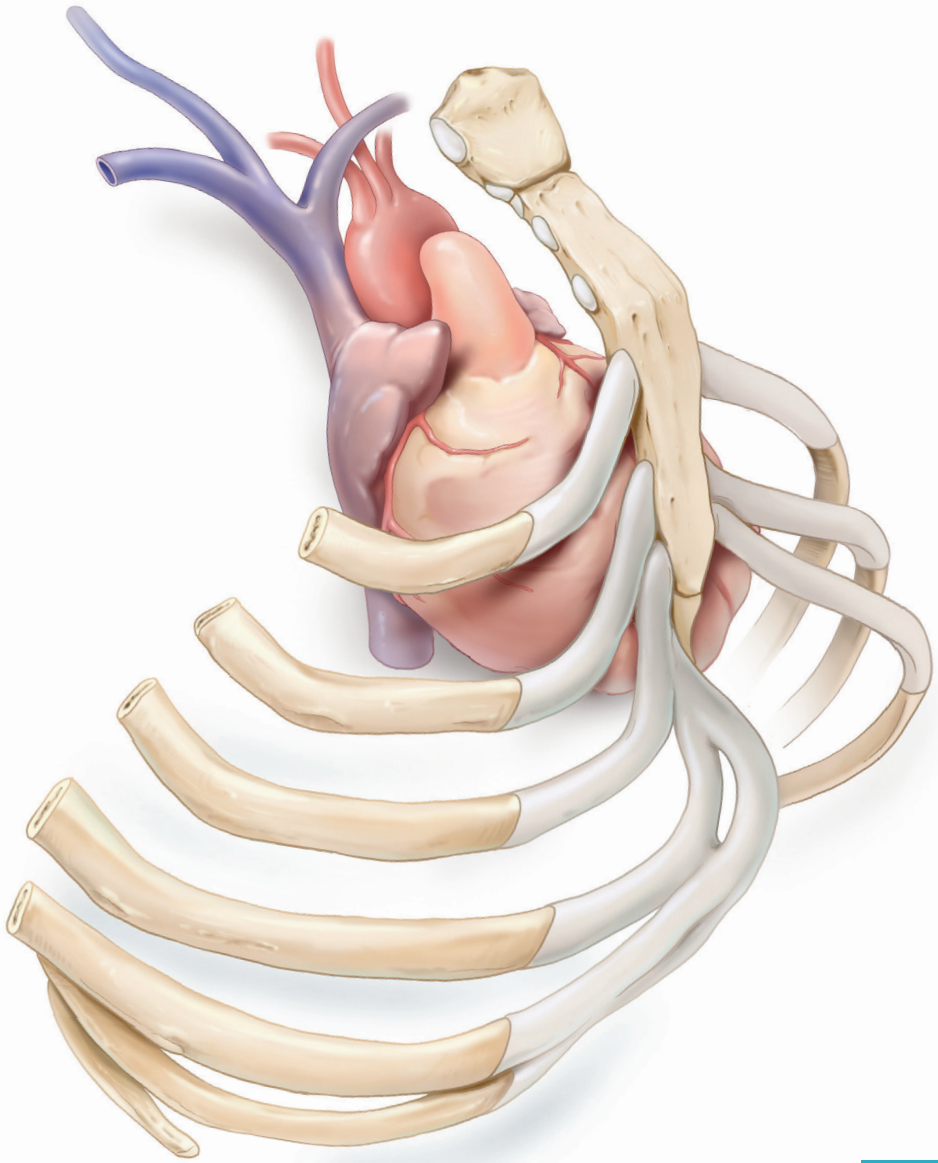
Potential complications after the modified Ravitch procedure include pulmonary (e.g., pleural effusion and pneumothorax) and cardiac complications (e.g., pericardial effusion or pericarditis), wound problems (e.g., surgical site infections, seroma or scar hypertrophy) and recurrence [2]. This is the first report to describe the rare phenomenon of major pectoral muscle dehiscence after the modified Ravitch procedure and, moreover, the first to describe repair by sternal suture anchors. Suture anchor repair is a commonly used surgical technique for osseous reinsertion of teared tendons [3] and is shown to be a feasible and effective method for pectoral muscle re-insertion in the cases presented.

In both cases, the exact etiology of pectoral muscle dehiscence/detachment was unclear. However, the patient in Case A was a smoker (8 cigarettes/day). Smoking is known to affect tissue healing and has been described to cause impairment of collagen synthesis and deposition [4]. This may have resulted in biomechanical weakness of the sternal attachment with subsequent failure. Case B had a cardiovascular history (hypertension and rhythm disorders) and was relatively old. High age is known to be associated with delayed wound healing and decreased strength. Other factors that may have attributed include suture failure, deep surgical site infection, abrading over the plate material, excessive muscle loading after surgery and diabetes.

Based on the presented cases we advocate for repair using sternal suture anchors in the presence of symptomatic major pectoral muscle dehiscence after the modified Ravitch procedure.

REFERENCES

1. Ravitch MM. The Operative Treatment of Pectus Excavatum. *Ann Surg.* 1949;129:429-44.
2. Jaroszewski DE, Fonkalsrud EW. Repair of pectus chest deformities in 320 adult patients: 21 year experience. *Ann Thorac Surg.* 2007;84:429-33.
3. Visscher LE, Jeffery C, Gilmour T, Anderson L, Couzens G. The history of suture anchors in orthopaedic surgery. *Clin Biochem.* 2019;61:70-78.
4. Sørensen LT. Wound healing and infection in surgery: the pathophysiological impact of smoking, smoking cessation, and nicotine replacement therapy: a systematic review. *Ann Surg.* 2012;255:1069-79.



10

General discussion and
future perspectives

GENERAL DISCUSSION AND FUTURE PERSPECTIVES

This thesis describes and evaluates improvements in various aspects of surgical care in patients with pectus excavatum. Despite increasing attention in literature and improved awareness among care givers, significant knowledge gaps and controversies regarding this condition are still present.

Pectus excavatum, also known as funnel chest, is a structural deformity of the anterior chest wall with typical indentation of sternum and adjacent ribs. Associated complaints can be of cosmetic, psychosocial, or physical origin. Cardiac compression due to the inwardly displaced sternum can lead to disabling conditional decline, exercise intolerance, fatigue, and palpitations.

Pectus excavatum is the most common deformity of the anterior chest wall. There seems to be a rather large geographical variance. In Western countries, the reported prevalence of pectus excavatum exceeds that of pectus carinatum. In contrary, in South America, pectus carinatum seems to occur more frequently. Reports on the incidence of pectus excavatum are scarce and reported prevalence rates vary considerably. In literature, many articles refer to an occurrence of pectus excavatum in approximately 1 in 300–400 live births. This is based on a study by Chung et al. (1975) who evaluated 46,689 live births and fetal deaths of whom complete information was available on study variables such as chest wall deformities [1]. A more realistic statement would be that until now, robust data on prevalence of pectus excavatum lacks in current literature. Other authors estimate the prevalence of pectus excavatum in a selected subpopulation. Kwiecinski et al. reviewed reports of computed tomography (CT) scans in 217 ancient Egyptian mummies, revealing 3 presumed cases of pectus excavatum [2]. Biavati et al. described a prevalence of 1 in 20 (defined as: Haller index >3.25) in a population-based cohort study (the Dallas Heart Study), evaluating chest CT scans of 2687 adults [3].

Another challenge is the strive for increased awareness about pectus excavatum among health care professionals. Due to limited knowledge of the disorder amid physicians, the number of patients getting an appropriate treatment for their pectus is hampered [4]. This is experienced in our daily practice as well. Zuyderland medical center (Heerlen, the Netherlands) is an acknowledged tertiary referral center for chest wall abnormalities (<https://www.stz.nl/topklinisch-zorgregister>). The vast majority of patients is referred from outside our hospital adherence area. A considerable number of patients experience a lack of accessible information regarding their condition, which often leads to increased

uncertainty. Moreover, numerous patients tell anecdotal stories in which they were told that pectus excavatum is purely a cosmetic problem, as also stressed by Baudouin et al., and Eisinger et al. [5,6]. The last distributed a questionnaire among 331 patients with untreated pectus excavatum from 47 countries, recruited from the Facebook Pectus Awareness and Support Group, revealing significant discrepancy between expectations and delivery of care for people with pectus excavatum [5]. Patients often feel that health care providers can do more for them and need more training on this particular subject [5]. It would be in the interest of patients to give attention to pectus excavatum during bachelor and master programs at medical universities. For example, to date, chest wall deformities are not included in the curricula of my alma mater, the Faculty of Health, Medicine and Life Sciences of Maastricht University, the Netherlands. Personally, years went by before observing a real patient with pectus excavatum in clinical practice, after seeing the dated illustrations of a person with a funnel chest (alongside the more famous “pink puffer” and “blue bloater”) in a Netter atlas [7] during the first years of medical school. Furthermore, the selected group of medical specialists involved in the daily care for pectus patients are inadequately united and embedment in scientific societies is poor. In the Netherlands, surgical treatment of chest wall deformities is performed by general thoracic, cardiothoracic, and pediatric surgeons. Yet, a joint interest group has not been formally launched. Also, internationally, pectus-related working groups are scarce. The Chest Wall International Group (CWIG), the largest multinational and multidisciplinary collaborative on disorders involving the chest wall, has only just over a hundred members to date.

To support the importance of pectus excavatum, a solid scientific basis is crucial. During the last decades, there has been an exponential growth in the number of publications on this subject (PubMed search: [1990: n=28; 2000: n=45; 2010: n=148; 2020: n=192]). However, compared to disorders with similar prevalence rates, the absolute numbers of published articles are relatively low. Moreover, the number of multicenter randomized controlled trials on pectus excavatum in literature is very limited. In 2019, the English National Health Service (NHS) reviewed the evidence for surgical correction of pectus deformities and concluded that there is not enough evidence to routinely commission the intervention [8]. Consequently, reimbursement has recently been discontinued in the United Kingdom (UK). This inevitably causes deteriorated access to care for pectus patients who are withheld from adequate analysis and treatment. Moreover, a further decline in expertise among UK health care providers occurs. Therefore, pectus specialists should join hands together and collaborate to strengthen the scientific foundation.

Regarding the aforementioned presumed underestimation of pectus excavatum prevalence in the general population in conjunction with the lack of awareness among health care professionals, one could assume that a significant percentage of patients with a symptomatic pectus excavatum are still withheld from proper analysis and treatment. Future initiatives to improve recognition of pectus in a broad sense are thus essential.

However, increasing digitalization and internet accessibility also offers chances in this 21st century. Today's children and adolescents are immersed in both traditional and new forms of digital media [9]. Despite apparent disadvantages, social media also offers a wide range of opportunities. More and more patients use social media to obtain health care information [10-12]. Pectus patients, who are often young and part of the current digital generation, could especially benefit. The effects of internet and social media begins to be noticeable among patients with pectus excavatum. With the increased awareness through these media, the number of pectus patients who seek help continues to rise [13]. Moreover, introduction of patient information websites on pectus excavatum has significantly improved access to specialized pectus services [4]. Also, national initiatives on social media are appreciated, such as the so-called Pectus Support Groep Nederland. This is a Zuyderland-initiated support group for Dutch pectus patients on Facebook which already has more than four hundred members since its start in 2020. Likely, over the next few years internet will become an established medium in the process of providing information for pectus patients.

To document pectus morphology and severity, and to allow for objective follow-up, several pectus centers include optical imaging as diagnostic modality in their work up of pectus patients. Since the early days, medical photography has been part of the diagnostic process at our center. Over the years, multiple improvements in optical imaging have been explored. Three-dimensional raster stereography and external depth measurements were added to our conventional photographic routine as described in 2011 by Van Dijk and colleagues [14]. Besides many advantages of routine protocolized photo series in pectus patients, it also comes with limitations. For example, it only provides two-dimensional rendering of a three-dimensional deformity. Moreover, measurement of external pectus depth at the deepest point does not value other important aspects of pectus excavatum such as pectus asymmetry, sternal torsion, or volume of the indentation. Therefore, we explored three-dimensional (3D) optical imaging as an alternative modality. First, we conducted a systematic review with meta-analysis from which we concluded that 3D imaging was an attractive and promising alternative imaging technique compared to computed tomography (CT) and plain radiographs for determination of pectus excavatum severity, without the exposure to

ionizing radiation [15]. After comparison of the use of three different scanners for 3D imaging of the chest wall [16], the Artec Leo (Artec3D, Luxembourg, Luxembourg) imaging system was purchased and employed for pectus patient care. A novel 3D imaging and processing protocol was then developed providing an alternative to conventional photography for documentation of pectus surface geometry and severity [17]. Comparing 3D imaging to chest X-rays and CT, it proved an accurate radiation-free modality providing suitable indices for surgical decision making [18]. Furthermore, its ability to discriminate between presence or absence of cardiac compression turned out to be excellent [19]. The use of 3D optical imaging is foreseen to establish a central role in preoperative work up and post-operative evaluation of chest wall deformities.

Pectus excavatum is a clinical diagnosis, which is predominantly based on visual assessment. Except the necessity for inward displacement of the sternum and adjacent structures, further specific definitions on for example minimum required morphologic dimensions of the deformity are not available. Even amongst pectus experts, the diagnosis of pectus excavatum is still much debated, especially in moderate cases or in hybrid forms (e.g., pectus arcuatum) of chest wall deformities.

In **Chapter 2** of this thesis, we conducted a study in which experienced pectus surgeons evaluated interactive 3D images for the presence and various morphological aspects of pectus excavatum. Considerable inter- and intra-observer disagreements were found. Therefore, for the sake of adequate documentation of individual variables and objective comparison of groups in literature, a uniform definition of pectus excavatum is crucial. In other words, the need for a common language about the entity of pectus excavatum among care givers involved in diagnosis and management of these patients is needed.

In many conditions, especially in oncology, diagnostic work up and preoperative planning is standardized and protocolized. In pectus excavatum, a wide range of diagnostic modalities is utilized and consensus on its use is lacking among clinicians. Chest CT is the most commonly used preoperative study, however plain chest radiographs are still used by 52% of pectus experts [20]. One oft-cited drawback of CT is the use of ionizing radiation with associated risks, especially among pediatric patients. However, low-dose CT with tin filtration applies a radiation dose equal to plain radiographs [21] and therefore is a very suitable tool for work up preoperative planning in pectus patients. Although CT provides excellent information on the osseous structures of the chest wall, major drawbacks are its static character and the inability to provide insights in functional consequences of the deformity (e.g., dynamic

cardiac function). To objectify the structural and physiological components of pectus excavatum, magnetic resonance imaging (MRI) is gaining popularity [22-25]. Uniformity in sequence acquisition during different phases of breathing could be essential since the degree of cardiac compression seems to increase during expiration [26]. Most complaints in patients with pectus excavatum are posture or exercise dependent, and exercise intolerance is generally caused by external cardiac compression, specifically of the right ventricle [27]. Therefore, dynamic imaging modalities (e.g., echocardiography in sitting position or during performance) should preferably be incorporated in the work up of pectus excavatum [28]. Above all, diagnostic and preoperative processes need to be uniformed.

To objectively determine the severity pectus severity, a variety of imaging derived severity indices have been developed. The Haller index being one of them and is considered as gold standard severity measure. This index is calculated by dividing the transverse chest diameter (widest horizontal distance of the inner chest) by the anteroposterior diameter (shortest distance between spine and sternum) [29]. Despite being used in almost all series on pectus excavatum in literature, the Haller index is associated with major limitations. It attempts to quantify a 3D deformity by an equation of 2D metrics at the deepest point of indentation. Accordingly, it nullifies other important morphological aspects such as shape (i.e., asymmetry), length, width, point of onset, sternal rotation, and presence of costal flaring. Furthermore, functional implications (e.g., degree of cardiac impression, structural consequences) are not considered. By these reasons and as also stressed by Martinez-Ferro, there is a need for development of an alternative index which overcomes the current limitations of the Haller index. Such a new index should be able to discriminate between pectus excavatum patients and controls, evaluate the severity of the deformity, quantify physiological impact, help to select therapeutic strategies and be able to reflect results after treatment [20]. Furthermore, it should be widely accepted, and applicable and testable in both a clinical and scientific setting. With such purpose, an automatic quantification tool of morphologic features of pectus excavatum based on three-dimensional optical images was developed at our institution [30]. Future research should focus on its clinical value and ability to incorporate objective morphologic features in the process of surgical decision making.

Surgical treatment of pectus excavatum has undergone several transformations during the last decades, both in terms of number of treated patients and techniques. For decades, a variety of open techniques have been used for operative correction. The most well-known of these is the Ravitch procedure, as first described in 1949 [31]. Over the years, numerous modifications have been made to the original technique. The introduction of a less invasive

method by Nuss in the late 80's of last century has been a real game changer [32]. This procedure was later referred to as minimally invasive repair of pectus excavatum (MIRPE) and consists of retrosternal placement of one or more pre-bent metal bars which instantly correct the deformity. MIRPE was introduced in our center in 2008 and has been the preferred treatment option since. The introduction of new techniques may involve a learning curve. To evaluate this process for MIRPE, we evaluated all consecutive Nuss procedures between 2008 and 2018 in **Chapter 3**. The constructed learning curves demonstrated that adopting the Nuss procedure is safe in terms of complications while at least performing one procedure per month. From another point of view, by creating a strict initiation protocol through proctoring and thereafter having the necessary volume to build experience, high quality outcome could be established and maintained [33].

In the early days after introduction of MIRPE, the technique was predominantly used in pediatric patients. The group of Nuss and colleagues described a median age of 12.4 years in their initial experience of 303 cases which were treated between 1987 and 2000 [34]. Moreover, the initial experience of Haecker et al., consisted of a cohort of 22 with a median age of 15.5 years [35]. In those days, theoretical drawbacks for use at a higher age could be traced back to the changing aspects of chest wall rigidity over years. Due to ossification of cartilaginous structures and accompanying decrease in flexibility, MIRPE was ought less suitable and associated with more complications and postoperative pain at higher age. With gaining insights and experience, the area of indication for MIRPE has expanded toward adult patients [36]. Although the effect of pectus excavatum repair in adults was not comprehensively studied, recent literature demonstrates its feasibility in patients even beyond 50 years of age [37, 38]. Since MIRPE procedures in elderly are more difficult and inherently associated with increased risk for complications, correction in adult patients should be performed in specialized pectus centers and is crucial for favorable results [39]. Reviewing our results among adolescent and adult patients in **Chapter 4**, both patient groups demonstrated comparable major complication rates. Only the risk of chronic pain was higher in adults. MIRPE should therefore be considered as treatment of first choice in all age groups. However, considering the risk of more severe and long-lasting pain, shared decision making is pivotal, especially at older age.

One of the latest modifications during MIRPE is the use of sternal elevation techniques (SET), aiming to provide safe mediastinal passage (i.e., minimize pericardial trauma and risk of cardiac injury) by expansion of the retrosternal space and improving thoracoscopic exposure. A wide range of non-invasive and invasive techniques have been described, varying from

application of external vacuum devices to various invasive retraction systems. Park was one of the first pectus surgeons using the so-called crane technique. This technique makes use of a transsternal steel wire connected to a table-mounted retractor for intraoperative elevation of the sternum [40]. Over the years, a few modifications have been described, using different retraction systems or alternative retractors such as bone clamps, hooks, or tissue retractors [41-45]. Haecker et al. reviewed the available literature on the use of SET during MIRPE and found no cardiac or mammarian injuries, and SET-related complications in over 3000 cases by which elevation techniques were advocated to provide safety [46]. Unfortunately, conclusive evidence on improved safety in terms of a randomized controlled trial is unfeasible given the estimated incidence of 0.1% on SET-preventable major complications during MIRPE [47]. Therefore, solid scientific evidence should be provided by alternative means. Accordingly, we conducted a prospective cohort study which aimed to quantify the intraoperative effect of the crane technique by evaluating the amount of sternal lift and reduction of pectus depth using three-dimensional chest images acquired at different time points. In **Chapter 5** we revealed an effective sternal lift characterized by a 78% reduction of the sternal depression. As expected, its effect lessens with increasing pectus depth. However, especially in more severe cases, the degree of absolute lift may be more important than relative changes. Precisely in these patients, even a minimal lift could reduce the risk on serious adverse events. We therefore advocate for the use of sternal elevation during MIRPE without reservations, especially in moderate to severe cases, adult patients and during redo surgery. Future improvements of the crane technique could potentially further increase its efficacy, for example by exploring the use of more rigid or bilateral table-mounted frames.

Despite the established position of MIRPE, room still exists for open correction in selected cases. Considerations for such a procedure could include pectus morphology (e.g., extreme sternal torsion), unsuitability for MIRPE (e.g., prior failed Nuss procedure or prior thoracic surgery), and surgeon's and patient's preference. The modified Ravitch procedure is, despite its various modifications, still the most frequently performed technique for open correction. Yet, due to the limited institutional caseload and diversity among indications, sample sizes are generally low thereby limiting options for research. Nevertheless, surgeons still seek to improve its results by modifying the technique and switching to the use of alternative potentially superior materials. For example, the use of locking compression plates instead of the use of conventional cerclage wires with retrosternal mesh support for fixation of the sternal correctional osteotomy is described in **Chapter 7**. The use of locking plates drastically reduces the risk of symptomatic non-union. However, the price paid is a relatively

high reoperation rate for plate removal due to bulkiness of the hardware used. In a pursuit to reduce the need for revisional surgery, thinner anatomically contoured locking plates were investigated. Its pilot results were evaluated in **Chapter 8**, revealing unchanged favorable union rates and reduced need for hardware removal. Although larger series with long-term follow-up are warranted, angular stable plate fixation with thin and anatomically contoured locking plates seems a promising next step in further optimization of the modified Ravitch procedure. Potential future improvements should strive for the reduction of seroma formation, thereby reducing the length of hospital stay and wound infection rate. In the field of breast surgery, flap fixation techniques as fibrin glue application and quilting with use of sutures have already proven successful in reduction of the dead space where seroma formation usually occurs [48-50]. Another method could be suture anchor reinsertion of the pectoralis major muscles, as described in **Chapter 9**. Additional benefit may be a more anatomical soft tissue reconstruction, theoretically resulting in improved esthetic and functional outcome.

Enhanced recovery after surgery (ERAS) has played an important role in surgical practice during the last decade. The ERAS society started developing perioperative care programs in the beginning of the 21st century. They initially aimed to improve recovery in the field of colorectal surgery, but soon its principles were adopted by other surgical specialties. In 2019, the ERAS guideline for enhanced recovery after lung surgery was published [51]. One of the ERAS aspects concerns perioperative analgesia. This aspect is key in prosperous recovery after all types of surgery, but in particular for pectus surgery. Epidural analgesia has long been considered as gold standard [52-54] hence its established use in large pectus centers [55, 56]. However, the use of epidural catheters can come with technical difficulties and complications, but is, moreover, associated with longer use of urinary catheters and length of hospital stay [57]. Cryoablation, also referred to as cryoanalgesia, is a new and promising alternative for longlasting postoperative analgesia. In cryoablation, the bilateral intercostal nerves are frozen causing Wallerian degeneration, thereby preventing transmission of pain signals. We conducted a systematic review and meta-analysis of all available literature in which we compared the results of cryoablation versus thoracic epidural analgesia following MIRPE (**Chapter 6**). Intercostal nerve ablation was found to serve as an attractive and effective modality, which was moreover associated with a reduced length of hospital stay. However, conclusive evidence was limited by a small sample size and the fact that the majority of studies used a non-randomized study design. In addition, all studies originated from the United States of America where the device used for cryoablation already received

FDA approval. In Europe, CE marking for this specific use of cryoablation probes is expected late in 2021. Future adequately powered randomized trials including long-term follow-up will be needed to strengthen the evidence and provide insights in the durability of analgesia and its complications such as neuropathic pain.

Summarizing, widespread improvements in surgical care for patients with pectus excavatum were described and evaluated in this thesis. Consensus on the presence of pectus excavatum and its different morphologic aspects turned out to be absent among experienced pectus surgeons. This stresses the concern of inter- and intra-observer disagreements when evaluating patients with pectus excavatum. In addition, MIRPE proved to be a safe technique in both adolescents and adults with comparable risks on major complications. Implementation of a Nuss program was shown to be safe without a typical learning curve, under the condition that a strict initiation protocol and adequate case load was present. Intercostal cryoanalgesia suggests being an attractive alternative to classic epidural pain protocols given the relatively shorter length of hospital stay.

Alternatively, performing repair of pectus excavatum through the conventional modified Ravitch procedure, locking compression plates proved to provide sufficient stability, resulting in adequate union of the sternal osteotomy. Subsequent modifications using thinner plates reduced the need for plate removal due to implant related complaints. In addition, suture bone anchors can be successfully used for muscle reinsertion in symptomatic pectoralis dehiscence, a rare complication after modified Ravitch.

Limitations

The main limitation of the present thesis is the predominant retrospective character of the studies included. Patient characteristics and data were collected over a relatively long period, undeniably introducing inherent forms of bias, such as those due to missing data and confounders due to often subtle changes in daily practice over the years. Furthermore, treatment of pectus excavatum can be considered as a niche, which is accompanied by relatively small patient numbers.

Future perspectives

Further research in the field of chest wall deformities and, more specific, pectus excavatum, is crucial. Only a solid scientific foundation can provide insights in diagnostic and therapeutic pathways and allows for a fair comparison of outcomes. Furthermore, it serves an important

purpose for our pectus patients and can be used as critical opposition towards sometimes benevolent health care insurance companies. The set-up of a (inter-)national, prospective data registry is essential. With no intention of being complete, the following subjects must certainly be primary topic of research in the coming years. First, agreement on definition and preoperative work-up should be reached. This could for example be done by means of a Delphi study among international pectus experts. Second, physiological consequences of pectus excavatum, including the effects of cardiac compression, must be indisputably demonstrated, or ruled out. Third, innovative analgesic techniques like cryoanalgesia or other novel methods such as the use of virtual reality should be further investigated, preferably by means of prospective multicenter cohort studies or randomized controlled trials. Fourth, novel techniques including 3D imaging, 3D printing and artificial intelligence should be explored and be deployed for the benefit of preplanning and prediction of outcome and risk of recurrence. And, last but not least, questionnaires and patient reported outcome measures have to be developed and validated for the sake of implementation of value-based healthcare principles. Based on these points, we might be able to define criteria for successful outcome after repair of pectus excavatum, both from a patient's and a surgeon's point of view.

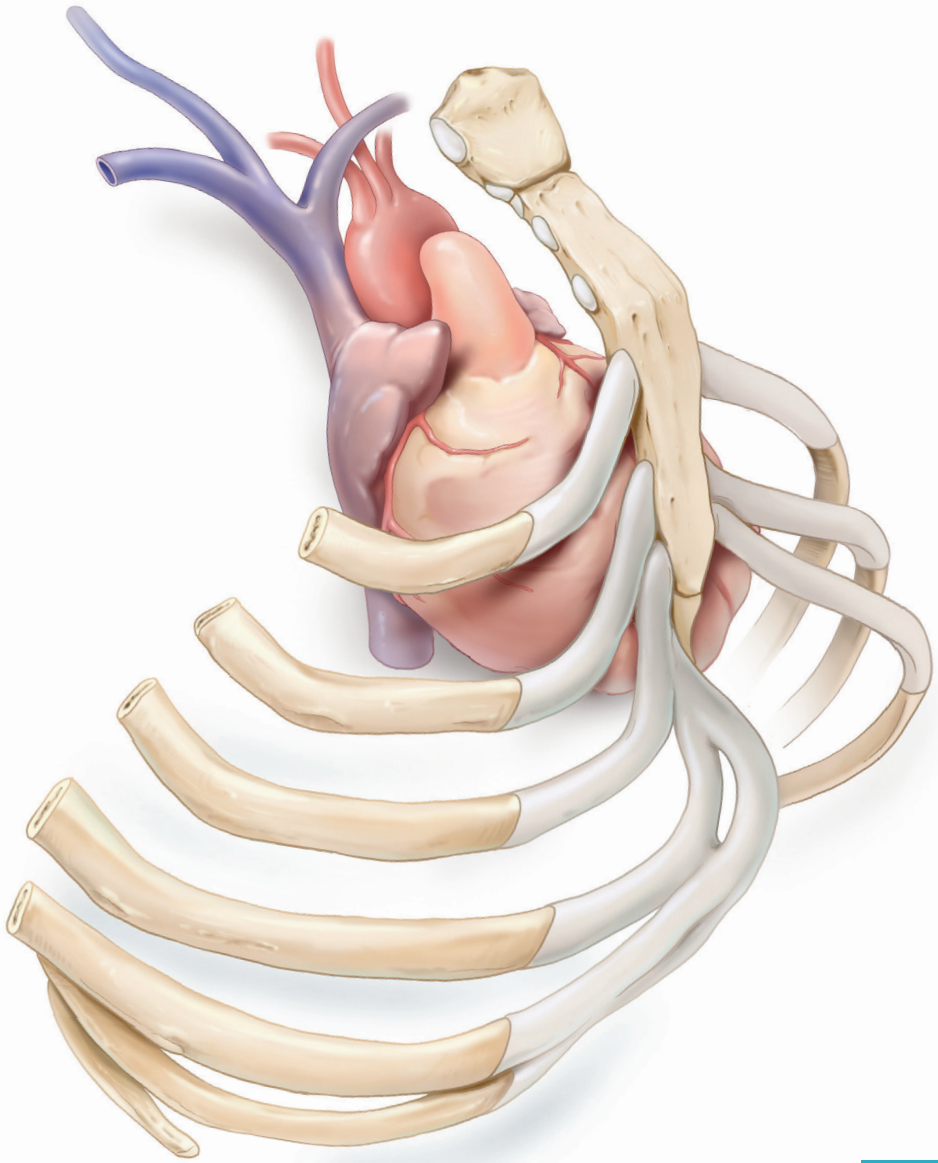
REFERENCES

1. Chung CS, Myrianthopoulos NC. Factors affecting risks of congenital malformations. I. Analysis of epidemiologic factors in congenital malformations. Report from the Collaborative Perinatal Project. *Birth defects original article series*. 1975;11(10):1-22.
2. Kwiecinski J. Pectus excavatum in mummies from ancient Egypt. *Interact Cardiovasc Thorac Surg*. 2016;23(6):993-5.
3. Biavati M, Kozlitina J, Alder AC, Foglia R, McColl RW, Peshock RM, et al. Prevalence of pectus excavatum in an adult population-based cohort estimated from radiographic indices of chest wall shape. *PLoS One*. 2020;15(5):e0232575.
4. Tikka T, Webb J, Agostini P, Kerr A, Mannion G, Steyn RS, et al. Pectus patient information website has improved access to care and patient reported outcomes. *J Cardiothorac Surg*. 2016;11(1):69.
5. Eisinger RS, Islam S. Caring for People With Untreated Pectus Excavatum: An International Online Survey. *Chest*. 2020;157(3):590-4.
6. Baudouin R, Levesque E, Jancovici R. Beyond aesthetic consequences: congestive hepatopathy caused by pectus excavatum. *Eur J Cardiothorac Surg*. 2018;54(3):604-6.
7. Netter FH. *The CIBA Collection of Medical Illustrations*: Saunders Elsevier; 1979.
8. NHS. Clinical Commissioning Policy: Surgery for pectus deformity (all ages) 2019 [updated 22 February 2019. NHS England Reference: 170113P:[Available from: https://www.england.nhs.uk/wp-content/uploads/2019/02/1675-Policy_Surgery-for-pectus-deformity.pdf.
9. Reid Chasiakos YL, Radesky J, Christakis D, Moreno MA, Cross C. Children and Adolescents and Digital Media. *Pediatrics*. 2016;138(5).
10. Smailhodzic E, Hooijsma W, Boonstra A, Langley DJ. Social media use in healthcare: A systematic review of effects on patients and on their relationship with healthcare professionals. *BMC Health Serv Res*. 2016;16(1):442.
11. Farsi D. Social Media and Healthcare: A Review, Part I. *J Med Internet Res*. 2021.
12. Grajales FJ, 3rd, Sheps S, Ho K, Novak-Lauscher H, Eysenbach G. Social media: a review and tutorial of applications in medicine and health care. *J Med Internet Res*. 2014;16(2):e13.
13. Pilegaard H, Licht PB. Minimal Invasive Repair of Pectus Excavatum and Carinatum. *Thorac Surg Clin*. 2017;27(2):123-31.
14. Van Dijk H, Höppener PF, Siebenga J, Kragten HA. Medical photography: a reliable and objective method for documenting the results of reconstructive surgery of pectus excavatum. *J Vis Commun Med*. 2011;34(1):14-21.
15. Daemen JHT, Loonen TGJ, Lozekoot PWJ, Maessen JG, Maal TJJ, Hulsewé KWE, et al. Optical imaging versus CT and plain radiography to quantify pectus severity: a systematic review and meta-analysis. *J Thorac Dis*. 2020;12(4):1475-87.
16. Daemen JHT, Loonen TGJ, Verhulst AC, Maal TJJ, Maessen JG, Vissers YLJ, et al. Three-Dimensional Imaging of the Chest Wall: A Comparison Between Three Different Imaging Systems. *J Surg Res*. 2021;259:332-41.
17. Daemen JHT, Loonen TGJ, Coorens NA, Maessen JG, Maal TJJ, Hulsewé KWE, et al. Photographic documentation and severity quantification of pectus excavatum through three-dimensional optical surface imaging. *J Vis Commun Med*. 2020;43(4):190-7.

18. Daemen JHT, Coorens NA, Hulswé KWE, Maal TJJ, Maessen JG, Vissers YLJ, et al. Three-dimensional Surface Imaging for Clinical Decision Making in Pectus Excavatum. *Semin Thorac Cardiovasc Surg.* 2021.
19. Daemen JHT, Heuts S, Ardabili AR, Maessen JG, Hulswé KWE, Vissers YLJ, et al. Development of prediction models for cardiac compression in pectus excavatum based on three-dimensional surface images. *Semin Thorac Cardiovasc Surg.* 2021.
20. Martinez-Ferro M. Indices for Pectus Deformities. In: Kolvekar SK, Pilegaard HK, editors. *Chest Wall Deformities and Corrective Procedures* Springer International Publishing. Switzerland: Springer International Publishing; 2016. p. 35-60.
21. Messerli-Odermatt O, Serrallach B, Gubser M, Leschka S, Bauer RW, Dubois J, et al. Chest X-ray Dose Equivalent Low-dose CT with Tin Filtration: Potential Role for the Assessment of Pectus Excavatum. *Acad Radiol.* 2020;27(5):644-50.
22. Sun J, Chen C, Peng Y, Zhang Y, Tian H, Yu J, et al. Comparison of magnetic resonance imaging and computed tomography to measure preoperative parameters of children with pectus excavatum. *Pediatr Investig.* 2019;3(2):102-9.
23. Lo Piccolo R, Bongini U, Basile M, Savelli S, Morelli C, Cerra C, et al. Chest fast MRI: an imaging alternative on pre-operative evaluation of Pectus Excavatum. *J Pediatr Surg.* 2012;47(3):485-9.
24. Stagnaro N, Trocchio G, Torre M, Rizzo F, Martucciello G, Marasini M. Cardiovascular MRI assessment of pectus excavatum in pediatric patients and postoperative simulation using vacuum bell. *J Pediatr Surg.* 2020.
25. Marcovici PA, LoSasso BE, Kruk P, Dwek JR. MRI for the evaluation of pectus excavatum. *Pediatr Radiol.* 2011;41(6):757-8.
26. Raichura N, Entwisle J, Leverment J, Beardsmore CS. Breath-hold MRI in evaluating patients with pectus excavatum. *Br J Radiol.* 2001;74(884):701-8.
27. Obermeyer RJ, Cohen NS, Jaroszewski DE. The physiologic impact of pectus excavatum repair. *Semin Pediatr Surg.* 2018;27(3):127-32.
28. Rodríguez-Granillo GA, Martínez-Ferro M, Capuñay C, Bellia-Munzón G, Deviggiano A, Raggio I, et al. Preoperative multimodality imaging of pectus excavatum: State of the art review and call for standardization. *Eur J Radiol.* 2019;117:140-8.
29. Haller JA, Jr., Kramer SS, Lietman SA. Use of CT scans in selection of patients for pectus excavatum surgery: a preliminary report. *J Pediatr Surg.* 1987;22(10):904-6.
30. Coorens NA, Daemen JHT, Slump CH, Loonen TGJ, Vissers YLJ, Hulswé KWE, et al. The Automatic Quantification of Morphological Features of Pectus Excavatum Based on Three-Dimensional Images. *Semin Thorac Cardiovasc Surg.* 2021.
31. Ravitch MM. The Operative Treatment of Pectus Excavatum. *Ann Surg.* 1949;129(4):429-44.
32. Nuss D, Kelly RE, Jr., Croitoru DP, Katz ME. A 10-year review of a minimally invasive technique for the correction of pectus excavatum. *J Pediatr Surg.* 1998;33(4):545-52.
33. Lazar JF. Commentary: Not just Nuss. *J Thorac Cardiovasc Surg.* 2020.
34. Croitoru DP, Kelly RE, Jr., Goretsky MJ, Lawson ML, Swoveland B, Nuss D. Experience and modification update for the minimally invasive Nuss technique for pectus excavatum repair in 303 patients. *J Pediatr Surg.* 2002;37(3):437-45.
35. Haecker FM, Bielek J, von Schweinitz D. Minimally invasive repair of pectus excavatum (MIRPE)--the Basel experience. *Swiss Surg.* 2003;9(6):289-95.

36. Velazco CS, Arsanjani R, Jaroszewski DE. Nuss procedure in the adult population for correction of pectus excavatum. *Semin Pediatr Surg.* 2018;27(3):161-9.
37. Hokschi B, Kocher G, Vollmar P, Praz F, Schmid RA. Nuss procedure for pectus excavatum in adults: long-term results in a prospective observational study. *Eur J Cardiothorac Surg.* 2016;50(5):934-9.
38. Jaroszewski DE, Ewais MM, Chao CJ, Gotway MB, Lackey JJ, Myers KM, et al. Success of Minimally Invasive Pectus Excavatum Procedures (Modified Nuss) in Adult Patients (≥ 30 Years). *Ann Thorac Surg.* 2016;102(3):993-1003.
39. Ewais MM, Chaparala S, Uhl R, Jaroszewski DE. Outcomes in adult pectus excavatum patients undergoing Nuss repair. *Patient Relat Outcome Meas.* 2018;9:65-90.
40. Park HJ, Jeong JY, Jo WM, Shin JS, Lee IS, Kim KT, et al. Minimally invasive repair of pectus excavatum: a novel morphology-tailored, patient-specific approach. *The Journal of thoracic and cardiovascular surgery.* 2010;139(2):379-86.
41. Johnson WR, Fedor D, Singhal S. A novel approach to eliminate cardiac perforation in the nuss procedure. *Ann Thorac Surg.* 2013;95(3):1109-11.
42. Jeong JY, Lee J. Use of needlescope and crane technique to avoid cardiac injury in Nuss procedure. *Ann Thorac Surg.* 2014;98(1):386-7.
43. St Peter SD, Sharp SW, Ostlie DJ, Snyder CL, Holcomb GW, 3rd, Sharp RJ. Use of a subxiphoid incision for pectus bar placement in the repair of pectus excavatum. *J Pediatr Surg.* 2010;45(6):1361-4.
44. Rygl M, Vyhnanek M, Kucera A, Mixa V, Kyncl M, Snajdauf J. Technical innovation in minimally invasive repair of pectus excavatum. *Pediatr Surg Int.* 2014;30(1):113-7.
45. Jaroszewski DE, Johnson K, McMahon L, Notrica D. Sternal elevation before passing bars: a technique for improving visualization and facilitating minimally invasive pectus excavatum repair in adult patients. *The Journal of thoracic and cardiovascular surgery.* 2014;147(3):1093-5.
46. Haecker FM, Krebs T, Kocher GJ, Schmid RA, Sesia SB. Sternal elevation techniques during the minimally invasive repair of pectus excavatum. *Interact Cardiovasc Thorac Surg.* 2019;29(4):497-502.
47. Hebra A, Kelly RE, Ferro MM, Yüksel M, Campos JRM, Nuss D. Life-threatening complications and mortality of minimally invasive pectus surgery. *J Pediatr Surg.* 2018;53(4):728-32.
48. Van Bastelaar J, Granzier R, van Roozendaal LM, Beets G, Dirksen CD, Vissers Y. A multi-center, double blind randomized controlled trial evaluating flap fixation after mastectomy using sutures or tissue glue versus conventional closure: protocol for the Seroma reduction After Mastectomy (SAM) trial. *BMC Cancer.* 2018;18(1):830.
49. Granzier RWY, van Bastelaar J, van Kuijk SMJ, Hintzen KFH, Heymans C, Theunissen LLB, et al. Reducing seroma formation and its sequelae after mastectomy by closure of the dead space: The interim analysis of a multi-center, double-blind randomized controlled trial (SAM trial). *Breast.* 2019;46:81-6.
50. Van Bastelaar J, van Roozendaal L, Granzier R, Beets G, Vissers Y. A systematic review of flap fixation techniques in reducing seroma formation and its sequelae after mastectomy. *Breast Cancer Res Treat.* 2018;167(2):409-16.
51. Batchelor TJP, Rasburn NJ, Abdelnour-Berchtold E, Brunelli A, Cerfolio RJ, Gonzalez M, et al. Guidelines for enhanced recovery after lung surgery: recommendations of the Enhanced Recovery After Surgery (ERAS[®]) Society and the European Society of Thoracic Surgeons (ESTS). *Eur J Cardiothorac Surg.* 2019;55(1):91-115.

52. Soliman IE, Apuya JS, Fertal KM, Simpson PM, Tobias JD. Intravenous versus epidural analgesia after surgical repair of pectus excavatum. *Am J Ther.* 2009;16(5):398-403.
53. Siddiqui A, Tse A, Paul JE, Fitzgerald P, Teh B. Postoperative epidural analgesia for patients undergoing pectus excavatum corrective surgery: a 10-year retrospective analysis. *Local Reg Anesth.* 2016;9:25-33.
54. Stroud AM, Tulanont DD, Coates TE, Goodney PP, Croitoru DP. Epidural analgesia versus intravenous patient-controlled analgesia following minimally invasive pectus excavatum repair: a systematic review and meta-analysis. *J Pediatr Surg.* 2014;49(5):798-806.
55. Nuss D, Croitoru DP, Kelly RE, Jr., Goretsky MJ, Nuss KJ, Gustin TS. Review and discussion of the complications of minimally invasive pectus excavatum repair. *Eur J Pediatr Surg.* 2002;12(4):230-4.
56. Pilegaard HK. Nuss technique in pectus excavatum: a mono-institutional experience. *J Thorac Dis.* 2015;7(Suppl 2):S172-6.
57. St Peter SD, Weesner KA, Sharp RJ, Sharp SW, Ostlie DJ, Holcomb GW, 3rd. Is epidural anesthesia truly the best pain management strategy after minimally invasive pectus excavatum repair? *J Pediatr Surg.* 2008;43(1):79-82.



11

Summary
Samenvatting

SUMMARY

Pectus excavatum, also known as funnel chest, is the most common congenital anterior chest wall disorder. Due to a growth disturbance of the costal cartilage, the sternum is displaced dorsally, often accompanied by sternal tilt or torsion. This results in a typical, often asymmetrical, indentation of the anterior chest wall. Pectus excavatum can be asymptomatic, but commonly results in a variety of complaints. These can be of cosmetic, psychosocial, or physical origin. Due to the dorsal displacement of the sternum, the underlying heart can be compressed, predominantly affecting the right heart-side. This compression results in palpitations, dyspnea, and exercise intolerance. Because of limited knowledge about pectus excavatum, in combination with small patient numbers, analysis and treatment preferably takes place in specialized pectus centers.

Chapter 1 starts with a general introduction on pectus excavatum describing the variety of its phenotype. There are several uncertainties as well as chances for improvement in the treatment of patients with anterior chest wall disorders. The **aim of this thesis** is to describe and evaluate improvements in various aspects of surgical care in patients with pectus excavatum.

Chapter 2 focusses on the diagnosis of pectus excavatum. The visual assessment of pectus excavatum was compared between different pectus experts. Three-dimensional (3D) images of 58 subjects were evaluated by five (cardio)thoracic surgeons. Pectus excavatum was diagnosed in 55% to 95% of cases by different surgeons, revealing considerable inter-observer differences. The variation in judgement could have a substantial impact on work up and treatment strategies. Therefore, objective standardization of visual assessment of pectus excavatum is urged.

In the second half of the 20th century, surgical correction of pectus excavatum emerged. Initially, through open techniques of which the Ravitch procedure was best known. During this operation, first described in 1949, the affected costal cartilage is resected, and the depressed sternum corrected via one or more sternal osteotomies. Over the years, many small modifications have been made to the original technique. Only two decades ago, a new, less invasive technique was introduced. Via limited incisions, one or more retrosternal correctional bars are placed to instantly correct the indentation of the anterior chest wall. Nowadays, this so-called Nuss procedure, also known as MIRPE (minimally invasive repair of pectus excavatum), is considered as treatment of choice for most patients with pectus excavatum.

In **Chapter 3**, we evaluate the learning curve associated with the adoption of MIRPE. After a 10-procedure proctoring period, the Nuss procedure proved to be a safe technique to adopt and perform without a typical learning curve. This requires the performance of at least 1 procedure per surgeon per 35 days.

In its early days, MIRPE was thought to solely suitable for pediatric patients. Due to the increased chest wall rigidity with increasing age, pectus correction by retrosternal bar placement was long considered as more difficult and too dangerous in elderly patients because of the higher rigidity of the chest wall with increasing age. Moreover, postoperative recovery was deemed to be prolonged in adults. In recent years, the indication area has extended more and more towards adult patients.

Chapter 4 describes postoperative complications in the Nuss procedure and evaluates differences in outcome and recovery between adolescent (≤ 24 years of age) and adult patients (>24 -year-old). In a single-center retrospective cohort study, 327 patients with pectus excavatum who underwent the Nuss procedure were evaluated. Analysis showed that the incidence of major complications was comparable for both age groups. However, older patients more frequently suffer from chronic postoperative pain than younger ones.

One of the recent developments in pectus excavatum surgery is the use of sternal elevation techniques. With the help of tools such as retractors, bone hooks, and hoist systems, the sternum is temporarily lifted during surgery. As a result of the achieved increased retrosternal space, Nuss bar placement becomes easier and less dangerous. The use of sternal elevation techniques therefore aims to reduce surgical risks, improve safety, and expand the spectrum of indications for minimally invasive repair. A popular method for sternal elevation is the crane technique, during which the sternum is lifted by a transsternal steel wire attached to a table mounted retractor. In **Chapter 5**, a prospective quantitative analysis of the use of this crane technique during MIRPE is performed with the use of 3D images. In 30 patients, sternal elevation by the crane provided a median reduction of the deformity of 78%, corresponding with a median residual depth of three millimeters. The effect lessened with increasing pectus depth.

Pain management plays a key role in the perioperative care of pectus excavatum. Adequate pain control is the main determinant for length of hospital stay, postoperative recovery and patient satisfaction. Epidural analgesia is currently considered as gold standard, but has significant drawbacks, including impediment of mobilization and sensorimotor disturbances of the upper limbs. A novel approach in the field of pain management is the use

of intercostal nerve cryoablation. Applying this technique, the intercostal nerves are frozen at multiple levels causing Wallerian degeneration and subsequent regeneration over time, intending to achieve more adequate and prolonged pain relief. **Chapter 6** is a systematic review and meta-analysis on the use of cryoablation for analgesia after MIRPE. This review shows a significantly reduced length of hospital stay and amount of postoperative opioid usage associated with cryoablation compared with conventional epidural analgesia.

As stated earlier, open repair has long been the only surgical technique available for repair of pectus excavatum. Currently, the Ravitch procedure is still performed in selected cases, albeit to a limited extent. Over the years, many small modifications to the original Ravitch procedure have been reported. The most relevant adjustment in our center has been the switch from the use of retrosternal mesh support and cerclage wires to the use of conventional locking compression plates for fixation of the sternal correctional osteotomy. The goal of **Chapter 7** is to compare the influence of these refinements in techniques on the risk of symptomatic non-union. A retrospective analysis of 44 patients was performed, revealing a lower incidence of symptomatic non-union after locking plate fixation. However, a remarkable finding was the relatively high need for plate removal due to implant prominence. Therefore, we adjusted our technique, and thinner but potentially biomechanically weaker sternum-specific locking plates were introduced. **Chapter 8** focusses on the safety and feasibility of rigid fixation of the sternal osteotomy by SternaLock Blu plates. The initial results of a pilot study in nine patients are reported. No intra-operative complications were encountered. Moreover, union of the osteotomy was achieved in all patients. In only one case, plate removal was indicated, thus achieving a reduction for hardware removal compared to our previous study using conventional locking compression plates. Therefore, thin SternaLock Blu plates seem to be safe and effective in providing adequate rigid fixation during the modified Ravitch procedure.

During years of practice, surgeons may encounter rather rare complications after pectus surgery. Generally, there is no standard treatment option available in these scarce situations, warranting improvisation by the treating surgical team. In **Chapter 9** we report two cases of pectoralis major dehiscence after modified Ravitch. Successful repair with the use of Mitek bone suture anchors was carried out.

Finally, the general discussion in **Chapter 10** elaborates on the above-mentioned topics. A broader perspective on perioperative care in pectus excavatum patients is given, as well as a preview for future research in this field.

In conclusion, pectus excavatum is a common anterior chest wall disorder which negatively affects patients' well-being. Unfortunately, the general knowledge on this condition is still limited, even among health care professionals. This thesis describes several aspects of surgical care for patients with pectus excavatum and evaluates different innovative techniques. Further research and innovation on this subject are crucial to provide better future care for pectus patients.

SAMENVATTING

Pectus excavatum, ook wel bekend als trechterborst of schoenmakersborst, is de meest voorkomende aandoening van de borstwand. Opvallend genoeg is er nog maar relatief weinig over deze afwijking bekend. Waarschijnlijk ontstaat er ten gevolge van een groeistoornis van het ribkraakbeen een progressieve achterwaartse verplaatsing van het borstbeen, welke meestal gepaard gaat met een kanteling of verdraaiing hiervan. Dit resulteert in een typische, vaak asymmetrische, indeuking van de voorste borstwand. Pectus excavatum is soms asymptomatisch, maar geeft vaak aanleiding tot een verscheidenheid aan klachten. Deze kunnen van cosmetische, psychosociale en/of lichamelijke aard zijn. Door de achterwaartse verplaatsing van het borstbeen kan het onderliggende hart worden samengedrukt, waarbij vooral de rechterboezem en -kamer zijn aangedaan. Dit kan weer leiden tot hartkloppingen, kortademigheid en inspanningsintolerantie. Vanwege het relatief zeldzame karakter van pectus excavatum vindt analyse en behandeling bij voorkeur plaats in ziekenhuizen die gespecialiseerd zijn in de zorg voor pectuspatiënten.

Dit proefschrift begint met een algemene inleiding over pectus excavatum in **Hoofdstuk 1**. Bij de behandeling van patiënten met een afwijking aan de voorste borstwand zijn er verscheidene facetten nog onduidelijk of onbekend. Dit biedt kansen voor verbetering van het zorgproces. Het **doel van dit proefschrift** is het beschrijven en evalueren van verbeteringen van diverse aspecten van chirurgische zorg bij patiënten met een pectus excavatum.

Hoofdstuk 2 richt zich op de diagnose van pectus excavatum. We vergeleken de visuele beoordeling van pectus excavatum door verschillende pectusspecialisten. Driedimensionale (3D) beelden van 58 patiënten werden beoordeeld door vijf (hart-)longchirurgen. Pectus excavatum werd in 55% tot 95% van de gevallen gediagnosticeerd door de verschillende chirurgen, waarbij er aanzienlijke verschillen tussen de beoordelaars aan het licht kwamen. De variatie in deze beoordeling zou van invloed kunnen zijn op verschillen in analyse en behandelingsstrategie tussen ziekenhuizen. Daarom lijkt het verstandig om te streven naar een objectieve en gestandaardiseerde visuele beoordeling van pectus excavatum.

In de tweede helft van de twintigste eeuw werd gestart met het uitvoeren van operatieve behandelingen van pectus excavatum. Aanvankelijk werden hiervoor alleen open technieken gebruikt. De meest bekende hiervan is de Ravitchprocedure, welke voor het eerst werd beschreven in 1949. Tijdens deze operatie wordt via een grote snee het aangedane ribkraakbeen verwijderd, waarna de stand van het ingedrukte borstbeen

gecorrigeerd wordt via een of meer zaagsneden. In de loop van de jaren zijn vele kleine wijzigingen aangebracht in de oorspronkelijke techniek. Twee decennia geleden werd een geheel nieuwe, minder invasieve techniek geïntroduceerd, de zogenaamde Nussprocedure. Hierbij worden via kleine sneetje's een of meerdere metalen beugels achter het borstbeen geplaatst om de indeuking van de voorste borstwand te corrigeren. Tegenwoordig wordt deze Nussprocedure beschouwd als de behandeling van eerste keuze voor de meeste patiënten met een symptomatische pectus excavatum.

In **Hoofdstuk 3** evalueren we de leercurve van de Nussprocedure. In een single-center retrospectieve observationele cohortstudie werd het leerproces na een proctoringperiode beoordeeld. Na proctoring van tien operaties bleek de Nussprocedure een veilig uit te voeren techniek te zijn, zonder dat deze gepaard ging met een typische leercurve. Een vereiste hiervoor is wel dat deze operatie per chirurg tenminste eens per 35 dagen wordt uitgevoerd.

In de beginjaren werd de Nussprocedure alleen geschikt geacht voor de behandeling van pectus excavatum bij jonge patiënten. Vanwege de toegenomen stijfheid van de borstwand op latere leeftijd werd een pectuscorrectie door middel van plaatsing van Nussbars lange tijd als (te) moeilijk en (te) gevaarlijk beschouwd bij oudere patiënten. Bovendien werd ingeschat dat het herstel na de operatie bij volwassenen veel langer zou zijn. De laatste jaren is het indicatiegebied van de Nussprocedure gaandeweg uitgebreid richting volwassen patiënten.

Hoofdstuk 4 beschrijft de postoperatieve complicaties na de Nussprocedure en maakt een vergelijking tussen jongere (≤ 24 jaar) en volwassen patiënten (> 24 jaar). In een single-center retrospectieve cohortstudie werden 327 patiënten met een pectus excavatum welke een Nussprocedure ondergingen geëvalueerd. Analyse toonde aan dat het vóórkomen van belangrijke complicaties vergelijkbaar was voor beide leeftijdsgroepen. Oudere patiënten hadden wel vaker last van chronische postoperatieve pijn dan jongeren.

Een van de belangrijkste recente ontwikkelingen binnen de pectuschirurgie is het gebruik van zogenoemde sternale elevatietechnieken. Met behulp van hulpmiddelen zoals retractors, bothaken en takelsystemen wordt het borstbeen tijdens de operatie tijdelijk opgetild. Als gevolg van de hierbij verkregen extra ruimte tussen het ingedeukte borstbeen en het hart wordt het plaatsen van een Nussbar gemakkelijker en minder gevaarlijk. Het gebruik van sternale elevatietechnieken heeft tot doel de operatierisico's te verkleinen, de veiligheid te verbeteren en het spectrum van indicaties voor minimaal-invasieve behandeling uit te

breiden. Een populaire methode voor sternale elevatie is de zogenaamde kraantechniek, waarbij het borstbeen wordt opgetild door middel van een door het borstbeen geplaatste staaldraad die wordt vastgemaakt aan een takelsysteem. In **Hoofdstuk 5** wordt een kwantitatieve analyse uitgevoerd van het gebruik van deze kraantechniek tijdens de Nussprocedure. Bij dertig patiënten werd het effect prospectief geëvalueerd met behulp van driedimensionale foto's. Sternale elevatie door middel van de kraantechniek gaf een mediane afname van de borstkasindeuking van 78%, overeenkomend met een restdiepte van drie millimeter. Bovendien werd de voorste borstwand over een groter oppervlak opgetild dan in vergelijking met het uiteindelijke resultaat na Nussbarplaatsing. Zoals verwacht werd het relatieve effect minder naarmate de pectusdiepte toenam. Sternale elevatie door middel van de kraantechniek lijkt een veilige en effectieve methode. Het routinematige gebruik ervan tijdens de Nussprocedure zou overwogen dienen te worden in de (meer) ernstige gevallen.

Pijnbestrijding speelt een sleutelrol in het perioperatieve zorgproces bij pectus excavatum. Adequate pijnstilling is de belangrijkste bepalende factor voor de opnameduur in het ziekenhuis, het postoperatieve herstel en de patiënttevredenheid. Epidurale pijnstilling wordt beschouwd als de gouden standaard, maar heeft ook belangrijke nadelen. Een nieuwe pijnstillingstechniek is het gebruik van cryoablatie. Bij deze methode worden de tussenribzenuwen tijdens de operatie op meerdere niveaus bevroren, met als doel een meer adequate en langdurige pijnstilling te bewerkstelligen. **Hoofdstuk 6** is een systematische review en meta-analyse over het gebruik van cryoablatie voor perioperatieve pijnstilling na de Nussprocedure. Alle beschikbare wetenschappelijke literatuur over dit onderwerp werd systematisch geëvalueerd, waarbij er een significant kortere verblijfsduur in het ziekenhuis en een aanzienlijk lager gebruik van morfineachtige middelen na de operatie werd aangetoond.

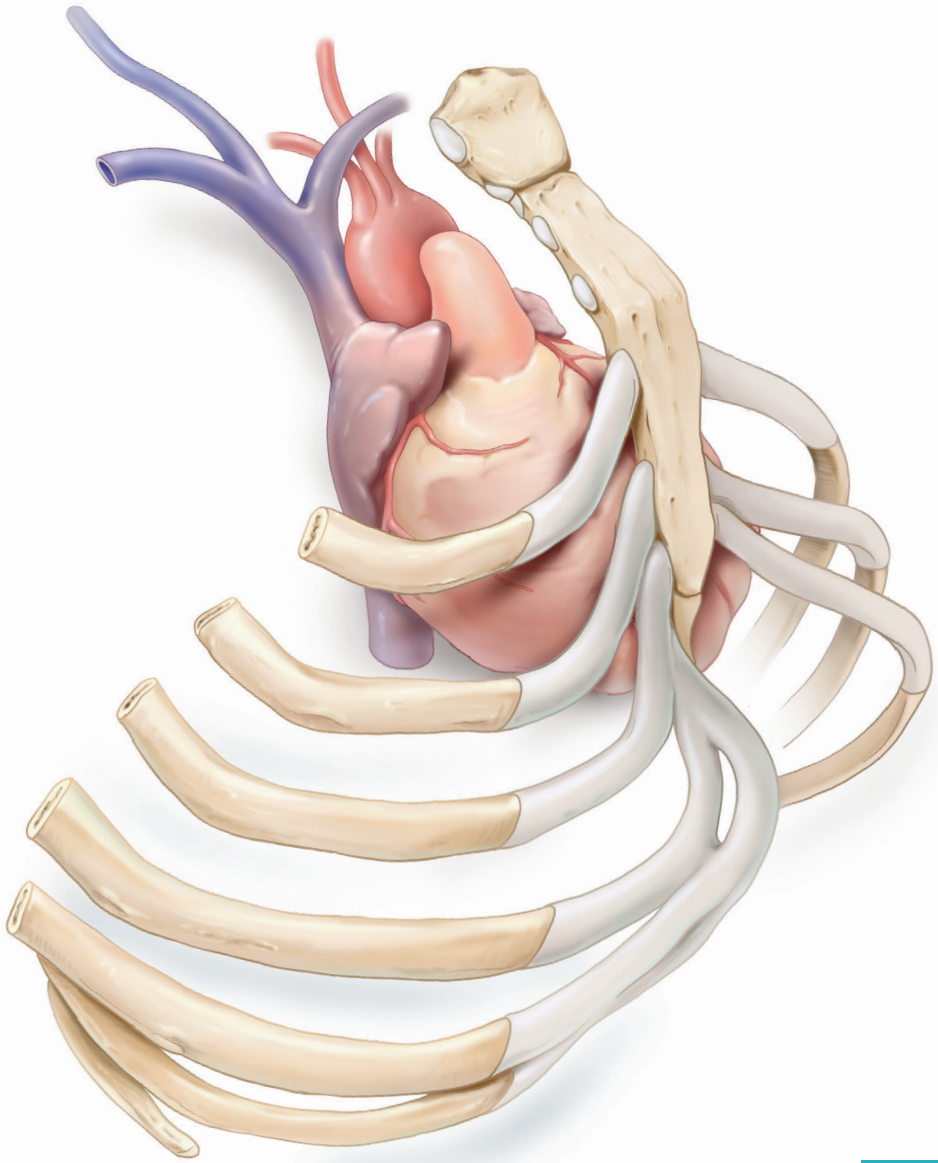
Zoals eerder vermeld, is de open correctie via de Ravitchprocedure gedurende lange tijd de enige beschikbare operatietechniek geweest voor de chirurgische behandeling van pectus excavatum. Momenteel wordt de Ravitchprocedure nog steeds in geselecteerde gevallen uitgevoerd, zij het in beperkte mate. In de loop der jaren zijn er vele kleine aanpassingen in de oorspronkelijke techniek gedaan. In ons centrum was de grootste verandering de overstap van kunststof matjes en staaldraden ter ondersteuning en fixatie van het gecorrigeerde borstbeen naar het gebruik van klassieke hoekstabiele titanium platen en schroeven. Het doel van **Hoofdstuk 7** is om de invloed van deze beide technieken op het risico van een niet-genezende zaagsnede van het borstbeen te vergelijken. Een retrospectieve analyse

van 44 patiënten werd uitgevoerd, waarbij de kans op slechte genezing lager bleek na fixatie met hoekstabiele platen. Opvallend was wel dat er relatief vaak werd besloten tot het verwijderen van de platen en schroeven ten gevolge van klachten door het uitsteken van het materiaal. Daarom hebben wij onze techniek verder aangepast en werden kleinere en dunnere hoekstabiele platen geïntroduceerd, welke specifiek zijn ontwikkeld voor plaatsing op het borstbeen. **Hoofdstuk 8** richt zich op de veiligheid en haalbaarheid van rigide fixatie van de zaagsnede van het borstbeen door middel van deze zogeheten SternaLock Blu platen. De resultaten van een pilotstudie bij negen patiënten worden beschreven. Er werden geen complicaties gedurende de operaties vastgesteld. Bovendien genazen de zaagsneden van het borstbeen bij alle patiënten. In slechts één geval hoefde de plaat later weer te worden verwijderd, hetgeen een verbetering was vergeleken met de resultaten uit de beschikbare literatuur. Kleine en dunne SternaLock Blu platen lijken derhalve veilig en effectief te zijn voor het verzorgen van een adequate en rigide fixatie van de zaagsnede van het borstbeen tijdens de gemodificeerde Ravitchprocedure.

In de loop der jaren kwamen wij soms zeldzame complicaties na pectuschirurgie tegen. In het algemeen was er dan geen standaard behandeloptie bekend, waardoor improvisatie door het behandelend chirurgisch team noodzakelijk was. In **Hoofdstuk 9** beschrijven wij twee gevallen waarbij de grote borstspieren niet goed genazen na een gemodificeerde Ravitchprocedure. Er werden met goed resultaat hersteloperaties uitgevoerd, waarbij gebruik werd gemaakt van zogenaamde botankers.

Tenslotte wordt in de algemene discussie in **Hoofdstuk 10** dieper ingegaan op de bovengenoemde onderzoeksonderwerpen. Een breder perspectief op perioperatieve zorg bij patiënten met pectus excavatum wordt gegeven, evenals een vooruitblik op toekomstig onderzoek op dit gebied.

Concluderend kan worden gesteld dat pectus excavatum een frequent voorkomende aandoening van de voorste borstwand is die het welzijn van patiënten negatief kan beïnvloeden. Helaas is de algemene kennis over deze aandoening nog beperkt, zelfs onder zorgprofessionals. Dit proefschrift beschrijft meerdere aspecten van chirurgische zorg voor patiënten met een pectus excavatum en evalueert verschillende innovatieve technieken. Verder onderzoek naar en innovatie op dit gebied zijn van cruciaal belang om in de toekomst betere zorg voor onze pectuspatiënten te kunnen bieden.



12

Impact paragraph

IMPACT PARAGRAPH

The **aim of this chapter** is to describe the scientific and societal impact of the results of the present thesis.

Pectus excavatum, also known as funnel chest, is the most common anterior chest wall disorder. Symptoms can be of cosmetic, psychosocial, and physical nature. Consequences of pectus excavatum can be dramatic for patients, often resulting in body image disturbances, decreased self-esteem, and severe limitations in activity levels. Research on this subject is crucial to substantiate the seriousness of complaints and improve the quality of care. Moreover, it promotes awareness among patients and care givers and will eventually lead to a solid scientific evidence basis for health care insurance companies and governments.

Relevance for patients

Due to the relatively unknown character of pectus excavatum, many patients visit multiple care givers in different hospitals before final referral to a specialized pectus center. Internet and social media play a crucial role in the provision of specific information to patients, causing patients to be often better informed than their treating physician. Thus, from a patient's perspective, there is a strong need for advanced knowledge on chest wall deformities among health care professionals.

On patient level, pectus excavatum often elicits a significant burden. The majority of patients express that they are ashamed about their appearance and experience an unfavourable body image. Consequently, patients are being hindered in social interactions and have a declined social self-consciousness. By example, this may result in impediment to taking off clothes and thereby avoidance of public places such as beaches and swimming pools. Cardiac impression due to the depressed sternum frequently leads to exercise intolerance and inability to perform sports with peers. Surgical treatment of pectus excavatum significantly improves psychosocial and physical performance. However, in the interest of patients, there is still a lot to improve in terms of general knowledge on chest wall deformities and surgical care. Scientific research plays a crucial role in this. Therefore, pectus patients directly benefit from the results as described in this thesis as well as future studies.

Relevance for clinical practices

Raising awareness for chest wall deformities amongst care givers is of utter importance. A spectrum of doctors with different backgrounds can be confronted by patients who present with symptomatic pectus excavatum and their associated request for help. The more health care professionals are familiar with the disorder, the better they will be able to recognize the consequences and need for referral to a specialized center for further diagnostics and subsequent treatment. Currently, the tertiary referral centers in themselves should be challenged to unite and take care of establishing uniform definitions and care pathways. Development of new surgical techniques and improvement of perioperative care is strongly dependent on the effort of the small number of expert pectus surgeons worldwide. To facilitate further studies, a larger number of patients per center and thus further centralization of care is beneficial. By improving surgical techniques and perioperative care, recovery and patient reported outcomes will be enhanced. Research promotes knowledge sharing and accordingly enhances quality of care and outcome.

Relevance for pectus society

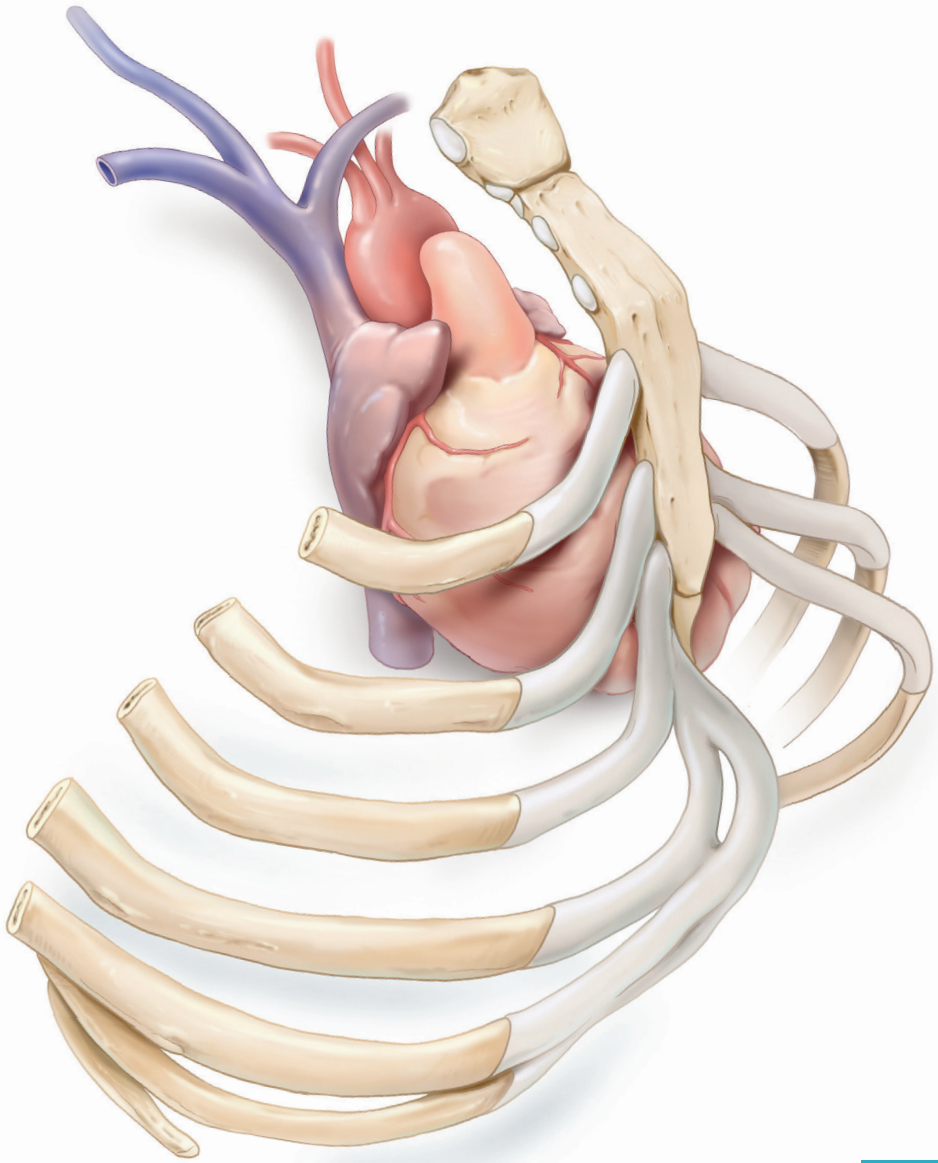
The medical field for chest wall deformities is very diverse. Globally, surgical treatment is in hands of different specialties and is being carried out by general thoracic, cardiothoracic, pediatric, general, and orthopedic surgeons. Solid anchorage in national or regional professional associations is lacking. Worldwide, only few interest groups on chest wall disorders exist. There is a strong need for development of (inter-)national networks in which pectus experts are brought together. A joint data registration could allow prospective multicenter and multinational research, therewith substantially increasing the number of participating patients and providing robust data. The latter is of importance to stress the relevance of adequate diagnostics and treatment in patients with pectus excavatum. Moreover, scientific substantiation plays a pivotal role in discussions with national health care insurance companies, such as currently in the United Kingdom where the NHS does no longer reimburses treatment.

Relevance for commercial parties

Since pectus excavatum is classified as specialized highly complex but low-volume care, the disorder is not a very attractive subject for medical industries. Development of new surgical instruments and implants is not prioritized, and such processes often take years. In contrast to other disorders, industry-facilitated research on chest wall disorders is almost non-

existent. In the interest of pectus patients and their care givers, an intensive cooperation with commercial parties would result in a substantial boost to quality. Extensive collaboration between tertiary referral centers for pectus surgery might increase the volume, therewith increasing the interest of commercial parties.

In conclusion, the present thesis contributes to increasing knowledge on pectus excavatum and its treatment. Furthermore, awareness amongst health care professionals is being expanded. As a result, this thesis contributes to the pursuit of perioperative care for patients suffering from pectus excavatum, thereby aiming to enhance their psychosocial and physical condition.



13

Dankwoord

DANKWOORD

Een vaak gelezen onderdeel van een proefschrift is het dankwoord. Het schrijven ervan is enerzijds eenvoudig, anderzijds een hele uitdaging. Een van de vereisten voor een promovendus verwoord in het Promotiereglement der Universiteit Maastricht is “zelfbeperking bij de omvang van de tekst”. Ik zal mijn best doen.

Promoveren naast een baan als thorax- en traumachirurg in Zuyderland medisch centrum in combinatie met vele neventaken binnen en buiten het ziekenhuis was onmogelijk geweest zonder hulp van velen.

Allereerst ben ik grote dank verschuldigd aan al onze pectuspatiënten. Wat is het een voorrecht om zorg en begeleiding te mogen bieden aan deze veelal jonge mensen die van heinde en verre hun weg weten te vinden naar ons pectuscentrum. Veelal ontstaat tijdens dit traject een intensieve band tussen patiënt en behandelteam. Met veel voldoening geniet ik van het behaalde resultaat na een operatie, dat voor patiënten en ouders vaak een ware ommekeer in hun leven betekent. Dank ook voor de grote bereidheid om als proefpersoon deel te nemen aan de vele studies die worden uitgevoerd.

Vervolgens wil ik graag mijn promotor en copromotoren bedanken. Hoewel wellicht niet conform de mores, begin ik met de laatsten.

Dr. Hulsewé en dr. Vissers, Karel en Yvonne. Wat hebben we toch een mooi en hecht team als thoraxsectie. En wat hebben we de afgelopen jaren veel bereikt! Slechts enkele voorbeelden zijn de implementatie van een uniportal VATS programma, erkenning van onze centra voor minimaal invasieve thoraxchirurgie en thoraxwandaandoeningen als topklinische functies door STZ en de prioritering van de thoraxchirurgie binnen Zuyderland onder meer als patiëntgericht centrum en speerpunt. We zijn uitgegroeid tot een gerenommeerd Europees trainingscentrum voor minimaal invasieve thoraxchirurgie, met maandelijks gasten uit de gehele EMEA-regio. Ook is het ons gelukt om in relatief korte tijd een goed draaiende researchgroep op te zetten. Ik ben ervan overtuigd dat, mede gezien onze tomeloze ambities, het mooiste nog moet komen. Met heel veel plezier denk ik terug aan onze vele buitenlandse avonturen, waarbij onze jaarlijkse bezoeken aan hoog-volume centra in China wat mij betreft met stip bovenaan blijven staan. Beste Karel, directeur van het ziekenhuis. Altijd rustig, weloverwogen, een goede strateeg. Ondersteunend, waarbij je anderen de ruimte laat om te excelleren. Maar ook met gevoel voor humor. Zelfs als ik je om 12 uur 's nachts vanachter een Duitse vangrail bel om te vragen of je mijn dienst van de volgende

dag zou willen overnemen. Ik kan enorm genieten van je twinkelogen, soms gelijktijdig hoofdschuddend, als er weer voor de zoveelste keer een flauwe of schuine grap voorbijvliegt aan de operatietafel. Lieve Yvonne, we hebben samen al veel meegemaakt. Wat ben je toch een topmens. Een echte teamplayer, organisatorisch ijzersterk. En de liefste dokter die een patiënt zich wensen kan. Bedankt voor alles, bedankt voor dat je bent wie je bent.

Vervolgens wil ik graag mijn promotor bedanken. Professor Maessen, beste Jos. We proberen samen al jarenlang de regionale samenwerking op het gebied van thoraxchirurgie van de grond te krijgen. Na wat aanvankelijk een vliegende start leek, strooiden onder andere aanpalende specialisten en bestuurders roet in het eten van ons mooie plan. We zijn altijd contact blijven houden, zoekende naar mogelijkheden om toch gezamenlijk de kwaliteit van zorg voor onze thoraxchirurgische patiënten te verbeteren. Eén daarvan was het opzetten en uitvoeren van onderzoek. Je was enigszins verbaasd maar direct enthousiast toen ik enige tijd later naar je toe kwam met ook een uitgewerkt voorstel voor mijn eigen promotie. Hartelijk dank voor je directe toezegging om hierbij als promotor te willen optreden. Hopelijk lukt het ons ook om de andere partijen te overtuigen van het nut van intensieve regionale samenwerking, een gezamenlijke opleiding en hopelijk ook de toekomstige concentratie van de niet-cardiale thoraxchirurgie in een groot, gezamenlijk regionaal thoraxchirurgisch centrum. In één adem wil ik ook graag jouw steun en toeverlaat, Monique Loo, bedanken voor het regelen van de vele afspraken, logistiek en lekkere kopjes koffie.

De leden van de beoordelingscommissie, prof. dr. Bouvy (beste Nicole), prof. dr. Van Gemert (beste Wim), prof. dr. Poeze (beste Martijn), prof. dr. De Leyn (beste Paul) en dr. Zuidema (beste Wietse), graag wil jullie bedanken voor de snelle en kritische beoordeling van dit proefschrift en de geboden mogelijkheid tot verdediging hiervan. Tevens dank voor de plezierige samenwerking gedurende de jaren. De overige leden van de promotiecommissie wil ik bedanken voor hun bereidheid zitting te nemen in de corona en het optreden als opponent tijdens mijn verdediging.

Mijn paranimfen, Paul Hustinx en Berry Meesters. Wat een eer dat jullie mij nu ook hierbij willen ondersteunen. Onze eerste kennismaking is alweer ruim 20 jaar geleden, in de zomer van 2001 om precies te zijn. Paul toen als jonge traumachirurg, Berry als oudste assistent chirurgie en ik als co-assistent die in jullie woorden "pas net over zijn klompen kon piesen". We zijn altijd samen blijven optrekken en in de tijd is er een hechte band ontstaan. Dit resulteerde er voor mij uiteindelijk ook mede in dat ik, direct aansluitend aan het afronden van mijn opleiding, in 2011 als traumachirurg mocht toetreden tot de Maatschap Heelkunde

Zuid-Limburg (MHZL). Jullie hebben mij altijd alle ruimte geboden, zowel binnen als buiten de traumachirurgie en muren van het ziekenhuis. Jullie stimuleerden mij zelfs om, als net toegetreden traumamaat, een CHIVO-schap longchirurgie te volgen. Deze kruisbestuiving heeft veel gebracht, onder andere op het gebied van thoraxtrauma. Heel veel dank daarvoor.

Beste Paul, je bent sinds januari 2021 van je welverdiende pensioen aan het genieten. Ik mis je nog dagelijks als collega, altijd beschikbaar voor overleg, solide en betrouwbaar. Tijdens jouw afscheidsrede, aansluitend aan je benoeming tot Officier in de Orde van Oranje-Nassau, omschreef je mij als een zoon. Dit heeft mij erg geroerd, temeer omdat jij ook altijd als een vader voor mij gezorgd hebt, vanaf het moment dat ik als 21-jarig broekie aansluiting bij jullie zocht. Je stond en staat altijd voor mij klaar. Ook heb je me altijd gestimuleerd om te gaan promoveren, voor mijn eigen belang en dat van de maatschap.

Berry White, vanaf dag 1 hadden we een enorme klik, die is uitgegroeid tot een ontzettend hechte vriendschap. Wat hebben we een lol en wat hebben we al veel meegemaakt samen. Je nam me vanaf het begin af aan binnen en buiten het ziekenhuis op sleeptouw, naar café Sjik of op de Mergelweg, naar allerlei cursussen en congressen, waarbij we beiden mijn eerste kennismaking met de traumadagen niet snel zullen vergeten. Onze westerse roots en mentaliteit blijven roepen, mede getuige de vele over en weer gestuurde foto's van de Van Brienoordbrug als een van ons weer eens thuis is. Toch blijven we het zuiden trouw en is Maastricht nu ons tweede thuis. Op OK worden de meisjes met grote regelmaat gek van ons, muziek op standje 10 en de ene flauwe grap na de andere, tot tranen van het lachen aan toe. Buurman & buurman, gebroeders Bever, duo Ed & Ed en Bertje & Henk zijn enkele van de vele bijnamen die ze ons al gegeven hebben. Ik ben er trots op, net zoals op onze vriendschap.

There is no I in team. Ik ben er dan ook van overtuigd dat het doen van onderzoek teamsport pur sang is. In enkele jaren tijd hebben we in recordtempo een goed lopende researchgroep op het gebied van thoraxchirurgie opgezet, waarin een hechte onderlinge samenwerking centraal staat. Wat ooit kleinschalig begonnen is na een gezellig etentje met Lori en Matthijs, is snel uitgegroeid tot een hecht onderzoeksteam van data-/researchmanagers, studenten (Technische) Geneeskunde, onderzoekers, arts-assistenten en promovendi. Zonder volledig te kunnen zijn en met het risico onbedoeld mensen te vergeten en hiermee te kort te doen, wil ik graag Aimée Franssen, Alexander Pennings, Anna Hofstra, Arlette Ramos Gonzalez, David van Dijk, Elise van Polen, Enzo Ramazzotti van Loo, Iris Kamps, Iris Laven, Jean Daemen, Linda Crapels, Lori van Roozendaal, Luca van Hulst, Matthijs van Gool, Nadine Coorens, Nicky

Janssen, Omar Ashour, Paul Aniel, Pieter Lozekoot, Robert van den Broek en Tessa Geraedts bedanken voor jullie tomeloze inzet en gezellige pizza-avonden!

Zonder de anderen te kort te willen doen, wil ik Jean Daemen apart bedanken. Beste Jean, kleine grote boef, of "Sjaan met de grappige neus" zoals mijn destijds 3-jarige dochter je sinds jullie eerste kennismaking nog altijd noemt. Een aantal jaar geleden kwam je als co-assistent naar ons toe op de thorax-OK, met de vraag of je eens mee mocht kijken. En, zoals je mij later vertelde, met de hoop om hierna aan te kunnen sluiten bij onze researchgroep. En aldus geschiedde. Niemand had toen kunnen voorzien wat voor enorme boost jij aan het thoraxonderzoek zou geven. Cum laude afgestudeerd als AKO, simultaan met het cijfer 10 afgestudeerd als Technisch Geneeskundige. Kartrekker van meerdere onderzoeksprojecten. Binnen no-time je promotie afgerond. Voor mij ben je ondertussen een open boek, waarbij de knopjes om jou te triggeren en stimuleren tot jouw frustratie gemakkelijk te vinden zijn. Ik vind het ontzettend leuk om samen onze beide promotietrajecten te hebben doorlopen en geniet dagelijks van het vele contact. Je droom om chirurg te worden gaat ongetwijfeld uitkomen, ik hoop dat we nog vele jaren samen kunnen werken!

Ook de behandeling van pectuspatiënten is teamsport. De leden van ons pectusteam bestaan, naast de reeds genoemde thoraxchirurgen, uit kinderartsen, cardiologen en medisch fotografen en leveren allen een grote bijdrage aan ons pectuscentrum.

Dr. Kragten, beste Hans. Jij bent als cardioloog met pectus als speciaal aandachtsgebied vanaf het eerste moment betrokken geweest. De laatste jaren geniet je van je welverdiende pensioen, maar blijf je de pectuspatiënten en ons een warm hart toedragen, onder andere via onze Facebookgroep.

Dr. Lenderink, beste Timo. Jij hebt het stokje feilloos overgenomen van Hans. Altijd bereid om patiënten die vaak van ver komen, tussendoor te zien. Ik kijk er naar uit om samen ook het cardiale gedeelte van het pectusresearch verder uit te bouwen.

Dr. Höppener, beste Paul. Oud-huisarts, inhouds- en ervaringsdeskundige. Ondertussen heb je een respectabele leeftijd bereikt, maar ben je nog steeds vol enthousiasme om je bijdrage te leveren aan de pectuszorg, onder meer via de door jou opgezette en onderhouden website spesweb.nl.

Dr. Busari, beste Jamiu. Jarenlang heb jij je hard gemaakt voor onze pectuspatiënten en het belang van multidisciplinaire samenwerking benadrukt. Na je vertrek uit het Zuyderland werk je sinds enkele jaren onder de Caribische zon. Dr. Hendriks, dr. Van Horck en drs. Van

den Berg, beste Han, Marieke en Jochem. Jullie zijn in de voetsporen van Jamiu gestapt en hebben de samenwerking met de kindergeneeskunde verder versterkt. Dank voor de fijne samenwerking.

Ernst, Mirianne en Juul, onze medisch fotografen. Jullie zien iedere pectuspatiënt en vervolgen hen van begin tot eind. Jullie zijn als onze ogen en oren, en vaak minstens zo goed op de hoogte van alle wel en wee van onze patiënten. Bedankt voor jullie kwalitatief hoogwaardige foto's en jullie bereidheid om ook 3D opnames te maken en proefpersonen te helpen includeren. Ook als ik jullie weer eens last minute bel of app met een verzoek om tijdens een operatie foto's te maken, wordt hier altijd tijd voor vrijgemaakt.

Nancy Plum, bedankt voor je ondersteuning van ons pectusteam en het organiseren van de vele overlegmomenten.

Zuyderland medisch centrum ben ik erkentelijk voor alle geboden mogelijkheden en het positioneren van de thoraxchirurgie inclusief de behandeling van pectus als belangrijk speerpunt. Wij hebben hierin veel steun ontvangen van het RVE-management: Max Wellens, Berry Meesters, Anke Neyens en Tom Dormans. Anke, jij verdient een aparte vermelding. Wat ben je toch een heerlijk mens. Bedankt voor je ondersteuning, grenzeloze vertrouwen en alles wat je voor ons mogelijk hebt gemaakt. Geniet van je welverdiende pensioen!

Zowel op het gebied van thoraxwandaandoeningen als minimaalinvasieve longchirurgie bestaat er een nauwe samenwerking met de ziekenhuizen en universiteiten om ons heen. Bijzondere dank ben ik verschuldigd aan de opleiding Technische Geneeskunde van de Universiteit Twente (professor Slump) en het 3D-lab van de Radboud Universiteit (professor Maal). Ook te vernoemen zijn de afdelingen cardiothoracale chirurgie (professor Maessen) en kinderchirurgie (professor Van Gemert) van het MUMC. Collega pectuschirurgen dr. Van Veer, drs. Elenbaas en drs. Van Huijstee, beste Hans, Ted en PJ, bedankt voor jullie samenwerking, onder andere tot uiting komend in hoofdstuk 2 van dit proefschrift.

Mijn maten, chirurgen van MHZL. In de ruim 10 jaar na fusie tussen de maatschappen chirurgie van voormalig Atrium medisch centrum en Orbis medisch centrum is een hoop gebeurd. We zijn uitgegroeid tot een goed georganiseerde vakgroep, waarin nagenoeg volledig gedifferentieerd gewerkt wordt. Alle subdisciplines binnen de heekunde maar ook onze vakgroep als geheel blinken uit in enthousiasme, ambitie en kwaliteit. Bedankt voor de samenwerking en werkplezier. En jullie onvoorwaardelijke steun, ook in moeilijke tijden, zoals ik helaas recent ook heb moeten meemaken. Mijn familie en ik zijn jullie hiervoor zeer erkentelijk. Ik ben er trots op om onderdeel uit te maken van onze club.

In het bijzonder wil ik nog de traumasectie benoemen. Na eerdere woorden tot Paul en Berry wil ik ook nadrukkelijk Annette en Raoul bedanken voor hun collegialiteit en plezierige samenwerking. Kostan, alvast welkom bij de club!

Ook Meindert Sosef verdient een aparte vermelding. Al vele jaren zijn we samen als (vice-) opleiders verantwoordelijk voor de opleiding chirurgie binnen Zuyderland. Voor beiden een grote eer en een ontzettend dankbare functie. Onze karakters verschillen soms wat, maar we hebben eigenlijk nagenoeg altijd dezelfde visie en sowieso hetzelfde doel: een topopleiding voor onze assistenten. Ik vind het ontzettend leuk om dit onderdeel samen met jou te trekken.

Zowel de huidige assistentengroep chirurgie en PA's als onze voormalige ANIOS, AIOS, VAIOS en BAIOS. Het is een voorrecht om als vice-opleider bij te mogen dragen aan jullie opleiding en vorming. Ik geniet er enorm van om jullie te zien groeien, zowel chirurgisch als op persoonlijk vlak. Bedankt voor alle mooie momenten, binnen en buiten het ziekenhuis.

Als opleider ontwikkel je een innige band met de fellows thoraxchirurgie. Na een of meerdere intensieve jaren waait eenieder weer uit en vindt zijn of haar definitieve plek. Soms maakt iemand een onuitwisbare indruk achter. Hes Brokx, jij was de laatste officiële CHIVO-longchirurgie voordat de opleiding verderging als fellowship. Ondertussen werk je alweer vele jaren naar tevredenheid als longchirurg in het Bravis. Gelukkig hebben we contact gehouden en zien we elkaar nog regelmatig tijdens cursussen en congressen. Paul Hollering, Piet Paulusma, Paultje Holleeder. Je kwam als gecertificeerd vaatchirurg vanuit Antwerpen naar ons voor een vervolgopleiding thoraxchirurgie. Na je eerste dag, waarin je mij tijdens een operatie hebt geleerd hoe je een BH kunt vouwen uit een buikgaas, waren wij twee handen op één buik. Wat heb je toch een enorm gevoel voor humor en wat hebben we een mooie tijd gehad. Vrij abrupt eindigde je fellowship ook weer ten gevolge van de ingestelde lockdown tijdens de COVID-19 pandemie. Je bent weer terug op het Antwerpse ZNA-nest en geniet met je mooie gezin van al het mooie Brasschaat jullie te bieden heeft. We hebben nog veel contact en er een mooie vriendschap aan over gehouden. Yanina Jansen, met veel overgave en enthousiasme zet jij je in als onze huidige fellow. Ik geniet van je leergierigheid, gezelligheid en wetenschappelijke interesse. Je zal je carrière na je fellowship voortzetten als thoraxchirurg in het UZ Leuven. We kijken al uit naar onze voortgezette samenwerking!

Dr. Bollen en dr. Siebenga, voorlopers binnen de thoraxchirurgie in Nederland. Jullie lieten mij al vroeg in mijn opleiding kennis maken met de thoraxchirurgie. Beste Ewald, veel van wat jij me destijds hebt geleerd, breng ik nog dagelijks in praktijk. Je voorliefde voor netjes

opereren en een goed weefselgevoel staan in mijn geheugen gegrift. Net als je minutieuze instructies hoe je de verschillende instrumenten het beste kunt vasthouden en gebruiken, tot in de laatste fase van mijn opleiding. En je opmerking met de jou zo typerende hoge stem “nee nee nee Loosje, nu niet stoer proberen te doen hè” tijdens een van mijn eerste lobectomieën. Tijdens je afscheid in december 2010 gaf je mij je Pearson, met hierin de handgeschreven tekst “Erik, wat zou het geweldig zijn als jij naast jouw traumatologische interesse ook de longchirurgie je eigen zou kunnen maken”. En aldus geschiedde, waarvoor dank!

Beste Jan, je hebt altijd vertrouwen in mij gehad en me (mede) opgeleid tot de chirurg die ik nu ben. Jouw voorliefde voor thoraxwandaandoeningen in het algemeen en pectus in het bijzonder heb je op mij overgedragen. Vele jaren hebben we samengewerkt, urenlang samen geopereerd en lief een leed gedeeld. Helaas lopen door omstandigheden onze paden nu niet meer parallel. Ik ben je zeer erkentelijk en dankbaar voor alles wat je me geleerd hebt. Hopelijk kruisen onze paden ergens in de toekomst weer.

Niet rechtstreeks betrokken bij het onderwerp van dit proefschrift, maar in mijn dagelijkse werk niet minder belangrijk zijn de collega's van de vakgroepen anaesthesie, longziekten, orthopaedie en spoedeisende geneeskunde binnen Zuyderland medisch centrum. Bedankt voor de plezierige samenwerking!

Geen operaties zonder een goed geoliede operatieafdeling. Lieve Carla, Femke, Iris, Judith, Kim (OK), Marjo, Moniek, Serena, Shelly en (last but not least) Thijs. Als inhoudsdeskundigen thoraxchirurgie zorgen jullie er dagelijks voor dat alles op rolletjes loopt op OK3. Schijnbaar zonder enige moeite gaan jullie telkens weer mee in onze eindeloze ideeën om verder te innoveren, of het nu om operatietechnieken of nieuwe sets gaat. Als volleerde gastvrouwen en -heer stellen jullie je operatiekamer telkens weer open voor onze talloze binnenlandse en buitenlandse gasten en maken jullie de cursusdagen tot een groot succes. Ook alle onderzoekers zijn welkom en wordt er alle tijd genomen voor weer de zoveelste extra 3D foto bij een pectuspatiënt. Ik geniet volop van jullie gezelligheid, flauwe grappen en gekibbel over het volume van de rode boom box. Met grote regelmaat zegt één van jullie: “Loosje, jij wordt ook nooit volwassen”. Laten we het vooral blijven hopen!

Ondanks het feit dat de operaties in de studies van dit proefschrift op de thorax-OK plaatsvonden, zijn de traumameisjes van OK5 zeker niet minder belangrijk in mijn dagelijks leven en verdienen zij een speciaal woord van dank. Lieve Nikita, Beau en Denise, bedankt voor alle gezelligheid en plezierige samenwerking. Lieve Chantal en Karlijn, we kennen

elkaar al jaren en door en door. Jullie zijn het motorblok van de trauma-OK. Altijd alles op en top geregeld en voorbereid, jullie zijn sturend en meedenkend, en opereren ook echt mee. Heerlijk direct. En iedereen die spatjes denkt te moeten krijgen wordt hierin feilloos gecorrigeerd. Jullie zijn toppers!

Kim, Leontine en Sandra, onze PRC-meisjes, bedankt voor jullie creativiteit en flexibiliteit!

Ook wil ik graag mijn dank uitspreken richting het management van de operatiekamers, en in het bijzonder naar Marjon Vincken, Ron Wetzels en Marcel Berkman. Marjon, we hebben altijd een goede klik gehad. Ik was dan ook blij dat je een paar jaar geleden het nieuwe unithoofd van het OK-complex in gebouw Q werd. Denken in mogelijkheden, maar altijd eerlijk en realistisch. Ik besef mij terdege welke mogelijkheden wij als thoraxchirurgie hebben gekregen en hoeveel van onze plannen binnen korte tijd ook echt geïmplementeerd konden worden. Ron, de directeur van de operatiekamers. Jaren geleden stonden we als twee broekies samen aan de operatietafel. Je bent doorgegroeid naar de functie van afdelingshoofd en hebt recent een mooie stap in je carrière gemaakt en bent nu directeur bedrijfsvoering bij de Mooi! kliniek. We hebben de laatste jaren nauw samengewerkt, onder andere in het DB-OK en verschillende werkgroepen. Sinds de start van de COVID-19 pandemie zijn we samen verantwoordelijk geweest voor de OK-capaciteit en invulling hiervan. Goudeerlijk en zoekend naar mogelijkheden, altijd en voor iedereen. Bovenal ben je gewoon een fijne kerel. Hopelijk keer je in de toekomst weer terug naar Zuyderland! Marcel, jij hebt recent het stokje van Ron overgenomen, inclusief zijn taken op het gebied van OK-planning en binnen de crisisorganisatie. Recht door zee en met het hart op de juiste plaats. Dank voor de plezierige samenwerking!

Secretariaat, OK-planners en poliklinieken chirurgie en kindergeneeskunde, hartelijk dank voor jullie ondersteuning. Een bijzonder woord van dank verdient Simone Rouwette. Lieve Simon(e), jij regelt alles tot in en achter de puntjes. We hebben altijd intensief samengewerkt, onder andere op het gebied van de planning, hetgeen uit veel meer bestaat dan alleen hokjes kleuren. Je gevleugelde uitspraak "Loos, ik zou je zelf gemaakt kunnen hebben" geeft al aan hoeveel we gemeen hebben.

Als thoraxsectie hebben we altijd nauwe contacten gehad met de industrie, waaruit vele mooie nationale en internationale projecten zijn ontstaan. Een bijzondere plaats hierin is altijd de samenwerking met Ethicon geweest. Luc Hennen, bedankt voor al je steun, vertrouwen en hulp bij de internationale profilering van ons centrum. Naast een intensieve samenwerking is er ook een goede vriendschap ontstaan. Van alle mooie momenten staat

voor mij nog steeds onze week in Shanghai met stip bovenaan. Wat hebben we een lol gemaakt binnen en buiten Shanghai Pulmonary Hospital. Ik denk bijvoorbeeld aan Bar Rouge met roof top bar, Club Mint met zijn haaienbassin, Luke Skywalker en Darth Vader, met onze nieuwe drones vliegen door de gangen van het hotel en de befaamde taxirit terug. Recent heb je besloten om Johnson&Johnson te verlaten en de overstap te maken naar Rods&Cones. Dank voor alles, ik hoop dat we onze samenwerking de komende jaren nog verder kunnen voortzetten!

Dan verlaat ik nu het ziekenhuis en komen we bij de mensen die het dichtst bij mij staan.

Zonder iedereen bij naam en toenaam te kunnen noemen, wil ik graag alle vrienden en familie bedanken voor alle steun en gezelligheid, ieder op zijn of haar eigen manier. Bijzonder is een vriendengroep die al vanaf onze middelbareschooltijd bijeen is en waarmee we menig mooie avond en vakantie beleefd hebben. Beste Alex, Nico, Marco, Menno en René: ieder van ons heeft ondertussen zijn eigen gezin en is ergens tussen Groningen en Oostenrijk neergestreken. Mooi dat we al die jaren contact hebben weten te houden. Hopelijk kunnen we elkaar na deze COVID-periode weer wat vaker zien!

Beste Bert, ondanks dat wij de eeuwige jeugd hebben, kennen we elkaar ondertussen al meer dan 40 jaar. Je ouders hebben altijd voor mij gezorgd alsof ik hun eigen kind was. En wij hebben er een vriendschap voor het leven aan overgehouden. Hopelijk vinden we wat meer tijd om elkaar weer wat regelmatig te zien!

Van de vele oppassen die het mogelijk maken om onze drukke banen te combineren met ons gezinsleven, verdienen er twee bijzondere aandacht. Jeanique, je kwam als eerstejaars studente Geneeskunde voor het eerst bij ons over de vloer. Ondertussen heb je vlekkeloos je opleiding doorlopen en sta je binnenkort hopelijk aan de vooravond van je carrière als kinderrevalidatiearts. Bedankt voor de vele oppasuren en je bereidheid en flexibiliteit om ook 's nachts voor ons klaar te staan als we weer eens samen dienst hadden of afwezig waren door cursussen of congressen. José, jij hebt echt rust en regelmaat gebracht in het leven van de kinderen en daarmee in het onze. Altijd sta je voor ons klaar, vaak met een heerlijk bordje eten na een lange drukke dag. Bedankt voor alles, we hopen dat je nog lang bij ons wilt blijven.

Lieve Thijs, Jade, Leon, Sharita, Cas en Julia. Ik had mij geen betere zwagers en schoonzussen kunnen wensen. Bedankt voor de vele avonden vol slechte verhalen en goede wijn, BBQ's met only charcoal -no wood-, tafeltennistafels en pokerspellen. Beste Theo en Paula, bedankt

voor jullie gezelligheid en levenslessen. Met tranen in mijn ogen van het lachen heb ik twee hooggeleerden zien stoeien met het aanmaken van een BBQ. Gelukkig heb ik naderhand ook jullie iets kunnen bijbrengen! Lieve Lily, jij bent ondertussen bijna de belangrijkste spil binnen ons gezin. Bedankt voor al je liefde, gezelligheid en bereidheid om altijd en onvoorwaardelijk voor ons klaar te staan.

Lieve Wouter, Marie-Claire, Sophie en ons pasgeboren neefje Olivier. Ondanks dat jullie nu nog verder weg wonen in jullie kasteel aan de golfbaan, zien we elkaar gelukkig met regelmaat. Jullie hebben een prachtig gezin, we vinden erg het fijn om samen te zijn en leuke herinneringen te maken!

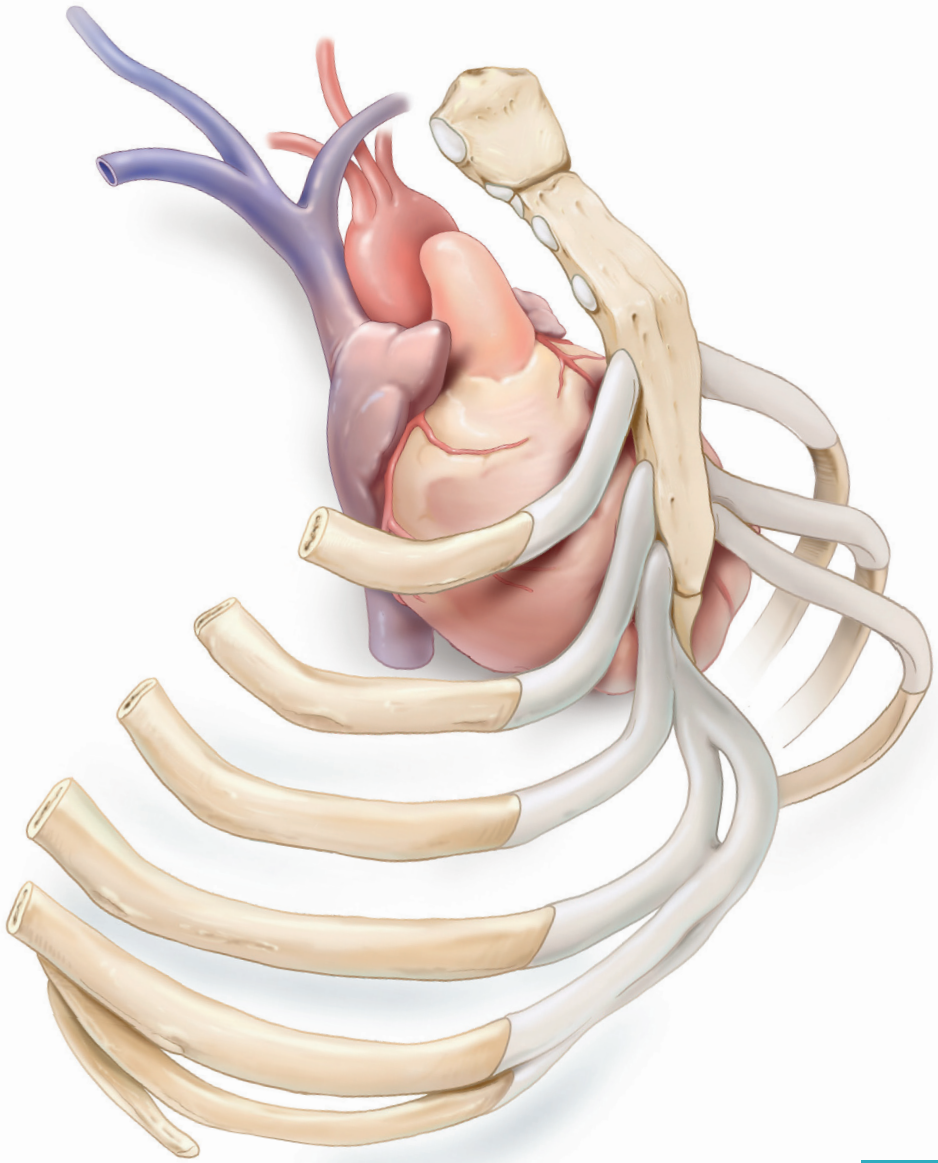
Dan mijn ouders, lieve papa en mama. Zonder jullie nimmer aflatende steun, liefde en vertrouwen was ik niet de persoon geworden die ik nu ben. Doe maar normaal, dan doe je al gek genoeg was het devies. Jullie opvoeding heeft mij geleerd dat het leven een vat vol keuzes en kansen is en jullie steun heeft mij hierin een vliegende start gegeven. Pap, ik had dit dankwoord eigenlijk al geschreven voordat je recent, niet geheel onverwachts maar toch vrij plotseling, overleed. Wat had ik je graag aan mijn zijde gehad tijdens de verdediging van dit proefschrift. En wat zou je trots zijn geweest. Aanvankelijk had je je bedenkingen bij mijn "keuze" (lees: noodlot) voor een studie Geneeskunde in Maastricht. De woorden van mijn klassenleraar op de middelbare school ("Loos, als jij naar Maastricht gaat, eindig je in de goot") zullen daar waarschijnlijk ook wel wat aan hebben bijgedragen. Toch is het uiteindelijk allemaal een soort van goed gekomen en heb je het met een gerust hart kunnen achterlaten! Lieve mama, wat ben je toch een schat. Je staat altijd klaar voor iedereen, onvoorwaardelijk. Je brengt en houdt onze familie echt bij elkaar. Alle leuke activiteiten die je organiseert, van ergens een hapje eten tot de vele weekendjes en weekjes weg. Met eindeloos geduld speel je urenlang met je kleinkinderen. Je kunt zo intens genieten van een avondje kletsen, aan de telefoon, samen aan de keukentafel met een biertje of voor de open haard met een glas wijn. En van heerlijke vakanties met ons in bella Italia. Jouw liefde voor ons is echt onbeschrijflijk en niet in woorden uit te drukken. Bedankt voor alles.

Er zijn al veel personen genoemd in de bovenstaande regels. Chirurgie is een prachtig vak en in praktijk vaak meer een way of living dan een baan. Toch zijn het uiteindelijk de dingen buiten het ziekenhuis waar het écht om draait. Wat is het toch heerlijk om deel uit te maken van mijn fijne, liefdevolle en hechte gezin. Ik kan er intens van genieten om samen te zijn. Met als absolute hoogtepunt de vele vakanties: auto volgeladen, deur op slot, hoofd leeg en lekker op weg naar Zuid-Europa of de bergen. Even voor een paar weken de rest van de

wereld vergeten.

Lieve Tijmen en Flore, wat is het een genot om jullie te zien opgroeien. En wat gaat die tijd toch snel. De eerste keer jullie luier verschonen voelt nog als de dag van gisteren. Tijmen, wat ben je toch een heerlijk ventje. Ondertussen al bijna 8. Vol overgave bouw je van alles en nog wat van Lego en ben je continu in de weer. Er is geen boom meer in de buurt waarin je niet geklommen hebt. En tegenwoordig moet ik achter jou aan skiën... En Flore, ook jij bent al bijna 5 en al een echt dametje. Alles roze, vol met glitters. De ene dag ben je een prinses, de andere een ballerina. Een eigen willetje en al stellig over je toekomst. Acht kinderen en bij de Jumbo werken, we gaan het zien!

Lieve Sanne. Het is niet in woorden uit te drukken en al zeker niet in de laatste zinnen van dit dankwoord te vatten. Bedankt voor je grenzeloze liefde en steun. Ik heb er diep respect voor hoe het je, ogenschijnlijk nauwelijks moeite kostend, altijd lukt om vrolijk te zijn en voor alles en iedereen klaar te staan. Zonder jou zou het me niet lukken om alle ballen op mijn werk en daaromheen in de lucht te houden en al zeker niet gelukt zijn om daarnaast dit proefschrift af te ronden. Bedankt dat je er altijd voor me bent en voor me klaarstaat. Ik hou van jou!



14

About the author

List of publications

Curriculum vitae

LIST OF PUBLICATIONS

Geraedts TCM, Daemen JHT, Vissers YLJ, Hulsewé KWE, van Veer HG, Abramson H, **de Loos ER**. Minimally invasive repair of pectus carinatum by the Abramson procedure: a systematic review of six studies. *J Pediatr Surg*. (accepted).

Laven IEWG, Daemen JHT, Janssen N, Hulsewé KWE, Gronenschild MRM, Vissers YLJ, **de Loos ER**. Can chest tubes be omitted after VATS wedge resections? *Innovations (Phila)*. (accepted).

Willems S, Daemen JHT, Hulsewé KWE, Belgers EHJ, Sosef MN, Soufidi K, Vissers YLJ, **de Loos ER**. Outcomes after hybrid minimally invasive treatment of Boerhaave syndrome: a single-institution experience. *Acta Chir Belg*. 2022 (epub ahead of print).

Janssen N, Laven IEWG, Daemen JHT, Hulsewé KWE, Vissers YLJ, **de Loos ER**. Negative pressure wound therapy for massive subcutaneous emphysema: a systematic review and case series. *J Thorac Dis*. 2022;14(1):43-53.

Daemen JHT, Loonen TGJ, Verhulst AC, Maal TJJ, Maessen JG, Vissers YLJ, Hulsewé KWE, **de Loos ER**. Three-dimensional surface imaging of the anterior chest wall: a comparison between three different imaging systems. *J Surg Res*. 2021;259:332-341.

Ji Y, Zhang T, Yang L, Wang X, Qi L, Tan F, Daemen JHT, **de Loos ER**, Qiu B, Gao S. The Effectiveness of Three-Dimensional Reconstruction in the Localization of Multiple Nodules in Lung Specimens: a prospective cohort study. *Transl Lung Cancer Res*. 2021;10(3):1474-1483.

Bakens MJAM, Andel PCM, Daemen JHT, Hulsewé KWE, Vissers YLJ, **de Loos ER**. A case series: xiphoidectomy for xiphodynia, a rare thoracic wall disorder. *J Thorac Dis*. 2021;13(4):2216-2223.

De Loos ER, Andel PCM, Daemen JHT, Maessen JG, Hulsewé KWE, Vissers YLJ. Safety and feasibility of rigid fixation by SternaLock Blu plates during the modified Ravitch procedure: a pilot study. *J Thorac Dis*. 2021;13(5):2952-2958.

Coorens NA, Daemen JHT, Slump, CH; Loonen TGJ, Vissers YLJ, Hulsewé KWE, **de Loos ER**. The automatic identification and quantification of morphological pectus excavatum features based on three-dimensional images. *Semin Thorac Cardiovasc Surg*. 2021 (epub ahead of print).

Daemen JTH*, **de Loos ER***, Geraedts TCM, van Veer H, van Huijstee PJ, Elenbaas TWO, Hulsewé KWE, Vissers YLJ. Visual diagnosis of pectus excavatum: an intra-observer and inter-observer agreement analysis. *J Pediatr Surg.* 2021 (epub ahead of print).

De Loos ER, Daemen JHT, Coorens NA, Maessen JG, Vissers YLJ, Hulsewé KWE. Sternal elevation by the crane technique during pectus excavatum repair: a quantitative analysis. *JTCVS Tech.* 2021 Jul 17;9:167-175.

Olsthoorn JR, Daemen JHT, **de Loos ER**, ter Woorst JF, van Straten AHM, Maessen JG, Sardari Nia P, Heuts S. A minimally invasive approach versus full sternotomy for resection of benign atrial masses: a systematic review and meta-analysis of observational studies. *Innovations (Phila.)* 2021 Sep-Oct;16(5):426-433.

Daemen JHT, Coorens NA, Hulsewé KWE, Maal TJJ, Maessen JG, Vissers YLJ, **de Loos ER**. Three-dimensional surface imaging based severity measures for clinical decision making in pectus excavatum: a diagnostic accuracy study. *Semin Thorac Cardiovasc Surg.* 2021 (epub ahead of print).

Lozekoot PWJ, Tegels JJW, van Vugt R, **de Loos ER**. Bone suture anchor repair and functional outcome of a triceps tendon rupture, a rare clinical entity. *BMJ Case Rep.* 2021 Jul 27;14(7):e241773.

De Loos ER*, Pennings AJ*, van Roozendaal LM, Daemen JHT, van Gool MH, Lenderink T, van Horck M, Hulsewé KWE, Vissers YLJ. Nuss procedure for pectus excavatum: a comparison of complications between young and adult patients. *Ann Thorac Surg.* 2021;112(3):905-911.

De Loos ER, Daemen JHT, Janssen N, Hulsewé KWE, Vissers YLJ. Suture anchor repair of pectoralis major muscle dehiscence after modified Ravitch. *Innovations (Phila.)* 2021;16(5):485-487.

Lozekoot PWJ, Daemen JHT, van den Broek RR, Maessen JG, Gronenschild MHM, Vissers YLJ, Hulsewé KWE, **de Loos ER**. Video-assisted mediastinoscopic lymphadenectomy is superior to video-assisted mediastinoscopy for surgical mediastinal lymph node staging of non-small-cell lung carcinoma. *Transl Lung Cancer Res.* 2021;10(8):3643-3658.

Zonnebeld N, Broos PPHL, Engelen SME, Vissers YLJ, **de Loos ER**. Pneumomediastinum in late pregnancy: a case report and review of the literature. *Acta Chir Belg.* 2021 (epub ahead of print).

Moosdorff M, Maesen B, Den Uijl D, Lenderink T, Franssen F, Vissers YLJ, **de Loos ER**. Ventricular fibrillation provoked by forward-bending maneuver in an adolescent with severe pectus excavatum. *Eur Heart J Case Rep*. 2021;5(10):1-6.

Daemen JHT, Hulsewé KWE, Vissers YLJ, **de Loos ER**. Uniportal VATS right apical segmentectomy (S1): a case report and the surgical technique. *J Vis Surg*. 2021 (epub ahead of print).

Daemen JHT, Vissers YLJ, Hulsewé KWE, **de Loos ER**. Editorial commentary: Journey towards the least invasive form of thoracic surgery? *Trans Lung Cancer Res*. 2021;10(10):4027-4028.

Stassen RC, Jeuken JM, Boonen B, Meesters B, **de Loos ER**, van Vugt R. First clinical experience with the femoral neck system for internal fixation of femoral neck fractures. *Arch Orthop Trauma Surg*. 2021 (epub ahead of print).

Daemen JTH, Heuts S, Ardabili AR, Maessen JG, Hulsewé KWE, Vissers YLJ, **de Loos ER**. Development of a prediction model for cardiac compression in pectus excavatum based on three-dimensional images. *Semin Thorac Cardiovasc Surg*. 2021 (epub ahead of print).

Geraedts TCM, Daemen JHT, Vissers YLJ, **de Loos ER**. VATS assisted surgical rib fixation for costochondral separation injury: a case report. *Innovations (Phila.)* 2021 (epub ahead of print).

Wang L, Yan X, Zhao J, Chen C, Chen C, Chen J, Chen K-N, Cao T, Chen M-W, Duan H, Fan J, Fu J, Gao S, Guo H, Guo S, Guo W, Han Y, Jiang G, Jiang H, Jiao W-J, Kang M, Leng X, Li H-C, Li J, Li J, Li S-M, Li S, Li Z, Li Z, Liang C, Mao N-Q, Mei H, Sun D, Wang D, Wang L, Wang Q, Wang S, Wang T, Liu L, Xiao G, Xu S, Yang J, Ye T, Zhang G, Zhang L, Zhao G, Zhao J, Zhong W-Z, Zhu Y, Hulsewé KWE, Vissers YLJ, **de Loos ER**, Jeong JY, Marulli G, Sandri A, Sziklavari Z, Vannucci J, Ampollini L, Ueda Y, Liu C, Bille A, Hamaji M, Aramini B, Inci I, Pompili C, Van Veer H, Fiorelli A, Sara R, Sarkaria IS, Davoli F, Kuroda H, Bölükbas S, Li X-F, Huang L, Jiang T. Expert consensus on resection of chest wall tumors and chest wall reconstruction. *Transl Lung Cancer Res*. 2021;10(11):4057-4084.

Vissers YLJ, Hulsewé KWE, **de Loos ER**. Hoofdstuk 27: Een man met aanhoudende hoestklachten. In: *Probleemgeoriënteerd denken in de chirurgie*. Utrecht: De Tijdstroom, 2021 (in press).

Schots JPM, van Laarhoven SN, Hustinx PA, Pijnenburg AM, Meesters B, **de Loos ER**. Surgical treatment of acromioclavicular dislocation associated with midshaft fracture of the ipsilateral clavicle. *Acta Orthop. Belg.* 2020(86):532-538.

De Loos ER*, Daemen JHT*, Pennings AJ, Maessen JG, Hulsewé KWE, Vissers YLJ. Minimally invasive repair of pectus excavatum by the Nuss procedure: the learning curve. *J Thorac Cardiovasc Surg.* 2020 (epub ahead of print).

Daemen JHT*, **de Loos ER***, Vissers YLJ, Bakens MJAM, Maessen JG, Hulsewé KWE. Intercostal nerve cryoablation versus thoracic epidural for postoperative analgesia following pectus excavatum repair: a systematic review and meta-analysis. *Interact CardioVasc Thorac Surg.* 2020;31(4):486-498.

Daemen JHT, van den Broek R, Lozekoot PWJ, Maessen JG, Hulsewé KWE, Vissers YLJ, **de Loos ER**. The learning curve of video-assisted mediastinoscopic lymphadenectomy for staging of non-small cell lung carcinoma. *Interact CardioVasc Thorac Surg.* 2020;31(4):527-535.

Geraedts ACM, Broos PPHL, Gronenschild MHM, Custers FHL, Hulsewé KWE, Vissers YLJ, **de Loos ER**. Minimally invasive approach to esophageal perforation after EUS-FNA: report of two cases. *KJTCVS* 2020;53(5):313-316.

Daemen JHT, Loonen TGJ, Coorens NA, Maessen JG, Maal TJJ, Hulsewé KWE, Vissers YLJ, **de Loos ER**. Photographic documentation and severity quantification of pectus excavatum through three-dimensional optical surface imaging. *J Vis Commun Med.* 2020;43(4):190-197.

De Loos ER, Hulsewé KWE, Van Loo ERJ, Kragten JA, Höppener PF, Busari JO, Vissers YLJ. Does the use of locking plates or mesh and wires influence the risk of symptomatic non-union of the sternal osteotomy after modified Ravitch? *J Thorac Dis.* 2020;12(7):3631-3639.

Van de Pas JM, van Roozendaal LM, Custers F, Wanders R, Vissers YLJ, **de Loos ER**. Bronchopleural fistula after chemoradiation. *Adv Radiat Oncol.* 2020;5(3):511-515.

De Loos ER, Höppener PF, Busari JO, Kragten JH, Hulsewé KWE, Vissers YLJ. Trechterborst: niet alleen een cosmetisch probleem. *Ned Tijdschr Geneeskd.* 2020;164:D4509.

Van Middendorp LB, Franssen S, Gillissen S, Maessen JG, Hulsewé KWE, Vissers YLJ, **de Loos ER**. Uniportal video-assisted thoracoscopy is a safe approach in patients with empyema requiring surgery. *J Thorac Dis.* 2020;12(4):1460-1466.

Daemen JHT, Loonen TGJ, Lozekoot PWJ, Maessen JG, Maal TJJ, Hulsewé KWE, Vissers YLJ, **de Loos ER**. Optical imaging versus CT and plain radiography to quantify pectus severity: a systematic review and meta-analysis. *J Thorac Dis*. 2020;12(4):1475-1487.

Claassen L, Franssen MA, **de Loos ER**. A rare case of hemorrhagic shock: Morel-Lavalée lesion. *Clin Pract Cases Emerg Med*. 2019;3(4):417-420.

Wijffels MME, Prins JTH, Polinder S, Blokhuis TJ, **de Loos ER**, Den Boer RH, Flikweert ER, Pull Ter Gunne AF, Ringburg AN, Spanjersberg WR, Van Huijstee PJ, Van Montfort G, Vermeulen J, Vos DI, Verhofstad MHJ, Van Lieshout EMM. Early fixation versus conservative therapy of multiple, simple rib fractures (FixCon): protocol for a multicenter randomized controlled trial. *World J Emerg Surg*. 2019 Jul 30:14-38.

Daemen JHT, Lozekoot PWJ, Maessen JG, Gronenschild MHM, Bootsma GP, Hulsewé KWE, Vissers YLJ, **de Loos ER**. Chest tube drainage versus video-assisted thoracoscopic surgery for first episode of primary spontaneous pneumothorax: a systematic review and meta-analysis. *Eur J Cardiothorac Surg*. 2019 Nov 1;56(5):819-829.

Van de Pas JM, Van der Woude MCE, Belgers HJ, Hulsewé KWE, **de Loos ER**. Bronchus Perforation by EZ-Blocker Endobronchial Blocker During Esophageal Resection After Neoadjuvant Chemoradiation. *Korean J Anesthesiol*. 2019 Apr;72(2):184-187.

Van de Pas JM, Tegels JJW, van Vugt R, Vissers YLJ, **de Loos ER**. Posture-dependent thoracic outlet syndrome due to a dorsally and inferiorly angulated clavicle fracture. *ANZ J Surg*. 2019 Oct;89(10):E474-E475.

Van Roozendaal LM, van Gool HM, Sprooten RTM, Maesen BAE, Poeze M, Hulsewé KWE, Vissers YLJ, **de Loos ER**. Surgical treatment of bronchial rupture in blunt chest trauma: a review of literature. *J Thorac Dis*. 2018 Sept;10(9):5576-5583.

De Mooij K, Bakens M, **de Loos E**, Stoot J. A common procedure with a rare anatomical finding: a case report on a true left-sided gallbladder. *J Vis Surg*. 2018;4:192.

Van Middendorp LB, van Veer HG, Hulsewé KWE, Vissers YLJ, **de Loos ER**. Abramson procedure voor de behandeling van pectus carinatum: eerste ervaringen in Nederland. *Nederlands Tijdschrift voor Heelkunde*. 2018 Sept;27(5):28-31.

Handels N, Kragten J, **de Loos ER**, Höppener P. Long-term results following surgical correction of symptomatic pectus excavatum in seniors. Considerable improvement of cardiovascular function and quality of life. *Ital J Vasc Endovasc Surg*. 2017 Dec;24(4):131-6.

Van Laarhoven SN, Latten G, **de Loos E**, van Hemert W, Vles GF. Annual load of the world's largest indoor skiing center. *Eur J Trauma Emerg Surg*. 2017 Apr;43(2):233-7.

Schots JPM, Vissers YLJ, Hulsewé KWE, Meesters B, Hustinx PA, Pijnenburg A, Siebenga J, **de Loos ER**. Addition of video-assisted thoracoscopic surgery to the treatment of flail chest. *Ann Thoracic Surg*. 2017 Mar;103(3):940-44.

Brokx HAP, **de Loos ER**, de Jong M, Bootsma G, Hulsewé KWE, Siebenga J. Uniportal VATS (u-VATS) lobectomy voor de behandeling van longkanker. *Nederlands Tijdschrift voor Heelkunde*. 2015;24(5):36-7.

Ten Bosch JA, Willigendael EM, Kruidenier LM, **de Loos ER**, Prins MH, Teijink JA. Early and mid-term results of a prospective observational study comparing emergency endovascular aneurysm repair with open surgery in both ruptured and unruptured acute abdominal aortic aneurysms. *Vascular*. 2012;20(2):72-80.

Ten Bosch JA, Willigendael EM, van Sambeek MR, **de Loos ER**, Prins MH, Teijink JA. EVAR suitability is not a predictor for early and midterm mortality after open ruptured AAA repair. *Eur J Vasc Endovasc Surg*. 2011;41(5):647-51.

De Loos ER, Lim RF, Teijink JAW. Endovascular Aortic Occlusion for a Secondary Aorto-Enterocutaneous Fistula: 44-Month Follow-up. *J Endovasc Ther*. 2008;15(2):237-240.

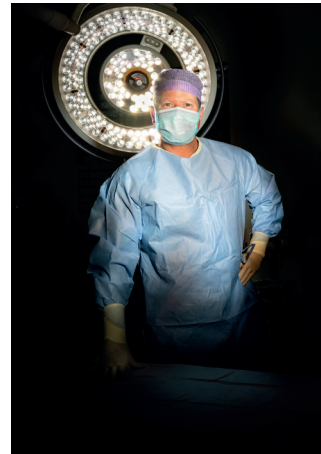De Loos ER, de Ploeg IH, Bollen ECM, Welten RJThJ, Teijink JAW. Screening naar aneurysmata van de aorta abdominalis. *Patiënt Care* 2006;4:27-31.

De Loos ER, Geerdink CH, Heyligers IC, Hustinx PA, Meesters B. Geïsoleerde dislocaties van het proximale tibio-fibulaire gewricht. *Ned Tijdschr Traum*. 2005;6:182-6.

De Loos ER, Teijink JAW, Moll FL. Een minimaal invasieve techniek voor de behandeling van perifeer arterieel vaatlijden: remote endarteriëctomie met behulp van de Ring Strip Cutter. *Nederlands Tijdschrift voor Hart en Vaatverpleegkundigen Cordiaal* 2004;3:4-7.

CURRICULUM VITAE

Erik de Loos (1980) was born and raised in Pijnacker, at the time a small village near Rotterdam. He attended high school at Sint Stanislas college in Delft. In 1997 he moved to Maastricht to study medicine at Maastricht University, where he graduated with a cum laude degree in 2003. He attended his general surgical training with a subspeciality in trauma surgery at the Atrium medical center in Heerlen (prof. dr. C.J. van der Linden[†], dr. R.J.Th.J. Welten and dr. M.N. Sosef) and Maastricht University Medical Center (prof. dr. J.W.M. Greve and prof. dr. C.H.C. Dejong). After finishing training in 2011,



he joined Maatschap Heelkunde Zuid-Limburg to start as a staff surgeon at the currently named Zuyderland medical center (merger between Atrium medical center in Heerlen and Orbis medical center in Sittard-Geleen). After a post-graduate training in general thoracic surgery (dr. J. Siebenga), he is also certified as a general thoracic surgeon. His special interests are minimal invasive thoracic surgery (uniportal VATS), chest wall surgery (pectus, trauma and oncology), and the treatment of pelvic and acetabular injuries.

Since 2015, he is vice-chair of the general surgical training programme and chair of the thoracic surgical training programme at Zuyderland medical center. He is actively involved in numerous national and international courses in the field of minimal invasive thoracic surgery, chest wall surgery and trauma surgery. He is a certified Advanced Trauma Life Support (ATLS) course director and board member of the Dutch ATLS society on behalf of the Dutch association for trauma surgery (NVT).

Erik is married to Sanne de Loos-Engelen, an oncological and gastro-intestinal surgeon at Maastricht University Medical Center. They live in Cadier en Keer and are proud parents of Tijmen (2014) and Flore (2017).