


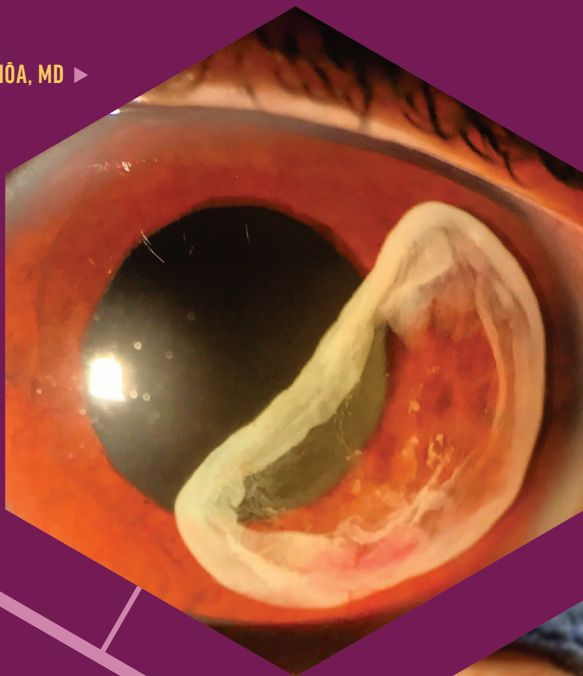
# 2021 Winners

## CRST'S ANNUAL

**BEATRICE KNOWLES UCHÔA, MD ▶**

### **Capsular Bag in Anterior Chamber**

This image shows the capsular bag in the anterior chamber of an eye with a history of trauma and surgery.

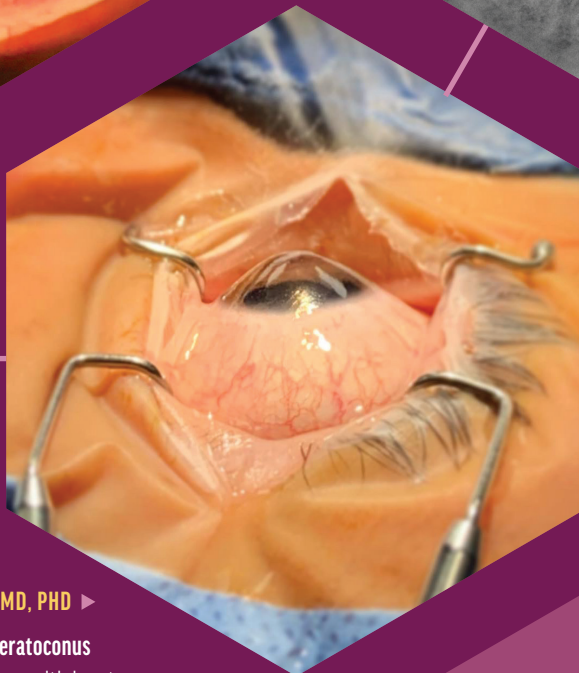


Interesting  
and  
Artistic

**▲ AARTI HEDA, DNB, MRCS, FCRS, FICO**

### **Life in Circles**

This is a photograph of the eye of a patient who presented for a dry eye evaluation with a dry eye analyzer.



**DANIEL WASILEWSKI, MD, PHD ▶**

### **The Last Moments of Keratoconus**

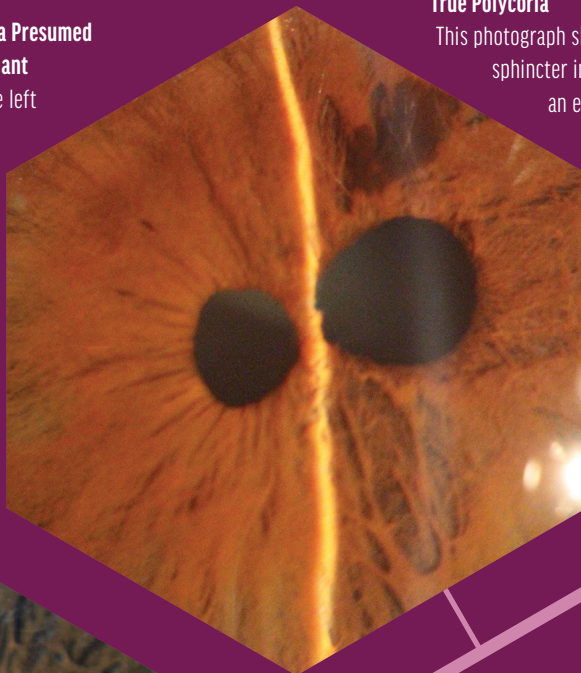
This photograph of an eye with keratoconus was taken just before corneal transplantation.

# PHOTO CONTEST

▼ **ABDELRAHMAN M. ELHUSSEINY, MD, MSC, AND HAJIRAH N. SAEED, MD**

## **Corneal Stromal Deposits in a Presumed Ehlers Danlos Syndrome Variant**

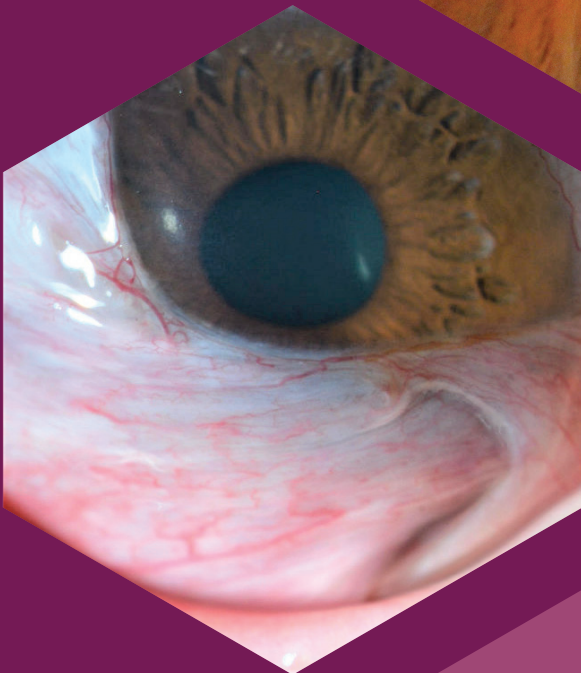
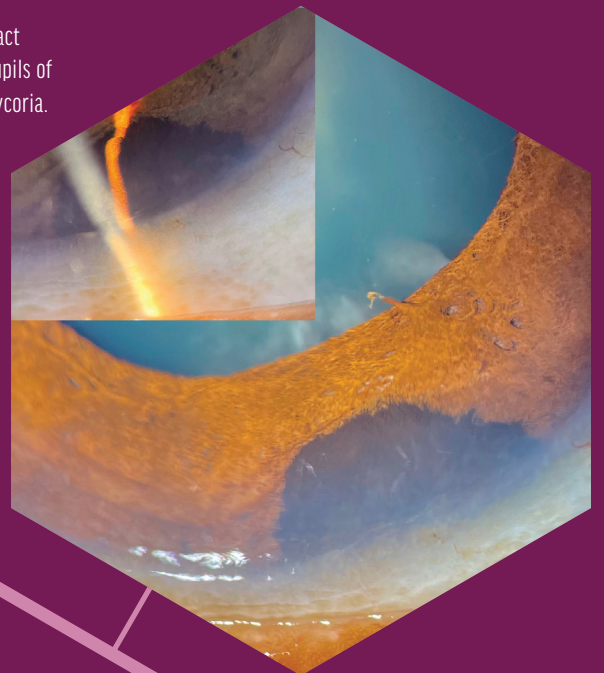
A slit-lamp photograph of the left eye of a patient with a presumed Ehlers Danlos syndrome variant shows superior refractile whitish-brown corneal deposits—a finding that has never been reported to the contributing physicians' knowledge—and a temporal pseudopterygium from the 2 to 8 clock positions.



▼ **ZAHRA KARJOU, MD**

## **True Polycoria**

This photograph shows an intact sphincter in the two pupils of an eye with polycoria.



## Rare and Unusual Diseases

▲ **AMIT MISHRA, MD**

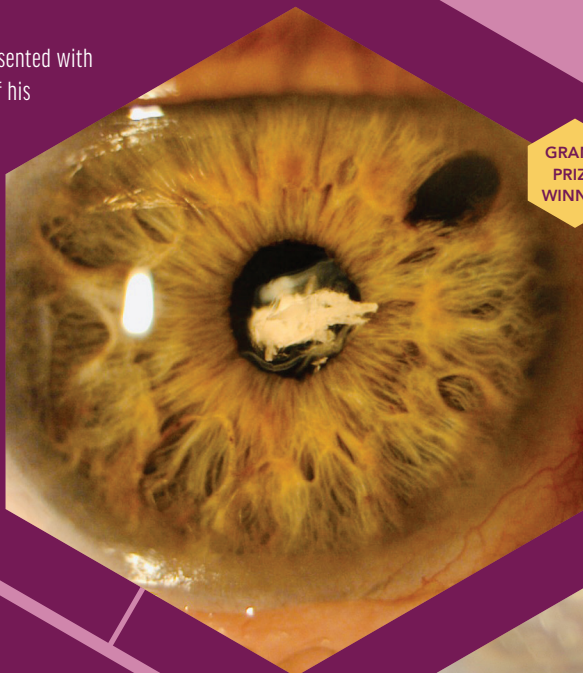
## **Iris Melanocytoma**

This image shows an incidental finding of melanocytoma of the iris in a 14-year-old patient who presented for a routine eye exam. A raised cobblestone appearance and slight pupillary distortion are evident.

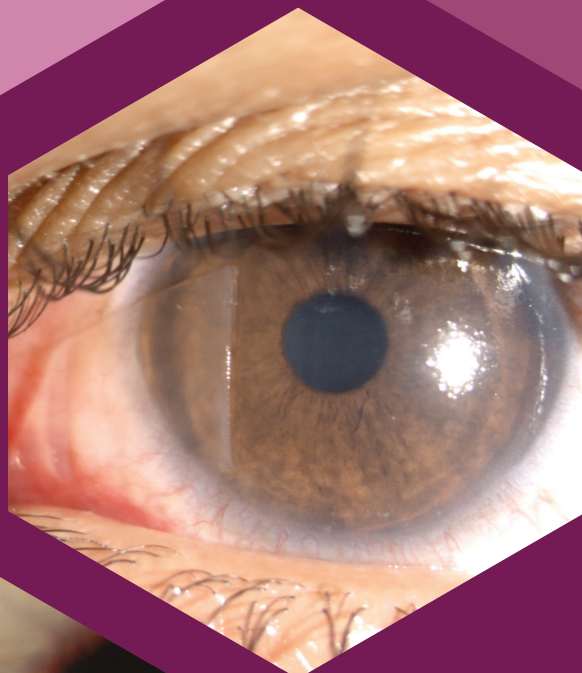**MATTHEW FENG, MD** ▼

### Enter the Dragon

A 68-year-old man presented with draconic dislocation of his right residual lens capsule and Soemmering ring, both prolapsing out from the pupil. He had undergone pars plana vitrectomy, scleral buckle, and a sutured IOL followed by IOL repositioning 10 years later.



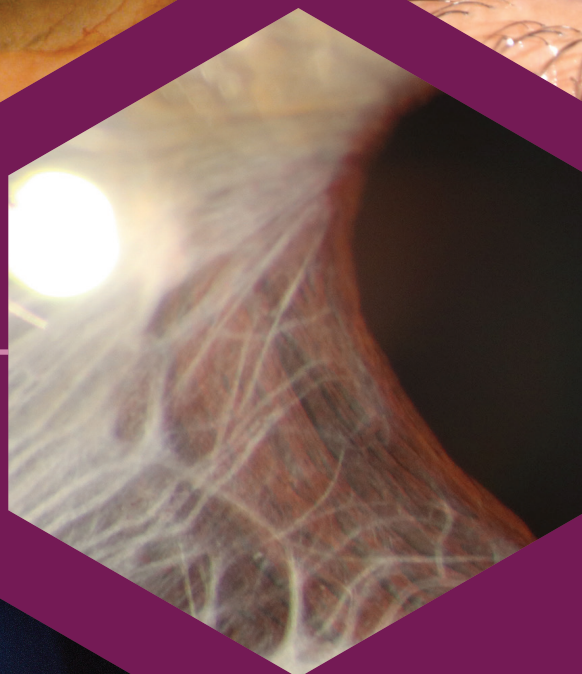
GRAND PRIZE WINNER



▲ **ANUJA DESAI, MS**

### Flap Bummer

This slit-lamp photograph was taken 1 day after an uneventful LASIK procedure using a corneal flap with a nasal hinge. The patient had unknowingly rubbed his eye in his sleep.

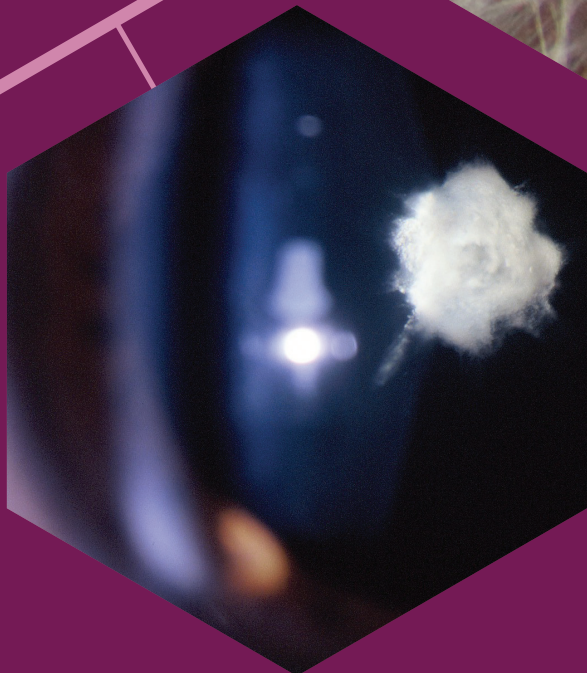

◀ **DMYTRO MARTYNOV, MD**

### Postuveal Iridoschisis

This is a photograph of a patient with postuveal iridoschisis resulting from chronic anterior uveitis with intermittent exacerbations.

Slit Lamp



◀ **C. MANUEL NICOLI, MD**

### Ocular Popcorn

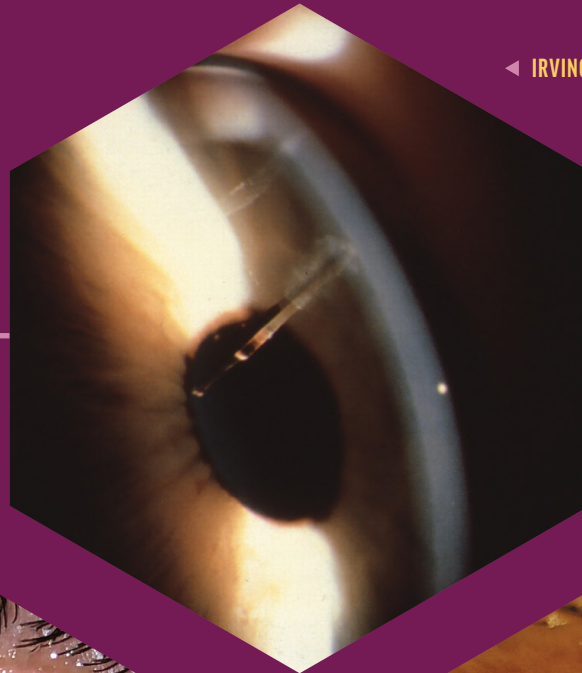
This photograph shows a posterior polar cataract that resembles popcorn.

**MANAS NATH, MBBS, DO, FAICO, FAEH** ▶

### Decentered IOL With Crumpled Capsular Bag

This image shows a decentered rigid one-piece IOL temporarily (yellow arrow), temporal zonular dehiscence, and a crumpled capsular bag (blue arrows) after an intraoperative complication.

# Trauma



◀ IRVING M. RABER, MD, AND THOMAS TIEN, MD

## Too Close for Comfort

This is a photograph of a glass fragment embedded in the cornea after a motor vehicle accident. The fragment extended into the anterior chamber and stopped just short of the anterior lens capsule.

▼ SASHWANTHI MOHAN, DNB, MRCS

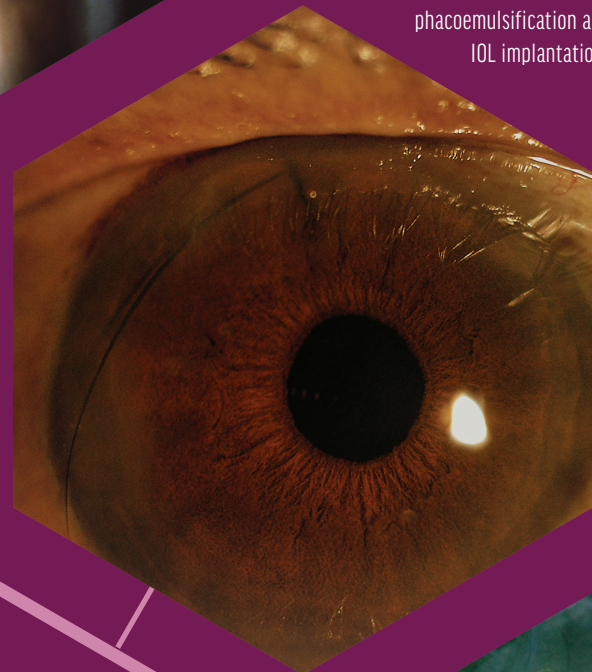
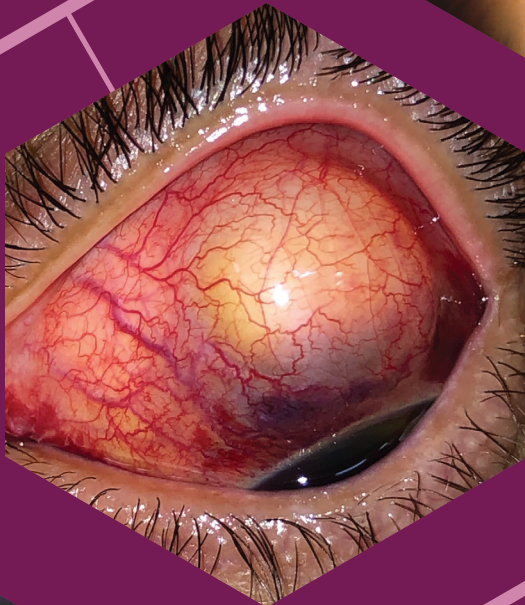## Lash in the Anterior Chamber

In this slit-lamp image, an eyelash in the anterior chamber protrudes out of a corneal sideport incision after phacoemulsification and IOL implantation.

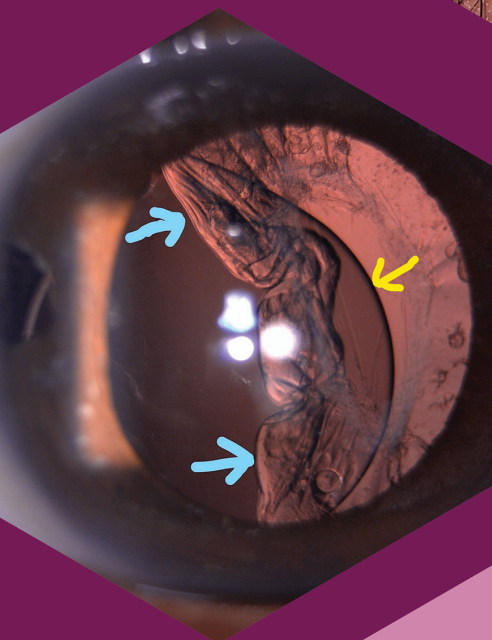
GABRIEL CASTILHO  
S. BARBOSA, MD ▶

## Traumatic Phacocele

This photograph shows a traumatic phacocele. In the image, the superior and nasal conjunctiva evinces a well-defined, elevated subconjunctiva with a yellow-orange mass underneath featuring the herniated lens.



# Surgical Complications



JOHN MOULD, BA, BVSC, DVOPHTHAL, FHEA, MRCVS ▶

## Vacuoles

This photograph shows an IOL, capsular opacity, and lens epithelial cell regrowth against the tapetal reflex after phacoemulsification in a dog.

