



PRECOCIOUS PUBERTY

Jasmine Gujral, MD
Pediatric Endocrinology
7/20/2020

Puberty: “a child becomes a young adult”

maturation of
gametogenesis

secretion of
gonadal
hormones

development of
secondary sexual
characteristics

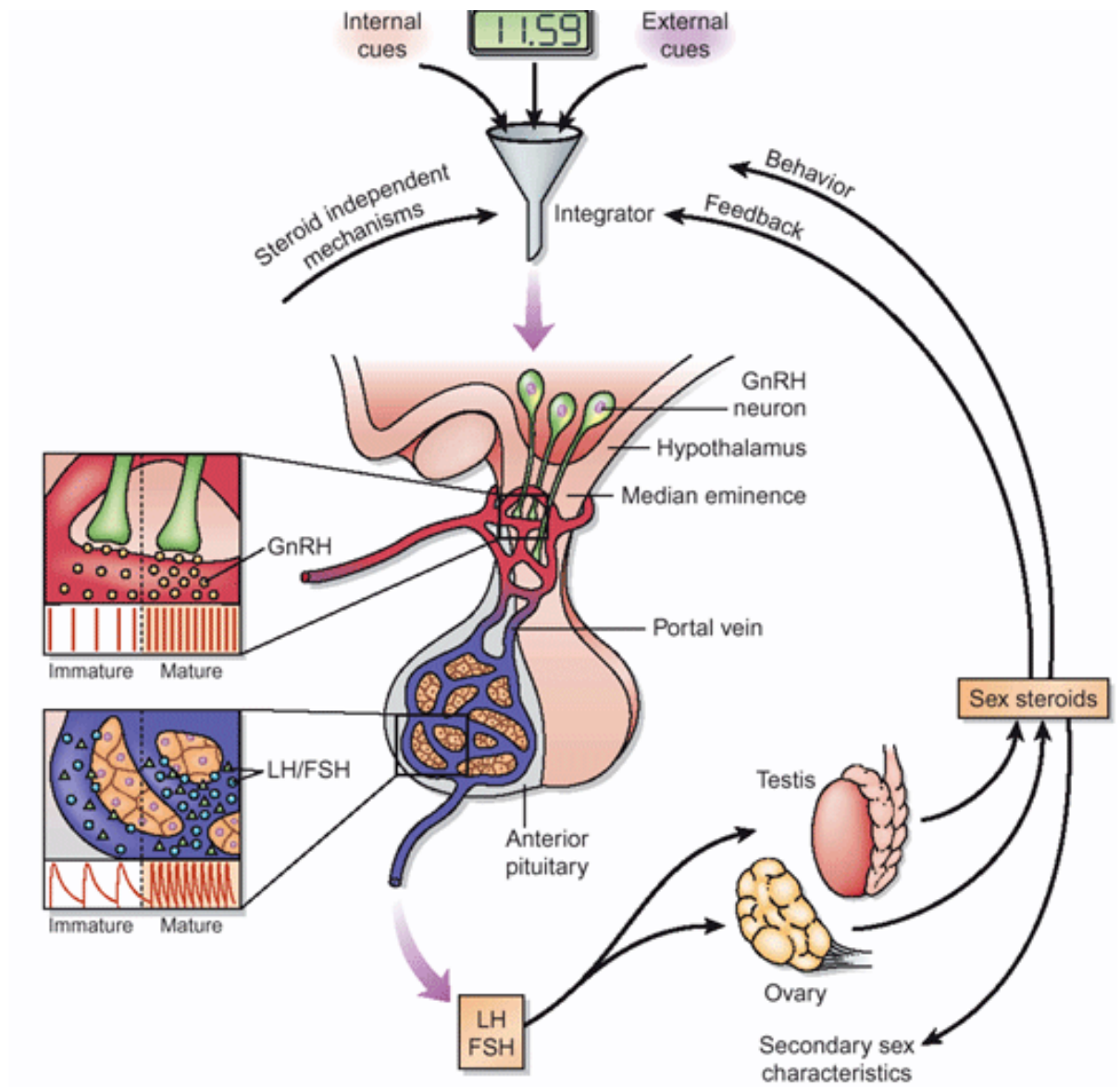
development of
reproductive
functions

Pubertal Definitions

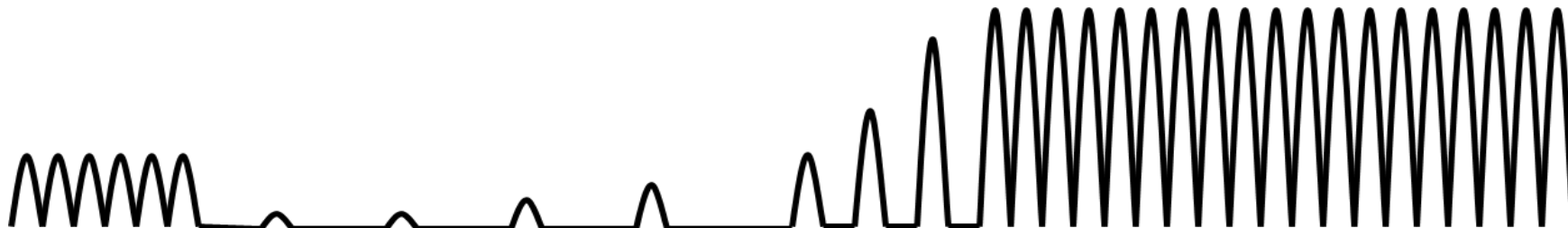
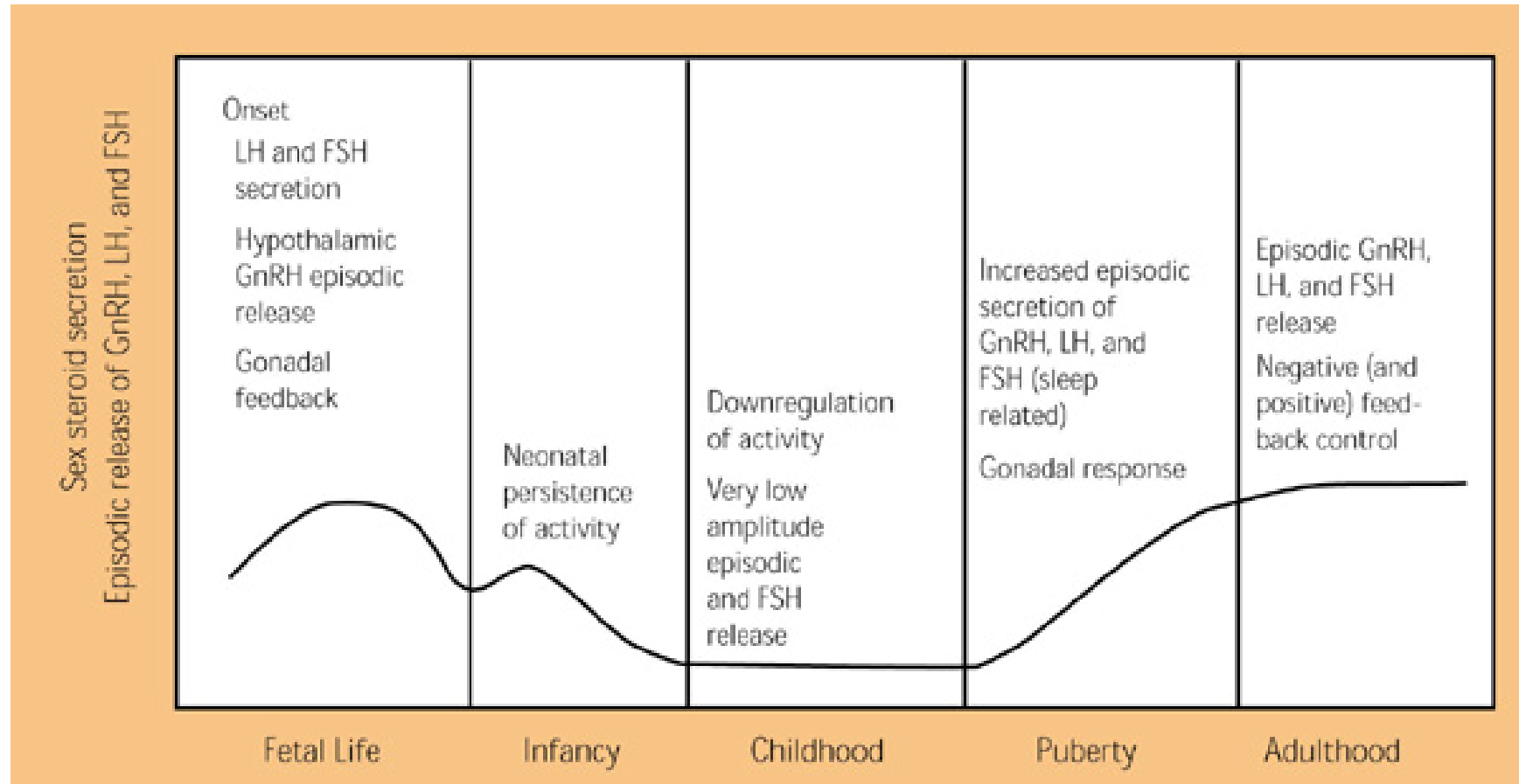
- **Thelarche:** onset of breast, an estrogen effect
- **Pubarche:** onset of sexual hair, an androgen effect
- **Adrenarche:** onset of the adrenal androgen production that contributes to pubarche
- **Menarche:** onset of menses
- **Spermarche:** appearance of spermatozoa in seminal fluid
- **Gonadarche:** onset of pubertal function of the gonads, which produce most of the sex hormones that underlie the pubertal changes in secondary sex characteristics.



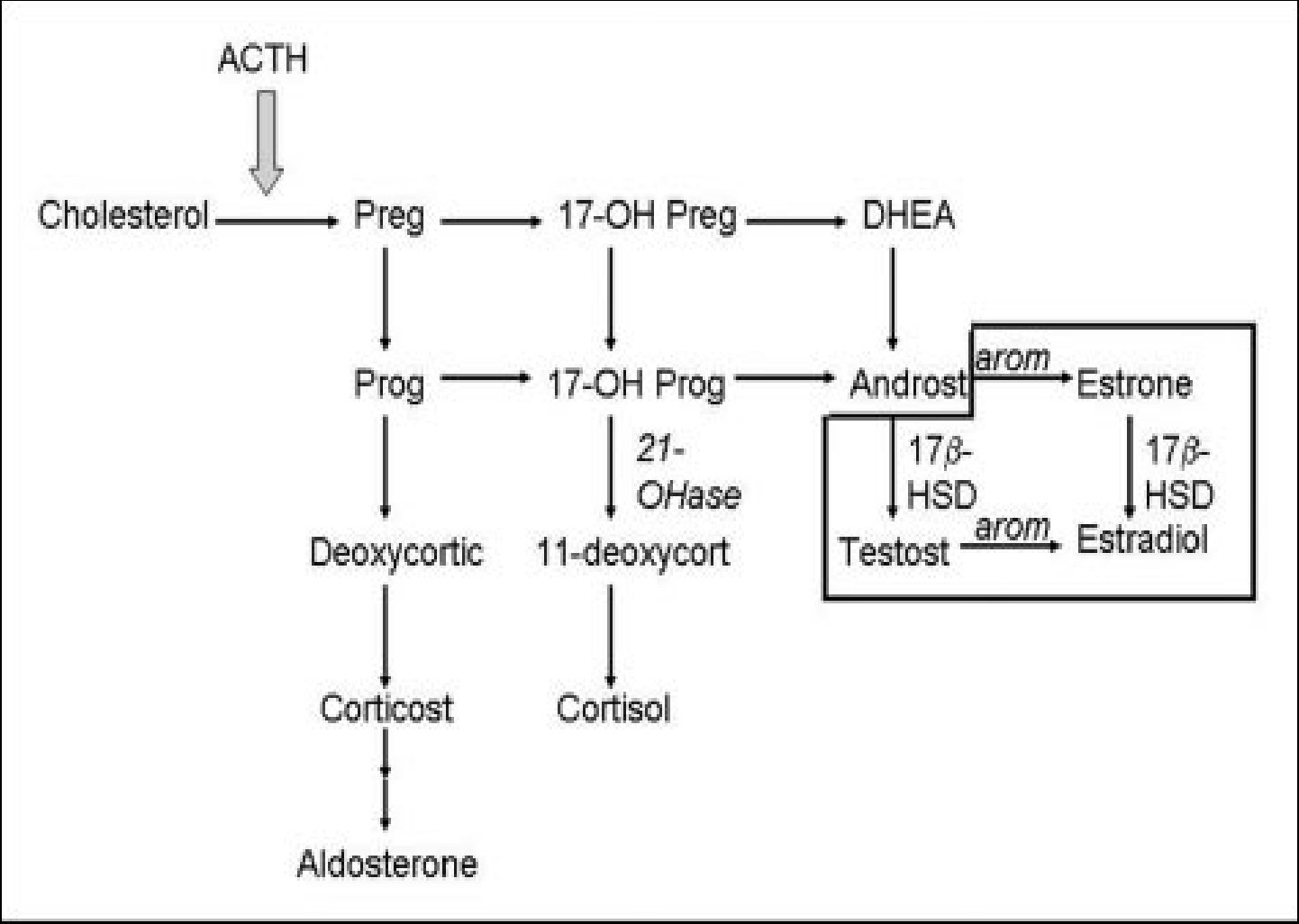
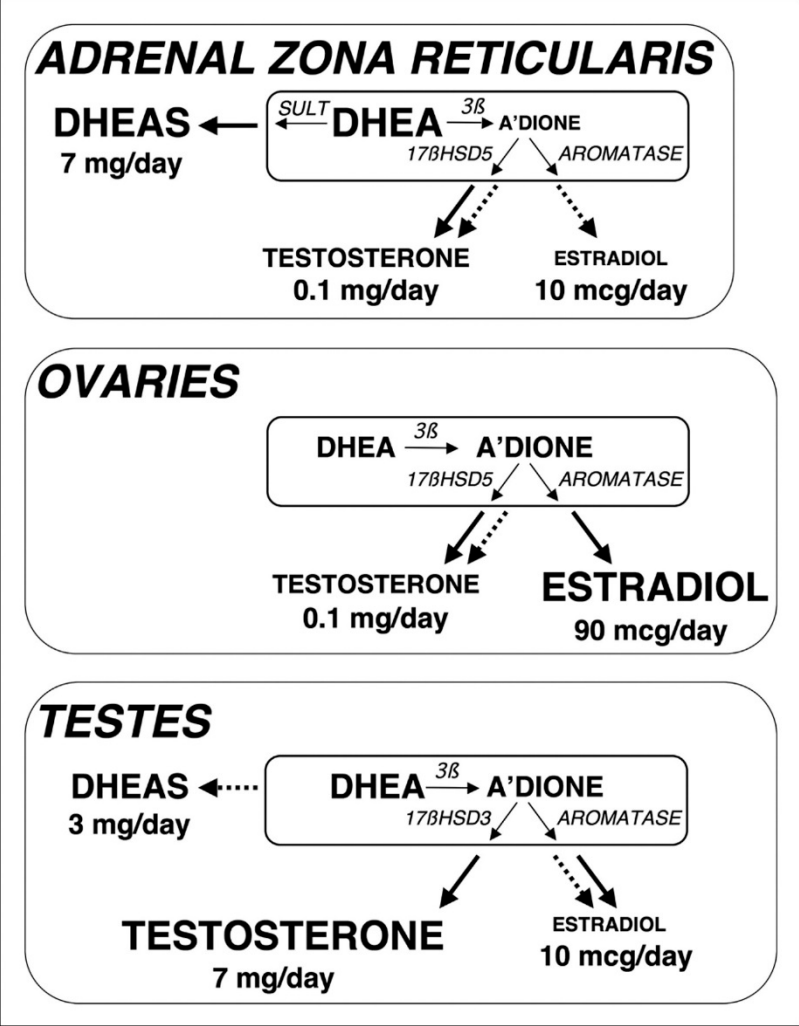
HPG axis



Hypothalamic-pituitary-gonadal axis and age



Simplified diagram of sex steroid production

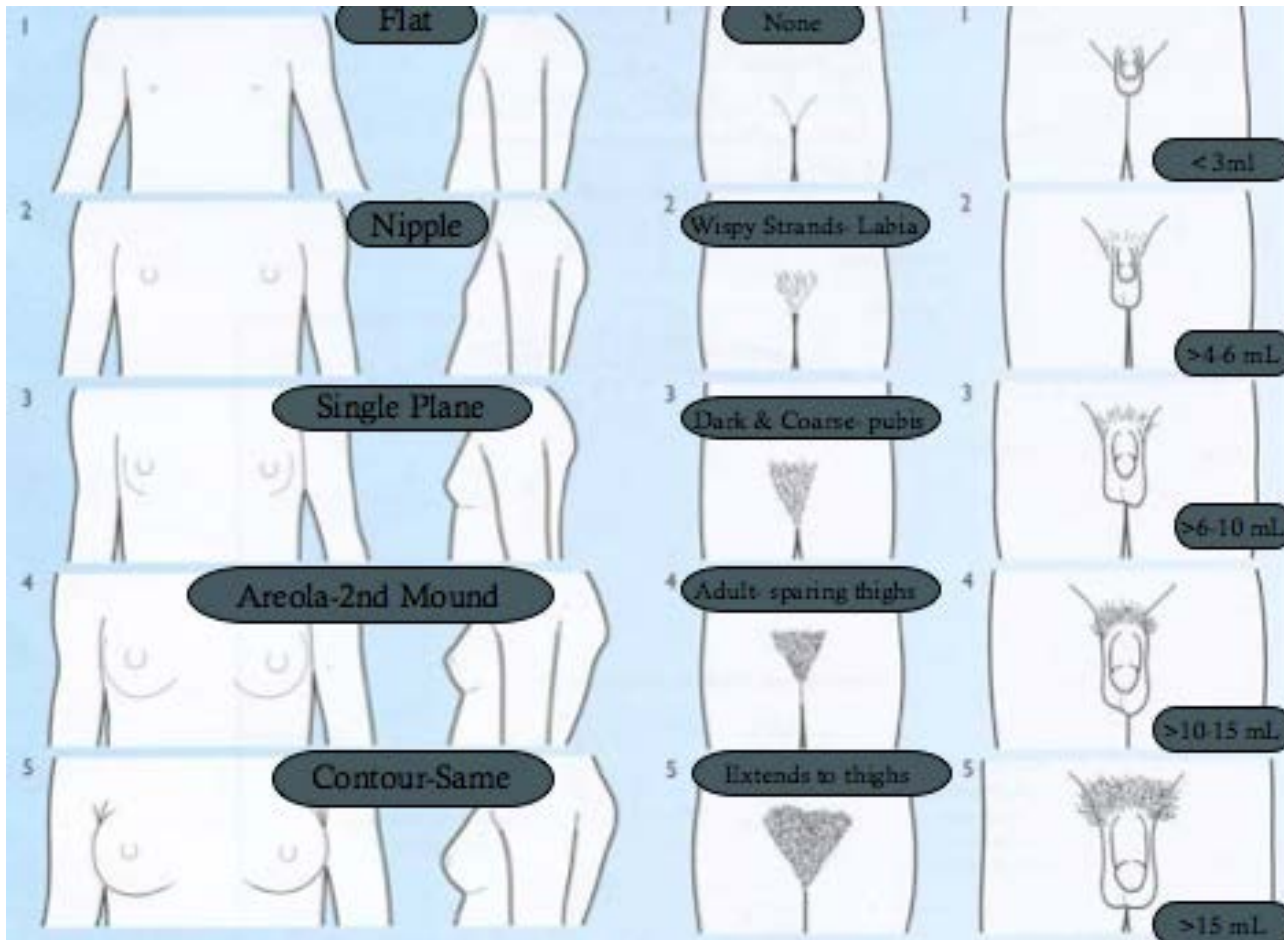


Normal Puberty

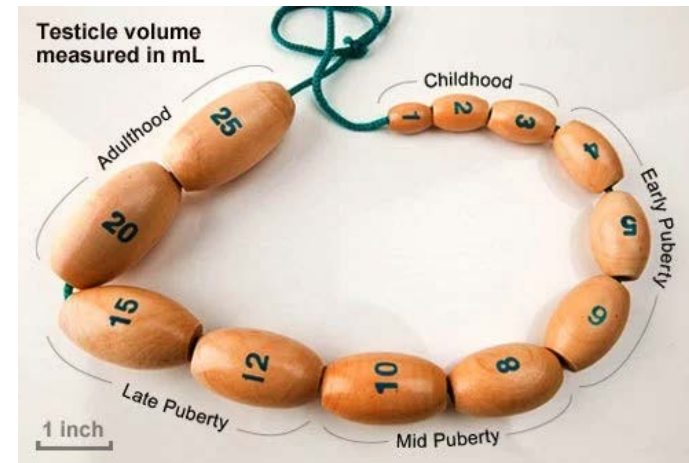
- ❖ The onset of puberty
 - breast buds in females
 - testicular enlargement in males
- ❖ Progression of events lasting 3-4 years.
- ❖ Adrenarche, result of adrenal androgen secretion, usually precedes puberty by 2-3 years.



TANNER STAGING

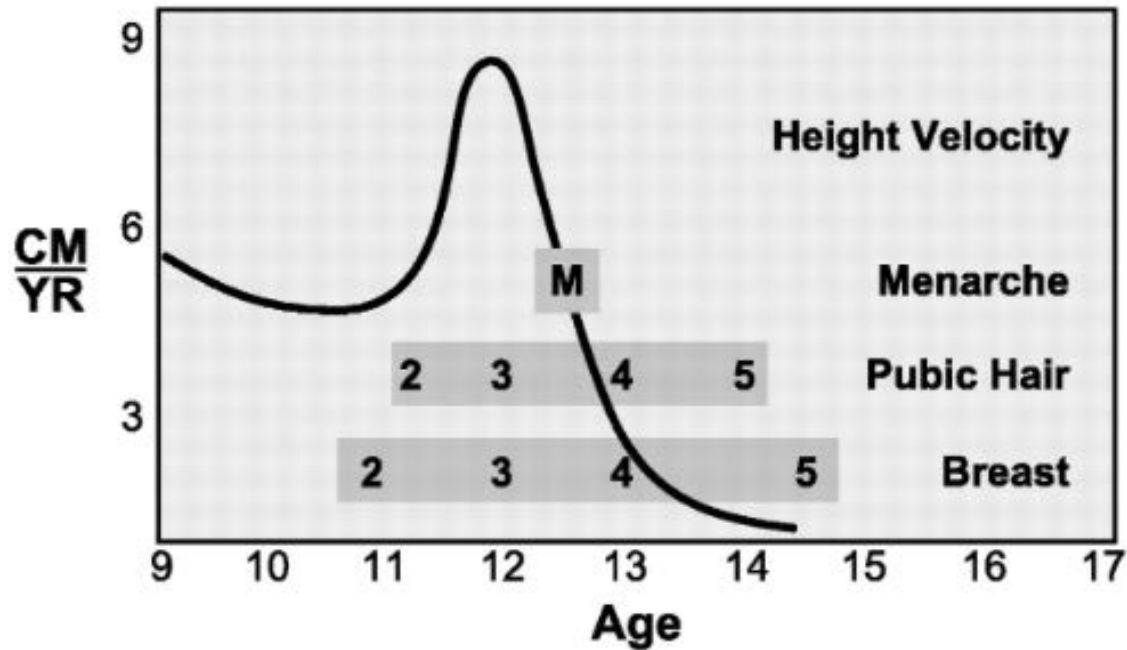


James Tanner

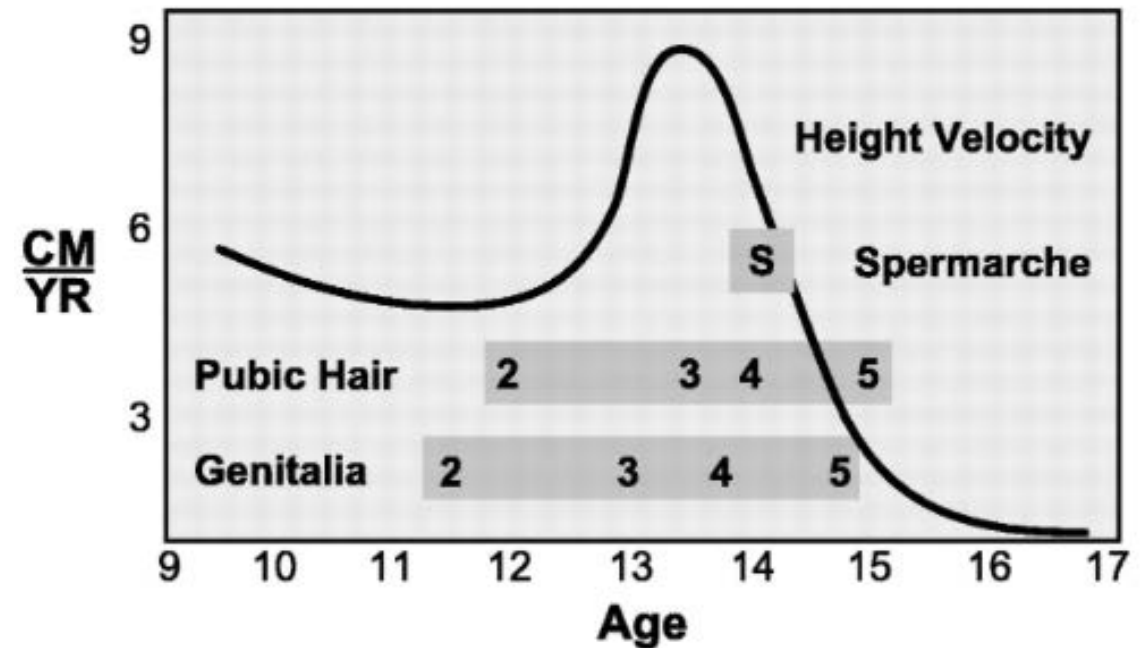


Normal Pubertal Onset and Progression in boys and girls

Sexual Development: Girls



Sexual Development: Boys





PRECOCIOUS PUBERTY

Nobody likes T...

REPORT OF A CASE OF PRECOCIOUS PUBERTY AND PREGNANCY IN 1834

In 1834 Dr. D. Rowlett of Kentucky reported the following remarkable occurrence of precocious puberty and pregnancy in a 10-year-old girl.

Sally Deweese, daughter of John Deweese, was born in Butler county, Kentucky, on the 7th of April, 1824. She was of the ordinary size, but her hips and breasts began to grow rapidly in a few weeks after she was born, and at twelve months of age she began to menstruate, and her hips and breasts had become so large as to be the objects of common remark; and as she took no pains to conceal her condition, her menstruating so young, became a fact of public notoriety, which continued regular till some time in the year 1833, when she became pregnant, and on the 20th day of April, 1834, she was delivered of a healthy female child, weighing seven and three-fourth pounds. Thus, at the age of ten years and thirteen days, she became the mother of a child of

ordinary size; which, however, refused to suck her, and has been so far raised by the bottle. It is as healthy as is usual for children to be when raised from the bottle, and at the time of taking these notes it weighed eight and three-fourth pounds, and its mother weighed one hundred pounds. She was four feet seven inches high and had the countenance of a girl not exceeding her in years, but is as intelligent as girls generally are at her age.

She was the fifteenth child her mother had given birth to, and was born when her mother was forty-five years of age. There had been no previous case of early puberty, or premature old age in either the family of the father or mother.'

NOTED BY T. E. C., JR., M.D.

REFERENCE

1. American Intelligence. Amer. J. Med. Sci., 15: 266, 1834.

Precocious Puberty

- ❖ Onset of secondary sexual characteristics more than 2.5-3 SD earlier than the mean age
- ❖ Girl
 - Puberty < 8 years
 - Menses < 9.5 years
- ❖ Boy
 - Puberty < 9 years of age

Differential Diagnosis

❖ Central precocious puberty

- Idiopathic
- CNS lesions: astrocytoma, hamartomas, NF1
- Radiation
- Trauma
- Genetic – KISS1, MKRN3

❖ Peripheral precocious puberty

- Tumors: adrenal, hcg, granulosa cell, leydig/sertoli cell
- CAH
- Functioning large ovarian cyst
- McCune Albright
- Exogenous exposure

❖ Benign pubertal variants

- Benign premature thelarche
- Benign premature adrenarche

❖ Other factors:

- Obesity
- International adoption

DETAILED MEDICAL HISTORY

- ❖ First pubertal changes- timing and progression
- ❖ Family history
- ❖ History of exposure to androgens or estrogens- lavender oil, tea tree oil
- ❖ History of head trauma
- ❖ Previous CNS disease- headache, vomiting, seizures, CNS malformations, radiation, chemotherapy
- ❖ Fractures
- ❖ Growth charts!

PHYSICAL EXAM

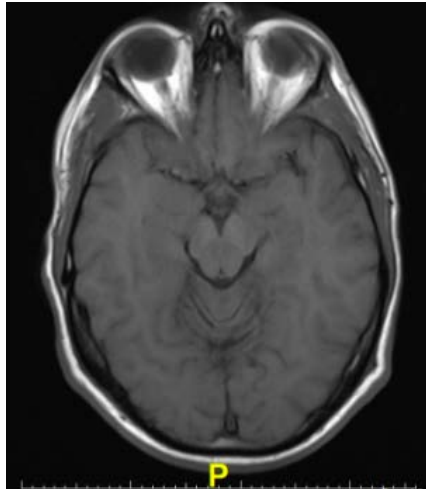
- ❖ Height, weight, **growth velocity**
- ❖ Fundoscopic exam (↑intracranial pressure)
- ❖ Visual fields (CNS mass)
- ❖ Dermatological exam (e.g. café au lait spots)
- ❖ Pubertal staging with palpation!

LABS/IMAGING

- ❖ Bone age: X-ray of left hand and wrist
- ❖ **First morning** measurement of LH, FSH (pediatric ultrasensitive assay), and Estradiol/Testosterone
 - ❖ Most lab prepubertal levels are <0.3 mIU/mL
 - ❖ Must be ultrasensitive assay adapted to pediatrics 0.1 mIU/mL
- ❖ If low/intermediate basal levels, then measure LH and estradiol/testosterone levels after GnRH stimulation
- ❖ Androgen levels: DHEA-S, 17OHP, androstenedione, testosterone
- ❖ Thyroid hormone: TSH, free T4
- ❖ Prolactin, ACTH, IGF-1
- ❖ Abdominal/pelvic ultrasound : Uterus: length 3.4-4cm, Ovarian volumes 2mL (1-3 mL) suggest puberty
- ❖ If LH and FSH, low: hCG, Inhibin, AFP or CA-125

BRAIN IMAGING

- Brain MRI is recommended for
- all boys with central precocious puberty with onset prior to 9 years of age
- all girls with central precocious puberty with onset prior to 6 years of age, between 6-8 years is up to the clinician



Why Treat Central Precocious Puberty?

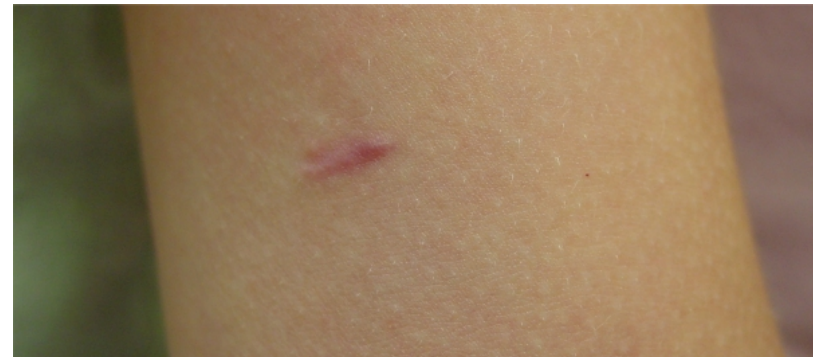- ❖ Psychological and social consequences of precocious puberty
- ❖ Impaired Adult height

Treatment: GnRH Agonist

TABLE 1 Characteristics of GnRHAs

	Rapid Acting	Monthly Depot	3-mo Depot	12-mo Implant
Dosing	3–4 times daily (intranasal) or every day (subcutaneous)	Every 28 d	Every 90 d	Every year
Peak serum concentrations	10–45 min	4 h	4–8 h	1 mo
Onset of therapeutic suppression	2–4 wk	1 mo	1 mo	1 mo
Advantage	Quick on/off	Dosing and efficacy well studied	Fewer injections and fewer compliance concerns	No injections needed
Disadvantage	Multiple daily doses needed/ compliance very difficult	Painful injections/suboptimal compliance	Painful injection	Requires surgical procedure for insertion and removal

Carel et al 2009



Treatment: GnRH Agonist

- ❖ Safe and effective
- ❖ May have stimulatory effect initially
- ❖ Adverse effects:
 - ❖ Headaches or hot flashes
 - ❖ 10% risk of sterile abscess
- ❖ Expectation:
 - ❖ <6 years of age, 9-10cm ↑ adult height,
 - ❖ 6-8 years, 4-7cm ↑ adult height
- ❖ Increase adult height:
 - ❖ Growth hormone
 - ❖ Oxandrolone

Treatment: GnRH Agonist

❖ Monitoring

- ❖ 3-6 months for pubertal assessment/growth
- ❖ 6-12 months Bone age
- ❖ Gonadotropins and Estradiol assessed with random or stimulated values to support chemical suppression

❖ Discontinuation

- ❖ Mean age 10.6 to 11.6 years
- ❖ Mean age menarche 12.3 years

TAKE HOME POINTS

Careful examination with palpation
and detailed history of pubertal
progression

Bone age

Refer early to a pediatric
endocrinologist

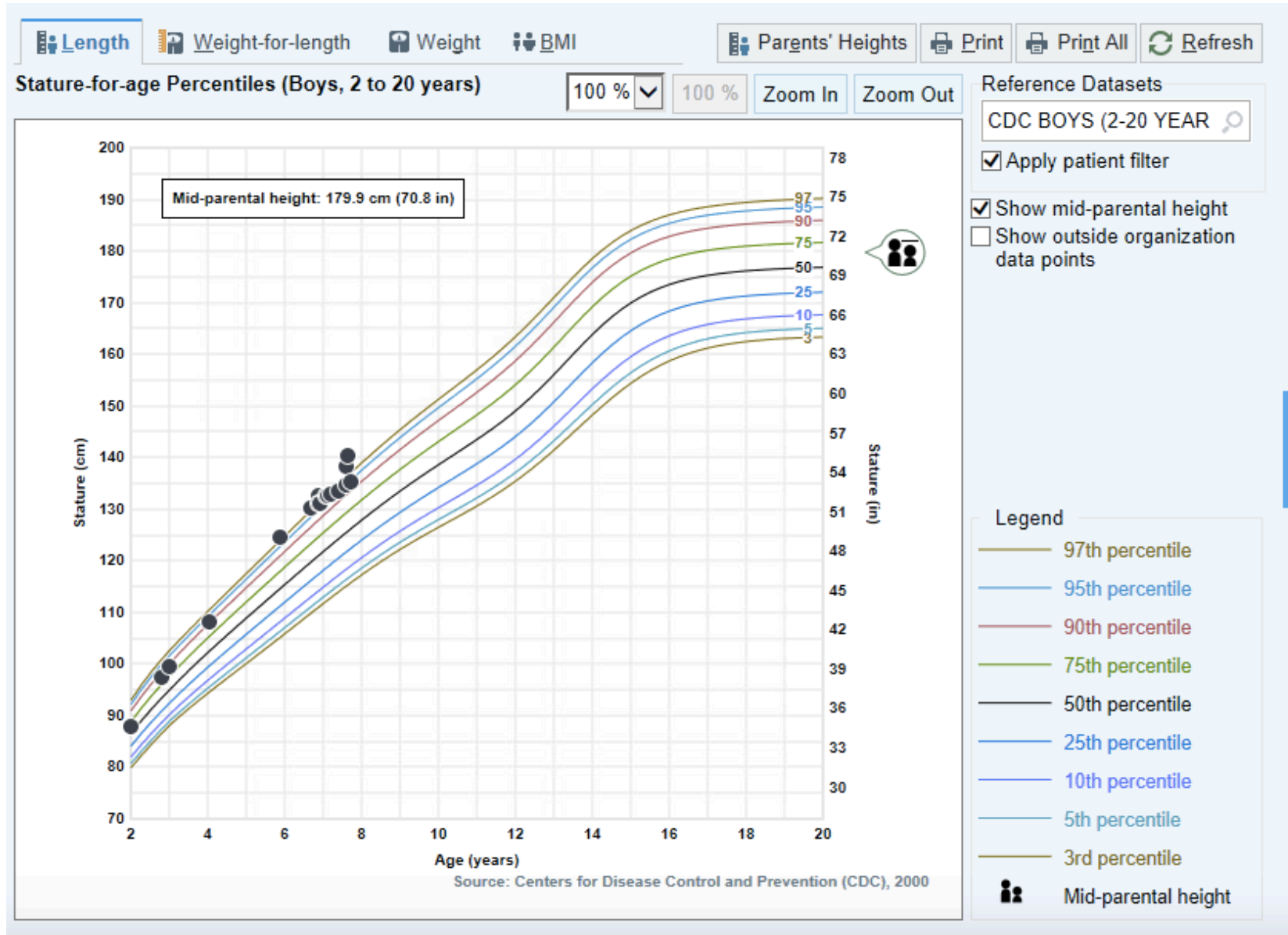


CASE 1

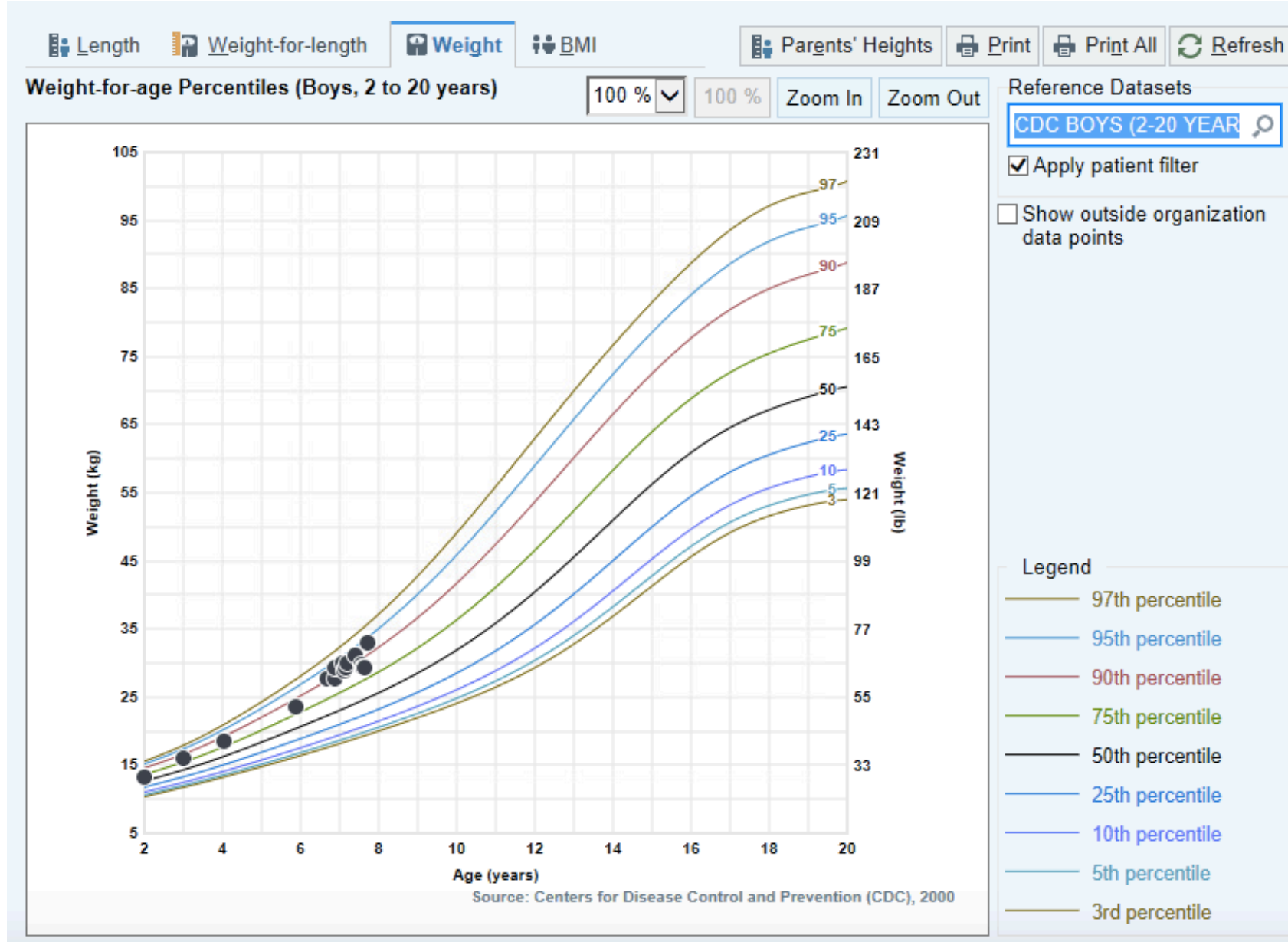
HPI

- 6 yr 10 m old male referred for concerns of early puberty
- Pediatrician noted a generous phallus for age, parents noted body odor and development of pubic hair 2 months ago
- Growth spurt noted for the last 2 years
- More anger/aggression and plays rough with sister

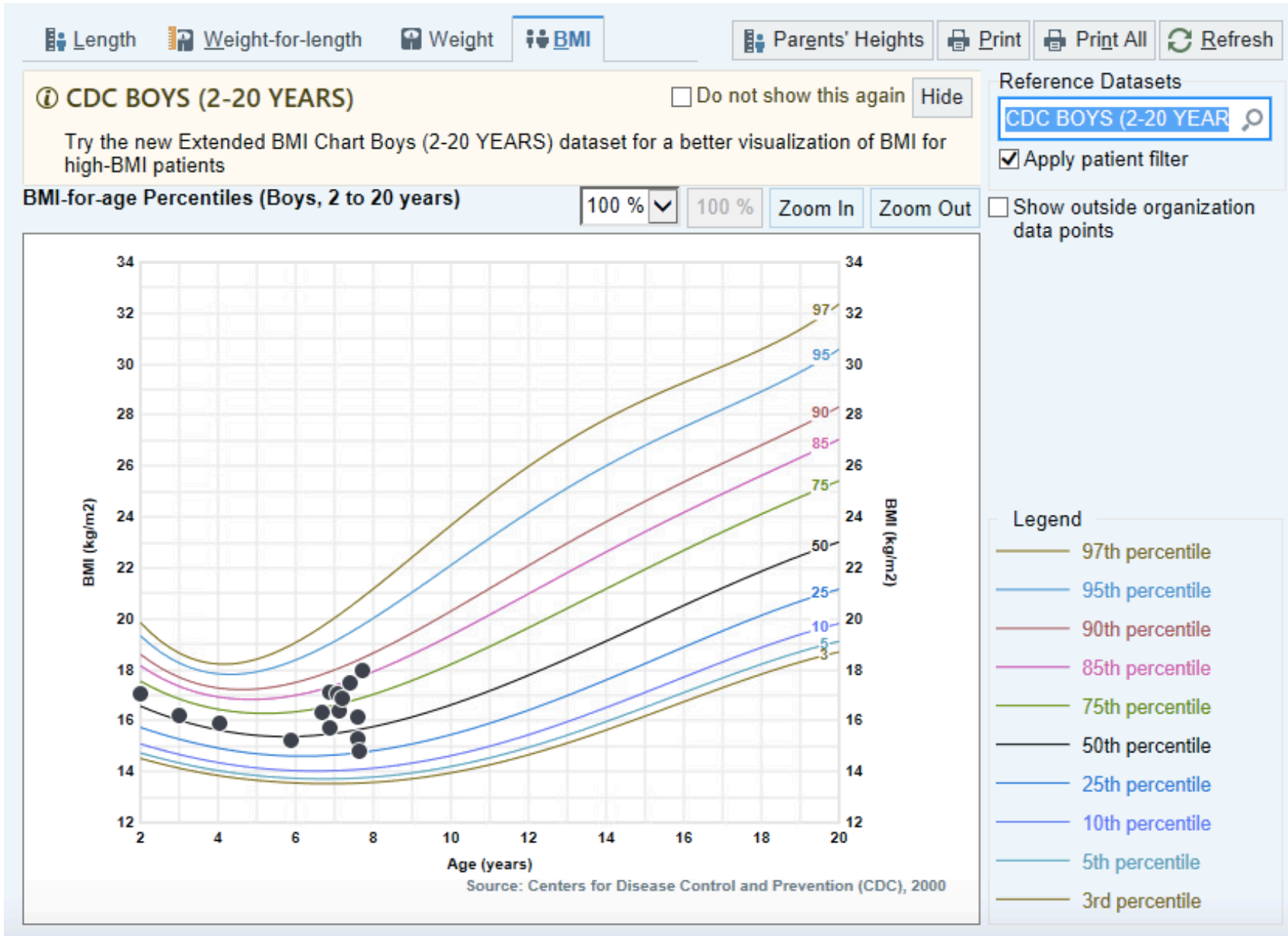
Physical Exam- Ht



Physical Exam- Weight



Physical Exam-BMI



PHYSICAL EXAM

- **Pubertal Exam:** Pubic hair Tanner stage 2, Testicular volume L 3 mL, R 3 mL , Penis large for age measuring 5 cm x 2.5 cm with central urethra, No axillary hair

Bone age

- Read as 13 years at a chronological age of 6 yrs 8 months.

LABS

Component <i>Latest Ref Rng & Units</i>	9/5/2019
LH, Pediatrics <i>< OR = 0.26 mIU/mL</i>	0.09
FSH, Pediatrics <i>0.21 - 4.33 mIU/mL</i>	0.78
Cortisol <i>ug/dL</i>	4.3
ACTH <i>9 - 57 pg/mL</i>	42
Testosterone, Total <i>See Comment ng/dL</i>	84
17-Hydroxyprogesterone <i><=137 ng/dL</i>	13097 (H)
Androstenedione <i>< OR = 36 ng/dL</i>	285 (H)
DHEA-SO4 <i><=27 mcg/dL</i>	155 (H)
hCG, Quantitative <i>See Comment mIU/mL</i>	<1
Free T4 <i>0.76 - 1.46 ng/dL</i>	0.95
Thyroid Stimulating Hormone, 3rd Gen. <i>0.610 - 6.390 μIU/mL</i>	1.580

DIAGNOSIS

- CONGENITAL ADRENAL HYPERPLASIA

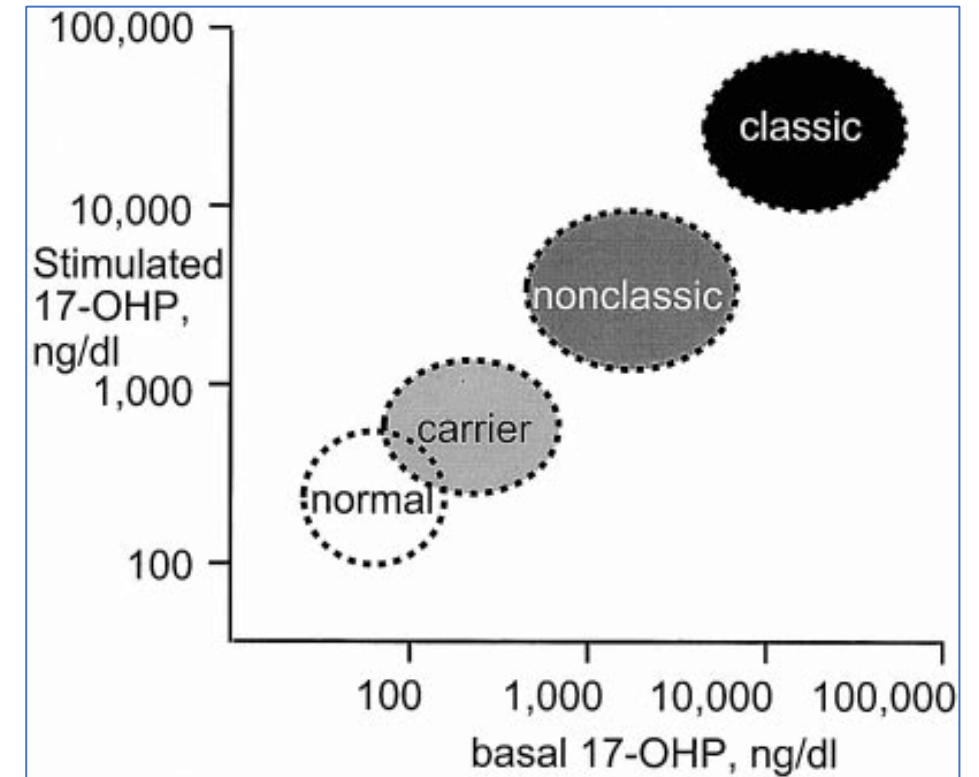
LABS

ACTH STIM TEST (250 mcg cortrosyn)

Lab	T- 60 mins	Baseline
Cortisol, Total, LC/MS/MS <i>2.0 - 27.2 mcg/dL</i>	3.5	2.7
17-Hydroxyprogesterone <i>≤137 ng/dL</i>	34706 (H)	7068 (H)

CAH GENETICS:

V281L and Q318X heterozygous mutations



CLINICAL COURSE : On Rx with HC

Component <i>Latest Ref Rng & Units</i>	10/14/2019	9/12/2019
Testosterone Total LC/MS/MS <i><=25 ng/dL</i>	40 (H)	90 (H)
Androstenedione <i>< OR = 36 ng/dL</i>	71 (H)	370 (H)
17-Hydroxyprogesterone <i><=137 ng/dL</i>	2531 (H)	34706 (H)



CASE 2

HPI

- 3 yr 8 m old female for consultation of concerns of early puberty
- Developed body odor since the last 8-9 months
- No breast dev, pubic hair, vaginal discharge or bleeding
- Tallest girl in her class but always been tall- no growth spurt noted
- No family history of early puberty

Physical Exam

- **Ht-** 85%, **Wt-** 94% **BMI-** 95%
- **Pubertal Exam:** Pubic hair Tanner stage 1 and breast tanner stage 1, no vaginal discharge, no estrogenized vaginal tissue, no clitoromegaly, body odor +

Labs

- Bone age : 5 years 9 months at 3 years and 8 months.

Component <i>Latest Ref Rng & Units</i>	3/3/2020
Testosterone Total LC/MS/MS <i><=8 ng/dL</i>	3
Free T4 <i>See Comment ng/dL</i>	1.30
Thyroid Stimulating Hormone, 3rd Gen. <i>See Comment µIU/mL</i>	1.260
DHEA-SO4 <i>35.0 - 430.0 ug/dL</i>	75.3
Androstenedione <i>< OR = 38 ng/dL</i>	12
17-Hydroxyprogesterone <i><=131 ng/dL</i>	8
LH, Pediatrics <i>< OR = 0.26 mIU/mL</i>	<0.02
FSH, Pediatrics <i>NOT ESTABLISHED mIU/mL</i>	1.51
Estradiol, Ultra Sens (LC/MS/MS) <i>pg/mL</i>	<2

DIAGNOSIS

- PREMATURE ADRENARCHE

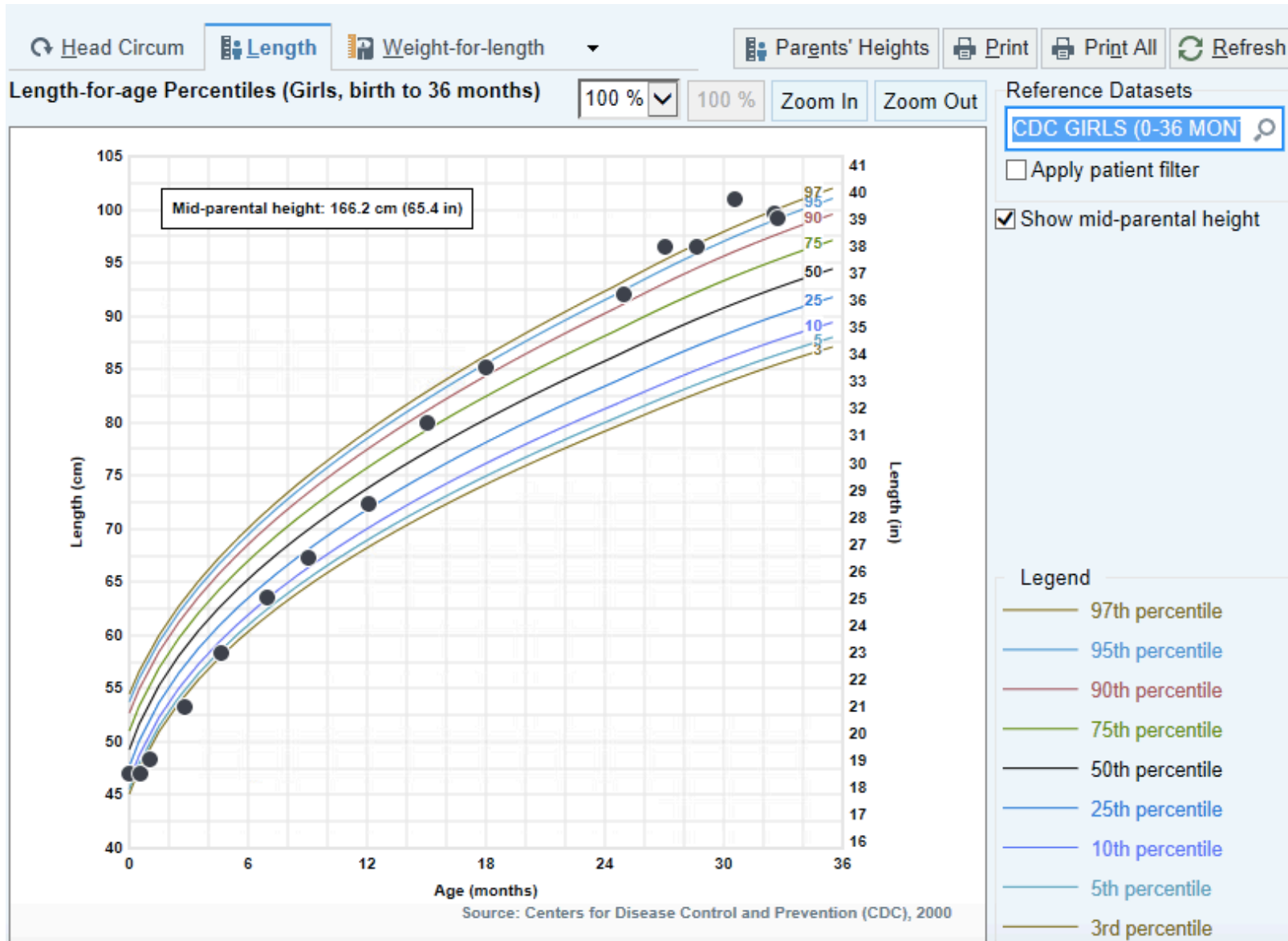


CASE 3

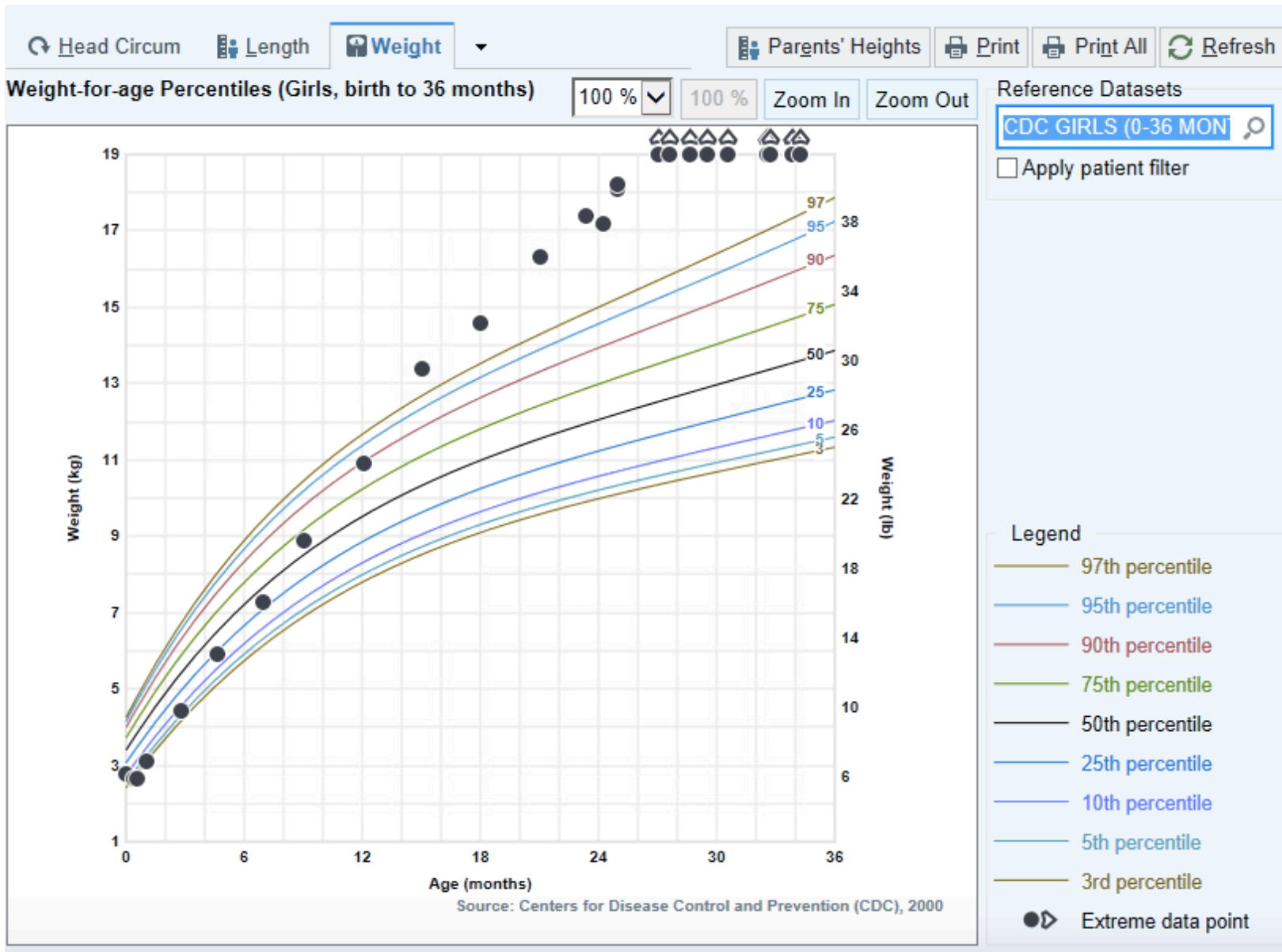
HPI

- 3 yrs old female referred for concerns of early puberty
- Pubic hair at 7 months of age, followed by axillary hair and body odor.
- Breast dev at 20 months of age
- Growth acceleration between 12 and 15 months of age.

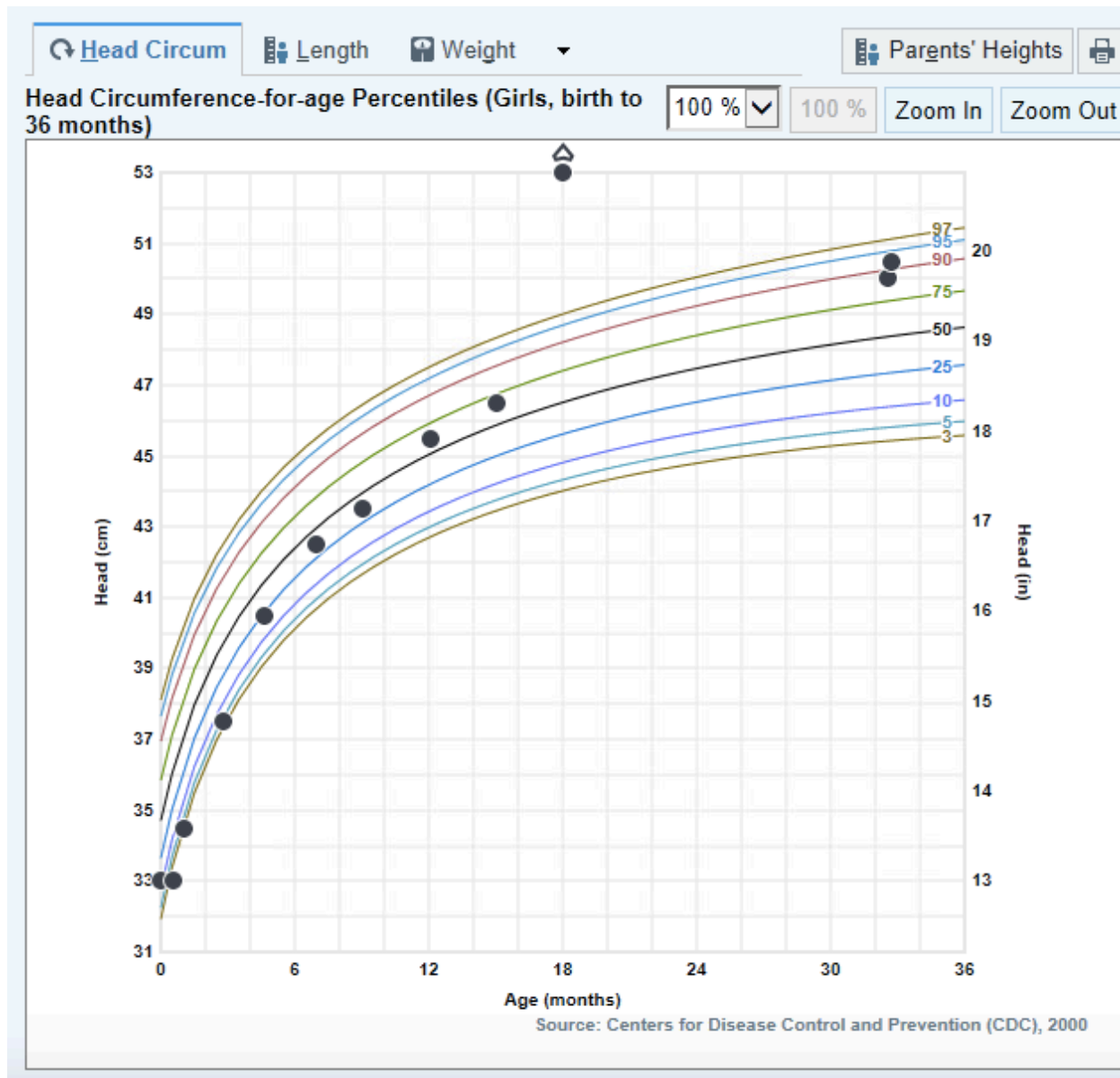
Physical Exam- Height



Physical Exam-Weight



Physical Exam-BMI



PHYSICAL EXAM

- Breast and Pubic hair - Tanner 3. Vaginal mucosa pink No clitoromegaly. Neurological exam is non-focal. DTR 2+. No scoliosis. Skin and hair are normal.
- No acne appreciated,
- no cafe au lait spots or other pigmented lesions

LABS

Component <i>Latest Ref Rng & Units</i>	1/10/2014
T4, Total <i>5.0 - 10.6 ug/dL</i>	6.3
Thyroxine Binding Capacity <i>19.0 - 28.0 ug/dL</i>	23.7
Free Thyroxine, Estimated <i>1.0 - 2.2 ng/dL</i>	1.2
DHEA-SO4 <i>35 - 430 ug/dL</i>	<15 (L)
Prolactin <i>0 - 20 ng/mL</i>	5
Androstenedione <i>5 - 51 ng/dL</i>	32
Thyroid Stimulating Hormone, 3rd Gen. <i>0.3 - 4.2 uU/mL</i>	7.65 (H)
Estradiol <i>pg/mL</i>	30
Follicle Stimulating Hormone (Esoterix) <i>mIU/mL</i>	3.58
Luteinizing Hormone (Esoterix) <i>mIU/mL</i>	0.64
17-Hydroxyprogesterone <i>4 - 115 ng/dL</i>	9

- Bone age radiograph read as 3 yr 6 mo at a chronological age of 2 years.

DIAGNOSIS

- CENTRAL PRECOCIOUS PUBERTY

CLINICAL COURSE

- Brain MRI : showed small (2 mm) hypothalamic hamartoma
- She had a supprelin (Histrelin) implant since she was 3 years of age.

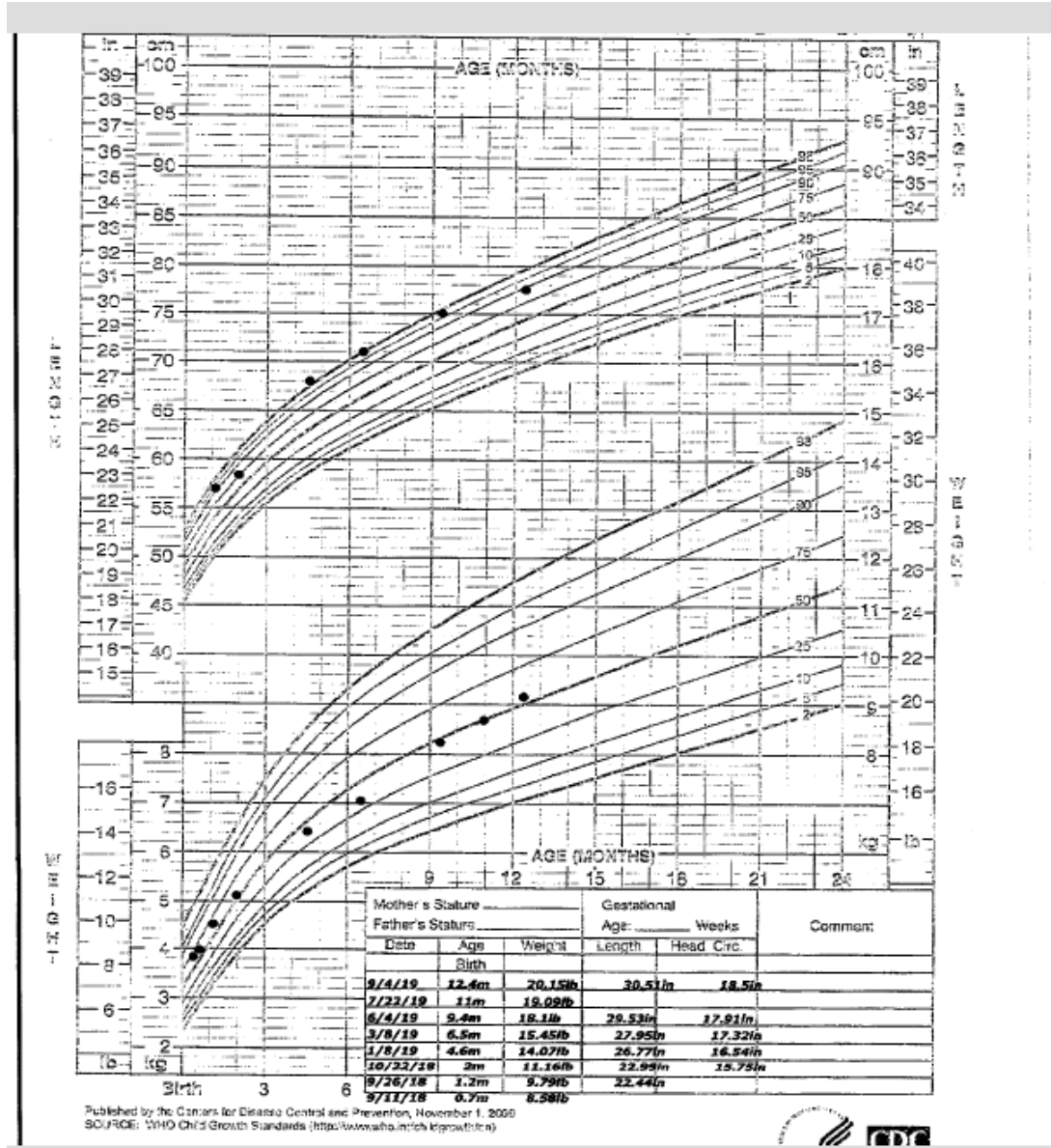


CASE 4

HPI

- 13 month old female seen for early breast development
- Breast development noted since she was 9 months old with increase in size
- No vaginal discharge, no bleeding, no pubic hair
- No external hormone exposure, no lavender or tea tree oil
- PMH- significant for medical NEC- treated with antibiotics in NICU

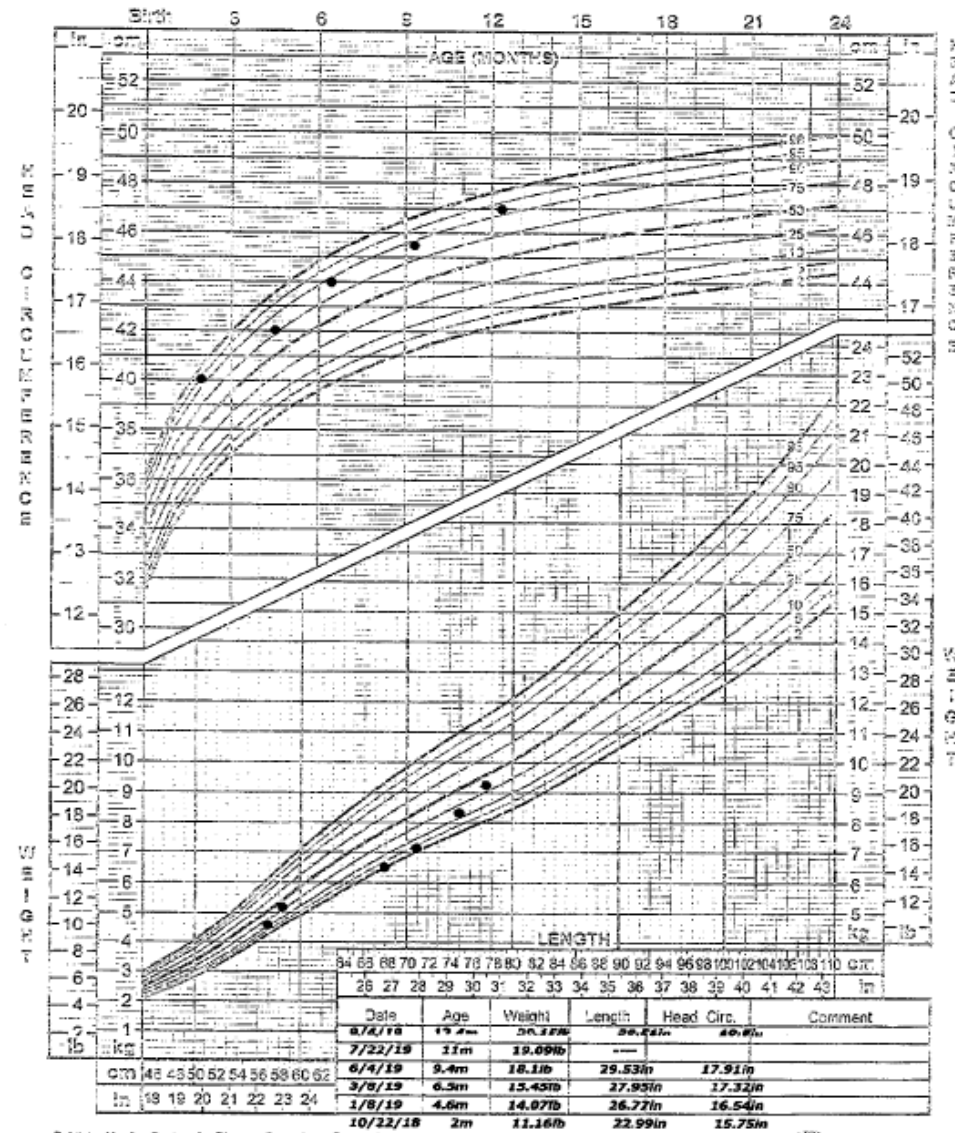
PHYSICAL EXAM



Published by the Centers for Disease Control and Prevention, November 1, 2006
 SOURCE: WHO Child Growth Standards (<http://www.who.int/childgrowth/>)



Head circumference



PHYSICAL EXAM

- Ht- 28%
- Wt- 56%
- HC- 48%
- Some pubic fuzz, bilateral small breast buds + with some puffiness

LABS

Component <i>Latest Ref Rng & Units</i>	10/10/2019
LH, Pediatrics <i>mIU/mL</i>	0.08
FSH, Pediatrics <i>NOT ESTABLISHED mIU/mL</i>	4.00
Estradiol, Ultra Sens (LC/MS/MS) <i>pg/mL</i>	26
17-Hydroxyprogesterone <i><=139 ng/dL</i>	134
Free T4 <i>0.80 - 1.50 ng/dL</i>	1.49
Thyroid Stimulating Hormone, 3rd Gen. <i>0.270 - 4.200 µIU/mL</i>	3.5
DHEA-SO4 <i><=22 mcg/dL</i>	6
Androstenedione <i>< OR = 35 ng/dL</i>	13
Testosterone Total LC/MS/MS <i><=8 ng/dL</i>	4
Prolactin <i>4.8 - 23.3 ng/mL</i>	24


PELVIC US

- A peripubertal appearing midline uterus is noted, measuring 2.8 x 1.3 x 0.8 (CC x TR X AP) cm.
- The endometrium is identified, measuring 1 mm. The ovaries are normal in size, position and parenchymal echotexture, the right measuring 1.3 x 1.1 x 1.0 cm and the left 1.0 x 0.9 x 2.9 cm.
- No ovarian cysts.

DIAGNOSIS

- PREMATURE THELARCHE

PABLO PICASSO: BEFORE PUBERTY.



....AFTER PUBERTY.



searchID: 46124194
1994

© Original Artist
Reproduction rights obtainable from
www.CartoonStock.com

THANK YOU!