



ELSEVIER

Available online at www.sciencedirect.com

British Journal of Oral and Maxillofacial Surgery xxx (2010) xxx.e1–xxx.e3

BRITISH
Journal of
Oral and
Maxillofacial
Surgerywww.bjoms.com**Short communication****A brain abscess following dental extractions in a patient with hereditary hemorrhagic telangiectasia**P. Corre^{a,*}, C. Perret^b, B. Isidor^c, R.H. Khonsari^a^a *Clinique de Chirurgie Maxillo-Faciale et de Stomatologie, Centre Hospitalier Universitaire de Nantes, France*^b *Service de radiologie, Centre Hospitalier Universitaire de Nantes, France*^c *Service de Génétique médicale, Centre Hospitalier Universitaire de Nantes, France*

Accepted 23 July 2010

Abstract

Oral and maxillofacial surgeons must be aware of the potentially life-threatening complications of dental extractions in patients with hereditary haemorrhagic telangiectasia because of their high prevalence of pulmonary arteriovenous fistulas. Despite the lack of evidence-based guidelines, antibiotic cover should be given to patients with HHT who require oral surgery according to the same rules as those used for patients at high risk of bacterial endocarditis.

© 2010 The British Association of Oral and Maxillofacial Surgeons. Published by Elsevier Ltd. All rights reserved.

Keywords: Dental extraction; Brain abscess; Hereditary hemorrhagic telangiectasia; Pulmonary arteriovenous fistula

Case report

A 63-year-old woman was admitted with acute confusion, fever, and aphasia. A week previously she had had 10 teeth extracted at a dental surgery. Computed tomogram (CT) and magnetic resonance imaging (MRI) of the brain showed a left temporal lesion that looked like a bacterial abscess (Fig. 1). Pus was drained by stereotactic puncture and grew *Fusobacterium nucleatum* and *Staphylococcus epidermidis*. Antibiotics were prescribed intravenously and the neurological symptoms settled. Cardiac and abdominal ultrasonography showed no port of entry.

Unexpected vascular lesions were detected on the chest radiograph, and CT showed 3 pulmonary arteriovenous fistulas (Fig. 2). Clinical examination showed multiple but previously un-noticed areas of telangiectasia on the facial

skin and the oral mucosa (Fig. 3). Oesophagogastroduodenoscopy for microcytic anaemia showed multiple gastric and duodenal angiodysplastic lesions, and we made a diagnosis of hereditary haemorrhagic telangiectasia (HHT). Mutation screening found a p. Gln489X mutation in the endoglin (ENG) gene.

The pulmonary arteriovenous fistulas were treated by embolisation, while 3 remaining infected teeth were extracted after she had taken amoxicillin 3 g orally 1 h preoperatively. Prosthetic dental rehabilitation and neurological follow-up for a minor residual memory impairment were planned. CT of the chest will be done every 5 years.

Discussion

The prevalence of HHT varies from 1:2351 in the French region of Ain to 1:39 216 in Northern England,¹ and neurological complications affect 8% to 12% of the members of families with HHT.² Pulmonary arteriovenous fistulas occur in 5–30% of patients with HHT^{3,4} and account for two-thirds of the reported neurological signs, mainly from paradoxical

* Corresponding author at: Clinique de Chirurgie Maxillo-Faciale et de Stomatologie, Centre Hospitalier Universitaire de Nantes, 1 place Alexis Ricordeau, 44093 Nantes, France. Tel.: +33 06 84 82 21 71; fax: +33 02 40 08 36 68.

E-mail address: pierrecorre@hotmail.com (P. Corre).

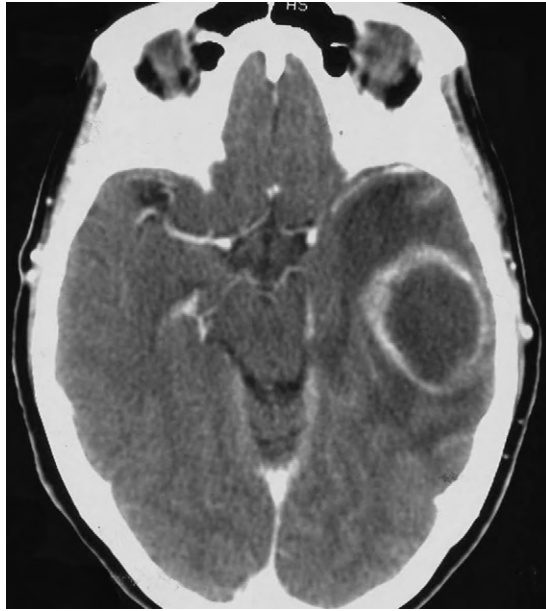

Fig. 1. Initial computed tomogram with injection showing a lesion of the left temporal ring that is inducing a midline shift.

septic emboli through a right-to-left shunt and subsequent brain abscess.¹ As many as 19–39% of patients with HHT-associated brain abscesses die, while less than 8% of patients with brain abscesses die in the general population.^{3,4}

Here, a secondary abscess in a hypoxic infarct or in an infarct resulting from an aseptic embolism could not be ruled out. Nevertheless, the patient's abscess might have been secondary to dental surgery for 4 reasons: 10 infected teeth (with associated maxillary sinusitis) were extracted without antibiotic cover shortly before admission; oral bacteria were

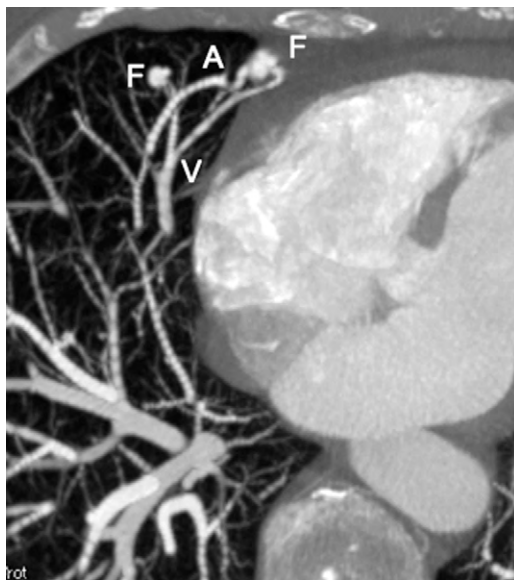


Fig. 2. Computed tomogram of the chest in maximum intensity projection; axial reconstruction, showing the presence of 2 fistulas. A: artery, F: fistula, and V: vein.

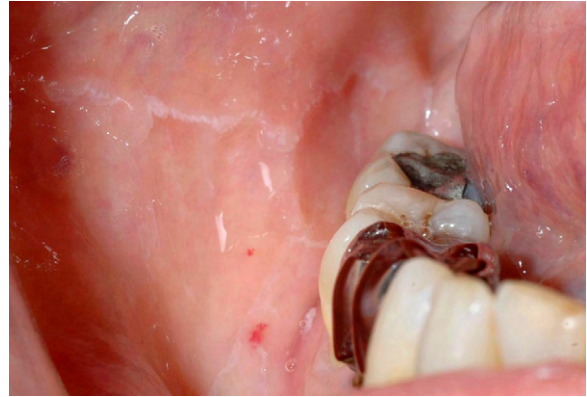

Fig. 3. Oral telangiectasia on the mucosa of the cheek in the area of the right mandibular molars.

found in the brain; no other port of entry was apparent; and the patient had untreated pulmonary arteriovenous fistulas.^{3,4} The cumulative risk of endocarditis resulting from bacteraemia caused by daily activity is far greater than the risk of endocarditis resulting from a single dental procedure,^{5,6} so by analogy with infective endocarditis, the effect of the recent oral procedure will never be ascertained, even if the causal relation seems plausible.

Patients with HHT are occasionally referred to oral surgeons for acute bleeding. The latest recommendations about the prevention of infective endocarditis during dental procedures state that the risk of adverse effects caused by antibiotics exceed any benefit from antibiotics given prophylactically. The exception is patients with high-risk underlying cardiac conditions, including non-operated cardiac malformations,^{5,6} which share common mechanisms with pulmonary arteriovenous fistulas, including right-left shunt and direct access to arterial blood for bacteria that avoid the pulmonary filter. Despite the controversies concerning prophylactic antibiotics,⁷ all practitioners should be aware that the presence of facial and buccal telangiectasia, or of a history of pulmonary vascular malformations, may indicate that the patient is at high risk.

References

- Guttmacher AE, Marchuk DA, White Jr RI. Hereditary hemorrhagic telangiectasia. *N Engl J Med* 1995;**333**:918–24.
- Mohler ER, Monahan B, Cauty MD, Flockhart DA. Cerebral abscess associated with dental procedure in hereditary haemorrhagic telangiectasia. *Lancet* 1991;**338**:508–9.
- Thompson RL, Cattaneo SM, Barnes J. Recurrent brain abscess: manifestation of pulmonary arteriovenous fistula and hereditary hemorrhagic telangiectasia. *Chest* 1977;**72**:654–5.
- Ratcliffe PJ, Earl CJ. Recurrent cerebral abscess in association with pulmonary arteriovenous fistulae. *J Neurol Neurosurg Psychiatry* 1982;**45**:566–7.
- Wilson W, Taubert KA, Gewitz M, Lockhart PB, Baddour LM, Levins M, et al. Prevention of infective endocarditis: guidelines from the American Heart Association: a guideline from the American Heart Association Rheumatic Fever, Endocarditis and Kawasaki Disease Committee,

- Council on Cardiovascular Disease in the Young, and the Council on Clinical Cardiology, Council on Cardiovascular Surgery and Anesthesia, and the Quality of Care and Outcomes Research Interdisciplinary Working Group. *J Am Dent Assoc* 2008;**139**:3S–24S. Erratum in *J Am Dent Assoc* 2008;139:253.
- Task Force on the Prevention, Diagnosis, and Treatment of Infective Endocarditis of the European Society of Cardiology; European Society of Clinical Microbiology and Infectious Diseases; International Society of Chemotherapy for Infection and Cancer, Habib G, Hoen B, Tornos P, et al. Guidelines on the prevention, diagnosis, and treatment of infective endocarditis (new version 2009): the Task Force on the Prevention, Diagnosis, and Treatment of Infective Endocarditis of the European Society of Cardiology (ESC). *Eur Heart J* 2009;30:2369–413.
 - te Veldhuis EC, te Veldhuis AH, van Dijk FS, Kwee ML, van Hagen JM, Baart JA, et al. Rendu-Osler-Weber disease: update of medical and dental considerations. *Oral Surg Oral Med Oral Pathol Oral Radiol Endod* 2008;**105**:e38–41.