

See discussions, stats, and author profiles for this publication at: <https://www.researchgate.net/publication/285897237>

# Neurological Symptoms in a Cancer Patient With Osler–Weber–Rendu Syndrome

ARTICLE *in* INFECTIOUS DISEASE IN CLINICAL PRACTICE · DECEMBER 2015

DOI: 10.1097/IPC.0000000000000353

READS

59

7 AUTHORS, INCLUDING:



**Michael Grabau**

University of South Florida

1 PUBLICATION 0 CITATIONS

SEE PROFILE



**Nam D Tran**

Moffitt Cancer Center

36 PUBLICATIONS 379 CITATIONS

SEE PROFILE



**Frank D Vrionis**

Moffitt Cancer Center

99 PUBLICATIONS 2,094 CITATIONS

SEE PROFILE



**John Greene**

Moffitt Cancer Center

220 PUBLICATIONS 1,016 CITATIONS

SEE PROFILE

# Neurological Symptoms in a Cancer Patient With Osler-Weber-Rendu Syndrome

## *Brain Abscess or Metastasis?*

Michael Grabau,\* Ganesh Gajanan, MBBS,† Sowmya Nanjappa, MD,† Chandrashekar Bohra, MBBS,†  
Nam D. Tran, MD, PhD,‡ Frank D. Vrionis, MD, MPH, PhD,‡ and John N. Greene, MD, FACP†§

**Abstract:** Osler-Weber-Rendu disease, also known as hereditary hemorrhagic telangiectasia (HHT), is a rare autosomal dominant disease characterized by aberrant vascular development. Arteriovenous malformations that can bypass capillaries form fistulas, and a dampened immune system predispose these patients to infections. Because of the pathophysiology of hereditary hemorrhagic telangiectasia, most patients with pulmonary arteriovenous malformations go on to eventually develop brain abscesses that can be fatal if left untreated. Neurological symptoms are the most common presenting complaint in these patients. Hereditary hemorrhagic telangiectasia patients with cancer who present with neurological symptoms pose a diagnostic challenge. We wanted to highlight the importance of considering the possibility of brain abscess in a patient with HHT presenting with neurological symptoms and to understand the differences in the microbiology of brain abscesses in HHT and non-HHT patients. We collected data regarding the causative organisms from various studies using Medline search. Through this literature review, we found a significant difference in the microbiology between the 2 groups, with anaerobic organisms being isolated in the majority of HHT patients.

**Key Words:** hereditary hemorrhagic telangiectasia, Osler-Weber-Rendu syndrome, arteriovenous malformation, brain abscess  
(*Infect Dis Clin Pract* 2015;00: 00–00)

Osler-Weber-Rendu disease, or more commonly known as hereditary hemorrhagic telangiectasia (HHT), is a rare autosomal dominant disease characterized by vascular dysplasia and hemorrhage due to disorder of development of the vasculature.<sup>1</sup> In most cases, HHT arises from a germline mutation of the endoglin and activin receptor-like kinase (*ALK1/ACVRL1*) genes.<sup>2</sup> The most common clinical manifestations are epistaxis, multiple telangiectasias, and visceral arteriovenous malformations (AVMs).<sup>3</sup> Neurological symptoms are very common and may be the first presenting symptom in many patients. Formation of brain abscess is one of the frequent and most feared complication of this disease and carries significant morbidity and mortality. The focus of this article was to highlight the importance of considering brain abscess in any HHT patient with new-onset neurological symptoms and the difficulty in diagnosis of other brain lesions in the setting of HHT. We also discuss the differences in the microbiology of brain abscess in HHT and non-HHT patients and thus help physicians to narrow the empiric antibiotic coverage while treating such patients.

### CASE REPORT

A 48-year-old woman with a history of resected stage IIIC, high-grade clear-cell adenocarcinoma of the ovary 6 months back was transferred from an outside hospital where she presented with new-onset seizures. She had an episode of seizure on admission, which was controlled with diazepam. Her past medical history was significant for brain abscess 30 years ago, which developed after extensive dental work, and was subsequently diagnosed with HHT with pulmonary AVM. Her clinical course was uncomplicated until the diagnosis of ovarian cancer 6 months ago. She denied recent dental work, intravenous drug abuse, or trauma. Urine culture reports from an outside hospital were significant for more than 100,000 colonies of *Enterococcus* for which she was treated with vancomycin and piperacillin/tazobactam.

On admission, her temperature was 98.2°F, heart rate was 76 beats per minute, blood pressure was 112/63 mm Hg, and respiratory rate was 18 breaths per minute. There were no significant findings on physical examination. Laboratory findings showed a glucose level of 118 mg/dL, electrolytes within reference range, white blood cell count of 9.19 kU/L, hemoglobin level of 9.3 g/dL, and creatinine level of 1.4 mg/dL.

Computed tomography (CT) scan of the brain without contrast revealed multiple hyperdense lesions in the brain suspicious for hemorrhagic masses or metastatic deposits. Magnetic resonance imaging (MRI) of the brain with contrast revealed multiple enhancing masses containing blood products, most likely representing diffuse brain metastases, with the largest lesion in the right frontal lobe measuring 1.9 × 1.3 cm. There was associated vasogenic edema, but no midline shift was noted (Fig. 1). Since there was a suspicion of metastasis, a CT scan of the thorax and abdomen was obtained, which did not show any new tumor growth. The CT also revealed findings consistent with multiple AVMs of the liver, left kidney, and lungs. Antibiotic therapy with ceftriaxone and metronidazole was initiated to cover the potential brain abscess.

Serial MRI scans reported interval progression of multiple supratentorial enhancing masses, with the right frontal lobe mass now measuring 2 × 1.9 cm. There was a high suspicion of the right frontal lobe lesion being a brain abscess because of the patient's past history of HHT and brain abscess. Hence, we decided to proceed with a diagnostic brain biopsy to rule out brain abscess before palliative radiation. Biopsy was consistent with metastatic brain disease from the primary ovarian cancer. She was discharged on day 12 as the patient and family decided to pursue the choice of home hospice.

### DISCUSSION

Hereditary hemorrhagic telangiectasia was first recognized in the 19th century as a familial bleeding disorder. Osler, Weber, and Hanes first brought the disorder to the attention of the general medical community, which resulted in the eponym Osler-Weber-Rendu syndrome.<sup>4,5</sup> Hereditary hemorrhagic telangiectasia is an autosomal dominant disease characterized by an aberrant vascular

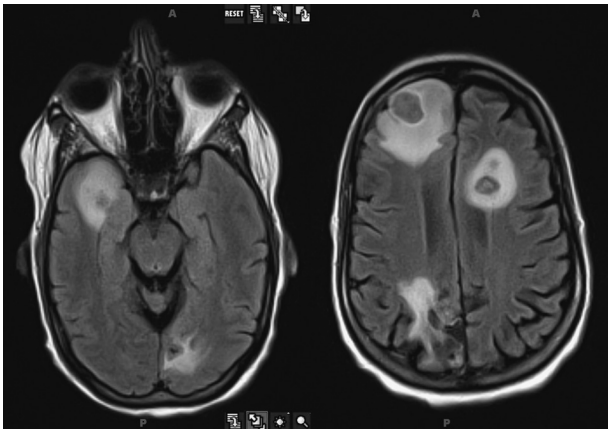
From the \*University of South Florida; †Moffitt Cancer Center; ‡Department of Neuro-Oncology, Moffitt Cancer Center; and §University of South Florida College of Medicine, Tampa, FL.

Correspondence to: John N. Greene, MD, FACP, Moffitt Cancer Center, 12902 Magnolia Dr, FOB-3, Tampa, Florida. E-mail: john.greene@moffitt.org.

The authors have no funding or conflicts of interest to disclose.

Copyright © 2015 Wolters Kluwer Health, Inc. All rights reserved.

ISSN: 1056-9103



**FIGURE 1.** MRI of the brain showing multiple enhancing masses that were later proven to be metastasis from the primary ovarian cancer.

development and with a reported incidence of 1 per 5000 to 10,000 population per year.<sup>6</sup> There are 2 different subtypes—HHT1 and HHT2. The exact pathogenesis is unknown, but a germline mutation in at least 2 distinct genes—endoglin (HHT1) and ALK1/ACVRL1 (HHT2)—is found in most patients.<sup>2</sup> The mutation leads to the development of abnormal vascular structures, which range from dilated microvessels to large AVMs, and can present with a spectrum of clinical features that requires a multidisciplinary approach for the diagnosis and management. Multiple case series suggest that pulmonary and cerebral AVMs are more common in HHT1 and hepatic AVMs in HHT2.<sup>7–9</sup>

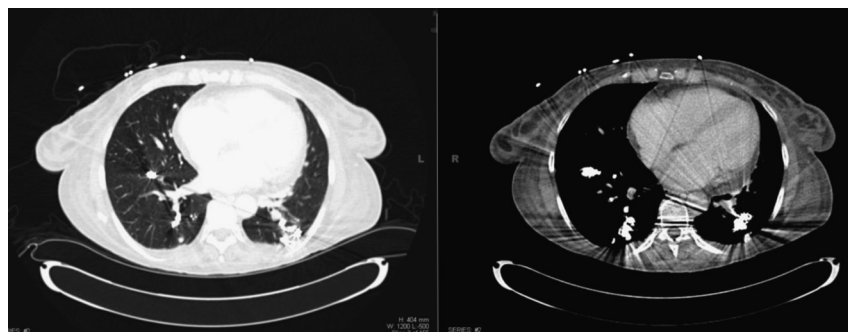
Most cases of HHT go undiagnosed, but some result in severe abnormalities and are frequently complicated by central nervous system hemorrhage, ischemia, and infection. Patients with HHT are at a substantially increased risk of serious neurologic and hemorrhagic complications.<sup>10</sup> Brain abscess is one of the most serious complications of HHT, occurring in approximately 5% to 10% of patients and carries a mortality rate of 19% to 39%.<sup>11–13</sup> Brain abscess is one of the most serious diseases of the central nervous system and is defined as a focal infection within the brain parenchyma, which starts as a localized area of cerebritis, which is subsequently converted into a collection of pus within a well-vascularized capsule. It classically presents with a clinical triad of fever, headache, and focal neurologic deficits and is associated with high mortality.<sup>14,15</sup> Approximately 70% of pulmonary AVMs (PAVMs) are associated with HHT, and approximately 15% to 30% of individuals with HHT have a PAVM<sup>16</sup> (Fig. 2). Five percent to 19% of patients with PAVM go on to

eventually develop brain abscesses, which can be fatal if left untreated.<sup>17–19</sup>

In patients afflicted by HHT, rogue arteries or veins wind throughout the body and in severe cases form fistulas. These fistulas bypass normal valves and blood filtration systems and thus predispose to the hematogenous spread of infection to vital organs. Because the AVMs bypass the normal filtration action of pulmonary capillaries, they encourage unfiltered, unoxygenated blood to travel into the brain.<sup>20,21</sup> Because of this circulatory anomaly, the unoxygenated blood eventually leads to necrotic nidi developing in the brain. These regions of nidi seed the infected blood allowing for bacteria to proliferate and thus predispose these patients to develop brain abscess. According to Agamanolis,<sup>22</sup> “The necrotic center cavitates while, at the periphery, a vascular zone of brain tissue with macrophages, mononuclear cells, and reactive astrocytes contains the infection. In 4 to 5 weeks, collagen (derived from vascular cells) is laid down in this reactive zone forming a thick capsule that walls off the infection, causing large parts of the brain to be deformed and altered.”

Even though the aforementioned factors place patients with HHT at high risk for developing brain abscesses, it has been repeatedly shown that the presence of HHT per se increases the prevalence of infectious diseases.<sup>23</sup> A recent study has confirmed that there is an altered adaptive immune response in HHT patients that is thought to be related to a deficit of oxidative burst and phagocytosis—an immune system relationship beyond the AVM complications of vascular shunting HHT.<sup>24</sup> The combination of a weakened immune system and a faulty circulatory system allows for infections to find their way to necrotic regions in the brain.

Since our patient with HHT had metastases to the brain, we were interested to study the relationship between HHT and cancer. It would be reasonably expected that patients with such severe potential disease complications should have higher mortality rates than the general population. In contrast, several studies suggest that patients with HHT have improved survival outcomes and a reduced risk of cancer, especially prostate, abdominal, and lung cancer.<sup>25,26</sup> It is thought that the systemically reduced endoglin expression in HHT is responsible for the decreased risk.<sup>27</sup> But interestingly, recent data suggests that long-term endoglin deficiency may render endoglin deficient mice at enhanced risk of tumor metastatic spread.<sup>28</sup> In 1 study, the most common sites for metastasis were found to be the lung, liver, and brain in that order.<sup>26</sup> Brain metastases from cancers of the female genital tract, apart from choriocarcinoma, are rare. The primary mechanism of spread from the genital tract to the brain is by hematogenous dissemination of tumor cells to the lungs and then to the brain via the pulmonary vasculature.<sup>29</sup> We were curious to know whether the presence of PAVM increases the risk of cancer cell seeding from the lungs, but unfortunately could not find any literature supporting this.



**FIGURE 2.** CT scan of the lung demonstrating PAVM.

**TABLE 1.** Etiological Literary Review of HHT-Related Cultured Brain Abscesses

| Reference                        | Organism  | No. Cases |
|----------------------------------|---|-----------|
| Sobel and Norman <sup>30</sup>   | <i>Streptococcus mutans</i>   | 1         |
| Corre et al <sup>31</sup>        | Polymicrobial: <i>Fusobacterium nucleatum</i> , <i>S. epidermidis</i>   | 1         |
| Press and Ramsey <sup>32</sup>   | Anaerobic and microaerophilic streptococci (most common of 31), 1 case of meningitis  | 31        |
| Dupuis-Girod et al <sup>23</sup> | <i>Streptococcus</i> species (3), <i>Hemophilus aphrophilus</i> (3), <i>Actinomyces meyeri</i> (2),<br><i>Fusobacterium</i> species (2), <i>Eikenella corrodens</i> (1), <i>Micromonas micros</i> (1),<br><i>Peptostreptococcus micros</i> (1), Gram-positive cocci (1)   | 7         |
| Mylona et al <sup>33</sup>       | <i>Enterococcus faecalis</i>  | 1         |
| Diaz et al <sup>34</sup>         | Polymicrobial: MRSA, <i>Streptococcus intermedius</i> , <i>Candida guilliermondii</i>   | 1 (HIV+)  |
| Mathis et al <sup>35</sup>       | Anaerobic streptococci (most common of 26)  | 26        |
| Musso et al <sup>36</sup>        | <i>S. aureus</i>  | 5         |
| Chen and Lin <sup>37</sup>       | <i>A. meyeri</i>  | 1         |
| Koubaa et al <sup>38</sup>       | All cases were polymicrobial:<br>Case 1: <i>A. meyeri</i> , <i>S. intermedius</i> , <i>F. nucleatum</i> , <i>Capnocytophaga</i> species, <i>S. aureus</i><br>Case 2: <i>Actinomyces</i> , nonhemolytic streptococci, alpha hemolytic streptococci<br>Case 3: <i>Actinomyces</i> , Gram-positive cocci<br>Case 4: <i>Actinomyces odontolyticus</i> , <i>H. aphrophilus</i> , <i>Peptostreptococcus</i> , <i>Bacteroides</i> species<br>Case 5: <i>Actinomyces</i> species<br>Case 6: <i>Actinomyces</i> species<br>Case 7: <i>Actinomyces bovis</i><br>Case 8: <i>Actinomyces israelii</i> | 8         |

MRSA indicates Methicillin-resistant *Staphylococcus aureus*; HIV, human immunodeficiency virus.

In the general population, multiple predisposing factors and a number of microorganisms lead to the formation of brain abscesses. Immunodeficient patients and post-neurological/maxillofacial surgery patients are at high risk for bacteria, mycobacteria, fungi, or parasites crossing the blood-brain barrier. In these patients, the infection is usually caused by *Staphylococcus aureus* and *Staphylococcus epidermidis*, but can also be polymicrobial. The polymicrobials are usually anaerobic Gram negatives and/or positives.<sup>11</sup>

We were interested in understanding the differences in microbiology of brain abscesses in HHT and non-HHT patients. We collected the data regarding the causative organisms for brain abscess in HHT patients (Table 1) and non-HHT patients (Table 2) from several published articles using Medline search.

On analyzing the data, we found that it is common for PAVM/HHT patients to develop a myriad of infections including polymicrobial cerebral infections due to both anaerobic and aerobic organisms, with anaerobic organisms being responsible in most cases. As shown in Table 1, 13 of 15 organisms are capable

of thriving in little or no oxygen. Our findings correlate with the pathophysiology of development of brain abscess in HHT patients as mentioned before. The most common organism isolated was an aerobic *Streptococcus* species followed by *Actinomyces* species.

Non-HHT-related brain abscesses result due to the same mechanism as HHT brain abscesses, that is, via hematogenous spread, but usually result due to some sort of neurological trauma or immunodeficiency that predicates the cerebral infection.<sup>39</sup> Non-HHT-related cerebral infections are equally capable of being polymicrobial and equally diverse as in HHT, but less likely to be anaerobic.

### CONCLUSIONS

Patients with HHT are at substantially increased risk of serious neurologic complications. These patients are also predisposed to develop infections, and brain abscess is one of the most feared complication, which is commonly seen in these patients, and it is associated with high mortality. Cancer patients with HHT who present with neurological symptoms can pose a diagnostic

**TABLE 2.** Etiological Literary Review of Non-HHT-Related Brain Abscesses

| Reference                           | Organism (Most Commonly Isolated Are Displayed in Descending Order)  | No. Cases                    |
|-------------------------------------|--|------------------------------|
| Baradkar et al <sup>39</sup>        | <i>Candida albicans</i>  | 1                            |
| Seneviratne Rde et al <sup>40</sup> | Most common species was <i>Streptococcus milleri</i>   | 26                           |
| Prasad et al <sup>41</sup>          | <i>Streptococcus viridans</i> , <i>S. aureus</i> , <i>Bacteroides/Peptostreptococcus</i>   | 118                          |
| Sims et al <sup>42</sup>            | Streptococci, Enterobacteriaceae, Staphylococci, <i>Bacteroides</i>  | Unknown                      |
| Moazzam et al <sup>43</sup>         | <i>S. viridans</i> , <i>Actinomyces</i> , <i>Peptostreptococcus</i> , <i>Prevotella</i> , <i>Fusobacterium</i> ,<br><i>Aggregatibacter actinomycetemcomitans</i> , <i>E. corrodens</i> | 60 (All oral origin)         |
| Kommedal et al <sup>44</sup>        | Polymicrobial combinations of <i>Aggregatibacter aphrophilus</i> ,<br><i>F. nucleatum</i> , <i>S. intermedius</i>  | Prospective nationwide study |
| Haggerty and Tender <sup>45</sup>   | <i>Actinomyces</i>   | Unknown                      |
| Brouwer et al <sup>46</sup>         | <i>Streptococcus</i> , <i>Staphylococcus</i> species   | 9699                         |
| Collin et al <sup>47</sup>          | <i>S. aureus</i> , <i>Streptococcus</i> , <i>Bacteroides</i> , <i>Listeria</i> species   | Unknown                      |
| Mishra et al <sup>48</sup>          | <i>S. intermedius</i>  | Unknown                      |

challenge because of the possibility of metastasis. The possibility of brain abscess should be considered in all patients with HHT who present with focal neurological symptoms. The microbiology of brain abscesses in these patients is different from that seen in the general population, and they are more likely to develop brain abscess due to anaerobic microorganisms, with anaerobic *Streptococcus* species being the most common followed by *Actinomyces* species. Hence, the initial empiric antibiotic therapy should include adequate anaerobic coverage. Early and appropriate diagnosis and treatment is of utmost importance because of the high mortality associated with brain abscess.

## REFERENCES

- McDonald J, Bayrak-Toydemir P, Peyeritz RE. Hereditary hemorrhagic telangiectasia: an overview of diagnosis, management, and pathogenesis. *Genet Med*. 2011;13(7):607–616.
- Azuma H. Genetic and molecular pathogenesis of hereditary hemorrhagic telangiectasia. *J Med Invest*. 2000;47(3–4):81–90.
- Garzon MC, Huang JT, Enjolras O, et al. Vascular malformations. Part II: associated syndromes. *J Am Acad Dermatol*. 2007;56(4):541–564.
- Osler W. On a family form of recurring epistaxis, associated with multiple telangiectases of the skin and mucous membranes. *Bull Johns Hopkins Hosp*. 1901;12:333–337.
- Weber F. Multiple hereditary developmental angiomas (telangiectases) of the skin and mucous membranes associated with recurring haemorrhages. *Lancet*. 1907;ii:160–162.
- te Veldhuis EC, te Veldhuis HA, van Dijk FS, et al. Rendu-Osler-Weber disease: update of medical and dental considerations. *Oral Surg Oral Med Oral Pathol Oral Radiol Endod*. 2008;105(2):e38–e41.
- Bayrak-Toydemir P, McDonald J, Markewitz B, et al. Genotype-phenotype correlation in hereditary hemorrhagic telangiectasia: mutations and manifestations. *Am J Med Genet A*. 2006;140(5):463–470.
- Sabbà C, Pasculli G, Lenato GM, et al. Hereditary hemorrhagic telangiectasia: clinical features in ENG and ALK1 mutation carriers. *J Thromb Haemost*. 2007;5(6):1149–1157.
- Letteboer TG, Mager JJ, Snijder RJ, et al. Genotype-phenotype relationship in hereditary haemorrhagic telangiectasia. *J Med Genet*. 2006;43(4):371–377.
- Donaldson JW, McKeever TM, Hall IP, et al. Complications and mortality in hereditary hemorrhagic telangiectasia: a population-based study. *Neurology*. 2015;84(18):1886–1893.
- Brouwer MC, Tunkel AR, McKhann GM II, et al. Brain abscess. *N Engl J Med*. 2014;4(371):447–456.
- Sell B, Evans J, Horn D. Brain abscess and hereditary hemorrhagic telangiectasia. *South Med J*. 2008;101(6):618–625.
- Thompson RL, Cattaneo SM, Barnes J. Recurrent brain abscess: manifestation of pulmonary arteriovenous fistula and hereditary hemorrhagic telangiectasia. *Chest*. 1977;72:654–655.
- Alvis Miranda H, Castellar-Leones SM, Elzain MA, et al. Brain abscess: current management. *J Neurosci Rural Pract*. 2013;4(suppl 1):S67–S81.
- Tseng JH, Tseng MY. Brain abscess in 142 patients: factors influencing outcome and mortality. *Surg Neurol*. 2006;65(6):557–562.
- Kjeldsen AD, Oxhøj H, Andersen PE, et al. Pulmonary arteriovenous malformations: screening procedures and pulmonary angiography in patients with hereditary hemorrhagic telangiectasia. *Chest*. 1999;116(2):432–439.
- Olitky SE. Hereditary hemorrhagic telangiectasia: diagnosis and management. *Am Fam Physician*. 2010;82(7):785–790.
- Hall WA. Hereditary hemorrhagic telangiectasia (Rendu-Osler-Weber disease) presenting with polymicrobial brain abscess. Case report. *J Neurosurg*. 1994;81(2):294–296.
- Román G, Fisher M, Perl DP, et al. Neurological manifestations of hereditary hemorrhagic telangiectasia (Rendu-Osler-Weber disease): report of 2 cases and review of the literature. *Ann Neurol*. 1978;4(2):130–144.
- Dong SL, Reynolds SF, Steiner IP. Brain abscess in patients with hereditary hemorrhagic telangiectasia: case report and literature review. *J Emerg Med*. 2001;20(3):247–251.
- Shovlin CL. Iron deficiency, ischaemic strokes, and right-to-left shunts: from pulmonary arteriovenous malformations to patent foramen ovale? *Intractable Rare Dis Res*. 2014;3(2):60–64.
- Agamanolis DP. Chapter 5 infections of the nervous system. In: *Neuropathology: An Illustrated and Interactive Course for Medical Students*. 2014. Available at: <http://neuropathology-web.org/chapter5/chapter5aSuppurative.html>.
- Dupuis-Girod S, Giraud S, Ducellier E, et al. Hemorrhagic hereditary telangiectasia (Rendu-Osler Disease) and infectious diseases: an underestimated association. *Clin Infect Dis*. 2007;44(6):841–845.
- Cirulli A, Loria MP, Dambra P, et al. Patients with hereditary hemorrhagic telangiectasia (HHT) exhibit a deficit of polymorphonuclear cell and monocyte oxidative burst and phagocytosis: a possible correlation with altered adaptive immune responsiveness in HHT. *Curr Pharm Des*. 2006;12(10):1209–1215.
- Marinac CR, Natarajan L, Sears DD, et al. Prolonged nightly fasting and breast cancer risk: findings from NHANES (2009–2010). *Cancer Epidemiol Biomarkers Prev*;24:2015–789.
- Hosman AE, Devlin HL, Silva BM, et al. Specific cancer rates may differ in patients with hereditary haemorrhagic telangiectasia compared to controls. *Orphanet J Rare Dis*. 2013;8(1):195.
- Uneda S, Toi H, Tsujie T, et al. Anti-endoglin monoclonal antibodies are effective for suppressing metastasis and the primary tumors by targeting tumor vasculature. *Int J Cancer*. 2009;125:1446–1453.
- Anderberg C, Cunha SI, Zhai Z, et al. Deficiency for endoglin in tumor vasculature weakens the endothelial barrier to metastatic dissemination. *J Exp Med*. 2013;210:563–579.
- Ogawa K, Yoshii Y, Aoki Y, et al. Treatment and prognosis of brain metastases from gynecological cancers. *Neurol Med Chir (Tokyo)*. 2008;48:57–62.
- Sobel D, Norman D. CNS manifestations of hereditary hemorrhagic telangiectasia. *AJNR Am J Neuroradiol*. 1984;5(5):569–573.
- Corre P, Perret C, Isidor B, et al. A brain abscess following dental extractions in a patient with hereditary hemorrhagic telangiectasia. *Br J Oral Maxillofac Surg*. 2011;49(5):e9–e11.
- Press OW, Ramsey PG. Central nervous system infections associated with hereditary hemorrhagic telangiectasia. *Am J Med*. 1984;77(1):86–92.
- Mylona E, Vadala C, Papastathopoulos V, et al. Brain abscess caused by *Enterococcus faecalis* following a dental procedure in a patient with hereditary hemorrhagic telangiectasia. *J Clin Microbiol*. 2012;50(5):1807–1809.
- Diaz M, Cuellar J, Valencia-Rey PA, et al. Unsuspected polymicrobial brain abscess arising from an intra-abdominal source in a patient with hereditary hemorrhagic telangiectasia. *South Med J*. 2010;103(8):842–844.
- Mathis S, Dupuis-Girod S, Plauchu H, et al. Cerebral abscesses in hereditary haemorrhagic telangiectasia: a clinical and microbiological evaluation. *Clin Neurol Neurosurg*. 2012;114(3):235–240.
- Musso M, Capone A, Chinello P, et al. Extra-cerebral severe infections associated with hemorrhagic hereditary telangiectasia (Rendu-Osler-Weber Disease): five cases and a review of the literature. *Infez Med*. 2014;22(1):50–56.
- Chen KH, Lin CH. Brain abscess as an initial presentation in a patient of hereditary haemorrhagic telangiectasia caused by a novel ENG mutation. *BMJ Case Rep*. 2013:2013.
- Koubaa M, Lahiani D, Máloul I, et al. Actinomycotic brain abscess as the first clinical manifestation of hereditary hemorrhagic telangiectasia—case

- report and review of the literature. *Ann Hematol.* 2013;92(8):1141–1143.
39. [Baradkar VP, Mathur M, Kumar S. Cerebral candida abscess in an infant. \*Indian J Med Microbiol.\* 2009;27\(1\):70–72.](#)
40. [Seneviratne Rde S, Navasivayam P, Perera S, et al. Microbiology of cerebral abscess at the neurosurgical unit of the National Hospital of Sri Lanka. \*Ceylon Med J.\* 2003;48\(1\):14–16.](#)
41. [Prasad KN, Mishra AM, Gupta D, et al. Analysis of microbial etiology and mortality in patients with brain abscess. \*J Infect.\* 2006;53\(4\):221–227.](#)
42. [Sims L, Lim M, Harsh GR IV. Review of brain abscesses. \*Oper Tech Neurosurg.\* 2004;7\(4\):176–181.](#)
43. [Moazzam AA, Rajagopal SM, Sedghizadeh PP, et al. Intracranial bacterial infections of oral origin. \*J Clin Neurosci.\* 2015;22\(5\):800–806.](#)
44. [Kommedal O, Wilhelmsen MT, Skrede S, et al. Massive parallel sequencing provides new perspectives on bacterial brain abscesses. \*J Clin Microbiol.\* 2014;52\(6\):1990–1997.](#)
45. [Haggerty CJ, Tender GC. Actinomycotic brain abscess and subdural empyema of odontogenic origin: case report and review of the literature. \*J Oral Maxillofac Surg.\* 2012;70\(3\):e210–e213.](#)
46. [Brouwer MC, Coutinho JM, van de Beek D. Clinical characteristics and outcome of brain abscess: systematic review and meta-analysis. \*Neurology.\* 2014;82\(9\):806–813.](#)
47. [Collin T, Rull G, Bonsall A. Intracranial abscesses. \*Brain Cerebral Abscesses.\* Available at: <http://patient.info/doctor/intracranial-abscesses>. Accessed August 1, 2015.](#)
48. [Mishra AK, Dufour H, Roche PH, et al. Molecular revolution in the diagnosis of microbial brain abscesses. \*Eur J Clin Microbiol Infect Dis.\* 2014;33\(12\):2083–2093.](#)