



Minimal-change renal disease and Graves' disease: a case report and literature review

Citation

Hasnain, Wirasat, Isaac E. Stillman, and George P. Bayliss. 2011. "Minimal-change renal disease and Graves' disease: a case report and literature review." *NDT Plus* 4 (2): 96-98. doi:10.1093/ndtplus/sfq213. <http://dx.doi.org/10.1093/ndtplus/sfq213>.

Published Version

doi:10.1093/ndtplus/sfq213

Permanent link

<http://nrs.harvard.edu/urn-3:HUL.InstRepos:16120988>

Terms of Use

This article was downloaded from Harvard University's DASH repository, and is made available under the terms and conditions applicable to Other Posted Material, as set forth at <http://nrs.harvard.edu/urn-3:HUL.InstRepos:dash.current.terms-of-use#LAA>

Share Your Story

The Harvard community has made this article openly available.
Please share how this access benefits you. [Submit a story](#).

[Accessibility](#)

Case Report

Minimal-change renal disease and Graves' disease: a case report and literature review

Wirasat Hasnain¹, Isaac E. Stillman² and George P. Bayliss¹

¹ Division of Kidney Diseases and Hypertension, Brown University, Providence, RI and ² Department of Pathology and Renal Division, Department of Medicine, Beth Israel Deaconess Medical Centre, and Harvard Medical School, Boston, MA

Correspondence and offprint requests to: Wirasat Hasnain; E-mail: wirnain@hotmail.com

Abstract

Objective

To describe a possible association between Graves' disease and nephrotic syndrome secondary to minimal change renal disease and to review the literature related to renal diseases in patients with Graves' disease.

Methods

The clinical, laboratory, and renal biopsy findings in a patient with Graves' disease and minimal change renal disease are discussed. In addition, the pertinent English-language literature published from 1966 to 2009, determined by means of a MEDLINE search, is reviewed.

Results

A 63-year-old man who was admitted to the hospital with nephrotic syndrome. Patient had a history of Graves' disease for last 2 years with associated ophthalmopathy. He had been treated with methimazole and low low-dose steroids (prednisone 5 mg daily). Examination revealed generalized oedema and exophthalmoses. Laboratory tests showed 6.62 g/day of proteinuria. Antinuclear antibodies, anti-glomerular basement membrane antibodies, antineutrophil cytoplasmic antibody (ANCA), serum complement levels, cryoglobulin, hepatitis screen and serum and urine protein electrophoreses were normal. A kidney biopsy revealed features consistent with minimal change disease on light, immunofluorescence, and electron microscopy. The patient had an excellent clinical and laboratory response after treatment with steroids and near total thyroidectomy.

Conclusions

To the best of our knowledge, this is the fourth report of the occurrence of minimal change disease in a patient with

Graves' disease in the absence of any other immunologic disorder known to be associated with minimal change renal disease.

Keywords: Graves' disease; minimal change disease; nephrotic syndrome

Introduction

There have been several cases of thyroid diseases associated with glomerular diseases [1–6]. Published studies, however, have described only a few cases of the association of Graves' disease with primary renal diseases. We describe a patient with Graves' disease who had nephrotic syndrome due to minimal change disease (MCD) and discuss the potential pathogenic mechanisms involved in the renal lesions associated with autoimmune thyroid disease.

Case report

A 63-year-old Caucasian man with a past medical history of hypertension and Graves' disease was initially admitted to another hospital for a 30-pound weight gain, lower extremity edema and shortness of breath. There, he was treated for congestive heart failure with intravenous furosemide. His creatinine increased from a baseline of 1.1 mg/dL (97.2 µmol/L) to 1.7 mg/dL (150.2 µmol/L). Further workup revealed 7 g/day of proteinuria. The patient was transferred to our hospital for further evaluation and treatment. He was diagnosed with Graves' disease 2 years prior to admission when he experienced a 50-pound weight loss, weakness and fatigue. He was also noted to have exophthalmose, which was treated with radiation therapy. He has been on varying doses of methimazole for the last 2 years and on a dose of 5 mg daily for the last 8 months. His mother also had Graves' disease, and his father was diabetic. The patient himself had no history of diabetes, and

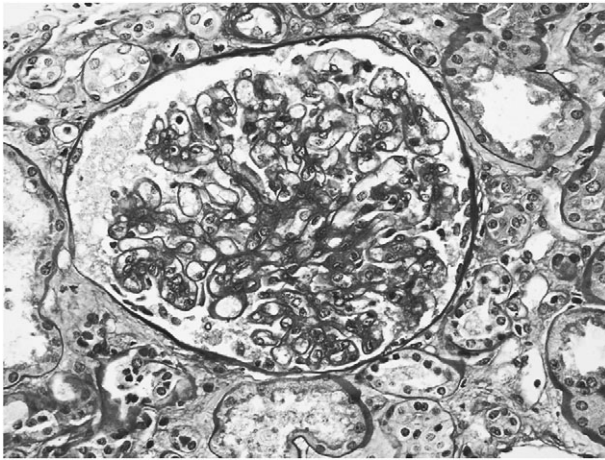


Fig. 1. Light microscopy revealed mild mesangial prominence and focal increase in endoluminal cells. No global or segmental glomerulosclerosis was noted. A proximal tubule (center, bottom) shows mild acute injury (PAS reaction, original magnification $\times 40$).

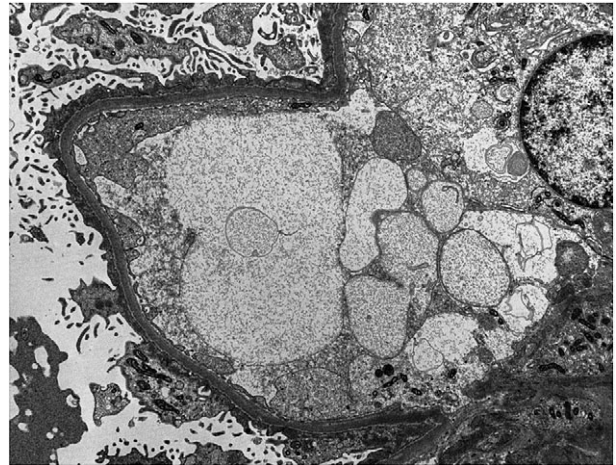


Fig. 2. Ultrastructural studies revealed widespread acute podocyte injury, with near total foot process effacement as well as microvillous transformation and condensation of the actin cytoskeleton. Some proteinaceous material is noted in the capillary lumen (electron microscopy, original magnification $\times 8000$).

his glycosylated hemoglobin A1c was 5.9%. He denied any prolonged use of nonsteroidal anti-inflammatory drugs.

Physical examination revealed an obese man with a blood pressure of 170/88 mmHg, a pulse rate of 52 beats/min and regular cardiac rhythm. Pertinent findings on systemic examination were right eye exophthalmose, lower extremity edema and clear lungs. The thyroid gland was not enlarged. No bruit was detected over the thyroid gland.

Laboratory evaluation revealed mildly elevated thyroid stimulating hormone of 5.59 mIU/L (normal, 3.5–5.5 mIU/L), normal free thyroxine (T4) of 1.01 ng/dL (12.99 pmol/L) (normal, 0.80–1.80 ng/dL) and a normal free triiodothyronine (T3) of 264 pg/dL (4.06 pmol/L) (normal, 230–420 pg/dL). Results of additional tests showed a mild normochromic, normocytic anemia; albumin 2.4 g/dL (24 g/L); normal lipid profile (on a statin) and creatinine 1.7 mg/dL (150.2 μ mol/L). Urinalysis showed only one red blood cell (RBC)/high power field and no casts. Spot urine protein-to-creatinine ratio was 6.62 g/day. His chest X-ray was normal and echocardiogram showed a left ventricular ejection fraction of 60%. Antinuclear antibodies, cryoglobulin, anti-streptolysin O, anti-glomerular basement membrane, serum complement (C3) level, hepatitis and antineutrophil cytoplasmic autoantibody (ANCA) screen were normal. Spun urine sediment was significant for dysmorphic RBCs, occasional hyaline casts containing RBCs and white blood cells and renal tubular epithelial cells.

A kidney biopsy was performed. Light microscopy revealed 12 glomeruli, none of which were globally or segmentally sclerotic. Glomeruli showed up to mild mesangial proliferation, with occasional foci of increased cells within capillary lumens (Figure 1). No endocapillary foam cells or podocyte hyperplasia/capping were noted. Some tubules showed focal acute injury but there were only minimal chronic changes in the vasculature and tubulointerstitium. Immunofluorescence microscopy (10 glomeruli present) showed no immunopositivity. Electron microscopy of two glomeruli confirmed the above findings and revealed near total podocyte foot process effacement with associated

microvillous transformation (Figure 2). While occasional small electron-dense deposits were identified in the mesangium, no subepithelial or subendothelial deposits were seen. Endocapillary cellularity was somewhat increased, associated with swollen endothelial cells (pathologist thinks this could be an artifact). A minute focus of podocyte stripping with reparative changes of the basement membrane and a possible adhesion was present. However, no unequivocal changes of segmental sclerosis were seen. The findings were therefore felt to be consistent with MCD.

The patient was started on prednisone (1 mg/kg) but heavy proteinuria persisted (11 g/day) despite being on steroids for 2 weeks. Three weeks after the presentation, the patient underwent near total thyroidectomy and repeat laboratory work 2 weeks later showed a significant reduction in proteinuria (0.44 g/day). His creatinine also improved to 1.0 mg/dL (88.4 μ mol/L). Methimazole was stopped. The patient remained on prednisone for 6 months with resolution of edema, nephrotic range proteinuria and atypia of the urine sediment. The clinical course and response to treatment was felt to confirm the diagnosis of MCD.

Discussion

Autoimmune thyroid diseases are occasionally associated with glomerular diseases. A few case reports have been published in the medical literature, as determined by a MEDLINE search of English-language publications for the interval from 1966 to 2010. Glomerular disease in association with Graves' disease may be attributable to an unknown cause or to the use of antithyroid drugs or radioactive iodine treatment. Membranous glomerulonephritis is the most commonly reported renal disease in patients with Graves' disease [3] but over the last decade, there have been a few case reports of Graves' disease associated with MCD. In 2002, Tanwani *et al.* [7] reported a case of the concomitant occurrence of Graves' disease and MCD. In

the same year, Holt *et al.* [8] reported the case of a patient in whom Graves' disease and MCD were diagnosed simultaneously and in whom relapse of the Graves' disease was invariably accompanied by relapse of MCD. More recently, Esteve *et al.* [9] reported the case of a patient who was diagnosed with Graves' disease and was started on methimazole therapy. She subsequently developed MCD, which the authors attributed to hypothyroidism caused by antithyroid therapy.

MCD has been reported in association with other autoimmune diseases, including other autoimmune thyroid diseases. In 1996, Mundlein *et al.* [6] reported a case of Graves' disease, sarcoidosis and MCD. The patient was diagnosed with MCD in 1984 and had a relapse in 1994. Graves' disease and sarcoidosis were diagnosed in April 1995. In 1996, the patient had concurrent relapses of minimal change nephropathy and Graves' disease [10]. Nishimoto *et al.* [11] reported a case of concomitant occurrence of minimal change nephropathy, sarcoidosis and Hashimoto's thyroiditis. A case report of IgA nephropathy, sarcoidosis and chronic thyroiditis has also been described in the literature [12]. At the same time, glomerular disease has been reported to occur in association with sarcoidosis in the absence of autoimmune thyroid disease [13, 14]. In our patient, no clinical or radiologic evidence of sarcoidosis was observed. Methimazole has been reported to be associated with MCD [15] but our patient was on methimazole for 2 years before he developed MCD. The literature also suggests a high frequency of occurrence of ANCA positivity in propylthiouracil and methimazole-treated patients with Graves' disease. In our patient, ANCA screen was negative.

The mechanism involved in the pathogenesis of MCD in association with Graves' disease is unclear. Some investigators have suggested, however, that MCD may be a disorder of cell-mediated immunity. T lymphocytes secrete various cytokines that may damage the glomerular epithelial cells and increase the permeability of proteins [16, 17]. In addition, several studies suggest that cytokines have an important role in the evolution of autoimmune thyroid diseases, such as Hashimoto's thyroiditis and Graves' disease [18]. Thus, concomitant occurrence of MCD in association with autoimmune thyroid disease suggests an abnormality of the immune system common to both disorders.

Conclusion

To our knowledge, this is the fourth case report of the concomitant occurrence of Graves' disease and minimal change nephropathy in the absence of any other immunologic condition known to occur in association with minimal change nephropathy. In addition, this case report provides further evidence that the two diseases may be linked to each other by some unknown immune mechanism, as suggested

by Mundlein *et al.* [6]. Patients with concurrent autoimmune thyroid disease and nephrotic syndrome should undergo renal biopsy, inasmuch as the treatment and prognosis varies for each histologic entity. Documentation and investigation of such cases may provide further insights into the immunopathogenesis of minimal change glomerulonephritis.

Conflict of interest statement. None declared.

References

1. Paydas S, Gokel Y. Different renal pathologies associated with hypothyroidism. *Ren Fail* 2002; 24: 595–600
2. Mahjoub S, Ben Dhia N, Achour A *et al.* Primary hypothyroidism and glomerular involvement. *Ann Endocrinol (Paris)* 1991; 52: 289–292
3. Becker BA, Fenves AZ, Breskau NA. Membranous glomerulonephritis associated with Grave's disease. *Am J Kidney Dis* 1999; 33: 369–373
4. Weetman AP, Pinching AJ, Pussell BA *et al.* Membranous glomerulonephritis and autoimmune thyroid disease. *Clin Nephrol* 1981; 15: 50–51
5. Valentín M, Bueno B, Gutiérrez E *et al.* Membranoproliferative glomerulonephritis associated with autoimmune thyroiditis. *Nefrología* 2004; 24 (Suppl 3): 43–48
6. Mundlein E, Greten T, Ritz E. Graves' disease and sarcoidosis in a patient with minimal-change glomerulonephritis. *Nephrol Dial Transplant* 1996; 11: 860–862
7. Tanwani LK, Lohano V, Broadstone VL *et al.* Minimal change nephropathy and Graves' disease: report of a case and review of the literature. *Endocrine Practice* 2002; 8: 40–43
8. Holt S, Kingdon E, Morganstein D *et al.* Simultaneous relapse of Graves' disease and minimal change glomerular disease. *Nephrol Dial Transplant* 2002; 17: 666–668
9. Esteve V, Fontseré N, Saurina A *et al.* Graves disease, hypothyroidism, and minimal-change glomerulonephritis. *Nefrología* 2008; 2: 230–231
10. Ritz E. Simultaneous relapse of minimal-change glomerulonephritis and Graves disease. *Nephrol Dial Transplant* 1997; 12: 1538–1545
11. Nishimoto A, Tomiyoshi Y, Sakemi T *et al.* Simultaneous occurrence of minimal change glomerular disease, sarcoidosis and Hashimoto's thyroiditis. *Am J Nephrol* 2000; 20: 425–428
12. Nishiki M, Murakami Y, Yamane Y *et al.* Steroidsensitive nephrotic syndrome, sarcoidosis and thyroiditis—a new syndrome? *Nephrol Dial Transplant* 1999; 14: 2008–2010
13. Parry RG, Falk C. Minimal-change disease in association with sarcoidosis. *Nephrol Dial Transplant* 1997; 12: 2159–2160
14. Taylor RG, Fisher C, Hoffbrand BI. Sarcoidosis and membranous glomerulonephritis: a significant association. *Br Med J (Clin Res Ed)* 1982; 284: 1297–1298
15. Reynolds LR, Bhatena D. Nephrotic syndrome associated with methimazole therapy. *Arch Intern Med* 1979; 139: 236–237
16. Koyama A, Fujisaki M, Kobayashi M *et al.* A glomerular permeability factor produced by human T cell hybridomas. *Kidney Int* 1991; 40: 453–460
17. Matsumoto K, Kanmatsuse K. Increased IL-12 release by monocytes in nephrotic patients. *Clin Exp Immunol* 1999; 117: 361–367
18. Spitzweg C, Morris JC. The immune response to the iodide transporter. *Endocrinol Metab Clin North Am* 2000; 29: 389–398, viii

Received for publication: 12.4.10; Accepted in revised form: 13.12.10