

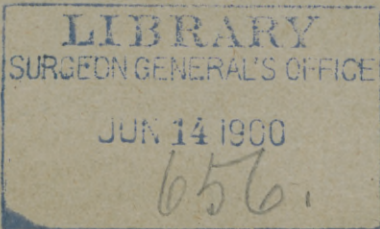
WHITE (J.C.)

HYDROA VACCINIFORME?

BY

JAMES C. WHITE, M.D.,
Professor of Dermatology in Harvard University.

REPRINTED FROM THE JOURNAL OF
CUTANEOUS AND GENITO-URINARY DISEASES,
FOR NOVEMBER, 1898.



HYDROA VACCINIFORME¹

By JAMES C. WHITE,
Professor of Dermatology in Harvard University.

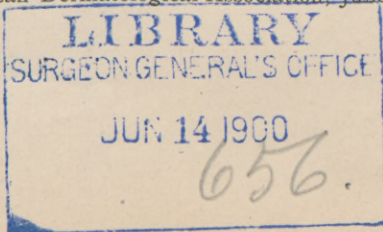
ASK your attention to a report of some cases questionably of this infrequent affection, which present some unusual features, and I will first make brief mention of two instances I find recorded in my unpublished "memorabilia," which may recall to you the typical phases of the disease.

1. A boy, seven years old, came to my clinic at the Massachusetts General Hospital late in the month of April. The changes in his skin had begun three weeks previously, after a few hot days. His face presented upon the sides large umbilicated vesicles, some of them a third of an inch in diameter. The ears were much swollen and generally occupied by similar confluent lesions; on the backs of the hands and wrists they were smaller and less abundant. The contents of some of the vesicles were hemorrhagic and some of the lesions were covered by crusts. In addition to these appearances of recent date, there were pits or scars of various sizes upon the face and ears, a sequel of a similar attack during the previous summer. Cultures from the contents of the vesicles were sterile.

2. A boy, ten years old, was brought to me April 24th, who had a sparse eruption of large vesicles, some of which were already crusted upon the face and limbs. A few were noticed upon the trunk also. The lesions resembled those of chicken-pox, and were of one-week's duration. The continued development of the efflorescence for some time under observation proved the case to be not a varicella. The mother reported that the child had had one or two similar attacks each summer of three previous years, and these attacks had left many shallow white depressions, still visible, situated principally upon the extremities.

Other instances of the affection, which I have observed in children, might be mentioned, in which the lesions were confined to the ears and backs of the hands, characterized by their umbilicated and necrotic condition, their recurrency, and cicatricial sequelæ. These are the typical features of the disease first described by Bazin under the title hydroa vacciniforme. How widely the cases I now present differ from, or exceed this type, the following description will show:

¹ Read at meeting of American Dermatological Association, June 1, 1898.



In March, 1897, two children were brought to my clinic, a girl aged ten years, and a boy eighteen months old. They were of healthy American parentage.

Case I.—The mother related the history of the girl as follows: “She was an apparently healthy child until she was eight months old, when in the month of December a spot, the size of a pea, appeared, which became a blister and broke. A small crust formed, which dropped off in about three weeks, leaving a scar. By the time the first one had healed others had made their appearance on the legs and arms, some of them being dry, some very sore, and some of them running with pus. As fast as one crop began to heal another would break out, until the following April they all dried up, and she was not troubled any more until the next November, when they broke out again. They have been coming about the same ever since, breaking out in November and healing up in April. Her general health has always been very good.”

At the time this patient was first seen by me the statement was made that the seats of the eruption had been the face, ears, hands to the elbows, and the feet up to the knees. The central face and ears presented at that time many pitted scars. The hands and forearms looked as if scarred by a burn, and the lower legs showed similar appearances. The disease had been in a state of marked activity upon these parts during the previous winter, but then showed only a few fresh, poorly developed, flat, large vesicles. During the past winter, 1897-98, it has awakened as usual after its summer quiescence, there having been three severe outbreaks of vesicular and bullous efflorescence. At the present time, March 1st, there are only a few fresh lesions.

Case II., the boy. The mother states that “in April following his birth he had chicken-pox, and immediately afterward an eruption appeared in the form of small pimples, which became water-blisters the next day and broke, leaving either running sores or crusts, and later dark marks. They affected the feet, buttocks, hands and arms, and face. In November and December they dried up a little for a while, but in January they broke out again worse than ever. At this time he was seen by Dr. Tirrell of South Weymouth, who kindly sends me the following report:

“I first saw the patient when he was four months old. He had what I called pemphigus. The lesions were located upon the buttocks only. I was called to see him again January, 1897. When I reached there his mother told me that he had had a convulsion. He had a temperature of 103° F., pulse 125-130, and had every symp-

tom of the beginning of some infective disease. The next day the mother called my attention to the right arm, which was red and swollen, a general blush throughout the arm from finger-tips to the shoulder. The day after, the upper part of the arm from elbow to shoulder was covered with erythematous spots, size of small peas, which quickly developed into pustules, which ruptured, and became crusted in a day or two. On the hand the process extended beneath the skin, and required cutting to allow the pus to escape." This attack seems to have been a form of localized dermatitis, quite distinct from the process elsewhere presented.

On his first visit to me, March, 1897, the face and extremities below the elbows and knees were thickly occupied by large vesicles and small bullæ, which were partly in an excoriated or crusted condition. Some of them presented hemorrhagic contents and black bases. Mingled with these were a few urticaria-like lesions, but of considerable duration. Deep-pitted scars were thickly interspersed among the fresh lesions on all the affected parts. The alæ of the nose had undergone partial destruction, being deeply notched, and the ears were very thin and nicked. The child's general condition was good.

A year later I saw him again. The mother reported that there had been fresh attacks nearly every month in the interval, and that they were more severe in cold weather. At this visit in March the disease was not in a state of activity and his condition was recorded as follows:

Face.—Above the eyebrows there are scars slightly fibrous, some of them red, some of a yellowish color. Between the eyes small white pits looking like smallpox scars. On the tip of the nose the cicatrices are more recent and larger, and one of them is still surmounted by a crust. The alæ of the nose are partly destroyed. On the cheeks and about the mouth there are several large scars of a reddish color, the largest of which is nearly an inch in diameter. Along the borders of the ears there is some loss of substance, and a few scabs are present.

Arms and Legs.—The little and third fingers of the right hand are ankylosed as in the main *en griffe*. The other fingers of both hands are covered with depressed cicatrices, some of which are surmounted by thick brown crusts. The arms show the effects of the process in a degree diminishing as we approach the trunk. The same is true of the legs. Near the wrists and ankles very little normal skin remains. The limbs are thickly covered with scars of varying ages. The older ones are white, the more recent ones are covered with

brownish or red crusts. All the scars are depressed. The trunk is quite free from any evidences of the disease.

In a recent paper,¹ Dr. McCall Anderson calls attention to the condition of the urine in the case of two brothers affected with this disease under his observation. During the outbreak of the efflorescence and for some time afterward, the urine was of a Burgundy-wine color, and was found to contain a peculiar pigment allied to urohematoporphyrin, to be recognized by the spectroscope, for which he proposes the name mei-ode-oxyhematoporphyrin. Desirous of learning if any such condition of the urine existed in my cases, a specimen from the younger patient was kindly examined by Professor Wood of Harvard University, who did not find any of this pigment in it. The mother stated that she had never noticed a high-colored urine from either child at any time. It must be remembered, however, that the disease was in a quiescent state at the time of the analysis, and possibly such pigment may not be formed in early childhood under any conditions.

Much attention has also been given of late to the condition of the cell elements of the blood in dermatoses of vesicular and bullous type especially. In dermatitis multiformis, in pemphigus, and after vaccination the eosinophiles have been found greatly increased both in the blood and the fluid contents of the vesicles and bullæ. In a recent case of the former under my observation, ninety-three per cent. of the cells of the fluid in the vesicles were of this variety. An examination of blood of the younger patient was accordingly made by Dr. Richard Cabot, whose special knowledge in this branch of research is well known to you. The reports follow:

BLOOD REPORT.

Blood obtained from McCormick of O. P. D., February 16, 1898.

Showed dermatitis herpetiformis.

Red Corpuscles	} Ratio 1:	
White Corpuscles		
Hemoglobin	oo	(Fleischel)
Color Analysis (Erich) of 200 leucocytes showed:—		
Polymorphonuclear neutrophiles.....		54.5 per cent.
Lymphocytes.....		30. "
Large mononuclear and transitional cells.....		7. "
Eosinophiles.....		8.5 "
Adventitious Forms	} Large myelocytes (over 13 m) } } Small " (under 13 m) }	None.

While counting these, no normoblasts and no megaloblasts were seen.

¹ *British Medical Journal of Dermatology*. January, 1898.

Remarks:—

The fluid from the vesicles was crowded with eosinophiles—ninety-three per cent. of all the cells being of this variety.
The blood shows also a marked increase.

R. C. CABOT.

BLOOD REPORT.

Blood obtained from Dr. J. C. White of Boston, February 8, 1898.

Showed Red Corpuscles normal in size and shape and apparently in number,

White Corpuscles not increased.

Hemoglobin normal.

Color Analysis (Erlich) of 500 leucocytes showed:—

		Normal.
Polymorphonuclear neutrophiles.....	40.8 per cent.	65 per cent
Lymphocytes.....	42.4 “	28 “
Large mononuclear and transitional cells....	8.6 “	6. “
Eosinophiles.....	8.2 “	1 to 3 “

Adventitious Forms } Large myelocytes (over 13 *m*) } None.
 } Small “ (under 13 *m*) }

While counting these, no normoblasts and no megaloblasts were seen.

Remarks:—

The eosinophiles are markedly increased. For an adult the percentage of the lymphocytes is considerably increased at the expense of the polymorphonuclear cells. For children this is normal.

There is no evidence of anemia nor of leucocytosis.

R. C. CABOT.

BLOOD REPORT.

Blood obtained from case of *Hydroa Estivale* of February 16, 1898.

Showed

Red Corpuscles }
White Corpuscles } Ratio 1:

Hemoglobin diminished.

Color Analysis (Erlich) of 100 leucocytes showed:—

Polymorphonuclear neutrophiles.....	34 per cent.
Lymphocytes.....	43 “
Large mononuclear and transitional cells.....	8 “
Eosinophiles.....	15 “

Adventitious Forms } Large myelocytes (over 13 *m*)
 } Small “ (under 13 *m*)

While counting these, normoblasts and megaloblasts were seen.

Remarks:—

The eosinophiles even more numerous than before. Anemia now appearing.

R. C. CABOT.

So far as I know a similar investigation of the blood in this disease has not been reported for comparison, but our knowledge of

its condition in this direction in affections of the skin is at present too limited to permit any deduction of value as to its significance in the way of differential diagnosis.

In connection with these cases it is interesting to note that another child in the family, a boy, had, when six months old, an eruption, described by the mother as similar, upon the face, arms, and legs, but he died three months later of "typhoid pneumonia." There are five other children in the family, and they, as well as the parents, are in good health. Nothing resembling the affection is known to have occurred in preceding generations of the family.

Possibly if I could present these little patients for inspection here to-day, some of you might doubt the correctness of the diagnosis of their disease I have suggested. The cases differ indeed widely from the ordinary type of the affection and from those first cited by myself, but chiefly in the way of exaggeration. Let me quote Bazin's original description of the disease given in his "Affections Cutanées de Nature Arthritique et dartreuse," Paris, 1860:

HYDROA ARTHRITIQUE. DEUXIEME VARIÉTÉ.

L'hydroa vacciniforme n'est pas connu des auteurs, l'année dernière j'eus l'occasion d'observer cette singulière éruption. J'envoyai mon malade consulter plusieurs médecins des hôpitaux; les uns crurent qu'il s'agissait d'une affection syphilitique, d'autres ne se prononcèrent pas sur la nature de cette éruption. L'affection durait depuis un an et avait été combattue sans succès par les moyens les plus variés.

L'hydroa vacciniforme apparaît à la suite d'une promenade au grand air ou après l'exposition à un soleil ardent. Il existe un peu de malaise, de l'anorexie; l'éruption se montre d'abord sur les surfaces découvertes, puis sur les autres parties du corps. La muqueuse buccale est aussi envahie par l'affection. On voit en premier lieu des taches rouges, sur les quelles naissent bientôt des vésicules transparentes qui ressemblent à celles qu'on observe dans l'herpès. Des le second jour ces vésicules, qui sont, arrondies, présentent une ombilication très évidente; en peu de temps il se forme une croûte successivement au centre et à la circonférence de la vésicule. Lorsque cette croûte se détache, elle laisse une cicatrice déprimée; chez le malade dont nous parlions plus haut les cicatrices nombreuses qui couvraient la surface du corps auraient pu faire croire à l'existence antérieure d'une variole. L'affection se prolonge par des poussées successives pendant des mois; dans le cas qui nous rapportons, l'hydroa vacciniforme a duré six mois.

From the time when this description of the disease as an individual affection was published until Mr. Hutchinson again called attention to it in his account of a case of "summer eruption" in 1888 it escaped recognition, but within the past ten years many dermatologists have written upon it, and in one of the latest of these articles by Professor Mibelli of Parma, a long bibliography of these pub-

lications is given. From a study of the cases therein referred to it appears that the commonly accepted definition of the disease, as follows, is too narrow: It begins between the first and third years of life, almost exclusively in boys; the attacks occur in spring and summer after exposure to the sun; the lesions consist of small and large vesicles, which coalesce to form large bullæ, and are seated upon the face, ears, wrists, and hands; they are often depressed in the center, like those of vaccinia, and present a dark sunken base from hemorrhage or necrosis; crusts succeed, followed by scars resembling those of smallpox. The most notable deviations from this type which have been recorded are its appearance for the first time as late as the tenth year, its occurrence in girls, and in winter exclusively, or throughout the year.

The most striking and exceptional features in my own cases are the cessation of all activity in the process during the warm months for ten consecutive years in the girl, the all-the-year-round outbreaks in the boy, the failure to be especially influenced by exposure to sun or weather, the extensive distribution of the cutaneous changes in both cases (affecting large portions of the legs and arms beyond its usual seats), the large size and long duration of the individual lesions, the magnitude of the subsequent cicatrices, and the great disfigurement observed from time to time, and judged by the immediate appearance of individual lesions the case of the boy might suggest exceptional forms of:

1. The herpes iris type of generalized erythema multiforme,
2. Dermatitis multiformis (herpetiformis of Duhring).
3. Pemphigus.
4. Epidermolysis bullosa hereditaria.
5. Bullous syphiloderma.

Indeed, I think we may recognize a close affiliation between the first two affections and hydroa estivale or vacciniforme, and must acknowledge that although the ordinary types of all three are clearly defined, there are many cases where the dividing lines cannot be sharply drawn. The case of the boy, in fact, has been pronounced pemphigus, syphilis, and dermatitis herpetiformis by physicians who have seen it at various times. The noteworthy differential points in diagnosis may be briefly stated. Erythema multiforme does not run a continuous twelve-months' course, present lesions of a large size uniformly, or leave scars, at least of this character. Dermatitis multiformis would scarcely confine itself absolutely to the localities here affected in so long a course as that of the girl, nor has it ever been known to produce such scars and disfigurement. Dr. Duhring kindly

sends me the following valuable opinion upon this point: "I believe scarring may occur in dermatitis herpetiformis, but it is rare, especially in a marked form, and I regard such cases as peculiar, that is where scars exist a year or two after the eruption has disappeared."

In a recent discussion on dermatitis herpetiformis in the London Dermatological Society several members spoke of having observed the occurrence of "temporary (?) superficial scars."

Pemphigus, too, would be more generalized, would present plumper bullæ at first, and could not persist over such period of time, as have these cases, without grave results upon the system, nor does it cause such scars.

In epidermolysis the lesions appear generally as the result of direct mechanical influences, as pressure on friction, and upon parts especially accessible to such influences. They are always of short duration, and leave no permanent marks of their seat. In this connection it may be added that the children have never had excessive sweating, that their nails are not diseased, that their teeth are perfectly developed, that the bullæ are never the result of direct pressure and never occur within the mouth, and that no milia or "epidermic pearls" have ever formed in the vicinity of the lesions.

Syphilis of a bullous type in children might present such appearances. The lesions upon the palms and soles, the large scars, the contraction of the fingers, and the destruction or notching of the alæ of the nose might well raise the question of its possible existence here. But bullous syphilis is one of the most malignant types of the disease. It could not exist of so wide a distribution for two and a half years persistently without the gravest results, certainly not ten years, as in the girl. Here there is no cachexia in either case. Nor does it present so sharply defined an intermittent type. Such syphilitic lesions lead to deep ulcerations. Here none have occurred. Moreover, the most characteristic signs of syphilis in children, the tegumentary changes about anus and lips, those within the mouth and nostrils are wanting. Nor is there any bone disease. It is interesting to remember in this connection that in the case reported by Dr. McCall Anderson, above referred to, there was the same nicking of the nose and contraction of the fingers, as his photographic illustration well shows. (See article.)

So far as the subjective symptoms are of diagnostic importance, it may be added that in the case of the girl there has never been any itching "except when the attacks are dying away," whereas in the boy the skin always itches greatly during the active stages of the disease.

The final question now arises. Where shall we place these extraordinary cases? They vary from every normal type of dermatosis known to us in many features. Shall we regard them as exceptional forms of dermatitis multiformis as modified in course, and by the graver tissue changes resulting in general scar formation, incidental to childhood? I have seen this affection in other children pursue its ordinary course, and leave no permanent mark of its presence, and Unna's "hydroa puerorum" is certainly a different affection. I, too, have seen slight scarring follow the pustular forms of dermatitis multiformis in adults, but none approaching these in gravity. Or shall we enlarge our definition of hydroa vacciniforme so materially as to admit the protean and exaggerated character, and the indefinitely prolonged duration of the lesions, with their atypical relations to seat and season, which characterize these cases?

To me the latter conclusions seem the less forced, and I must, therefore, adopt it, unless we are prepared to establish a new position for them in our system of classification.

