

## Invited Review

# Classification of salivary gland tumours - a brief histopathological review

R.H.W. Simpson

Department of Histopathology, Postgraduate Medical School, University of Exeter, Exeter, England

**Summary.** Tumours of the salivary glands display a wide variety of histological appearances, and vary in behaviour from totally benign to high grade and usually fatal malignancies. Over the past 40 years several classification schemes have been proposed, of which the most comprehensive and accurate are those of the Armed Forces Institute of Pathology (AFIP) and the World Health Organization (WHO) which were both revised in 1991. They are readily applicable by practising surgical pathologists, and encompass most of the range of tumours likely to be encountered. If I have a slight preference, it is for the WHO classification which is more concise. This paper briefly discusses each tumour, and highlights the changes from previous classifications, including the proper recognition of several newly described tumours which are distinct clinico-pathological entities. Neither of the new schemes solves every problem, and brief attention is drawn to defects. These are minor, and do not significantly detract from the advantages of both new classifications, which represent a major advance in our ability to understand these often perplexing tumours.

**Key words:** Salivary gland neoplasms, Classification

### Introduction

Neoplasms arising within the major and minor salivary glands exhibit a wide variety of microscopic appearances - often within a single lesion. Therefore, classification of these tumours has presented considerable problems. From 1954 to 1986, six schemes were proposed (Foote and Frazell, 1954; Evans and Cruickshank, 1970; Tachkay and Sobin, 1972; Tachkay and Lucas, 1974; Batsakis, 1979; Seifert et al., 1986b), of which the World Health Organization (WHO) Classification (Thackray and Sobin, 1972) was perhaps

the most widely adopted. However, actually using it (and the others) in practice became increasingly difficult, particularly as various new clinico-pathological entities were described. A revised classification was clearly needed, and two new schemes have been published more recently which correct many, but not all, of the defects in the earlier ones.

They are the AFIP morphologic classification of Ellis et al. (1991), and the revised WHO classification (Seifert and Sobin, 1991) (Table 1). Both recognize the great variety of adenomas and replace the imprecise term «monomorphic adenoma». There are separate categories for several new carcinomas which are distinct clinico-pathological entities, and both rightly upgrade acinic cell and mucoepidermoid «tumours» to the carcinomas they undoubtedly are. The AFIP classification also divides carcinomas into low, intermediate and high grades of malignancy. Whilst this has advantages, it does lead to a greater degree of complexity.

Both of these classifications represent great improvements on their predecessors, and I would certainly advocate the adoption of one or other by all diagnostic surgical histopathologists. Which one depends as much on personal choice, but my preference is for the WHO one, as it is more concise, but still allows most tumours to be correctly classified.

### Adenomas

Warthin's tumour (adenolymphoma) with its characteristic microscopic appearance of eosinophilic columnar cells and lymphoid stroma presents few problems in diagnosis, and it has been recognized as a separate tumour by all classifications. Rare variants show metaplasia of the epithelium to goblet, sebaceous or squamous cells.

Pleomorphic adenoma (mixed salivary tumour) has also retained a separate category in all classifications. It is composed of small ducts, myoepithelial cells and a myxochondroid stroma. In its classic form it too is easy to diagnose, but the proportion of each constituent often varies greatly, and may cause problems in practice. The

**Table 1.** Revised WHO histological classification of salivary gland tumours.

---

<b>1. Adenomas</b>
1.1. Pleomorphic adenoma
1.2. Myoepithelioma (myoepithelial adenoma)
1.3. Basal cell adenoma
1.4. Warthin tumour (adenolymphoma)
1.5. Oncocytoma (oncocytic adenoma)
1.6. Canalicular adenoma
1.7. Sebaceous adenoma
1.8. Ductal papilloma
1.8.1. Inverted ductal papilloma
1.8.2. Intraductal papilloma
1.8.3. Sialadenoma papilliferum
1.9. Cystadenoma
1.9.1. Papillary cystadenoma
1.9.2. Mucinous cystadenoma
<b>2. Carcinomas</b>
2.1. Acinic cell carcinoma
2.2. Mucoepidermoid carcinoma
2.3. Adenoid cystic carcinoma
2.4. Polymorphous low grade adenocarcinoma (terminal duct adenocarcinoma)
2.5. Epithelial-myoepithelial carcinoma
2.6. Basal cell adenocarcinoma
2.7. Sebaceous carcinoma
2.8. Papillary cystadenocarcinoma
2.9. Mucinous adenocarcinoma
2.10. Oncocytic carcinoma
2.11. Salivary duct carcinoma
2.12. Adenocarcinoma
2.13. Malignant myoepithelioma (myoepithelial carcinoma)
2.14. Carcinoma in pleomorphic adenoma (malignant mixed tumour)
2.15. Squamous cell carcinoma
2.16. Small cell carcinoma
2.17. Undifferentiated carcinoma
2.18. Other carcinomas
<b>3. Non-epithelial tumours</b>
<b>4. Malignant lymphomas</b>
<b>5. Secondary tumours</b>
<b>6. Unclassified tumours</b>
<b>7 Tumour-like lesions</b>
7.1. Sialadenosis
7.2. Oncocytosis
7.3. Necrotizing sialometaplasia (salivary gland infarction)
7.4. Benign lymphoepithelial lesion
7.5. Salivary gland cysts
7.6. Chronic sclerosing sialadenitis of submandibular gland (Kuttner tumour)
7.7. Cystic lymphoid hyperplasia in AIDS

---

varied appearance is really a spectrum that includes not only pleomorphic adenoma, but also myoepithelioma at one end and predominantly ductal adenomas at the other (Barnes et al., 1985). There is a valid case for «lumping» the entire group of tumours together, but I favour the retention of such terms as myoepithelioma, because these tumours simply look different and pose their own problems in differential diagnosis. However, further subdivision of pleomorphic adenoma as advocated by

some authors (Seifert et al., 1986b) is, I feel, of unproven value.

Benign myoepitheliomas exhibit several growth patterns - solid, reticular, myxoid or various combinations. The component cells may be spindle shaped, plasmacytoid (hyaline), epithelioid, rarely clear or a mixture of any of these (Dardick et al., 1989). Many authors also feel that an otherwise typical tumour with a small number of ducts should still be called a myoepithelioma.

Both new classifications have dropped the term «monomorphic adenoma» as it became apparent that this term encompassed several distinct entities, some of which were not even benign. For example, the 1972 WHO classification included in this category a «clear cell adenoma» which would now be recognized as an epithelial-myoepithelial carcinoma.

Basal cell adenoma is the tumour that previously accounted for most monomorphic adenomas. It is composed of basaloid cells with a prominent basal layer and basement membrane. There are three subtypes: solid, trabecular-tubular and membranous. The first two are probably different patterns of the same tumour, but the membranous (dermal analogue tumour) may well be a separate entity. There is a significant association with skin appendage tumours (typically cylindromas), and it has a seven-fold increased risk of malignant transformation - 28% compared with 4% for other basal cell adenomas (Batsakis et al., 1991).

Canalicular adenoma (Fig. 1) also has a basaloid appearance with a characteristic morphology of anastomosing bi-layered strands of darkly staining cells set in a loose vascular stroma. It is usually small, and most cases occur in the upper lip.

Oncocytoma (oncocytic adenoma) is a well demarcated tumour composed of cells with intensely eosinophilic granular (or rarely, clear) cytoplasm, the result of large numbers of mitochondria. They stain dark blue with phosphotungstic acid-haematoxylin (PTAH), and although some glycogen may be present, the granules are negative with periodic acid-Schiff (PAS) after diastase digestion. These staining reactions are the opposite to those seen in acinic cell carcinoma. Electron microscopy confirms that the granules are indeed mitochondria. Oncocytic adenoma has the same appearance as one of the nodules in multifocal oncocytic adenomatous hyperplasia, which is classified as a tumour-like lesion by the revised WHO scheme. The gland (usually the parotid) contains numbers of nodules of varying sizes composed of cells with oncocytic and often clear cytoplasm (Ellis, 1988). The condition is not infrequently bilateral. Oncocytic neoplasms and tumour-like lesions have fairly recently been the subject of two excellent studies/reviews (Palmer et al., 1990; Brandwein and Huvos, 1991).

The less common adenomas merit their own categories in the new classification, but a full description of each is beyond the scope of this study. For this, I would refer the reader to Ellis et al. (1991). The tumours

include sebaceous adenoma which is very rare. It is well circumscribed and often partly cystic, and is composed of nests of sebaceous cells without cytological atypia. An even less common variant is sebaceous lymphadenoma, which is probably related to Warthin's tumour. Ductal papilloma includes inverted ductal papilloma which is similar to its counterpart in the nose and paranasal sinuses. It also includes intraductal papilloma, a rare solitary tumour of the excretory ducts of minor salivary glands, and thirdly, sialadenoma papilliferum which resembles syringocystadenoma papilliferum of the cutaneous sweat glands (van der Wal and van der Waal, 1992). There are two subtypes of cystadenoma: the papillary, which resembles Warthin's tumour without the lymphoid stroma, and the mucinous, which is a circumscribed, partly cystic tumour where the cysts are lined by mucus-producing cells. The importance of the latter lies in differentiating it from more common mucus producing carcinomas.

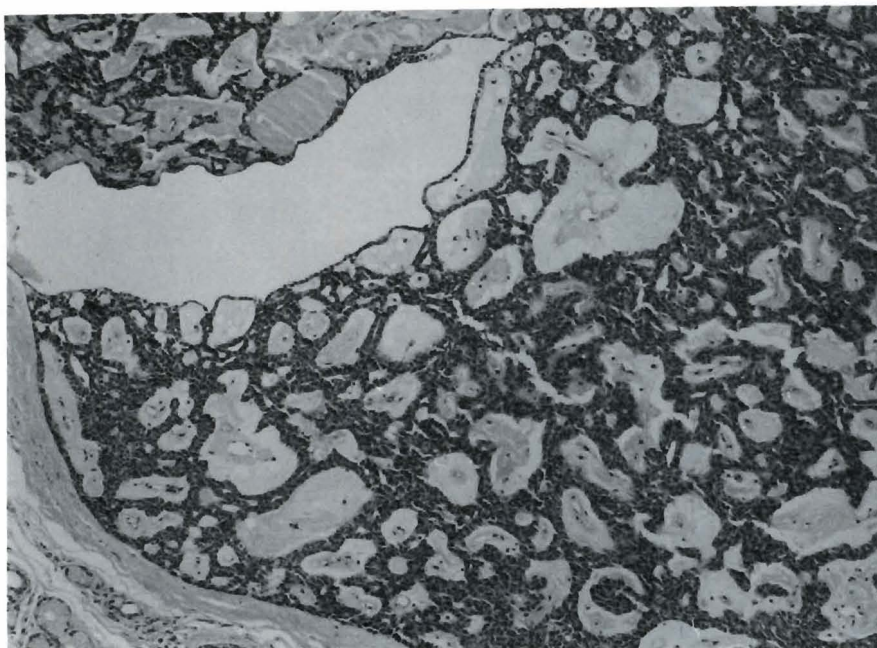
#### Mucoepidermoid and acinic cell carcinomas

The 1972 WHO classification described both of these as «tumours», because it doubted whether most were genuinely malignant. It is now clear that this view underestimated their aggressiveness, and both new classifications recognize them as carcinomas.

This is especially true for mucoepidermoid carcinoma which has an overall 5 year survival rate of 70%. Microscopy shows squamous cells, mucus-producing cells and cells of intermediate type. The epidermoid cells may occasionally have clear cytoplasm, and give the lesion the appearance of a clear cell neoplasm (Ogawa et al., 1992). The histological appearance is an important predictor of clinical

behaviour, and a subdivision into three grades has been proposed, based on growth pattern and cellular characteristics (Spiro et al., 1978). This reflects the degree of histological differentiation, and the tabulation of microscopic appearances by Batsakis and Luna (1990) is a most useful guide. Recent reappraisals by Clode et al. (1991) and Auclair et al. (1992) confirmed the value of such grading. In the former study, there were 39 cases with approximately equal numbers in each grade, and the 5 year cumulative survival was 100%, 70.1% and 47.2% for grades 1, 2 and 3 respectively.

Acinic cell carcinoma is a malignant epithelial neoplasm that demonstrates some cytological differentiation towards acinar cells. Several growth patterns may be seen: solid, microcystic, papillary-cystic and follicular. The individual cells contain dark PAS-diastase positive cytoplasmic granules similar to those in normal acinar cells, but variants such as vacuolated or clear cells may also be seen. On occasions, they can constitute most of a tumour, but a careful search always reveals cells with the characteristic granules (Batsakis, 1980). The behaviour of acinic cell carcinomas is that of a low grade malignancy. A study of 294 cases revealed that 12% had one or more recurrences after apparently curative surgery, 7.8% developed metastases and 6.1% died of disease (Ellis and Corio, 1983); all growth patterns and cell types were represented in the tumours that progressed. This is also my experience, and, although a three tier grading system has been proposed (Batsakis et al., 1990a), it remains untested. An interesting new line of research is the MIB 1 monoclonal antibody which recognizes the Ki-67 antigen in formalin-fixed, paraffin-embedded tissues. A recent study showed close correlation between the percentage of MIB 1 positive tumour cell nuclei and clinical



**Fig. 1.** Canalicular adenoma: a well circumscribed benign basaloid tumour composed of cellular trabeculae separated by oedematous stroma containing prominent thin-walled blood vessels. H&E, x 100

outcome. None of the patients with MIB 1 indices lower than 5% developed recurrences during follow-up periods of, in some cases, up to 30- years (Skálová et al., 1994). However, for most histopathologists who do not have access to this antibody, it is my view that even the most «benign looking» acinic cell carcinoma must be considered malignant, even though it may take many years to metastasize.

### Other carcinomas

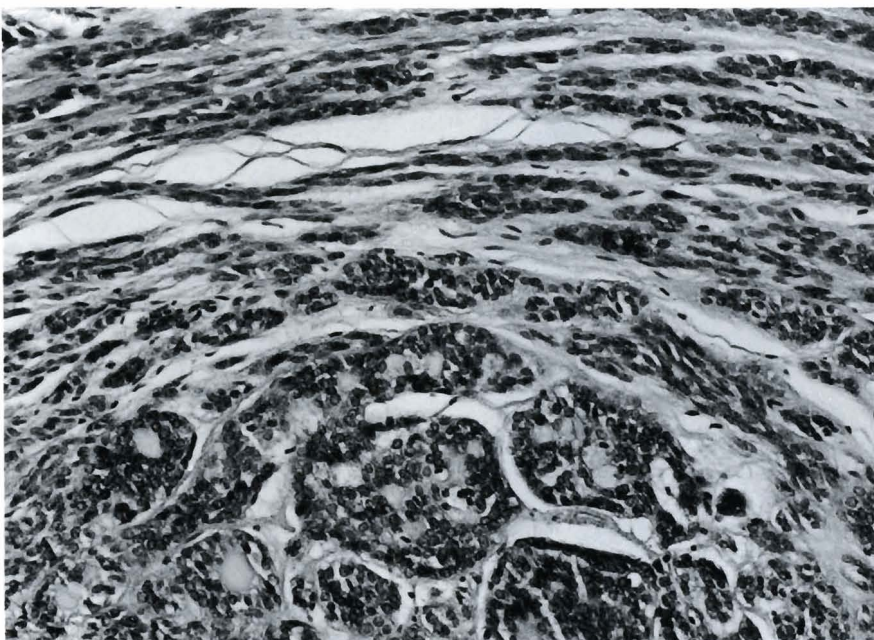
The 1972 WHO classification recognized 5 different types of carcinoma. This has now been increased in the 1991 revision to 16, in addition to acinic cell and mucoepidermoid carcinomas, largely due to the identification in the intervening years of several new tumours, particularly in what was formerly just adenocarcinoma. This is not mere hair-splitting, but the recognition of several distinct clinico-pathological entities with widely differing behaviour patterns.

Both new classifications retain adenoid cystic carcinoma, as it is usually easily recognizable as an infiltrative growth of groups of darkly staining, somewhat basaloid cells. Subdivision into three grades has been suggested, based on the increasing proportion of solid islands and the decreasing quantities of tubular and cribriform structures (Batsakis et al., 1990b). All have a poor prognosis, but the high grade tumours pursue a particularly aggressive and often rapidly fatal course (Szanto et al., 1984).

Polymorphous low grade adenocarcinoma (or terminal duct carcinoma) arises almost exclusively in the intra-oral minor salivary glands, especially in the palate. Microscopically (Fig. 2), it is characterized by cytological uniformity and morphological diversity - i.e.

regular bland cells arranged in a variety of patterns including ducts, cribriform and solid structures and an infiltrative growth with Indian filing, somewhat reminiscent of lobular carcinoma of the breast. The tumour is invasive, particularly around nerves, but recurrences develop in only a minority, and metastases and death due to disease are most unusual. Polymorphous low grade adenocarcinoma may be confused with the much more aggressive adenoid cystic carcinoma; the growth patterns can be similar, but the cytological features are significantly different (Simpson et al., 1991c). However, there remain unresolved questions of the relationship of polymorphous low grade adenocarcinoma to tumours with prominent papillary structures (Mills et al., 1984), and indeed to papillary cystadenocarcinoma, which is accorded a separate category in the revised WHO classification. It is clear that papillary carcinomas are slightly, but significantly, more aggressive (Mitchell et al., 1989), and some authors advocate separating them (Slootweg and Muller, 1987). However, others believe that they all lie within the same spectrum (Batsakis and El-Naggar, 1991). The significance of finding just a few papillary structures in an otherwise typical polymorphous low grade adenocarcinoma is uncertain, but I feel that, in practice, attention should be drawn to them and the possibility of a slightly worse prognosis.

Epithelial-myoepithelial carcinoma usually occurs in the parotid gland, and is composed of ducts lined by small epithelial cells, surrounded by a mantle of myoepithelial cells, beyond which is a PAS positive basement membrane of varying thickness (Fig. 3). The myoepithelial cells frequently display marked cytoplasmic clarity, such that this neoplasm has sometimes been mislabelled as «clear cell carcinoma or



**Fig. 2.** Polymorphous low grade adenocarcinoma is characterized by cytologically bland cells arranged in a variety of patterns - here, ducts and streaming. H&E, x 200

tumour». The two cell layers have different immunohistochemical reactions - the inner cells express low molecular weight cytokeratins such as AE 1, CAM 5.2 and MNF 116, and the outer cells S-100 protein and alpha smooth muscle actin. In its classical or clear cell patterns it should be easy to recognize, but this may not be the case with a subgroup where there is an extensive hyaline-sclerotic stroma with only sparse bi-layered ducts (Simpson et al., 1991b). Most studies have shown that epithelial-myoepithelial carcinoma behaves as a low grade malignancy; a recent literature review (Batsakis et al., 1992b) revealed that 31.3% of patients had recurrences, 17.9% cervical lymph node metastases and only 7.5% died of disease. However, since then, a disturbing series of 22 cases has been published in which 50% had recurrences and 40% died from their tumours (Fonseca and Soares, 1993).

Basal cell adenocarcinoma is a generally low grade malignancy of the parotid gland; it has the cytological characteristics of basal cell adenoma, but with an invasive growth pattern. It can arise *de novo*, or from a pre-existing basal cell adenoma, usually the membranous subtype (Batsakis and Luna, 1991b). However, there is undoubtedly a group of basaloid carcinomas that appears to be much more aggressive and which does not fit neatly into the category of high grade adenoid cystic carcinoma (Gallimore et al., 1994).

Salivary duct carcinoma occurs almost exclusively in the major glands. Most patients are over the age of 50, and there is a male predominance. It has previously been regarded as extremely rare, although I and some others believe it occurs more frequently (Di Palma et al., 1993; Hellquist et al., 1994). Its microscopic appearance is characteristic (Fig. 4), as it closely resembles ductal carcinoma of the breast, and there is often marked in situ

comedo-carcinoma (Simpson et al., 1991a). It is highly aggressive, and few patients survive beyond three years. It has been suggested that tumours with a diameter of 3 cm or less have a better prognosis (Hui et al., 1986), but studies from New York and Madrid found that this was not so, and that even a lesion as small as 2 cm could be fatal (Brandwein et al., 1990; Ruiz et al., 1993). Delgado et al. (1993) have suggested that carcinomas which are purely in situ, or only minimally invasive, have a better clinical outcome. The number of cases was too small to be statistically significant, but this aspect clearly deserves further study.

Malignant myoepithelioma (myoepithelial carcinoma) is accorded a separate category in both new classifications. Although only a few cases have been described, I suspect that it too may be less rare than previously supposed. Microscopy shows the variability of benign myoepitheliomas, and the malignant tumours are also composed of spindle, round, stellate or plasmacytoid cells which express S-100 protein, vimentin, cytokeratin and sometimes alpha smooth muscle actin. For the diagnosis of malignancy, the presence of cytological abnormalities, an increased mitotic rate and, particularly, invasiveness are the most useful criteria (Di Palma and Guzzo, 1993). Malignant myoepitheliomas may arise *de novo* or in a pre-existing pleomorphic adenoma, with the former appearing to be more aggressive.

Squamous cell carcinoma of the salivary glands is rare and, amongst the 390 tumours in the Exeter archives from 1978 to 1992, I found only 2 that I was convinced were primary, whereas there were 4 which were metastatic.

Small cell carcinomas also are encountered only rarely, and, in some, neuroendocrine differentiation can

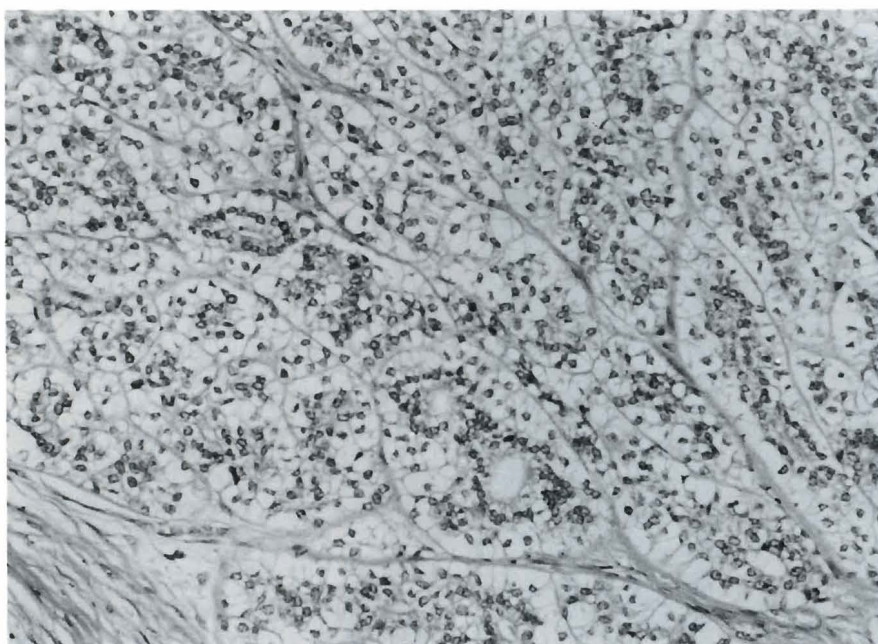


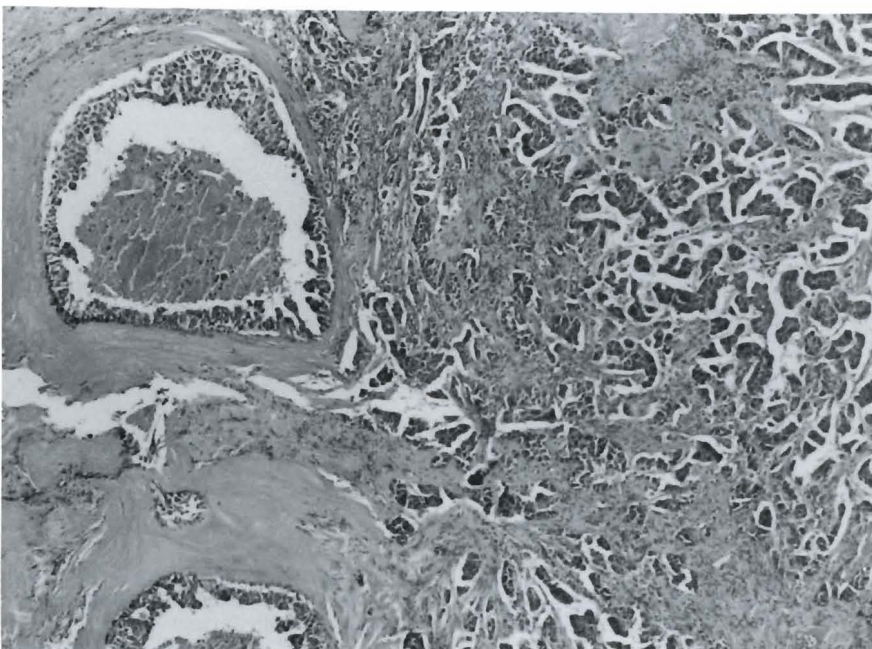
Fig. 3. Epithelial-myoepithelial carcinoma: ducts are lined by inner small epithelial cells and outer, often clear, myoepithelial cells H&E, x 200

be identified by immunohistochemistry or electron microscopy. Others appear to be undifferentiated small cell ductal neoplasms (Batsakis and Luna, 1991a). Amongst the group of tumours described as undifferentiated carcinomas are included neoplasms identical to nasopharyngeal carcinoma. They have a high incidence in Eskimos and Chinese, and Epstein-Barr virus genomes can be detected in the malignant cells (Hamilton-Dutoit et al., 1991). In addition, familial clusters have also been identified amongst patients from Greenland (Albeck et al., 1993). This tumour probably deserves its own separate category, as in the AFIP classification.

Mucinous adenocarcinoma is defined as a tumour in which mucus constitutes more than 50% of the lesion, and which lacks epidermoid differentiation. As many salivary neoplasms contain epithelial mucin in varying amounts, it is unlikely that it represents a single entity. One group that may be distinct is the mucus-producing adenopapillary carcinoma of Blanck et al. (1971), in which papillae are lined by columnar cells. There is some resemblance to intestinal adenocarcinoma, and its behaviour is low grade. However, some of the intra-oral examples may just be excessively mucinous variants of low grade papillary carcinoma, which as discussed above, may itself be a variant of polymorphous low grade adenocarcinoma. In reality, no clear picture of these tumours has emerged, and no classification has, as yet, sorted them out. In practice, when faced with such a mucinous carcinoma, one must first exclude a metastasis, and then try to allocate the lesion to the category it most resembles. Failing that, an attempt should be made to grade it as high, intermediate or low grade, based on general morphological and cytological criteria.

Carcinoma arising in a pleomorphic adenoma

(malignant mixed tumour) is a well recognized event, occurring in 3-4% of all pleomorphic adenomas. It is partly dependent on time, as the risk increases from 1.5% with a 5 year history of a benign tumour, to 9.5% after more than 15 years. The carcinomatous element generally appears to be aggressive, but the prognosis is excellent if it is restricted within the capsule of the pleomorphic adenoma, or shows only early invasion. A figure of 0.8 cm infiltration beyond the capsule has been proposed as the dividing line between a good and a poor prognosis (Tortoledo et al., 1984). Several types of epithelial malignancy may arise in a pleomorphic adenoma, although acinic cell and adenoid cystic carcinomas probably do not. High grade ductal carcinoma occurs, and so probably does polymorphous low grade adenocarcinoma. Other forms of malignancy may also develop in a pleomorphic adenoma, although much less frequently; true malignant mixed tumour (i.e. carcinosarcoma) is extremely rare, and the mesenchymal element is usually chondrosarcoma. Metastasizing pleomorphic adenomas are also exceptionally uncommon. They are histologically identical to the benign tumours, and why they metastasize is inexplicable, but they may still kill the patient (Wenig et al., 1992). Considering the important role myoepithelial cells play in pleomorphic adenomas, it is surprising that so few cases of malignant myoepithelioma arising from them have been described. The largest series is the 5 of Di Palma and Guzzo (1993); although 2 patients eventually died of disease, none of the 5 tumours was particularly aggressive. Several questions about malignancy in a pleomorphic adenoma remain unanswered, in particular, the importance of subclassification of the carcinomatous element, and whether invasion beyond 0.8 cm is really the prognostic milestone that has been proposed. A possibly profitable line of research is a suggestion that



**Fig. 4.** Salivary duct carcinoma: invasive and comedo-type in situ malignancy closely resembling mammary ductal cancer. H&E, x 100

the immunohistochemical demonstration of c-erbB-2 oncoprotein may be an indicator of aggressiveness (Sugano et al., 1992). In practice, the diagnosis of malignancy in a pleomorphic adenoma can be made definitely if there is true extracapsular invasion or when metastases have occurred. Cytological pleomorphism, necrosis or excessive haemorrhage should always raise suspicion, and such tumours must be sampled as completely as possible. If there is undoubted malignancy, or the chance of it is high, complete excision must be answered. If not, further surgery and perhaps adjuvant therapy may need to be considered.

Both new classifications include categories for the exceedingly rare sebaceous and oncocytic carcinomas. The former is composed of lipid-rich cells with a sebaceous appearance, and sometimes mucin. They have a 62% five year survival, sharing this aggressiveness with similar tumours of the eyelids, caruncle and orbit (Takata et al., 1989; Batsakis and El-Naggar, 1990). Although focal oncocytic change can occur in other tumours, only a small number of true oncocytic carcinomas has been reported, and they appear to be aggressive (Brandwein and Huvos, 1991; Scher et al., 1991). However, this may be a reflection of case selection for publication, as a «benign looking» oncocytoma will need to metastasize before it can convincingly be accepted as malignant.

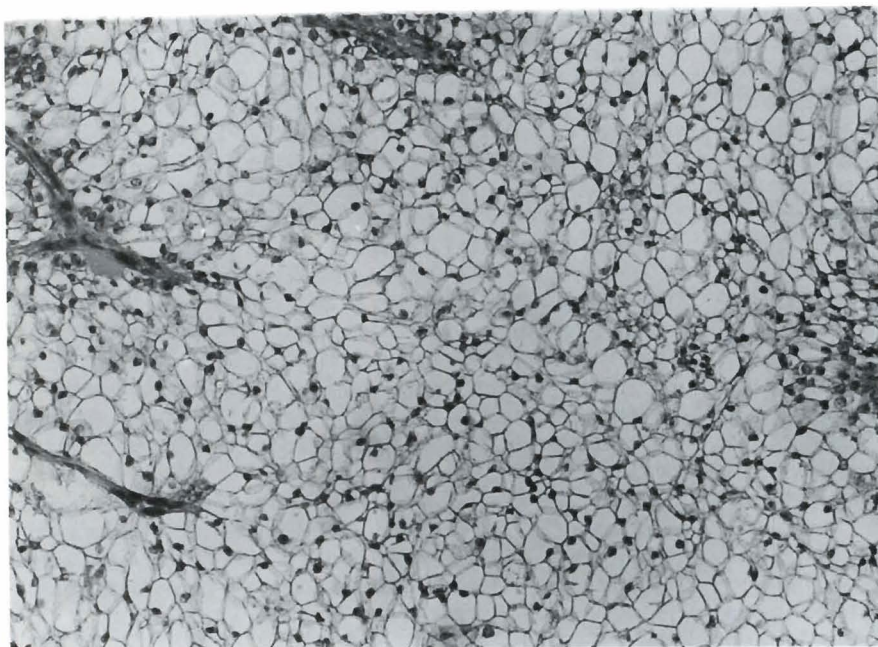
The unqualified term «clear cell carcinoma» is rightly not given a separate category in the revised WHO classification. Several tumour types may be composed wholly or partly of cells with clear cytoplasm. A few are benign, such as sebaceous adenoma, some oncocytic lesions, and rare examples of myoepithelioma. However, most clear cell tumours are malignant, such as variants of epithelial-myoepithelial, mucoepidermoid and acinic

cell carcinomas, not forgetting metastases from the kidney and elsewhere. In addition, we have identified a rare monomorphic clear cell carcinoma that seems not to fit easily into any other category (Simpson et al., 1990) (Fig. 5). It is also highly likely that cases 2 and 3 of Ogawa et al. (1991), and the hyalinizing clear cell carcinoma of Milchgrub et al. (1994) are examples of the same neoplasm. It is a low grade carcinoma that almost always arises in the minor salivary glands and displays no evidence of myoepithelial differentiation. Although it may eventually turn out to be a variant of another tumour, its histogenesis is, at present, uncertain. Thus, I believe it will probably deserve a separate category in future classifications.

Finally, there is a place in both new classifications for adenocarcinoma NOS (not otherwise specified). As the name suggests, these are malignant glandular neoplasms that cannot be accommodated elsewhere, and should represent only a few cases (Batsakis et al., 1992a). Such a diagnosis is sometimes unavoidable, particularly on a needle biopsy specimen, but, if at all possible, the histopathologist should try to designate any given tumour as high, intermediate or low grade based on general morphological and cytological criteria.

#### Other tumours

Various non-epithelial tumours may arise within or in close proximity to the salivary glands, and they should be classified by systems appropriate to, for example, soft tissue tumours at other sites. About 90% are benign, and they include lipomas, Schwannomas, vascular tumours and non-neoplastic conditions such as nodular fasciitis. Sarcomas are rare, the least so being malignant fibrous histiocytoma, malignant Schwannoma, and in children,



**Fig. 5.** Monomorphic clear cell carcinoma is composed of sheets of cells with clear cytoplasm. H&E, x 200

rhabdomyosarcoma.

The salivary glands (and intra-parotid lymph nodes) may be involved by systemic lymphomas, or may be the site of primary extranodal lymphomas. These should be categorized using the terminology of lymphoid classifications. Hodgkin's disease and non-Hodgkin's lymphomas of either high or low grades occur, and of these, by far the most common is the lymphoma arising in the mucosa-associated lymphoid tissue (MALT). These are composed of characteristic small centrocyte like cells, and are usually associated with myoepithelial sialadenitis (benign lympho-epithelial lesion) (Hyjek et al., 1988).

Secondary tumours do not cause problems in classification although, in practice, they can be a considerable source of diagnostic difficulty. They emphasize the need for a good clinical history when assessing any tumour of the salivary glands. In a series of 108 cases of metastases in the major glands and associated lymph nodes, approximately 60% originated from primary tumours in the head and neck region: of these, half were carcinomas of the skin, with melanomas as the next large group. Twenty percent of the metastases arose at distant sites of which the lung and kidney were more frequent. In a further 20%, the primary site could not be established (Seifert et al., 1986a). Renal cell carcinoma may first present as a parotid mass (Melnick et al., 1989), and must always be included in the differential diagnosis of a clear cell tumour.

### Non-neoplastic tumour-like lesions

A miscellaneous group of lesions may present as salivary gland swellings or masses. The revised WHO classification lists the seven most important entities, to which can be added, a variety of conditions: cystic fibrosis, amyloidosis, haemosiderosis, lipomatosis and epithelial metaplasias - sebaceous, goblet, squamous and oncocytic (Seifert, 1992).

Sialadenosis is a disorder of autonomic innervation of the salivary glands, and is seen in conditions such as chronic alcoholism, autonomic dysfunction and various endocrine abnormalities including diabetes mellitus and hypothyroidism. Histologically, there is enlargement of the serous acinar cells with some compression of the duct system by the swollen acini.

There are two types of oncocytosis: multifocal adenomatous oncocytic hyperplasia, as discussed above along with benign oncocyomas, and diffuse oncocytosis. The latter is a rare lesion which occurs in the parotid glands of older women. It is unilateral, and microscopy shows complete oncocytic metaplasia of the affected gland, involving both acini and ducts. It appears to be due to an intracellular metabolic disorder, probably of mitochondria.

Necrotizing sialometaplasia (salivary gland infarction) is an ischaemic lesion, usually associated with previous surgery; this may only have been relatively minor, for example a biopsy. Although often

seen in the palate, more than half of the cases in the Hamburg Salivary Gland Register occurred in the parotid and submandibular glands (Seifert, 1992). Microscopy shows a lobular arrangement with squamous cell metaplasia of the duct system in the centre, surrounded by necrotic acini and inflammation. Goblet cells may be found in the squamous areas, and thus necrotizing sialometaplasia can resemble squamous or mucoepidermoid carcinomas, from which it must be distinguished.

Benign lymphoepithelial lesion is a chronic auto-immune disorder. It can remain localized to the salivary glands, and is then termed myoepithelial sialadenitis, or it can be part of Sjogren's syndrome. It usually occurs in women, and patients present with painful recurrent swelling of the parotid gland. The histological appearance consists of a triad of parenchymal atrophy, interstitial lymphocytic infiltration with germinal centre formation, and epimyoeplithelial islands. These islands have different appearances at different stages of development, with progressive hyaline transformation of the ducts as lymphocytes infiltrate them. Hyjek et al. (1988) describe a spectrum of myoepithelial sialadenitis at one end and frank lymphoma at the other, with a transition of increasing numbers of centrocyte-like cells and light chain restriction. Indeed, there is a forty-fold risk of developing lymphoma in patients with Sjogren's syndrome compared to the normal population. The minor glands of the lip are also inflamed in addition to the major glands, but epimyoeplithelial islands are only rarely found.

Non-neoplastic cysts account for about 6% of all salivary gland masses. This group includes extravasation mucocoeles of the lip, which are really pseudocysts, as well as salivary duct cysts which contain mucus and are lined by ductal epithelium. Others are less common, and include lymphoepithelial and dermoid cysts, ranula and dysgenetic polycystic disease (Seifert, 1992).

Cystic lymphoid hyperplasia in AIDS consists of hypervascular reactive hyperplasia of the intra-parotid lymph nodes, which contain cystic spaces lined by squamous epithelium derived from invaginating salivary duct inclusions. The picture somewhat resembles a reactive tonsil. The changes result from direct viral activity of the HIV antigen, and are not a manifestation of altered immune function.

Chronic sclerosing sialadenitis of the submandibular gland (Kuttner tumour) is an inflammatory process producing a firm swollen gland. Microscopy shows periductal sclerosis and a dense lymphoid infiltrate with germinal centre formation in severe cases. There is eventually destruction of the lobular architecture and ductular proliferation. Sialolithiasis is seen in 30% of cases.

---

*Acknowledgements.* I am most grateful to colleagues in the Department of Pathology, ARAMCO Medical Center, Dhahran, Saudi Arabia for general advice and assistance. I also thank Sue Eames for typing the manuscript.

---



## References

- Albeck H., Bentzen J., Ockelmann H.H., Nielsen N.H., Bretlau P. and Hansen H.S. (1993). Familial clusters of nasopharyngeal carcinoma and salivary gland carcinomas in Greenland natives. *Cancer* 72, 196-200.
- Auclair P.L., Goode R.K. and Ellis G.L. (1992). Mucoepidermoid carcinoma of intraoral salivary glands: evaluation and application of grading criteria in 143 cases. *Cancer* 69, 2021-2030.
- Barnes L., Appel B.N., Perez H. and El-Attar A.M. (1985). Myoepitheliomas of the head and neck: case report and review. *J. Surg. Oncol.* 28, 21-28.
- Batsakis J.G. (1979). Tumors of the head and neck: clinical and pathological considerations. 2nd ed. Williams and Wilkins, Baltimore. p 9.
- Batsakis J.G. (1980). Clear cell tumors of salivary glands. *Ann. Otol.* 89, 196-197.
- Batsakis J.G. and El-Naggar A.K. (1990). Sebaceous lesions of salivary glands and oral cavity. *Ann. Otol. Rhinol. Laryngol.* 99, 416-418.
- Batsakis J.G. and El-Naggar A.K. (1991). Terminal duct adenocarcinoma of salivary tissues. *Ann. Otol. Rhinol. Laryngol.* 100, 251-253.
- Batsakis J.G. and Luna M.A. (1990). Histopathologic of grading of salivary gland neoplasms: I. mucoepidermoid carcinomas. *Ann. Otol. Rhinol. Laryngol.* 99, 835-838.
- Batsakis J.G. and Luna M.A. (1991a). Undifferentiated carcinomas of salivary glands. *Ann. Otol. Rhinol. Laryngol.* 100, 82-84.
- Batsakis J.G. and Luna M.A. (1991b). Basaloid salivary carcinoma. *Ann. Otol. Rhinol. Laryngol.* 100, 785-787.
- Batsakis J.G., El-Naggar A.K. and Luna M.A. (1992a). «Adenocarcinoma, not otherwise specified»: a diminishing group of salivary carcinomas. *Ann. Otol. Rhinol. Laryngol.* 101, 102-104.
- Batsakis J.G., El-Naggar A.K. and Luna M.A. (1992b). Epithelial-myoeplithelial carcinoma of salivary glands. *Ann. Otol. Rhinol. Laryngol.* 101, 540-542.
- Batsakis J.G., Luna M.A. and El-Naggar A.K. (1990a). Histopathologic grading of salivary gland neoplasms: II. acinic cell carcinoma. *Ann. Otol. Rhinol. Laryngol.* 99, 929-933.
- Batsakis J.G., Luna M.A. and El-Naggar A.K. (1990b). Histopathologic grading of salivary gland neoplasms: III. adenoid cystic carcinomas. *Ann. Otol. Rhinol. Laryngol.* 99, 1007-1009.
- Batsakis J.G., Luna M.A. and El-Naggar A.K. (1991). Basaloid monomorphic adenomas. *Ann. Otol. Rhinol. Laryngol.* 100, 687-690.
- Blanck C., Eneroth C.-M. and Jacobsson P.A. (1971). Mucus-producing adenopapillary (non-epidermoid) carcinoma of the parotid gland. *Cancer* 28, 676-685.
- Brandwein M.S. and Huvos A.G. (1991). Oncocytic tumors of major salivary glands: a study of 68 cases with follow-up of 44 patients. *Am. J. Surg. Pathol.* 15, 514-528.
- Brandwein M.S., Jagirdar J., Patil J., Biller H. and Kaneko M. (1990). Salivary duct carcinoma (cribriform salivary carcinoma of excretory ducts): a clinicopathologic and immunohistochemical study of 12 cases. *Cancer* 65, 2307-2314.
- Clode A.L., Fonseca I., Santos J.R. and Soares J. (1991). Mucoepidermoid carcinoma of the salivary glands: a reappraisal of the influence of tumor differentiation on prognosis. *J. Surg. Oncol.* 46, 100-106.
- Dardick I., Thomas M.J. and van Nostrand A.W.P. (1989). Myoepithelioma - new concepts of histology and classification: a light and electron microscopic study. *Ultrastruct. Pathol.* 13, 187-224.
- Delgado R., Vuitch F. and Albores-Saavedra J. (1993). Salivary duct carcinoma. *Cancer* 72, 1503-1512.
- Di Palma S. and Guzzo M. (1993). Malignant myoepithelioma of salivary glands: clinicopathological features of ten cases. *Virchows Arch. (A)* 423, 389-396.
- Di Palma S., Guzzo M. and Eveson J.W. (1993). Salivary duct carcinoma - a highly malignant tumour with close resemblance to breast ductal carcinoma. *Pathol. Res. Pract.* 189, 681 (Abstract).
- Ellis G.L. (1988). «Clear cell» oncocytoma of salivary gland. *Hum. Pathol.* 19, 862-867.
- Ellis G.L., Auclair P.L. and Gnepp D.R. (1991). Surgical pathology of the salivary glands. W.B. Saunders, Philadelphia. pp 129-134. and 238-268.
- Ellis G.L. and Corio R.L. (1983). Acinic cell carcinoma: a clinicopathologic analysis of 294 cases. *Cancer* 52, 542-549.
- Evans R.W. and Cruickshank A.H. (1970). Epithelial tumours of the salivary glands. W.B. Saunders, Philadelphia. p 19.
- Fonseca I. and Soares J. (1993). Epithelial-myoeplithelial carcinoma of the salivary glands: a study of 22 cases. *Virchows Arch. (A)* 422, 389-396.
- Foot F.W. Jr. and Frazell E.L. (1954). Atlas of tumor pathology. Section IV. Fascicle 11. Tumors of the major salivary glands. Armed Forces Institute of Pathology, Washington D.C. p 8.
- Gallimore A., Spraggs P., Allen J. and Hobsley M. (1994). Basaloid carcinomas of salivary glands: a clinicopathological and immunohistochemical study. *Histopathology* 24, 139-144.
- Hamilton-Dutoit S.J., Hamilton Therkildsen M., Nielsen N.H., Jensen H., Hansen J.P.H. and Pallesen G. (1991). Undifferentiated carcinoma of the salivary gland in Greenlandic eskimos: demonstration of epstein-barr virus DNA by in situ nucleic acid hybridization. *Hum. Pathol.* 22, 811-815.
- Hellquist H.B., Karlsson M.G. and Nilsson C. (1994). Salivary duct carcinoma - a highly aggressive salivary gland tumour with overexpression of c-erbB-2. *J. Pathol.* 172, 35-44.
- Hui K.K., Batsakis J.G., Luna M.A., MacKay B. and Byers R.M. (1986). Salivary duct adenocarcinoma: a high grade malignancy. *J. Laryngol. Otol.* 100, 105-114.
- Hyjek E., Smith W.J. and Isaacson P.G. (1988). Primary B-cell lymphoma of salivary glands and its relationship to myoeplithelial sialadenitis. *Hum. Pathol.* 19, 766-776.
- Melnick S.J., Amazon K. and Dembrow V. (1989). Metastatic renal cell carcinoma presenting as a parotid tumor: a case report with immunohistochemical findings and a review of the literature. *Hum. Pathol.* 20, 195-197.
- Milchgrub S., Gnepp D.R., Vuitch F., Delgado R. and Albores-Saavedra J. (1994). Hyalinizing clear cell carcinoma of the salivary gland. *Am. J. Surg. Pathol.* 18, 74-82.
- Mills S.E., Garland T.A. and Allen M.S. (1984). Low grade papillary adenocarcinoma of palatal salivary gland origin. *Am. J. Surg. Pathol.* 8, 367-374.
- Mitchell D.A., Eveson J.W. and Ord R.A. (1989). Polymorphous low grade adenocarcinoma of minor salivary glands - a report of three cases. *Br. J. Oral Maxillofac. Surg.* 27, 494-500.
- Ogawa I., Nikai H., Takata T., Ijuhin N., Miyauchi M., Ito H. and Vuhahula E. (1991). Clear cell tumors of minor salivary gland origin: an immunohistochemical and ultrastructural analysis. *Oral Surg. Oral Med. Oral Pathol* 72, 200-207.
- Ogawa I., Nikai H., Takata T. and Yasui R. (1992). Clear-cell variant of

*Salivary tumour classification*

- mucoepidermoid carcinoma: report of a case with immunohistochemical and ultrastructural observations. *J. Oral Maxillofac. Surg.* 50, 906-910.
- Palmer T.J., Gleeson M.J., Eveson J.W. and Cawson R.A. (1990). Oncocytic adenomas and oncocytic hyperplasia of salivary glands: a clinicopathological study of 26 cases. *Histopathology* 16, 478-493.
- Ruiz C.C., Romero M.P. and Perez M.M. (1993). Salivary duct carcinoma: a report of nine cases. *J. Oral Maxillofac. Surg.* 51, 641-646.
- Scher R.L., Feldman P.S. and Lambert P.R. (1991). Oncocytic malignancy of the parotid gland. *Otolaryngology - Head Neck Surg.* 105, 868-876.
- Seifert G. (1992). Tumour-like lesions of the salivary glands: the new WHO classification. *Pathol. Res. Pract.* 188, 836-846.
- Seifert G. and Sobin L.H. (1991). World Health Organization international histological classification of tumours: histological typing of salivary gland tumours. 2nd ed. Springer-Verlag, Berlin.
- Seifert G., Hennings K. and Caselitz J. (1986a). Metastatic tumors to the parotid and submandibular glands - analysis and differential diagnosis of 108 cases. *Pathol. Res. Pract.* 181, 684-692.
- Seifert G., Miehke A., Haubrich J. and Chilla R. (1986b). Diseases of the salivary glands: Pathology - Diagnosis - Treatment - Facial Nerve Surgery. Georg Thieme Verlag, Stuttgart. pp 171-285.
- Simpson R.H.W., Clarke T.J., Sarsfield P.T.L. and Babajews A.V. (1991a). Salivary duct adenocarcinoma. *Histopathology* 18, 229-235.
- Simpson R.H.W., Clarke T.J., Sarsfield P.T.L. and Gluckman P.G.C. (1991b). Epithelial-myoepithelial carcinoma of salivary glands. *J. Clin. Pathol.* 44, 419-423.
- Simpson R.H.W., Clarke T.J., Sarsfield P.T.L., Gluckman P.G.C. and Babajews A.V. (1991c). Polymorphous low-grade adenocarcinoma of the salivary glands: a clinico-pathological comparison with adenoid cystic carcinoma. *Histopathology* 19, 121-129.
- Simpson R.H.W., Sarsfield P.T.L., Clarke T.J. and Babajews A.V. (1990). Clear cell carcinoma of minor salivary glands. *Histopathology* 17, 433-438.
- Skálová A., Leivo I., von Boguslawsky K. and Saksela E. (1994). Cell proliferation correlates with prognosis in acinic cell carcinomas of salivary gland origin. Immunohistochemical study of 30 cases using the MIB 1 antibody in formalin-fixed paraffin sections. *J. Pathol.* 173, 13-21.
- Slootweg P.J. and Muller H. (1987). Low grade adenocarcinoma of the oral cavity: a comparison between the terminal duct and the papillary type. *J. Cranio.-Max.-Fac. Surg.* 15, 359-364.
- Spiro R.H., Huvos A.V., Berk R. and Strong E.W. (1978). Mucoepidermoid carcinoma of salivary gland origin: a clinicopathologic study of 367 cases. *Am. J. Surg.* 136, 461-468.
- Sugano S., Mukai K., Tsua H., Hirohashi S., Furuya S., Shimosato Y., Ebihara S. and Takeyama I. (1992). Immunohistochemical study of c-erbB-2 oncoprotein overexpression in human major salivary gland carcinoma: an indicator of aggressiveness. *Laryngoscope* 102, 923-927.
- Szanto P.A., Luna M.A., Torteledo E. and White R.A. (1984). Histologic grading of adenoid cystic carcinoma of the salivary glands. *Cancer* 54, 1062-1069.
- Takata T., Ogawa I. and Nikai H. (1989). Sebaceous carcinoma of the parotid gland: an immunohistochemical and ultrastructural study. *Virchows Arch. (A)* 414, 459-464.
- Thackray A.C. and Lucas R.B. (1974). Tumors of the major salivary glands. Fascicle 10. 2nd series. Armed Forces Institute of Pathology, Washington, D.C.
- Thackray A.C. and Sobin L.H. (1972). Histological typing of salivary gland tumours. World Health Organization, Geneva.
- Tortoledo M.E., Luna M.A. and Batsakis J.G. (1984). Carcinomas ex pleomorphic adenoma and malignant mixed tumors: histomorphologic indexes. *Arch. Otolaryngol.* 110, 172-186.
- van der Wal J.E. and van der Waal I. (1992). The rare sialadenoma papilliferum. Report of a case and review of the literature. *Int. J. Oral Maxillofac. Surg.* 21, 104-106.
- Wenig B.M., Hitchcock C.L., Ellis G.L. and Gnepp D.R. (1992). Metastasizing mixed tumor of salivary glands: a clinicopathologic and flow cytometric analysis. *Am. J. Surg. Pathol.* 16, 845-858.