

## A case of rhinoscleroma treated with ciprofloxacin

LYDIA BADIA, F.R.C.S., VALERIE J. LUND, M.S., F.R.C.S., F.R.C.S. (Ed)

### Abstract

Respiratory scleroma (often termed 'rhinoscleroma') is a chronic inflammatory condition in which deforming masses of tissue distend the nasal cavity. *Klebsiella rhinoscleromatis* is the causative agent of this infection and the Mikulicz cell is specific to the lesion being a large macrophage with clear cytoplasm containing the bacilli.

Antibiotic therapy has traditionally consisted of streptomycin and tetracycline long-term but this presents problems with adverse side-effects and poor patient compliance.

We report on a young patient with nasal rhinoscleroma who achieved resolution after treatment with oral ciprofloxacin. As mentioned in a review of patients with rhinoscleroma at the Mayo clinic in 1993, the fluoroquinolones deserve further study as potentially highly effective agents for this condition. Ciprofloxacin is convenient for oral administration and has few adverse effects. It achieves good tissue penetration, is concentrated in macrophages and may prove to be useful in the therapy of rhinoscleroma.

**Key words:** Rhinoscleroma, Therapy

### Introduction

Rhinoscleroma was first described by Von Hebra in 1870. Initially thought to be a neoplasm, it was established as an inflammatory process in 1876 by Mikulicz and the causative agent, *Klebsiella rhinoscleromatis*, isolated by Von Frisch in 1882.<sup>1</sup> Although the disease may remain confined to the external nose and nasal cavity in some patients, it often affects the entire respiratory tract and this condition is therefore best termed 'respiratory scleroma'. Rhinoscleroma infection is worldwide but has a peculiar geographical distribution being commoner in Central and South America, some parts of Africa, the Middle East, India, the Philippines and some other areas of the Pacific.<sup>2</sup> It seems to affect impoverished people, predominantly in rural areas. It is a poorly communicable infection although transmission after prolonged household contact with infected family members has been reported.<sup>3</sup>

It is rarely encountered in the UK and diagnosis is frequently delayed because of the insidious onset, non-specific symptoms and equivocal findings on routine histological examination. The causative organism is resistant to most antibiotics and, being intracellular, is not always exposed to sufficient concentrations of the drug. We report on a case that achieved resolution during treatment with oral ciprofloxacin.

### Case report

A 15-year-old Caucasian female noticed bilateral nasal obstruction of a sudden onset at age five, followed by a bilateral sensorineural hearing loss and later developed insulin-dependent diabetes mellitus. She had undergone adenoidectomy and sub-mucous diathermy of the inferior turbinates in the past with temporary relief. Her older sister had also suffered hearing loss and diabetes at approximately the same age but had no nasal symptoms. Examination revealed a diamond-shaped expansion of the

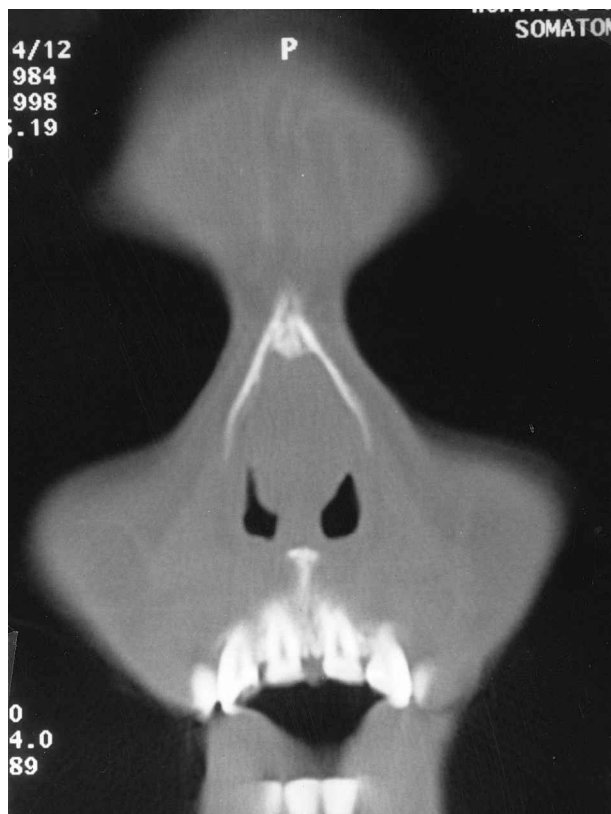


FIG. 1

Coronal CT scan showing a diamond shaped expansion of the cartilaginous nasal septum.

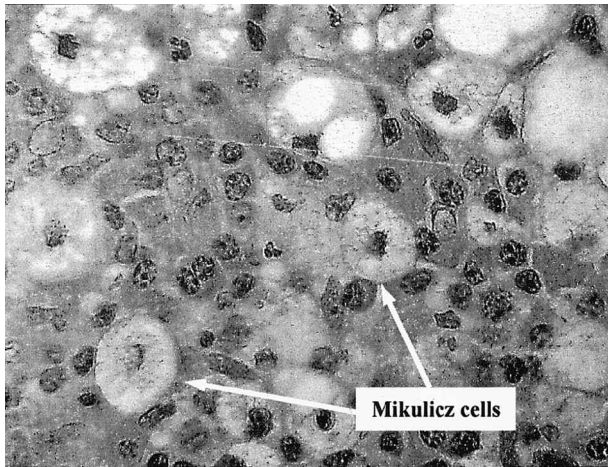


FIG. 2

Microscopic appearance of the nasal mucosa which shows fibrosis and a mixed inflammatory cell infiltrate. The inflammation is chronic, featuring plasma cells, lymphocytes and macrophages. The Mikulicz cells are large macrophages with clear cytoplasm containing rodlike structures (H & E;  $\times 340$ ).

anterior nasal septum and scattered thickening of her nasal mucosa in both nasal cavities, the rest of the physical examination was normal. Nasal inspiratory peak flow was impossible due to the nasal obstruction, although oral pulmonary peak flow was normal for her age and height. She was normotensive and skin prick testing to a range of common allergens was negative. A computed tomography (CT) scan (Figure 1) and magnetic resonance imaging (MRI) confirmed expansion of the cartilagenous septum with no significant sinus disease or any other pathology. There was no evidence of bony erosion or destruction. She underwent limited septal surgery and biopsies of the septum and floor of left nasal cavity showed disease characteristic of rhinoscleroma (Figure 2), with a marked mononuclear and plasma cell infiltrate and organisms seen within foamy macrophages (Mikulicz's cells).

Following the microbiologist's advice she was started on a course of ciprofloxacin, 500 mg orally twice a day for eight weeks. After one month of therapy, her symptoms had resolved but the course of ciprofloxacin was continued for another four weeks. Examination showed a normal nasal mucosa and nasal inspiratory peak flow improved to 120 litres per minute. At 12 months after discontinuation of therapy she remains asymptomatic and rhinoscleroma has clinically cleared, biopsies at this stage were negative although she remains under follow-up.

## Discussion

Scleroma is a term used to describe an infectious disease caused by a Gram negative diplobacillus. The term was adopted in 1932 by the International Otolaryngology Clinical Congress to emphasize that the disease process can affect any area of the upper or lower respiratory tract, not just the nasal vault and sinuses.<sup>4</sup> Nevertheless the less accurate term 'rhinoscleroma' may endure because the bacterium causing the infection is *Klebsiella rhinoscleromatis*. The presentation of scleroma varies, but the most common symptom complex relates to nasal symptoms, including nasal obstruction, purulent or foetid nasal discharge and submucosal masses.<sup>5</sup> The clinical progression of scleroma is generally divided into three or four phases of involvement that are thought to occur in sequence if the infection remains incompletely treated. Stage one is the exudative or catarrhal phase, character-

ized by profuse purulent inflammation. This is followed by the atrophic phase, in which dry crusting of the mucous membrane occurs and leads to friable, easily bleeding tissue. Stage three is the granulomatous stage, in which nodules and masses often proliferate and obstruct the affected portion of the respiratory tract. Finally in the cicatricial stage, scarring forms in the infected area.<sup>4</sup>

With the availability of computed tomographic scanning and nasal endoscopes, scleroma has been found to infect the interior of the maxillary sinus as well as the ethmoid sinuses more often than was typically reported before the advent of this technology. Nasopharyngeal involvement can occur and lead to eustachian tube dysfunction or to ulceration of the soft palate with eventual scarring or nasopharyngeal stenosis.<sup>7</sup> Scleroma occasionally involves the subglottis, trachea or distal respiratory tract but in most cases, the airway involvement occurs after nasal involvement has been present, although isolated subglottic involvement has also been reported.<sup>8</sup> The distribution of scleroma involvement was reported by Gamea in 1990.<sup>9</sup> In this study of 80 patients, 100 per cent had nasal vault involvement or rhinoscleroma, 22.5 per cent had involvement of the maxillary sinus, 27.5 per cent had involvement of the eustachian tube, 26 per cent had laryngoscleroma, 20 per cent had tracheoscleroma, and 7.5 per cent had bronchoscleroma. In this report the role of endoscopy is emphasized, including sinus endoscopy and bronchoscopy, in evaluating scleroma.

The diagnosis of scleroma will be obtained by culture material and biopsy of the affected area.<sup>10</sup> *Klebsiella rhinoscleromatis* can usually be grown in the laboratory on blood agar or MacConkey agar. Culture results are important because they confirm the diagnosis and guide future antibiotic choices through sensitivities obtained *in vitro*. The organisms can be visualized on routine HE staining and their presence (Gram negative diplobacilli) confirmed on Gram staining. Microscopic findings vary depending on the stage of involvement, but a classic manifestation is the presence of Mikulicz cells (Figure 2) which are large macrophages with clear cytoplasm containing the bacilli. The organism is encapsulated within a mucopolysaccharide coat that confers antibiotic resistance. Special silver stains, such as Warthin-Starry and Giemsa, are often required to reveal the classic histological picture. Immunohistochemical techniques are now also available, with the capsular antigen O2K3 being the basis for immunoperoxidase testing.<sup>4</sup>

In the pre-antibiotic era, the mainstay of therapy for scleroma was surgery, particularly in the late fibrotic stage with airway problems due to obstruction or disfigurement. Many antibiotic have been tried against scleroma. Clinical response can be obtained with different drugs but relapses result from incomplete treatment.<sup>11</sup> Systemic streptomycin was the first drug to be used successfully and for years it was the drug of choice but it has severe side-effects, especially in the vestibular system and it has now acquired resistance. When tetracycline was introduced it had the facility of oral administration, but it required prolonged therapy in terms of months or years with poor patient compliance. Tetracycline is to be avoided in the paediatric age group and during pregnancy because of teeth staining.<sup>12</sup> Rifampicin has also been shown to have good results, but patients receiving rifampicin must be closely monitored for sign of toxicity. To avoid the systemic effects of rifampicin, topical rifampicin has been used with good results.<sup>13</sup> Trimethoprim-sulfamethoxazole has been found to be effective, and its low cost is especially important in third world nations.<sup>5</sup>

Most recently, quinolones have been reported as adequate treatment.<sup>4</sup> Ciprofloxacin, a fluoroquinolone, is an antibiotic with excellent tissue penetration and a broad antibacterial spectrum of action. Adverse effects are comparatively few and include gastrointestinal symptoms in three to six per cent of patients. Its use is not recommended in patients under 12 years of age because of the risk of arthropathy. Ciprofloxacin has the advantage of twice-daily administration, that may improve compliance for long courses of therapy. Another theoretical advantage is that the quinolones are concentrated within macrophages.<sup>14</sup> Ciprofloxacin, 250–500 mg administered twice daily for four weeks, was shown to have excellent clinical efficacy in an area of Mexico where scleroma is endemic.<sup>15</sup> It was also cheaper in the long run than drugs with a lower initial cost that required longer periods of treatment. There have been other case reports of rhinoscleroma cured with ciprofloxacin<sup>16–18</sup> but the appropriate duration of antibiotic therapy has not been established. Most authors suggest continuing treatment until repeated tissue culture and histological examination are negative for the bacillus. Long-term follow-up is required to monitor for re-activation of disease after treatment.

In conclusion, there is growing evidence that ciprofloxacin is an appropriate antimicrobial agent and possibly shortens the duration of therapy. Further investigation of the use of ciprofloxacin for treatment of rhinoscleroma, including comparative trials with other therapies, would be of considerable interest.

## References

- 1 Winstead W, Connely TV, Raff MJ. Rhinoscleroma: A case report and clinical update. *Am J Rhinol* 1993;**7**:281–5
- 2 Michaels L. *Infections in Ear, Nose and Throat. Histopathology*. Berlin, Heidelberg: Springer-Verlag, 1987
- 3 Shaw HJ, Martin H. Rhinoscleroma – A clinical perspective. *J Laryngol Otol* 1961;**75**:1011–39
- 4 Andraca R, Edson RS, Kern EB. Rhinoscleroma: A growing concern in the United States? Mayo Clinic experience. *Mayo Clinic Proc* 1993;**68**:1151–7
- 5 Murr AH. Diagnosis and treatment of scleroma. *Otolaryngol Head Neck Surg* 1998;**6**:186–9
- 6 Abou-Seif SG, Baky FA, el-Ebrashy F, Gaafar HA. Scleroma of the upper respiratory passages: a CT study. *J Laryngol Otol* 1991;**105**:198–202
- 7 Soni NK, Hemani DD. Scleroma of the Eustachian tube: salpingoscleroma. *J Laryngol Otol* 1994;**108**:944–6
- 8 Postma GN, Wawrose S, Tami TA. Isolated subglottic scleroma. *Ear Nose Throat J* 1996;**75**:306–8
- 9 Gamea AM. Role of endoscopy in diagnosing scleroma in its uncommon sites. *J Laryngol Otol* 1990;**104**:619–21
- 10 Batsakis JG, el Naggat AK. Rhinoscleroma and rhinosporidiosis. *Ann Otol Rhinol Laryngol* 1992;**101**:879–82
- 11 Ssali CLK. The management of rhinoscleroma. *J Laryngol Otol* 1975;**89**:91–9
- 12 Shum TK, Whitaker CW, Meyer PR. Clinical update on rhinoscleroma. *Laryngoscope* 1982;**92**:1149–53
- 13 Gamea AM. Local rifampicin in the treatment of rhinoscleroma. *J Laryngol Otol* 1988;**102**:319–21
- 14 Hooper DC, Wolfson JS. Fluoroquinolone antimicrobial agents. *New Engl J Med* 1991;**324**:384–94
- 15 Borgstein J, Sada E, Cortes R. Ciprofloxacin for rhinoscleroma and ozena (letter). *Lancet* 1993;**342**:122
- 16 Avery RK, Salman SD, Sullivan Baker A. Rhinoscleroma treated with ciprofloxacin: a case report. 1995;**105**:854–6
- 17 Valor-Garcia C, Castillo-Serrano E, Martin-del Guayo G, Bhathal-Guede B, Barcia-Fernandez E, Olalla-Tabar A, et al. Rhinoscleroma. A case report. *Acta Otorrinolaringol Espan* 1999;**50**:321–3
- 18 Trautmann M, Hels Th, Ruhnke M, Schnoy N. A case of rhinoscleroma cured with ciprofloxacin. *Infection* 1993;**21**:403–6

Address for correspondence:

Lydia Badia, F.R.C.S.,  
The Royal National Throat, Nose and Ear Hospital,  
330 Gray's Inn Road,  
London WC1X 8DA, UK.  
Fax: 020 7 8339480

---

Miss L Badia takes responsibility for the integrity of the content of the paper.

Competing interests: None declared

---