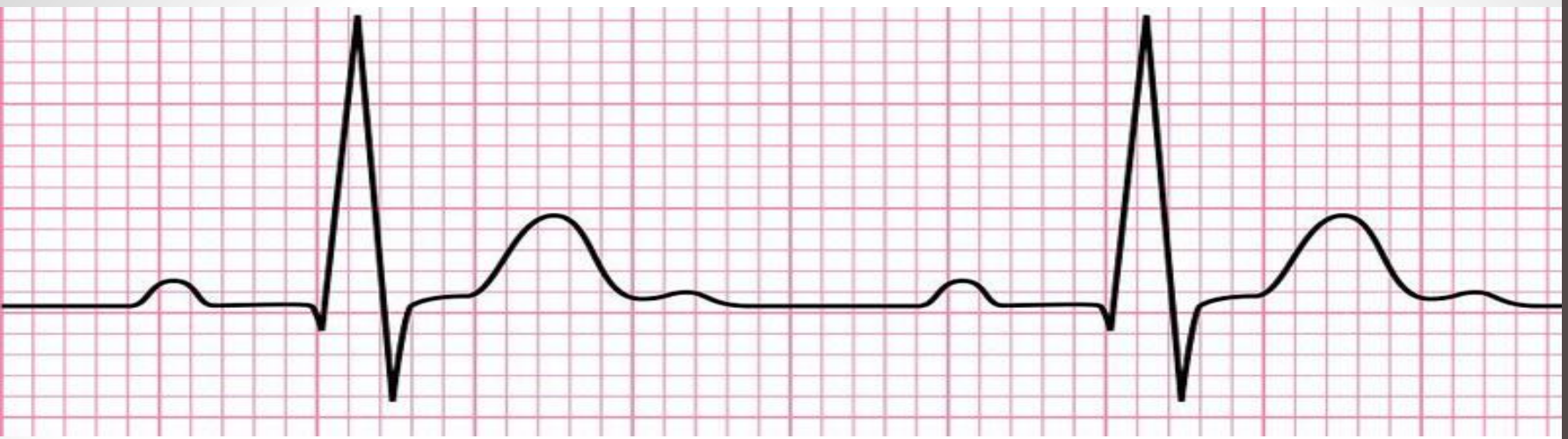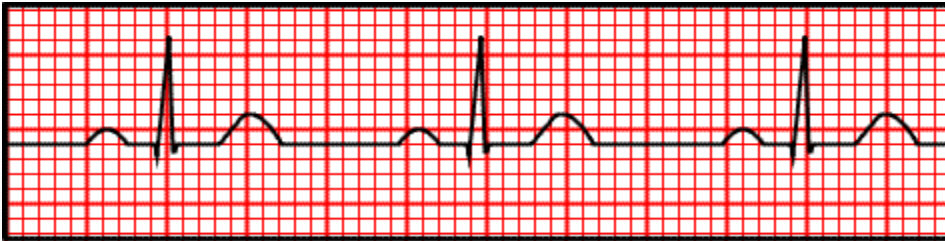


ECG: A closer L^oo^oK

Dr. Tamara Alqudah

Heart Rate

- Normal heart rate in adults ranges from 60 to 100 beats per minute
- How to calculate heart rate from ECG:
 - ✓ Determine the length of R-R interval
 - ✓ Heart Rate = $300 / \# \text{ large squares in R-R interval}$
 - ✓ Or Heart Rate = $1500 / \# \text{ small squares in R-R interval}$
 - ✓ Or Heart Rate = $60 / \text{time in R-R interval}$



$$\text{HR} = 300 / 4 = 75 \text{ B.P.M}$$

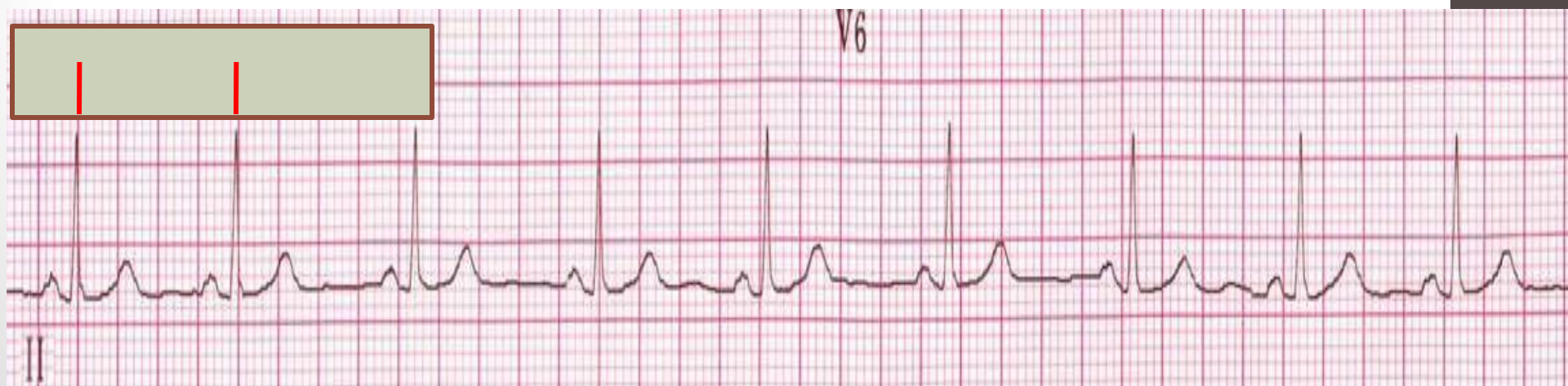$$\text{HR} = 1500 / 20 = 75 \text{ B.P.M}$$

$$\text{HR} = 60 / 0.8 = 75 \text{ B.P.M}$$

Heart rhythm

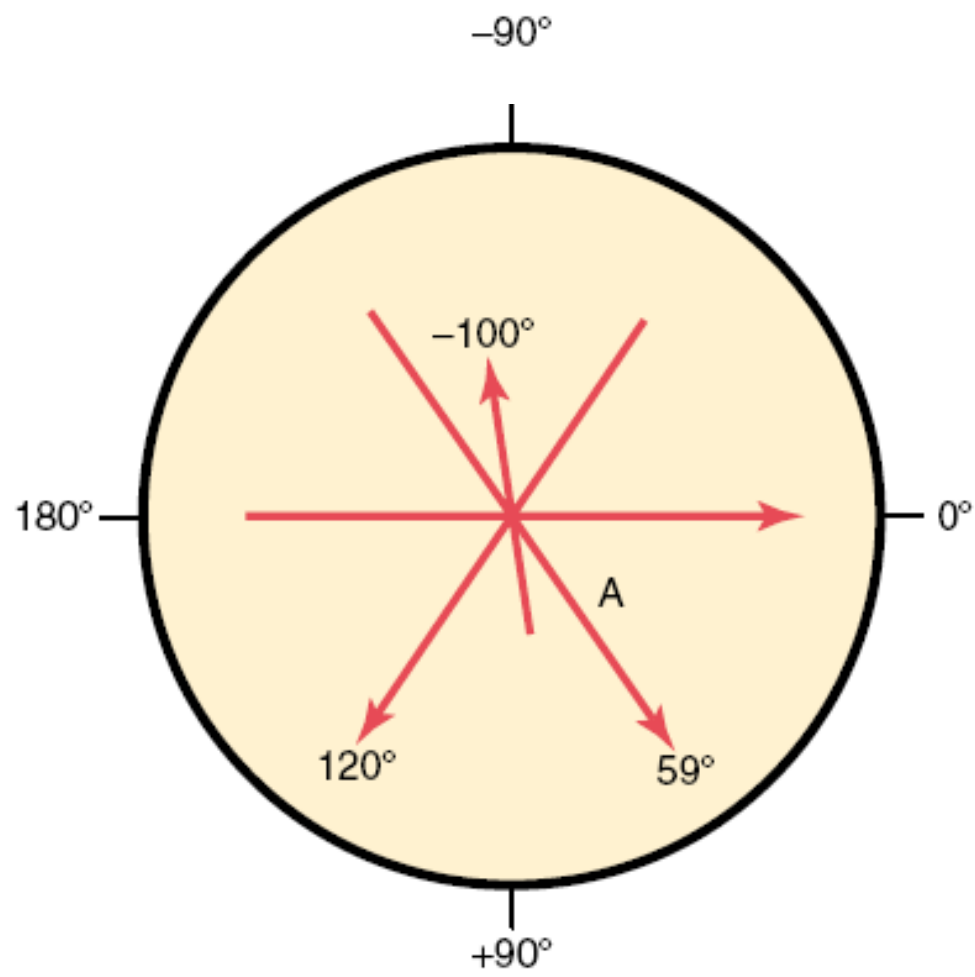
- When depolarization begins in the SA node and spreads in a its normal pathway the heart is said to be in sinus rhythm. This is the normal heart rhythm
- If depolarization begins else where the rhythm is named after the part where the depolarization starts. E.g nodal rhythm starts in AV node
- The best way to assess the ECG rhythm is by inspecting the rhythm strip. This is usually a 10 second recording from lead II

- ✓ Checking for the presence of Sinus rhythm:
 - Ascertain the presence of a P wave prior to every QRS complex
 - The P wave should have the same contour in the same lead
 - R-R interval should have little variation (<0.12 sec) throughout the ECG. This can be checked by a ruler or by marking on a piece of paper the distance between the first two R waves, and comparing this distance between pairs of QRS complexes on the rhythm strip



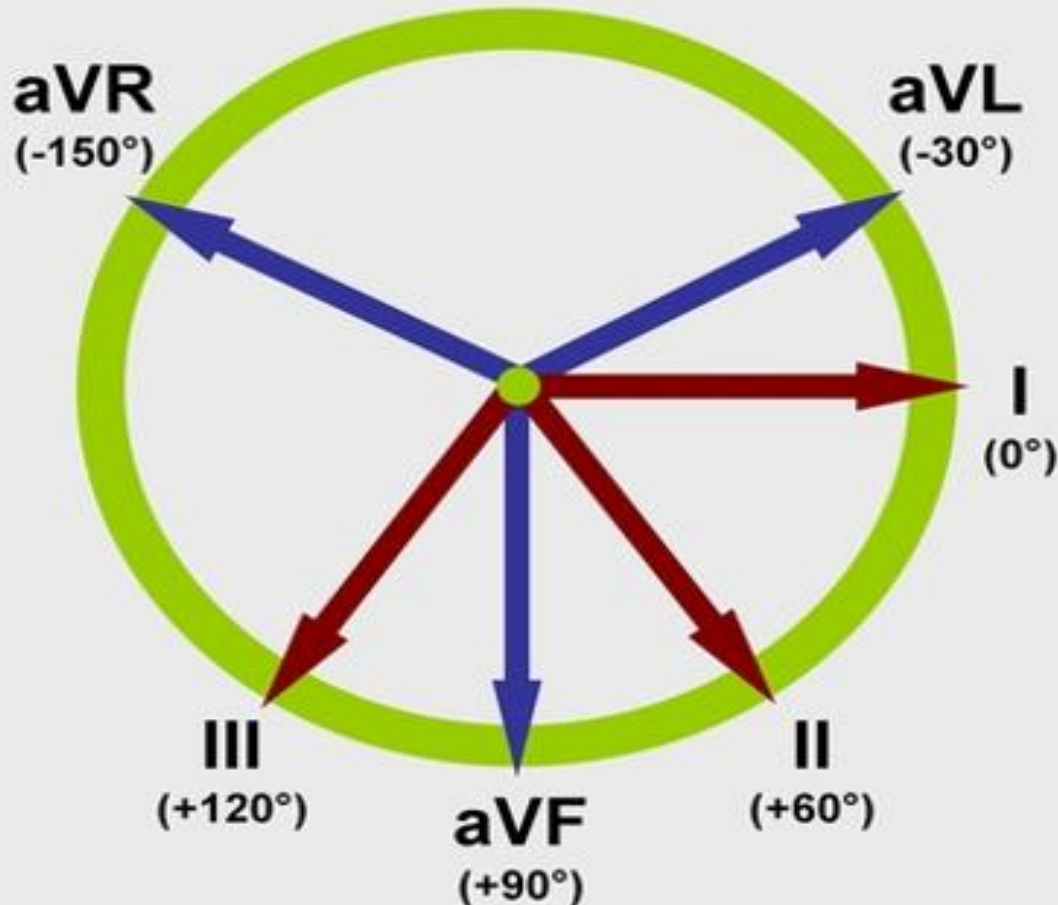
Principles of vectorial analysis of ECG

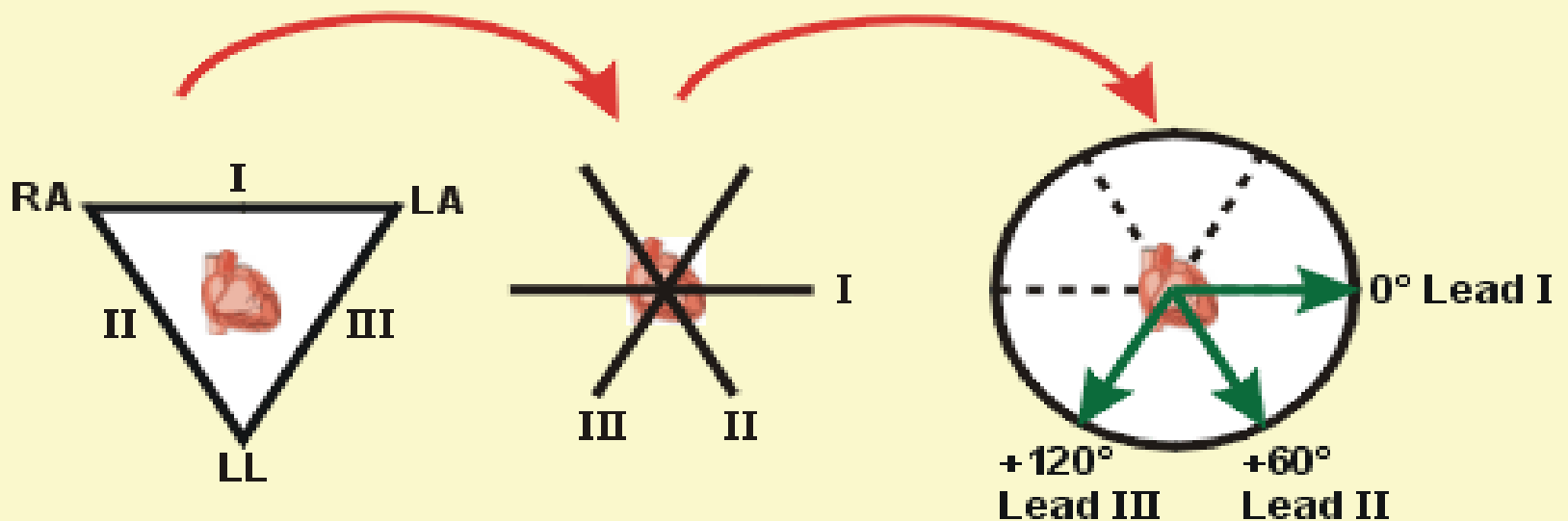
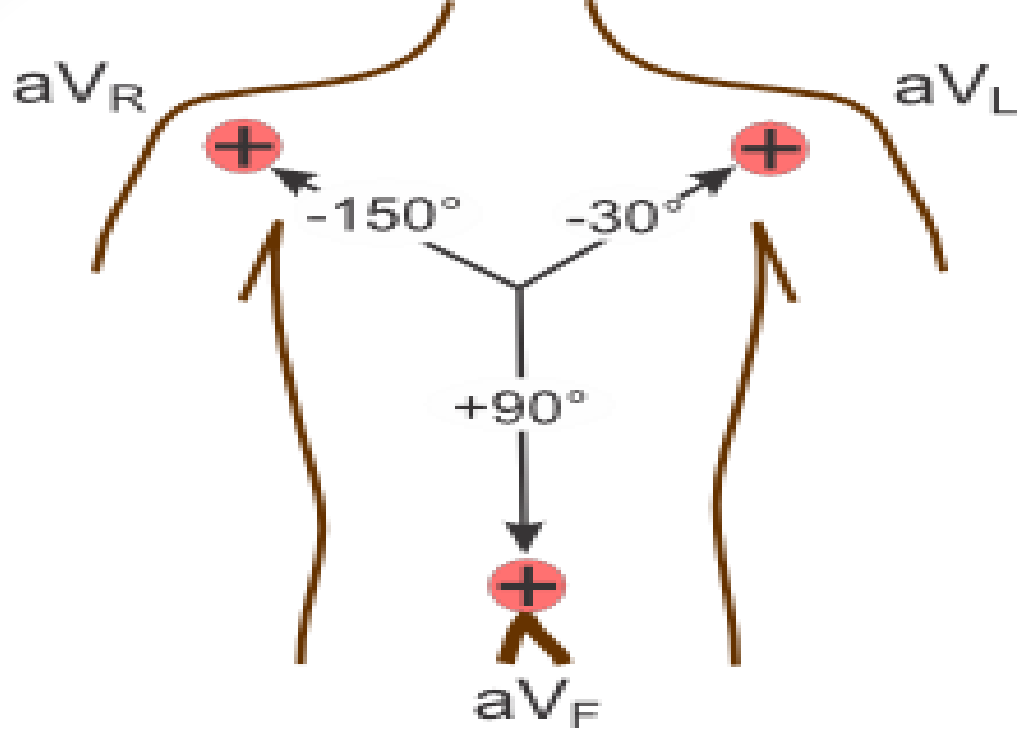
- A vector is an arrow that points in the direction of the electrical potential generated by the current flow, with the arrow head in the positive direction. Also, by convention, the length of the arrow is drawn proportional to the voltage of the potential.
- When a vector is exactly horizontal and directed toward the person's left side, the vector is said to extend in the direction of 0 degrees. From this zero reference point, the scale of vectors rotates clockwise.
- In a normal heart during ventricular depolarization considerably more current flows downwards ;from the base of the ventricles toward the apex ,than in the upward direction.
- The mean QRS vector, is about +59 degrees.
- This means that during most of the depolarization wave, the apex of the heart remains positive with respect to the base of the heart.



Hexagonal reference system

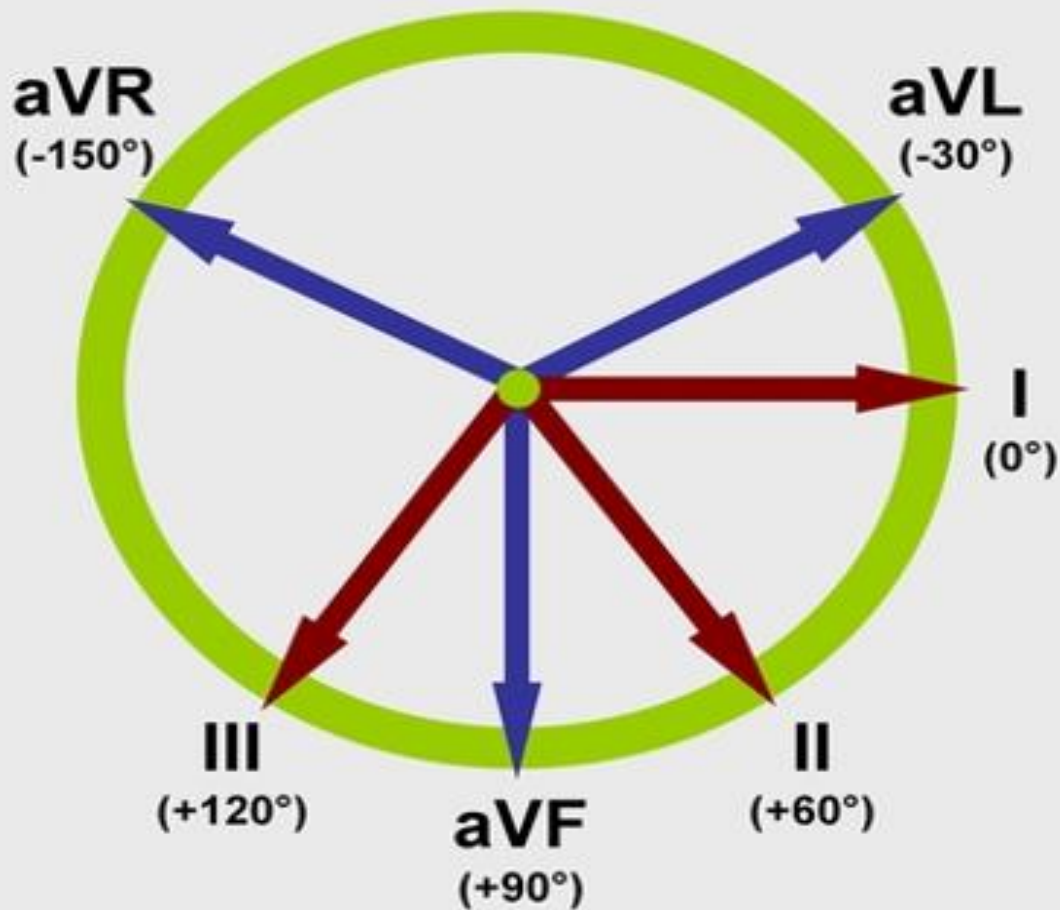
For each limb lead the direction from the negative electrode to the positive electrode of that lead is called the “axis” of the lead.





Einthoven's Triangle

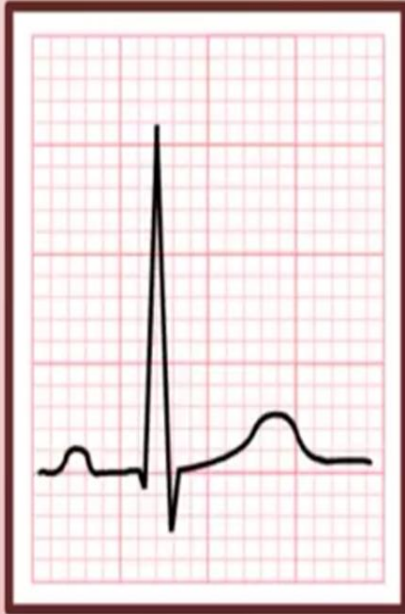Axial Reference System



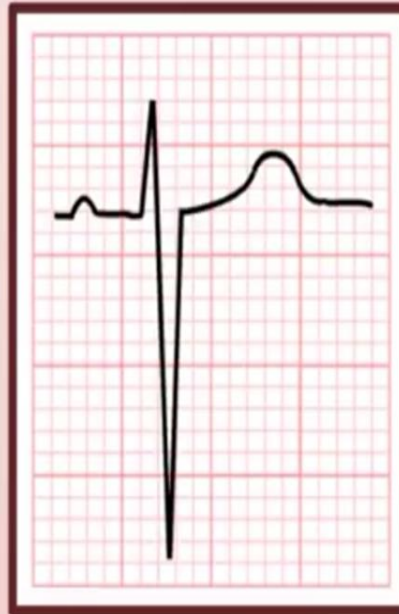- The upper half of the circle is negative and the lower part is positive
1. Lead I and aVF are perpendicular to each other.
 2. Lead II and aVL are perpendicular to each other.
 3. Lead III and aVR are perpendicular to each other.

Determining the Cardiac Axis

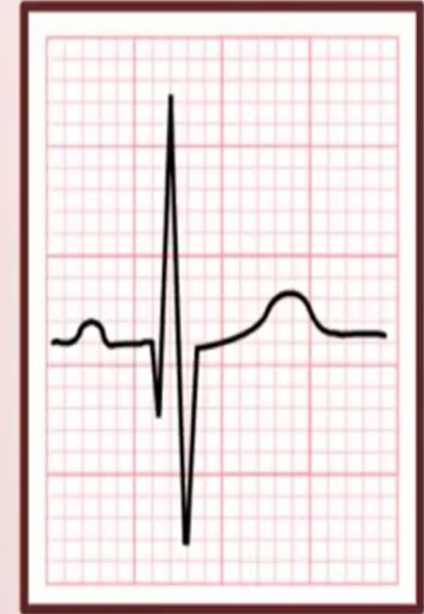- The cardiac axis refers to the general direction in which the ventricles depolarize. ~ 59 degrees
- Normal cardiac axis can swing from - 30 degrees to 90 degrees, due to anatomical differences in the Purkinje distribution system or in the musculature itself.
- The axis varies normally with age & body built
- Some pathological conditions can cause axis deviation
- Any two limb leads can be used to determine the axis.
- There are a number of ways via which a cardiac axis can be determined using an ECG and the hexaxial reference system.



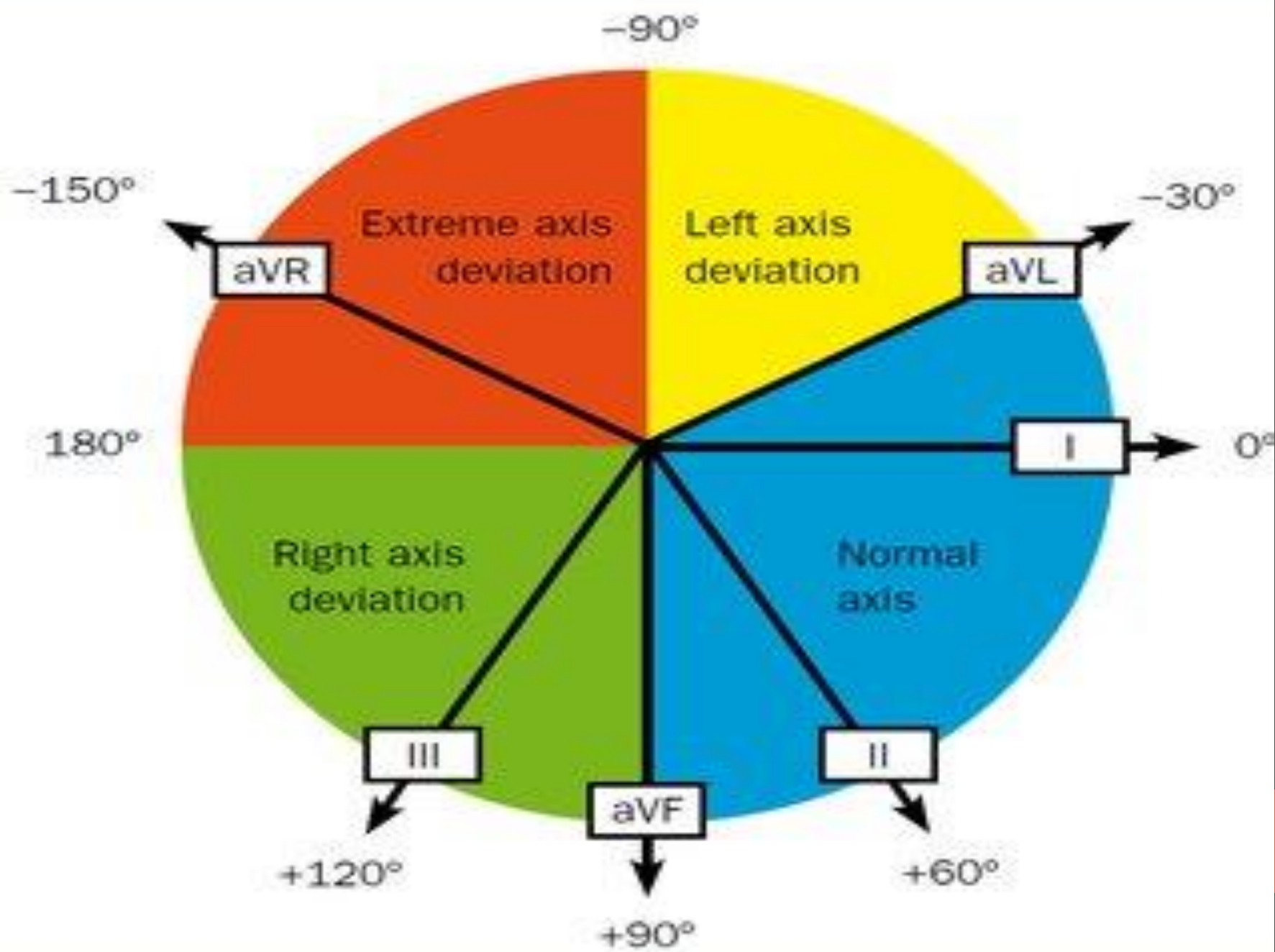
**Predominantly
Positive**



**Predominantly
Negative**



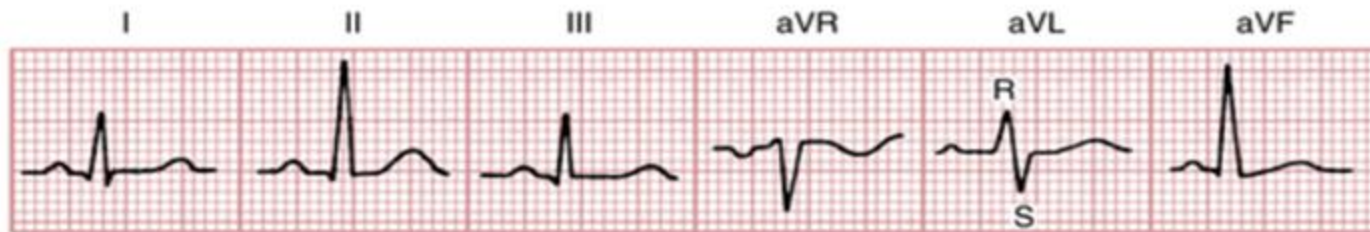“Isoelectric”




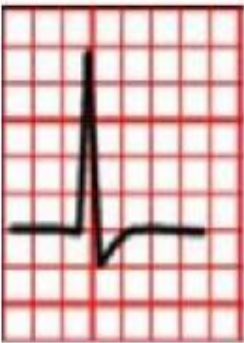

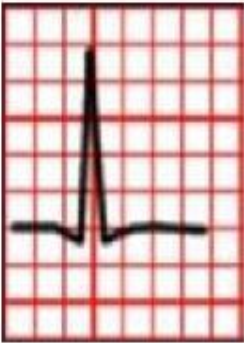
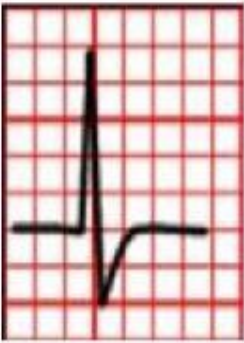
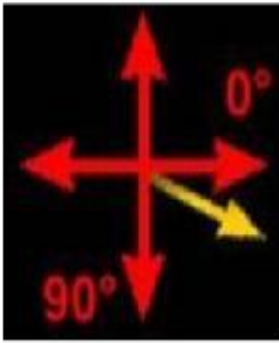
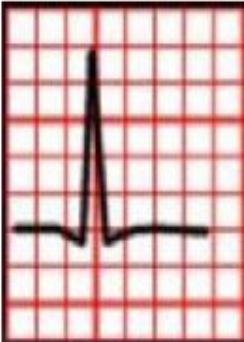

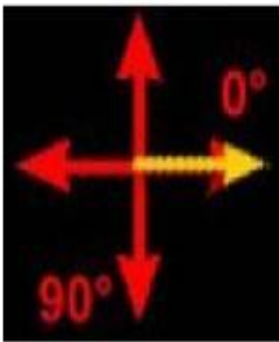
- Quadrant Method (Qualitative)

Lead I	Lead aVF	AXIS
Positive	Positive	Normal
Positive	Negative	Left Axis Deviation or Normal
Negative	Positive	Right Axis Deviation
Negative	Negative	Extreme Axis Deviation

To further distinguish normal from left axis deviation When Lead I is positive & Lead aVF is negative we look at lead II. If lead II negative, then the cardiac axis is more towards -120 , and left axis deviation is present. If the QRS complex in lead II is positive, then the cardiac axis is more towards $+60$ degrees, and the cardiac axis is normal.



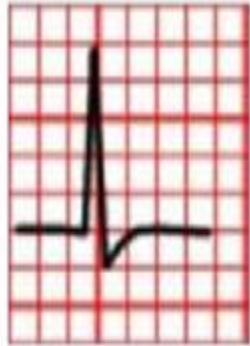In the example above both lead I and aVF are positive so the axis is normal

	Lead 1	Lead aVF	Description	Interpretation	Axis
ECG#1			Leads I and aVF equally positive. The axis will be midway between 0° and 90°.	Normal axis ~ 40°-50°	
ECG#2			Leads I and aVF both positive. Lead I more positive than aVF. The axis will therefore be oriented more toward 0°.	Normal axis ~ 20° - 40°	
ECG#3			Lead I positive. Lead aVF almost equiphasic. Therefore, the axis will be approaching 0°. (<i>Note: when a lead is equiphasic, the axis will be 90° to that lead.</i>)	Normal axis ~ 0°	

Lead I

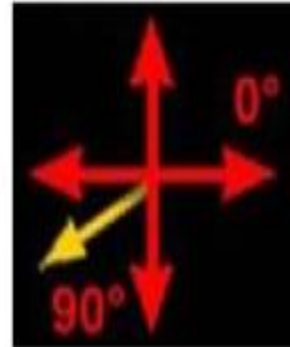Lead aVF

ECG#5





Lead I negative. Lead aVF positive. The axis will be oriented positively past 90°.

Right axis deviation ~ -120°

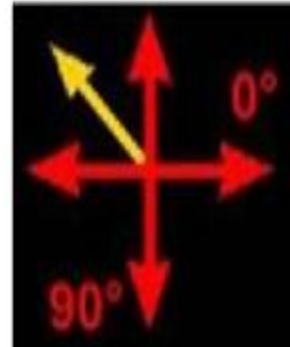

ECG#6



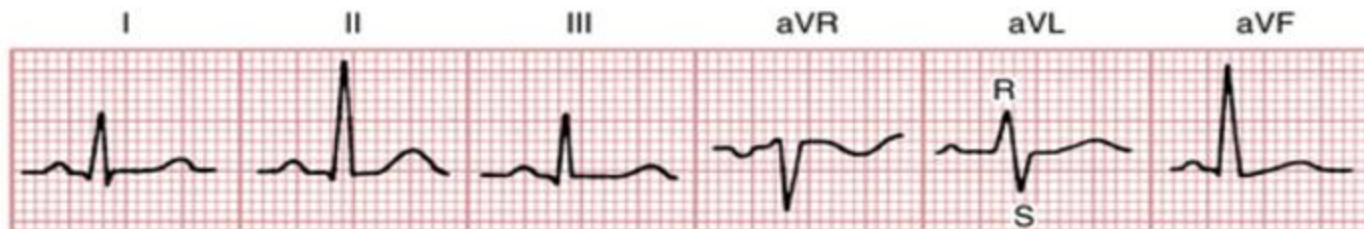Both leads I and aVF negative. The axis will be oriented between -90° and -180°.

Indeterminate axis ~ -135°



The isoelectric lead method

1. Find the isoelectric lead; it has zero net amplitude. This can be either:
 - A biphasic QRS where R wave height = Q or S wave depth.
 - A flat-line QRS with no discernible features.
2. Look for the lead perpendicular to the isoelectric lead. If the QRS complex in this lead is predominantly positive, the cardiac axis will be located in its direction; if the QRS is predominantly negative, the cardiac axis will be located on the opposite direction



In the above example, the most isoelectric lead is aVL. Lead II is perpendicular to it. Lead II is positive so the cardiac axis must be in its direction which is 60 degrees. So the axis is normal.

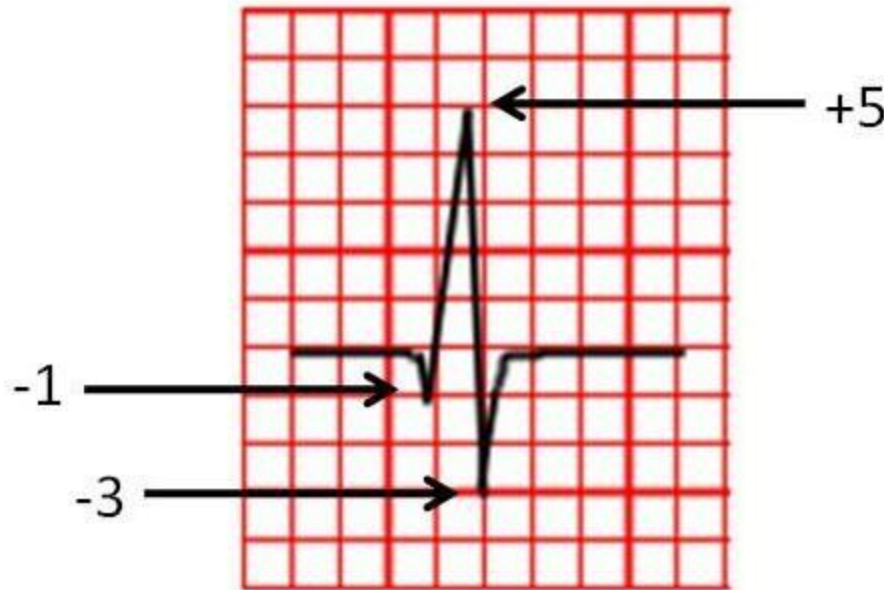
Mathematical method

- Calculating the Axis:
 1. Record the bipolar and augmented limb leads
 2. Determine the net potential and polarity of the recordings in leads I and aVF.
 3. The net potential for leads I and aVF is plotted on the axes of the respective leads, with the base of the potential at the point of intersection of the axes. If the net potential of the lead is positive, it is plotted in the positive direction. Conversely, if this potential is negative, it is plotted in a negative direction.
 4. Draw perpendicular lines from the apices of leads I and aVF potentials. The point of intersection of these two perpendicular lines represents the apex of the mean QRS vector in the ventricles, and the point of intersection of the lead I and lead aVF axes represents the negative end of the mean vector. Therefore, the mean QRS vector is drawn between these two points.
 5. To determine the axis, measure the angle created by the vector using a **protractor** or use the tangent rule

The tangent of the angle = $\frac{\text{the length of the opposite side}}{\text{the length of the adjacent side}}$

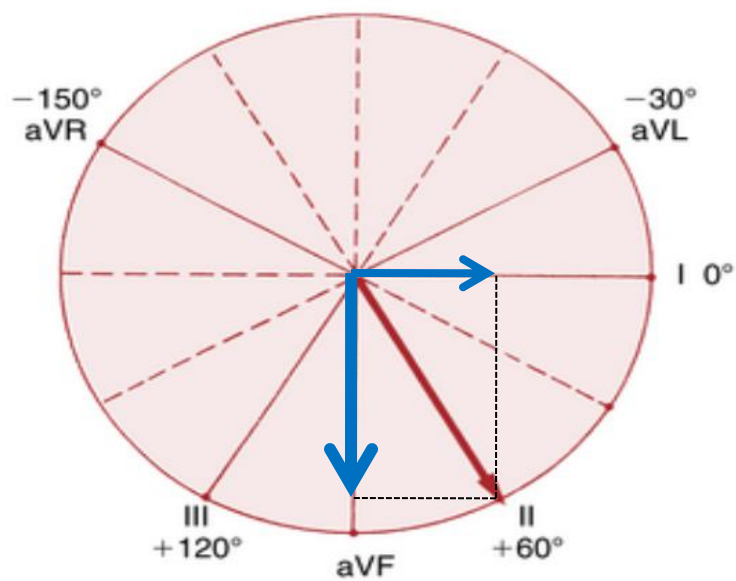
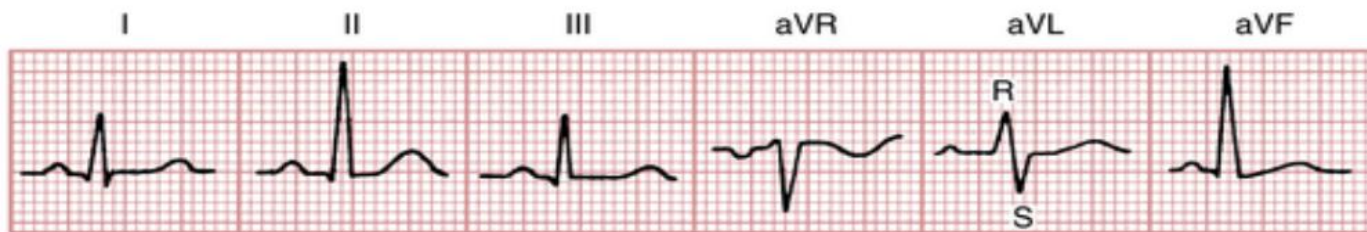calculating the net QRS potential(deflection)

If the recording is mostly positive but has some negative potential, this negative potential is subtracted from the positive part of the potential to determine the **net potential** for that lead and vice versa.



$$\begin{aligned} \text{Net deflection} &= 5 - 1 - 3 \\ &= +1 \end{aligned}$$

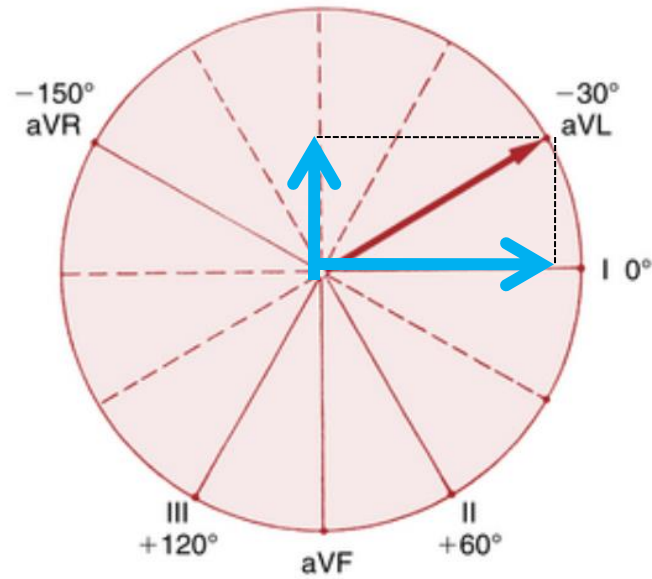
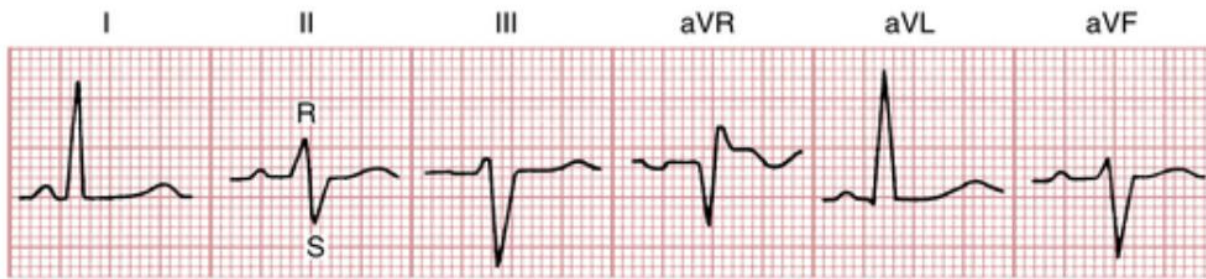
Voltage of the QRS complex is measured from the peak of the R wave to the bottom of the S or Q wave. In the above example it is 8 mV



Lead I = 5mm

Lead aVF = 10mm

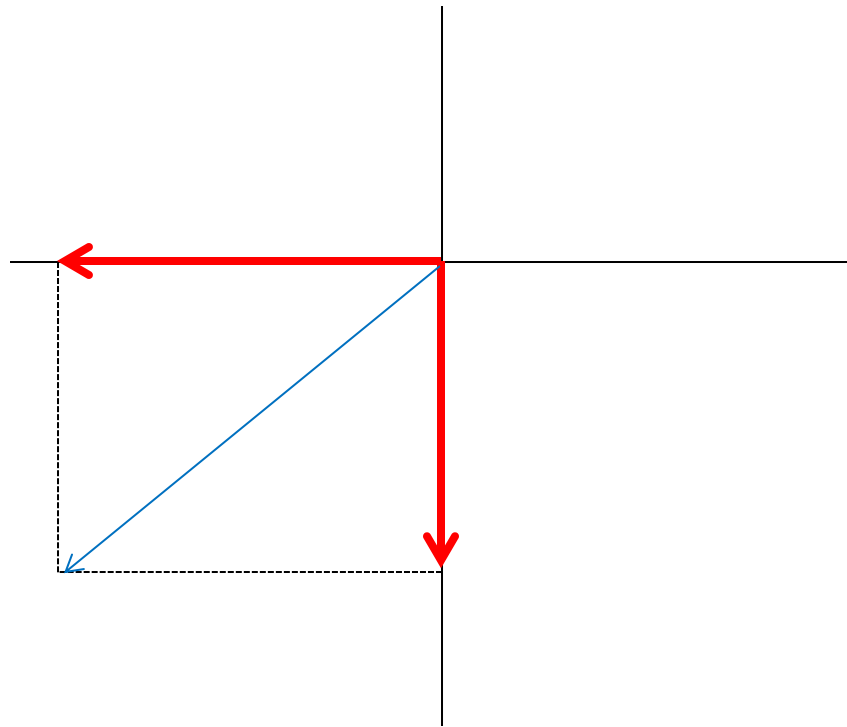
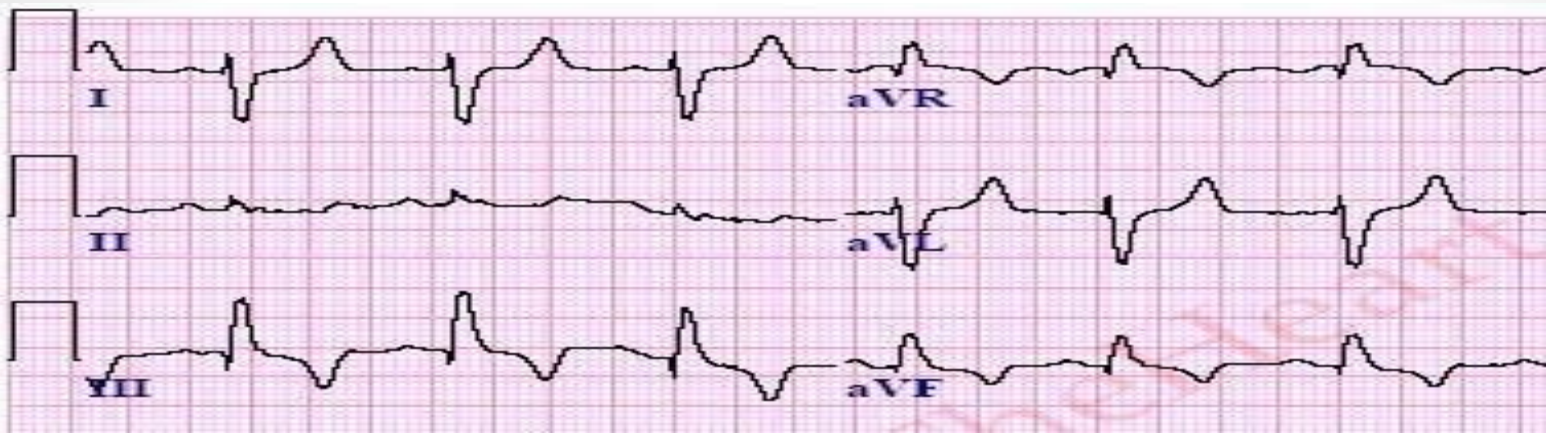
The angle of the calculated axis is 60°, so this is a normal axis



Lead I = 12mm

Lead aVF = -6mm

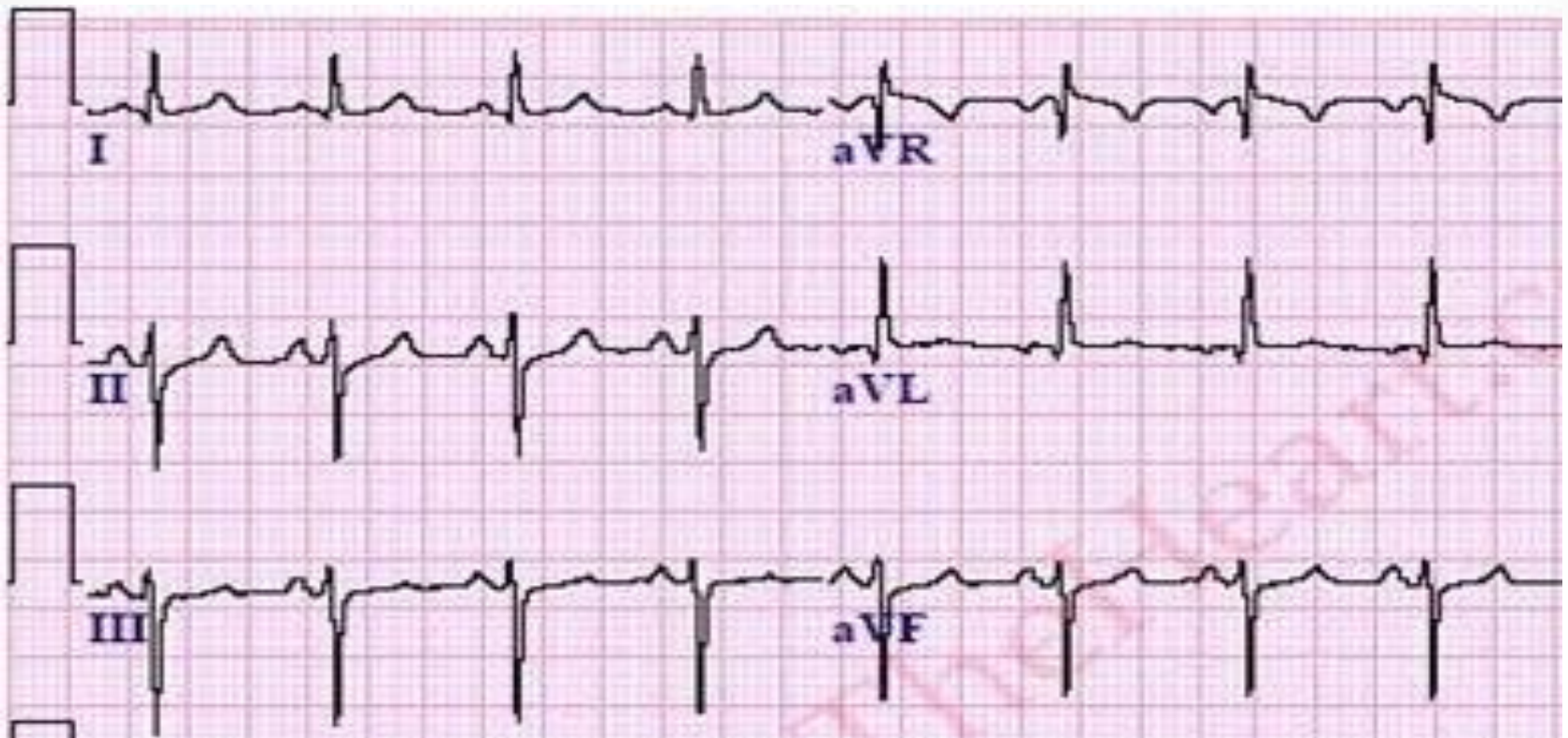
The angle of the calculated axis is -30 so this is Normal Axis



Lead I = -6mm

Lead aVF = 5mm

Angle is 140 so this is Right Axis deviation



Calculate the Axis.

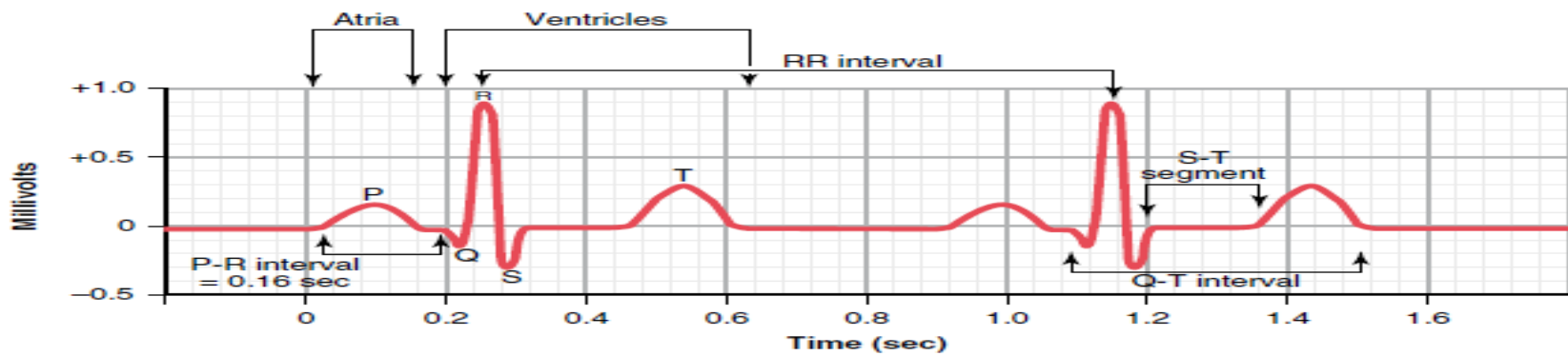


Figure 11-1 Normal electrocardiogram.

- The waves, intervals & segments of the ECG
 - P wave
 - QRS complex
 - T wave
 - PR interval
 - QT interval
 - R-R interval
 - ST segment
 - TP segment
 - PR segment

P wave

- Represents Atrial depolarization
- The axis of atrial depolarization is 70 degrees
- Usually, lead II will have the clearest P wave.
- The maximum height of the P wave is 2.5-3 mm.
- The P wave duration is shorter than 0.12 sec.
- Positive in inferior leads II, III & aVF

- When atrial repolarization starts the area that had originally become depolarized first will repolarize first. So the region around the sinus node becomes positive with respect to the rest of the atria. This makes the repolarization vector in opposite direction to the depolarization vector. This results in a repolarization wave that is negatively deflected

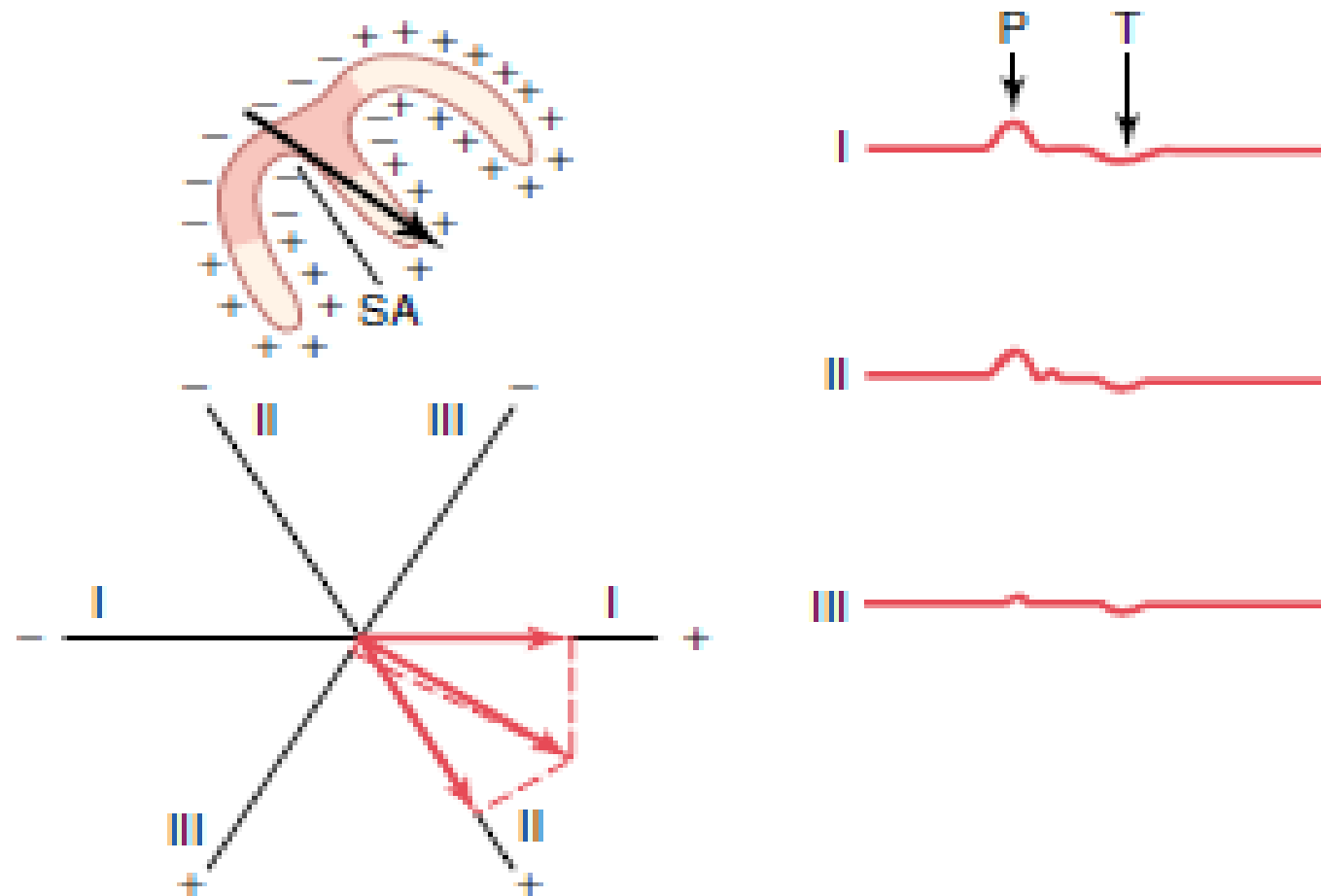
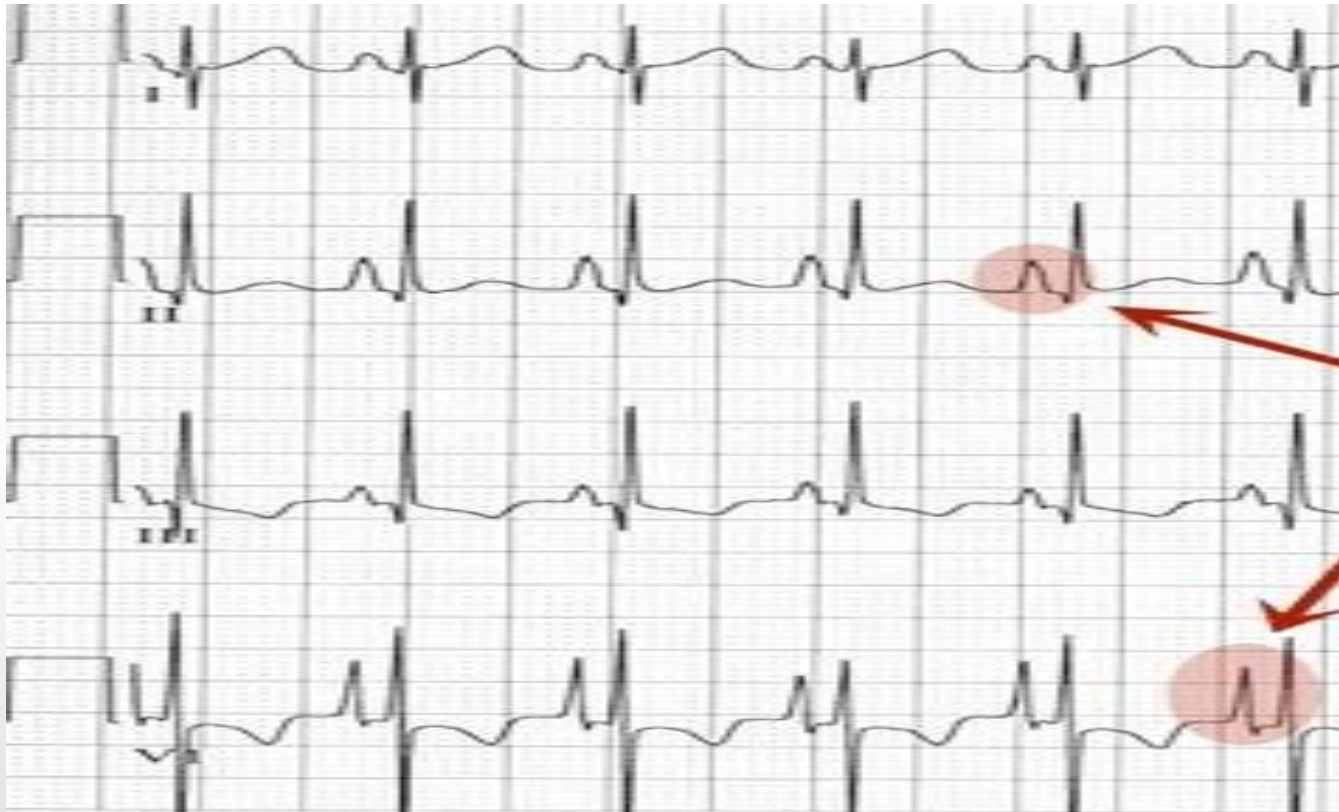

Figure 12-9 Depolarization of the atria and generation of the P wave, showing the maximum vector through the atria and the resultant vectors in the three standard leads. At the right are the atrial P and T waves. SA, sinoatrial node.

P wave Abnormalities

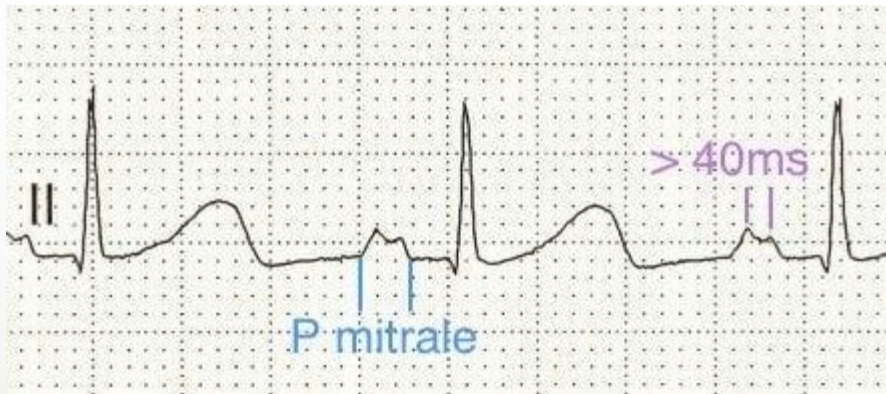
- Right atrial enlargement results in a P wave that is peaked and narrower than usual called **P Pulmonale**



P pulmonale

P wave Abnormalities

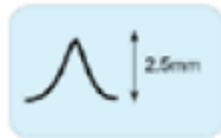
- Left atrial enlargement results in a notched P wave with prolonged duration called **P Mitrale**




Normal Sinus Rhythm



Right atrial enlargement
(= P Pulmonale)



Left Atrial Enlargement
(=P Mitrale)

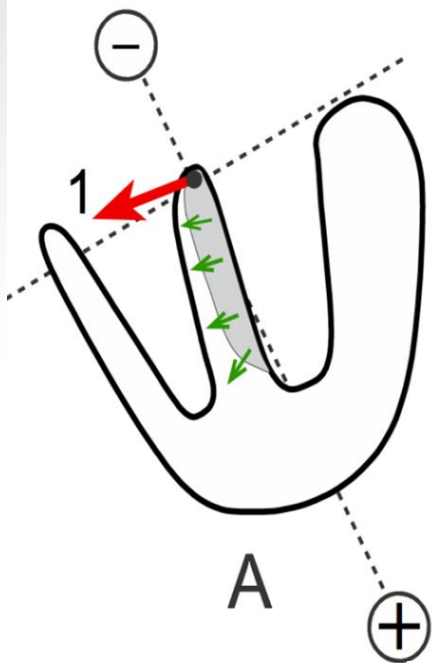


QRS complex

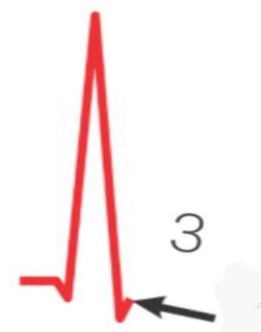
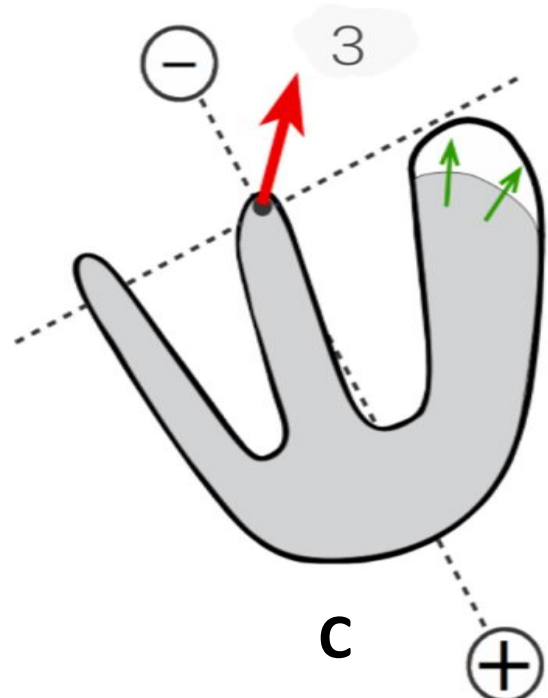
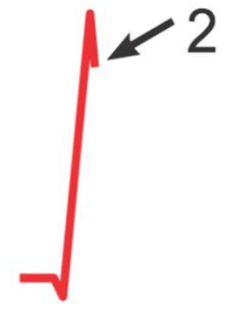
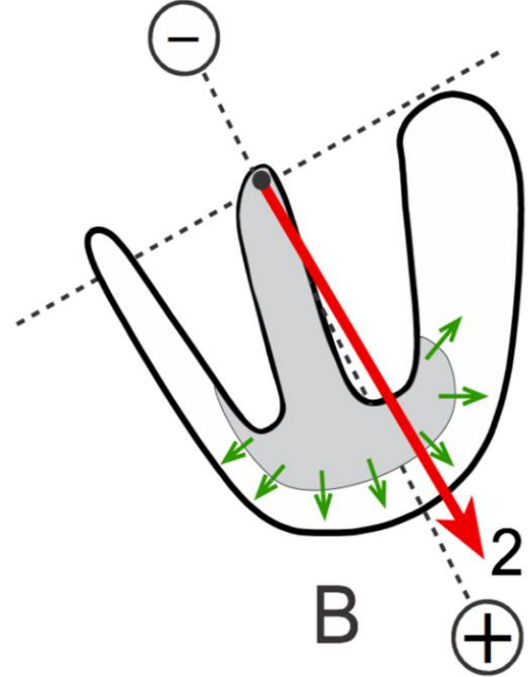
- Q wave is the first negative deflection
- R wave is the first positive deflection
- S wave is any negative deflection following R wave.

- QRS Duration: 0.06 - 0.1 sec

- QRS voltage should be greater than 0.5 mV in at least one limb lead, and greater than 1.0 mV in at least one chest lead. Upper limit of normal voltage in chest leads is 2.5 - 3.0 mV.

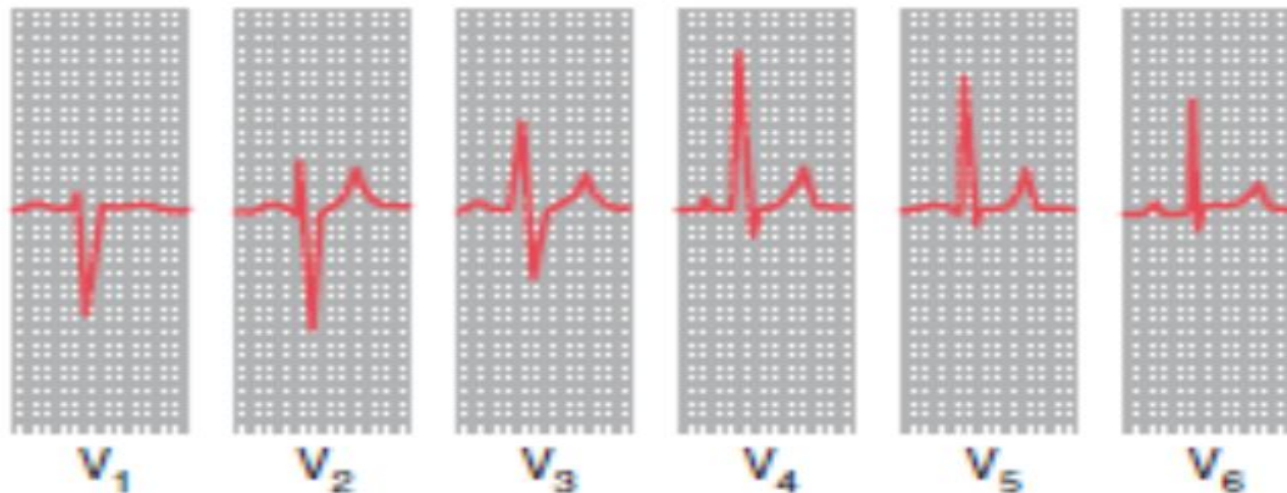


QRS Complex
Lead II



QRS complex progression in chest leads

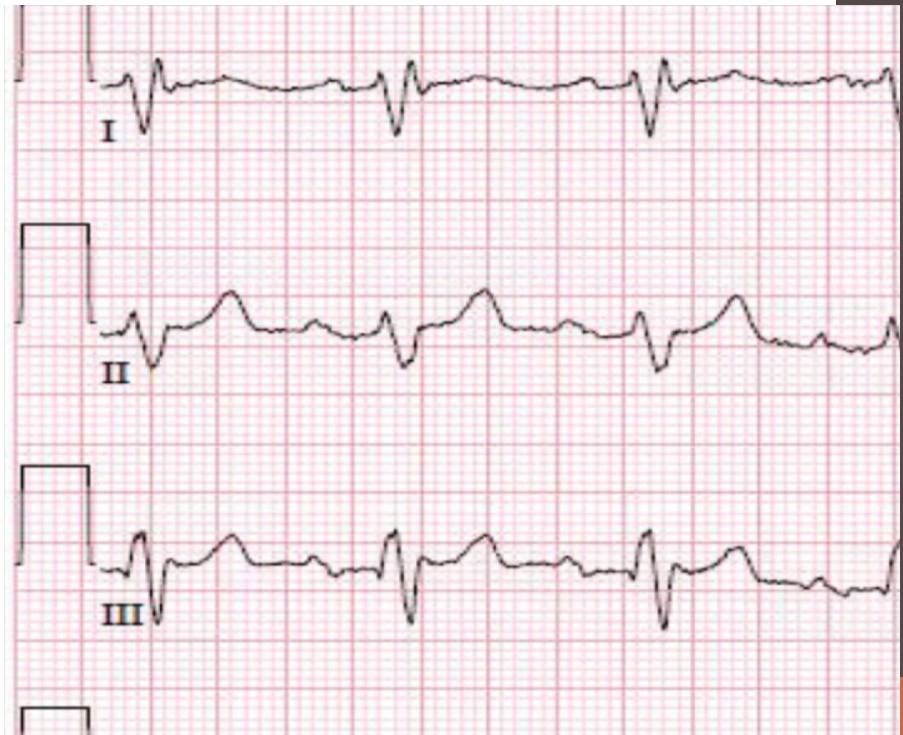- The QRS complex in the chest leads shows a progression from lead V1, where it is predominantly negatively deflected, to lead V6, where it is predominantly positively deflected. The 'transition point', where the R and S waves are equal, indicates the anatomical position of the interventricular septum. It is normally seen in leads V3 or V4.



If the right ventricle is enlarged, and occupies more of the precordium than is normal, the transition point will move from its normal position of leads V3/V4 to leads V4/V5 or sometimes leads V5/V6.

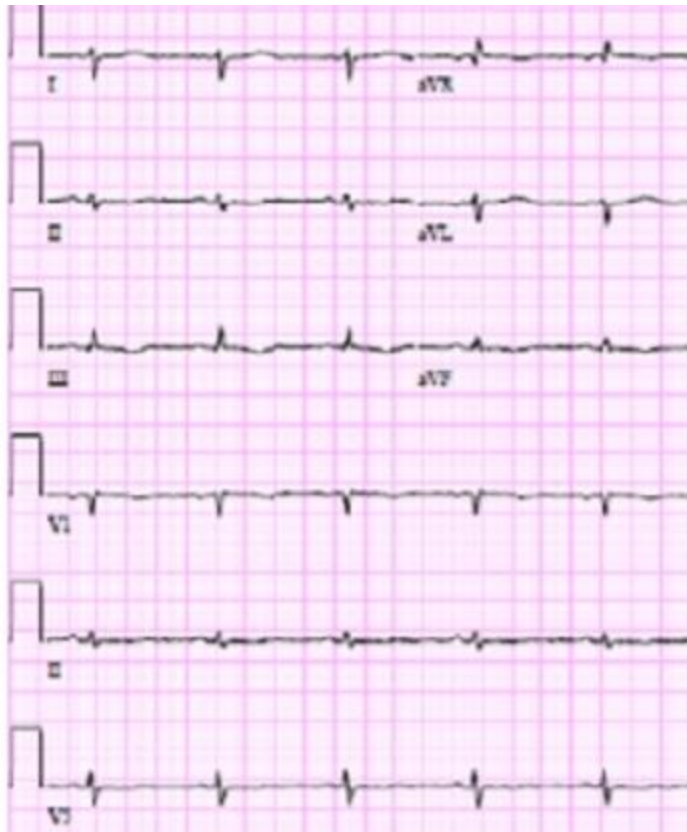QRS Abnormalities

- Increased QRS width:
 - Cardiac hypertrophy or dilatation
 - Bundle branch block, in this case the QRS duration > 0.12 sec



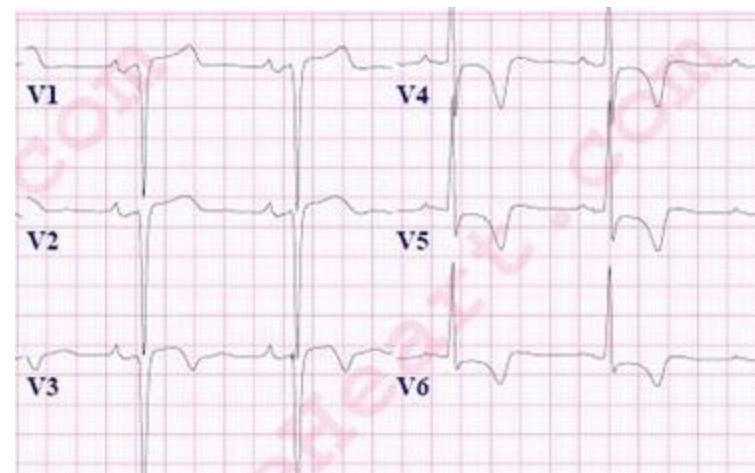
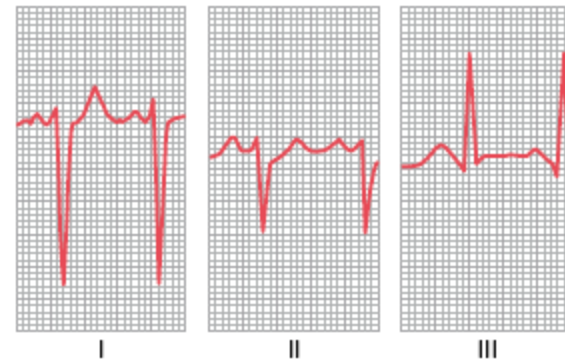
➤ Low voltage:

- Old myocardial infarctions
- Pericardial effusion



➤ High voltage :

- Cardiac hypertrophy



Pathological Q wave

- Q waves are considered pathological if:
 - > .04 sec
 - > 2 mm deep
 - > 25% of depth of QRS complex
- **Pathological Q waves usually indicate ongoing or prior myocardial infarction.**

V1

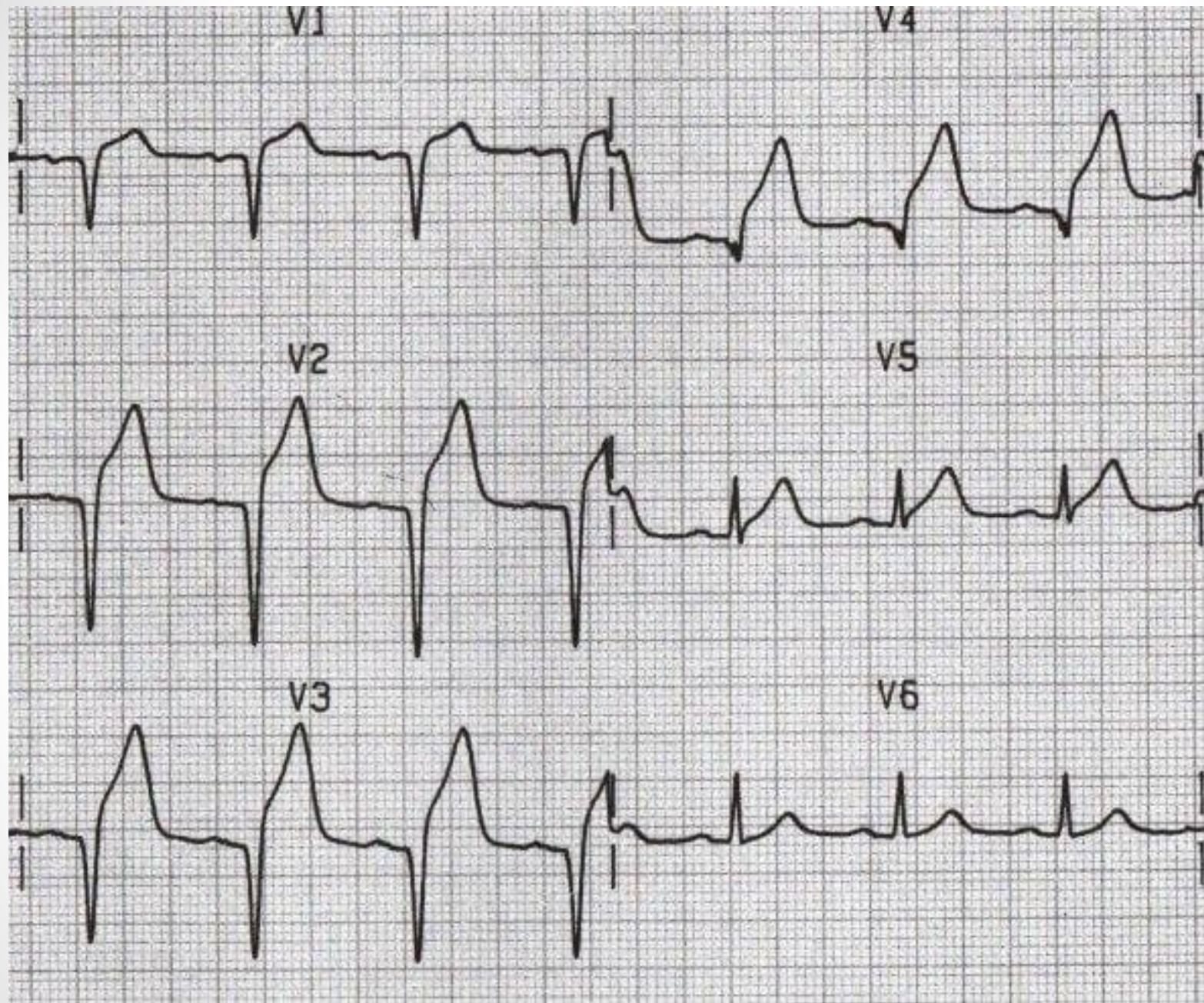
V4

V2

V5

V3

V6



T wave

- The outer surface of the ventricles, especially near the apex of the heart is the first to repolarize, and the endocardial areas repolarize last.
- The overall ventricular vector during repolarization is towards the apex of the heart.
- T wave deflection should be in the same direction as the QRS complex
- In normal adults, the T wave is usually upright in all leads, except the aVR and V1 leads (sometimes aVL & III)
- Normally rounded and asymmetrical with a rounded peak.
- When compared to QRS complex it has longer duration and lower voltage. Because repolarization occurs slower than depolarization.
- The height of the T wave should not exceed 5 mm in limb leads and 10 mm in chest leads

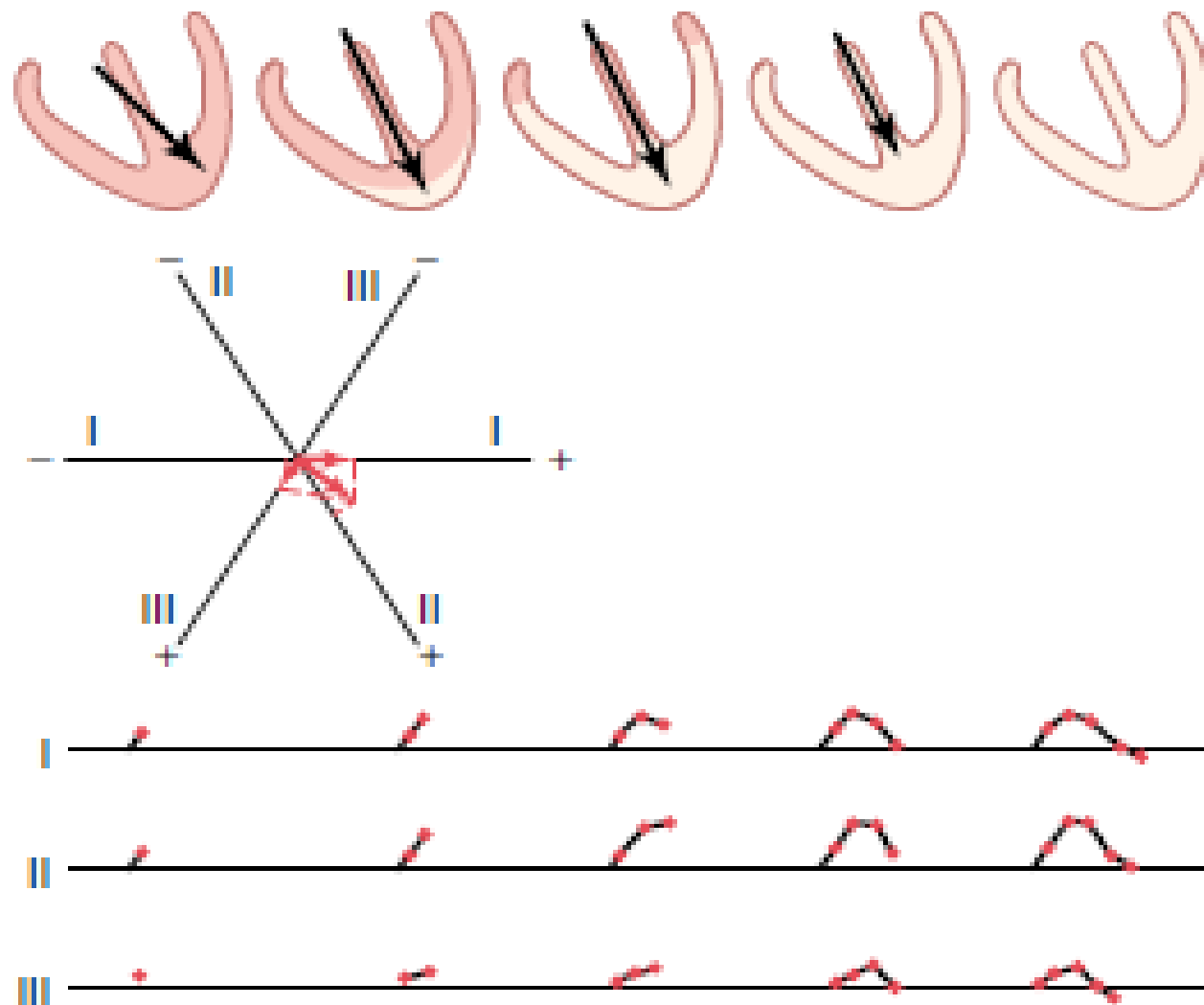
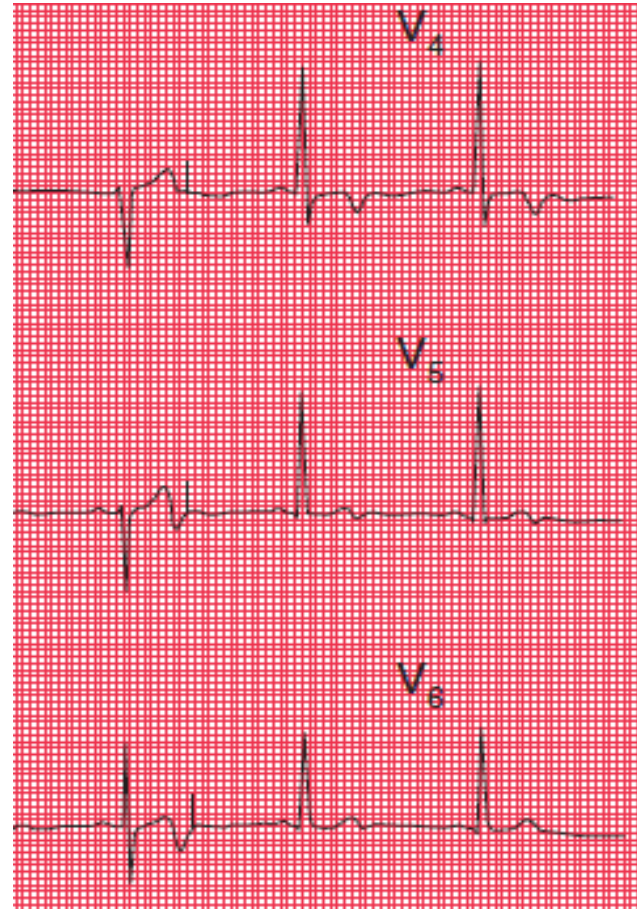


Figure 12-8 Generation of the T wave during repolarization of the ventricles, showing also vectorial analysis of the first stage of repolarization. The total time from the beginning of the T wave to its end is approximately 0.15 second.

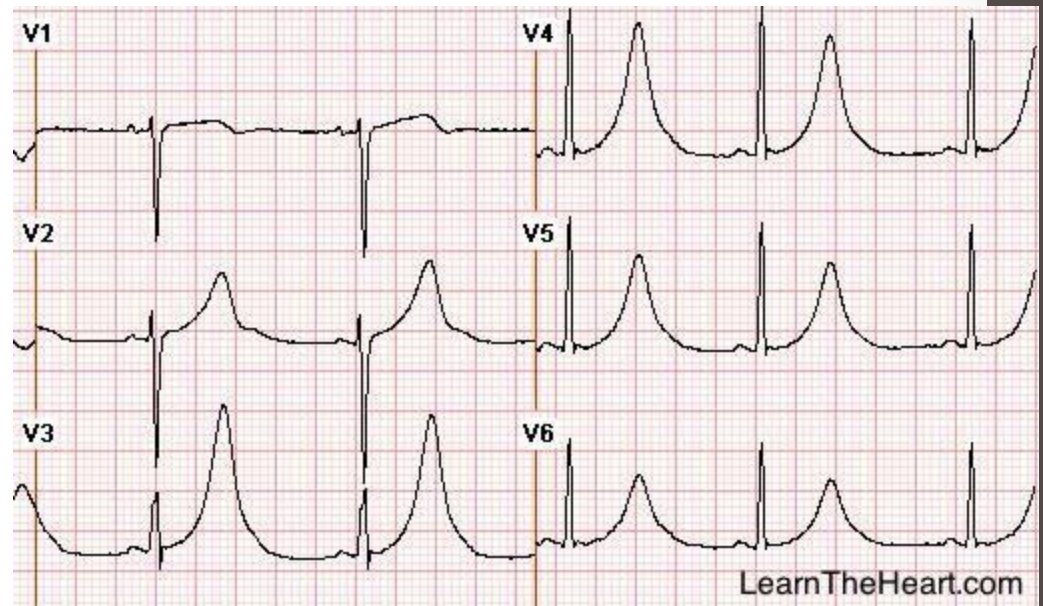
T wave abnormalities

- T wave inversion:
 1. Mild ischemia
 2. Ventricular hypertrophy
 3. Bundle Branch Block
 4. Digoxin Toxicity
 5. Normal finding in aVR & V1



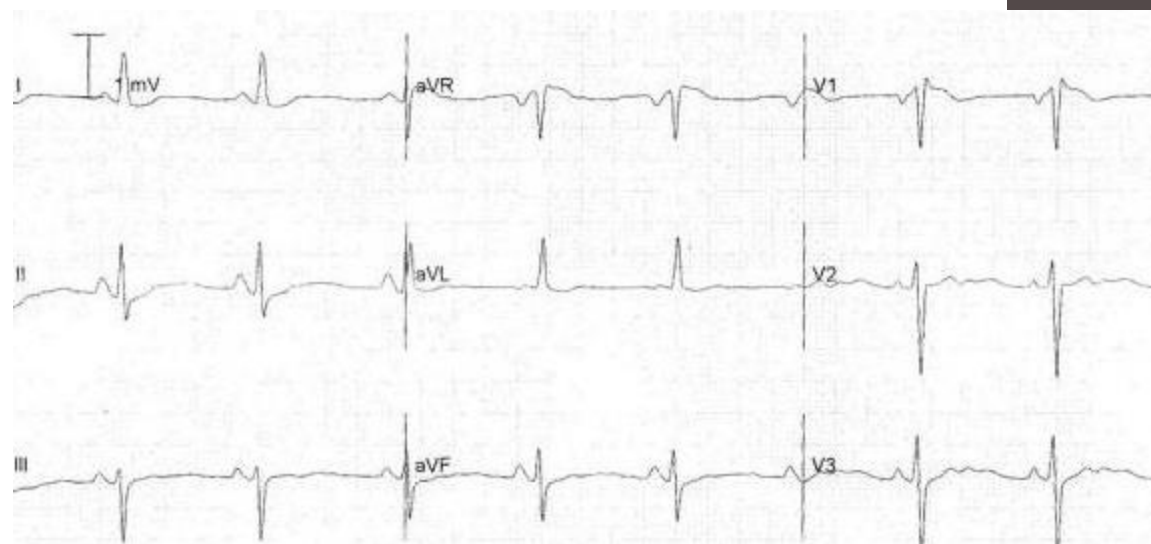
- Peaked & tall T waves:

1. Early stages of MI
2. Hyperkalemia
3. Normal finding



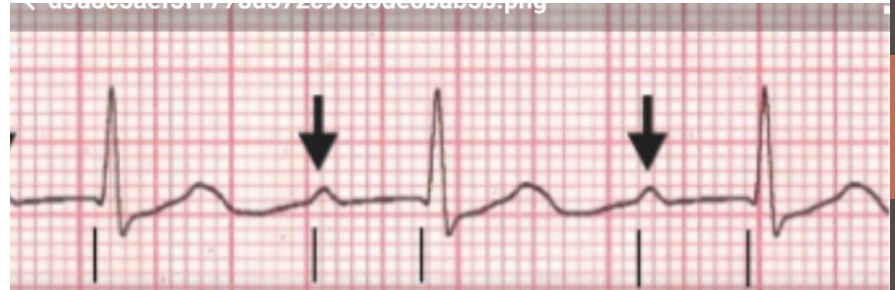
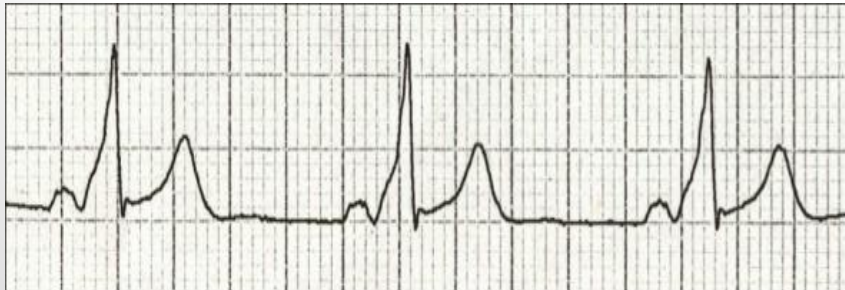- Flattened T Wave

1. Hypokalemia
2. Ischemia



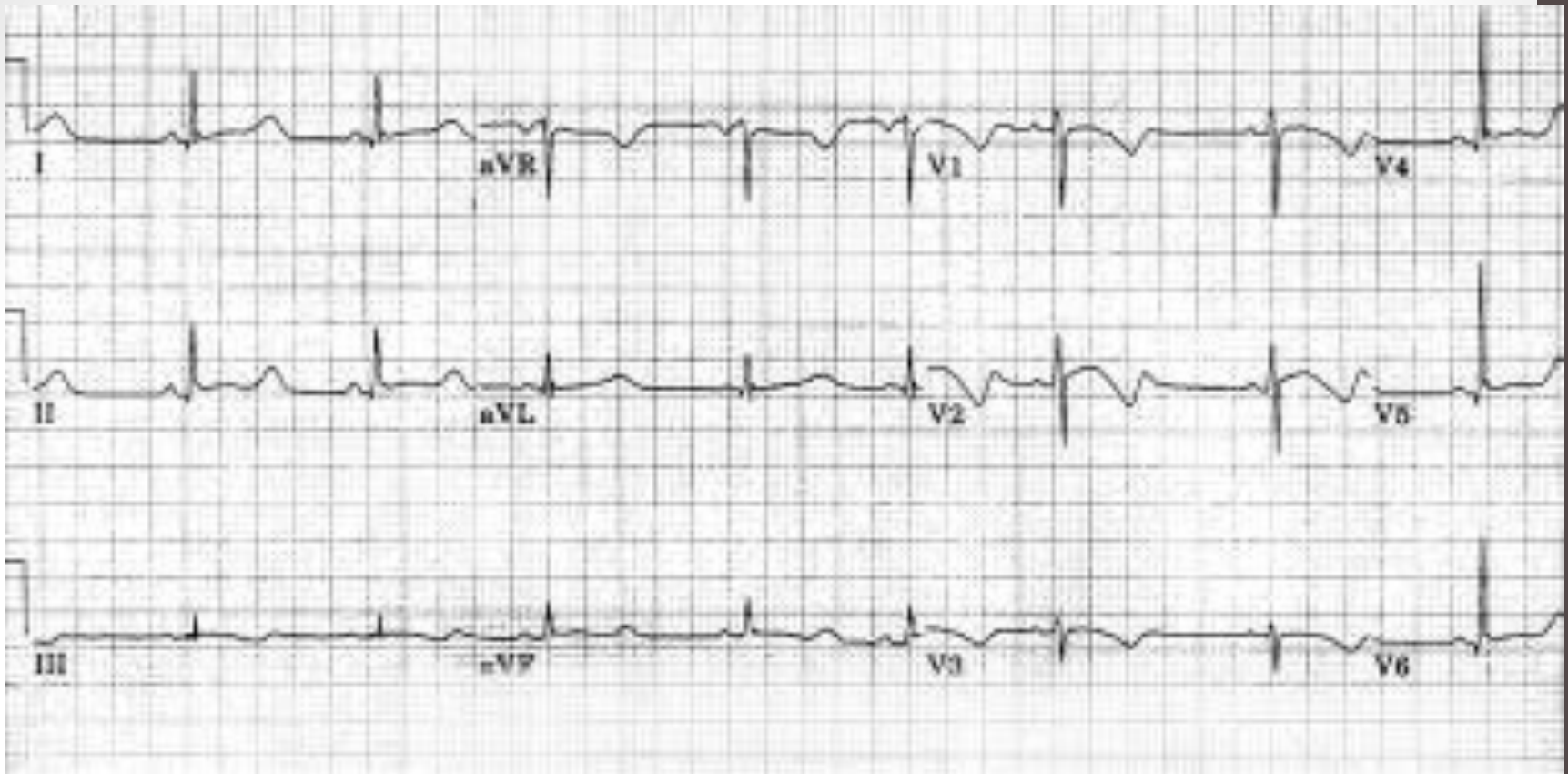
PR interval

- The PR interval is measured from the beginning of the P wave to the beginning of the QRS complex
- The normal PR interval is 0.12–0.22 seconds
- Short PR interval:
 - Abnormally fast conduction from the atria to the ventricles
- Long PR interval:
 - First degree heart block



QT interval

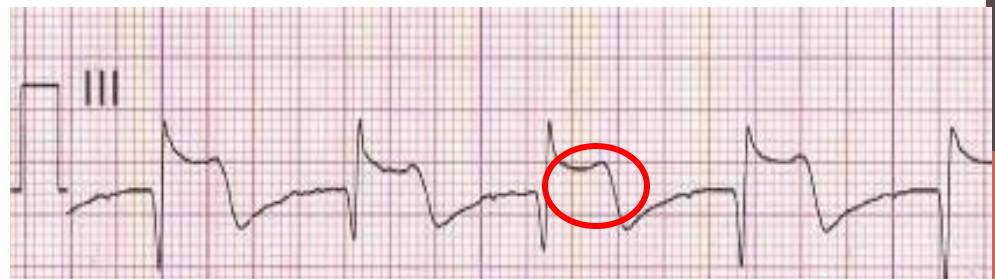
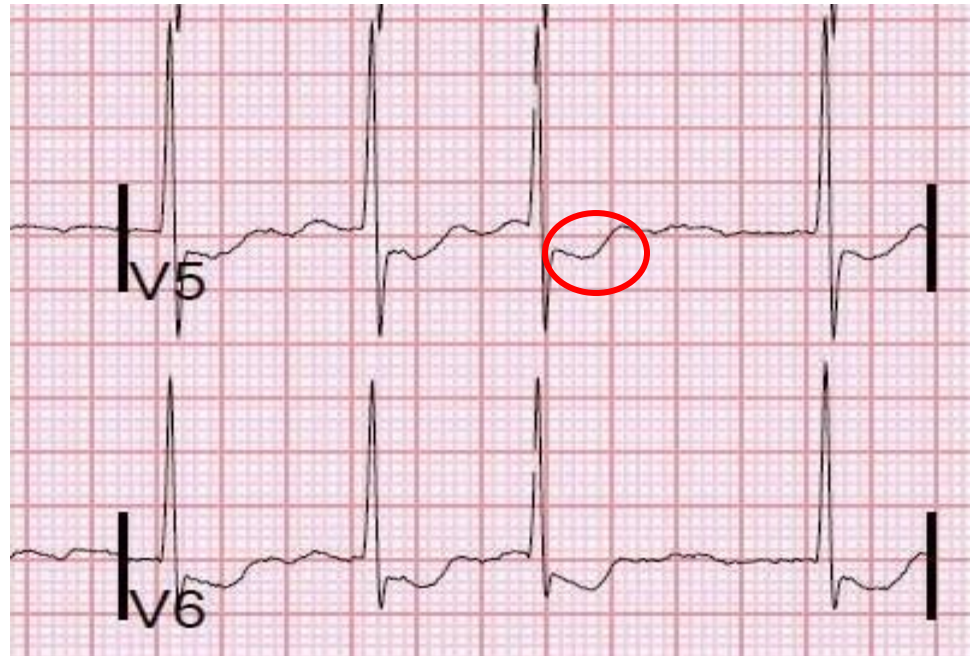
- The time from the beginning of the QRS complex to the end of the T wave
- Should be less than 0.43 seconds
- QT interval is inversely correlated with heart rate so it must be corrected for heart rate. The corrected QT interval is calculated using the following formula:
- $QT \text{ corrected} = (QT \text{ observed}) / (\text{square root of RR interval})$
- Prolonged QT interval is seen in Long QT syndrome, hypokalemia, hypocalcemia & hypothyroidism.



Marked prolongation of QT interval in a 15-year-old male adolescent with long QT syndrome (LQTS) (R-R = 1.00 s, QT interval = 0.56 s, QT interval corrected for heart rate [QTc] = 0.56 s)

ST segment

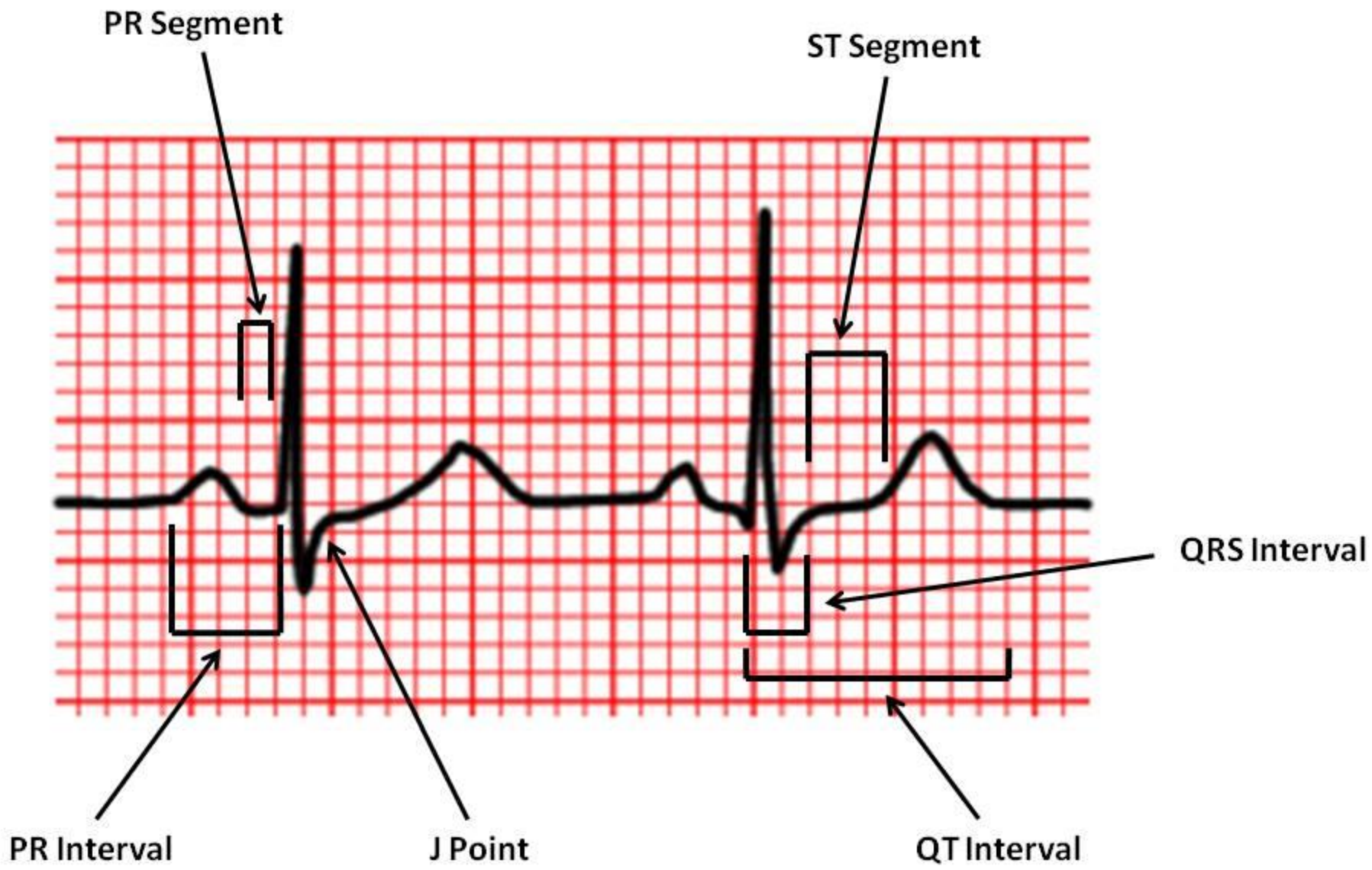
- Extends from the end of the QRS complex to the beginning of the T wave
- Should be isoelectric
- Compare it to the T-P segment
- Should be checked in all leads
- Depressed in ischemia
- Raised in MI & pericarditis



To be considered significant, more than 1 mm of ST segment elevation in at least two contiguous limb leads (e.g. I and VL; III and VF), or more than 2 mm of ST segment elevation in at least two contiguous precordial leads

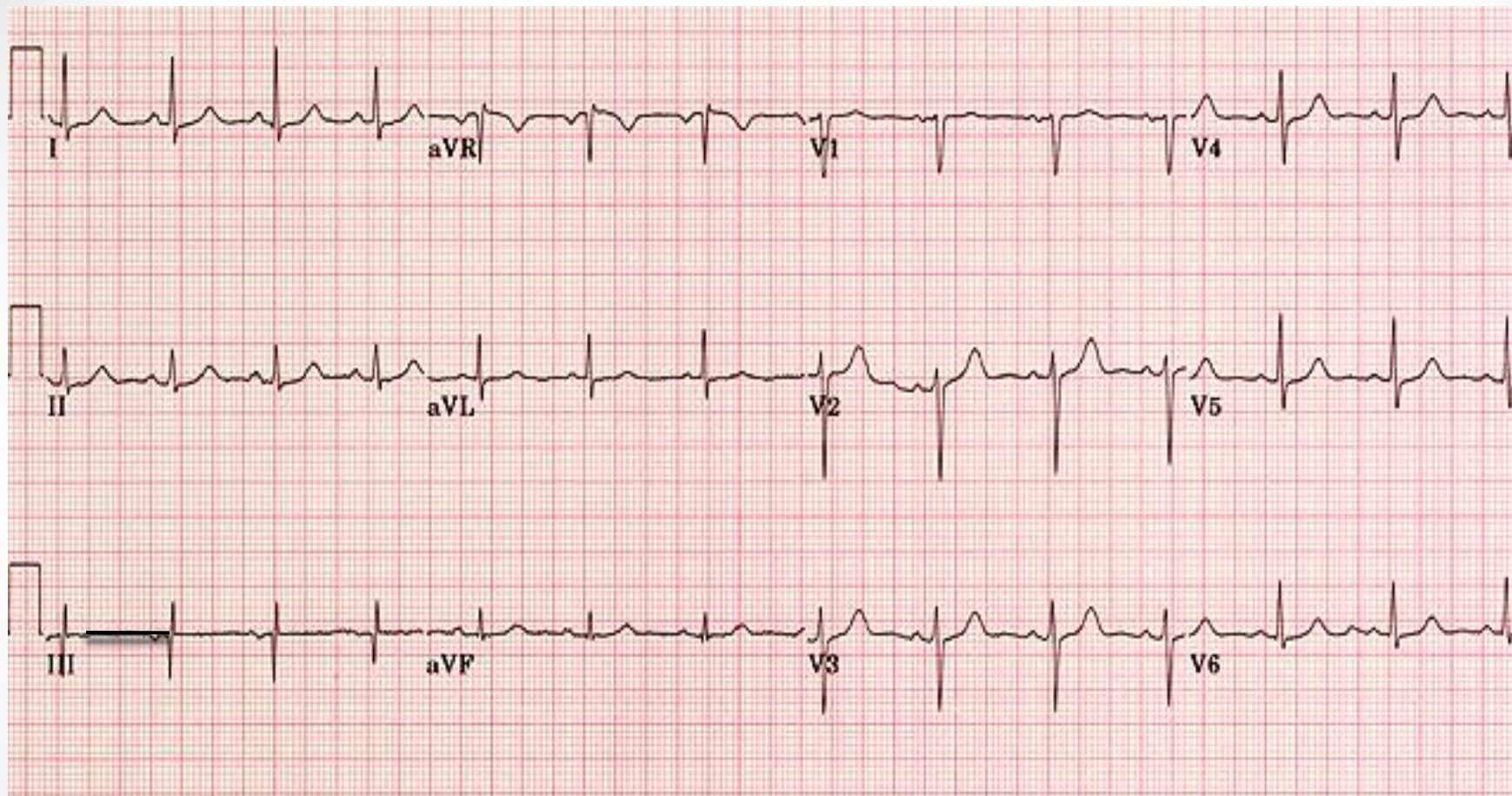
HOW TO REPORT AN ECG

- When reporting an ECG the report should include:
 1. The rate
 2. Rhythm
 3. Cardiac axis
 4. A description of the P waves, QRS complexes, & T waves.
 5. A description of the ST segment.
 6. A description of conduction intervals
- ✓ Don't forget to mention the patient's name , age & gender.
- ✓ Don't forget to check the speed of ECG record & the voltage calibration



Choose the lead with the clearest waves to perform these measurements.

Ahmad Saif. Age: 32 Y Gender :male



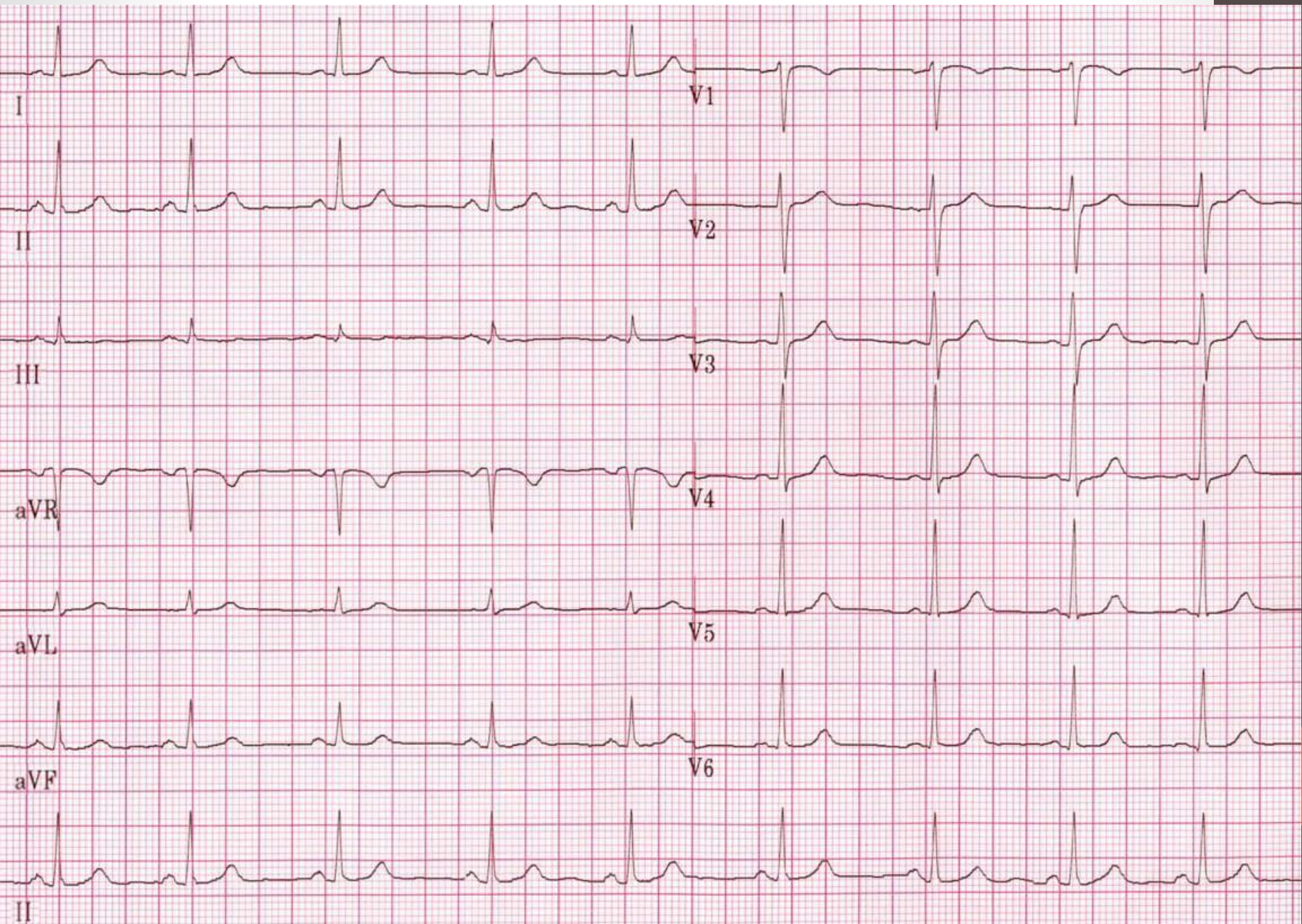
25mm/sec 10mm/mV

- This ECG belongs to Ahmad Saif a 32 year old male patient who presented to the ER with chest pain.
- The heart rate is 94 beats/min. R-R interval 0.64 sec
- Normal sinus rhythm. There is a P wave before every QRS complex. The P waves all look alike in same lead. Little R-R variation.
- The cardiac axis is within normal limits (21 degrees).
- P waves duration is 0.08 sec & are upright in the inferior leads
- The QRS complexes duration is 0.06 sec. R wave progression is correct in the chest leads.
- The T waves are upright except in Lead aVR which is normal.
- The PR interval is about 0.16 sec. and the QT interval is about 0.32 sec. QTc = 0.4 sec. Both are normal
- The ST segments are isoelectric in all leads.

- Practice reporting ECG on the following example of a normal ECG

Huda Jamal 40 years Female

25mm/sec 10mm/mV



THANK YOU

