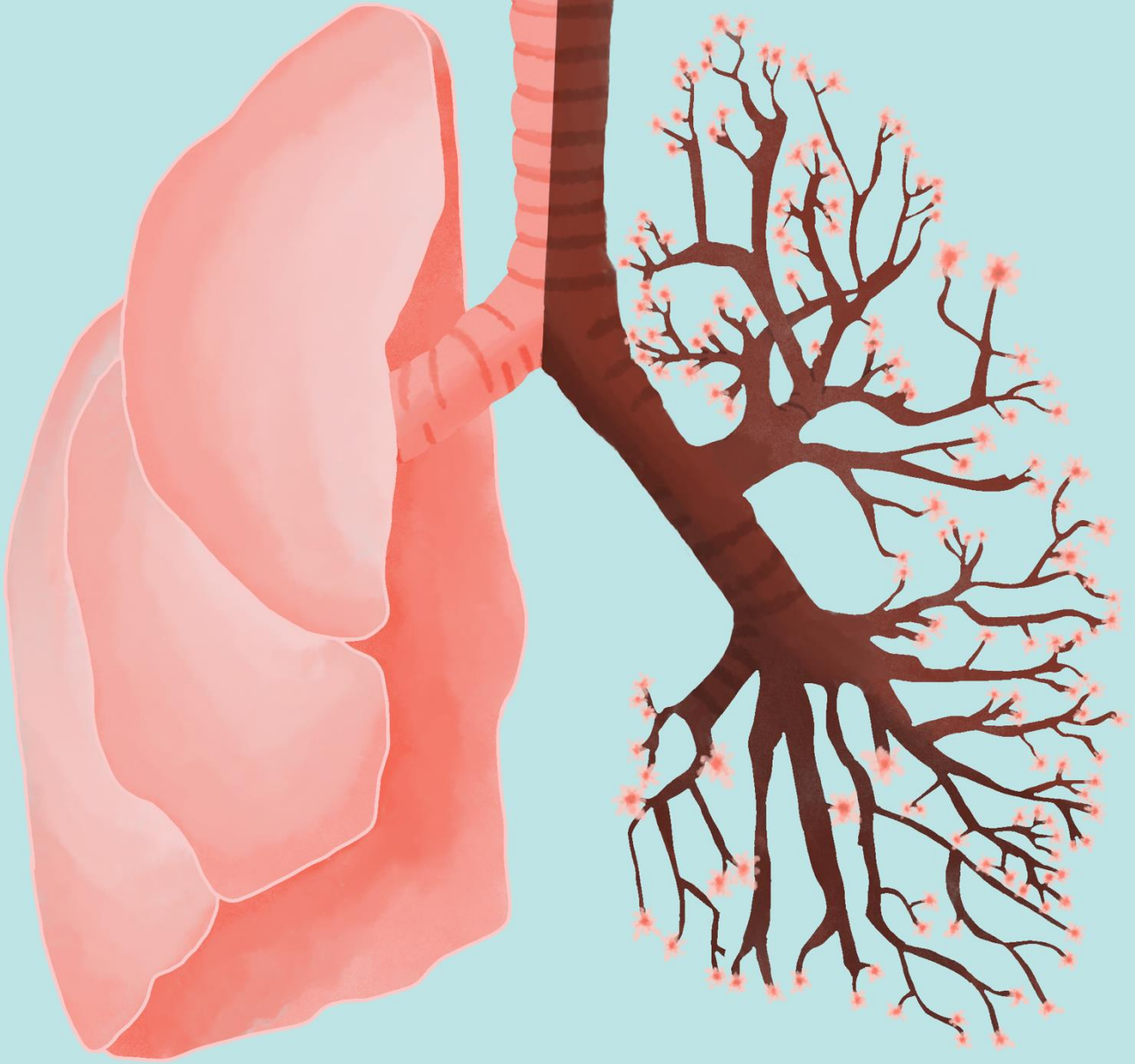

RESPIRATORY SYSTEM



PBL



Title: Sheet 1 – Upper Airway Obstruction in Children

Writer: Laila Nazzal

Science: Batool Albdour

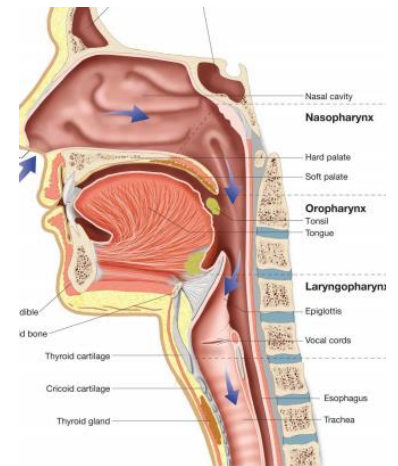
Final: Lina abdelhadi

Doctor: Montaha AL-Iede

UPPER AIRWAY OBSTRUCTION IN CHILDREN

The respiratory system is divided into upper and lower airways; in this lecture we are interested in cases of the **upper airways**, while the lower airways will be discussed in the next lecture.

Anatomy revision: Upper respiratory tract includes (Nose, Pharynx -nasopharynx and oropharynx-, Larynx and finally extra thoracic part of trachea which is considered a part of the upper airways.



STRIDOR:

❖ Obstructive conditions are usually associated with musical noisy sounding breaths

There are two main sounds of interest, wheezing and stridor. You can hear these sounds by clicking on them!

- **stridor** is mainly associated with → **Upper airway obstruction**
- While **wheezing** is mainly associated with → **lower airway obstruction**

As we're discussing the upper airways, our following discussion is all about stridor, its types and major causes.

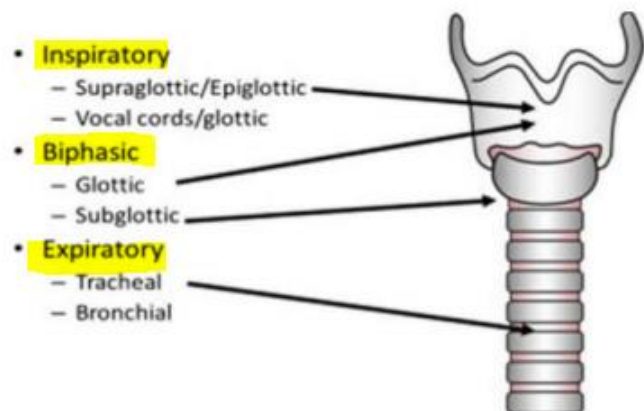
❖ Types of stridor: depending on the anatomical obstruction site are 3:

- **Inspiratory stridor**: sound is heard during **inspiration** (the obstruction is usually **high** at the level of supraglottic, epiglottic or vocal cord regions)
Examples of diseases causing this type: croup and epiglottitis. Coming in downwards discussion.

It's important to mention here that the **Majority** of stridor is **inspiratory**

- **Biphasic**: occurs during inspiration and expiration "continuous". (obstructed regions are subglottic or glottic regions). It is associated with fixed anatomical obstruction;

TYPES OF STRIDOR



💡 **Further clarification:** in **dynamic** obstruction, there may be a change in the state of obstruction during breathing phases, while in **fixed** problems there is no change in the shape of the airway nor in the state of obstruction thus it's biphasic.

Examples: an example of a fixed problem is a severely immature baby - born at about 25th weeks of gestation- who required mechanical ventilation and was intubated for 5 months for example which is a long duration; this baby may face **subglottic stenosis** which is considered a fixed problem.

Conversely, in *laryngomalacia*; which is a dynamic obstructive state, the larynx changes its state while breathing. i.e. in inspiration it closes causing stridor, in expiration it opens normally causing no stridor (thus it's not biphasic)

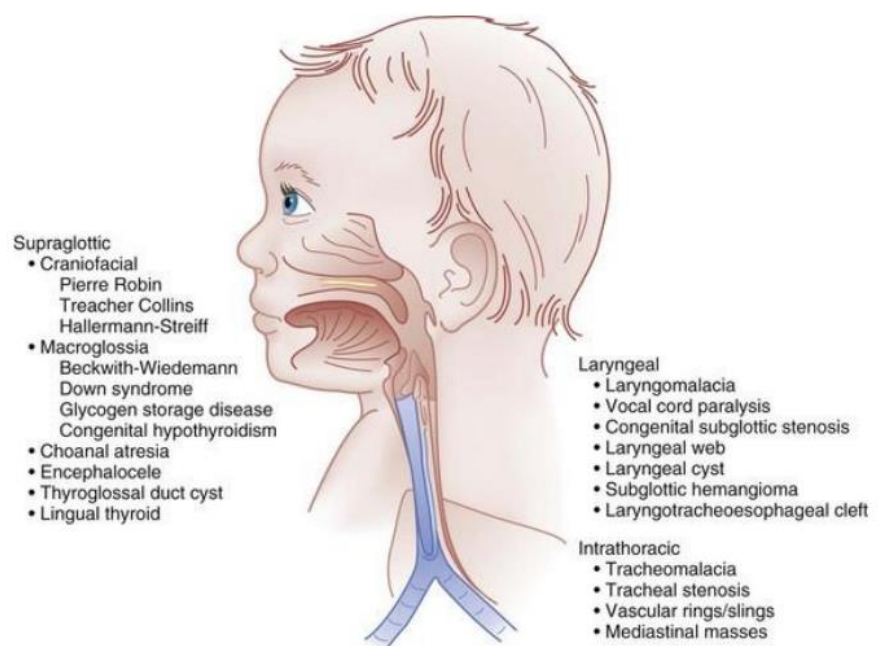
➡ So, stridor is usually biphasic in cases of **FIXED** problems.

➤ **Expiratory:** during expiration. (Lowest points of upper airways are usually affected, like trachea and bronchi).

\note/: usually, bronchial obstruction is manifested as wheezes, but may produce stridor if **severe** obstruction is there. Remember lower airways are wheezers :P

❓ What causes stridor? Anything that causes partial obstruction of the airway!

Upper airway partial obstruction may be caused by a mass, foreign body, **edema** due to infections, compression due to lymph nodes enlargement and others. The image aside shows many causes, all of which may cause obstruction in children and thus stridor. Just read and know them generally.



✓ Some notes added by the doctor if you are interested:

- Macroglossia: a condition in which the patient's **tongue is very big** to the point it can lead to obstruction, especially when the patient lays back.
- Choanal atresia: an obstruction of the nose that may lead to respiratory distress

This table isn't really for memorizing, read it and consider doctor's notes mentioned below:

In pediatrics, we usually consider **age groups** during evaluation of cases (infancy, new born or toddlers); this can direct us to diseases thoroughly in many situations.

New born baby < 28 days. **Infancy** < 1 year. **Toddlers** up to 3 years

- ✓ In new born babies, the most common cause of upper airway obstruction is **vocal cord paralysis** (whether it is iatrogenic or congenital).
- ✓ While the most common one in toddlers is **viral croup**.

❖ **Stridor can be acute or chronic**

Starting with **ACUTE STRIDOR**

Main causes/ diseases of acute stridor are **croup, bacterial tracheitis and epiglottitis**

According to severity: epiglottitis (severest) > bacterial tracheitis > croup

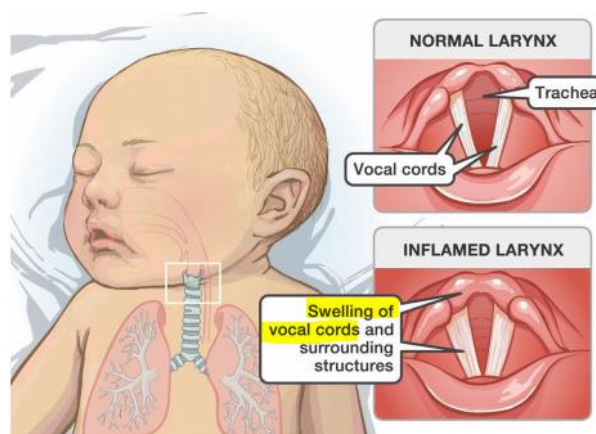
CROUP: < it refers to an infection of the upper airway, which obstructs breathing>

The most common cause of acute stridor in children

So the patient usually had an **infection** (parainfluenza 3 viral infection for example), resulting in **inflamed** upper airways presented mainly at the level of **vocal cords**, so the patient would have **swollen vocal cords** and surrounding structures, this swelling occupies space so it causes **partial obstruction** and finally, stridor!

Compare inflamed larynx with normal larynx. Look at the swollen vocal cords in the picture!

Age Related Differential Diagnosis of Upper Air way obstruction		
Newborn	Infancy	Toddlers
<ul style="list-style-type: none"> • Choanal atresia • DigGeorge syndrome • Laryngeal web , atresia • Vocal cord paralysis • Pharyngeal collapse 	<ul style="list-style-type: none"> • Laryngomalacia • Viral croup • Subglottis stenosis • Laryngeal web • Vascular ring • Rhinitis 	<ul style="list-style-type: none"> • Viral croop • Bacteria tracheitis • Foreign body • Retrolaryngeal abscess • Hypertrophied tonsil • Laryngeal papillomatosis



Clinical manifestations of the disease:

- usually starts with minor upper **respiratory infection coryzal symptoms** with non-specific cough, rhinorrhea and fever.
- **Barking cough**, and respiratory distress (mild to moderate distress but not severe) that develops **suddenly** during the evening or at **night**
- **Stridor** typically occurs during **inspiration** (listen to inspiratory stridor from the lecture 16:33). With more severe cases, it can be biphasic.
- **Hoarseness of voice**

*Why do you think symptoms worsen at night? Levels of endogenous steroids (i.e. anti-inflammatory) approach zero at midnight, so manifestations of inflammation will be clearer.

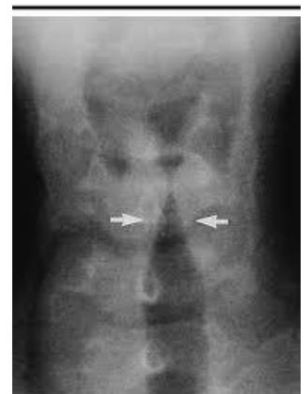Management: upper airway obstruction is considered a top emergency, as you don't know when will the patient deteriorate, steroids are given to limit inflammation and thus **edema**, oxygen therapy if patient is hypoxic, and the patient may be hospitalized if needed to keep him under observation.

Chest x-ray

Remember, in radiology air is radiolucent/ appears black (notice the trachea filled with air), soft tissues are grey, bones and fluids are white.

Steeple sign: it is a characteristic of croup; it is a narrowing near the larynx <where white arrows are pointing> that advances to partial obstruction above.

Steeple sign on CXR

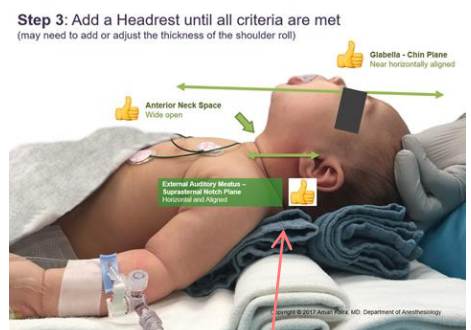


BACTERIAL TRACHEITIS:

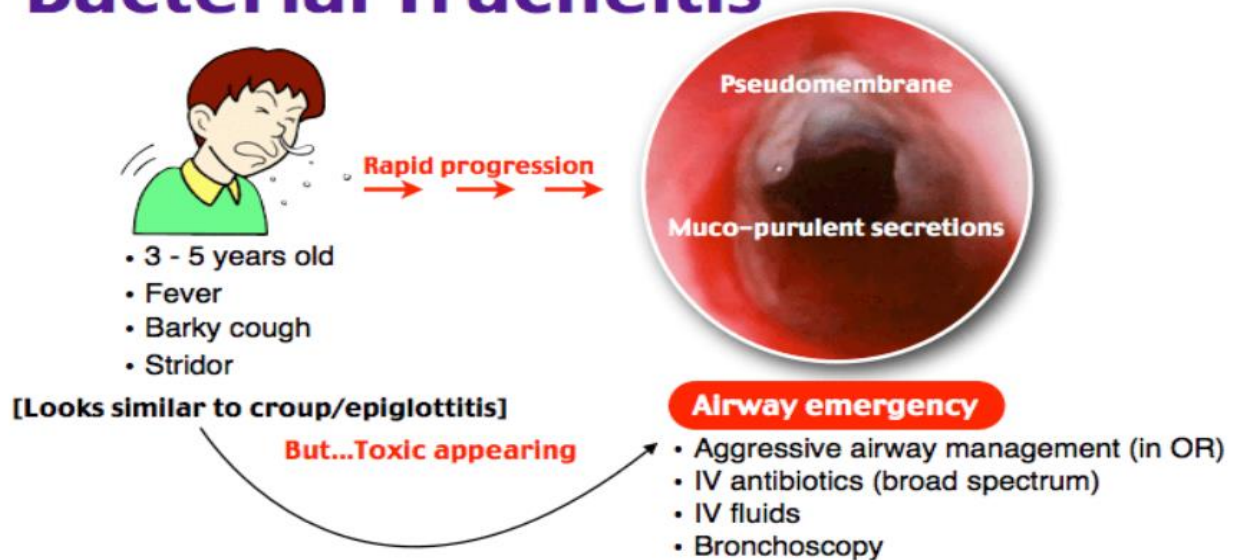
As the name indicates; it is an infection of trachea caused by bacteria, notice the white mucopurulent secretions caused by the infection in the photo **below**.

Study the image in the next page which includes all that you need to know about this disease! Here are some points illustrated:

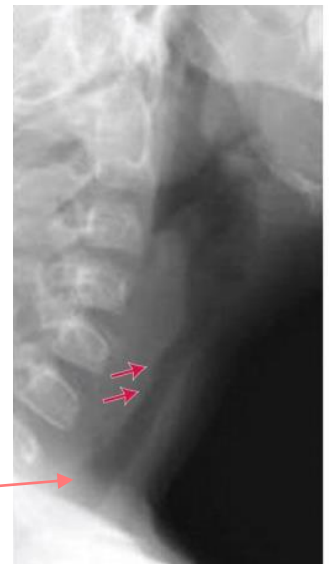- **Clinically, Bacterial trachietis** resembles croup with fever, barky cough and stridor
- Patients have a more toxic appearance than croup, as more upper airway obstruction exists, patient presents with hypoxia and cyanosis with **sniffing position** (extended neck in order to keep upper airway open to facilitate breathing).



Bacterial Tracheitis



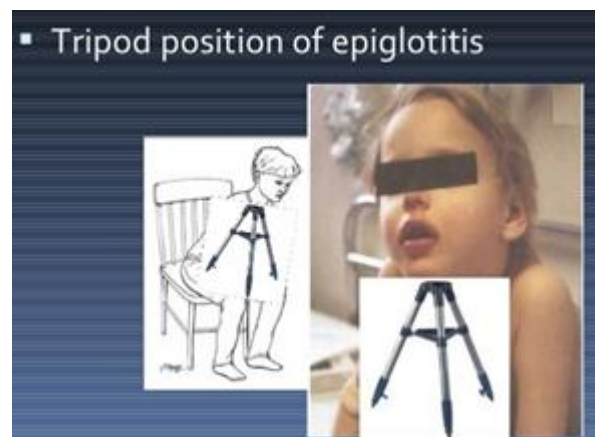
- Usual **Age Involved**: bacterial tracheitis are associated with a bit older children (3-5 years) while croup patients are usually younger (1-3 yrs)
- **Management**: Prognosis of the disease is good. **Broad spectrum antibiotics (e.g. Rocephin)** is needed (**most common cause of bacterial tracheitis is Staph aureus**). Also, if the patient is hypoxic, oxygen therapy is needed.
- IV hydration may be needed too, so supportive therapy is applied until the patient resolves.
- **Radiograph**: the arrows point at tracheal 'bulbs' where the mucosa is swollen due to tracheitis and pushing towards the airway thus narrowing it (notice how it is more patent below)



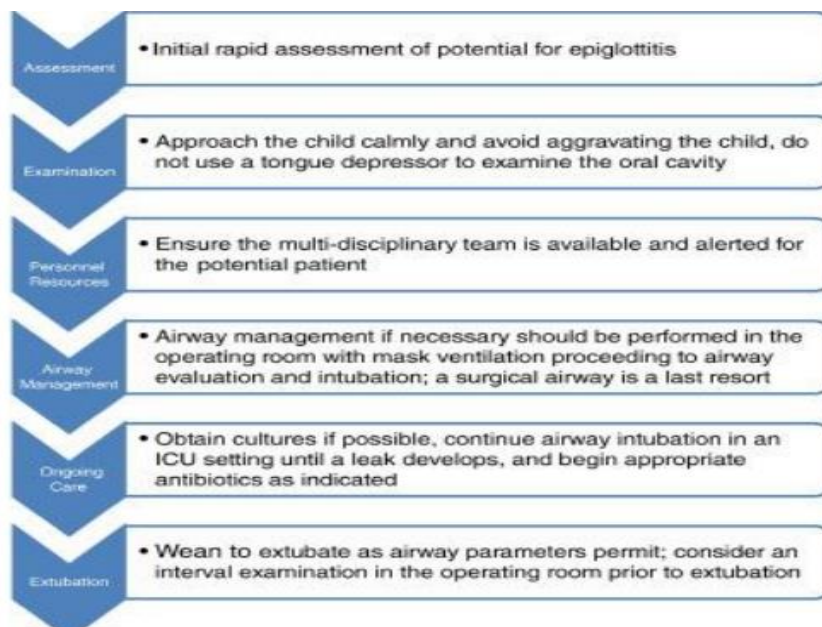
EPIGLOTTITIS: it is an infection of the epiglottis.

Inflamed and swollen epiglottis causes significant obstruction of upper airways.

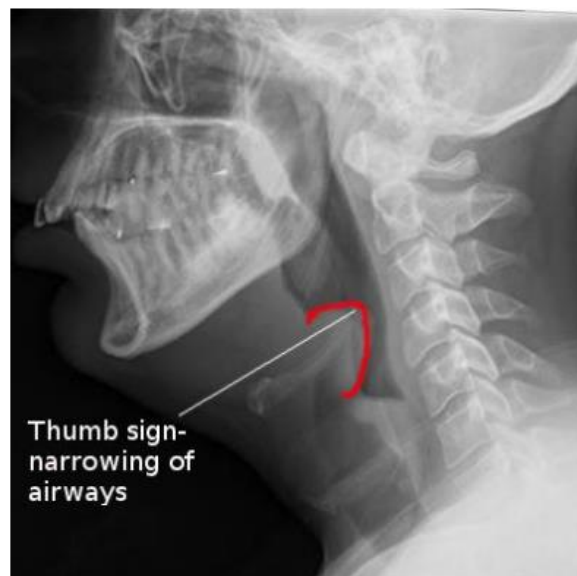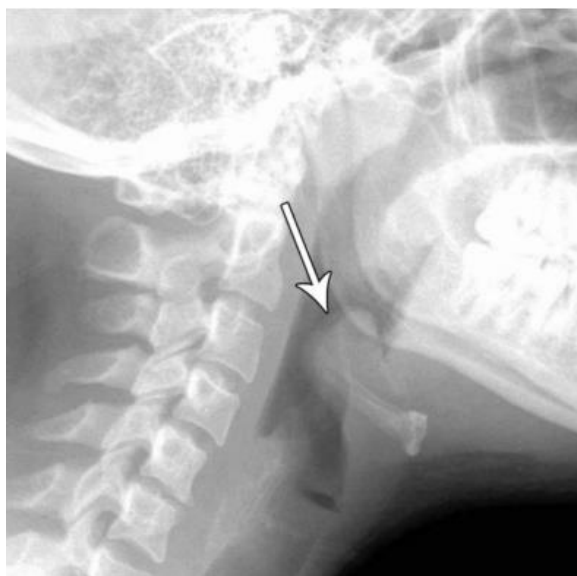- The most common organism to cause this infection is *Haemophilus influenzae*, specifically type B AKA HIB bacterium. Fortunately, cases of epiglottitis have dropped significantly due to vaccination against these bacteria (HIB vaccine)!
- **Clinically**, patient is in **Tripod position** with his trunk leaning forward to decrease work of breathing, also with extended neck, opened mouth and **drooling of saliva (no swallowing)**. Cough is unusual.



- **Management:** if you see these clear clinical signs of epiglottitis, don't touch the patient, don't examine him! As if you touched him and he got irritated and start crying, this may lead to closure of ***inflamed*** epiglottis which is VERY HARD to reopen, so the patient may suffocate and die unless you emergently make a tracheostomy! This patient is usually admitted to the ICU and put on IV Rocephin antibiotic (enough without other ABx) along with supportive therapy for a few days. Read the figure below to have an idea how doctors deal with these patients.



- **Radiology:** Lateral neck x-ray, ***Thumb sign*** is characteristic in epiglottitis (a clearly swollen epiglottis)



💡 Quick recap break: Causes of acute stridor in children:
Croup (most common), **Bacterial Tracheitis** caused by *Staphylococcus aureus*,
Epiglottitis caused by *Haemophilus influenza*

Chronic stridor: stridor that may start at 6 weeks of age and continue to 3 years of age.

LARYNGOMALACIA رخاوة الحنجرة :

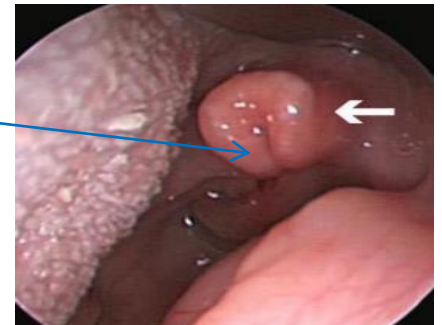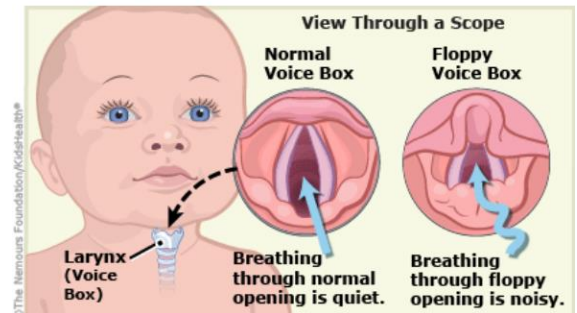
The most common cause of chronic stridor in children.

In this disease, all muscles of the larynx are floppy and redundant, so we will have **omega shaped epiglottis** which may cause obstruction of the airways.

Clinically: Low pitched inspiratory stridor

- Peaks at 6-9 months
- Positional variation
- Stridor does not appear in normal calm situations like when the baby is sleeping, but when the patient is irritated by crying, infection or any other, stridor becomes apparent. It is exacerbated by activity (feeding, exertion), supine position and during viral illnesses, and diminished by rest, prone position and sleeping.
- Rarely produces cyanosis.
- Appears within first 2 weeks of life. But should recover on its own (6 months-2/3 years of age).
- Usually it's benign. However, if the patient is not feeding well and not gaining weight, also if associated with respiratory distress, here we need to interfere, and supraglottoplasty surgery may be needed.

✓ Omega shaped epiglottis



Sooo,

Child presented with stridor, assessment:

- Is it inspiratory, biphasic or expiratory?
- Is it associated with **FEVER** or not? If yes, so most likely it is an acute state with an **infectious process (croup- viral, bacterial tracheitis- S.aureus, epiglottitis- H.influenza)**
- Evaluate the severity of the obstruction by noticing the position the patient presented with and the presence of cyanosis
- If the child is a toddler or a little older and he presents with sudden upper airway obstruction, think of foreign body obstruction too.

Most important information you need to know from this lecture:

1. **Upper airway obstruction** is associated mainly with → **stridor**
While **lower airway obstruction** is mainly associated with → **wheezing**
2. Types of stridor: inspiratory, biphasic and expiratory
3. **Causes of ACUTE and CHRONIC stridor**
4. **Have a look at these clinical cases:**

Case 1: child presented to the ER with **inspiratory stridor**, **barking cough** and respiratory symptoms and CXR shows **steeple sign**, what is your diagnosis?

Case 1: Croup

Case 2: Epiglottitis

Case 3: laryngomalacia'

Case 2: Patient presented to the ER with his mother, he looks very sick and toxic, his fever is spiking up to 40 degrees, with **drooping saliva**, **tripod position** and his CXR shows **thumb sign** image, what is your diagnosis?

Case 3: Child presented to you with his mom complaining of a continuous noisy sound (**chronic stridor**) that appeared early in his life, the sound isn't there while the baby is sleeping, but it is apparent when he is crying. What is it likely to be based on information mentioned in this lecture?

سُنْرِيهِمْ آيَاتِنَا فِي الْأَفَاقِ وَفِي أَنْفُسِهِمْ حَتَّىٰ يَتَبَيَّنَ لَهُمْ أَنَّهُ الْحَقُّ ۗ أَوَلَمْ يَكْفِ بِرَبِّكَ أَنَّهُ عَلَىٰ كُلِّ شَيْءٍ

شَهِيدٌ؟

- سورة فصلت

2021, ولا زالت سنريهم تراقنا كل يوم..