

CNS

ANATOMY

3

Writer: Batool Albdour

Science: Mahmoud Odeh

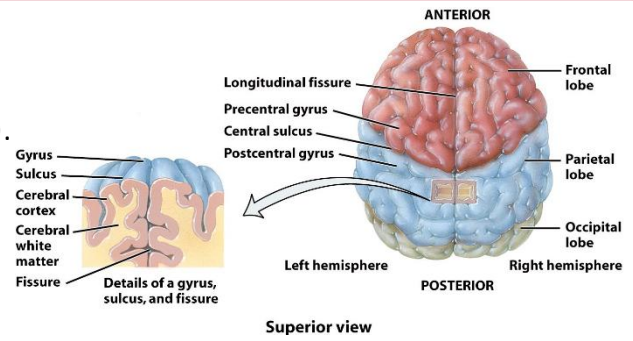
Final: Nour Awamleh

Doctor: Mohammad Alsalem



Information to keep in mind:

- White matter is a collection of axons (tracts). It can be divided into columns (posterior, lateral and anterior).
- Tracts can be ascending or descending.
- Dorsal — always associated with sensory.
- The cortex is anatomically divided into Sulci and gyri - notice fissures, gyrus, sulcus.




We'll start with **Ascending sensory tracts**:

1. The **Posterior Column – Medial Lemniscal** Pathway

- › Located in the posterior white column of the spinal cord (hence the name!).
- › The posterior white column is divided into two fasciculi on each side, fasciculus gracilis (medially) and fasciculus cuneatus (laterally).

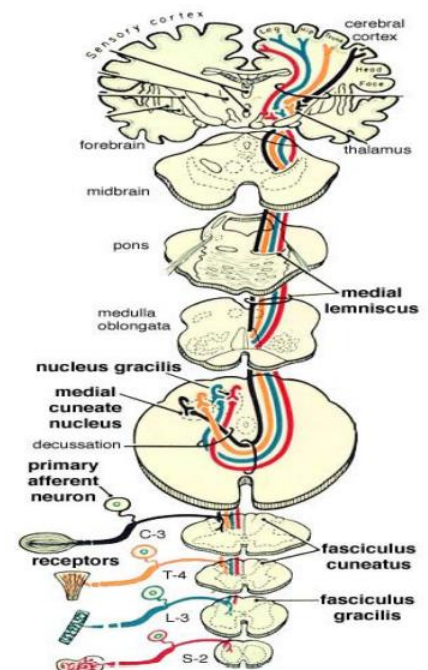
ID profile of the pathway:

- **Modality: Discriminative Touch Sensation** *the ability to discriminate when touched in two different points (including Vibration) and **Conscious Proprioception**
 - ➔ Proprioception is a **muscle joint sense**, by which the CNS knows how every muscle and joint of the body is positioned in space. It is very important for motor coordination, in order for me to make a move I need to know my initial position, the position I want to achieve with the move, and how each muscle should change to achieve it.
 - ➔ **Conscious proprioception**: the proprioception that reaches the cortex (unconscious only reaches cerebellum).
- **Receptor: Most types of receptors** (like spindles and GTO) except free nerve endings.
- **1st order Neuron**: cell bodies lie in the **Dorsal Root Ganglion**.

 **A note to keep in mind:** The posterior column is a sensation pro. It specializes in high velocity and precise signals.

Cell bodies of the 1st neurons are pseudo-unipolar. They have a single stalk that divides into two processes: one that goes peripherally and one that ascends centrally.

Journey: Mechanoreceptors enter the posterior white column, their fibers ascend upwards **ipsilaterally** (on the same side they came from), they go up till they reach the lower part of **medulla oblongata**, and there they **synapse with the bodies of second order neurons**.



→ 2nd neurons' bodies collect in **two nuclei**; one that is more medial called **nucleus gracilis** (fasciculus gracilis fibers synapse in it) and one that is more lateral called **nucleus cuneatus** (fasciculus cuneatus fibers).

- **2nd Neuron:**

Journey summary: Dorsal Column Nuclei (Nucleus Gracilis and Cuneatus) ---Internal Arcuate Fiber - Lemniscal Decussation ---Medial Lemniscus

Details:

The processes of the second order neurons in the lower part of medulla oblongata cross over to the other side (performing **primary sensory decussation**) creating an arch, which is why we call them **'internal arcuate fibers'**, then ascend **contralaterally**.

→ As they go up, these fibers gather and lie close to the midline, forming a lemniscus (an **elongated shape**) called **medial lemniscus**. They keep ascending through the medulla, pons, and midbrain until they reach the thalamus where they **synapse with the third order neurons**.

💡 **A note to keep in mind:** At this level, the sensation is carried **CONTRALATERALLY**.

The thalamus is the secretary of the cortex. It's made of two egg-shaped collections of gray matter, and it consists of multiple nuclei (VPL, VPM, etc).

- **3rd Neuron:**

Journey summary: Thalamus (VPL) (Internal Capsule ----- Corona Radiata)

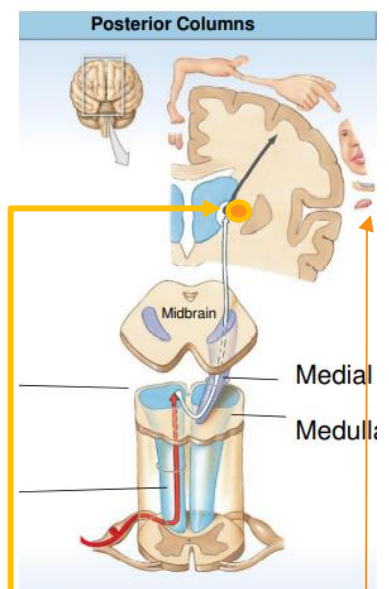
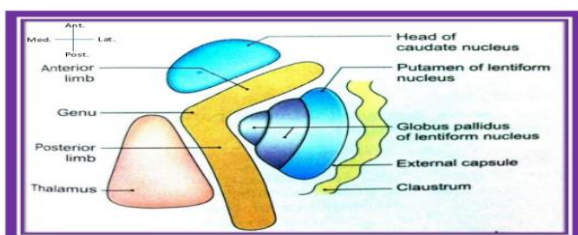
Details:

Ventral posterolateral nucleus (VPL) is the thalamic nucleus related to the posterior white column. It receives the medial lemniscus where the synapse between the second and third order neurons takes place.

3rd neurons project from the thalamus towards the cortex (the **outer aspect of the cerebrum (telencephalon)**).

→ As the fibers head towards the cortex, they pass through a **critical narrow area between multiple nuclei** (caudate nucleus, the thalamus, and the lentiform nucleus) and this area is called **internal capsule**.

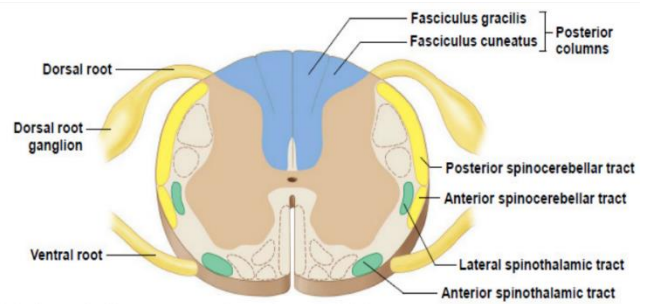
→ Additional image to illustrate **internal capsule**:



The body is represented as a map/ homunculus (a tiny human representation) on the cortex which helps our CNS localize the body parts.

➔ As they approach the cortex, the fibers spread out forming **corona radiata**, here they show localization as each body part is represented by these fibers on a specific area.

- **Termination:** the part of the cortex they terminate into is known as **primary somatosensory (Somesthetic) Area (SI)**, a part of the parietal lobe.



Discriminative touch, vibratory sense, and conscious muscle-joint sense

•Posterior Column tract consists of:

- Fasciculus gracilis
- Transmits information coming from areas inferior to T6
- Fasciculus cuneatus
- Transmits information coming from areas superior to T6

What is the difference between fasciculus gracilis and cuneatus?

They hold the same function, but **fasciculus gracilis** transmits information coming from areas **inferior to T6** (lower parts of the body) while **Cuneatus** transmits **above** it (upper part of the body).

Why is that?

In the posterior WC-ML pathway, the fibers come ipsilaterally. Now, let's take a look at the lowest part of the body 'THE FOOT'. A fiber coming from the foot would be the first to enter, taking place in the first-row seats which happen to be the **most medial part of the column**. The fibers that come afterwards would then sit next to them and more laterally. Thus, the lower part is most medial, and the upper part is most lateral.

Somatotopic principle exists here too. Just like the representational order on the cortex, there is also order in the spinal cord.

Here's an example:

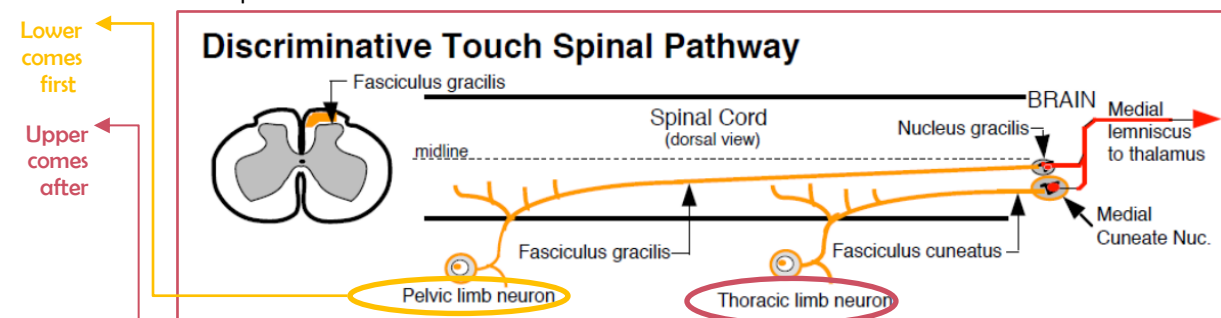
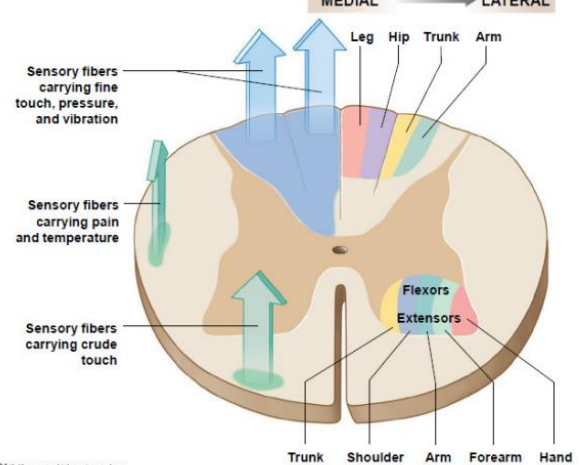


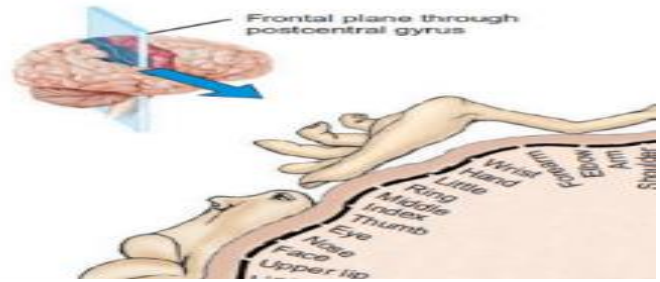
Figure 15.1 Anatomical Principles for the Organization of the Sensory Tracts and Lower-Motor Neurons in the Spinal Cord



© 2012 Pearson Education, Inc.

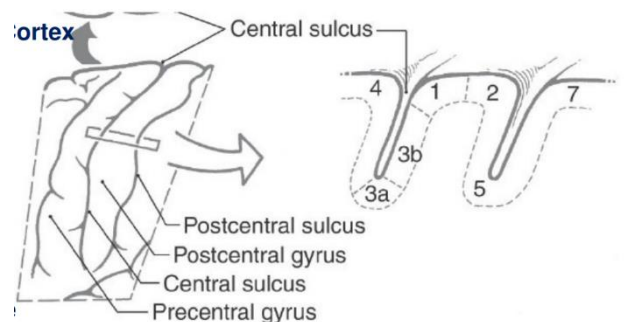
Notice: This system is an advanced and fast system due to the velocity of the fibers that supply its receptors (A α and A β).

- ➔ Just like the skull, the cortex is divided into a frontal, parietal, temporal, and occipital lobes
- ➔ The sensory system goes to the **post-central gyrus** of the parietal lobe and gets represented as a homunculus.



A scientist named Brodmann divided the cortex into functional areas by numbers:

- ➔ This region (postcentral gyrus) is subdivided by types of receptors into four distinct areas: from anterior to posterior, Brodmann areas 3a, 3b, 1, and 2.
- **Area 3a:** Muscle spindle afferents (mainly).
- **Area 2:** Golgi tendon organs and joint afferents (mainly).
- **Areas 3b and 1:** They receive cutaneous afferents from receptors such as Meissner corpuscles and Merkel cells. Also, they receive input from cutaneous receptors that **transmit pain and temperature**.

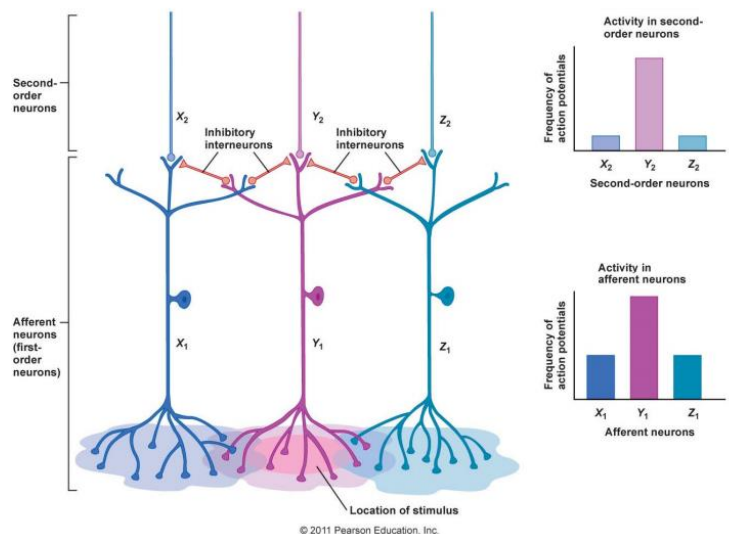


Lateral Inhibition:

This process **facilitates the localization of the site of stimulation**.

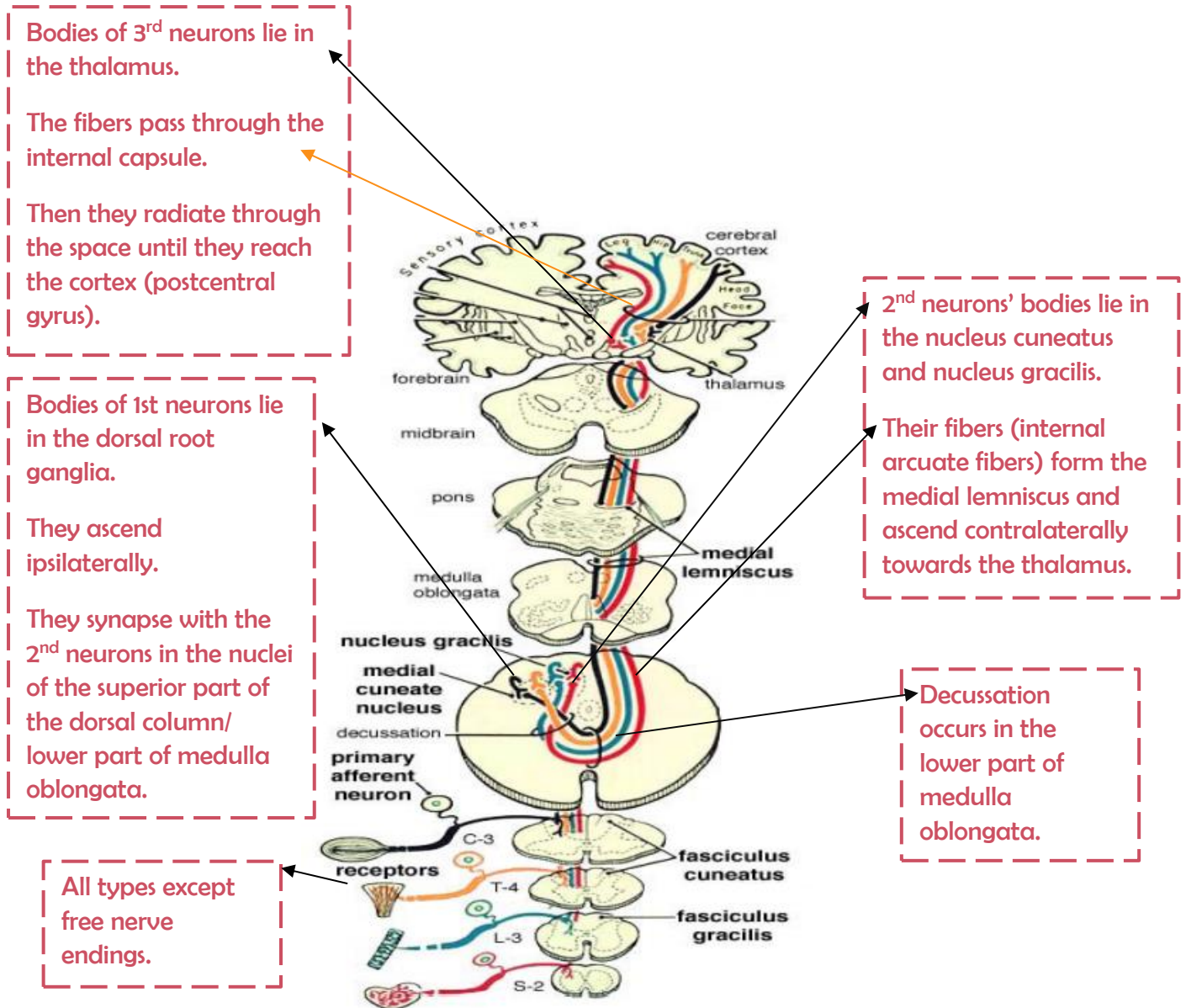
Explanation:

- The receptor at the site of most intense stimulation is activated to the greatest extent. Surrounding receptors are also stimulated but to a lesser degree
- The most intensely activated receptor pathway **halts transmission of impulses** in the less intensely stimulated pathways through lateral inhibition by inhibitory interneurons which are activated by collateral processes of the neuron, thus the **localization of the stimulus becomes more precise**.



Posterior column-medial lemniscal pathway revision: (start at the bottom)

Modality: discriminative touch and conscious proprioception.



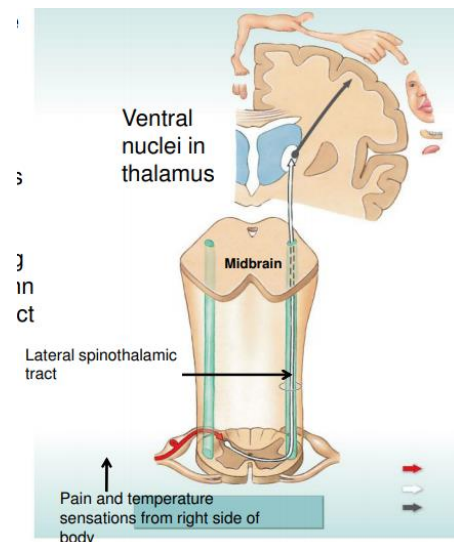
2. Spinothalamic Tract:

↳ it can be divided into anterior and lateral.

Lateral Spinothalamic Tract:

ID profile of the pathway:

- **Modality:** transmits pain and temperature.
- **Receptors:** Free nerve endings (the opposite of the posterior column).
- **1st Neuron:** The cell bodies lie in the Dorsal root ganglia, just like the previous pathway. However, the central process of the 1st neuron doesn't go to the posterior white column, rather it synapses with the 2nd neurons' cell bodies directly in the dorsal horn (gray matter).
- **2nd Neuron:** Their cell bodies lie in the dorsal horn of the posterior gray column called '**substantia gelatinosa**'. *



➔ The axons of 2nd order neurons cross obliquely to the opposite side passing through the anterior gray and white commissures *'axons that connect the right and left parts of the cord', ascending in the contralateral white column as the **lateral spinothalamic tract**, (the crossing here is early in the spinal cord).

↳ **3rd neuron pathway:** Thalamus (VPL)-- Internal Capsule ----- Corona Radiata

Details: The fibers of the 2nd neurons reach the thalamus, and they synapse with 3rd order cell bodies in the Ventral Posterolateral nucleus. Then, the fibers of the 3rd order go to the cortex in the same fashion as the PC-MLp.

↳ **Termination:**

They terminate in the Primary Somesthetic cortex (SI), specifically in area number 3b, and in **Widespread Cortical Region (more on this soon)**.

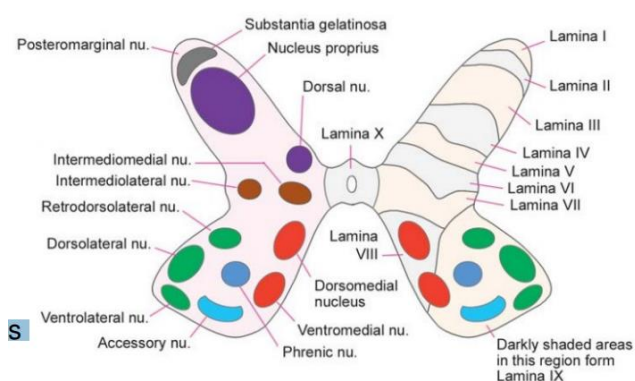
➔ First, let's understand Substantia gelatinosa:

Rexed laminae

↳ This is the gray matter of the spinal cord.

↳ It has dorsal, lateral, and ventral horns.

In general, we divide the gray matter into laminae numbered (I - X), forming the dorsal horn are the laminae (I-VII).



focus on 1,2 and 5 for now:

- **Lamina 1** relay information related to **pain and temperature.**
- **Lamina 2:** relay information related to **pain and temperature.**
- **Lamina 3 and 4:** nucleus proprius, modulation and touch. **These laminae have many interneurons.**
- **Lamina 5:** relay information related to **pain and temperature.**
- **Lamina 6:** presents only at the cervical and lumbar enlargements and receives **proprioception.**
- **Lamina 7:** Intermedio-lateral nucleus, contains preganglionic fibers of sympathetic (T1 - L2). Intermedio-medial nucleus, all over the spinal cord, receive visceral pain. Dorsal nucleus of Clark's presents at (C8 – L2 or T1- L4), relay center for unconscious proprioception ***will be discussed later.**

These two are what form substantia gelatinosa

'Substantia gelatinosa is formed by laminae 1 and 2. It's the place of synapse of the first order neurons with the cell bodies of the second order neurons.'

Now about the **'Widespread Cortical Region'**, we first need to have a little introduction:

There are two types of pain, **fast and slow**:

- Slow pain has multiple components and is considered **complicated** (autonomic and emotional components).

What's the difference?

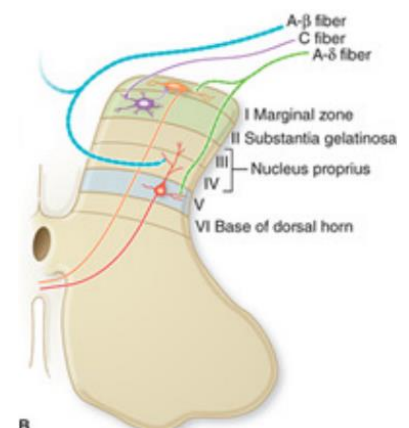
- The first sharp pain caused by an instant tissue injury, like a cut, is **fast**.
- After inflammation and edema, tenderness in the area is **slow** pain which is diffused and long.

Aδ	III	1-5	5-30	Skin mechanoreceptors, thermal receptors, and nociceptors
C	IV	0.2-1.5	0.5-2	Skin mechanoreceptors, thermal receptors, and nociceptors

Why is there a difference?

- It's due to the type of fibers that transmits each type. Fast pain uses A delta fibers, which are wider in diameter and faster than C fibers which are used for slow pain.

- Notice that laminae 1,2 and 5 of the gray matter all transmit the same type of information. However, the difference in the fibers that relay information to these lamina creates subspecialities of pain transmission for them.



↪ Laminae 1&2 → receive C fibers → unmyelinated and smaller → **SLOW PAIN**

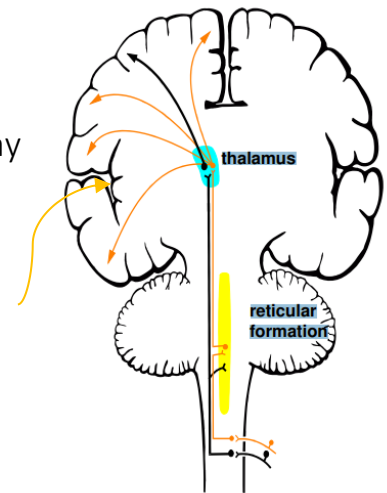
↪ Laminae 1&5 → receive A delta → wide diameter and myelinated → **FAST PAIN**

Widespread cortical region termination exists because there are **other terminations (destinations) of the lateral spinothalamic tract** that are related to the fact that we have 2 types of pain. Let's see how:

As we said, pain is complex. This complexity is wired in the CNS itself. The termination of these signals doesn't stop at the level of the cortex, they rather stimulate different areas too, for instance:

- **The Reticular formation:** The majority of **slow pain fibers** stimulate the **reticular formation**, which is a network of fibers present in the core of the brain stem. Many would say that this formation is the door to the conscious mind through which the individual becomes **aware of the pain**.

An example: When you are asleep, mild sounds don't usually wake you up. However, when there is a massive sensory input (loud sudden sounds), it stimulates the reticular formation which in turn **switches on the cortex and brings you to awareness**.

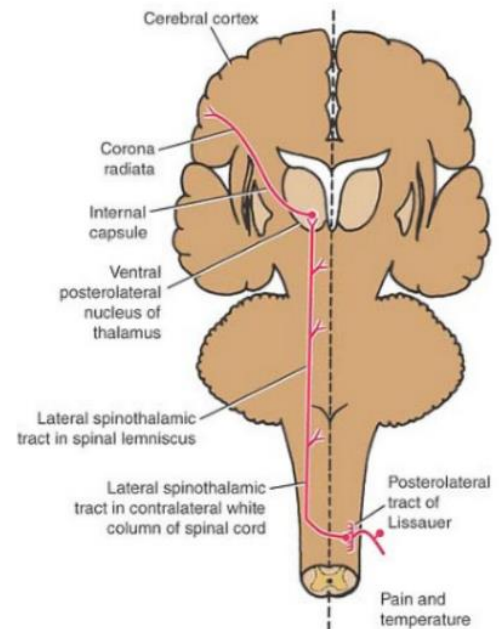


- **Cingulate gyrus:** It is a very important part of the limbic system which acts in the interpretation of the **emotional aspect of pain**. (Limbic means borderline- it's between the outside and the inside of the cortex).
- **We normally relate pain to feelings and perceptions. This association and the existence of this system helps us avoid pain.**
 - ↳ There is an experiment called **conditioned place preference** in which rats were put into two distinct rooms; one that induces pain and one that offers safety. The rat would learn to conditionally associate the pain with one room and the safety with the other, so that when the choice is the rat's, it would choose the safe room due to the existence of the cingulate gyrus.
- **Insular gyrus AKA insula:** is a hidden part of the cortex inside the lateral fissure (**yellow arrow in the picture above**). It is concerned with the interpretation of pain stimuli from the internal organs of the body and bringing about an **autonomic response** to the pain, like increasing the heart rate or causing sweating.

Posterolateral tract of Lissauer

It is located between the posterior white column and the lateral white column.

Details: Some fibers like to differ from the crowd. Instead of synapsing and crossing over in the segment they entered, they ascend upwards or go downwards and do just that but in the segment above or below the segment they entered. This creates a local tract called the posterolateral tract of Lissauer.



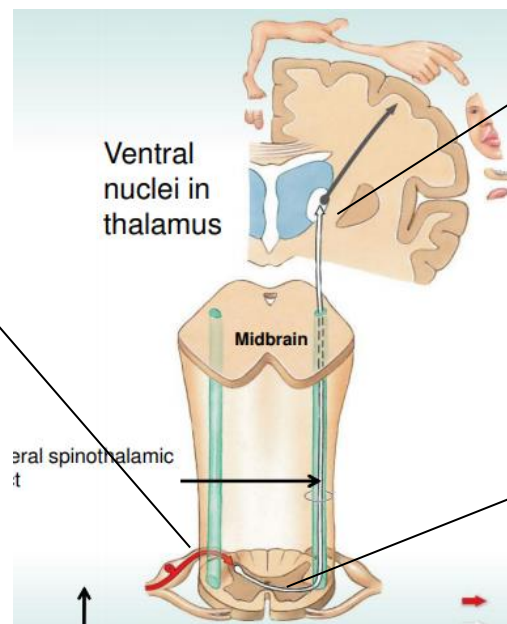
Revision:

Lateral spinothalamic tract

1st neuron cell bodies are in the dorsal root ganglia.

They synapse with the second order neuron in the SPINAL CORD (substantia gelatinosa) without ascending ipsilaterally.

Free nerve ending receptors.



3rd neurons start in the thalamus and ascend towards the cortex through the internal capsule.

2nd neuron cell bodies are located in the substantia gelatinosa.

They cross to the other side early in the spinal cord.

They carry sensation contralaterally and ascend forming the lateral spinothalamic tracts until they reach the VPL of the thalamus.

Some fibers don't synapse at the level of the segment they entered. They rather synapse 1-2 segments above or below creating the Posterolateral tract of Lissauer.

Other terminations (destinations) of the lateral spinothalamic tract:

- Reticular formation → awareness of pain.
- Cingulate gyrus → emotional aspect of pain.
- Insular gyrus → autonomic responses to pain.