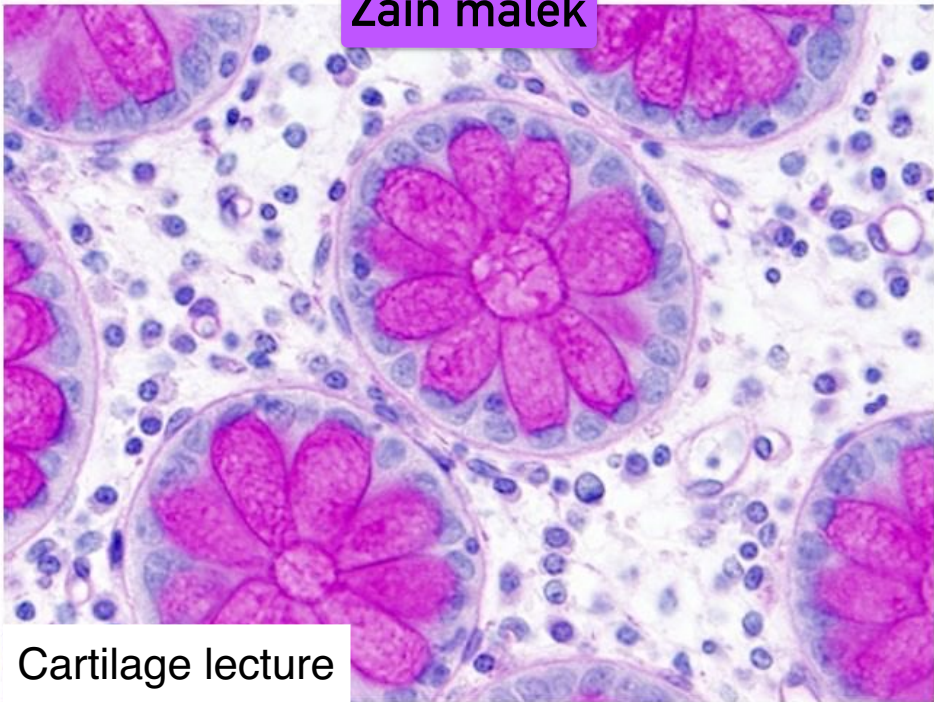



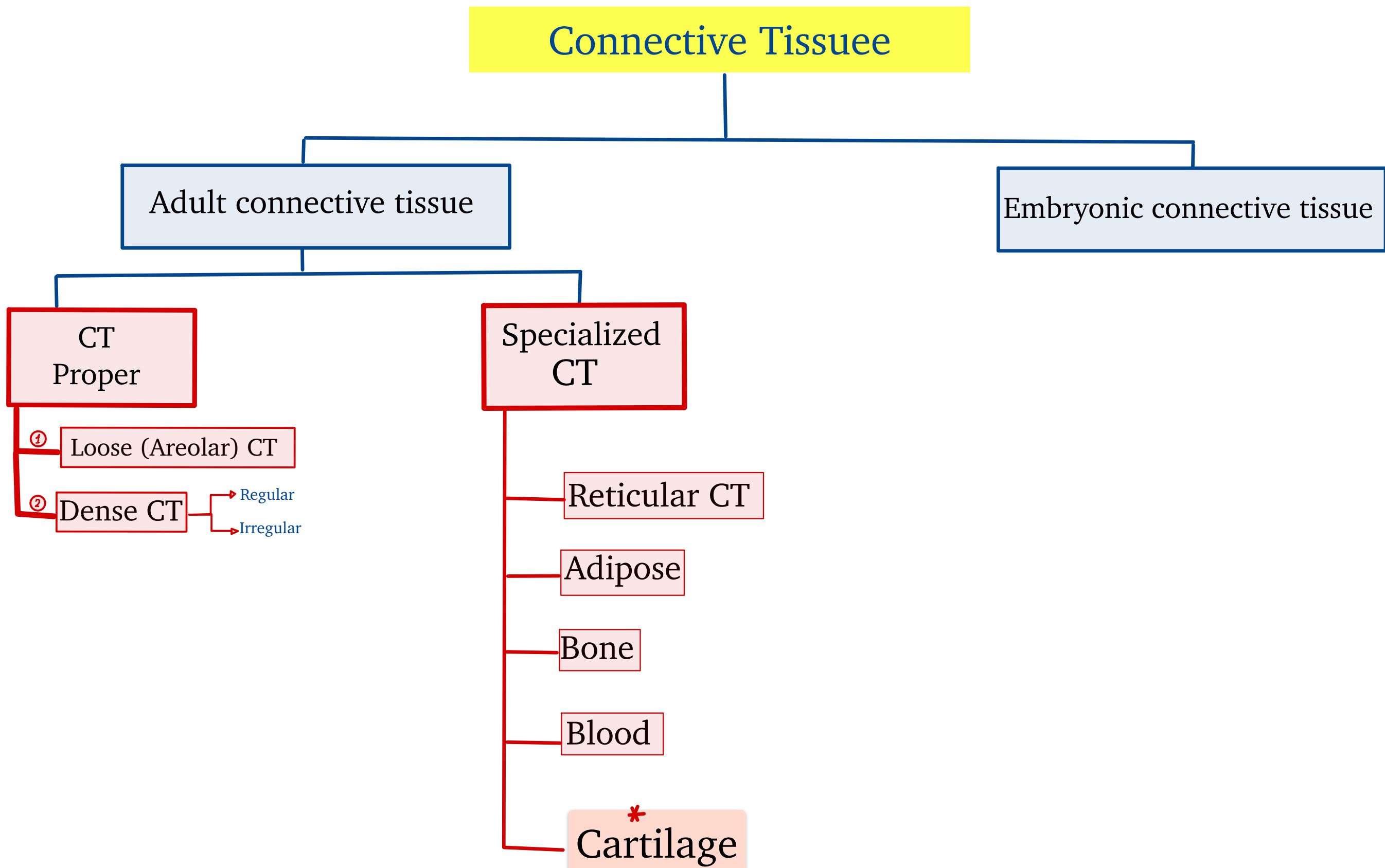
Zain malek



Cartilage lecture

# Chapter 7: cartilage

L ◆ Recover that:



S ◆ What is cartilage?

- ◆ It is tough and durable connective tissue.
- ◆ It is Rich in extracellular matrix (ECM) and Proteoglycans.
- ◆ It contains collagen and elastic fibers.
- It is avascular (low metabolic activity). → No vessels
- It lacks nerves. → No nerves

No blood vessels that actually can be seen within the structure of cartilage. The blood vessels just stop right outside of cartilage and the nutrients will reach the cartilage's cells by diffusion.

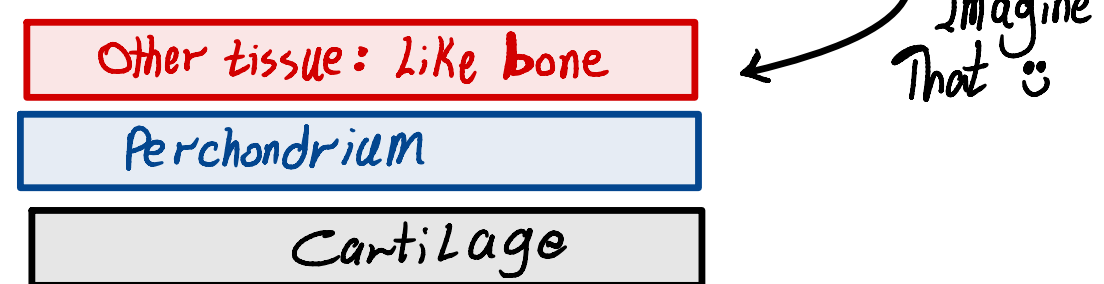
Also this means that cartilage's cells have low metabolic productivity (or activity) not like bone cells or liver cells (have a high metabolic activity).

◆ when we talk about cartilage, we talk about cells, fibers and ground substances.

◆ Difference between cartilage and bone: Cartilage is tough and compressible. Bone is incompressible (can not compress).

## S + L ♦ The perichordium:

- ♦ It is a sheath of dense connective tissue that surrounds cartilage.
- ♦ It forms an interface (like isolated barrier: حاجز عازل) between the cartilage and the tissue supported by the cartilage (the other structures of any other tissues).



- ♦ It contains blood supply that does not reach the cartilage and neural components.

○ There are three types of cartilage:

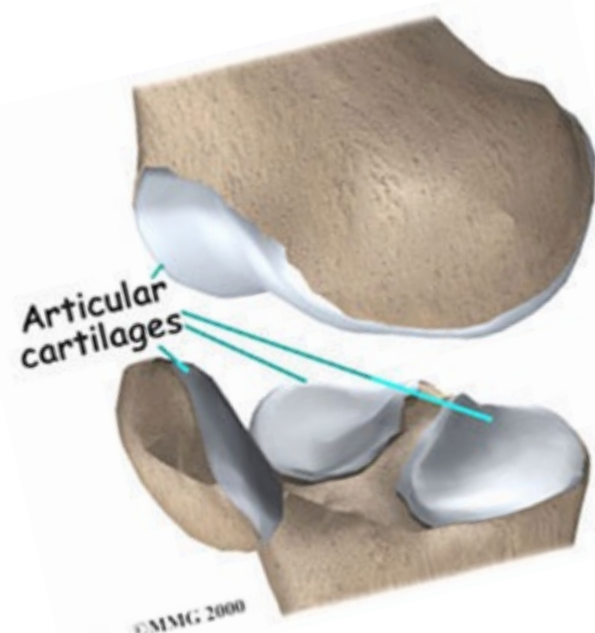
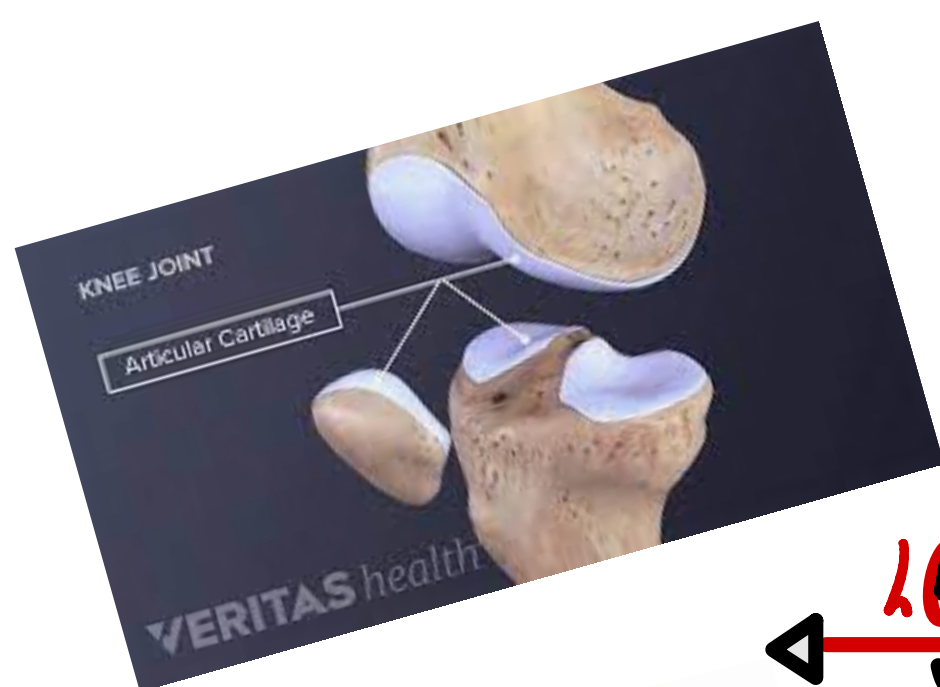
- 1) Hyaline cartilage. [The most common of three types.]
- 2) Elastic cartilage.
- 3) Fibrocartilage.

○ Two of them have a perichondrium and the last type does not have perichondrium.

○ But, there is one type of hyaline cartilage does not have perichondrium, this type is (Articular cartilage). <sup>result</sup> → Diffusion of oxygen and nutrients from synovial fluid.

○ So, Two locations do not have perichondrium:

- 1) Just one type of hyaline cartilage is (Articular cartilage).
- 2) The fibrocartilage.



LOOK

When the hyaline cartilage covers the ends of bones when they participate in the formation of joints, we call it (articular cartilage)

When the bones reach their articulation with the other one, they are all covered by hyaline cartilage specifically articular cartilage.

## L 1) Hyaline cartilage

How various elements bind to Each other in hyaline cartilage?

The reason of considering the hyaline cartilage as shock absorber.

The reason particularly hyaline cartilage covers the particular surfaces.

Answer: ① we usual consider the hyaline cartilage - or particular cartilage in General - as semi rigind because it still have same some sort of compressibility [not elasticity, we cannot stretch it].

② the hyaline cartilages have lots of gags chain Extending from proteoglycans and usually these are negatively charged so, they are gonna apply to so many water molecules.

③ because of the physical properties of cartilage that depend on electrostatic bonds between **type2 collagen fibrils**, **hydoronan**, and **the sulfated GaGs** on densely packed **proteoglycans**.

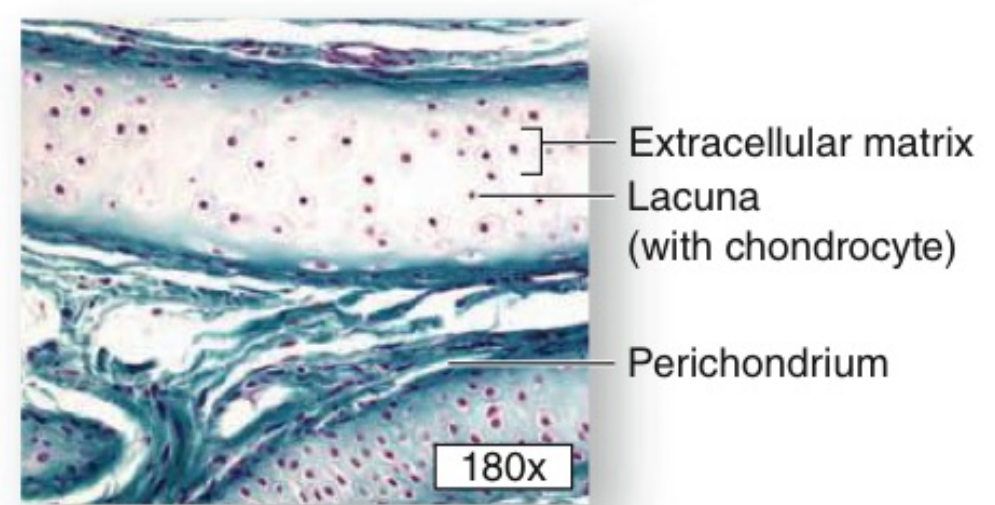
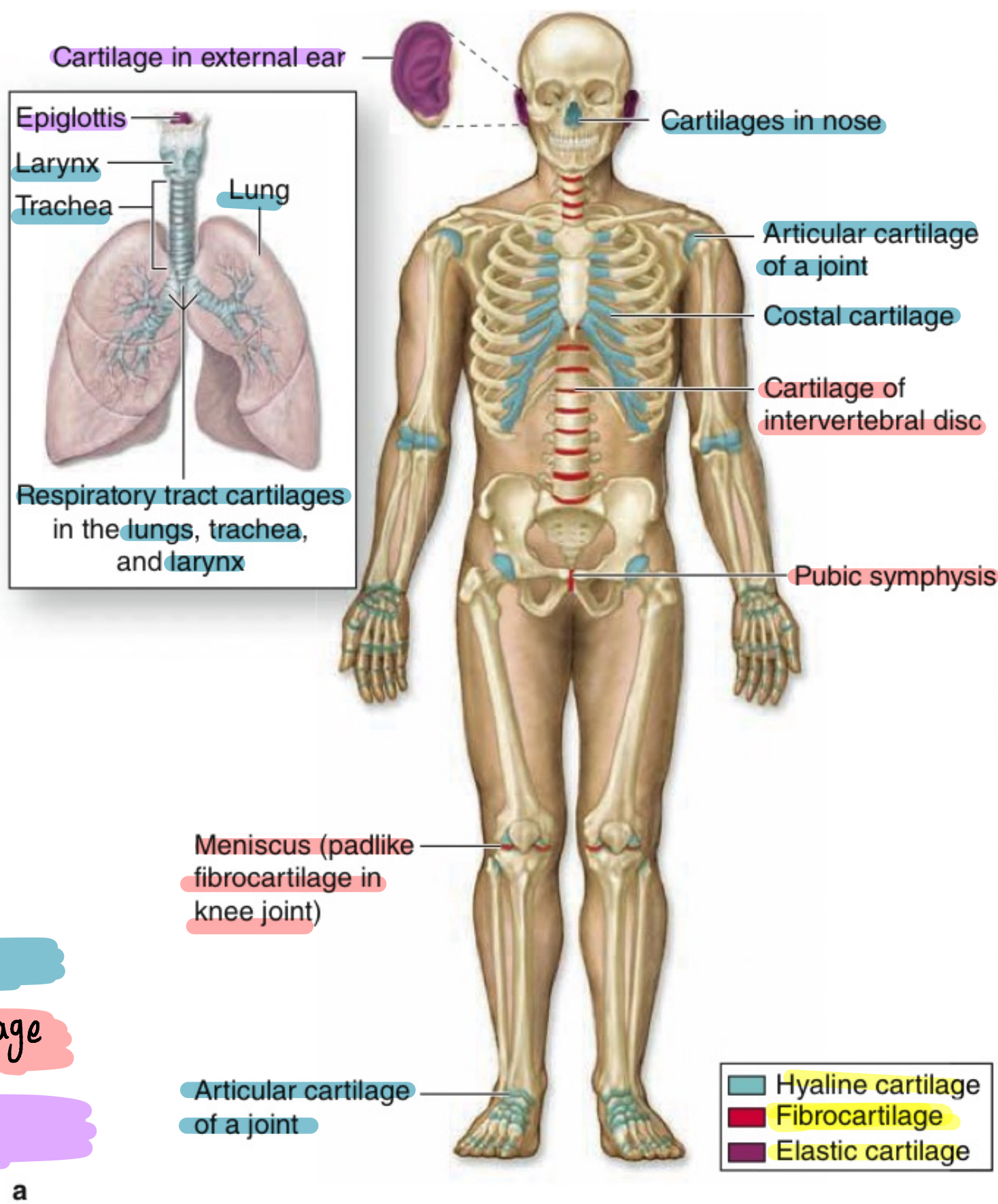
◆ I don't need something **as hard as** bone to cover the articulations and something **that's more compressible**, that kind of structure allows bit of movement within itself so, can protect the inner structures which cover it like bones 🦴.

I need semi-rigind and comprisable structure like cartilage ✓

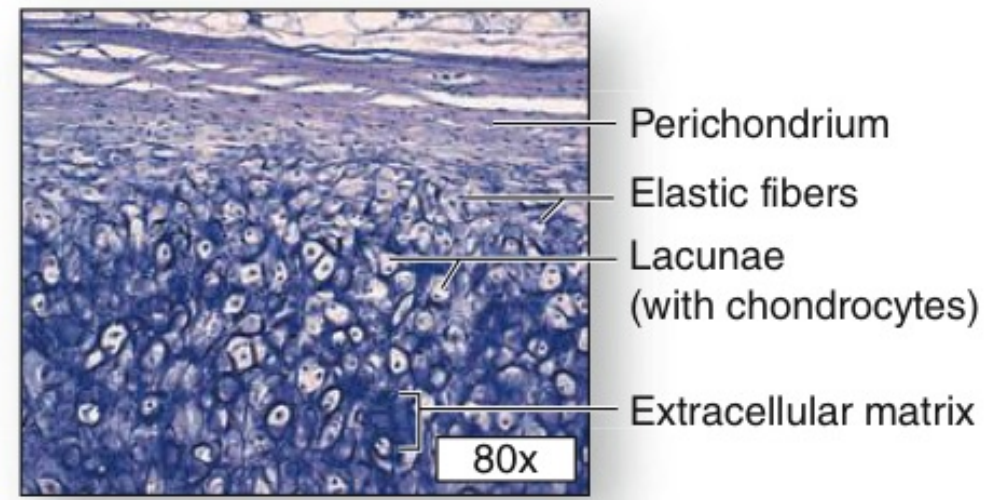
## S ◆ Features of hyaline cartilage:

- ① The physical properties of cartilage depend on **electrostatic bonds** between type II collagen fibrils, hyaluronan, and the sulfated GAGs on densely packed proteoglycans
- ② **most common** of the three types .
- ③ Is **homogeneous and semitransparent** in the fresh state.
- ④ Its **semi-rigid consistency**

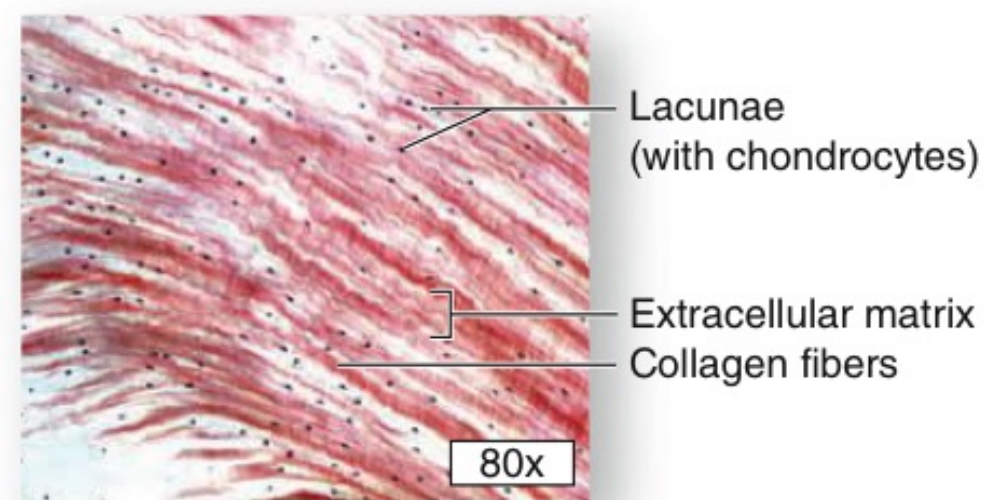
# The types of cartilages and their locations:



**b** Hyaline cartilage



**c** Elastic cartilage



**d** Fibrocartilage

Hyaline  
fibrocartilage  
Elastic

(a) There are three types of adult cartilage distributed in many areas of the skeleton, particularly in joints and where pliable support is useful, as in the ribs, ears, and nose. Cartilage support of other tissues throughout the respiratory tract is also prominent. The photomicrographs show the main features of (b) hyaline cartilage, (c) elastic cartilage, and (d) fibrocartilage. Dense connective tissue of perichondrium is shown here with hyaline and elastic cartilage.

## Why we have three types of cartilages?

**A:** to fix all the functions that they are supposed to do.

♥ Each cartilage has specialized features, may be semi rigid, flexible or harder to be suitable for its function like protection or allow movement.....

Hyaline cartilage

Cells → Chondrocyte  
Chondroblast

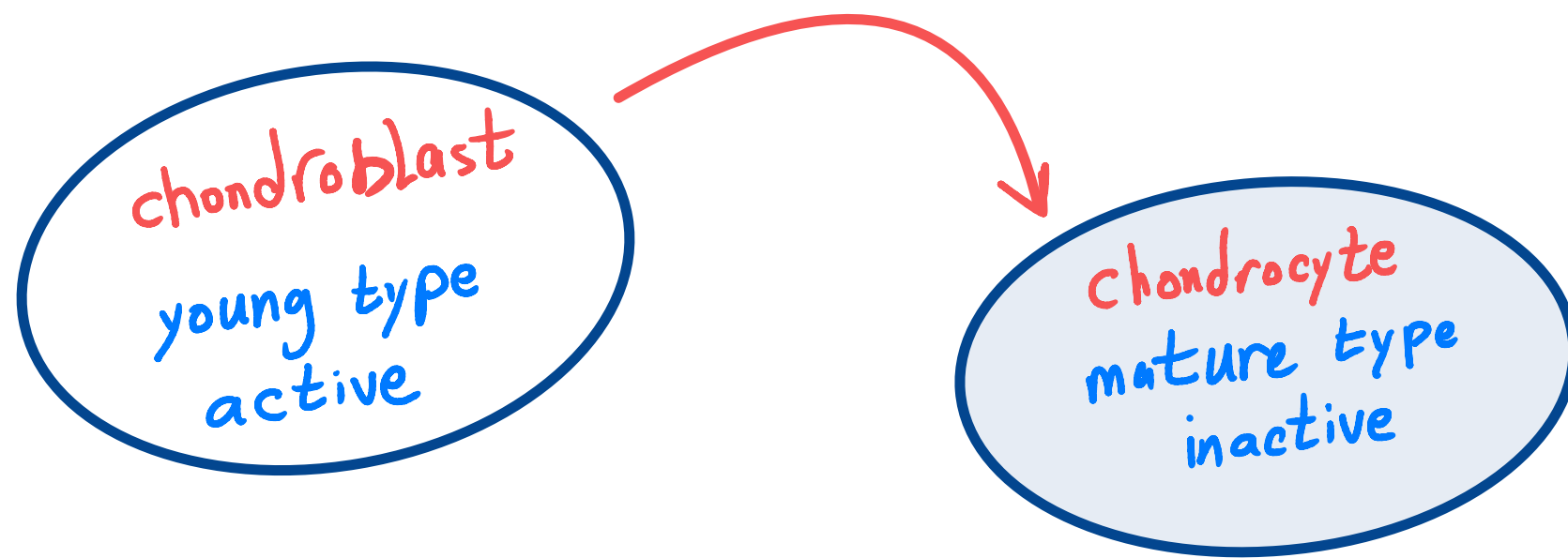
- ECM= fibers = ground substance
- \* Type 2 collagen fibrils.
  - \* hyaluronan.
  - \* sulfated GAGs = chondroitin sulfate.
  - \* Proteoglycans.
- ← It's a part of it

next Page

L ◆ we have 2 types of cartilage cells **but actually one of them is more mature than the other.**

◆ the chondrocytes are mature type of cartilage cells whereas, the chondroblasts are the young one.

◆ mature means: they have done their job and are resting in their homes ( **homes = cavity = Lacuna** ) whereas, the young ones are active, they are synthesizing the ECM around them  $\xrightarrow{\text{SOON}}$  and with time they move and advance forward, the more they will become the mature type of cartilage cells (= **chondrocytes** )



يعني الخلايا الغضروفية الناضجة (تامة النمو) تربعت يعني قعدت في بيتها بدون نشاط . اما الخلايا الغضروفية الشابة كلها نشاط و بتصنع ECM

B + L

### Hyaline cartilage locations

In adult

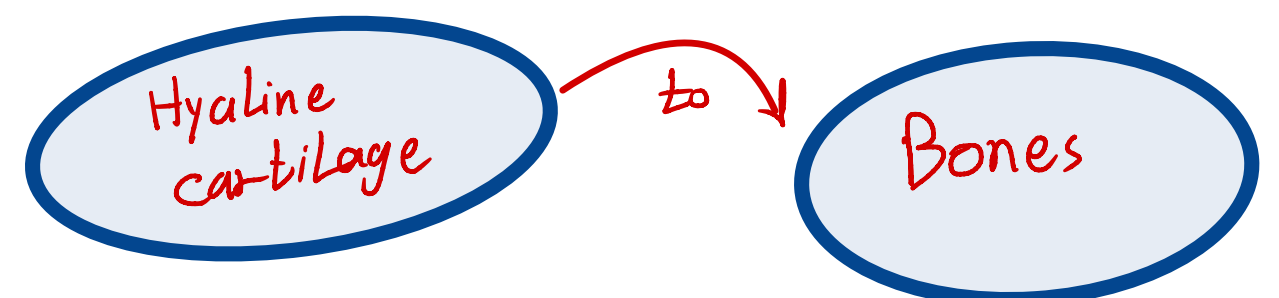
- ① It is located in the particular surfaces of movable joints.
- ② It is located in the walls of respiratory tract (passages) [nose, larynx, trachea, bronchi]
- ③ It is located in the ventral (anterior) ends of ribs (costal cartilage).
- ④ It is located in the epiphyseal plates of long bones.

Or (growth plates)  $\downarrow$   
 We will still growing as epipheseal plates are there - in the bone, once effusion for these two ends, we simply stop growing (and that growth is related to growth hormone)

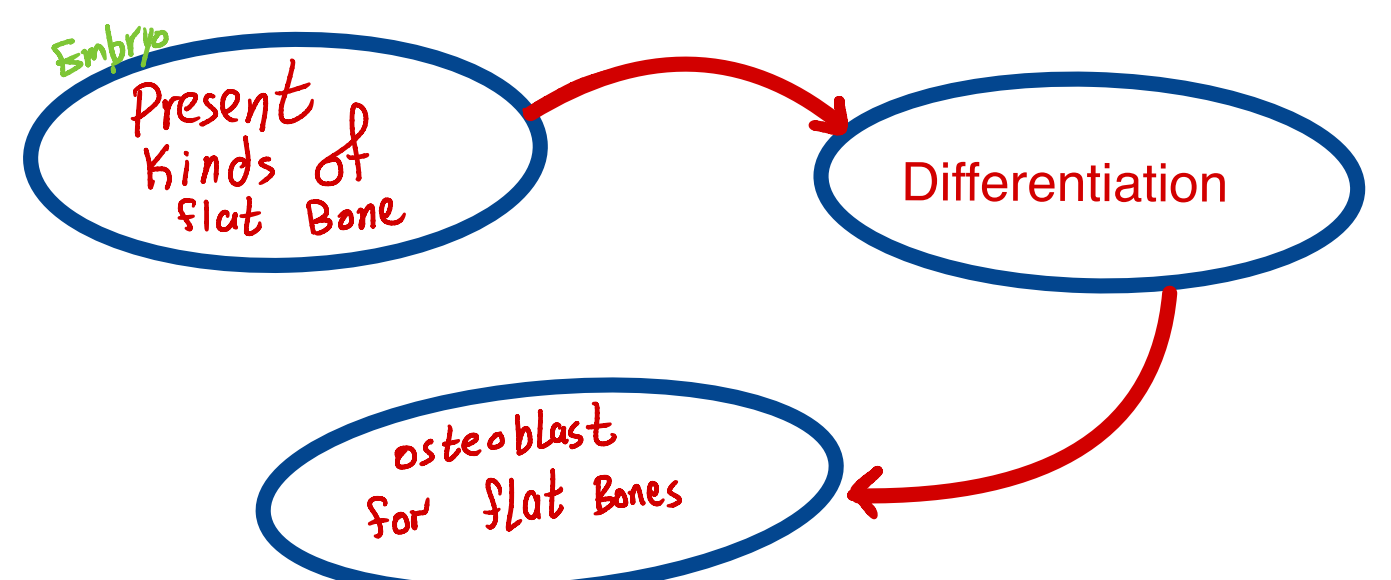
In embryo

Long bone: cartilage will be replaced by long bones except epipheseal plates will still have hyaline cartilage to keep growing.

Hyaline cartilage forms the temporary skeletal that is gradually replaced by bone



But, flat bones exist in embryo and hyaline cartilage isn't replaced by them by the time.



# ◆ Hyaline cartilage structure



◆ Collagen is embedded in a firm, hydrated gel of **proteoglycans** and structural glycoproteins (carbohydrates + proteins).

◆ **Proteoglycans**: matrix basophilic and the collagen fibrils are barely discernible.

◆ Aggrecans: core proteins attached to 150 GAGs, It is most abundant proteoglycan of hyaline cartilage.

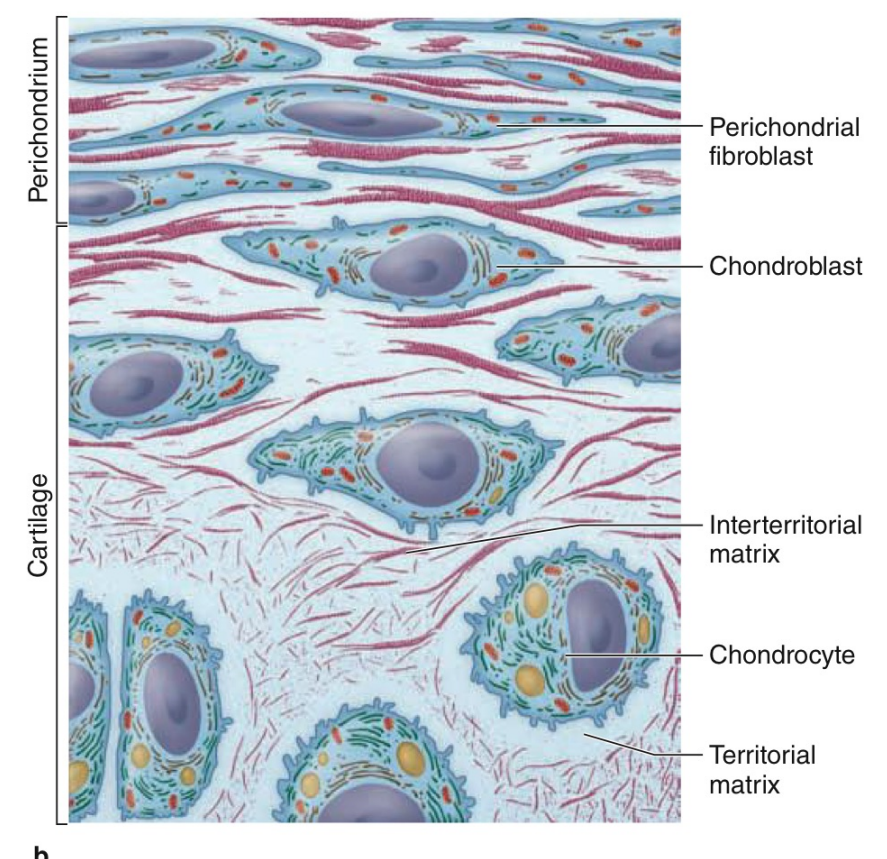
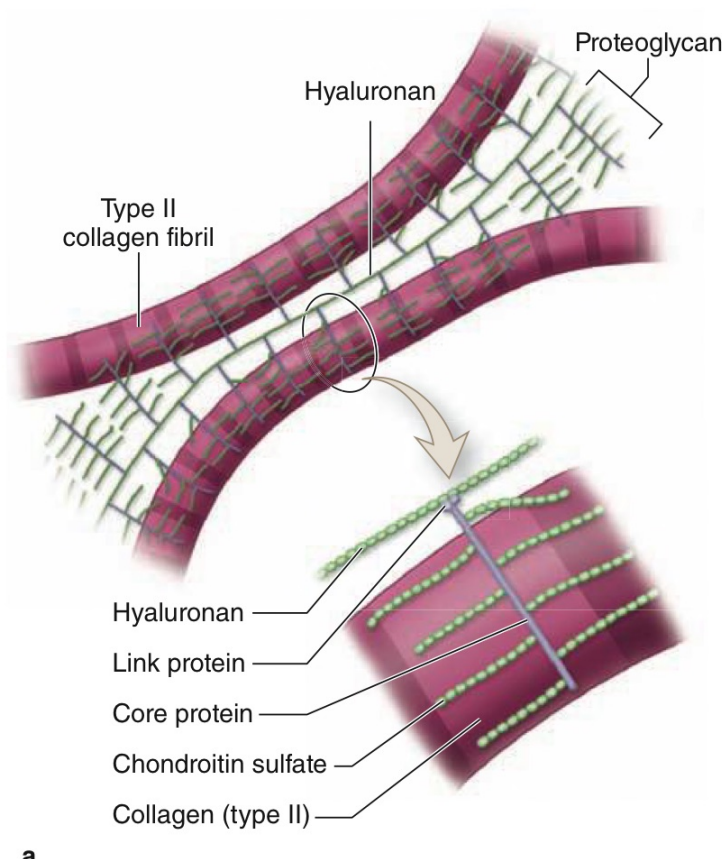
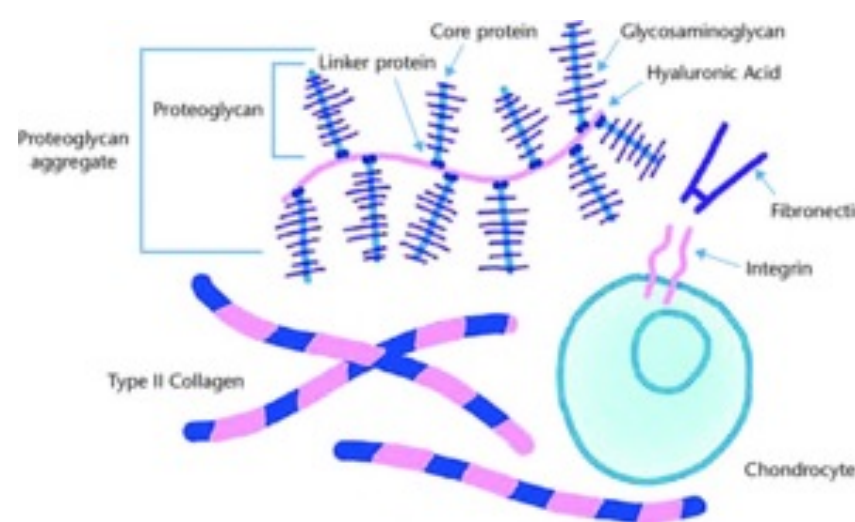
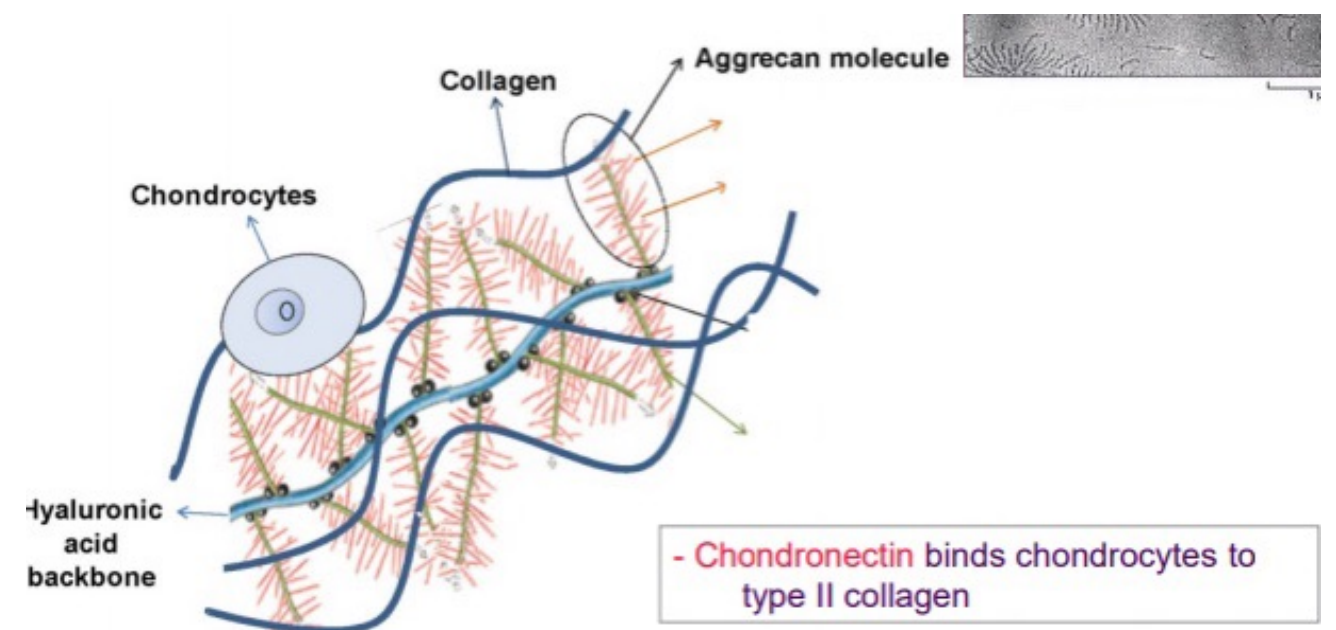
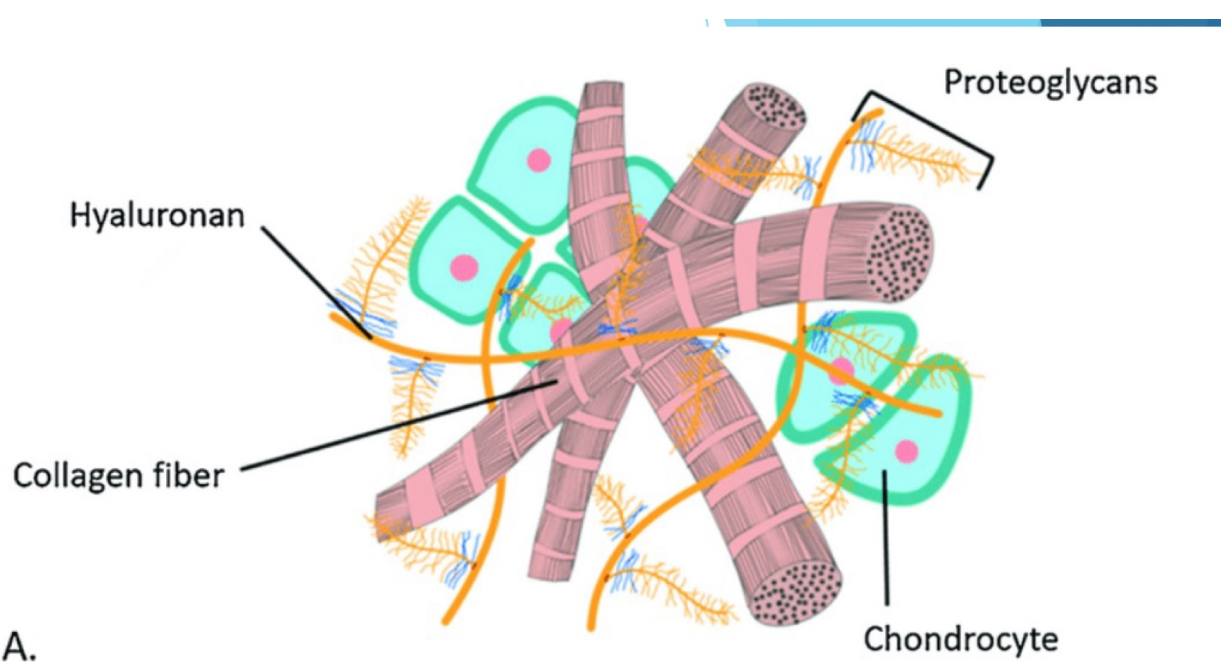
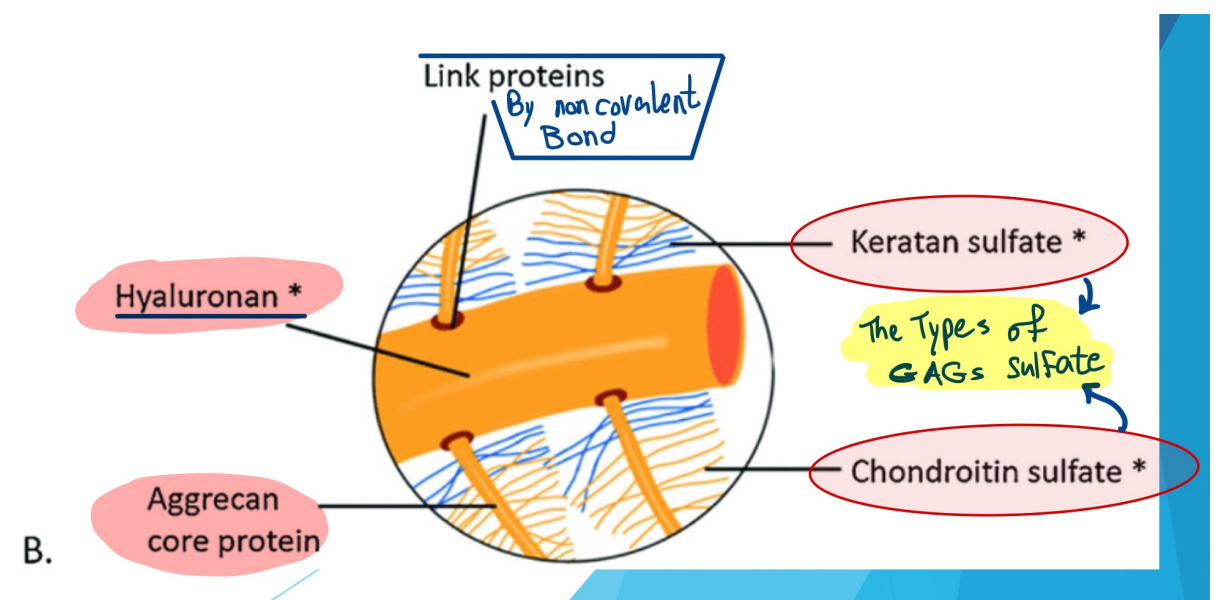
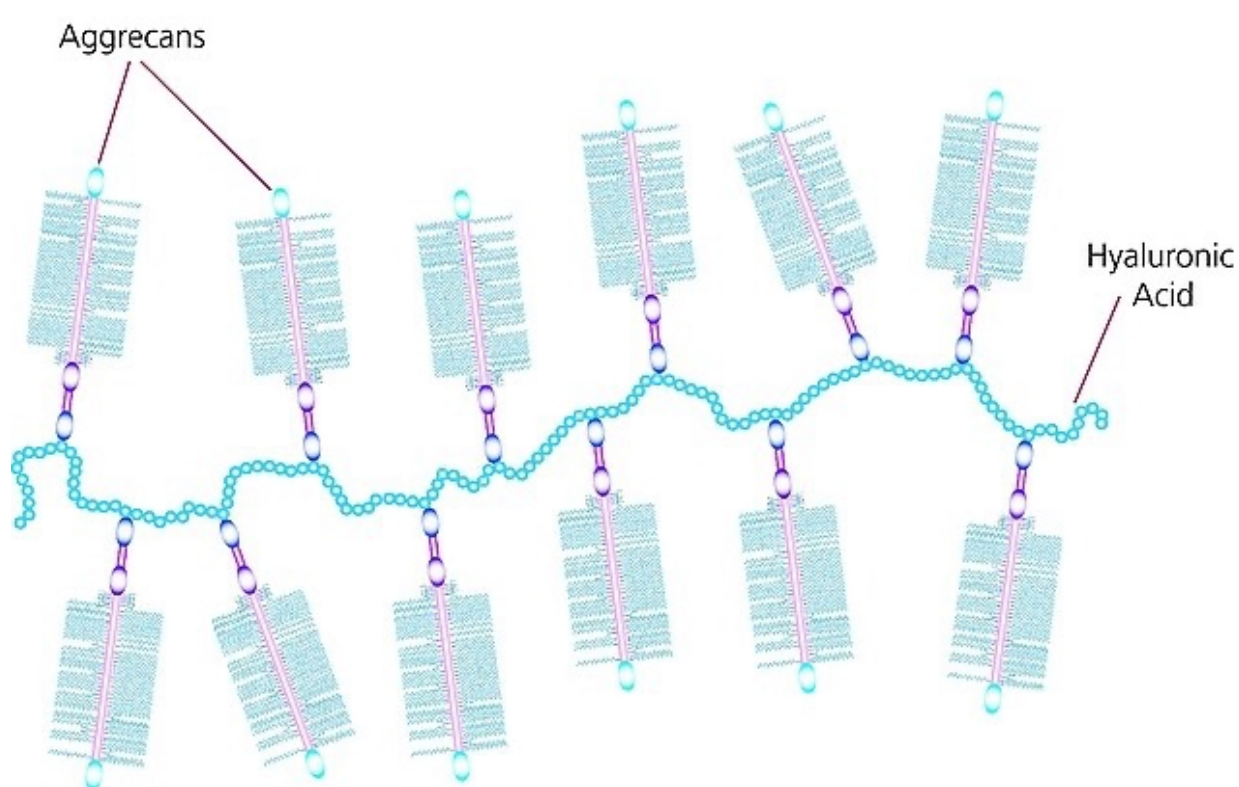
Which type of GAGs?!

① Chondroitin sulfate

② Keratan sulfate

◆ Chondronectin: structural multiadhesive glycoprotein bind specifically to GAGs, collagen and integrins, mediating the adherence of Chondrocytes to the ECM.

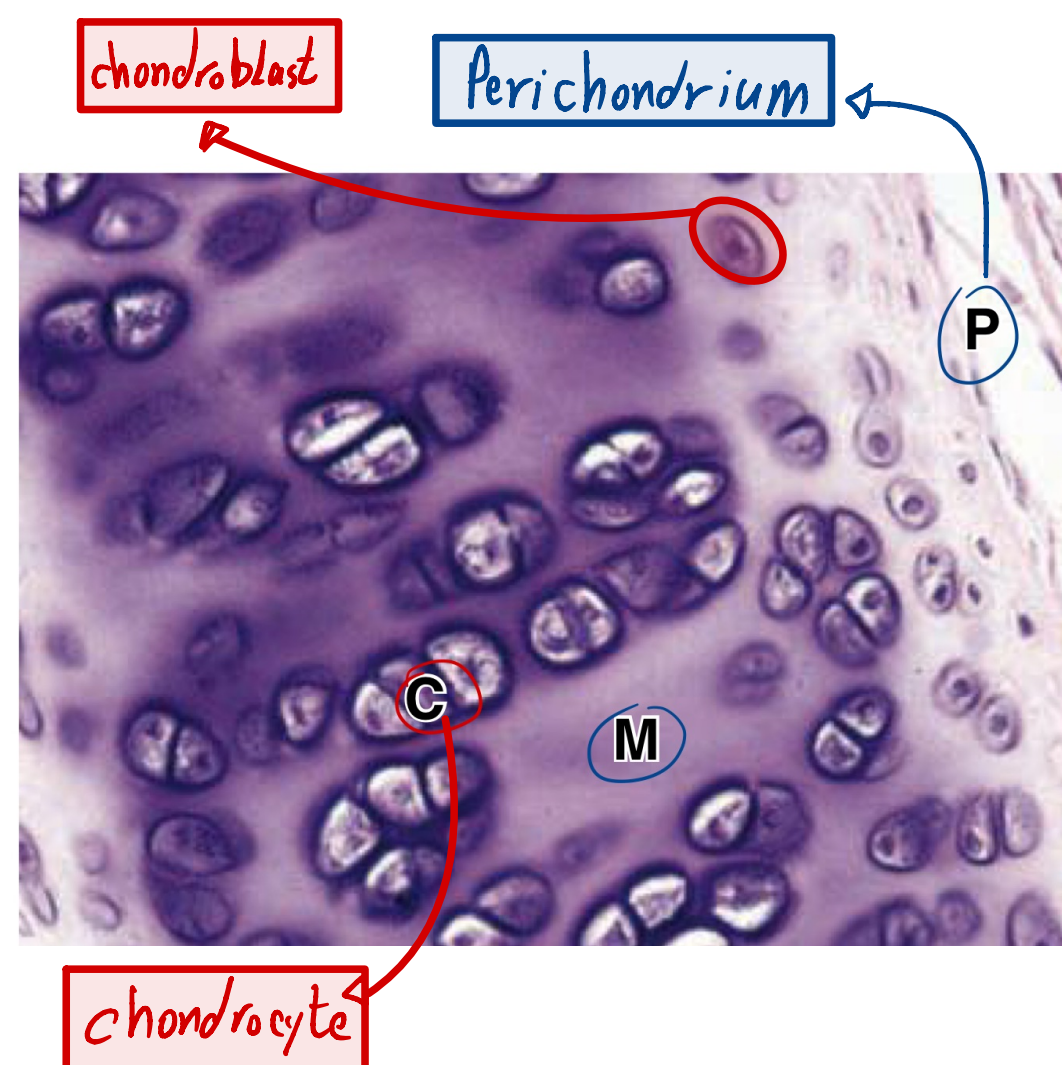
It allows the collagen type 2 to bind to the cells inside the ECM.



يوجد همور خارجية من  
لثة شرف لزيادة التوضيح  
😊

## L ◆ The perichordium ( the covering of cartilage).

The outside of perichondrium is fibers tissue rich in collagen type 1 and fibroblasts. This is the external environment away from the interior cartilage.



The inner surface of perichondrium (more cellular), we can see cells -their shape like fibroblast but they aren't fibroblast- that they are called progenitor cells.

They will later differentiate and become longer to form chondroblasts ( the young active cells.

Any thing that end with blast where is something active ( like chondroblast or osteoblast...)

Then, the chondroblast will mature to form the chondrocytes.

## L ◆ The Matrix

○ the cells do not appear to be as single ones, they tend to be in doublets (2,4,8...).

This happen during the formation of the cartilage, one cell divides in to two cells and these cells divide to two other cells =4cells.

That are called isogenous groups.

◆ when you look to matrix around cells, you will see that there are quite a difference in the color around the chondrocytes and the color between chondrocytes by microscope.

◆ which one of these colors is more intense (darker) ? And why?

A1: the color around chondrocytes.

A2: Because it is more rich in GAGs and less in collagen so, the stain is more basophilic.

○ The color (stain) around the chondrocytes is called:

**Territorial Matrix.** ↴

Territorial matrix: immediately surrounding each chondrocyte, the ECM is relatively richer in gags than collagen, causing these areas of to stain more basophilic. Contains mostly proteoglycans and sparse collagen

○ and the color (stain) between the chondrocytes is called:

**Interterritorial matrix.** ↴

Interterritorial matrix: more distant from lacunae, richer in collagen and may be less basophilic.

Go To Picture again and see Them

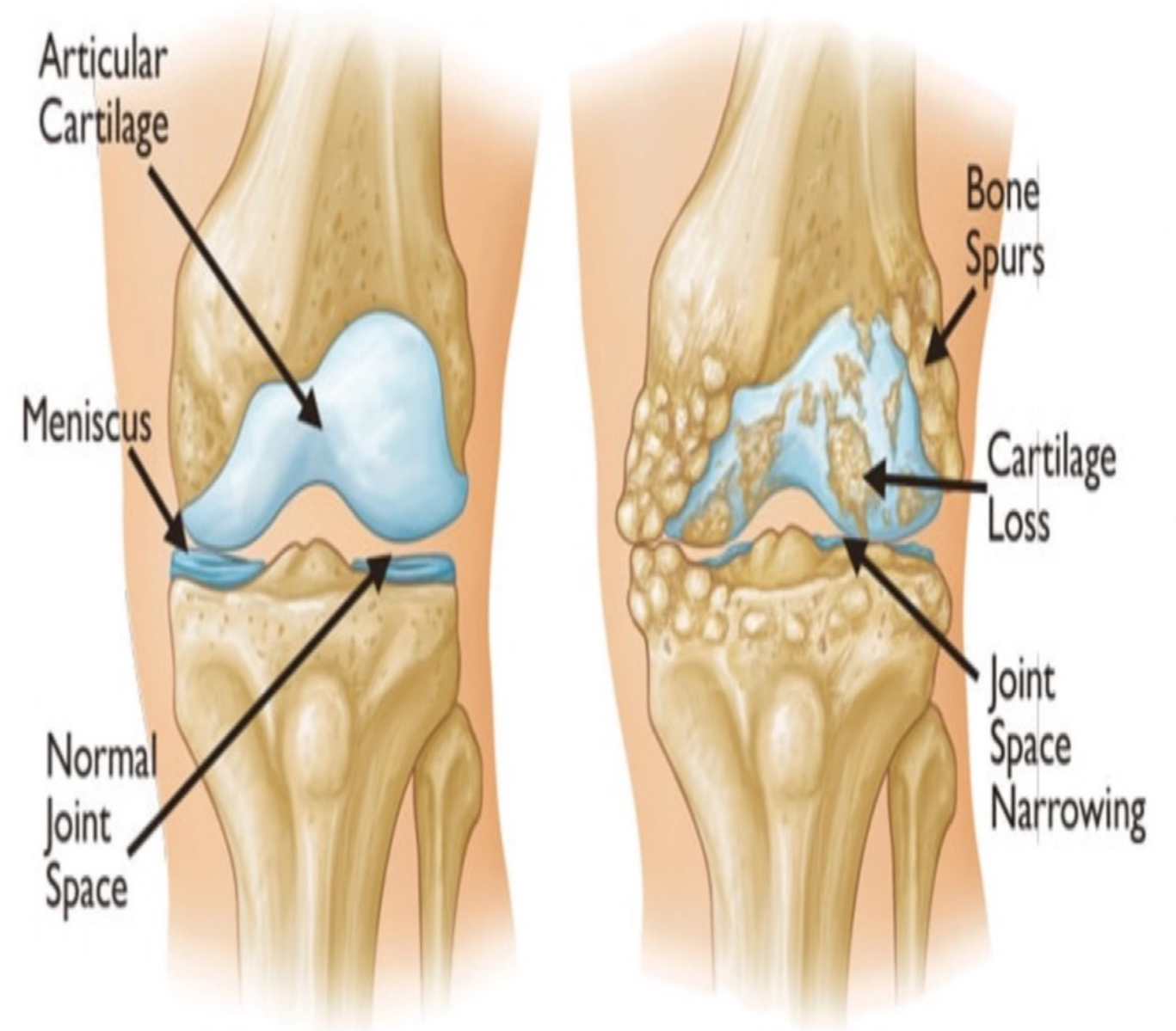


# L + S Medical (clinical) application

## Osteoarthritis

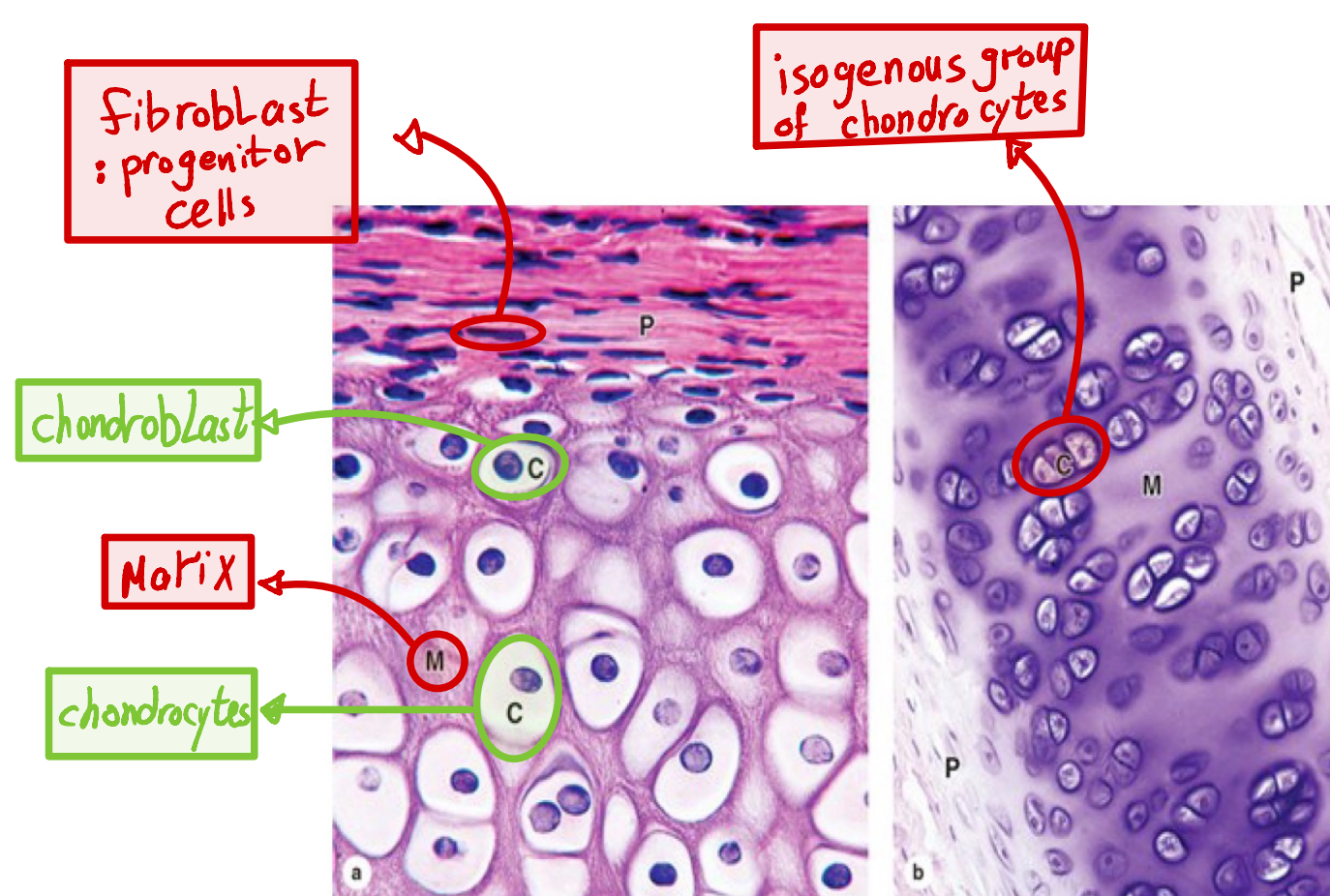
- ◆ A chronic condition that commonly occurs during aging.
- ◆ Involves the gradual loss or changed physical properties of the articular cartilages.
- ◆ Weight-bearing Joints (knees, hips) or heavily used (wrist, fingers) are most prone to cartilage degeneration.
- ◆ **What will happen?**

The cartilage eventually will be lost and bone to bone contact will happen which is painful, because we lose the cartilage (hyaline / articular) that protects inner structure (bone) and limits the movability of the joints



### >> MEDICAL APPLICATION B

**Osteoarthritis**, a chronic condition that commonly occurs during aging, involves the gradual loss or changed physical properties of the hyaline cartilage that lines the articular ends of bones in joints. Joints that are weight-bearing (knees, hips) or heavily used (wrist, fingers) are most prone to cartilage degeneration. Fragments released by wear-and-tear to the articular cartilage trigger secretion of matrix metalloproteinases and other factors from macrophages in adjacent tissues, which exacerbate damage and cause pain and inflammation within the joint.



### ○ Imp. Notes:

The outer most layer is: perichondrium. Chondroblasts, we find them at interface between tissue of cartilage and perichondrium. The more they advance inside, the more they become the chondrocytes.

	Hyaline Cartilage	Elastic Cartilage	Fibrocartilage
<b>Main features of the extracellular matrix</b>	Homogeneous, with type II collagen and aggrecan	Type II collagen, aggrecan, and darker elastic fibers	Type II collagen and large areas of dense connective tissue with type I collagen
<b>Major cells</b>	Chondrocytes, chondroblasts	Chondrocytes, chondroblasts	Chondrocytes, fibroblasts
<b>Typical arrangement of chondrocytes</b>	Isolated or in small isogenous groups	Usually in small isogenous groups	Isolated or in isogenous groups arranged axially
<b>Presence of perichondrium</b>	Yes (except at epiphyses and articular cartilage)	Yes	No
<b>Main locations or examples</b>	Many components of upper respiratory tract; articular ends and epiphyseal plates of long bones; fetal skeleton	External ear, external acoustic meatus, auditory tube; epiglottis and certain other laryngeal cartilages	Intervertebral discs, pubic symphysis, meniscus, and certain other joints; insertions of tendons
<b>Main functions</b>	Provides smooth, low-friction surfaces in joints; structural support for respiratory tract	Provides flexible shape and support of soft tissues	Provides cushioning, tensile strength, and resistance to tearing and compression

# واعلموا أَنَّ مَهْمَتَكُمْ لَيْسَتْ وَرَقَةً تَنَالُونَهَا بَلْ أُمَّةٌ تُحْيُونَهَا

سُويَعَاتُ النَّهَارِ لَمْ تَكْفِينِي...  
وَإِذْ بِي أَقْرَضُ مِنَ اللَّيْلِ عَلَى حِسَابِ النَّوْمِ...  
مَاذَا أَفْعَلُ بِهَذَا الْهِيَامِ...  
لَقَدْ أَرَهَقَنِي... جَعَلَنِي فِي إِدْمَانٍ.  
لَا أَبْرَحُ مَكَانِي حَتَّى أَفْعَلَ خِيَالِي...  
فِيحْتَارُ الْعَقْلُ وَيَهْتَزُّ الْقَلْبُ فَيَرُدُّ لِسَانِي:  
سُبْحَانَ الْخَالِقِ الْمَنَّانِ...  
الَّذِي أَبْدَعَ خَلْقَ الْإِنْسَانِ...  
فَكَيْفَ لِي أَنْ أَتَقَنَّ مَكَانِي  
دُونَ هَذَا الْإِدْمَانِ...  
فِي هَذَا الْكُونِ الْفَانِي...

رَبِّي ثَبَّتْ قَلْبِي وَعَقْلِي عَلَى صَوَابِ النِّيَّةِ  
وَجَسَدِي عَلَى إِرْهَاقِ الْجُلُوسَةِ 

زين مالك