

NCBI Bookshelf. A service of the National Library of Medicine, National Institutes of Health.

De Groot LJ, Beck-Peccoz P, Chrousos G, et al., editors. Endotext [Internet]. South Dartmouth (MA): MDText.com, Inc.; 2000-.

## Carcinoid Tumors

Aaron Vinik, MD

Dr Aaron Vinik is Professor of Medicine and Director of the Strelitz Diabetes Center, at Eastern Virginia Medical School, 855 West Brambleton Avenue, Norfolk, VA 23510 Email: vinikai@evms.edu

Eric Feliberti, M.D.

Assistant Professor, Department of Surgery, Eastern Virginia Medical School, Norfolk VA 23507. Email : felibeec@evms.edu

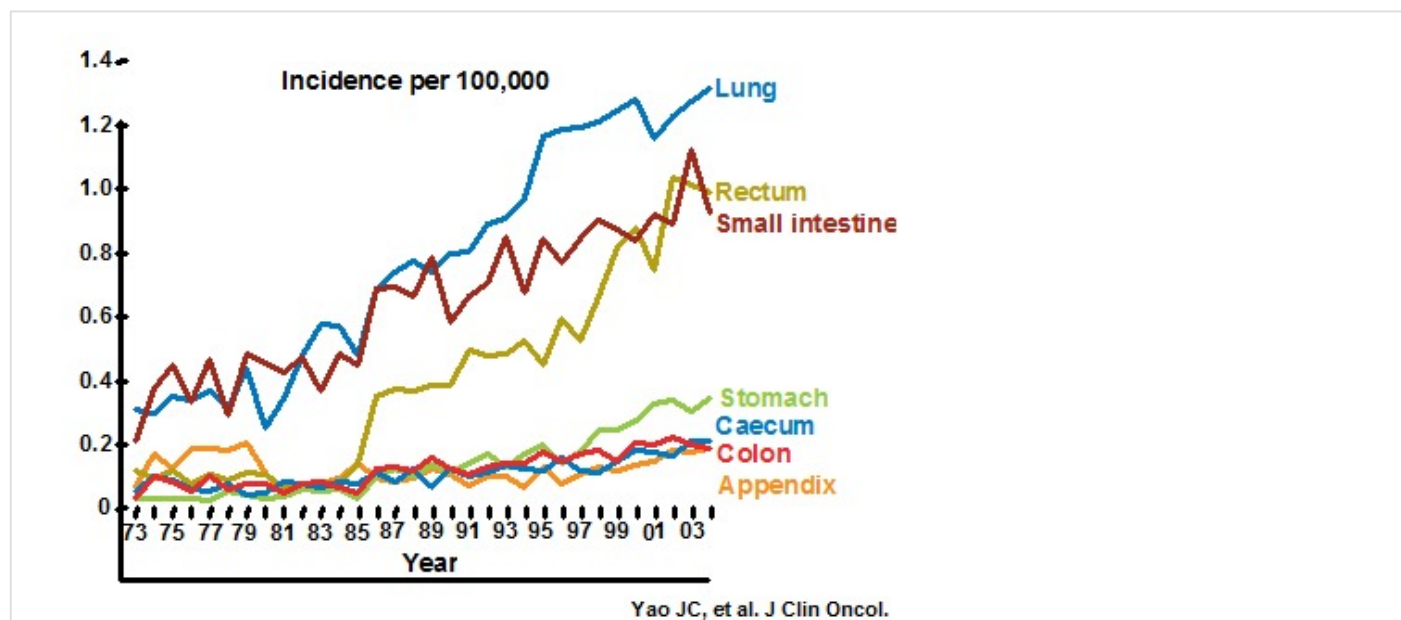
Roger R Perry, M.D., FACS

Professor of Surgery, Chief - Division of Surgical Oncology, Eastern Virginia Medical School Norfolk, VA 23507. Email: perryrr@evms.edu

Last Update: August 1, 2014.

### INTRODUCTION

Carcinoid tumors are the most commonly occurring gut endocrine tumors. They account for 13 to 34% of all tumors of the small bowel and 17 to 46% of all malignant tumors of the small bowel (8). The incidence previously has been estimated to be approximately 1.5 cases per 100,000 of the general population (i.e., approximately 2,500 cases/year in the United States). Recently, the annual incidence of neuroendocrine tumors (NETs) has risen to 40-50 cases per million due to better diagnosis, the availability of highly specific and sensitive ways to measure tumor products, and improved immunohistochemistry techniques for tumor detection (11) (12). A review of the SEER database showed an increase in the incidence of NETS from 1973 (1.09/100,000) to 2004 (5.25/100,000), with an estimated prevalence of 103,312 cases in the United States (Figure 1) (13) (14) (15). This is twice the prevalence of gastric and pancreatic cancers combined (13). The great majority (56%) of these tumors are carcinoid and the remainder are mostly pancreatic neuroendocrine tumors (pNETS). The distribution of carcinoids is Gaussian in nature. The peak incidence occurs in the sixth and eleventh decade of life, but patients as young as 10 years of age and people in their ninth decade are also seen.



**Figure 1**

Carcinoid tumors derive from primitive stem cells and are generally found in the gut wall. Carcinoids may, however, occur in the pancreas, rectum, ovary, lung, and elsewhere. The tumors grow slowly and often are clinically silent for many years before becoming manifest after metastases have occurred. They frequently metastasize to the regional lymph nodes, liver, and, less commonly, to bone. The likelihood of metastases relates to tumor size. The incidence of metastases is less than 15% with a carcinoid tumor smaller than 1 cm but rises to 95% with tumors larger than 2

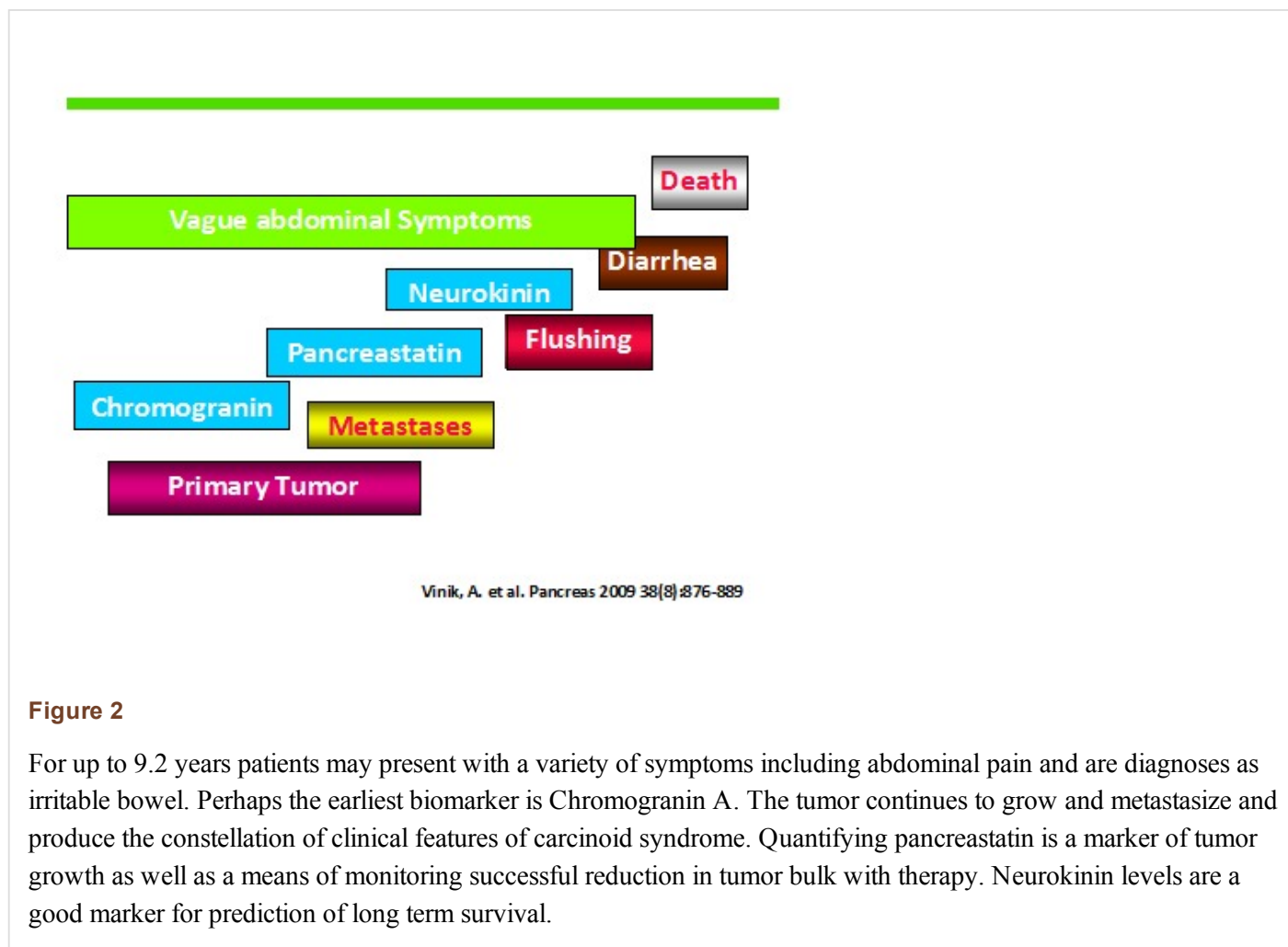
cm. These tumors may be symptomatic only episodically, and their existence may go unrecognized for many years. The average time from onset of symptoms attributable to the tumor and diagnosis is just over 9 years, and diagnosis is usually made only after the carcinoid syndrome occurs.

Of the carcinoid tumors, the most common organ source is the small intestine (16). These tumors are either referred to as small intestinal neuroendocrine tumors (SI-NETs) or midgut carcinoids (MGC). It has been estimated that as many as 71% of patients with MGC have metastatic disease at presentation (13). One of the more clinically useful classifications of carcinoid tumors is according to the division of the primitive gut from which the tumor cells arise and the vascular supply of the digestive tract: the foregut, midgut, and hindgut. The foregut includes tumors arising from the lungs, stomach, liver, biliary tract, pancreas, and first portion of the duodenum. The midgut includes the distal duodenum, the small intestines, the appendix, the right colon, and the proximal transverse colon. The hindgut includes the distal transverse colon, the left colon, and the rectum.

This distinction assists in distinguishing a number of important biochemical and clinical differences between carcinoid tumors because the presentation, histochemistry, and secretory products are quite different (see Table 1). It should be noted that the carcinoid syndrome occurs in less than 10% of patients with carcinoid tumors (17). Carcinoid syndrome is especially common in tumors of the ileum and jejunum but also occurs with bronchial, ovarian, and other carcinoids (18).

<b>Location</b>	<b>Clinical</b>	<b>Biochemical</b>
Gastric Secondary to achlorhydria (Type I) ZE/MEN-I (Type II) Primary (Type III)	Pernicious anemia, atrophic gastritis, gastric polyps gastrin >1000 pg/ml gastrin elevated, low gastric pH nl gastrin, nl gastric pH	Same as foregut
Foregut	Atypical carcinoid, ZE, acromegaly, Cushing's, etc.	5HTP, histamine, peptide
Midgut	Classic carcinoid	5HT, SP, CGRP, kinins and peptides
Hindgut	Silent	Non-secretory

**Table 1. Clinical and Biochemical Characteristics of Carcinoid Neuroendocrine Tumors**



**Figure 2**

For up to 9.2 years patients may present with a variety of symptoms including abdominal pain and are diagnosed as irritable bowel. Perhaps the earliest biomarker is Chromogranin A. The tumor continues to grow and metastasize and produce the constellation of clinical features of carcinoid syndrome. Quantifying pancreastatin is a marker of tumor growth as well as a means of monitoring successful reduction in tumor bulk with therapy. Neurokinin levels are a good marker for prediction of long term survival.

There are impediments to the diagnosis of these tumors. First, they comprise <2% of gastrointestinal malignancies and are therefore not the first diagnosis considered. Symptoms are often nonspecific and do not lend themselves to identifying the specific underlying tumor. The manifestations are protean and mimic a variety of disorders. The natural history of this disease is invariably attended by a long course of vague abdominal symptoms, recurrent visits to primary care practitioners, and referral to a gastroenterologist, with a misdiagnosis of irritable bowel syndrome (IBS). The median latency to correct diagnosis is 9.2 years by which time the tumor has often metastasized, causing symptoms like flushing and diarrhea and progressing slowly until the patient dies (Figure 2). Thus, greater index of suspicion and a carcinoid tumor profile screen is warranted for all patients presenting with “traditional IBS symptoms.” Midgut carcinoids are associated with mesenteric fibrosis, which can compress mesenteric vessels and cause bowel ischemia and malabsorption, even in the absence of an obvious abdominal mass. The diagnosis of metastases to the liver often takes place after a delay of many years. Even then, an incorrect diagnosis is not uncommon. Unless biopsy material is examined for the secretory peptides chromogranin, synaptophysin, or neuron-specific enolase (NSE), tumors may be labeled erroneously as adenocarcinoma, impacting management and underestimation of prospects for survival (19).

Although carcinoids classically are tumors of enterochromaffin and argentaffin cells of the digestive tract, the term carcinoid tumor can be expanded to cover gut tumors of paracrine- and endocrine-like cells of unknown function (20) (21). It now is established that these tumors are of neuroendocrine origin and derive from a primitive stem cell. They may differentiate into any one of a variety of adult endocrine secreting cells: b cell and insulinoma, a cell and glucagonoma,  $\delta$  cell and somatostatinoma, and the PP cell and PPoma, or cells capable of producing ACTH, growth hormone-releasing hormone, VIP, SP, gastrin-releasing factor, calcitonin, Ghrelin and the EC cell, with its ability to co-secrete amines such as serotonin and the peptide motilin. At any one point in time, these cells may secrete one humor, whereas at others, the peptide or amine secreted may differ and yield an entirely different clinical syndrome. Indeed,

metastases are known to secrete hormones that differ from the parent tumor, and different metastases may secrete different hormones. Symptoms may derive from secretion of one or more of the hormones secreted.

### **Molecular Genetics**

The genetics of neuroendocrine tumorigenesis have yet to be elucidated. Although small familial clusters of midgut carcinoids have been described, there are no known genetic cancer syndromes associated with them. Tumors have clustered in several small families without MEN I, and multiplicity of tumors is a feature in one quarter of isolated cases. Among sporadic midgut carcinoids, several studies using comparative genomic hybridization or microsatellite markers have shown frequent allelic deletion of chromosome 18 (22) (23). On an epigenetic level, midgut NETS have been found to have global hypomethylation (24). There is little data about genetic aspects in NETs of the appendix or cecum. Tumor multiplicity is much less frequent in the appendix and cecum than the ileum

### **Clinical Classification:**

#### **Foregut Carcinoids**

Foregut carcinoids are argentaffin negative. They have a low content of serotonin (5-hydroxytryptamine [5-HT]). They often secrete the serotonin precursor 5-hydroxytryptophan (5-HTP), histamine, and a multitude of polypeptide hormones. Their functional manifestations include carcinoid syndrome, gastrinoma syndrome, acromegaly, Cushing's disease, and a number of other endocrine disorders. Furthermore, they are unusual in that the flush tends to be of protracted duration, is often of a purplish or violaceous hue as contrasted with the usual pink or red, and frequently results in telangiectasia and hypertrophy of the skin of the face and upper neck. The face may assume a "leonine" characteristic after repeated episodes. It is not unusual for these tumors to metastasize to bone. (Serotonin, gastrin, and other peptide assays available at Inter Science Institute-800-255-2873). A further point of interest is that if a carcinoid tumor co-exists with MEN-1, more than two-thirds of the time in males the tumor is in the thymus, whereas in females, it is in the lung over 75% of the time.

#### **Gastric Carcinoid Tumors**

There are three types of gastric carcinoid tumors. Type I gastric carcinoid tumors represent approximately 70 to 80 % and are associated with hypergastrinemia due to chronic atrophic gastritis and pernicious anemia (25). These are typically multiple small lesions which arise from the gastric enterochromaffin-like (ECL) cell and are less likely to metastasize. The achlorhydria is usually caused by atrophic gastritis that accompanies pernicious anemia wherein there is loss of gastric acid secretion and thereby impairment of the normal restraint mechanism suppressing gastrin production. Gastrin is trophic to the enterochromaffin cells in the stomach and when levels arise above 1000pg/ml this constitutes a threshold for the induction of gastric carcinoid polyps and tumors (26) (27). The association between hypergastrinemia and the development of gastric carcinoids supports the hypothesis that growth factors are important in the genesis of endocrine tumors. The clinical picture is invariably a patient with evidence of pernicious anemia, premature graying of the hair, and associated autoimmune disorders. Antibodies to gastric parietal cells and intrinsic factor are found and there is achlorhydria or hypochlorhydria and sampling of gastric content reveals near neutral instead of the normal highly acidic pH. In this setting measurement of serum gastrin usually suffices to herald the threat of development of carcinoid tumors and periodic gastroscopy and enucleation of the lesions is advisable. When gastrin levels exceed 1000pg/ml it may occasionally be appropriate to carry out an antrectomy to remove the source of the gastrin. In animal models this clinical condition has been duplicated by long-term administration of proton pump inhibitors, but this does not appear to be the case in humans since gastrin levels may rise but seldom if ever reach the critical level for induction of dysplasia.

Type II gastric carcinoid tumors are much less common, representing approximately 5 %, and are associated with hypergastrinemia due to Zollinger-Ellison syndrome and multiple endocrine neoplasia (MEN) Type I. These lesions also are typically multiple and small, although the risk of metastasis appears to be slightly higher than for Type I (28).

Type III gastric carcinoid tumors account for approximately 20 % of lesions, and are sporadic. There is no known

association with hypergastrinemia, chronic atrophic gastritis or Zollinger-Ellison syndrome. These typically present as large solitary lesions. They may be associated with atypical carcinoid syndrome mediated by histamine. These have the highest risk of metastasis, and are sometimes metastatic upon initial diagnosis.

Fasting serum gastrin levels are important to differentiate types I and II gastric carcinoids from type III. Gastrin levels are elevated in both type I and type II gastric carcinoids but not in type III. It is important to note that patients with type I gastric carcinoid are hypochlorhydric or achlorhydric while patients with type II gastric carcinoids have high acid levels. 5-HIAA levels are generally not elevated because development of the carcinoid syndrome is uncommon (29). Plasma chromogranin A (CGA) levels are recommended because CGA is frequently elevated in patients with all 3 types of gastric carcinoid tumors (30) and changes in CGA levels may be helpful in follow-up (30). In patients treated with somatostatin analogs, CGA levels should be interpreted cautiously, since these agents significantly reduce plasma CGA levels (30),(31). In patients on stable doses of somatostatin analogs, consistent increases in plasma CGA levels over time may reflect loss of secretory control and/or tumor growth. Plasma CGA levels also have prognostic value in patients with metastatic disease (30),(32).

### **Midgut Carcinoids**

Midgut carcinoids, in contrast, are argentaffin positive, have high 5-HT content, rarely secrete 5-HTP, and often produce a number of other vasoactive compounds, such as kinins, prostaglandins, and SP. The clinical picture that results is the classic carcinoid syndrome of flushing and diarrhea with or without wheezing. These tumors may produce adrenocorticotrophic hormone (ACTH) on rare occasions and infrequently metastasize to bone.

### **Hindgut Carcinoids**

Hindgut carcinoids are argentaffin negative, rarely contain 5-HT, rarely secrete 5-HTP or other peptides, and usually are silent in their presentation. They may be discovered on rectal exam, flexible sigmoidoscopy, or colonoscopy. They may metastasize to bone.

### **CLINICAL PRESENTATION:**

Carcinoid tumors are slow growing and may be present for years without overt symptoms, thus escaping attention. During the early stages, vague abdominal pain goes undiagnosed and invariably is ascribed to irritable bowel or spastic colon. Fully one-third of patients with carcinoid tumors present with years of intermittent abdominal pain. Carcinoid tumors can present in a variety of ways. For example, duodenal tumors are known to produce gastrin and may present with the gastrinoma syndrome.

An interesting association between pernicious anemia, atrophic gastritis, chronic thyroiditis, and gastric carcinoid tumors has been previously discussed in detail above (25). Patients with carcinoid tumors of the thymus most often manifest ectopic Cushing's syndrome or hypercalcemia. Bronchial carcinoids may be associated with MEN-1.

The major clinical manifestations of carcinoid tumors are based on mechanical complications (pain, obstruction, bleeding) or due to the secreted bioactive factors (11). The carcinoid syndrome is a constellation of signs and symptoms associated with hypersecretion of vasoactive substances (e.g., serotonin, histamine, tachykinins, and prostaglandins) by the carcinoid tumor. The extent of these signs and symptoms are a function of the degree and type of substances that are secreted. Because the liver can inactivate these substances, hepatic metastases are typically present in the case of midgut carcinoids but are not essential in foregut carcinoids. Since hindgut carcinoids do not secrete vasoactive amines their presentation is invariably pain, bleeding from the GI tract, intestinal obstruction, or symptoms from distant metastases.

The symptom complexes are given in Table 2 and include cutaneous flushing, which occurs in 84% of patients, gastrointestinal (GI) hypermotility with diarrhea (70%), heart disease (37%), bronchial constriction (17%), myopathy (7%), and an abnormal increase in skin pigmentation (5%) (11). More recently it has come to be recognized that carcinoid tumors can be associated with myopathy, skin pigmentation which is a pellagra like eruption, a paraneoplastic neuropathy, arthropathy and peripheral edema (33) (Figure 3). When co-existence of the major symptoms of flushing

and diarrhea is sought, it emerges that flushing and diarrhea occur simultaneously in 58%, diarrhea without flushing in 15%, flushing without diarrhea in 5%, and neither flushing nor diarrhea as a symptom complex in 22%. The natural history of these tumors is illustrated in [Figure 2](#). Invariably there has been a long history of vague abdominal symptoms, a series of visits to the primary care practitioner and referral to a gastroenterologist and the diagnosis of irritable bowel syndrome (IBS) made. In a review of our own experience with midgut carcinoid patients, the diagnosis of IBS at some point in time could always be found in the patient record. With a median latency to diagnosis of 9.2 years by the time the diagnosis is made the tumor has often metastasized, causing flushing and diarrhea and progressing on its slow but relentless course to demise. Clearly a greater index of suspicion is warranted in all patients presenting with “traditional irritable bowel symptoms”.

Carcinoid tumors may metastasize to various sites, but especially the liver ([Figure 5](#)).

The incidence of metastatic disease based on primary tumor size is shown in [Figure 4](#). With metastases to the liver, the correct diagnosis generally is arrived at, but often with a delay of many years. Even then, mistaken identity is not uncommon, and unless biopsy material is examined for the secretory peptide chromogranin, (34) synaptophysin, (35) or NSE, (36) tumors may be labeled erroneously as adenocarcinoma, with a negative impact on attitudes toward management and underestimation of prospects for survival.

**Table 2 The Clinical Presentations, Syndromes, Tumor Types, Sites and Hormones (19).**

<b>Clinical Presentation</b>	<b>Syndrome</b>	<b>Tumor Type</b>	<b>Sites</b>	<b>Hormones</b>
<b>Flushing</b>	Carcinoid Medullary Carcinoma of Thyroid Pheochromocytoma	Carcinoid C cell tumor Tumor of Chromaffin cells	Mid/ foregut Adrenal medulla Gastric Thyroid C cells Adrenal and Sympathetic Nervous system	Serotonin, GCRP, Calcitonin Metanephrine and Normetanephrine
<b>Diarrhea abdominal pain and dyspepsia</b>	Carcinoid, WDHHA, ZE, PP, MCT	Carcinoid, VIPoma, Gastrinoma, PPoma, Medullary carcinoma thyroid thyroid,mastocytoma	As above, pancreas, mast cells, thyroid	As above, VIP, gastrin, PP, calcitonin
<b>Diarrhea/ steatorrhea</b>	Somatostatin Bleeding GI tract	Somatostatinoma, neurofibromatosis	Pancreas Duodenum	Somatostatin
<b>Wheezing</b>	Carcinoid	Carcinoid	Gut/pancreas/lung	SP, CGRP, serotonin
<b>Ulcer /dyspepsia</b>	Zollinger Ellison,	Gastrinoma	Pancreas/ duodenum	Gastrin
<b>Hypoglycemia</b>	Whipple’s triad	Insulinoma, sarcoma, hepatoma	Pancreas, retroperitoneal liver	Insulin, IGF1, IGF11.
<b>Dermatitis</b>	Sweet Syndrome Pellagra	Glucagonoma Carcinoid	Pancreas Midgut	Glucagon Serotonin
<b>Dementia</b>	Sweet syndrome	Glucagonoma	Pancreas	Glucagon
<b>Diabetes</b>	Glucagonoma Somatostatin	Glucagonoma Somatostatinoma	Pancreas Pancreas	Glucagon Somatostatin

<b>DVT, Steatorrhea, Cholelithiasis Neurofibromatosis</b>	Somatostatin	Somatostatinoma	Pancreas Duodenum	Somatostatin
<b>Silent, liver mets</b>	Silent	PPOMA	Pancreas	PP

Table 2 summarizes the suggested approach to diagnose a NET based upon the clinical presentation, the tumor type, their sites of origin the possible means of diagnosis, and the biochemical markers that should be measured.

Abbreviations: CGRP: Calcitonin gene-related peptide

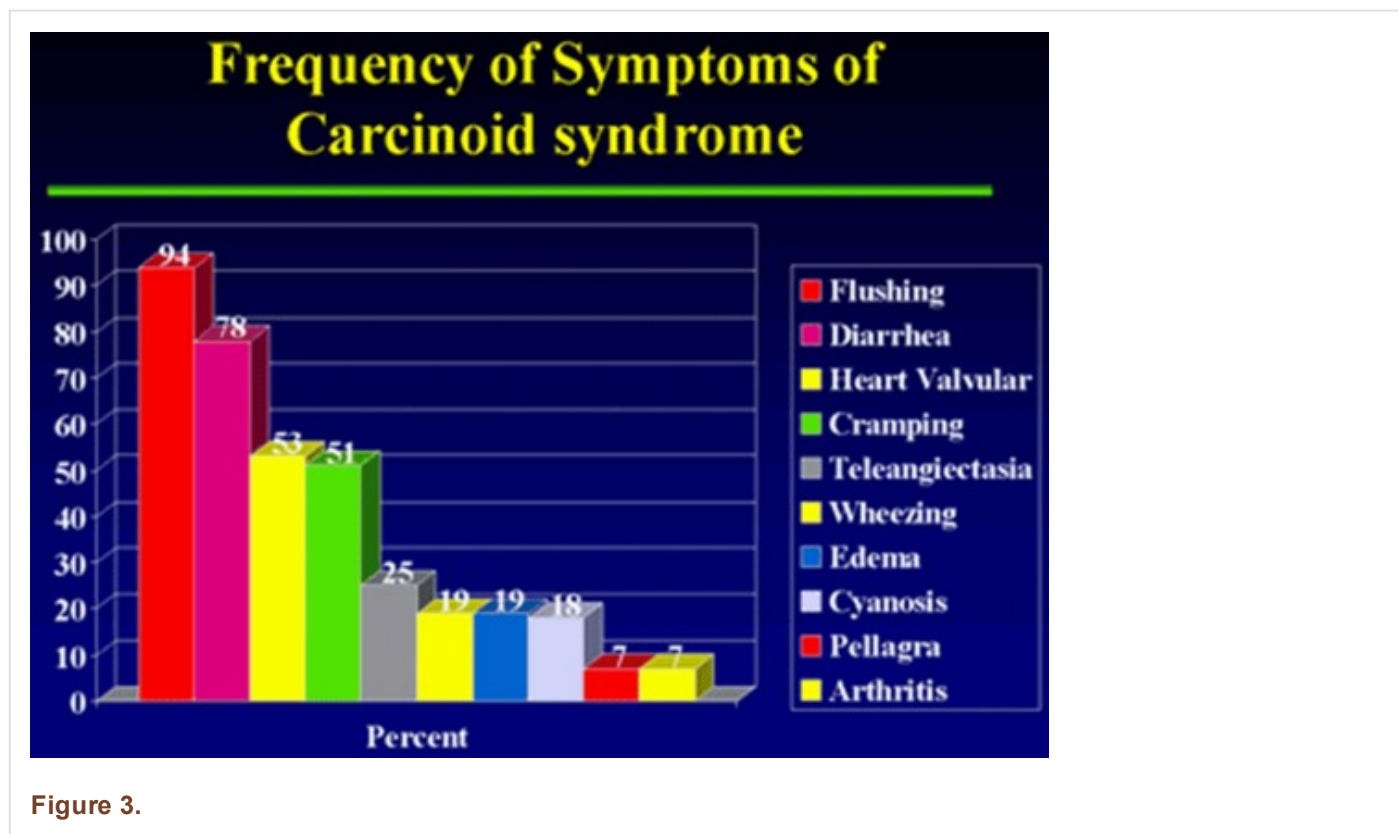


Figure 3.

	Tumor Location (%)	Incidence of Metastases (%)
<b>Foregut</b>		
Stomach	38	31
Duodenum	21	33
Lung	32.5	27
<b>Midgut</b>		
Jejunum	2.3	70
Ileum	17.6	70
Appendix	7.6	35
Colon	6.3	71
<b>Hindgut</b>	10	14

Jensen, Current Opinions Oncology, 2000

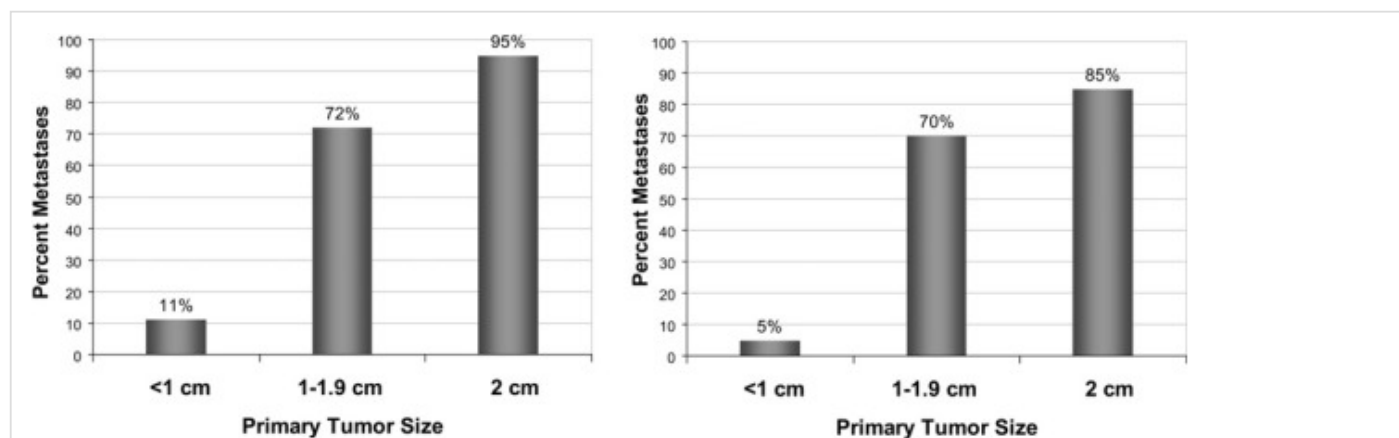
**Table 3. Tumor Location and Frequency of Metastases n = 5468**

Figure 4 Incidence of metastases stratified by primary tumor size in two analysis: single-center database of 165 cases (Moertel [10];left) and literature review (Rorstad[15]; right).

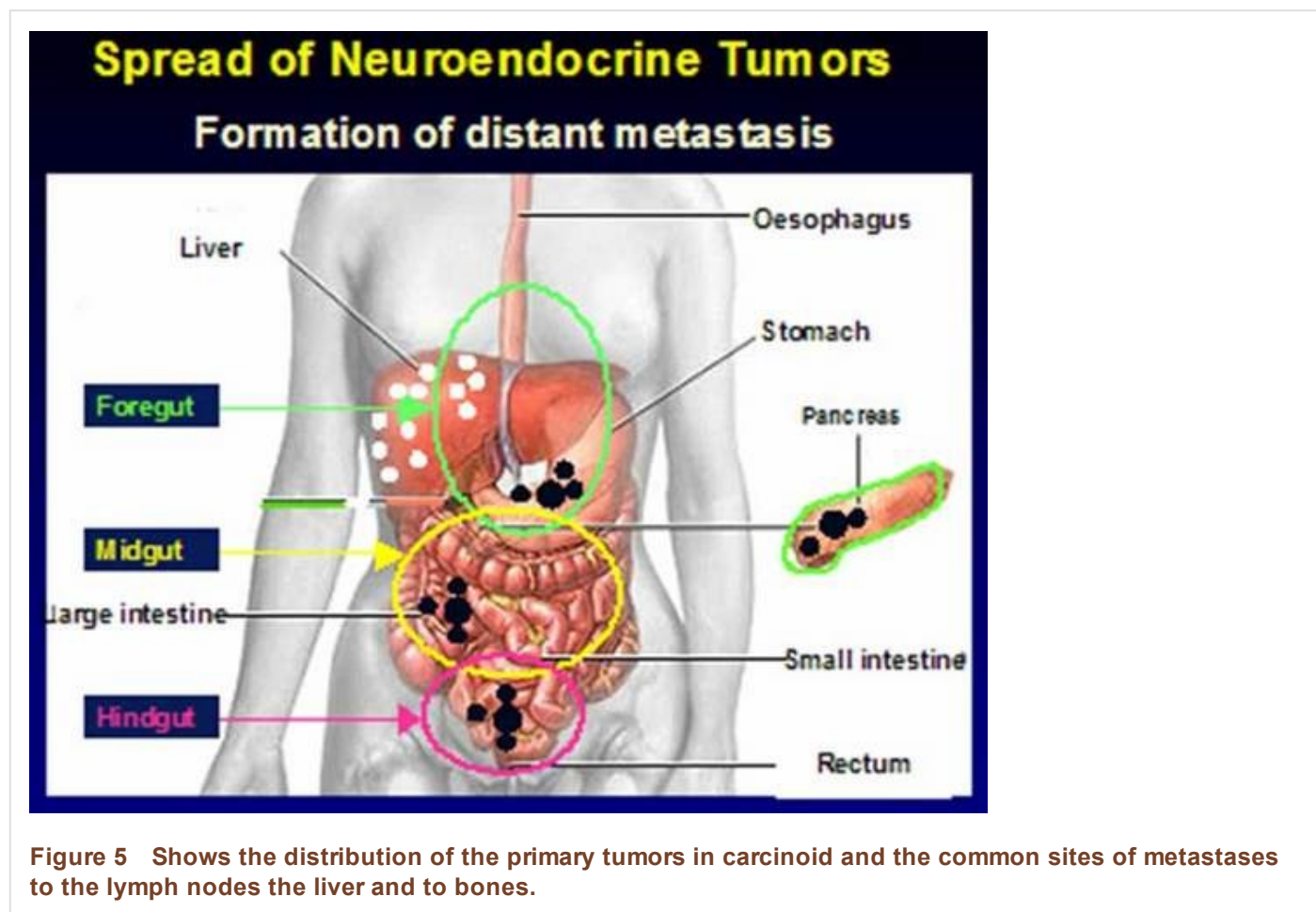


Figure 5 Shows the distribution of the primary tumors in carcinoid and the common sites of metastases to the lymph nodes the liver and to bones.

### Carcinoid Syndrome

Carcinoid syndrome occurs in less than 10% of patients with carcinoid tumors. Principal features include flushing, sweating, wheezing, diarrhea, abdominal pain, endomyocardial fibrosis, and pellagra. Diarrhea is found in 76-83% of cases, flushing in 94%, (37), heart valvular disease and abdominal cramping each in about 50%, dyspnea in 20%, and bronchospasm in 6%. A variety of other symptoms such as wheezing, edema, cyanosis, pellagra and arthropathy occur much less frequently (Figure 3). The relationship between diarrhea and flushing is variable. One can occur without the



other, and there may be no temporal relationship between the two. The specific etiologic agent or agents for each of the protean manifestations of the carcinoid tumors are not known. Serotonin, (37) (38) prostaglandins, (38) 5-HTP, (39) (40) SP, (41) (42), kallikrein, (43) histamine, (44) dopamine, (45) and neuropeptide K (46) are thought to be involved in the clinical manifestations of carcinoid tumors. In addition, symptoms may relate to overproduction of peptides in the pro-opiomelanocortin family (e.g., endorphin and enkephalin). Pancreatic polypeptide and motilin levels often are raised, (47) may be important markers of tumor activity, and may provide a means of monitoring tumor growth and response to therapy rather than contributing to specific symptomatology.

Feldman and O'Dorisio (48) (49) examined the proportion of 43 patients with carcinoid tumor having increased levels of serotonin and various other vasoactive peptides (49). Serotonin, measured either as its urinary metabolite 5-HIAA (50) or whole-blood serotonin, (51) (52) was raised in 84% of patients with carcinoid tumors and within normal limits in patients having other tumors and miscellaneous illnesses. Urinary 5-HIAA alone had 73% sensitivity and 100% specificity. Seven of these patients had normal urinary 5-HIAA levels but other elevated indices of serotonin production. Neurotensin and SP were raised in 43 and 32% of patients and had specificity values of 60 and 85%, respectively. False-positive results occurred in 23 and 26%, respectively, of patients with conditions other than carcinoid tumors. Motilin and somatostatin were raised in 14 and 50%, respectively.

### Flushing

Flushing, a cardinal symptom of carcinoid tumors occurs in a variety of other conditions that need to be distinguished. The differential diagnosis of flushing includes the postmenopausal state, simultaneous ingestion of chlorpropamide and alcohol, panic attacks, medullary carcinoma of the thyroid, autonomic epilepsy, autonomic neuropathy, and mastocytosis (Table 4).

A good rule of thumb is that if the flushing is wet it is due to a cause other than carcinoid. Table 4 lists the variety of causes that are confounding and the features that help distinguish them from flushing due to carcinoid.

### Tests to identify cause of flushing

CLINICAL CONDITION	TESTS
<b>Carcinoid</b>	<b>Urine 5HIAA, 5HTP, SP, CGRP, CGA</b>
<b>Medullary Carcinoma Thyroid</b>	<b>Calcitonin, Calcium Infusion, Ret Proto-oncogene</b>
<b>Pheochromocytoma</b>	<b>Plasma free metanephrines, Urine metanephrines, VMA, Epi, Norepi, glucagon stim, MIBG</b>
<b>Diabetic AN</b>	<b>HRV, 2 h PP glucose</b>
<b>Menopause</b>	<b>FSH</b>
<b>Epilepsy</b>	<b>EEG</b>
<b>Panic</b>	<b>Pentagastrin/ACTH</b>
<b>Mastocytosis</b>	<b>Plasma histamine, urine tryptase</b>
<b>Hypomastia, Mitral prolapse</b>	<b>Cardiac echo</b>

**Table 4.** Various tests to identify the cause of flushing

*AN=autonomic neuropathy, 5HIAA=5 hydroxyindole acetic acid, 5HTP= 5 hydroxy tryptophan, SP=substance P, CGRP=calcitonin gene related peptide, CGA=chromogranin A, VMA=vanillyl mandelic acid, Epi=epinephrine, Norepi= norepinephrine, stim =stimulation, MIBG=metiodobenzylguanidine, HRV=heart rate variability,*

*PP=postprandial, FSH=follicle stimulating hormone, EEG=electroencephalogram, ACTH =adrenocorticotrophic hormone*

Flushing in carcinoid syndrome is of two varieties. First, with midgut carcinoid, the flush usually is of a faint pink to red color and involves the face and upper trunk as far as the nipple line. The flush is initially provoked by alcohol and food containing tyramines (e.g., blue cheese, chocolate, red sausage, and red wine). With time, the flush may occur spontaneously and without provocation. It usually is ephemeral, lasting only a few minutes, and may occur many times per day but generally does not leave permanent discoloration.

In contrast, in the second type, the flush of foregut tumors often is more intense, of longer duration, purplish in hue, frequently followed by telangiectasia, and involves not only the upper trunk but may also affect the limbs. The limbs may become acrocyanotic, and the nose resembles that of rhinophyma. The skin of the face often thickens, with the appearance of a leonine facies resembling that seen in leprosy and acromegaly.

A more recently described cause of flushing is the non-insulinoma pancreatogenous hypoglycemia syndrome (NIPHS). Several recent reports describing this syndrome are shown in Table 5. Typical findings on immunohistochemistry are shown in Figure 6 and 7. This syndrome is likely to become more common with the increasing number of patients undergoing bariatric surgery.

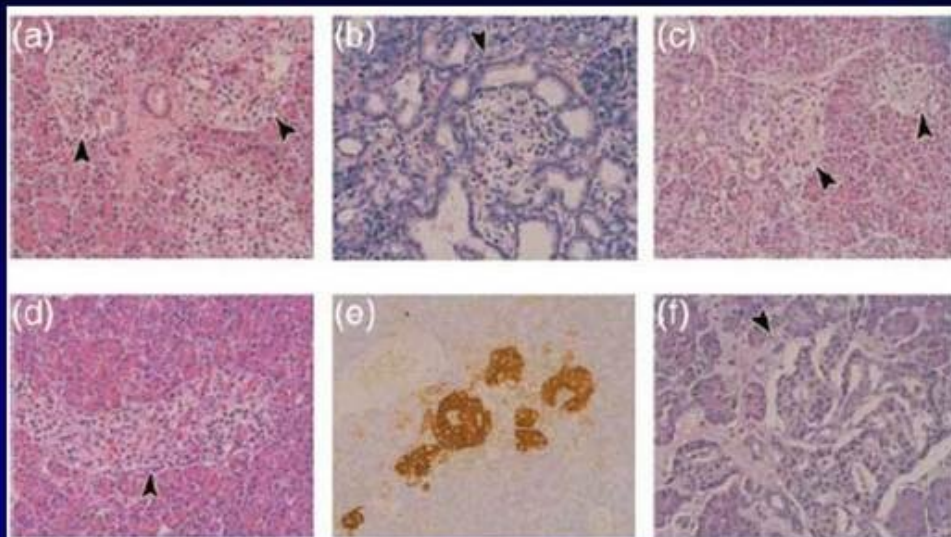
### **Non Insulinoma Pancreatogenous Hypoglycemia Syndrome (NIPHS)**

- **Service**
  - **Six cases developed postprandial hypoglycemia after Roux en Y gastric bypass surgery**
- **Patti**
  - **3 cases developed postprandial hypoglycemia after Roux en Y gastric bypass surgery**
- **Won, Pittenger, Vinik et al**
  - **10 sporadic cases of postprandial hypoglycemia, 5 after Roux e, 5 after Roux en Y procedure**

**Symptoms: Flushing, sweating, palpitations, tingling, confusion even coma.**

*Table 5. Non Insulinoma Pancreatogenous Hypoglycemic Syndrome (NIPHS).*

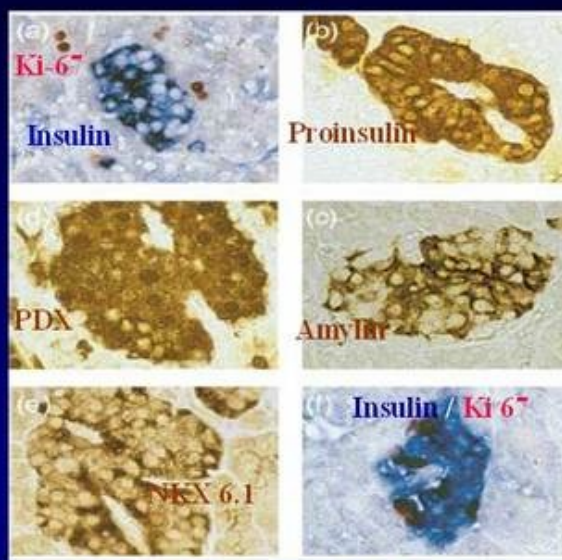
## Clusters of Islets of Varying shape and Size and Formation of the Ductulo-Insular Complex



Won, Pittenger, Vinik et al Clinical Endocrinology: 65; 566-578, 2006:

Figure 6 Immunohistochemistry of Islets in NIPHS (2).

## Immunohistochemistry of Pancreases in NIPHS Syndrome



Won, Pittenger, Vinik et al Clinical Endocrinology: 65; 566-578 2006:

Figure 7

Immunohistochemistry of Islets in NIPHS demonstrating presence of Insulin, Pro-Insulin, Amylin plus transcription

factors PDX, NKX 6.1 as well as cell proliferation factor Ki-67 (2).

Flushing in carcinoid syndrome has been ascribed to prostaglandins, kinins, and serotonin (5-HT). With the advent of sophisticated radioimmunoassay methods and region-specific antisera, a number of neurohumors now are thought to be secreted by carcinoid tumors, including serotonin, (37) dopamine, (45) histamine, and 5-HIAA, (44) kallikrein, (40) SP, (39) neurotensin, (48) motilin, (41) (48) SRIF, (169) VIP, (53) prostaglandins, (54) neuropeptide K, (46) and gastrin-releasing peptide (GRP) (48).

Feldman and O'Dorisio have previously reported the incidence of elevated levels of plasma neuropeptide concentrations (48). Despite the elevated basal concentrations of SP and neurotensin, these authors were able to document further increases in these neuropeptides during ethanol-induced facial flushing. We support this contention and hasten to add that neuropeptide abnormalities frequently occur in patients with other forms of flushing and may be of pathogenetic significance (55).

Several provocative tests have been developed for to identify the cause of flushing in carcinoid syndrome (Table 4). These tests are based upon the need to distinguish the flushing from that found in a host of other conditions particularly in panic syndrome in which the associate anxiety and phobias usually establish the cause but frequently the physician and patient need reassurance that there is no underlying malignancy. The treatment of the various causes of flushing are summarized in Table 6.

Ahlman and colleagues (56) reported the results of pentagastrin (PG) provocation in 16 patients with midgut carcinoid tumors and hepatic metastases. All patients tested had elevated urinary 5-HIAA levels, and 12 had profuse diarrhea requiring medication. PG uniformly induced facial flushing and GI symptoms in patients with liver metastases, but it had no effect in healthy control patients. All patients with PG-induced GI symptoms demonstrated elevated serotonin levels in peripheral blood. Administration of a serotonin-receptor antagonist had no effect on serotonin release but completely aborted the GI symptoms. The authors emphasized the improved reliability of PG compared with calcium infusion, another provocative test popularized by Kaplan and colleagues, (57) and pointed out that PG provocation occasionally can be falsely negative in patients with subclinical disease. Our own experience is that PG uniformly induced flushing in 11 patients with gastric carcinoid tumors that was associated with a rise in circulating levels of SP in 80% (27). Thus, SP is one neurohumor that may be involved in the flushing of carcinoid syndrome.

### Treatment of Flushing Syndromes

Flushing Syndrome	Treatment
Carcinoid	Octreotide
Medullary carcinoma thyroid	Thyroid tumor removal
Pheochromocytoma	Surgical removal, a1 and b blockers
Diabetic Neuropathy	Scopolamine, Botox
Menopause	Estrogen, clonidine
Epilepsy	Antiepileptic drugs
Panic syndrome	Alprazolam, sertraline
Mastocytosis	Histamine 1 and 2 blockers
Hypomastia	Beta Blockers
Idiopathic	Octreotide

**Table 6.**

## Diarrhea

The diarrhea syndrome that occurs with carcinoid tumors usually is of a secretory nature (Table 7). In fact all endocrine diarrheas are secretory in nature. In the absence of this feature the usual cause is gastroenterological. Secretory diarrhea that persists with fasting or fails to disappear when feeding has been curtailed and sustenance given by the intravenous route.

### Character of Secretory and Osmotic Diarrhea

- **Secretory**
  - **Large volume stools**
  - **Persists during fasting**
  - **$2X [Na^+ + K^+] = \text{stool osmolality}$**
- **Osmotic**
  - **Small volume <11 liter/d**
  - **Disappears with fasting**
  - **$2X[Na^+ + K^+] < \text{stool osmolality}$  i.e. osmotic gap.  
Search for idiogenic osmoles**

### Table 7.

Causes of secretory diarrhea include the WDHHA syndrome, medullary carcinoma of the thyroid, and gastrinoma syndrome. A history of improvement in the diarrhea with administration of  $H_2$ -receptor antagonists is strongly suggestive of the gastrinoma syndrome. Hypercalcemia is frequent with VIP-secreting tumors and steatorrhea and, for all intents and purposes, occurs only with the Zollinger-Ellison syndrome. Figure 8 illustrates the essential differences in the mechanisms involved in generation of diarrhea that occurs in the VIPoma, PPoma, Medullary Carcinoma of the thyroid tumors and the Zollinger Ellison (Gastrinoma) syndrome. In essence the humors that stimulate gastrointestinal secretions such as VIP increase the rate of fluid delivery from the proximal to the distal small intestine that exceed the absorptive capacity of the distal intestine. The diarrhea is watery in nature and there is great loss of bicarbonate and potassium ions. Hence, the term: Watery Diarrhea, Hypokalemia, Hypochlorhydria, Acidosis syndrome (WDHHA). This form of diarrhea persists with fasting and in the absence of a history to support this contention placing the patient on NPO while giving fluids IV rapidly establishes whether the diarrhea is secretory in nature or malabsorptive. In contrast the gastrinoma diarrhea is due to stimulation of gastric acid secretion by the tumor. Acid in the duodenum and small intestine inactivates lipase, amylase and trypsin, damages the mucosa of the small bowel precipitates the succus entericus thereby decreasing absorption of nutrients and impairing digestion leading to a secretory diarrhea with elements of malabsorption and or steatorrhea. Clinically this can be distinguished by asking what happens to the diarrhea with the use of a proton pump inhibitor or an  $H_2$  blocker. Also demonstration of the very acidic nature of gastric acid secretion can be helpful. Marked metabolic acidosis with bicarbonate wasting usually is only a characteristic of VIP-secreting tumors.

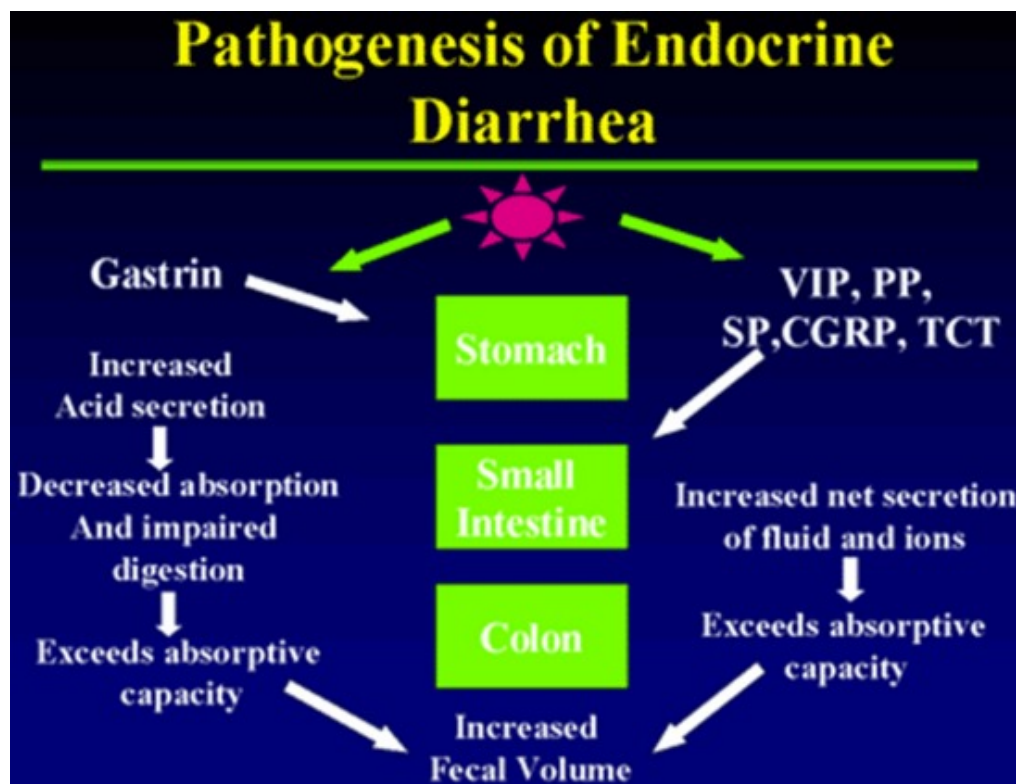
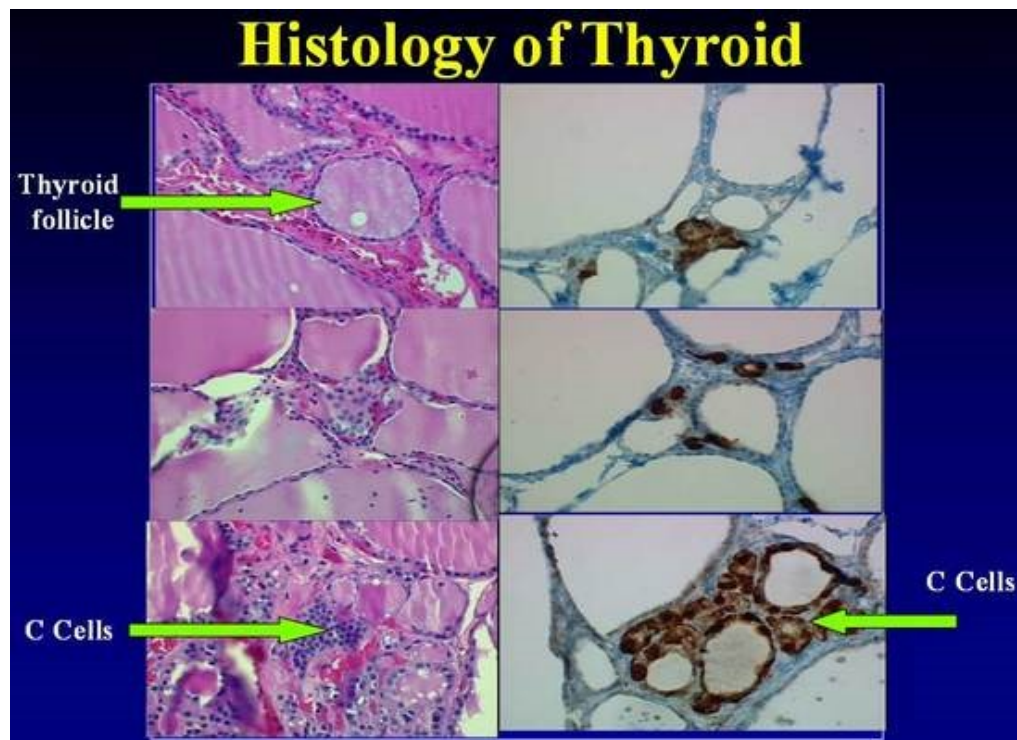


Figure 8.

The villous adenoma of the rectum causing secretory diarrhea is notoriously rare, and although it is referred to in many texts, most physicians have yet to see a case. Perhaps one of the most vexing problems is to exclude factitious diarrhea induced by for example laxative abuse. In this case measurement of stool osmolarity and electrolytes can be very revealing. An osmolar gap (i.e. there are osmoles not accounted for by the electrolytes) (Table 7) suggests the presence of laxatives which can then be readily identified in the stool using KOH. Measurement of intestinal secretion by passing a multilumen tube and quantifying electrolytes and water transport, in addition to the measurement of stool electrolytes, which should account for the total osmolarity, will also help to exclude laxative abuse.

### C-Cell Hyperplasia Syndrome

A recently described cause of secretory diarrhea is the C-cell Hyperplasia Syndrome, occurring in the absence of medullary thyroid cancer. Three cases of C-cell hyperplasia syndrome presented with longstanding flushing, abdominal pain, diarrhea and facial telangiectasia (2-20 years). The only biochemical abnormalities were elevated calcitonin levels and positive Pentagastrin and calcium stimulation tests. Venous sampling localized the overproduction to the thyroid. Histology of the thyroid showed C cell hyperplasia without evidence of medullary thyroid cancer. Symptoms improved to a large extent after subtotal thyroidectomy in one case and resolved in other two cases after total thyroidectomy. The condition may be a gene mutation but so far the site has not been identified. Ret Proto-oncogene evaluation came to be negative. All cases of flushing and diarrhea should have a calcitonin measurement. Total thyroidectomy is the treatment of choice for this syndrome. Histology of the thyroid of those cases can be seen with C cell hyperplasia shown by arrows in Figure 9.



**Figure 9. C**

cell staining with H&E and Immunohistochemical method. C cells are identified with difficulty in sections stained with hematoxylin and eosin, where they appear polygonal and with a granular weakly eosinophilic cytoplasm that is larger and paler than that of follicular cells. (Fig 1a,c,e) (See arrow). When compared with sections from the same patients using immunohistochemical staining, C cells as more readily identified part of the follicular epithelium and as isolated cluster between follicles.

## DIAGNOSIS

There are two ways that these patients are typically diagnosed. One way is in the asymptomatic patient who undergoes imaging or endoscopy for another reason and a lesion is incidentally discovered. The other way is in patients with long standing often vague gastrointestinal complaints that have eluded correct diagnosis for many years. A generalized evaluation scheme is shown in Table 8.

The diagnosis of carcinoid tumors in these patients is challenging. The diagnosis often rests on a strong clinical suspicion in patients who present with flushing, diarrhea, wheezing, myopathy, and right heart disease. Diagnosis requires appropriate biochemical studies (Table 9), localization studies, pathologic, and immunohistochemical studies.

### Evaluation of Neuroendocrine Tumors

#### Clinical Syndrome

**Flushing, diarrhea, wheezing Exclude other causes**

**Myopathy, right heart disease Secretory vs. non secretory**

**Hypoglycemia, ulcer, rash Wet vs. dry**

**Biochemical and Carcinoma, thyrotox, Cushing's**

**Tissue Diagnosis GBP, MCT, C cell hyperplasia**

**Urine: 5HT, 5HTP Negative Symptomatic**

**Blood: serotonin, TCT Treatment**

**Pancreastatin, CGA, NKA**

**Insulin, gastrin, glucagon IGF2, PThrp**

**ALK Phos, NTx etc**

**Tissue: CGA/Ki-67,**

**Synaptophysin, specific hormone**

## Table 8

### Biochemical Markers

The rate-limiting step in carcinoid tumors for the synthesis of serotonin is the conversion of tryptophan into 5-HTP, catalyzed by the enzyme tryptophan hydroxylase. In midgut tumors, 5-HTP is rapidly converted to 5-HT by the enzyme aromatic amino acid decarboxylase (dopa-decarboxylase). 5-HT is either stored in the neurosecretory granules or may be secreted directly into the vascular compartment. Most of the secreted 5-HT is taken up by platelets and stored in their secretory granules. The rest remains free in the plasma, and circulating 5-HT is then largely converted into the urinary metabolite 5-hydroxyindoleacetic acid (5-HIAA) by the enzyme monoamine oxidase and by aldehyde dehydrogenase. These enzymes are abundant in the kidney, and the urine typically contains large amounts of 5-HIAA.

Urinary 5-HIAA (24-hour collection) is a useful laboratory marker for carcinoid tumors. It is a surrogate measure of serotonin metabolism and is perhaps more useful than the direct measurement of serotonin as serum serotonin values vary considerably during the day according to activity and stress level. The specificity of this test has been reported to be 88% (58). However, certain foods and medications can increase urinary 5-HIAA levels and should be avoided during specimen collection (59). High serotonin concentrations occur with the ingestion of bananas, kiwis, pineapple, plantains, plums and tomatoes. Moderate elevations are found with avocado, black olives, spinach, broccoli, cauliflower, eggplant, cantaloupe, dates, figs, grapefruit and honeydew melon. Drugs that can increase 5-HIAA are: acetanilid, phenacetin, reserpine, glyceryl guaiacolate (found in many cough syrups) and methocarbamol. Drugs that can decrease 5-HIAA levels include: Chlorpromazine, Heparin, Imipramine, isoniazid, levodopa, MAOIs, methenamine, methyl dopa, phenothiazines, promethazine and tricyclic antidepressants. In addition foregut carcinoids do not produce 5-HIAA but rather only 5HTP, limiting the usefulness of these measures as a diagnostic or screening tool.

In patients with foregut tumors, the urine contains relatively little 5-HIAA but large amounts of 5-HTP. It is presumed that these tumors are deficient in dopa-decarboxylase, which therefore impairs the conversion of 5-HTP into 5-HT, leading to 5-HTP secretion into the vascular compartment. Some 5-HTP, however, is converted to 5-HT and 5-HIAA—thus, the modest increase in these metabolites. The normal range for 5-HIAA secretion is 2 to 8 mg per 24 hours, and the quantitation of serotonin and all of its metabolites usually permit the detection of 84% of patients with carcinoid tumors. No single measurement detects all cases of carcinoid syndrome, although the urine 5-HIAA appears to be the best screening procedure.

Several circulating tumor markers have been evaluated for the follow-up and management of NETs. However, isolated elevation of marker levels is generally not sufficient for diagnosis without tissue confirmation. An important characteristic of these markers is that they are not only secreted by functional tumors but also by those less well-differentiated NETs that do not secrete known hormones (60). The general principle of biomarker measurement is to identify a few biomarkers that are elevated in the particular patient in question and follow these over time.

The most important of these markers, chromogranin A (CgA) (60), is a 49-kDa acidic polypeptide that is present in the



secretory granules of neuroendocrine cells. Plasma CgA is elevated in 50% to 100% of patients with either functioning or nonfunctioning NETs (64). Elevated CgA levels may be associated with the primary tumor (gastrinomas 100%, pheochromocytomas 89%, carcinoid tumors 80%, nonfunctioning tumors of the endocrine pancreas 69% and medullary thyroid carcinomas 50%). The sensitivities and specificities of CgA for the detection of NETs range between 70% and 100% (61),(62), (63),(64). CgA level may correlate with tumor volume or disease progression, but this should be interpreted carefully (65, 66). For example, small tumors may be associated with normal CgA levels. In addition, since somatostatin analogs affect blood levels of CgA, serial CgA levels should be measured at approximately the same interval from injection of long-acting somatostatin analogs. Stridsberg et al 2007 reported common conditions that can spuriously increase the levels of this marker and give false positive measurements including: decreased renal function and treatment with proton pump inhibitors (65) liver failure, chronic gastritis, and even essential hypertension (66); these problems are not seen with Chromogranin B (CgB), with complementary measurement so proposed (65). Some of the “pearls” and “pitfalls” on the use of CgA are shown in Table 9.

Sensitivity and specificity of CgA depends on many factors. For example, sensitivity varies from 77.8 to 84% and specificity from 71.3 to 85.3% depending on the assay used, and of great importance is to establish the cutoff value that gives the highest sensitivity without compromising the specificity (67). Another utility of CgA is to discriminate between patients with or without metastasis, which also depends on the assay and the cut-off values used, with a sensitivity of 57-63.3% and specificity 55.6-71.4% (67).. The concentration of CGA in plasma is thought to reflect the neuroendocrine differentiation of the tumor, the total tumor burden and to be useful as a means of measuring response to treatment. Using nude mice with engrafted human ileal carcinoid tumors (68) a direct correlation between tumor weight and CGA levels was found. Octreotide treated animals had a significant reduction in plasma levels indicating that CGA does correspond with tumor burden and may be useful for monitoring the course of the disease but unfortunately the study did not define the action of Octreotide on secretion versus change in tumor bulk. To determine the usefulness of CGA for diagnosis and follow up of neuroendocrine tumors Nehar et al (63). Measured CGA levels using an immunoradiometric assay in 124 sporadic neuroendocrine tumors, 34 MEN-1 and 127 controls. Serial measurements were done in 56 patients (212 visits). In secretory tumors the sensitivity was 62.9% with specificity of 98.4%. It was higher in secreting vs. non secreting tumors (73 vs. 45%) and related to the extent of metastases. In non secreting tumors the positive predictive value (PPV) for the presence of metastases was 100% but the negative predictive value was only 50%. In MEN-1 a high value predicted the presence of a pancreatic tumor with 100% specificity but the sensitivity was only 59%. During follow up the concordance of tumor growth and CGA was 80%, indeed better than serotonin (81 vs. 54%). Thus due to its high specificity, CGA determination may help to discriminate the endocrine character of a neuroendocrine tumor and to establish a pancreatic tumor in MEN-1 syndrome. Serial measurements are also useful for following responses to treatment. Figure 10 shows the percent positivity of CGA vs. 5 HIAA in the different carcinoids. CGA is positive 80-100% of the time in fore-mid and hind-gut tumors whereas 5HIAA detects a little over 70% of midgut tumors, only 30% of foregut and fails to recognize the presence of a hindgut carcinoid tumor.

The “Pearls” and “Pitfalls” on the use of CgA are shown in Table 10.

Another useful blood marker, neuron specific enolase (NSE), is a dimer of the glycolytic enzyme enolase. NSE is mainly present in the cytoplasmic compartment of cells of neuronal and neuroectodermal origin. The serum level of NSE is thought to be unrelated to the secretory activity of the tumor (64). NSE has been found in thyroid and prostatic carcinomas, neuroblastomas, small-cell lung carcinoma, carcinoids, GEP NETs and pheochromocytomas. Despite its high sensitivity (100%), its use is limited as a blood biochemical marker for neuroendocrine tumors due to its very low specificity (32.9%) (64). Although it is less specific than CGA, it maybe a useful marker for follow-up of patients with known diagnosis of NETs.

A variety of other secreted molecules can be measured among patients with midgut NETs. These include other chromogranins such as chromogranin B and C, pancreastatin, neuropeptide K, pancreatic polypeptide (PP), and substance P (SP). These substances are stored in neurosecretory vesicles together with CgA (59).

**Table 9. Specific Biochemical Markers for each Carcinoid Tumor Type (69)**

now

Site	Tumor Type	Marker	Specificity
<b>All</b>		CgA and B PP, NSE, Neurokinin, Neurotensin HCG $\alpha$ and $\beta$	High Intermediate Low
<b>Thymus</b>	Foregut Carcinoid	ACTH	Intermediate
<b>Bronchus</b>	Foregut Carcinoid, Small Cell Lung Carcinoma.	ACTH, ADH, Serotonin, 5-HIAA, Histamine, GRP, GHRH, VIP, PTHrp	Intermediate Low
<b>Stomach</b>	Foregut Carcinoid, Gastrinoma, Ghrelinoma.	Histamine, Gastrin Ghrelin	Intermediate Low
<b>Pancreas</b>	Gastrinoma, Insulinoma, Glucagonoma, Somatostatinoma, PPoma, VIPoma.	Gastrin, Insulin, Proinsulin, Glucagon, Somatostatin C-peptide, Neurotensin, VIP, PTHrp, Calcitonin	High Low
<b>Duodenum</b>	Gastrinoma, Somatostatinoma.	Somatostatin, Gastrin	High
<b>Ileum</b>	Midgut Carcinoid	Serotonin, 5-HIAA Neurokinin A, Neuropeptide K, Substance P	High Intermediate
<b>Colon and Rectum</b>	Hindgut Carcinoid	Peptide YY, Somatostatin	Intermediate
<b>Bone</b>	Metastasis	Bone Alkaline Phosphatase, N-Telopeptide PTHrp	High (blastic lesions), Modest (lytic lesions) Intermediate
<b>Cardiac Involvement</b>	Carcinoid	BNP	Intermediate

**Table 9:** Shows the specific biochemical markers used for each tumor and their specificity. CgA and B: Chromogranin A and B; PP: pancreatic polypeptide; NSE: neuron-specific Enolase; HCG: human chorionic gonadotropin; ACTH: adrenocorticotrophic hormone; ADH: anti diuretic hormone; 5-HIAA: 5 hydroxyindoleacetic acid; GRP: gastrin releasing peptide; GHRH: growth hormone releasing hormone; VIP: vasointestinal peptide; PTHrp: parathyroid hormone related peptide; BNP: brain natriuretic peptide.

Pancreatic Polypeptide (PP) is considered another non-specific biochemical marker. In a study conducted by Panzuto et al. in Rome, Italy in 2004, PP sensitivity was 54% in functioning tumors, 57% in non-functioning, 63% in pancreatic tumors and 53% in gastrointestinal tumors. Specificity was 81% compared with disease free patients, and 67% compared to non-endocrine tumors' patients. But when combined with CgA the sensitivity increased compared to either of the markers alone. When used in combination, the sensitivity of these markers is: for gastro-entero-pancreatic neuroendocrine tumors (GEP NETs) 96%; for non-functioning tumors 95% and for pancreatic tumors 94% (70).

The combined use of CGA and PP may further enhance sensitivity. Both markers were measured in 68 patients, 28

functioning and 40 nonfunctioning tumors. CGA sensitivity was 96% in functioning tumors, 75% in non functioning, and 74% in pancreatic and 91 % in gastrointestinal tumors. Specificity was 89%. In contrast PP sensitivity for these tumors was approximately 50% but combining the two markers increased sensitivity for all tumors to >95%. More specifically the gain in pancreatic tumors was 93% vs. 68% using the one marker alone. It seems not unreasonable to recommend using both markers under these circumstances. There are however always caveats. Pelckmans and colleagues (71) examined the possibility that gastric parietal cell antibodies, which neutralize acid secretion, thereby unbridling the G cell to produce gastrin, which in turn is trophic to the gastric ECL cell, which can transform into the gastric carcinoid. Measurement of gastrin and CGA, but not NSE and 5HIAA is a means of evaluating the ECL mass. This is particularly useful in decision making with regard to doing an antrectomy or simply following conservatively and removing the carcinoid polyps as they arise. Of course this raises the issue of whether or not the reported elevations in CGA in people taking proton pump inhibitors are truly false positive or reflect ECL hyperplasia! Nonetheless all evidence point to the combined measurement of CGA, PP and gastrin as being a very effective means of discovering a neuroendocrine tumor, identifying its probable site of origin and monitoring response to intervention.

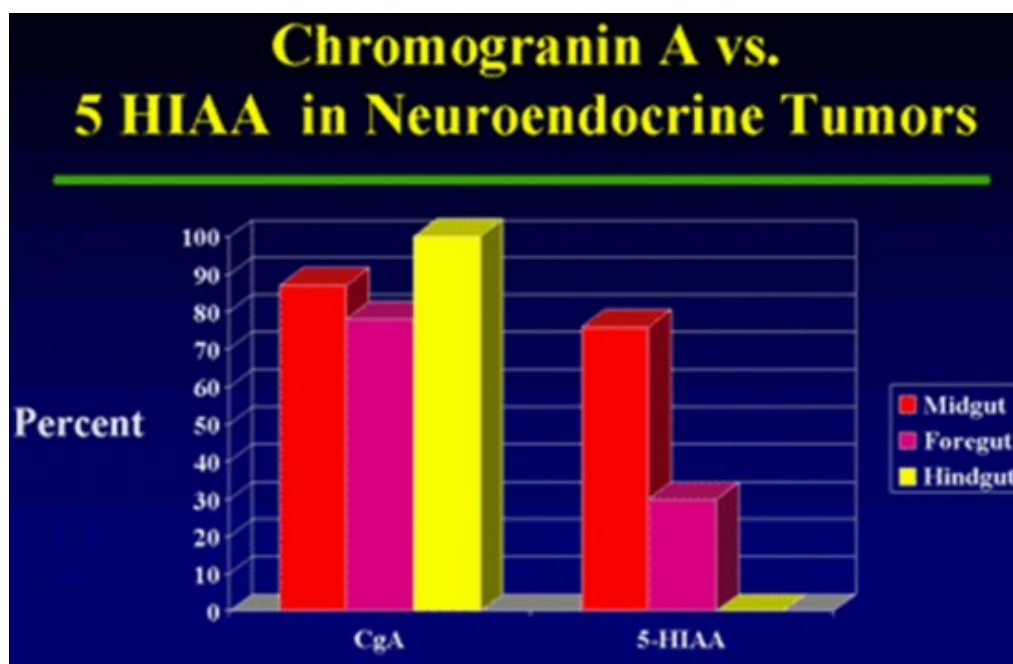


Figure 10.

#### “Pearls” and “Pitfalls” on Chromogranin A (CgA)

- Try and stay with the same lab
  - Very different levels e.g. <30 ng/ml-<5pmol/L
- Is very helpful when you know you have a N/E tumor
- May be elevated when there is no actual N/E tumor
  - Severe hypertension
  - Gastric acid suppression (PPI's)
  - Renal insufficiency

- May be a good marker of response to therapy
- Does not correlate with Symptoms
- Woltering, Vinik et al. *Pancreas*, 2006 Oct; 33(3):250-4

**Table 10. Pearls and Pitfalls on Chromogranin A (CgA) (3)**

In carcinoid tumors, neurotensin is elevated in 43%, SP in 32%, motilin in 14%, somatostatin in 5%, and VIP rarely. In miscellaneous illnesses, there may be elevation of the following hormones: neurotensin, SP, and motilin in 35, 7, and 5%, respectively. Up to one-third of people with idiopathic flushing who do not have carcinoid syndrome, however, have elevated levels of a number of neuropeptides. Furthermore, we have examined the relationship between the products of the preprotachykinin gene, SP, and neurokinin A in healthy subjects and in patients with carcinoid tumors. SP was elevated 80% of the time in patients with carcinoid tumors, whereas neurokinin A was raised in all patients. Why there should be a discrepancy in these two peptides that derive from a common precursor gene product remains unclear. Measurement of circulating levels enhances the ability to identify more patients with carcinoid tumors.

**Table 11 . Value of measurement of Neurokinin A (1).**

**Neurokinin A (NKA)**

- **Developed highly sensitive and specific radioimmunoassay**
- **Found very high levels of NKA-Like activity in tumor tissue from four patients with mid-gut carcinoids**
  - Regul Pept. 1986 Jan; 13(2):183-96
- **Patients in whom NKA levels continue to rise despite treatment with somatostatin analogs have poorer prognosis**
  - (1y survival 40% vs. 87%)
    - Turner et al. *Gut*. 2006 Nov; 55(11):1586-91

**Conclusion:**

NKA should be considered another of the substances secreted by mid-gut carcinoid (serotonin, substance P, calcitonin) and is an important marker for prognosis

Substance P has been found in tumor extracts and plasma from patients with carcinoid tumors and, in one reported case, was useful for tumor localization (34). Neurokinin A, its amino-terminally extended form, neuropeptide K, and SP are a group of peptides (i.e., tachykinins) with common biologic properties (72) (73). Norheim and colleagues (73) measured peptide responses to PG or ingestion of food or alcohol in 16 patients with metastatic carcinoid tumors and demonstrated two-fold or greater increases in neurokinin A and neuropeptide K in 75% of patients, as well as variable increases in SP in approximately 20% of patients (74). Additional information on neurokinin A is shown in Table 11.

Conlon and colleagues (72) used region-specific antisera to SP and neurokinin A to measure circulating tachykinins during a meal-induced flush in 10 patients with metastatic carcinoid tumors. Five patients had undetectable levels of neurokinin A and SP after stimulation, thus suggesting that elevated tachykinin concentrations are not a constant feature of such patients. The authors also studied the effect of a somatostatin-analogue administration on meal-induced

tachykinin responses in three patients with carcinoid tumors. Flushing was aborted in two patients, but tachykinin levels were only partially suppressed, indicating that these peptides cannot be solely responsible for the carcinoid flush.

**PATHOLOGY**

Neuroendocrine tumors (NETs) arising throughout the body share basic characteristics. They are classified according to site, differentiation (well vs. poorly differentiated), a marker of cell proliferation e.g. Ki-67, grade and stage, the hormones or amines produced, and markers of behavior such as chromogranin A and synaptophysin (Table 2). Tumor differentiation refers to the extent of resemblance to the normal cellular counterpart or loss of this resemblance. Tumor grade refers to the degree of biological aggressiveness. Tumor stage refers to the extent of spread of the tumor. The extent of invasion into the organ of origin and involvement of nodes or distant sites are critical factors. There are a number of different systems to classify, grade, and stage neuroendocrine tumors (Table 12, 13). Although the criteria differ among systems, the underlying basic data are similar. A review of nomenclature, grading, and staging system has been summarized in previous articles on the pathologic classification of neuroendocrine tumors adapted by the development of the NANETS, ENETS, and WHO Consensus Guidelines.

Site	Well-differentiated endocrine tumor (Benign behavior)	Well differentiated endocrine tumor (Uncertain behavior)	Well differentiated endocrine carcinoma (Low grade malignant)	Poorly differentiated endocrine carcinoma (High grade malignant)
Pancreas	Confined to pancreas <2 cm	Confined to pancreas >2 cm	Well to moderately differentiated	Small cell carcinoma and necrosis common
	<2 mitosis per HPF	> 2 mitosis per HPF	Gross local invasion and metastasis, 2-10 mitosis per HPF	<10 mitosis per HPF
	<2% Ki67 index; No vascular invasion	>2% Ki67 index or vascular invasion	>5% Ki67 index	>15% Ki67 index. Prominent vascular and/or perineural invasion
Stomach	Confined to mucosa-submucosa <1 cm; No vascular invasion	Confined to mucosa-submucosa >1 cm or vascular invasion	Well to moderately differentiated. Invasion to muscularis propia or beyond or metastasis	Small cell carcinoma
Duodenum, upper Jejunum	Confined to mucosa-submucosa <1 cm. No vascular invasion	Confined to mucosa-submucosa >1 cm or vascular invasion	Well to moderately differentiated. Invasion to muscularis propia or beyond or metastasis	Small cell carcinoma
Ileum, colon, rectum	Confined to mucosa-submucosa <1 cm (small intestine)	Confined to mucosa-submucosa >1 cm (small intestine)	Well to moderately differentiated. Invasion to muscularis propia or beyond or metastasis	Small cells carcinoma
	Confined to mucosa-submucosa <2 cm (large intestine)	Confined to mucosa-submucosa >2 cm (large intestine)		

	No vascular invasion	Vascular invasion		
Appendix	Non-functioning; Confined to appendiceal wall	Enteroglucagon producing. Confined to subserosa	Well to moderately differentiated. Invasion to meso appendix or beyond or metastasis	Small cell carcinoma

HPF - high power field

**Table 12.** WHO Classification of Gastroenteropancreatic tumors.

In addition to classic NETs, mixed histology tumors having neuroendocrine as well as glandular features, such as goblet cell carcinoids and adenocarcinoids, also occur. Mixed histology tumors are more frequent in the appendix and cecum. For example, mixed histology tumors accounts for 1% of jejunal/ileal NETs and 7.3% of cecal NETs ( $P < 0.001$ ) (75). While the number or fraction of appendiceal NETs having mixed histology tumors in the SEER registry is even higher, the exact percentage is difficult to ascertain. This is due to the fact that small appendiceal carcinoids are often considered benign and not reported to the registries, and mixed histology tumors such as goblet cell carcinoids are generally considered malignant and more likely to be reported.

Similarly, the distribution of poorly differentiated NETs among midgut sites is variable. Poorly differentiated NETs accounts for only 0.9% and 1.1% of appendiceal and jejunal/ileal NETs respectively. They however account for 14.2% of NETs arising from the cecum (75).

These pathologic descriptors provide important information for patient management as mixed histology tumors such as goblet cell can be more aggressive and prone to peritoneal dissemination. Poorly differentiated NETs are often rapidly progressive and may require cytotoxic chemotherapy.

In 2007, The European Neuroendocrine Tumor Society (ENETS) proposed a formal TNM staging system for tumors of the lower jejunum and ileum (Table 14), a system that was subsequently adopted by American Joint Committee on Cancer (76) (77).

**Table 13.**

#### Pathological classification of neuroendocrine tumors

Differentiation	Grade	Criteria
Well differentiated	Low (Typical)	<2 mitoses/10 HPF and <2% Ki67 index
	Intermediate (Atypical)	2–20 mitoses/10 HPF or 3%–20% Ki67 index
Poorly differentiated	High	>20 mitoses/10 HPF or >20% Ki67 index

**Table 13.** Pathological classification of neuroendocrine tumors.

T1 Tumor invades lamina propria or submucosa and size one cm or less

T2 Tumor invades muscularis propria or size >one cm

T3 Tumor invades through the muscularis propria into the subserosa or into the nonperitonealized tissue

T4 Tumor invades the visceral peritoneum (serosa) or any other organs or structures

N0 No regional LN metastasis

N1 Regional LN metastasis

M0 No distant metastasis

M1 Distant metastasis

**Table 14.** *ENETS/AJCC TNM staging classification of small bowel NETs*

Stage T N M

I T1 N0 M0

IIA T2 N0 M0

IIB T3 N0 M0

IIIA T4 N0 M0

IIIB Any T N1 M0

IV Any T Any N M1

All carcinoid tumors should be stained for chromogranin A and synaptophysin (Table 15, Figure 11). While most agree that a mitotic rate or Ki-67 is necessary in specific cases, whether Ki-67 staining is needed in all cases remains hotly debated (Table 15). An experienced pathologist familiar with NETs will likely be able to determine the tumor's grade in the majority of resected specimens and a Ki-67 can be obtained as needed in difficult cases (Table 16). In small biopsy specimens, there may not be sufficient material to differentiate between grade 1 versus 2 neuroendocrine carcinomas with or without Ki-67.

**Table 15.**

### **Diagnosis of Neuroendocrine Tumors**

- **Immunohistochemistry**
- Chromogranin A
- Synaptophysin
- Ki 67
- Individual hormones

- Insulin, glucagon, somatostatin, PP, INGAP, etc.

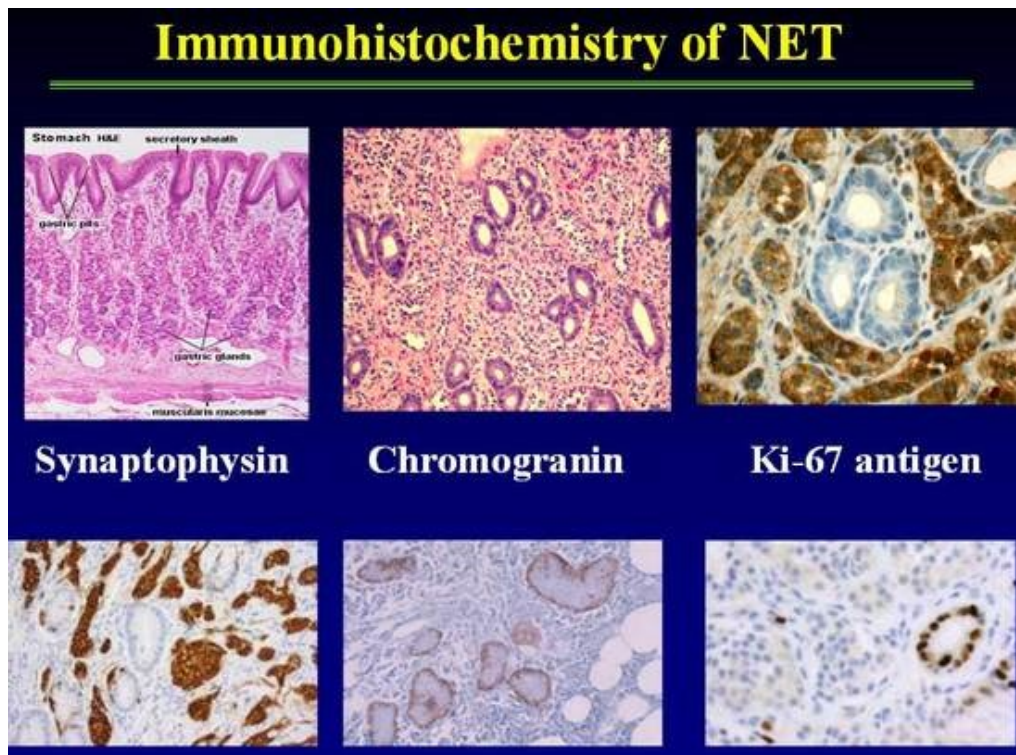


Figure 11. Immunohistochemistry of gastric mucosa with Synaptophysin, Chromogranin and Ki-67 antigen in a gastric neuroendocrine tumor.

- **Somatostatin Receptors and Subtypes**

**Table 16.**

Ki67 Tissue Staining

Considered a cellular proliferation marker

- A High molecular weight nuclear protein, associated with cellular proliferation
- Proliferation index refers to percentage (%) of cells (+) in a tumor section

**Table 16 (continued)**

**Ki67 (continued)**

**Index proposal by The World Health Organization (WHO)**

Well-differentiated carcinoid

- - <2% Ki-67 (+)
  - Well-differentiated endocrine carcinoma
    - 2-15% Ki-67 (+) (“malignant carcinoid”)
    - Well-differentiated endocrine ca
      - >15% Ki-67 (+) (“small cell carcinoma”)



Positive:

- May assist in planning therapy (high index may justify more

Aggressive therapy)

A Chaudry, K. Oberg, E. Wilander, Tumor Biol 1992 ; 13-27-35

Limitations:Ki67 staining % may vary from tumor slice to tumor slice (not standardized)

## LOCALIZATION STUDIES:

### General Overview:

A number of techniques have been used to identify the primary site of the tumor and to evaluate the extent of the disease and presence of metastases (Table 17 below). Chest radiography or computed tomography (CT) usually suffices to detect bronchial carcinoids. In contrast, carcinoids of the cecum, right colon, and hindgut carcinoids usually are demonstrable by endoscopy or barium enema examination. The greatest problems encountered are in localizing small bowel carcinoids, which may be small, and carcinoids in extra-intestinal sites. These tumors usually are not identified by upper endoscopy or GI roentgenographic studies. The ability of abdominal CT scans to detect midgut carcinoids has improved, however many primary tumors are below the resolution capacity of even the most sophisticated scanning apparatus. Capsule endoscopy and double balloon push-pull enteroscopy have occasionally been useful in cases of midgut based NETs. Endoscopic ultrasound (EUS) combined with biopsy is the most sensitive method to detect pancreatic NETS.

**Table 17 . Different modalities of localization of NET**

### Diagnosis of Neuroendocrine Tumors

- **Localization Procedures**
  - Ultrasound and Endoscopy
  - Barium contrast studies
  - CT
  - MRI
  - Octreoscan
  - PET (including Gallium DOTATOC scanning)
  - MIBG
  - Angiography
  - Venous sampling

The preliminary work-up of a neuroendocrine tumor often starts in the emergency department with plain abdominal X rays done to work up an abdominal pain syndrome. Any abnormal finding leads to CT scanning and the discovery of liver metastasis inevitably leads to CT guided liver biopsy. These tests are often used non-specifically because of the presence of vague symptom complexes. Once the NET diagnosis is suspected, more specific means of imaging are

typically employed. For detecting the primary NET tumor, a multimodality approach is best and may include CT, MRI, somatostatin receptor scintigraphy (SRS), endoscopic ultrasound (EUS), endoscopy, and less commonly digital selective angiography or venous sampling. CT is probably superior for localizing the primary tumor, mesenteric invasion, and thoracic lesions, whereas gadolinium enhanced MRI may be superior in characterizing liver lesions. Technique is critical and meticulous attention to detail is necessary. While some investigators in Europe advocate the use of enteroclysis with CT imaging, this techniques is used less in the US.

### **Gastric Carcinoid Tumors**

Most gastric carcinoid tumors are directly visualized and diagnosed during endoscopy. For larger lesions, endoscopic ultrasound may be performed to assess whether the gastric carcinoid is invasive. This technique, when used with tattooing of the gastric lesion, offers the endoscopist the opportunity to observe the lesion in a serial fashion. This is highly valuable in the case of type I gastric carcinoids which rarely need a formal gastric resection. In patients with more aggressive gastric carcinoids such as type II and type III gastric carcinoids, EUS offers the endoscopist the opportunity to access nearby nodes as well as the depth of tumor invasion. Cross-sectional imaging with CT or MRI is recommended to assess for metastases in patients with type I or type II gastric carcinoids more than 2 cm in diameter, and in patients with type III gastric carcinoids in whom metastatic risk is a significant concern (30). The predominant site of distant metastatic spread in patients with gastric carcinoid tumors is the liver. Carcinoid liver metastases are often hypervascular, and may become isodense relative to the liver with the administration of intravenous contrast. CT scans should thus be performed both before and after the administration of intravenous contrast agents (78). Somatostatin receptor scintigraphy provides a second useful imaging modality for the detection of metastatic disease in patients with malignant gastric carcinoids (30),(78),(79).

### **Midgut NETS**

Imaging studies for NETs are generally done for initial staging and subsequent follow-up. Goals of initial staging include identification of primary tumor, assessment of extent of disease, and treatment planning. Subsequent follow-up imaging studies are done for surveillance following complete resection or during periods of stability, and evaluation of response following treatment.

Imaging studies generally recommended at time of initial staging includes plain film chest xray, cross-sectional imaging (CT or MRI) of the abdomen and pelvis, and [ $^{111}\text{In-DTPA}^0$ ] octreotide scintigraphy. In cases, where a midgut primary is suspected but not directly identified (for example a mesenteric mass in the ileal mesentery), small bowel series, enteroclysis, or multiphasic CT of abdomen and pelvis with thin section non-ionic oral contrast can be used to locate the primary tumor.

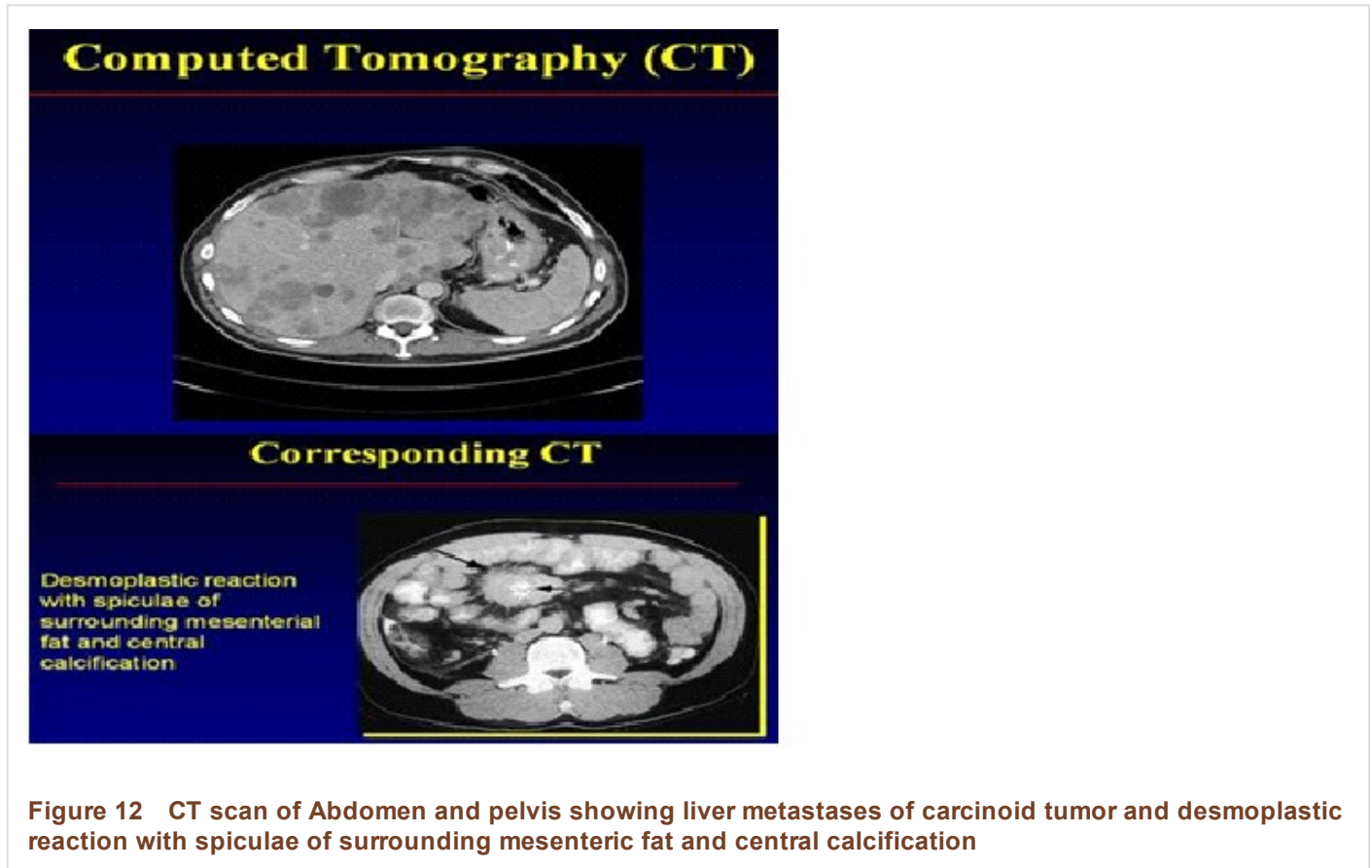
### **Techniques for cross-sectional imaging:**

#### **Computed Tomography (CT)**

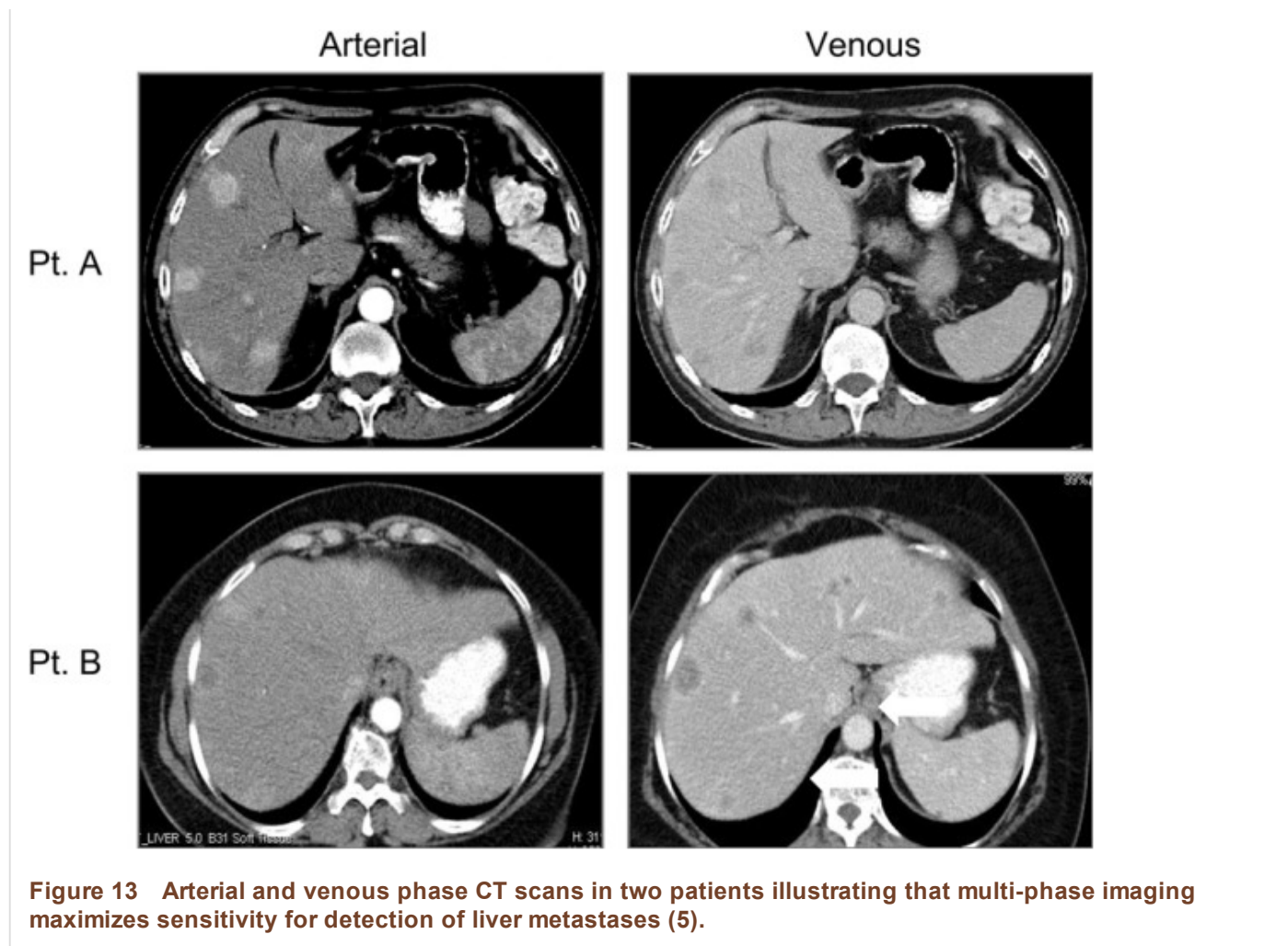
Multidetector CT has greatly improved the ability to diagnose midgut carcinoid tumors and is the primary diagnostic procedure for tumor staging. CT allows assessment of the extent of tumor spread to the mesentery and bowel wall as well as metastases to the lymph nodes and liver. The strengths of CT imaging for carcinoid are the wide field of view in the abdomen and pelvis and accuracy (80). When planning surgery, it is particularly helpful for determining carcinomatosis and the vascular relationship of mesenteric metastases - both major causes of morbidity and mortality. It is also useful in detecting liver metastases. CT remains the most useful roentgenographic method for localization of metastatic carcinoid tumors and evaluation of the response of metastatic carcinoid tumors to therapy.

NETs are generally vascular tumors that enhance intensely with intravenous contrast during early arterial phases of imaging with washout during the delayed portal venous phase. The key to detecting small NETs on CT is to maximize the contrast between the tumor and the adjacent normal parenchyma. For abdominal and pelvic imaging we recommend multiphasic CT that includes the arterial phase (beginning 25-30 seconds after the start of contrast injection) and the

portal venous phase (beginning approximately 60 seconds after the start of contrast injection). Rapid intravenous bolus of contrast at 4-5 cc per second is also recommended. Thin sectioning and the use of a non-ionic oral contrast agent also may be helpful in detecting small primary tumors in the small-bowel that may not otherwise be seen. The typical appearance of mesenteric invasion by carcinoid tumor on CT is a mesenteric mass with radiating linear densities representing thickened neurovascular bundles (Figure 12). Liver metastases appear as focal, hypodense lesions on non-enhanced CT scanning (81).



Metastatic NETs are particularly sensitive to the timing of the administration of the contrast used. When evaluating the liver, metastases are most visible on the arterial phase, difficult to visualize on the venous phase, and not visible on non-contrast phases (Figure 13). More importantly, the resolution of the borders of the carcinoid metastasis can be difficult for the radiologist to discern, making determination of progression inaccurate. It is also relatively insensitive in detecting small liver lesions. Also, given the relatively long survival of patients with carcinoid cancer, the repeated radiation exposure from frequent imaging can be a concern. Other modifications of CT, especially enterography, can be helpful in the evaluation of small intestine primary tumors (82). In the setting of emergent situations, such as small bowel obstruction, it still remains the exam of choice.



**Figure 13 Arterial and venous phase CT scans in two patients illustrating that multi-phase imaging maximizes sensitivity for detection of liver metastases (5).**

### Magnetic resonance imaging (MRI)

The wider availability of MRI and the development of new contrast agents have made MRI a powerful tool in the evaluation of NET. Like CT, the information from the MRI must be used in the context of the strengths and weaknesses of the test.

MRI is preferred over CT for patients with a history of allergy to iodine contrast material or for those with renal insufficiency. NETs can have variable appearances on non-contrast MRI. They can be hypo- or iso-intense on T1-weighted images. Metastases to the liver typically are usually high signal on T2 weighted images (83). Because T2-weighted images are obtained without intravenous contrast, they do not have the problems of variations in the timing of phases of contrast enhancement. T2 weighted imaging can be especially useful for patients unable to receive contrast. However, these metastases, especially when cystic or necrotic, can mimic the appearance of other T2 high signal intensity lesions, such as hemangiomas and occasionally cysts (84). Dynamic contrast enhanced imaging can provide additional information about the nature of the lesions, and may help to detect smaller lesions. We recommend T1-, T2-weighted imaging, and multiphasic (arterial, portal venous, and delayed) dynamic MRI for NETs (83) (85), which can improve the detection of small lesions not appreciated on CT.

Neuroendocrine metastases are uniquely vascular which makes evaluation of water motion by MRI highly sensitive. Moreover, with the introduction of hepatocyte specific contrast agents (e.g. gadoxetic acid or gadopentetic acid based gadolinium), NETs can be seen with great detail and measured accurately. This information is particularly important for patients potentially undergoing liver resection. While CT may only show disease in one area of the liver, bilobar disease detected on MRI may change the course of treatment. In one study of 64 patients with metastatic gastrointestinal NETs, MRI scans detected significantly more hepatic lesions than SRS or CT scans (86). Outside of the liver, the MRI is not

particularly strong in evaluating the small intestines or the mesentery because of movement artifact.

In summary, some have reported that MRI may be more sensitive than CT is for the detection of small liver metastases (87),(88) (86). However, CT may be better for the evaluation of extra hepatic disease including peritoneal and mesenteric disease. Whether CT or MRI is better overall for NETs will continue to be debated and may vary depending on the expertise of the local center. MRI needs further evaluation before it is used as primary modality for the diagnosis and staging of carcinoid tumor, (89) but, overall, it appears to have little advantage over CT.

### Ultrasound and Endoscopy

Ultrasonography is an excellent technique for NET, but its role in midgut carcinoid is more limited. In general, ultrasound liver guided biopsy of suspected metastases is the best use. Ultrasound is a common method of diagnosing the disease as the patient is undergoing an evaluation for abdominal pain and will have an abdominal ultrasound for biliary examination. It is also highly effective in evaluating liver lesions intra-operatively. Endoscopic ultrasound (EUS) with FNA biopsy is very useful for diagnosing pancreatic NETs. Echocardiography is very useful to detect carcinoid heart disease. In those patients with symptoms or elevated biological markers, evaluation of the right-sided heart valves is critical prior to initiating a treatment plan. Right heart failure can be difficult for the patient's quality of life as well as add significant morbidity to anyone being evaluated for surgery.

Endoscopy is a valuable diagnostic tool as well. Many of the tumors originate in the terminal ileum and can be seen on intubation of the small bowel with standard colonoscopy. However, small bowel enteroscopy and pill-cam endoscopy may be necessary to see lesions beyond the reach of the standard endoscope (90) (83). Upper endoscopy may identify gastric carcinoid tumors.

### Functional Imaging- Somatostatin Receptor Scintigraphy (SRS, Octreoscan)

The most sensitive imaging modality for detecting widespread metastatic disease in NET's is somatostatin receptor scintigraphy (SRS; OctreoScan<sup>®</sup>). Octreoscans are extremely useful in confirming the diagnosis and evaluating tumor distribution and burden.

Somatostatin receptors have been identified on most endocrine tumors, including carcinoid tumors, which generally express a high density of the receptors (Table 18). Five human somatostatin receptor subtypes have been cloned so far, and the binding affinity of octreotide may depend on the subtype(s) expressed (7).

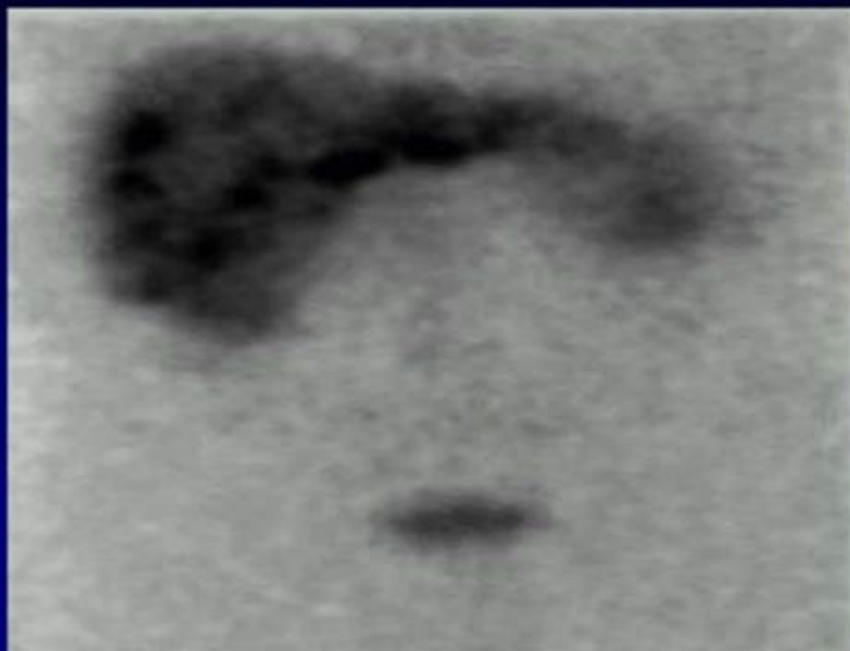	SSTR1	SSTR2	SSTR3	SSTR4	SSTR5
Normal Human Islets	+	+	-	+	-
Glucagonoma 1	+	+	+	+	-
Glucagonoma 2	+	+	+	+	-
Main tumor	+	+	+	+	-
Metastatic lymph node	+	+	+	+	-
Insulinoma 1	+	+	+	+	-
Insulinoma 2	+	+	-	+	-
Insulinoma 3	+	-	+	+	-
Insulinoma 4	+	+	-	-	-
Normal adrenal gland	+	+	-	-	-
Pheochromocytoma 1	+	+	-	-	-
Pheochromocytoma 2	+	+	-	-	-

Pheochromocytoma 3	+	+	-	-	-
Carcinoid	+	-	-	+	-

**Table 18.** Summary of the expression of the SSTR subtypes analyzed by Reverse transcription Polymerase Chain Reaction (RT-PCR) SSTR 2 are expressed in majority or neuroendocrine tumors and shows high binding affinity to somatostatin analogues. SSTR5 are rarely expressed by neuroendocrine tumors (7).

Tumors that express sst<sub>2</sub> or sst<sub>5</sub> can be visualized in vivo after injection of the radio-labeled compound (91). Several different imaging agents that bind to the receptors have been studied (92). I-Tyr3-octreotide was the agent initially used, but it has several disadvantages, including a short half-life, biliary excretion obscuring potential tumor sites, with liver accumulation and difficulties with conjugation. The most widely used analogue for scintigraphy is currently [<sup>111</sup>In-DTPA<sup>0</sup> octreotide, (Octreoscan, Tyco healthcare, Mallinckrodt, St Louis USA (93). This agent has a half-life of 3 days and renal excretion and has obviated many of these difficulties (Figure 14). Apart from this, In pentreotide [In-DOTA<sup>0</sup>] lanreotide can also be used (94) (95). SOM-230 is a new somatostatin analogue with potency to bind SSTR2, SSTR3 and SSTR5.

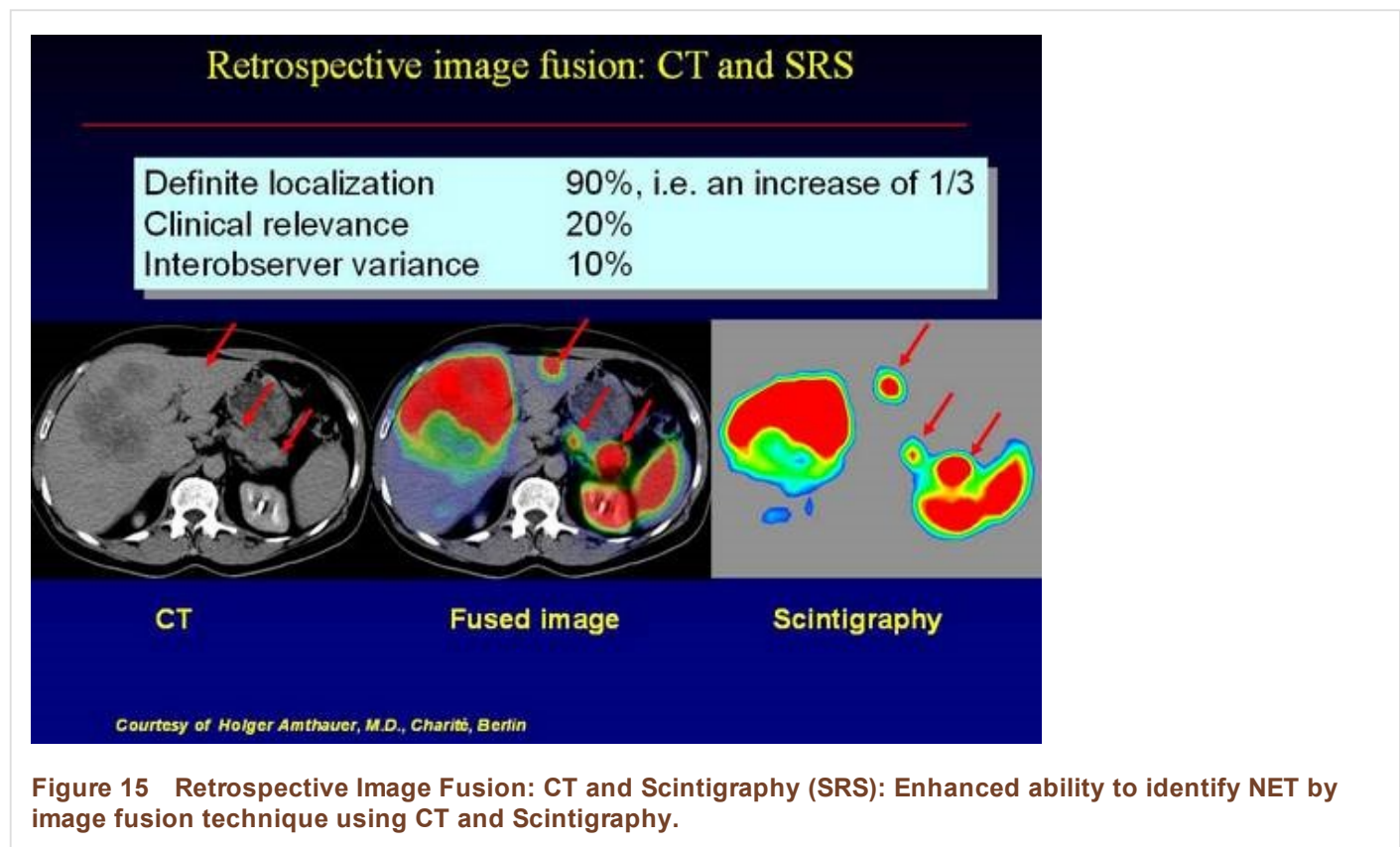
## Octreoscan in Malignant Metastatic Neuroendocrine Tumor



**Figure 14 Octreoscan**

Regardless of the peptide used, the tracer binds to tumors and full body imaging can be performed. In most centers single photo emission tomography (SPECT) imaging can be fused with CT to combine the functional information of the tumor with the cross-sectional imaging (Figure 15). The other strength of Octreoscan is that the whole body is usually imaged, so that distant metastases not normally in the field of view on CT or MRI can be detected (96). The overall

sensitivity of [ $^{111}\text{In}$ -DTPA $^{\text{U}}$ ]octreotide scintigraphy appears to be about 80% to 90% (91).

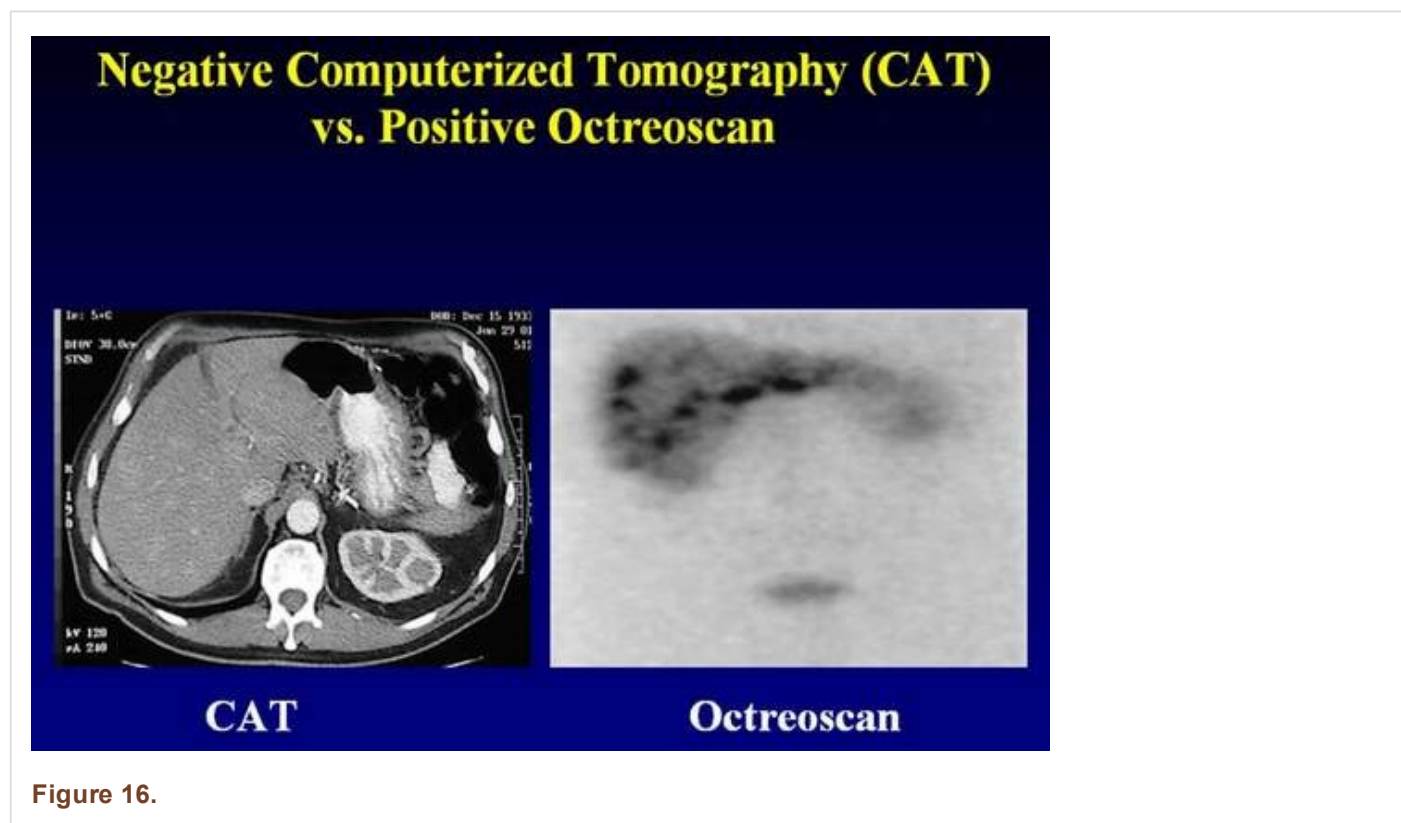


The efficacy of somatostatin receptor scintigraphy with [ $^{111}\text{In}$ ] In-DTPA octreotide was evaluated in a European Multicenter Trial (EMT) in 350 patients with a histologically or biochemically proven neuroendocrine GEP tumor (95). Tumor sites were detected by conventional imaging methods in 88%, whereas somatostatin receptor scintigraphy was positive in 80%. The highest success rates of somatostatin receptor scintigraphy were observed with glucagonomas (100%), Vipomas (88%), carcinoids (87%), and nonfunctioning islet cell tumors (82%). The low detection rate (46%) noted for insulinomas is related to the lower incidence of sst<sub>2</sub> somatostatin receptors on insulinoma cells. However, the overall 80% sensitivity found is somewhat lower than the 88% obtained by Krenning's group (73) in Rotterdam, who studied 130 patients with GEP tumors. This may be related to important differences in scanning procedures such as the amount of radioligand administered (minimal dose of In of 200 MBq and at least 10 mg of peptide by the Rotterdam group), the duration of the acquisition, and the use of single photon emission computed tomography (SPECT) (with a triple-head camera by (88)). The fact that abdominal SPECT was not systematically performed in all patients of the EMT may explain that only 73% of gastrinoma patients had a positive scan compared to the 90 to 100% sensitivity reported in other studies. In the EMT, a total of 388 sites were visualized with conventional imaging methods in 308 of the 350 patients. In addition to 297 known localizations, somatostatin receptor scintigraphy revealed another 166 unsuspected lesions. Forty percent of these unsuspected lesions were subsequently confirmed as true positive findings based on the results of additional imaging procedures or histology obtained during the 1-year follow-up period. The clinical relevance of detecting additional tumor localizations is very dependent on the clinical status of the patient. The demonstration of an unsuspected lesion in a patient with known metastatic spread usually has little impact on the management. In contrast, the detection of unsuspected tumor sites in patients with a single known lesion or without any known lesions is important in that it may affect patient selection for curative surgery, which remains the treatment of choice for patients with this type of tumor. In the cohort of 350 patients studied, 42 had no lesion detected by conventional imaging modalities (CIM) and 178 were known to have a single tumor localization prior to the study. Somatostatin receptor scintigraphy was positive in 11 of the 42 patients (25%), and 12 of 16 lesions revealed by somatostatin receptor scintigraphy were further confirmed as true positive. Somatostatin receptor scintigraphy

demonstrated multiple tumor sites in 62 of the 178 patients (35%); 60% of these lesions were confirmed by follow-up (1-year) procedures. A reply to an impact questionnaire was obtained for 235 patients. Overall, the scintigraphic findings led to management changes in 40% of the 235 patients. One center extended their number of patients and reported the results separately in more detail (97-99).

Knowledge of the fact that other processes can be somatostatin receptor positive is crucial for interpretation of these scintigrams (100). This has been re-emphasized recently by Gibril et al. (101). They report on the sensitivity of this technique and the importance of (1) having a thorough understanding of diseases or circumstances that result in false-positive localization and (2) including the clinical context at the time of reading and interpretation. Unjustified alteration in management can be reduced to below 3% of all  $^{111}\text{In}$ -DTPA octreotide scintigraphy studies in this way.

Shown in Figure 16 is an abdominal CT scan in a patient with a malignant metastatic neuroendocrine tumor producing predominantly pancreatic polypeptide. The tumor metastases are not evident in the CT scan, however they were clearly visible on Octreoscan. T2 weighted MRI images may also have revealed the tumors because of their vascular nature.



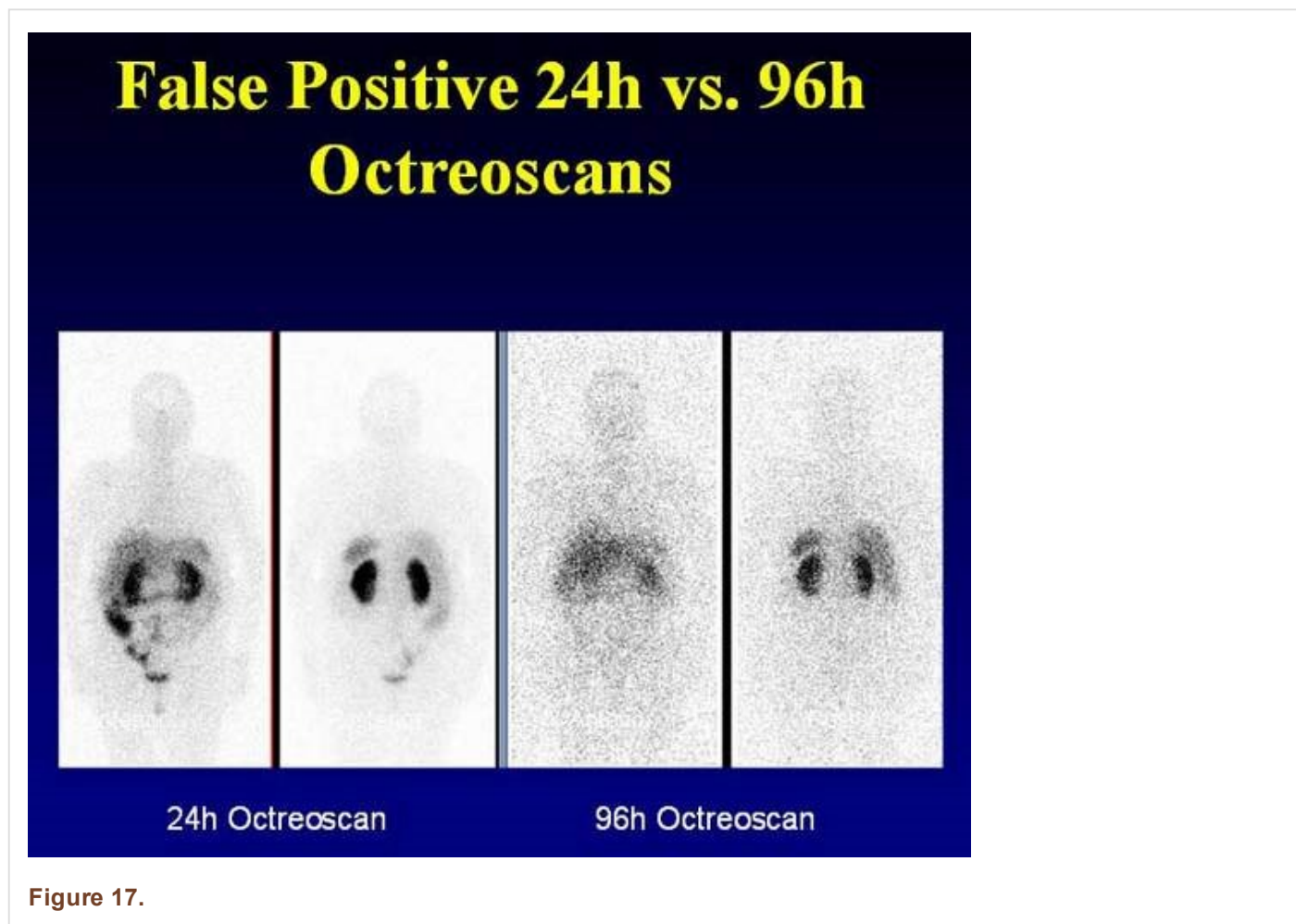
Thus, octreotide scintigraphy has benefit in identifying small primary tumors and liver metastases. This imaging technique is also valuable in identifying metastatic disease to extra-abdominal sites Figure 16 demonstrates the Octreoscan finding in a patient with malignant metastatic disease to the base of the brain, sternum, clavicles and ribs. This turns out to be helpful from at least two points of view. Firstly, the fact that the metastases take up the tracer suggest responsiveness to treatment with octreotide. Secondly, the recognition that there are bony metastases using octreotide tracer suggests treatment with bisphosphonates, which as in other malignancies involving bone appear to have a salutary effect on symptoms and may, although this has not been studied in detail, abrogate the rate of tumor growth in this site.

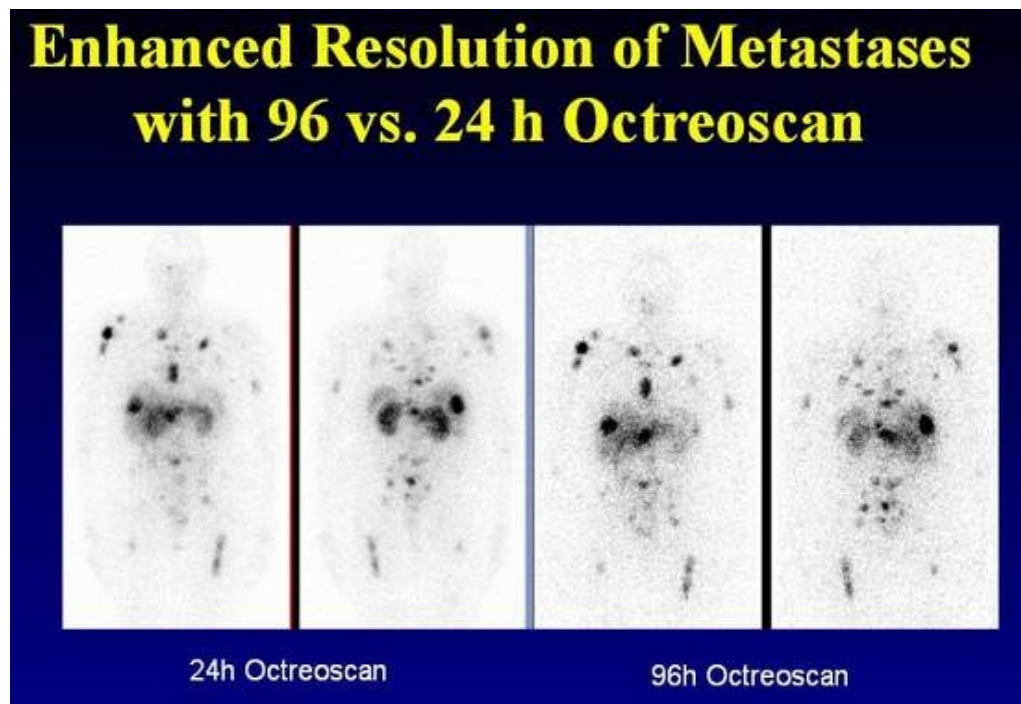
In addition to tumor imaging, octreotide scanning may be useful in predicting responses to octreotide. One recent study showed that 22 of 27 patients with carcinoid tumor and positive scans responded to octreotide, whereas all three patients with negative scans failed to respond (102). Other investigators have shown similar results (103).

Octreoscan is severely limited by two major aspects: the requirement that the tumor express SSTR and sensitivity. For



midgut carcinoid, up to 80% of tumors will express SSTR2, the receptor with the stronger binding affinity for the labelled ligand, and therefore be detectable. However, in some cases of carcinoid, if the primary tumor is already resected and a baseline octreoscan is not obtained, it may be difficult to know if the octreoscan is negative because there is no evidence of disease or if the tumor did not originally express SSTR. Also, because of the nature of SPECT, it is relatively insensitive for lesions < 1 cm. Also, physiological activity in the kidney, spleen, liver, and bowel can obscure the tumors and reduce sensitivity. The test itself is somewhat cumbersome for the patient requiring an initial intravenous injection of the tracer, a scan 4-6 hours and 96 hours later. At 4-6 hours, some lesions may be obscured by relatively high background activity; however, bowel activity is limited. Imaging at 96 hours provides better contrast due to lower background activity. However, there is often physiologic bowel activity that may produce false positive results. Shown in Figure 17 and 18 are the importance of delayed 96 hour imaging.





**Figure 18.**

[ $^{111}\text{In-DTPA}^0$ ]Octreotide scintigraphy can be performed for patients on long-acting Octreotide but is best performed 3-6 weeks after the last dose. While [ $^{111}\text{In-DTPA}^0$ ] octreotide scintigraphy can provide useful information about site of disease, it does not give information about size. Also, some agents such as interferon may up-regulate somatostatin receptors and thus can lead to increased uptake without disease progression.

### Functional Imaging – Positron Emission Tomography (PET)

PET with tracers based upon metabolic features (5 HTP) and receptor characteristics (DOTATOC) have shown promising results in a limited number of studies.

Conventional PET [ $^{18}\text{F}$ ]-fluorodeoxyglucose (FDG) imaging, while successful for many solid tumors, has not been helpful for NETs because of their generally lower proliferative activity.

Only tumors with high proliferative activity and dedifferentiation show FDG-PET uptake. Most patients who have been studied had classical midgut tumors and the carcinoid syndrome. PET has been shown to be capable of identifying midgut carcinoid tumors that have metastasized to a variety of sites, and it may be of value in monitoring the effects of treatment (104). The use of PET scanning in undifferentiated tumors or small cell like lesions of the bronchus or thymus is highly effective.

The next generation of functional imaging for neuroendocrine tumors utilizes a different imaging technology to evaluate these tumors. Positron emitters used in NETs include 11-carbon which has been used in most studies to date and the emerging new technology 68-gallium. Both tryptophan and 5-HTP have been used as tracer substances, but initial studies showed that only  $^{11}\text{C}$ -5-HTP was taken up in serotonin-producing tumors (105). While still binding to the SSTR, the PET technique offers greater sensitivity and resolution of images, especially for distant extra-abdominal metastases or difficult to locate abdominal lesions (106) (Figure 19). The technique is also simpler, requiring the patient to only wait approximately one hour prior to a single imaging session. 68-Ga-somatostatin analog imaging is currently being evaluated in clinical trials in the United States and is only available at a few specialty centers (Figure 20). Prior studies have shown  $^{11}\text{C}$ -5-HTP PET to be a promising imaging modality for the detection of NETs (107). The serotonin precursor 5-HTP labeled with  $^{11}\text{C}$  was used and showed an increased uptake and irreversible trapping of this

tracer in NETs (107). [ $^{11}\text{C}$ ]-5-HTP-PET proved better than somatostatin receptor scintigraphy for tumor visualization. However, the short half-life of  $^{11}\text{C}$  ( $t_{1/2}=20\text{min}$ ) makes it difficult to apply in clinical practice and is not available in the US.

s

## PET/CT with $^{11}\text{C}$ -5-HTP improves morphological accuracy

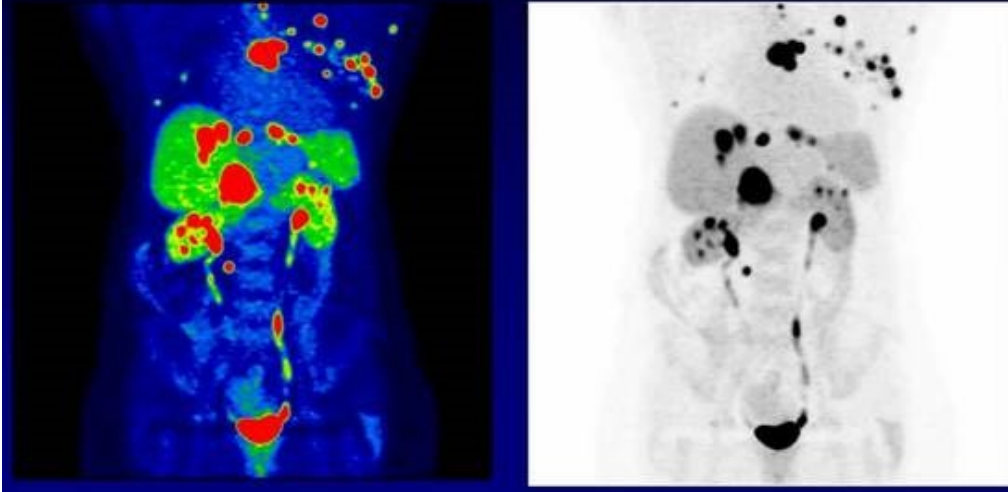
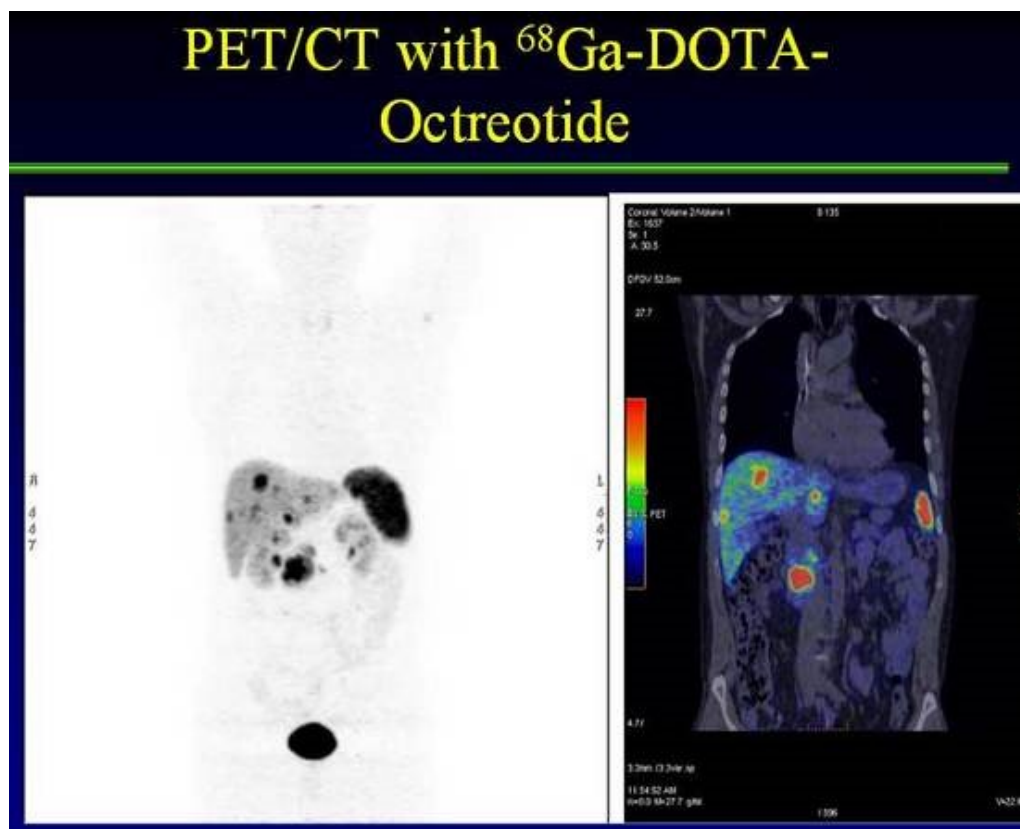


Figure 19 Fusion PET/CT scan of abdomen and pelvis showing metastases of carcinoid tumor to multiple sites including liver, sternum, ribs.



**Figure 20** Positron Emission Tomography (PET) Scan

### MIBG scanning

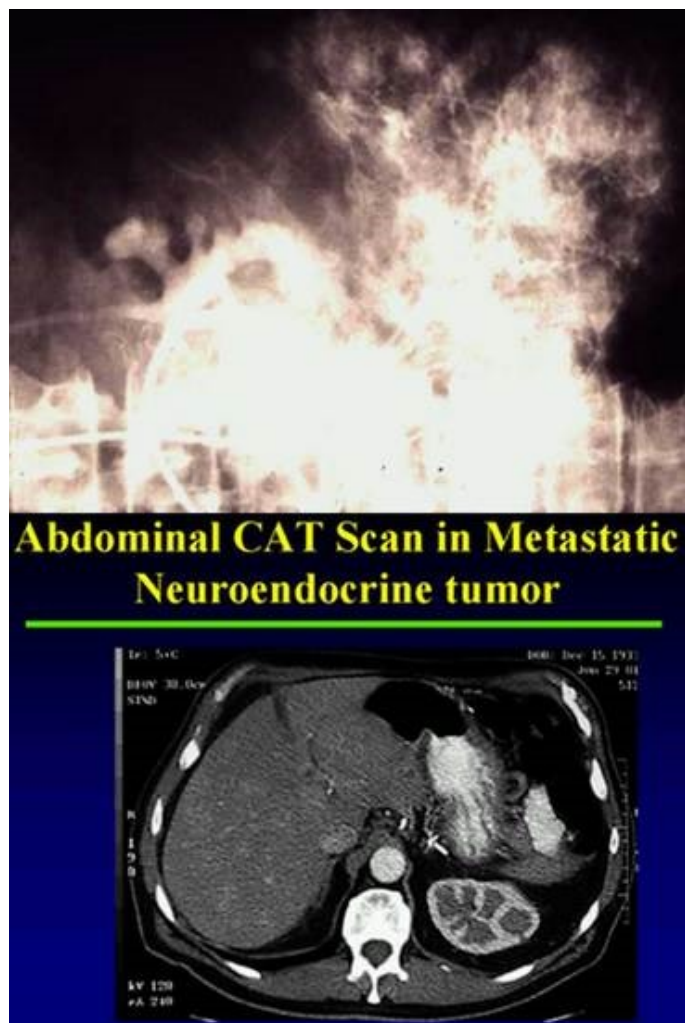
The first report of  $^{131}\text{I}$ -MIBG for the imaging of a carcinoid tumor was that of Fischer and colleagues in 1984, in which hepatic metastases that were seen as photopenic areas on a  $^{99\text{m}}\text{Tc}$ -phytate liver scan concentrated (108)  $^{131}\text{I}$ -MIBG (109). Since this initial description, there have been a number of reports of successful imaging of carcinoid tumors using  $^{131}\text{I}$ -MIBG. The number studied are far less than those reported for pheochromocytomas or neuroblastoma but it probably is fair to say that the sensitivity is significantly lower (110-112); Von, 1987 14301 /id}. The overall sensitivity is calculated to be 55%. Because MIBG is taken up by a wide variety of neuroendocrine tumors, specificity depends on the certainty of the clinical and biochemical diagnosis. In the correct clinical context, this is well over 95% for pheochromocytomas (113) and neuroblastoma, (114-116) but it is clearly less for carcinoid tumors.

$^{131}\text{I}$ -MIBG scanning offers information that is additive to the information gained by SRS imaging. In some patients SRS scanning is negative and other lesions light up on MIBG scanning. In other patients SRS imaging and MIBG scans both are positive or negative. In the case where both scans are positive patients may be candidates for future therapy with  $^{131}\text{I}$  MIBG or PRRT with radiolabeled somatostatin analogs.

### Other Diagnostic Methods:

Several other diagnostic methods have been evaluated for the diagnosis of carcinoid tumors, including barium examinations, angiography, and venous sampling with radioimmunoassay of hormones. Barium examinations rarely are diagnostic, but they may demonstrate fixation, separation, thickening, and angulations of bowel loops.

The role of angiography in the diagnosis of carcinoid tumor has decreased due to the availability of the newer imaging methods. Diagnostic angiography generally is employed when noninvasive imaging studies are equivocal and surgery or chemoembolization is contemplated (Figure 21).



**Figure 21 Positive angiogram with Negative CAT scan in a patient of NET.**

Liver metastases from carcinoid tumors vary in size and usually are vascular, with abundant neovascularity demonstrable on angiography. Figure 21 illustrates the highly vascular nature of neuroendocrine tumor metastases to the liver. It is this hypervascularity of the tumor that distinguishes it from other non-endocrine tumors that metastasize to the liver as well as providing insight into the availability of “feeder vessels” for chemoembolization for the reduction of tumor burden. This is particularly helpful in restoring responsiveness to octreotide, reducing tumor load and lessening the biochemical deviations, which in the case of serotonin for example may reduce the risk of development of carcinoid heart disease.

In the remaining cases, in whom the tumor has not been identified by the above techniques, total-body venous sampling with measurement of a peptide hormone that is produced may be

considered. Measurements of serotonin may be misleading, but those of SP may well direct attention to the source of overproduction of the peptide. This has proved useful in SP-producing tumors (41).

Percutaneous transhepatic portal and systemic venous sampling with hormone assay is generally not a very useful technique for the localization of carcinoid tumors. Such data must be used cautiously. In one report, whole-body venous sampling with measurements of plasma serotonin erroneously localized the tumor to the neck, for which a negative exploration was carried out; however, SP levels correctly localized certain of these tumors (41).

### Summary of Imaging for NETs

A major aspect in the evaluation of patients with suspected MGC is diagnostic imaging (32). The modalities typically

used include both standard cross-sectional techniques as well as nuclear functional imaging with the following diagnostic goals: making the diagnosis, determining the total tumor burden, determining the potential for resection and debulking, establishing disease prognosis, and determining the potential for non-conventional therapies, especially for systemic or inoperable disease.

### **Special Clinical Situations:**

#### **Carcinoid Heart Disease**

#### **Distinguishing Carcinoid from Cardiac Failure Symptoms**

<ul style="list-style-type: none"> <li>• <b>Right Heart Failure</b></li> <li>• <b>Dyspnea</b></li> <li>• <b>Fatigue</b></li> <li>• <b>Ascites</b></li> <li>• <b>Anorexia</b></li> <li>• <b>Edema</b></li> <li>• <b>Flushing</b></li> <li>• <b>Diarrhea</b></li> <li>• <b>Bronchospasm</b></li> <li>• <b>Hypotension</b></li> <li>• <b>Tachycardia</b></li> </ul>	<ul style="list-style-type: none"> <li>• <b>Carcinoid Symptoms</b></li> </ul>
--	---

***Table 19.***

With the advent of modern therapy for carcinoid tumors, increasing survival is unveiling a higher incidence of carcinoid heart disease. Carcinoid heart disease is a unique heart disease associated with this cancer and may be seen in up to 60% of patients with metastatic carcinoid. Valvular disease is the most common pathologic feature. Carcinoid heart disease is the only condition in which both right-sided valves are involved and the combination of pulmonary stenosis and tricuspid regurgitation occur. Tricuspid damage is found in 97% and pulmonary valve disease in 88% with 88% displaying insufficiency and 49% stenosis. The distinctive carcinoid lesion consists of deposits of fibrous tissue devoid of elastic fibers known as carcinoid plaque. The deposits are found on the endocardial surface on the ventricular aspect of the tricuspid leaflet and on the arterial aspect of the pulmonary valve cusps (117). Most patients have the distinctive lesions on the right side of the heart. In the setting of bronchial carcinoid, the left-sided lesions on the mitral valve may be so extensive as to cause mitral stenosis.

Table 19 indicates the difference in symptomatology between right heart failure and carcinoid symptoms. While there should be no mistaking these conditions it is not surprising that faced with a patient who is suffering from flushing, wheezing and bronchospasm the occurrence of dyspnea, fatigue and edema might go unnoticed. This can be particularly devastating since the advent of heart failure heralds a very poor prognosis. Its occurrence does not appear to be predicated by the bulk of the tumor, the duration of symptoms, or the location of the primary tumor but rather the level

of serotonin in the blood (Table 20). Values greater than 1000pg/ml correlate with the development of carcinoid heart disease. Possibly for this reason alone, in treating these patients all attempts should be made to keep serotonin levels down in addition to relieving symptoms and slowing or abrogating tumor growth.. Ovarian carcinoids are the rare variety in which cardiac involvement occurs without metastases to the liver, no doubt because of the direct drainage of the ovarian veins into the systemic circulation.

The condition can be diagnosed clinically. In approximately 20% of patients with carcinoid disease the presenting symptom may be attributable to heart failure (118). Ninety five percent of patients have the diastolic murmur of tricuspid incompetence and 13% the precordial systolic murmur of pulmonary stenosis. The chest radiograph may show an increase in the cardiothoracic ratio in 38% of cases and is not a sensitive measure (117). The electrocardiograph characteristically shows low voltage in that the sum of the QRS voltage in the standard leads I, II, and III is less than 15 mm, but evidence of right ventricular hypertrophy is rare. Pro-brain natriuretic peptide (NT-pro-BNP) can be used as a biomarker for the detection of carcinoid heart disease with high specificity and sensitivity and used as an adjunct to deciding who requires Echocardiography (119).

Transthoracic echocardiography, both M-mode and cross-sectional may show dilated right ventricular cavity and abnormal movement of the ventricular septum as well as thickened and retracted tricuspid leaflets with a fixed orifice but is not very sensitive, being positive only in only two thirds of (15/20) patients with clinical evidence of carcinoid heart disease (120). Transesophageal echocardiography may be more sensitive than transthoracic (71% vs 57% of 31 patients with ileal carcinoid) and allows for measurement of the thickness of the A-V valves (121). Doppler echocardiography was examined by Pellika and colleagues (122) in 132 patients with carcinoid syndrome. They found 74 (56%) with Doppler echocardiographic features of carcinoid heart. Ninety seven percent had thickened and shortened tricuspid leaflets and 100% had tricuspid regurgitation. A dagger-shape spectral profile with an early peak pressure and rapid decline was characteristic. The pulmonary valves were thickened, retracted and immobile in 59% and of these regurgitation was present in 81% and stenosis in 53%. Left-sided lesions were found in patients with patent foramen ovale in 7%, metastasis to the myocardium in 4% and small pericardial effusions in 14%. The 3-year survival in their series was reduced from 68% to 31% in those with carcinoid heart disease. Hemodynamic tests showed the expected pulmonary stenosis and tricuspid valve regurgitation and are only indicated for decision making with regard to possible valvulotomy. A Doppler gradient of >10mm Hg is considered by one group to indicate a need for pulmonary valvulotomy (123).

The pathogenesis of the plaque is not completely understood. The plaque is composed of smooth muscle cells, myofibroblasts and an overlying endothelial cell layer. The smooth muscle cells and the myofibrils are surrounded by an extracellular matrix of microfibrils, acid mucopolysaccharides, collagen fibers and basement membrane. Serotonin infusion in the presence of hepatic injury or tryptophan or niacin deficiency in animals leads to similar lesions (117). A similar condition is also observed in Uganda, with large consumption of the Cassava plant which is rich in tryptophan, the precursor of serotonin. The recent discovery of an analogous heart condition in obese patients taking

Fenfluramine and dexfenfluramine (Phentermine) known as phen/fen for weight reduction is thought to be due to the enhanced release of serotonin and decreased serotonin reuptake exposing the heart valves to much higher concentrations of 5 hydroxytryptamine (124). These appetite suppressants were in widespread use in the United States. On July 8th 1997, 24 case of valvular heart disease were reported in women who had been treated with the combination for about one year. Regurgitation was found in all cases. Both right and left-sided heart valves were involved. Eight women developed pulmonary hypertension. Cardiac surgical intervention was required in 5 patients at the time of reporting. The histological features were similar to those observed in carcinoid-induced valvular disease. Based on these observations the FDA issued a public health advisory and sent letters to 700,000 US health care practitioners advocating the immediate cessation of further prescriptions. The rarity of the syndrome in patients with bronchial carcinoids may be ascribable to the production only of 5 hydroxytryptophan rather than the amine, serotonin.

Lundin (125) and colleagues (1988) reported on 68 patients with midgut tumors 50 of who had carcinoid syndrome.

Eighty nine percent had elevated 5HIAA and the patients with severe right sided heart disease had significantly higher mean values (9800 vs 2190 umol/day). Pellika et al (122) reporting on the Mayo experience found higher urinary 5HIAA in their 84 patients with carcinoid heart compared with the remainder of the 132 patients studied (270 vs 131 mg/day). Robolio et al (126) reported on the Duke carcinoid database of 604 patients found strikingly higher plasma serotonin (1130 vs 426 pmol/ml) and urinary 5HIAA (219 vs 55 mg/day) in 119 patients with carcinoid heart than in 585 patients without carcinoid heart. Thus there is considerable circumstantial evidence to implicate serotonin per se in the pathogenesis of carcinoid heart. Our own experience is that treatment of patients with carcinoid syndrome with Octreotide often ameliorates the clinical syndrome but does little to lower serotonin levels and the heart disease progresses while the condition appears to regress (127). The finding by Lundin et al (125) in (1988) of higher levels of neuropeptide K and substance P in patients with midgut carcinoids and heart disease may simply reflect the advanced stage of the disease since these are potent vasodilators and are not known to be able to influence the development of the characteristic plaque. Similarly their report (128) of higher levels of Atrial Natriuretic Peptide (ANP) in patients with carcinoid heart may only reflect upon the development of failure, a known cause of increases levels of ANP.

**Table 20.**

**Carcinoid Heart Disease**

- **No obvious relation to:**
  - **Duration of disease**
  - **Tumor bulk**
  - **Location of primary**
  - **Progression of disease**
- **Significant difference**
  - **Survival**
  - **Serotonin (5HIAA) values >1000 pg/ml**

The dismal prognosis of patients with carcinoid heart disease with less than 20% 5 year survival compared with greater than 66% 5 year survival in patients with tumors treated with Octreotide dictates a much more aggressive approach to management. Up to 1995, a total of 38 patients had been reported with either single case studies or small series of patients who had undergone valve replacement. There were no significant differences in survival of patients with bioprosthesis vs a mechanical prosthesis in the tricuspid valve position. The 4 year survival was improved to 48±13% (124). In the Mayo and Duke experience (129) in 26 and 8 patients respectively, up to 30% die within the first 30 days of operation. Predictors of operative mortality are low voltage in the standard EKG leads (QRS in leads 1,11,111 <15mm), high preoperative serotonin and age > 60 years (>56% mortality). Long term survival was predicated by low serotonin values and none of the patients less than 60 years old died early. All who survived had symptomatic improvement. Balloon valvulotomy has had mixed results. Somewhat surprisingly Rayson and colleagues report four patients with severe carcinoid heart disease who had regression of their metastatic tumors postoperatively (130). Further descriptions of tumor status in patients who have had cardiac surgery to confirm or refute this observation are clearly necessary and it would be of considerable interest and therapeutic potential to determine the possible mechanism involved.

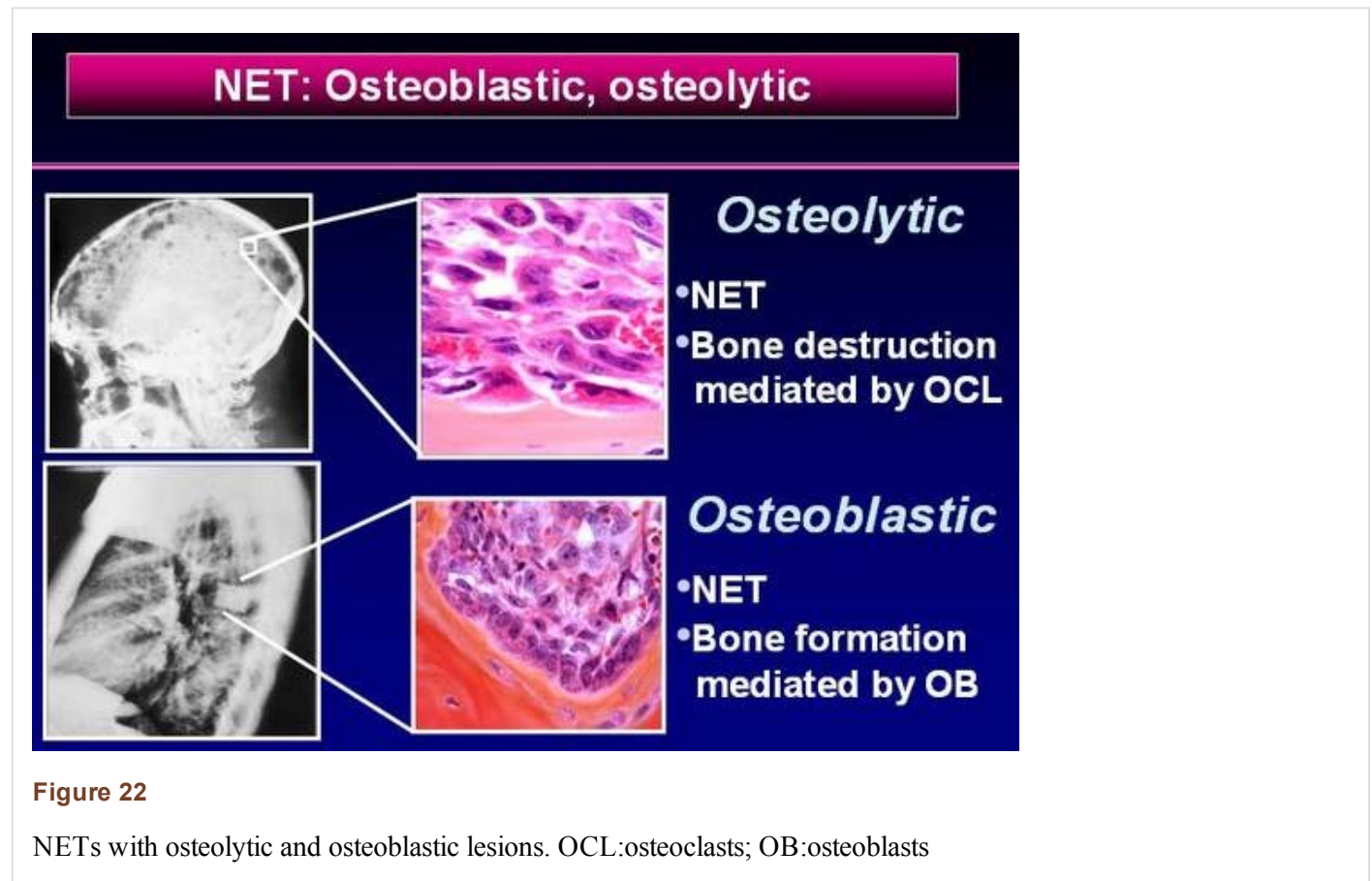
Thus if the distinction between symptoms due to cardiac disease are recognized early, before there is marked elevation of the serotonin levels, especially in patients under the age of 60 years and without EKG evidence of low voltage, it is



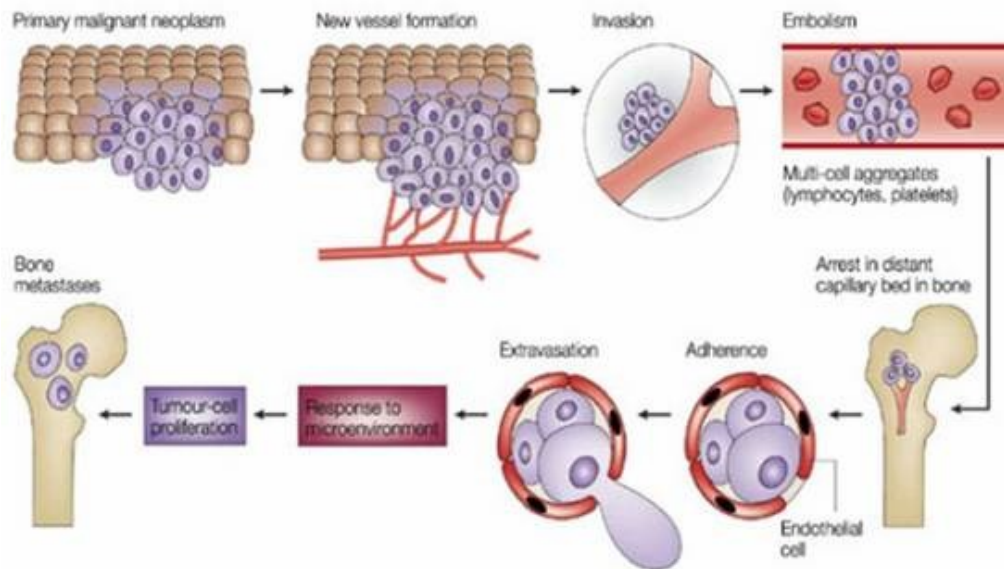
probably prudent today to aggressively replace the tricuspid and pulmonary valves. Since the long-term durability of bioprosthetic valves is > than the 20% 5 year survival of untreated patients this is not an issue. Prolongation of life can be achieved and more importantly the quality of life is greatly enhanced for the remaining years.

### Carcinoid Bone metastasis

NETs are renowned for their production of a host of peptides and amines as well as many cytokines, which may foster tumor growth as well as metastases to bone (Figure 22). Symptoms of bone metastases include pain, fractures, and spinal cord compression. Carcinoid bone metastases are being identified more frequently. A possible explanation for the increasing rate of bone metastases could be due the therapeutic use of various somatostatin analogs and interferon- $\alpha$ . These agents relieve symptoms mediated by amines secreted by the tumor (131) but have only a limited effect on tumor growth (132). Improvements in medical management can lead to prolonged survival in patients with advanced disease with more patients developing boney metastases. Finally the increasing use of imaging techniques like Octreotide scintigraphy reveals asymptomatic bone metastases, leading to diagnosis of higher rate of bone metastases.

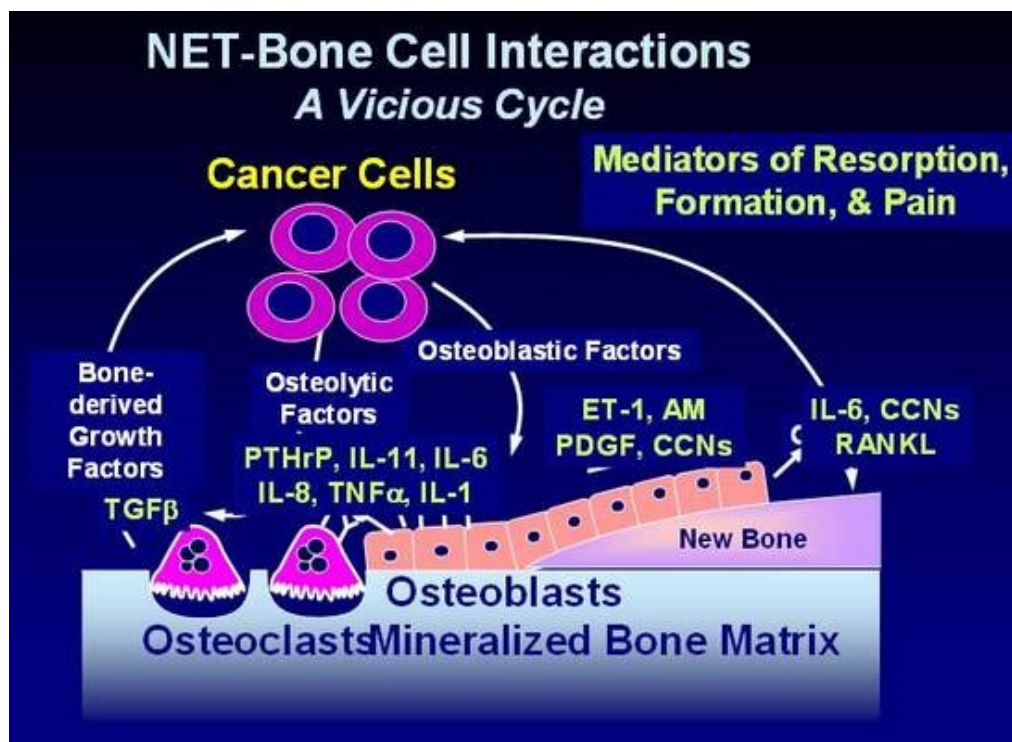


## Bone Metastases Mechanism



**Figure 23**

Bone metastases mechanism in neuroendocrine tumors showing the spread of neoplastic cells from the primary tumor invading blood vessels and spreading as emboli to distant regions like bone. Malignant tumor cells adhere to blood vessel at the distant capillary bed in bone to enter the bone matrix through extravasations and then they proliferate inside the bone matrix.



**Figure 24. A**

vicious cycle, interaction between the tumor cells and bone cells. Osteoclastic resorption and osteoblast deposition of bone during mineralization causes stimulation of Bone derived Growth Factors which in turn stimulate the cancer

cells which have capability to stimulate both osteoblast and osteoclast through osteoblastic and osteolytic chemokines and thus causing a vicious cycle. TGF $\beta$ : Tissue growth factor beta, PTHrP: Parathyroid hormone-related protein, IL: Interleukin, TNF: Tumor necrosis factor, ET: endothelin -1, PDGF: Platelet derived growth factor.

Shown in the figure 24 are some of the proposed mechanisms whereby NETs affect bone turnover. NETs cells are capable of producing both osteoblastic and osteolytic chemokines. Thus both types of metastases are observed. The figure shows a partial listing of chemokines involved which include immunoreactive Parathyroid hormone related protein or PTHrP, endothelin -1 (ET-1) shown to bind to Endothelin A and B receptor mediating osteolysis, and various cytokines such as tumor necrosis factor (TNF  $\alpha$ ) and interleukins 6 and 11. Perhaps the most significant of these is RANK which binds to its ligand RANKL, thereby promoting osteoclastic activity. The natural antagonist is osteoprotegrin (OPG) which binds to RANK and precludes its binding to RANKL, inhibiting osteoclastic activity.

#### Diagnosis of Bone Metastases:

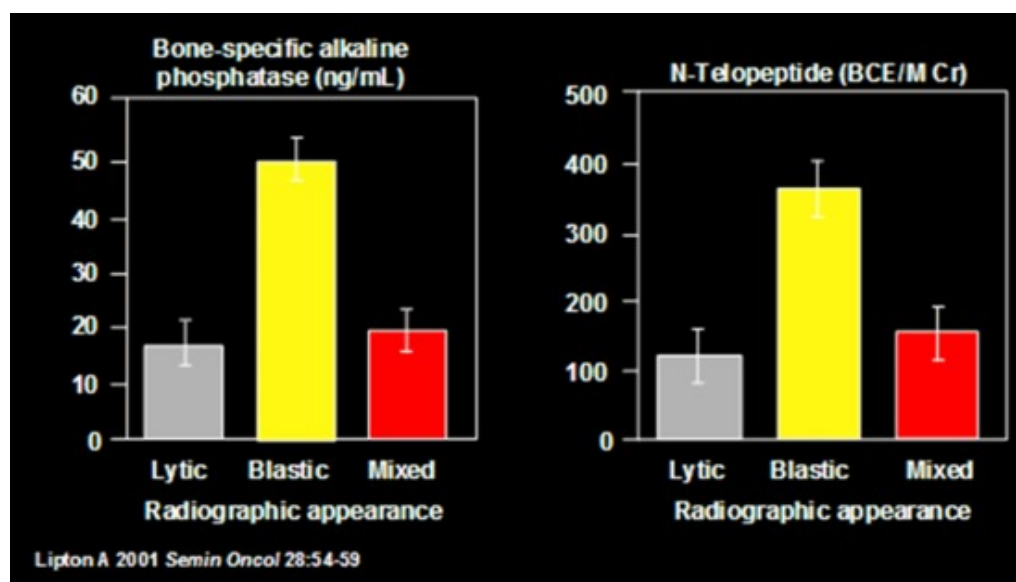
While the standard means of detecting bone metastases is radiological (e.g. X-ray, bone scan, Octreoscan) bone metastases can be sought with measurement of bone alkaline phosphatase, N telopeptide, and 25-OH Vitamin D, 1-25-OH Vitamin D. Bone alkaline phosphatase is an indicator of osteoblast function. Urinary N –telopeptide reflects osteoclast activity or bone resorption (Figure 23). Somewhat paradoxically only blastic metastases show an increase in both markers as indicated in Figure 24 (25). A more complete listing of bone markers that may aid in diagnosis, management, and response to therapy are shown in Table 21.

<ul style="list-style-type: none"> <li>• Bone formation markers:</li> <li>• Serum PINP</li> <li>• Serum Bone specific</li> </ul> <p>Alkaline Phosphatase</p> <ul style="list-style-type: none"> <li>• Serum Osteocalcin</li> <li>• Osteoprotegrin (OPG)</li> <li>• Bone Alkaline phosphatase</li> <li>• N telopeptide</li> <li>• Vitamin D25, 1:25 OHD</li> <li>• Urine NTX</li> <li>• Serum CTX</li> <li>• Serum NTX</li> <li>• Serum RankL</li> <li>• PTHrP in blood</li> <li>• Perhaps IGF1</li> <li>• Calcitonin</li> </ul>	<ul style="list-style-type: none"> <li>• Screening:</li> </ul>
---	--

<ul style="list-style-type: none"> <li>• TGF b</li> <li>• Endothelin 1</li> <li>• Serum IL1 and IL6</li> <li>• Serum 25 hydroxy Vitamin D (25OH D)</li> <li>• Ionized calcium</li> </ul>	
<ul style="list-style-type: none"> <li>• Bone resorbtion markers:</li> </ul>	<ul style="list-style-type: none"> <li>• Markers of malignancy:</li> </ul>
<ul style="list-style-type: none"> <li>• Markers of cytokine excess</li> </ul>	<ul style="list-style-type: none"> <li>• Vitamin D metabolism</li> </ul>

**Table 21.** Bone Metastases Screening for Bone Markers & Assays, Bone resorption markers, Markers of malignancy, Markers of cytokine excess and Vit D metabolism. IGF: Insulin like Growth Factor, IL: Interleukin, PTHrP: Parathyroid hormone-related protein, NTX: N-Telopeptide; TGF $\beta$ : Tissue growth factor beta.

Several studies have shown bone markers to be elevated in carcinoid patients who have documented evidence of metastatic bone disease. Increased levels are also observed in some patients without clinical evidence of bone metastases, when compared with normal subjects (6). Rises in such markers may be the first indication of bone involvement and therefore may potentially be useful in early diagnosis of progression. Preliminary data suggest bone marker level correlates with the extent of metastatic disease and the number of skeletal sites involved. Markers of bone turnover may be helpful in identifying those patients who are likely to respond to bisphosphonate treatment (6).



**Figure 25**

Bone markers in patients with lytic and blastic metastases. Note here that markers for bone formation-Alkaline Phosphatase and Bone lysis-N-telopeptide are both increased in blastic lesions (6).

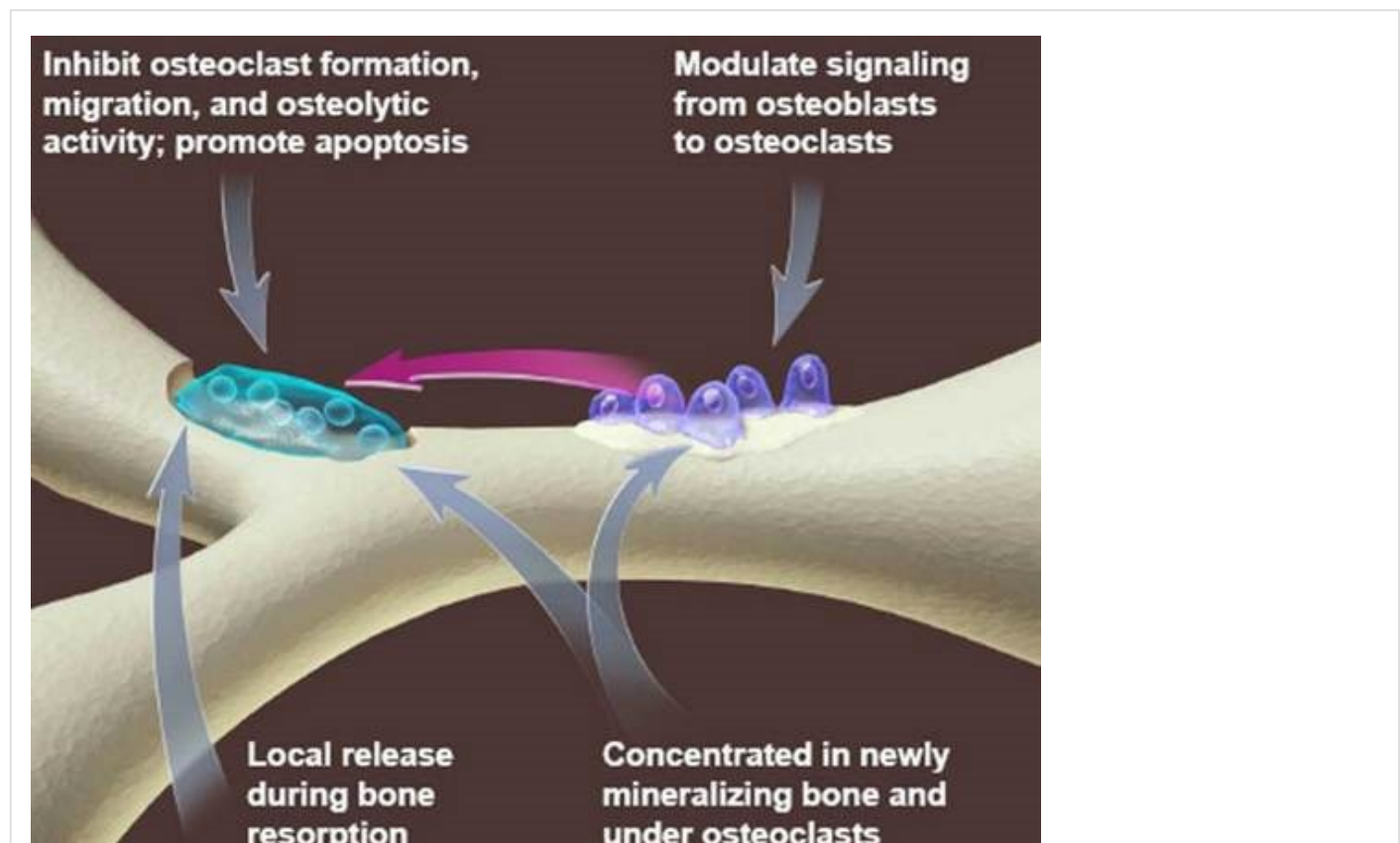
### **Treatment of Bone Metastases (BM):**

Therapeutic options include drugs, chemotherapy, surgery, and radiation therapy. Bisphosphonates, anti TGF beta, anti endothelin acting drugs, Denosumab human monoclonal antibody and antibody that binds RankL are major non invasive options. Surgery may be required to treat or prevent pathologic fractures. External beam radiation therapy is effective in treating painful boney metastases.

Bisphosphonates are effective for the prevention of skeletal complications secondary to bone metastases. The direct in vitro effects of bisphosphonates on bone include: Inhibition of growth, (133), invasiveness (134), (135), apoptosis (136) (137), adhesion to bone (138) (139), inflammatory effects on T cells, and Anti-angiogenic effects (Figure 26). None the less the clinical impression is that although symptoms (pain) may be relieved, little is done to inhibit growth of the tumor.

IV pamidronate and zoledronic acid are FDA-approved for other malignancies but are in extensive clinical use in NET. There is however, a need for more safe and effective therapies. Renal toxicity and osteonecrosis of the jaw are potential complications associated with bisphosphonates and are of considerable concern in patients with NET (140-146). All patients embarking the treatment with bisphosphonates should have an evaluation for possible complications. While we have used pamidronate exclusively, a recent report (147) suggests that Zoledronate is the more preferred agent.

Symptoms of possible osteonecrosis of the jaw from biophosphonates include a dull aching sensation, with the feeling that the jaw is “heavy”, numbness and tingling of the jaw, tooth pain, and undiagnosed oral pain. Signs of possible osteonecrosis include rough area on the jawbone, soft tissue swelling, drainage or infection, exposed bone in the oral cavity, sudden change of health in periodontal tissue, failure of oral lesions to heal, and loosening of the teeth.



**Figure 26**

Different mechanisms of action of Bisphosphonates. They inhibit osteoclasts formation, migration, osteolytic activity and promote apoptosis. They also modulate signalling from osteoblasts to osteoclasts.

Prospects for alternative therapies are a major area of research. One such area is inhibitors of TGF  $\beta$ . TGF  $\beta$  is a multifunctional cytokine with widespread effects, including antiproliferation, apoptosis, extracellular matrix production, angiogenesis, immune function, and epithelial to mesenchymal transition. The effects of TGF  $\beta$  on bone are complex, but it appears to be intimately involved with bone metastasis and osteolysis. Studies have shown that inhibition of TGF $\beta$  kinases in vitro have an effect on osteolytic and prometastatic factors including PTHrP, IL-11 and CTGF. In vitro studies have shown effects on osteolysis, tumor burden and survival.

Another promising area of research is the novel target endothelin Receptor ET-1. Endothelin Receptors are responsible for a number of effects on bone including vasoconstriction and cell proliferation. Phase II trials with Endothelin A Receptor (ETAR) antagonist, Atrasentan, in metastatic hormone resistant prostate cancer to bone, showed increased time for clinical progression of the disease as well as slow rise in PSA levels (148). In another Phase II trial with Atrasentan, they showed decreases levels of markers for bone remodeling after treatment with Atrasentan (149). Treatment with an orally active Endothelin A receptor antagonist dramatically decreased bone metastases and tumor burden in mice inoculated with ZR-75-1 cells (150). Tumor-produced endothelin-1 may have a major role in the establishment of osteoblastic bone metastases, and endothelin A receptor blockade represents effective treatment (150). Whether or not these agents have activity in carcinoid boney metastases is not known.

### **Prognosis of Bone Metastases**

Brown (2005) evaluated the outcome of the tumor metastases to bone and found that increased Osteoclast activity predicts a poor outcome (151). Increased osteoclast activity predicts a poor outcome, with a Relative Risk (RR) for high N-telopeptide ( $> 100$  nmol BCE/mM creatinine) of skeletal related events RR: 3.3 ( $p<0.001$ ) disease progression RR: 2.0 ( $p<0.001$ ) and death RR: 4.6 ( $p<0.001$ ) (151).

### **TREATMENT OVERVIEW:**

Surgical removal of the primary tumor is the treatment of choice for small and localized tumors as well as for the alleviation of any obstructive symptoms (Figure 27). Surgical cure of carcinoid tumor is almost impossible in the presence of intra-abdominal and widespread hepatic metastases.

# Management of Neuroendocrine Tumors

## ■ Localizaton and Resection

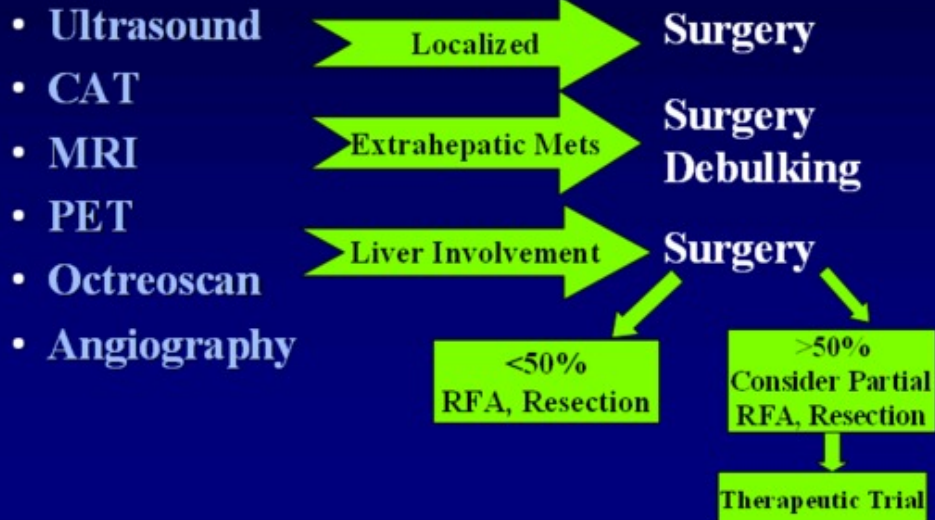


Figure 27.

Resection of NETS in the absence of metastases is a *sine qua non*. NETs may present several unique challenges for the surgeon. The primary tumor is often small and may be occult. It may be difficult to identify on preoperative imaging and in the operating room. Indeed, sometimes the primary cannot be located, with the only findings a mesenteric mass. An occult primary should not deter attempts at resection since the majority of these tumors are found intra-operatively after diligent and thorough inspection of the small bowel using open or laparoscopic techniques. NETs are characterized by small ileal, occasionally multiple, submucosal tumors, regularly associated with a larger mesenteric mass and intense fibrosis (152). The mesenteric lymph node involvement can be bulky and involving major mesenteric arterial and venous branches. This may make it difficult or impossible to completely remove the mass.

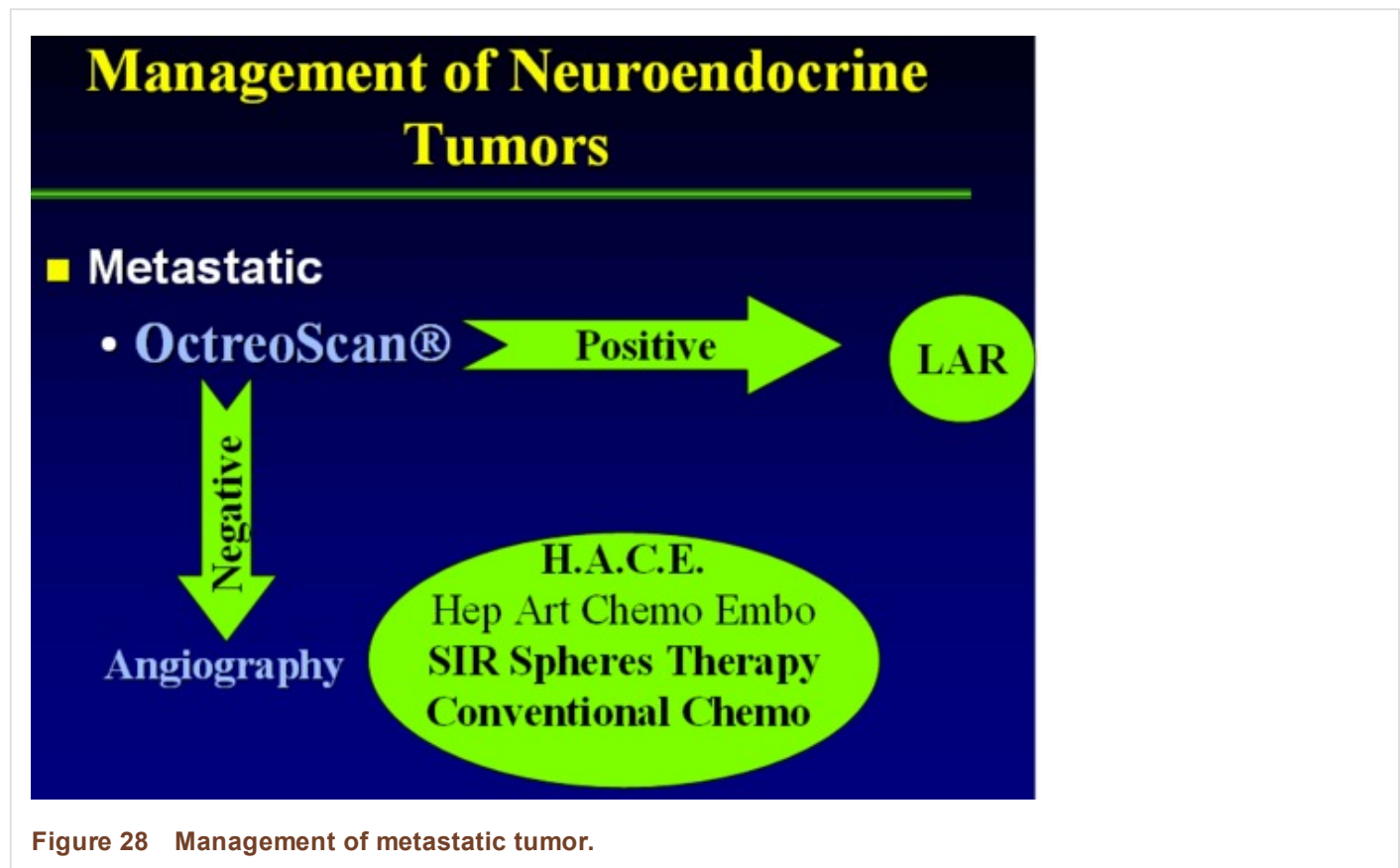
The aim of surgical treatment for small intestinal - NETs, when possible, should be the complete curative *en block* resection of the primary tumor and its mesenteric lymph node metastases/mass. Surgeons must be aware of the predilection of these tumors for spread along the bowel lymphatics hence mimicking multiple small bowel primaries. Loco-regional resection aims to remove the small bowel primary and other small bowel tumor deposits with an extensive mesenteric lymph node dissection. Resection after includes a right hemi-colectomy and extensive small bowel resection while respecting the blood supply to the remaining bowel and avoiding short bowel syndrome. Fibrosis is the hallmark of NETs and release of fibrotic bands can relieve obstructive symptoms.

Even in the presence of distant metastases, resection of the primary and mesenteric mass is increasingly being advocated (153). The median and 5 year overall survival after loco-regional resection and selective systemic therapy of NETs shows a survival benefit. (Debulking of liver metastasis by resection in combination with ablative therapies and other liver directed modalities may help decrease hormonal over production and palliate symptoms in carefully selected patients.

The hormonal effects of the tumor can be extreme. When the carcinoid syndrome is present or suspected, the surgeon and the anesthesia team should be prepared for the possibility of a carcinoid crisis with resulting hemodynamic

instability, hyperthermia, shock, arrhythmia, flushing or bronchial obstruction (154). Prior to a surgical procedure, patients with carcinoid syndrome should be evaluated for the presence of carcinoid valve disease, and undergo valve repair prior to abdominal surgery for the primary and/or metastatic disease. Patients at high risk for carcinoid crisis, those with flushing and/or large bulky tumors, should be given peri-operative continuous intravenous octreotide (155). In the past, it was deemed unwise to submit a patient to anesthesia or operation without premedication using a combination of adrenergic blockade, steroids, thorazine, and aspirin. Currently, however, preoperative use of octreotide is the most important drug to prevent carcinoid crisis. Kvols and colleagues (155) presented data on one such patient, who, soon after the induction of anesthesia, had a fall in blood pressure that was unresponsive to intravenous fluid, calcium, Neo-Syneprine, or epinephrine administration. Within 1 minute of 100 meg of octreotide given intravenously, blood pressure rose, and the patient made an uneventful recovery. Lastly, since somatostatin analogs are known to cause biliary stasis, and the majority of patients with small intestinal -NET will be treated with such agents at some point during their treatment course, cholecystectomy should be performed at the time of first operation for midgut carcinoids.

Carcinoids of the appendix are often found incidentally during appendectomy. The majority of appendiceal carcinoids are small (<1cm), located at the tip of the appendix and often cured with appendectomy. A right hemicolectomy with removal of the draining lymphatics is recommended when the primary tumor is  $\geq 2$ cm, incompletely resected, invades the base of the appendix or meso-appendix, displays lymphovascular invasion or lymph node metastases and unfavorable histology or grade (goblet cell, adenocarcinoid). The need for right hemicolectomy in appendiceal carcinoid of 1-2 cm in size remains controversial. Most are decided on a case by case basis looking at patient factors such as age and health, and pathological factors that suggest possible aggressive behavior. Cecal carcinoids usually present as a bulky mass causing intestinal obstruction or hemorrhage. Complete resection of the tumor and its draining lymphatics is recommended (156).



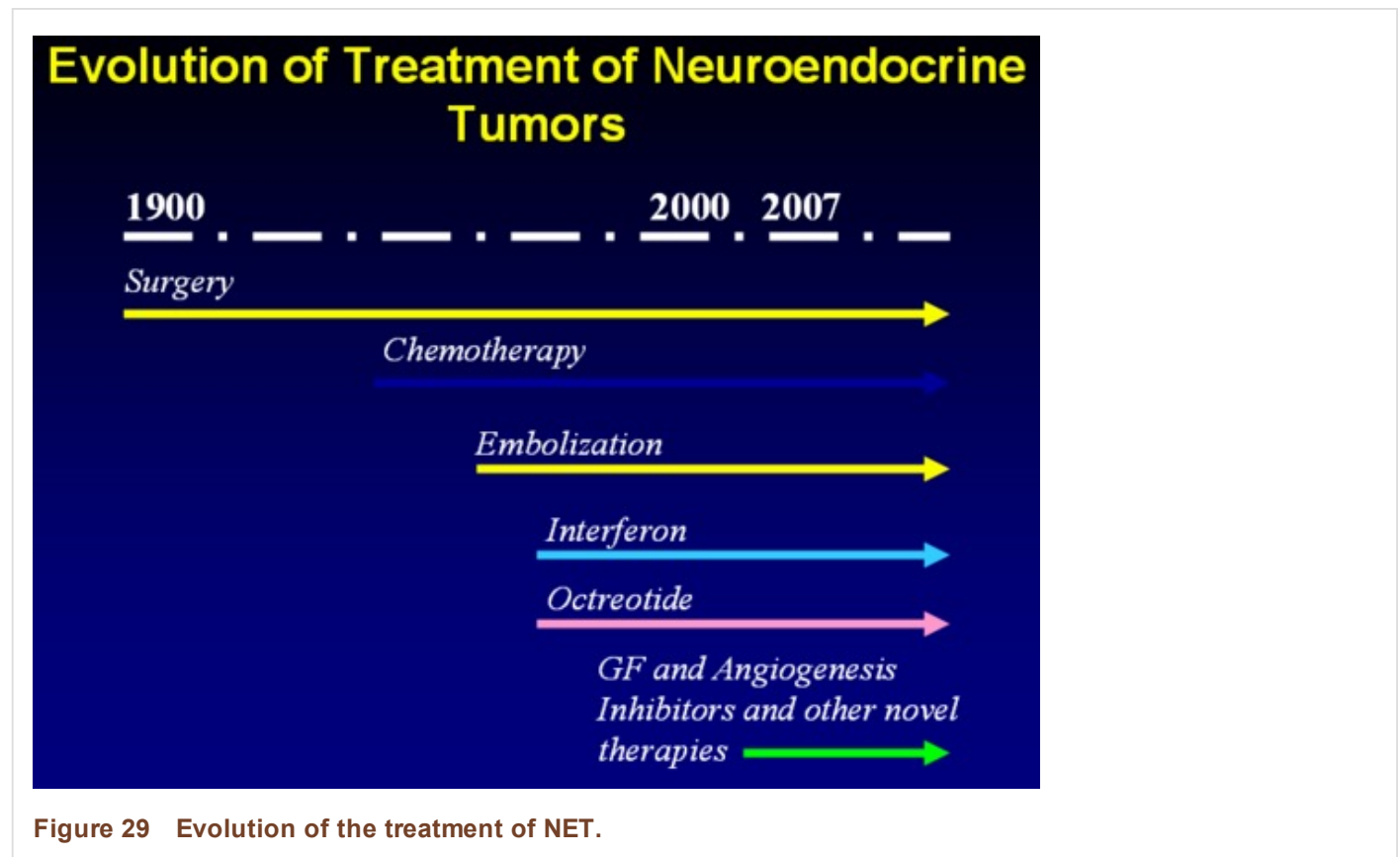
**Figure 28** Management of metastatic tumor.

Because carcinoid is a slow-growing tumor, even patients with extensive metastatic disease can enjoy a normal quality of life so long as the endocrine syndrome is controlled. The mainstay of treatment is octreotide (Figure 28). Different chemotherapeutic agents (157) and surgery or arterial embolization (158) have been used with variable success, but



eventual relapse with increasing resistance to the drugs is encountered (159). Various agents such as parachlorophenylalanine, methotrimeprazine, aprotinin, methysergide, cyproheptadine, heparin, phenothiazines,  $\alpha$ -adrenergic antagonists, corticosteroids, H<sub>1</sub> and H<sub>2</sub> antihistamine blockers and numerous antineoplastic agents have been used in carcinoid syndrome with variable success (53) (160). These medications either inhibit serotonin synthesis, act as systemic antagonist of serotonin, or block kallikrein release. Symptomatic treatment of diarrhea with opioids, and codeine have been tried with variable results (159). Because somatostatin has very broad inhibitory effects, somatostatin-14 has been used successfully to suppress diarrhea and flushing in patients with carcinoid tumors (161) but, its clinical use is limited by its short half-life (162) and the resulting need for continuous intravenous infusion. The advent of the long-acting somatostatin analogue octreotide, has resolved problems with short half life time and it has been used in the treatment of different neuroendocrine tumors, including carcinoid (161) (155) (163) (20) as discussed in more detail below.

More recently, tyrosine kinase (TK) inhibitors, mammalian target of rapamycin (mTOR) inhibitors, growth factor, inhibitors, angiogenesis inhibitors, and various biologics have shown activity in this disease. The medical and radiologic treatment of carcinoid tumors is discussed in more detail below. The evaluation of available treatments is shown in Figure 29.



### **Medical Treatment of Carcinoid Symptoms:**

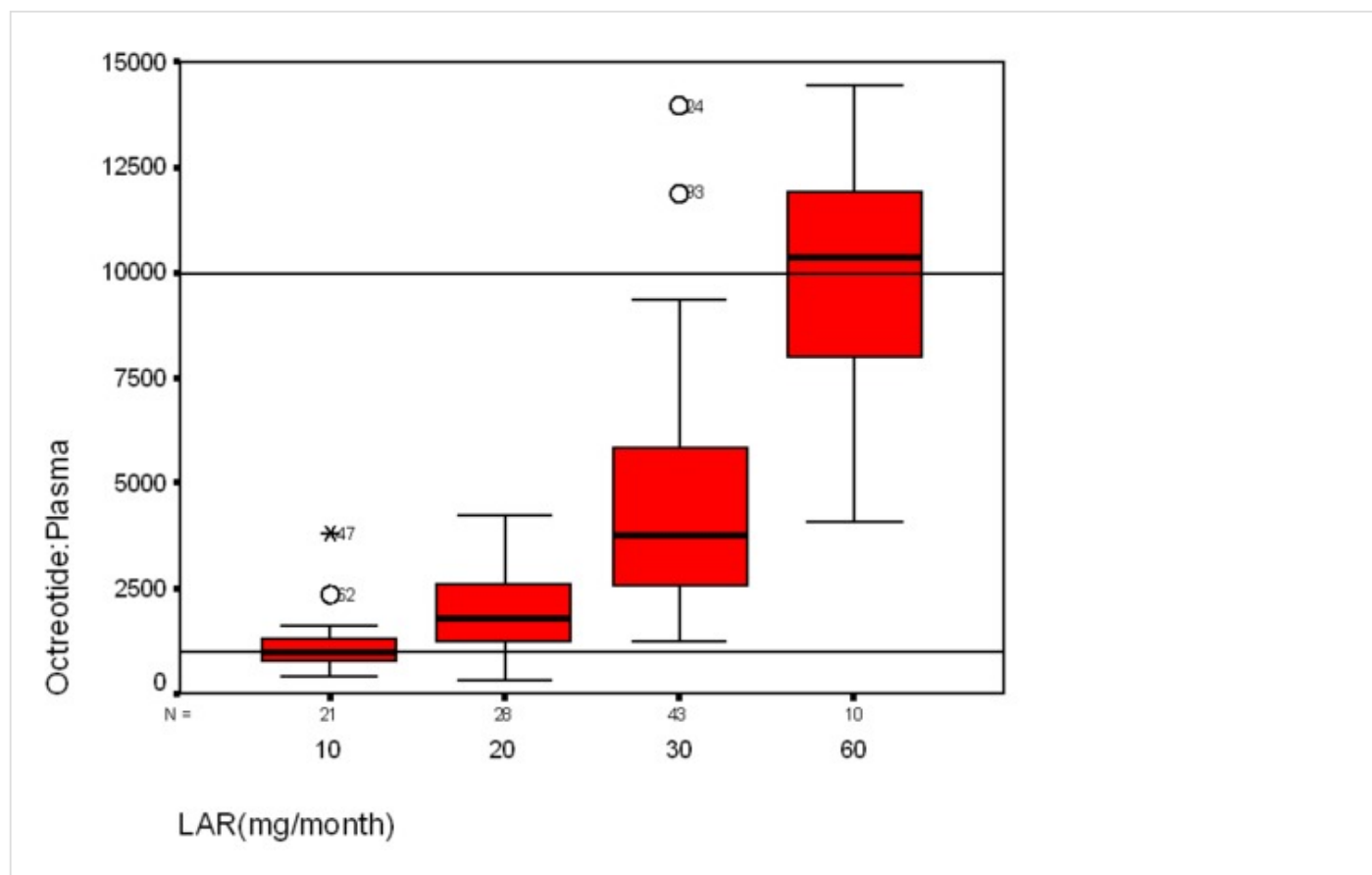
Somatostatin analogs (SAs) are the mainstay of treatment of carcinoid symptom complex. There are 5 somatostatin receptors present on these tumors as discussed in more detail earlier in the chapter. (164) (165). The commonly used SAs, octreotide and lanreotide, bind to SSTR-2 and 5 and are useful in reducing the diarrhea and flushing in at least 80% of patients (166). In a review of 15 studies including 481 patients, the slow-release formulations octreotide LAR (long acting release) and lanreotide Autogel achieved symptomatic improvement in 74% and 68%, biochemical response in 51% and 39%, and tumor response in 70% and 64%, respectively (167). Overall, octreotide and lanreotide have similar efficacy in symptom control and reducing tumor markers and serotonin levels (168). A recent study (ELECT

(169) evaluated rescue use as a measure of lanreotide autogel in patients who were SA naïve, receiving < 30mg LAR/4weeks or < 600ug/day octreotide. In a 16-week randomized double-blind phase 3 trial (lanreotide Autogel 120 mg [n=59] vs. placebo [n=56] every 4 weeks), and a 32-week open label Lanreotide autogel extension. Patients had access to octreotide s.c. as rescue for breakthrough symptoms. The primary endpoint was the percentage of days rescue was used during the double-blind phase. Complete/partial responses were more common in the autogel arm. (169). The starting dose of lanreotide autogel is usually 90-120 mg subcutaneously monthly, whereas octreotide LAR is 30-120 mg intramuscularly monthly.

SAs control growth of well differentiated NETs as well. In a double blind, placebo controlled phase 3b study with octreotide LAR 30 mg monthly in 85 subjects, the median time to tumor progression was 6 months for placebo and 14 months for octreotide subjects (170). In this study, an effect on survival analysis was not confirmatory given the low number of observed deaths. More recently, lanreotide autogel was evaluated as an antiproliferative agent in 30 subjects (including 12 with MGC) (171). In this open label, phase 2 study involving lanreotide autogel at a dose of 120 mg every 4 weeks, the median progression free survival (PFS) was 12.9 months, though there was no control group. The Clarinet trial is a multicenter global 96 week study on 204 patients with NETS randomized to Somatuline or placebo with primary endpoints of time to progression using CT or death with a multitude of secondary endpoints (Clin Trials .gov NCT 00353496). These data for both LAR and Somatuline suggest that SAs significantly extend the time to tumor progression.

In general, SAs are well tolerated, but patients may note nausea, abdominal discomfort, bloating and/or steatorrhea, often during the first several weeks of therapy after which the symptoms subside. Pancreatic malabsorption should be monitored and alleviated with pancreatic enzyme supplementation.

Although patients may be controlled with SAs for a number of years, refractory symptoms requiring dose escalation, increased dose frequency, or use of subcutaneous octreotide shots may occur in up to 40% of patients within 6-18 months (170) (172) (173). Slow progression over time of midgut tumors may contribute to reduction in SA efficacy within months to years (167).



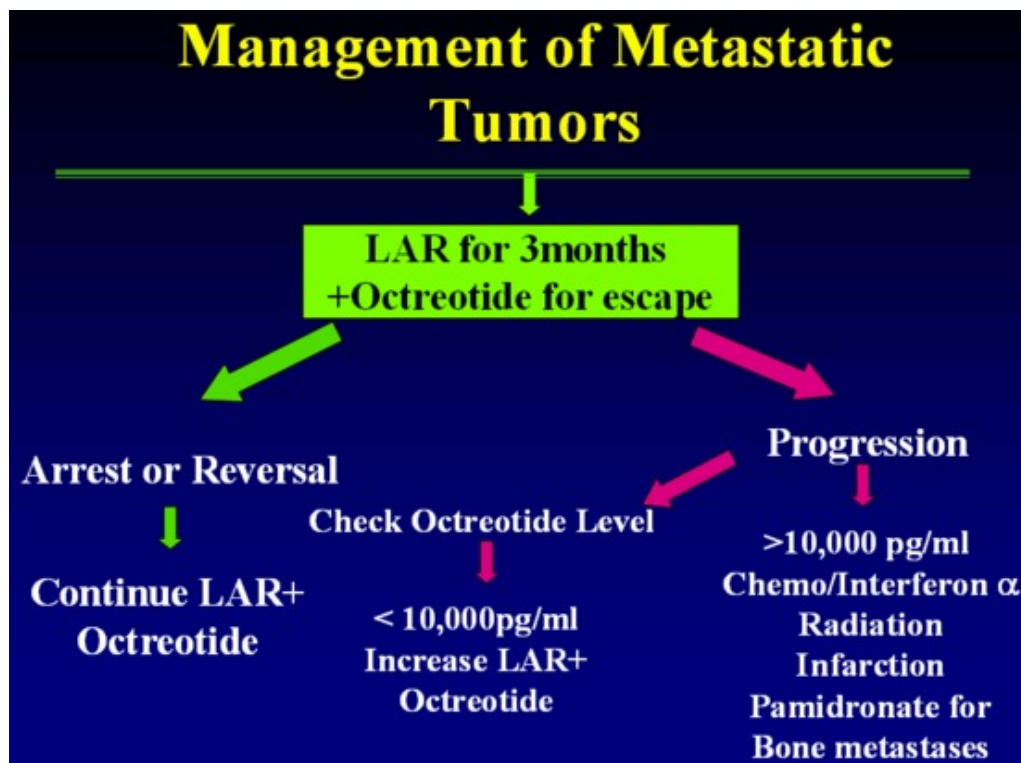
**Figure 30**

This figure represents the range of plasma octreotide levels versus the monthly dosage of LAR for the combined Novartis and ISI data. The dark line on each box-plot represents the median of the range, whereas the bottom and top of the solid box represents the 25th and 75th percentile of the plasma levels. The 2 reference lines are drawn at the Kd and saturation levels of the sst 2 receptor. Only the 60 mg/mo LAR dose covers the concentrations that would saturate sst 2. Circles and asterisks with values represent data that is out of range (3) (9).

Woltering et al, (9) found that the mean  $\pm$  SD plasma octreotide levels for patients receiving 20, 30, or 60 mg LAR/mo were 2518  $\pm$  1020, 5241  $\pm$  3004, and 10,925  $\pm$  5330 pg/mL, respectively (Figure 28). There was a significant correlation between plasma octreotide levels and octreotide levels measured in urine, saliva, and serum. Frequent measurement of octreotide levels may be useful to guide octreotide therapy in patients with poorly controlled symptoms or those patients experiencing tumor growth (9).

Other agents such as Interferon alpha and Everolimus may also be combined with SA's. Use of these agents is discussed in detail later in this chapter.

Pasireotide is a novel SA that has high affinity for SSTR-1, 2, 3, and 5 and displays a 30- to 40-fold higher affinity for SSTR-1 and SSTR-5 than octreotide or lanreotide. Pasireotide has been approved by the FDA for use in Cushing's disease and has demonstrated efficacy in patients with acromegaly (174) (175) (35) (36) and is generally well tolerated (174). Kvols et al. administered pasireotide as depot monthly injections to 45 subjects with carcinoid syndrome who had lost octreotide responsiveness. In this study, pasireotide controlled diarrhea and flushing in 27% of patients (176). Tumors remained stable in 13 (57%) and progressed in ten. This study suggested a role for pasireotide in patients resistant to currently available somatostatin analogs. In a more recent study, pasireotide administered as a monthly IM injection to 42 subjects with primary or metastatic GEP NET was well tolerated (177). Further study will help elucidate the role of pasireotide in patients with carcinoid tumors.

**Figure 31.**

## Responses to Octreotide

As a palliative agent, octreotide can control flushing, diarrhea, and wheezing in most patients with carcinoid tumors, with improvement in their general condition (Figure 30). Response is often dose dependent (Figure 31).

### Flushing

Frolich and colleagues (178) reported on the value of native somatostatin given by continuous infusion to reverse the PG-induced flushing in patients with carcinoid tumors. The initial patients treated with octreotide were a heterogeneous group with advanced carcinoid tumors refractory to conventional therapy who were tried on the somatostatin analogue with variable clinical and biochemical responses. Kvols and colleagues (166) found that 19 of 24 patients with carcinoid tumors had a 50% reduction in flushing, 3 had a minor response, and the octreotide failed in 2 patients. Richter and colleagues (179) showed that six of eight patients had improved symptoms.

Vinik's experience (163) was that 64% of his patients presented with flushing as their major symptom. In all instances, the symptom complex improved, with a clear decrease in the frequency of symptoms using doses of octreotide in the range of 450 to 1500  $\mu\text{g}/\text{d}$ . In no instance was there resistance to the drug. Tachyphylaxis did not occur, and withdrawal of the drug (or substitution with distilled water) was always followed by recurrence of the symptom complex. In contrast to another report (179) relapse of flushing did not occur with continued treatment once it was under control. However, in contrast to the reduction in a number of episodes, the severity in certain patients decreased only slightly, and the duration of each episode was essentially unchanged.

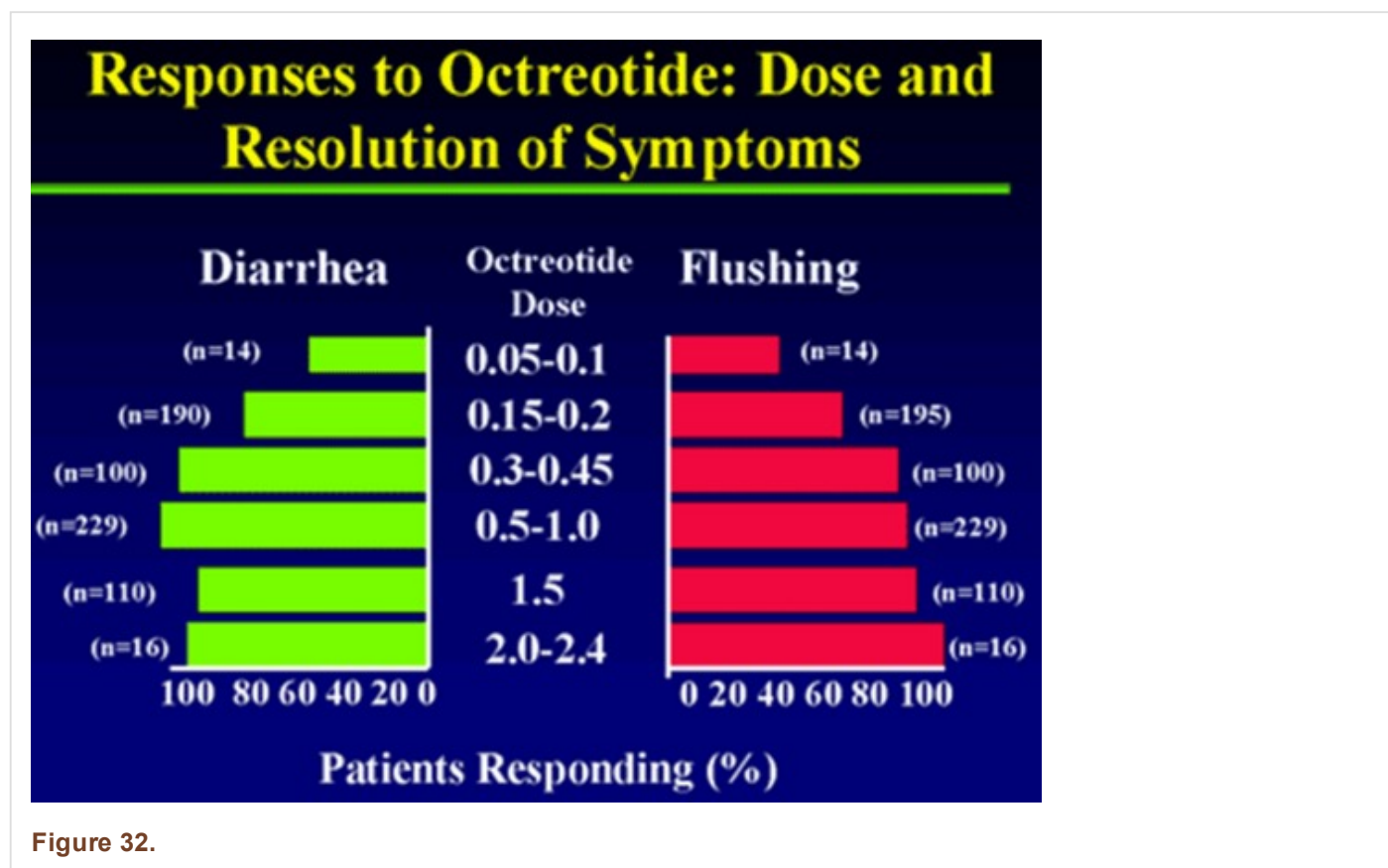


Figure 32.

Thus, although the mechanism of action by octreotide and the factors mediating flushing and vasodilatation are unclear, octreotide no doubt is a potent antidote to the vasoactive humors participating in the flush and hypotension. The drug is a useful adjunct in the preparation of patients for operative procedures as discussed earlier in this chapter, and should be available as a standby for the management of carcinoid crisis.

### Diarrhea

Diarrhea occurred in 86% of Vinik's (163) patients and responded variably to octreotide. Acute administration of octreotide normalized the water and electrolyte transport across the proximal intestine, as has been shown in patients with the watery diarrhea hypokalemia hypochlorhydria and acidosis (WDHHA) syndrome (163) (180). The acute reduction in electrolyte secretion did not, however, predict the long-term response of diarrhea to octreotide therapy, but this needs to be further examined in a larger number of patients. Only 58% of his patients with diarrhea had complete remission, which differs from the improvement in 19 of 25 patients (76%) reported by Kvolts and colleagues (166). This could result from the fact that diarrhea in patients with carcinoid tumors has multiple etiologies (i.e., secretory, increased motility, malabsorption, partial luminal lymphatic obstruction, bacterial overgrowth, and short bowel syndrome because of surgical resection). The diarrhea may even seem to worsen with the appearance of steatorrhea, and the physician not infrequently is faced with the confounding situation of not knowing to what to attribute the symptom. However, although octreotide does inhibit exocrine pancreatic secretion, (181) addition of pancreatic enzyme supplementation has not uniformly decreased octreotide-induced steatorrhea (182). There are no consistent changes in frequency or consistency of bowel movements in response to pancreatic supplements in those patients with steatorrhea before treatment or the bowel habits after therapy with octreotide, which is compatible with the notion that the steatorrhea has a complex pathogenesis and may be contributed to by alterations in bile flow, the direct effects of octreotide on nutrient absorption, and intestinal motility (183).

In addition to use of somatostatin analogs, antidiarrheal agents such as loperamide and/or diphenoxylate/atropine, and the opiates paregoric and tincture of opium may be useful. The serotonin-3-receptor antagonist ondansetron has been shown to be useful in reducing diarrhea in a small series of patients uncontrolled on a SA (184). If the diarrhea changes its character to a steatorrhea and the stools become foul-smelling, floating in the toilet bowl and do not flush enzyme replacement therapy is in order. We favor large doses of Zenpep.

### **Effects of octreotide on pulmonary function**

All of our patients with wheezing had clinical improvement, and spirometric improvement was documented. Pulmonary function did not improve further after 3 months of treatment, indicating an irreversible component or small airway disease secondary to longstanding smoking (185).

### **Effects of octreotide on myopathy**

One patient in our series presented with severe proximal muscle weakness and normal muscle enzymes and nerve conduction studies, but electromyographic features of a proximal myopathy. Although a neurologic deficit secondary to metastatic carcinoid has been reported, (186) metabolic-induced neuromuscular disease is very rare (187-189). Although our patient had a history of hypokalemia, his potassium was normal at the time of admission, with no biochemical evidence of thyrotoxicosis, ectopic ACTH production, or osteomalacia. We believe that his severe myopathy was caused by his carcinoid tumor, although it might have been aggravated by severe diarrhea, weight loss, and poor nutrition. Histologic changes can be induced in the skeletal muscle of mice by intraperitoneal injection of 5-HT (92). Three months after octreotide therapy, the patient had no clinical evidence of myopathy, with improvement in electromyographic features (185).

### **Biochemical responses**

Reports conflict regarding the biochemical responses of patients with carcinoid tumors to octreotide. Richter and colleagues (179) reported a significant drop in 5-HT levels in eight patients treated with 150 mcg/d of octreotide but no changes in urinary 5-HIAA; others have found a drop in urinary 5-HIAA (26). Despite prolonging treatment of patients from 15 to 30 weeks, blood serotonin remained unchanged (182).

In our patients, urinary 5-HIAA dropped in almost all patients and normalized in one-third, and 50% of patients normalized their 24-hour 5-HIAA. Although few of our patients had a fall in their blood serotonin level, the overall post-octreotide values were not significantly lower than the pretreatment values.

There were no clinical correlations between the clinical responses and either urinary 5-HIAA or the blood serotonin level. In contrast, for patients in whom urinary 5-HIAA fell, there was clinical improvement in one or more of the symptoms. This may reflect that multiple etiologic factors are involved in the symptomatology of carcinoid tumors. In our patients, those who responded clinically required no more than 500 mcg/d of octreotide to control their symptoms, although we have examined the response to higher doses in certain instances.

A strong positive linear relationship is noted between serum and plasma CGA levels. No correlation existed between plasma octreotide levels or LAR dose and the static, absolute plasma/serum CGA levels. A statistically significant inverse relationship was found between the frequency of flushing and the CGA levels ( $P = 0.0372$ ) (3).

### **Effects of octreotide on tumor growth, metastases, and survival**

Because of the slow growth of carcinoid tumors, it is difficult to assess the effect of octreotide on tumor growth or regression. Shrinkage of liver metastases in patients with carcinoid (163) (166) and other functioning pancreatic neuroendocrine tumors (190) has been reported. We have had variable experiences. The relationship between tumor size and growth and the biochemistry is not a simple one. In one patient, the tumor clearly shrank, but ACTH levels rose to the 2,000 to 3,000 pg/mL range. On molecular sieve chromatography, the ACTH coeluted with native ACTH, but the patient has no clinical features of Cushing's syndrome, is gaining weight, and has no diarrhea or flushing. Another patient had progression of tumor growth after 18 months of octreotide therapy, yet there was a dramatic fall in blood serotonin values and the patient is entirely asymptomatic. The opposite also is not unusual, wherein there is no change in tumor size, a very well patient, and hormonal levels that are unaffected by octreotide even at doses as high as 1,000  $\mu\text{g}/\text{d}$  (63).

Our longitudinal follow-up CT data for our patients showed some tumor regression in only two cases and, in one case, the tumor infarcted. One third of the patients showed progression and half the cases showed no changes on the CT scan when followed for up to 2 to 5 years. It appears that cessation or reversal of growth occurs in about two-thirds of patients with carcinoid tumors who are treated with octreotide.

Octreotide increases the median survival of patients with metastatic carcinoid tumor from 11 to 33 months. Higher doses of octreotide may yield even better outcomes. A recent phase II study of apudomas showed no major tumor regressions but a 50% disease stabilization rate (191). A study of 14 patients with neuroendocrine tumor who received doses of octreotide of up to 9,000  $\mu\text{g}/\text{d}$  showed partial responses in four patients (31%) and disease stabilization in two patients (16%) (192). Radiographic evidence of tumor necrosis was seen in five patients, but this did not correlate with response. A larger study of 55 patients showed an objective response rate of 37% (193). It is reasonable to offer octreotide at initial doses of 150  $\mu\text{g}$  subcutaneously t.i.d. for control of symptoms and palliation. Escalation of the dose to 250 or even 1000  $\mu\text{g}$  t.i.d. may be necessary in patients with a large tumor burden, but there is no evidence that higher doses have a greater likelihood of inducing actual tumor regression. When there is clear evidence that tumor growth is not contained by octreotide, alternative forms of treatment should be considered (129). Other therapeutic options are discussed in more detail below.

### **Internal Radiotherapy Delivered by Meta Iodo Benzyl Guanidine (MIBG) and other agents:**

There is the potential to deliver therapeutic doses of radiation to those tumors in which there is intense and prolonged tumor uptake of tracer doses of MIBG. At present, therapy for carcinoid tumor with MIBG is considered to be highly experimental. Based on the experience with other neuroendocrine tumors, situations in which this therapy may be considered include carcinoid lesions not readily treatable by alternative modalities, and patients with life expectancies sufficient to permit beneficial effects to become apparent (e.g., > 6 months or 1 year).

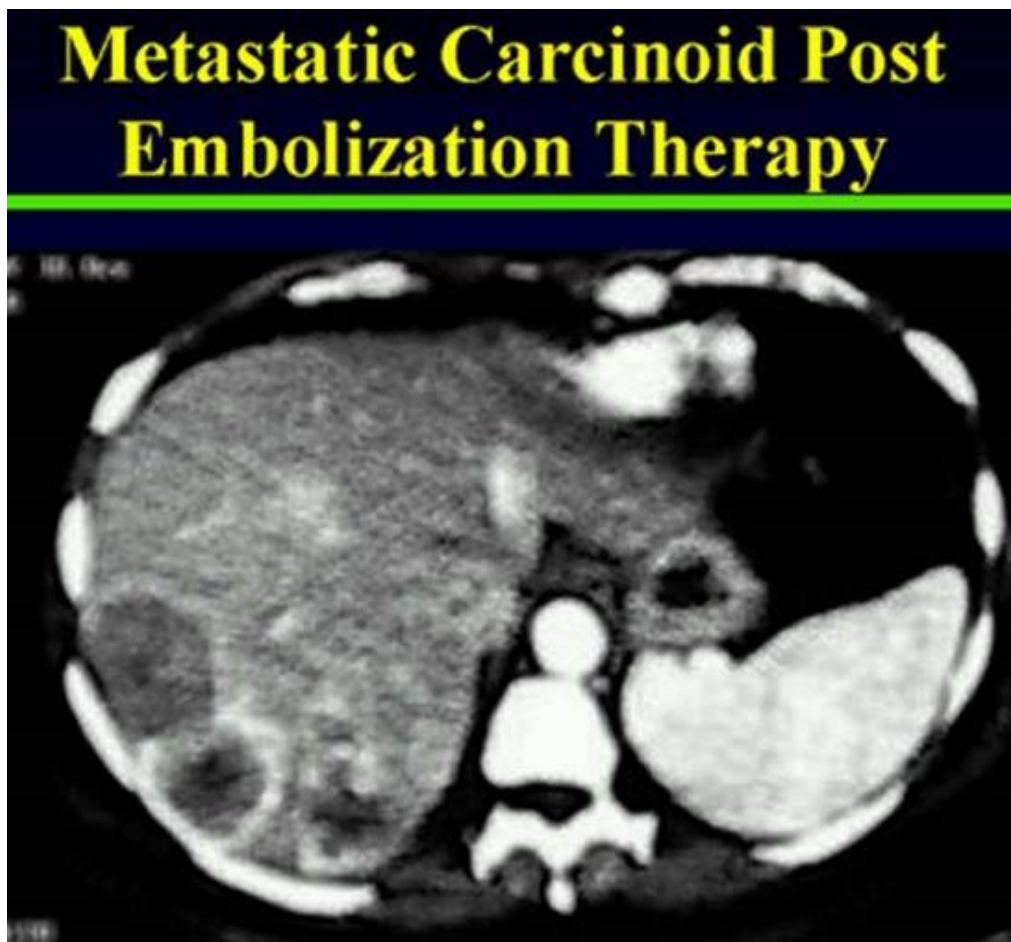Target-to-background ratios with tracer doses that achieve diagnostic imaging may not, however, always permit the delivery of therapeutic radiation when large doses of activity are administered (194) (195) (189-191). Prior to considering such treatment, it is critical to undertake dosimetric studies for whole-body and blood-absorbed radiation dose using tracer doses to guide the size of therapeutic administrations (108) (194) (195) (189-191). The bone marrow

and, especially, the platelets appear to be the dose-limiting tissues for MIBG therapy. Typical doses to date have been in the range of 100 to 250 mCi per administration, with cumulative doses sometimes exceeding 600 mCi. In addition, if at all possible, the absorbed radiation dose to one or more representative tumors should be determined from serial scintigraphic images. From these, the initial uptake and biologic reaction time of retention can be determined; the use of conjugate view technique with the inclusion of standard sources may be especially helpful (36). Tumor volume also must be determined by CT or another modality. This can be used with Medical Internal Radiation Dose (MIRD) formulas to calculate the radiation-absorbed dose (196).

The ability of somatostatin analogues to bind to GEP tumors has suggested other novel therapeutic approaches. Conjugating somatostatin with high energy gamma-emitters, short-acting alpha-particle emitters, or tumoricidal toxins such as ricin or modified diphtheria toxin has been proposed (197) (198). Although similar strategies have been used to deliver tumoricidal agents to other types of tumors, there are few data thus far on the therapeutic effectiveness of such an approach in GEP tumors. One study did show that high dose  $^{111}\text{In}$ -pentetreotide therapy is effective in stabilizing progression of disseminated neuroendocrine tumors (Delpassand, E.S., Safety and Efficacy of radionuclide therapy with multiple 500 mCi doses of In-111 Pentetreotide in patients with progressive NETs.)

### **INTERVENTIONAL RADIOLOGIC TECHNIQUE:**

For those with advanced liver dominant disease, liver directed therapy through interventional radiologic techniques is part of the treatment paradigm. Liver directed therapy may include bland embolization, chemo-embolization, or radio-embolization. Hepatic artery embolization has proved to be a relatively safe procedure for the palliation of carcinoid syndrome related to excessive hormone production from hepatic carcinoid metastases (199) (Figure 33). Generally such patients have extensive hepatic metastases not amendable to surgical approaches.



**Figure 33.**

This method usually is beneficial to the patients whose hepatic metastases have failed to respond to chemotherapy and other pharmacologic therapy (92). Gelfoam powder (particle sizes, 80–200 $\mu$ M) and Ivalon particles (sizes, 149–250  $\mu$ M) are the agents frequently used for devascularization of the hepatic metastases.

Several authors have described their experience with hepatic artery ligation or embolization in patients with malignant carcinoid tumors (200) (201). In one study, the former procedure resulted in objective tumor responses in 9 of 19 patients, stable disease in 5 of 19 patients, and progressive disease in 4 of 19 patients when they were assessed 6 and 12 months after the procedure (201). Two patients died 1 and 3 months postoperatively from complications including liver abscesses, and the remainder of patients experienced mild abdominal pain, fever, and fatigue that was self-limiting. Hepatic artery gelfoam embolization performed in eight patients resulted in three objective responses and five with stable disease. Toxicity from this procedure included fever, abdominal pain, nausea, and elevation of serum hepatic enzymes, which returned to normal within 12 days. Overall, the duration of palliation tends to be short-lived (157). Hepatic arterial occlusion combined with sequential chemotherapy has resulted in an 80% response rate, with a median duration of 18 months (202). Although hepatic artery occlusion may produce subjective and objective responses in the majority of highly selected patients, the toxicity and duration of responses resulting from this therapy generally do not support its routine use (157).

## EXTERNAL BEAM RADIATION THERAPY

No available data support the use of external beam radiation therapy in patients with metastatic carcinoid unless they have symptomatic bone metastases, spinal cord compression, or bronchial obstructions that are all amenable to this modality of treatment.

### Radiochemoembolization

There are two components: embolization and brachytherapy. The embolization procedure is defined with the angiographic endpoints of embolization and stasis with the need to modify the delivery according to angiographic findings under fluoroscopy. Brachytherapy is defined as the administration and delivery of internal radiation with modification of dose based on tumor and target volume (4).

Currently two different <sup>90</sup>Yttrium microsphere (Table 22) products, glass microsphere and resin microsphere are available. Resin microspheres have received FDA premarket approval for hepatic metastasis from colorectal cancer, concurrent with flurodeoxyuridine (FUDR). There has been no direct comparison of the efficacy of the two microsphere products (203). There is only anecdotal experience with use of these agents in carcinoid patients.

<sup>90</sup>Yttrium microsphere therapy is a complex procedure that requires a multidisciplinary approach for safety and success as shown in Figure 34 (4). The benefits of internal radiation to the liver includes low toxicity, low amount of radiation used, and ability to retreat the liver for new lesions or incompletely destroyed original lesions. Extensive prior systemic and non-radioactive hepatic therapy does not interfere with the successful delivery of <sup>90</sup>Yttrium microspheres (203).

<sup>90</sup>-Yttrium based therapy is effective at controlling carcinoid symptoms, but has not been shown to improve survival (204). In general, these patients undergo the procedure in three stages: 1. Mapping stage when the arterial anatomy of the liver is evaluated and potential shunting to the lung and foregut is determined, 2. Treatment of disease dominant liver lobe, 3. Treatment of remaining liver. In general, these procedures are performed as an outpatient and are well tolerated with pain or peptic ulceration as the major complications. Patients with poor hepatic synthetic function are not candidates.

A new emerging technology for treating systemic carcinoid is peptide receptor radiotherapy (PRRT) (205). Like nuclear functional imaging, this treatment modality uses the somatostatin receptor as a target of treatment. However, instead of carrying an imaging isotope, the somatostatin analogue is chelated to a beta-emitting cytotoxic isotope, <sup>90</sup>-Yttrium or <sup>177</sup>-Lutetium. These therapies can have both rapid and delayed activity. Survival for this therapy has been reported to



be as great as 44 months. 177-Lutetium-somatostatin analogue is currently being evaluated in a Phase 3 clinical trial in the United States and is available at select centers around the world.

Consultation-Tumor Board

Medical Oncology Surgical Oncology

Nuclear Medicine Radiation Oncology

Intervention Radiology

Consensus for the liver directed therapy with Y90 Microsphere

Hepatic angiogram and

Protective embolization of extra hepatic vessels and Microaggregated albumin

(99mTCMAA)

CT and MRI and Complimentary studies FDG PET (neuroendocrine)

Pretreatment screening evaluation

Team reviews imaging, proposed dose, planning tumor volume and optimal catheter placement for radioembolisation

Bremsstrahlung (Gamma) Scan Post-implant QA Documentation

Delivery of Y90 Microspheres to the planning treatment volume

1-2 weeks

Vessel mapping

Tumor mapping

1-2 weeks

Safe Delivery Achievable

Same day

Liver predominant Dz

1 week

**Table 22** *Treatment algorithm for 90yttrium microsphere brachytherapy*

### **Chemotherapy**

In malignant carcinoid tumor, chemotherapy has not been shown to be effective for most patients, and this approach should still be considered investigational. The single agent most studied in carcinoid tumor is 5-fluorouracil, which accounted for observed response rates of 26 and 18% in single-institution and multi-institutional trials, respectively (206) (207). Melia and colleagues (208) reported a high complication rate with little benefit when 5-fluorouracil was administered by intra-arterial, portal, or peripheral intravenous routes. Few responses were observed following intravenous doxorubicin, 60 mg/m<sup>2</sup>, every 3 to 4 weeks (159) (157) (209). Despite well-established activity in other

GEP cancers, streptozotocin has not demonstrated significant efficacy in patients with carcinoid tumor (181) (159). Among other single agents, there have been anecdotal reports of objective responses to dacarbazine and dactinomycin (209) (210), however, a study of 32 patients demonstrated that dactinomycin or dacarbazine had little activity against metastatic carcinoid tumor (211). A larger, more recent study confirmed the ineffectiveness of dacarbazine in carcinoid tumor. Phase II studies in evaluable patients with carcinoid tumor have shown rare objective responses to either cisplatin or etoposide (206) (212) (213). No responses to carboplatinum were seen in a series of 20 patients.

Initial experience with combination chemotherapy suggested that this modality might be effective against malignant carcinoid tumor. Early, nonrandomized studies of combinations of cyclophosphamide plus methotrexate, streptozotocin plus 5-fluorouracil, or weekly streptozotocin plus doxorubicin reported response rates in excess of 50%; however, rigid criteria for response were not always employed and complete responses were not seen (8) (159) (207) (213) (214). Based on these observations, the Eastern Cooperative Oncology Group conducted a series of multi-institutional, randomized trials of combinations that all contained streptozotocin, despite the low activity of this drug when used alone. In two studies of 170 evaluable patients, the response rates ranged from 23 to 33%, and there was no evidence for any difference between streptozotocin administered every 6 weeks or every 10 weeks plus 5-fluorouracil versus streptozotocin plus cyclophosphamide versus single-agent doxorubicin (159) (207) (215). In a prospective trial, the Southwest Oncology Group reported similar response rates of brief duration following a combination of 5-fluorouracil, cyclophosphamide, and streptozotocin with or without doxorubicin (216). Only 10% of 31 patients had objective response following streptozotocin and 5-fluorouracil in another prospective clinical trial reported by Oberg and colleagues (217).

Feldman (218) suggested that streptozotocin alone or in combination with 5-fluorouracil may be beneficial for patients with foregut carcinoid tumors, in contrast to patients with midgut carcinoid tumors. This contrasts with the Eastern Cooperative Oncology Group experience, (207) however, and remains unsubstantiated. Thus, in the absence of randomized trials that contain a no-treatment arm, there is no persuasive evidence that single-agent or combination chemotherapy provides any significant impact on disease progression or on survival in patients with malignant carcinoid tumor.

### **Combined Modality Therapy:**

Combined modality therapy, such as the use of adjuvant chemotherapy either before or following surgery, remains undefined. In the absence of well-established activity for chemotherapy in metastatic carcinoid, there is no rationale to support the use of adjuvant chemotherapy. In contrast, preliminary results of the prospective experience of sequential hepatic artery occlusion and alternating combination chemotherapy at the Mayo Clinic are of considerable interest (157) (209) (219). Following hepatic artery occlusion by surgical ligation or percutaneous embolization, 21 patients were treated with dacarbazine, 250 mg/m<sup>2</sup> daily for 5 days, plus doxorubicin, 60 mg/m<sup>2</sup>, alternating every 4 to 5 weeks with 5-fluorouracil, 400 mg/m<sup>2</sup> daily for 5 days, plus streptozotocin, 500 mg/m<sup>2</sup> daily for 5 days until maximum response was observed. Using this combined-modality approach, Moertel (157) reported a hormonal response rate of 86%, with a median duration of response of 2 years. The toxicity of this approach notwithstanding, and pending publication of the Mayo Clinic experience or other confirmatory experience, sequential hepatic artery occlusion and combination chemotherapy may be considered for selective patients with symptomatic metastatic carcinoid refractory to somatostatin therapy. Temodar and Xeloda may have a slight benefit in patients with neuroendocrine tumors but more controlled trials are needed to determine the role and benefits of them in NET.

### **Biologic Therapy**

Interferon may be useful in patients with refractory symptoms of carcinoid syndrome despite SA treatment. In one study, 17 of 36 patients (47%) with metastatic carcinoid tumor who were treated with human leukocyte interferon, 3 to 6 million units per day subcutaneously, had objective hormonal responses for a median duration of 34 months (217). Four patients had significant tumor regression, and two complete responses were noted. A second study randomized 20 patients to treatment with either a combination of streptozotocin and 5-fluorouracil or human leukocyte interferon, 6

million units five times per week (220). After 6 months, 50% of the patients treated with interferon had an objective hormonal response, and no patients treated with chemotherapy responded. Finally, Oberg and colleagues (217) conducted a study in 20 patients with malignant carcinoid tumor that suggested recombinant human interferon- $\alpha$ -2b,  $5 \times 10^6$  U/m<sup>2</sup> three times a week subcutaneously for 6 months, was as active as leukocyte interferon, and that the two agents may not be cross-resistant. In this study, the development of neutralizing interferon antibodies correlated with a lack of response to interferon in three patients.

Additional positive outcomes using recombinant human interferon- $\alpha$ -2b have been reported by several additional groups after small prospective trials (221) (222). Hanssen and colleagues (221) also gave interferon following hepatic artery embolization, and they observed five of seven patients with objective tumor and hormonal responses after 12 months. A recent review by Oberg (223) of 300 patients with carcinoid tumor treated with interferon- $\alpha$  for a median of 2.5 years concluded that this agent has significant antitumor effects in 70 to 80% of patients, as manifested by biochemical control and inhibition of tumor growth. Tumor progression generally occurred within 3 to 9 months after cessation of the drug. IFN $\alpha$  may reduce flushing and diarrhea in 40-50% refractory to SAs, although objective tumor regression is less common (224). However, benefits are usually transient and there are limiting side effects including fatigue, depression, and flu-like symptoms.

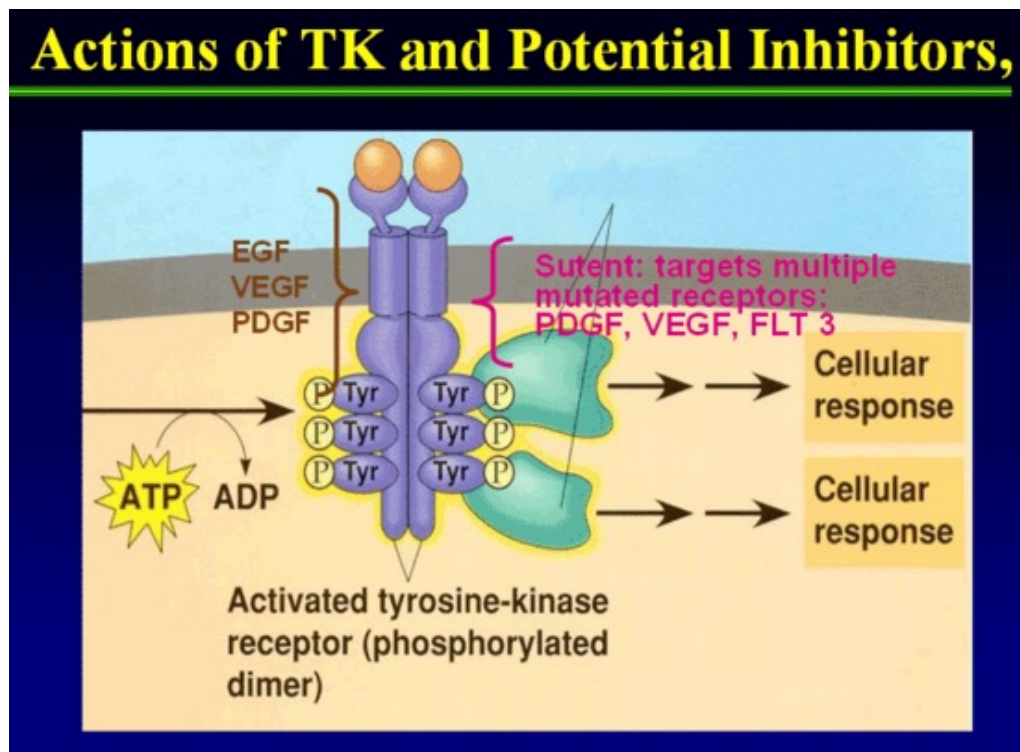
These encouraging results with interferon must be interpreted with caution, however, considering the results from another prospective study using interferon reported by Moertel and colleagues (225). In this study, 27 previously treated patients with malignant carcinoid tumors were treated with recombinant human interferon- $\alpha$ -2a,  $12$ – $24 \times 10^6$  U/m<sup>2</sup> subcutaneously three times weekly for 8 weeks. Nine of 23 patients (39%) with elevated 5-HIAA had objective responses for a median of 40 weeks (range, 23–127 weeks), and 4 of 20 patients (20%) had objective tumor responses for a median of 7 weeks (range, 4–26 weeks). The flu-like syndrome and fatigue side effects from interferon were common in this study, requiring dose reduction in 10 patients and causing deterioration of performance status in 50% of all patients. In addition to differences in dose and observed toxicities, the variable response rates found in these reported studies may relate to the use of different recombinant interferon subtypes (alpha-2a vs. alpha-2b) and the subsequent development of neutralizing antibodies (226). The role for the combination of recombinant human interferon- $\alpha$ -2a and doxorubicin in patients with advanced pancreatic endocrine or carcinoid tumors currently is under investigation (227). A series of 19 patients treated with interferon- $\alpha$  combined with octreotide showed a 92% median biochemical response rate for a period of 10 months (193).

### **Tyrosine Kinase (TK) inhibitors in Carcinoid:**

Receptor tyrosine kinases (RTKs) are transmembrane proteins containing extracellular ligand-binding domains and intracellular catalytic domains (Figure 35). RTKs are activated following binding of their cognate ligands and many of the processes involved in tumor growth, progression, and metastases are mediated by signaling molecules acting downstream from these proteins (Figure 34)

Several members of the split-kinase domain family of RTKs are implicated in deregulated/ autocrine proliferation and survival of solid and hematologic cancer cells. These include the platelet-derived growth factor receptors (PDGFR $\alpha$  and  $\beta$ ); vascular endothelial growth factor receptors (VEGFR) Type 1 and 2 (FLT1 and FLK1/KDR); the stem cell factor (SCF) receptor, KIT; and the FLT3-ligand receptor. In addition, PDGFR and VEGFR are implicated in tumor-dependent angiogenesis (228).

Neuroendocrine tumors are characterized by abundant vasculature. Inhibition of angiogenesis would therefore be expected to result in growth inhibition and regression of these tumors. A number of tumors, including NET, aberrantly express both the vascular endothelial growth factor (VEGF) ligand and its Flk-1/KDR receptor (VEGFR), both of which play critical roles in tumor angiogenesis. Investigation of novel angiogenesis inhibitors such as sunitinib in patients with pancreatic islet cell tumors is therefore of great interest. Tyrosine kinase inhibitors like sunitinib acts through the receptors for VEGF and PDGF, and also blocks signalling through the KIT, FLT3 and RET pathways.



**Figure 34** Actions of Tyrosine Kinase (TK) and potential inhibitor.

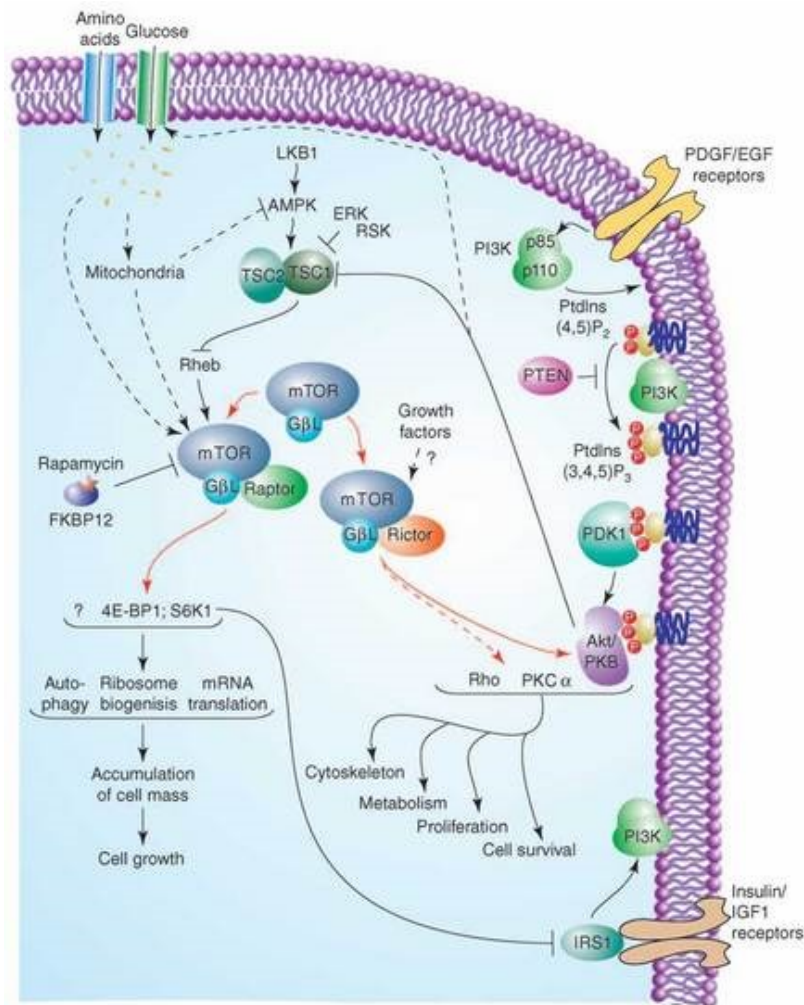
### **The mammalian target of rapamycin (mTOR) pathway in Neuroendocrine Tumors:**

The mTOR pathway is a key regulator of proliferation and growth of cells (Figure 36). mTOR is a threonine kinase that mediates downstream signaling from IGFi/SSA, VEGFi and VEGF TKIs signaling pathways implicated in neuroendocrine tumor growth (229). Activation of PI3K/AKT/mTOR pathways has been shown to increase translation of proteins regulating cell cycle progression (Figure 35, 36).

The mTOR pathway integrates signals from growth factors to regulate metabolism and ribosome synthesis. Deregulation of mTOR is associated with diverse human diseases including cancer and diabetes (10). Rapamycin binds to the FKBP12 protein to form a drug-

receptor complex that then interacts with and perturbs a large protein kinase called TOR (target of rapamycin) (10). Although the function of TOR is far from well understood, it is increasingly clear that TOR is the central component of a complex signaling network that regulates cell growth and proliferation. Rapamycin does not perturb all mTOR functions because mTOR exists in two distinct multi-protein complexes and only one binds to FKBP12-rapamycin (Figure 37). This complex is composed of mTOR as well as the GbL and raptor proteins, and rapamycin inhibits its kinase activity in vitro (10). The rapamycin-insensitive complex also contains mTOR and GbL, but, instead of raptor, a different protein called rictor.

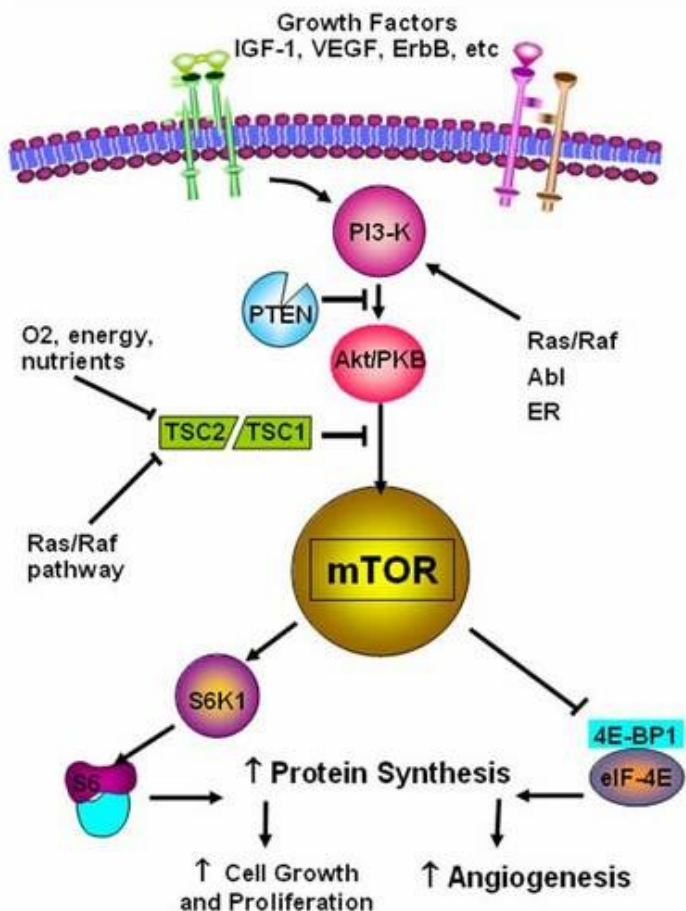
FKBP12-rapamycin binds to a region adjacent to GbL and the mTOR kinase domain but >1000 amino acids away from where raptor binds to mTOR (10). Perhaps FKBP12-rapamycin induces a conformational change in mTOR that weakens the binding of raptor and perturbs its capacity to recruit substrates (see below). It is also unclear why FKBP12-rapamycin does not bind the rictor-containing mTOR complex. Rictor or an unidentified component of the complex may block or occupy the FKBP12-rapamycin binding site or allosterically destroy the FKBP12-rapamycin binding pocket. As the rictor-mTOR complex cannot bind FKBP12-rapamycin, it is unlikely to mediate mTOR functions discovered through their sensitivity to acute treatment with the drug. Akt/PKB is a key component of the insulin/PI3K signaling pathway and modulates cell survival and proliferation through downstream. Thus, through the rictor- and raptor-containing complexes, mTOR affects cell size, shape and number (10)



**Figure 35. A**

model of the mTOR and PI3K/Akt signaling pathways and their interconnections. Two mTOR-interacting proteins, raptor and rictor, define distinct branches of the mTOR pathway. The raptor–mTOR pathway regulates cell growth (accumulation of cell mass) through S6K1 and 4E-BP1 as well as unknown effectors. It responds to nutrients and growth factors in part through the upstream regulators TSC1/2 and rheb. The rapamycin-insensitive rictor–mTOR pathway regulates Akt/PKB, PKC $\alpha$ , Rho/Rac to control cell survival, proliferation, metabolism and the cytoskeleton. The binding of growth factors to cell surface receptors activates PI3K to generate PtdIns P3 and recruits the PDK1 kinase and Akt/PKB to the plasma membrane. Akt/PKB is activated by its phosphorylation on two different sites. The rictor–mTOR complex phosphorylates Akt/PKB on Ser473 in the hydrophobic motif which may facilitate the phosphorylation by PDK1 of the activation loop of Akt/PKB on Thr308. How the rictor–mTOR complex is regulated is unknown. Dashed lines indicate interactions that are likely not direct (10).

## The PI3K/Akt/mTOR Pathway



**Figure 36**

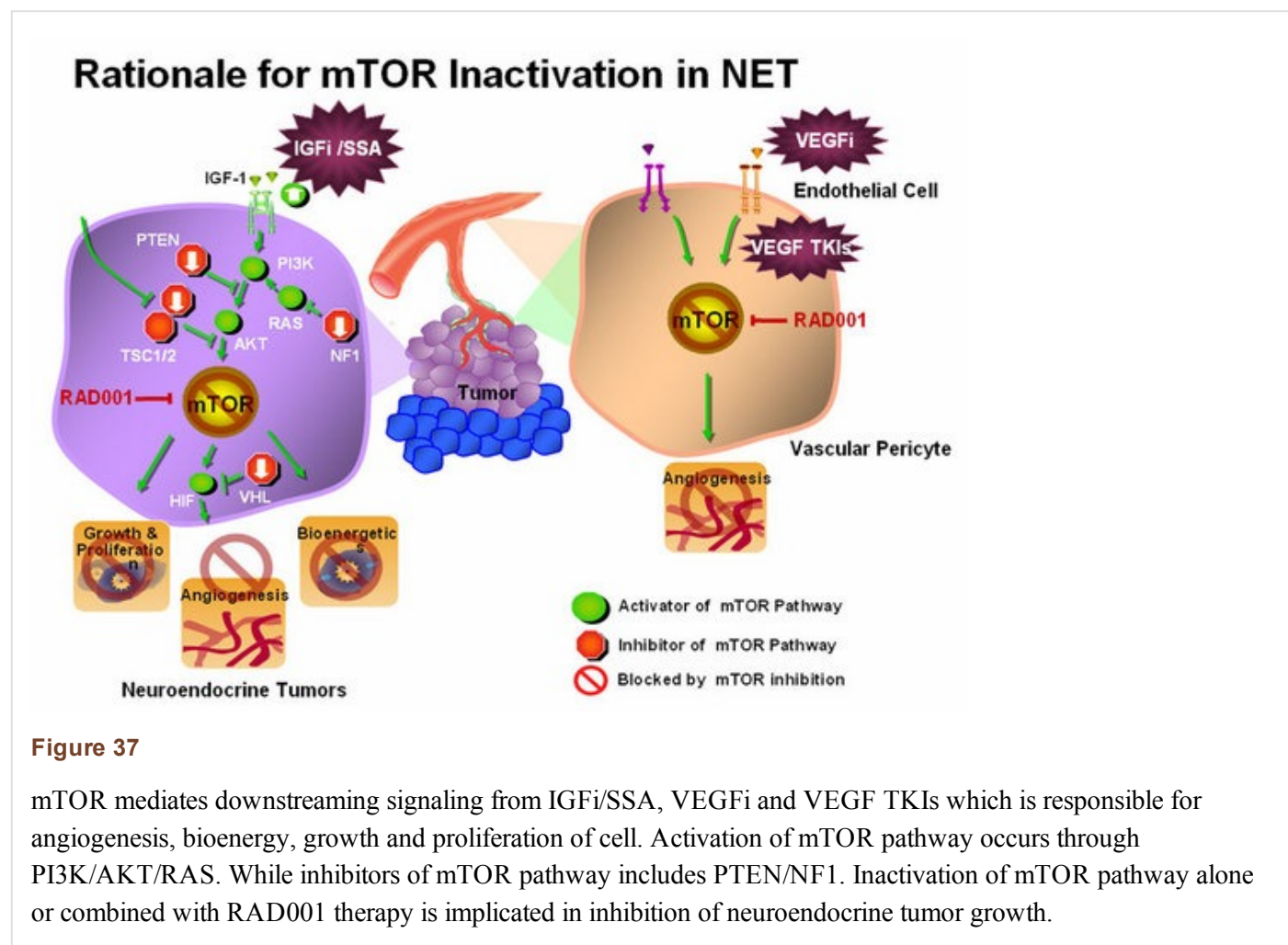
PI3K/Akt pathway integrates signals from growth factor receptors, stress and available nutrients. mTOR, an intracellular serine-threonine kinase is centrally located downstream of PI3K. mTOR is a master regulator involved in translation of proteins critical for cell growth, proliferation and angiogenesis in response to upstream signals.

### Regulation of cell proliferation and angiogenesis through various growth factors:

Insulin like Growth Factor (IGF)-I is a potent growth factor, exerting its actions by both endocrine and paracrine/autocrine mechanisms. The action of the IGFs in both the circulation and tissues is tightly regulated by a family of high-affinity IGF binding proteins (IGFBPs) (230). The synthesis of the IGFBPs in various tissues is under partial control of IGF-I. IGF-I exerts its biological effect by binding to the transmembrane type 1 IGF receptor, whose activation leads to the extensive tyrosyl-phosphorylation of insulin receptor substrate-1, which acts as a docking protein for the downstream signal transduction pathways (230).

Angiogenesis, the formation of new blood capillaries, is an important component of embryonic vascular development, wound healing, and organ regeneration, as well as pathological processes such as diabetic retinopathies, atherosclerosis and tumor growth (231). Vascular endothelial growth factor (VEGF) is essential for many angiogenic processes both in normal and pathological conditions. The binding of VEGF to its cognate receptors induces dimerization and subsequent phosphorylation of the receptors leading to the activation of several intracellular signaling pathways. In particular, the angiogenic signals triggered by VEGF are mediated through the activation of phospholipase C $\alpha$  (PLC $\alpha$ ) (231), protein kinase C (PKC), and subsequently the extracellular regulated kinases 1 and 2 (ERK1/2) (231).

VEGF also regulates vascular permeability and endothelial cell migration by stimulating the Src family kinases, in particular c-Src, and the phosphatidylinositol 3'-OH-kinase (PI3K)/Akt pathway-dependent endothelial nitric oxide synthase (eNOS) activation. The importance of VEGF-induced signaling is demonstrated in that the genetic inactivation of either receptor leads to a complete lack of development of blood vessels in the embryo, and inactivation of VEGFR2 function dramatically impairs the growth of cancer cells in vivo (231).



Inhibitors of mTOR have shown early activity in number of cancers including neuroendocrine tumors (232). The mechanism whereby everolimus (RAD001) inhibit growth NETS is shown in [Figure 37](#).

Thirty seven patients with progressive neuroendocrine tumors were treated with mTOR inhibitor temsirolimus in one phase II study. The response rate was 5.6% with 63.9% of patients showed partial response or stable disease (233). RAD001 (everolimus) is a novel agent that is being studied in the treatment of neuro-endocrine tumours, and is known to interact with mTOR. Everolimus, A finitor, RAD001) an oral inhibitor of the mammalian target of rapamycin (mTOR), has been studied as an adjuvant to SAs in patients with advanced NET, although this has not been FDA approved for this indication. The combined effect of mTOR inhibitors RAD001 (everolimus;5mg/day) and depot octreotide (30mg/4weeks) showed partial response of 12% in carcinoid patients while 37% of patients had > 50% reduction in chromogranin A (234). In another Phase I study by Awada (2008) showed that daily therapy with RAD001 plus letrozole suggest anti-tumor activity in breast cancers (235).

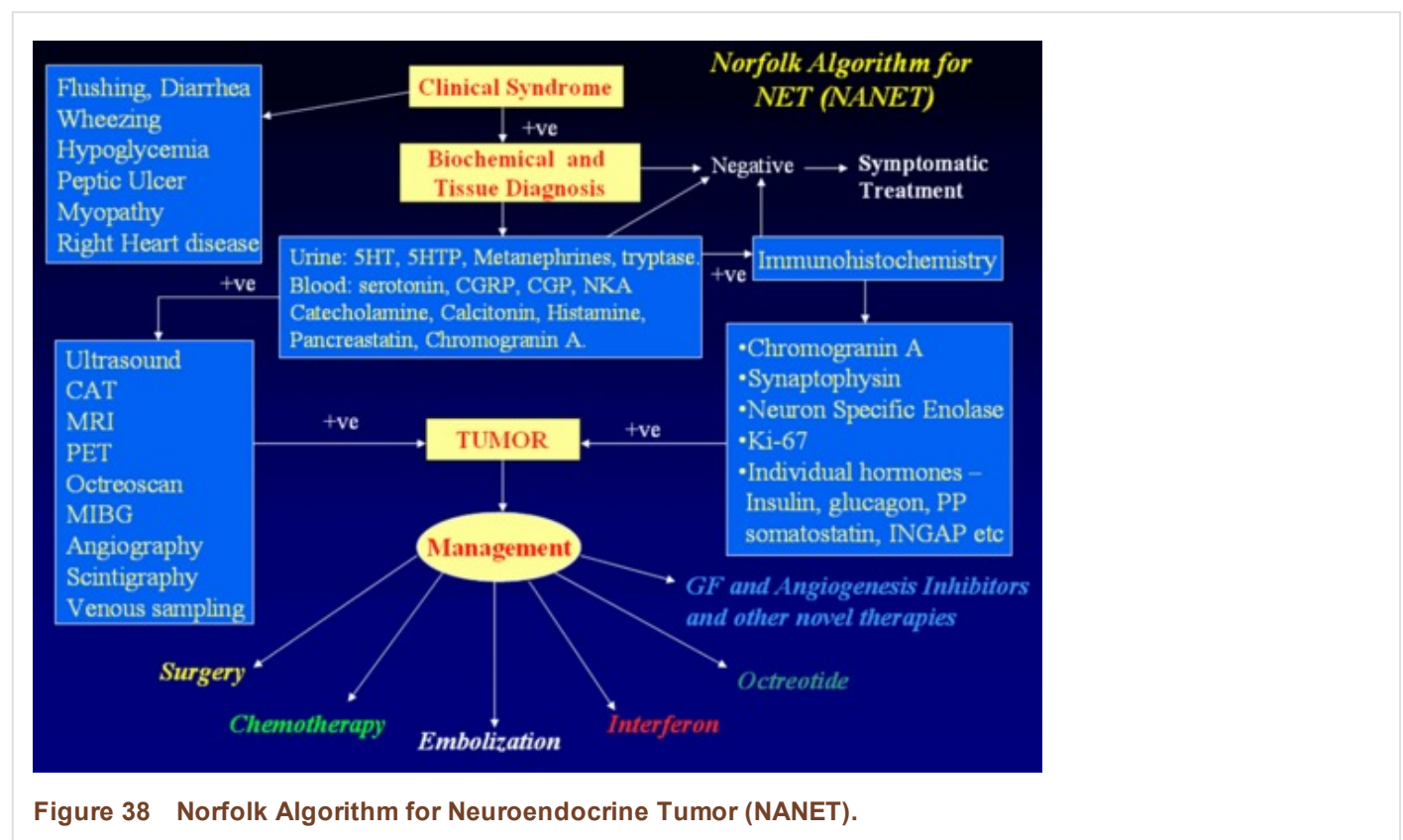
Grozonsky-Glasberg S (2007) found that treatment with octreotide and RAD001 inhibited proliferation and attenuated phosphorylation of all downstream targets of Akt: TSC2, mTOR, and p70S6K (226). Octreotide and RAD001 appear to act through a similar pathway and inhibit the Akt-mTOR-p70S6 kinase pathway downstream of Akt G (226).

The RADIANT-2 trial was a phase III, double blind placebo controlled study in patients with advanced NETs and carcinoid syndrome. In the initial study which included 429 patients with carcinoid syndrome, the median progression free survival improved by 5.1 months in the everolimus/octreotide arm compared with octreotide alone, however this just missed statistical significance. However there were randomization imbalances in the study. A subsequent reanalysis looked at treatment imbalances, and prognostic factors that may have affected outcomes in the original analysis. When adjusted for prognostic imbalances, the reanalysis found that everolimus plus octreotide resulted in a 38% reduction of risk of disease progression, and this was significantly different ( $P=0.003$ ).

Indeed, everolimus alone appears to have activity as a single agent. The RADIANT-3 trial was a phase III trial examining everolimus as first line therapy in patients with PNETS. A total of 410 patients were randomized to everolimus 10 ml once daily or placebo. The median progression free survival was 11 months with everolimus compared 4.6 months with placebo. The proportion of patients alive and progression free at 18 months was 34% with everolimus compared with 9% with placebo. Toxicity was mostly grade I or II (236).

### **Management summary:**

Any suspected case of carcinoid needs proper evaluation for the diagnosis and management of the patient. The schematic presentation of evaluation of carcinoid is described as follows in Figure 38.



**Figure 38 Norfolk Algorithm for Neuroendocrine Tumor (NANET).**

### **PROGNOSIS**

The general prognosis in carcinoid tumor is excellent compared with that of other visceral cancers.

A summary of many of the prognostic factors for carcinoid tumors is shown in Table 23

Based on a world literature of some 2,837 cases, the median 5-year survival rate for all cases is 82% (159).

### **Less Favorable Prognostic Factors for Carcinoid Tumors**



- **Age >50y**
- **Male gender**
- **Tumor site e.g. pancreas, colorectum**
- **Size and depth of penetration**
- **Lymph node metastases**
- **Hepatic metastases**
- **Symptomatic mode of discovery**
- **Nonsurgical curative likelihood**
- **Presence of the carcinoid syndrome**
- **Increased Chromogranin A, urinary 5-HIAA, TCT, gastrin and ACTH**
- **Proliferation indices**

If, however, the tumor is localized, then the 5-year survival is 94%, decreasing to 64% with regional lymph node involvement and 18% with distant metastases. A single-institution analysis of overall survival stratified by TNM stage revealed that 5-year survival rates were 100% for stage I and II tumors vs. 91% for stage III (locoregionally advanced) and 72% for stage IV tumors. The median overall survival for stage IV tumors was 103 months. Among stage III patients, survival differed significantly between patients with resectable mesenteric tumors (95% 5-year survival) vs. unresectable (78% 5-year survival) (237). Another analysis of 270 NETs (which included a combination of midgut and hindgut tumors) reported a 5-year disease-specific survival rate of 100% for patients with stage I and II tumors vs. 97% for stage III and 83% for stage IV tumors (238).

Davis and colleagues (18) reported a mean survival of 38 months from the first episode of flushing, with 25% of patients living for more than 6 years. With regional lymph node involvement, the figure falls to approximately 14 months, (239) and with urinary 5-HIAA in excess of 150 mg per 24 hours or inoperable tumors, median survival is only 11 months (159).

Some of the biochemical markers previously discussed are useful in determining prognosis. CgA is one such useful marker. Jensen et al. found that a reduction on CgA levels  $\geq 80\%$  after cytoreductive surgery for carcinoid tumors predicts symptom relief and disease control; it is associated with improved patient outcomes, even after incomplete cytoreduction (240).

Pancreastatin is one of the post-translational processing products of CgA and is an indicator of poor outcome when its concentration in plasma is elevated before treatment in patients with NETs. A level  $> 500\text{pmol/L}$  is an independent indicator of poor outcome. This marker is also known to correlate with the number of liver metastases, so it would be appropriate to use it in the follow-up of NET patients. Furthermore Stronge et al. found that an increase in pancreastatin levels following somatostatin analogue therapy is associated with a poor survival (241). Other studies have shown that pancreastatin should be measured prior to, during, and after treatment. Plasma levels of this marker above 5000 pg/ml pre-treatment were associated with increased peri-procedure mortality in patients with NETs that underwent hepatic artery chemoembolization (TACE) (242). These observations suggest that pancreastatin is potentially a very useful marker not only for diagnosis but more importantly for monitoring treatment response.

Neurokinin A has been shown to have strong prognostic value. Turner et al. in 2006 showed that in patients with midgut carcinoid that have raised plasma NKA, a reduction of this biochemical marker after somatostatin analog (SSA) therapy was associated with an 87% survival at one year compared with 40% if it increased. They also concluded that

any alteration in NKA predicts improved or worsening survival (1)

## **Summary and Conclusions:**

### **Carcinoid Tumors**

#### ***Table 24.***

- **Summary and Conclusions**
- **Small slow growing, episodic expression make diagnosis difficult, erroneous and late, need high index of suspicion**
- **Diagnosis complex with no single foolproof measures**
- **Major Clinical features are:**
  - **Flushing**
  - **Diarrhea**
  - **EMERGING NEW SYNDROMES that cause flushing such as NIPHS may be due to iatrogenic causes**
  - **Causes of symptoms not understood entirely**
  - **Symptomatic therapy effective**
  - **Always seek targeted primary therapy**
  - **Monitor**
    - **Tumor burden**
    - **Clinical responses**
    - **Biochemistry**
    - **Be aggressive. Use tumor debulking procedures judiciously**
    - **Tumor growth can be arrested**
      - **Carcinoids, Vipomas, Ppomas**
      - **ACTH, Calcitonin and Gastrin may be resistant**
      - **May require ancillary measures**
      - **Octreotide controls symptoms and may cause biochemical and tumor burden improvement, but LAR inconsistent and requires “escape therapy”**
      - **Must treat to target Octreotide Plasma Levels**
      - **New therapies with specific TK inhibitors, mTOR inhibitors and somatostatin analogs are in the pipeline**

## **Reference List**

1. Turner,GB, Johnston,BT, McCance,DR, McGinty,A, Watson,RG, Patterson,CC, Ardill,JE: Circulating markers of prognosis and response to treatment in patients with midgut carcinoid tumours. *Gut* 55:1586-1591, 2006. [PMC free article: PMC1860112] [PubMed: 16556667]
2. Won,JG, Tseng,HS, Yang,AH, Tang,KT, Jap,TS, Lee,CH, Lin,HD, Burcus,N, Pittenger,G, Vinik,A: Clinical features and morphological characterization of 10 patients with noninsulinoma pancreatogenous hypoglycaemia syndrome (NIPHS). *Clin Endocrinol (Oxf)* 65:566-578, 2006. [PubMed: 17054456]
3. Woltering,EA, Hilton,RS, Zolfoghary,CM, Thomson,J, Zietz,S, Go,VL, Vinik,AI, Vinik,E, O'Dorisio,TM, Mamikunian,G: Validation of serum versus plasma measurements of chromogranin a levels in patients with carcinoid tumors: lack of correlation between absolute chromogranin a levels and symptom frequency. *Pancreas* 33:250-254, 2006. [PubMed: 17003646]
4. Kennedy,A, Nag,S, Salem,R, Murthy,R, McEwan,AJ, Nutting,C, Benson,A, III, Espat,J, Bilbao,JI, Sharma,RA, Thomas,JP, Coldwell,D: Recommendations for radioembolization of hepatic malignancies using yttrium-90 microsphere brachytherapy: a consensus panel report from the radioembolization brachytherapy oncology consortium. *Int J Radiat Oncol Biol Phys* 68:13-23, 2007. [PubMed: 17448867]
5. Strosberg,J: Neuroendocrine tumours of the small intestine. *Best Pract Res Clin Gastroenterol* 26:755-773, 2012. [PubMed: 23582917]
6. Lipton,A, Costa,L, Ali,S, Demers,L: Use of markers of bone turnover for monitoring bone metastases and the response to therapy. *Semin Oncol* 28:54-59, 2001. [PubMed: 11544577]
7. Kubota,A, Yamada,Y, Kagimoto,S, Shimatsu,A, Imamura,M, Tsuda,K, Imura,H, Seino,S, Seino,Y: Identification of somatostatin receptor subtypes and an implication for the efficacy of somatostatin analogue SMS 201-995 in treatment of human endocrine tumors. *J Clin Invest* 93:1321-1325, 1994. [PMC free article: PMC294095] [PubMed: 8132773]
8. Buchanan,KD, Johnston,CF, O'Hare,MM, Ardill,JE, Shaw,C, Collins,JS, Watson,RG, Atkinson,AB, Hadden,DR, Kennedy,TL, .: Neuroendocrine tumors. A European view. *Am J Med* 81:14-22, 1986. [PubMed: 2879446]
9. Woltering E, Mamikunian P, Zietz S, Krutzik S, Go.V., Vinik A, Vinik E, O'Dorisio T, Mamikunian G: Effect of Octreotide LAR Dose and Weight on Octreotide Blood Levels in Patients with Neuroendocrine Tumors (Abstract). *Pancreas* 31 : 4, 2005. [PubMed: 16258376]
10. Sarbassov,DD, Ali,SM, Sabatini,DM: Growing roles for the mTOR pathway. *Curr Opin Cell Biol* 17:596-603, 2005. [PubMed: 16226444]
11. Vinik,AI, Woltering,EA, Warner,RR, Caplin,M, O'Dorisio,TM, Wiseman,GA, Coppola,D, Go,VL: NANETS consensus guidelines for the diagnosis of neuroendocrine tumor. *Pancreas* 39:713-734, 2010. [PubMed: 20664471]
12. Vinik,AI, Anthony,L, Boudreaux,JP, Go,VL, O'Dorisio,TM, Ruzsniowski,P, Woltering,EA: Neuroendocrine tumors: a critical appraisal of management strategies. *Pancreas* 39:801-818, 2010. [PubMed: 20664478]
13. Yao,JC, Hassan,M, Phan,A, Dagohoy,C, Leary,C, Mares,JE, Abdalla,EK, Fleming,JB, Vauthey,JN, Rashid,A, Evans,DB: One hundred years after "carcinoid": epidemiology of and prognostic factors for neuroendocrine tumors in 35,825 cases in the United States. *J Clin Oncol* 26:3063-3072, 2008. [PubMed: 18565894]
14. Ito,T, Igarashi,H, Nakamura,K, Sasano,H, Okusaka,T, Takano,K, Komoto,I, Tanaka,M, Imamura,M, Jensen,RT, Takayanagi,R, Shimatsu,A: Epidemiological trends of pancreatic and gastrointestinal neuroendocrine tumors in Japan: a nationwide survey analysis. *J Gastroenterol* 2014. [PubMed: 24499825]
15. Lawrence,B, Gustafsson,BI, Chan,A, Svejda,B, Kidd,M, Modlin,IM: The epidemiology of gastroenteropancreatic neuroendocrine tumors. *Endocrinol Metab Clin North Am* 40:1-18, vii, 2011. [PubMed: 21349409]
16. Modlin,IM, Lye,KD, Kidd,M: A 5-decade analysis of 13,715 carcinoid tumors. *Cancer* 97:934-959, 2003. [PubMed: 12569593]
17. BIORCK,G, AXEN,O, THORSON,A: Unusual cyanosis in a boy with congenital pulmonary stenosis and tricuspid insufficiency. Fatal outcome after angiocardigraphy. *Am Heart J* 44:143-148, 1952. [PubMed: 14933318]

18. Davis,Z, Moertel,CG, McIlrath,DC: The malignant carcinoid syndrome. *Surg Gynecol Obstet* 137:637-644, 1973. [PubMed: 4730072]
19. Vinik A, O'Dorisio T, Woltering E, Go VL: Neuroendocrine Tumors: A Comprehensive Guide to Diagnosis and Management. 1 ed. Interscience Institute, 2006,
20. Solcia,E, Capella C,BR: Morphological and functional classification of endocrine cells and related growths in the gastrointestinal tract. *Gastrointestinal Hormones* 1: 1980.
21. Weil,C: Gastroenteropancreatic endocrine tumors. *Klin Wochenschr* 63:433-459, 1985. [PubMed: 2861306]
22. Wang,GG, Yao,JC, Worah,S, White,JA, Luna,R, Wu,TT, Hamilton,SR, Rashid,A: Comparison of genetic alterations in neuroendocrine tumors: frequent loss of chromosome 18 in ileal carcinoid tumors. *Mod Pathol* 18:1079-1087, 2005. [PubMed: 15920555]
23. Kytola,S, Hoog,A, Nord,B, Cedermark,B, Frisk,T, Larsson,C, Kjellman,M: Comparative genomic hybridization identifies loss of 18q22-qter as an early and specific event in tumorigenesis of midgut carcinoids. *Am J Pathol* 158:1803-1808, 2001. [PMC free article: PMC1891959] [PubMed: 11337378]
24. Choi,IS, Estecio,MR, Nagano,Y, Kim,dH, White,JA, Yao,JC, Issa,JP, Rashid,A: Hypomethylation of LINE-1 and Alu in well-differentiated neuroendocrine tumors (pancreatic endocrine tumors and carcinoid tumors). *Mod Pathol* 20:802-810, 2007. [PubMed: 17483816]
25. Carney,JA, Go,VL, Fairbanks,VF, Moore,SB, Alport,EC, Nora,FE: The syndrome of gastric argyrophil carcinoid tumors and nonantral gastric atrophy. *Ann Intern Med* 99:761-766, 1983. [PubMed: 6197001]
26. Wynick,D, Williams,SJ, Bloom,SR: Symptomatic secondary hormone syndromes in patients with established malignant pancreatic endocrine tumors. *N Engl J Med* 319:605-607, 1988. [PubMed: 2842676]
27. Eckhauser,FE, Lloyd,RV, Thompson,NW, Raper,SE, Vinik,AI: Antrectomy for multicentric, argyrophil gastric carcinoids: a preliminary report. *Surgery* 104:1046-1053, 1988. [PubMed: 3194832]
28. Akerstrom,G: Management of carcinoid tumors of the stomach, duodenum, and pancreas. *World J Surg* 20:173-182, 1996. [PubMed: 8661814]
29. Rindi,G, Bordi,C, Rappel,S, La,RS, Stolte,M, Solcia,E: Gastric carcinoids and neuroendocrine carcinomas: pathogenesis, pathology, and behavior. *World J Surg* 20:168-172, 1996. [PubMed: 8661813]
30. Ruzniewski,P, Delle,FG, Cadiot,G, Komminoth,P, Chung,D, Kos-Kudla,B, Kianmanesh,R, Hochhauser,D, Arnold,R, Ahlman,H, Pauwels,S, Kwekkeboom,DJ, Rindi,G: Well-differentiated gastric tumors/carcinomas. *Neuroendocrinology* 84:158-164, 2006. [PubMed: 17312375]
31. Oberg,K, Kvols,L, Caplin,M, Delle,FG, de,HW, Rindi,G, Ruzniewski,P, Woltering,EA, Wiedenmann,B: Consensus report on the use of somatostatin analogs for the management of neuroendocrine tumors of the gastroenteropancreatic system. *Ann Oncol* 15:966-973, 2004. [PubMed: 15151956]
32. Janson,ET, Holmberg,L, Stridsberg,M, Eriksson,B, Theodorsson,E, Wilander,E, Oberg,K: Carcinoid tumors: analysis of prognostic factors and survival in 301 patients from a referral center. *Ann Oncol* 8:685-690, 1997. [PubMed: 9296223]
33. Vinik,AI, Gonzales,MR: New and emerging syndromes due to neuroendocrine tumors. *Endocrinol Metab Clin North Am* 40:19-63, vii, 2011. [PubMed: 21349410]
34. Cameron,SJ, Doig,A: Cerebellar tumours presenting with clinical features of pheochromocytoma. *Lancet* 1:492-494, 1970. [PubMed: 4190179]
35. Wiedenmann,B, Franke,WW, Kuhn,C, Moll,R, Gould,VE: Synaptophysin: a marker protein for neuroendocrine cells and neoplasms. *Proc Natl Acad Sci U S A* 83:3500-3504, 1986. [PMC free article: PMC323544] [PubMed: 3010302]
36. Simpson,S, Vinik,AI, Marangos,PJ, Lloyd,RV: Immunohistochemical localization of neuron-specific enolase in gastroenteropancreatic neuroendocrine tumors. Correlation with tissue and serum levels of neuron-specific enolase. *Cancer* 54:1364-1369, 1984. [PubMed: 6088026]
37. Feldman,JM: Urinary serotonin in the diagnosis of carcinoid tumors. *Clin Chem* 32:840-844, 1986. [PubMed: 2421946]

38. Melmon, KL, Sjoerdsma, A, Oates, JA, LASTER, L: TREATMENT OF MALABSORPTION AND DIARRHEA OF THE CARCINOID SYNDROME WITH METHYSERGIDE. *Gastroenterology* 48:18-24, 1965. [PubMed: 14252749]
39. Alumets, J, Hakanson, R, Ingemansson, S, Sundler, F: Substance P and 5-HT in granules isolated from an intestinal argentaffin carcinoid. *Histochemistry* 52:217-222, 1977. [PubMed: 885735]
40. Oates, JA, Pettinger, WA, Doctor, RB: Evidence for the release of bradykinin in carcinoid syndrome. *J Clin Invest* 45:173-178, 1966. [PMC free article: PMC292681] [PubMed: 5948092]
41. Strodel, WE, Vinik, AI, Jaffe, BM, Eckhauser, FE, Thompson, NW: Substance P in the localization of a carcinoid tumor. *J Surg Oncol* 27:106-111, 1984. [PubMed: 6207386]
42. Wilander, E, Grimelius, L, Portela-Gomes, G, Lundqvist, G, Skoog, V, Westermark, P: Substance P and enteroglucagon-like immunoreactivity in argentaffin and argyrophil midgut carcinoid tumours. *Scand J Gastroenterol Suppl* 53:19-25, 1979. [PubMed: 384502]
43. Lucas, KJ, Feldman, JM: Flushing in the carcinoid syndrome and plasma kallikrein. *Cancer* 58:2290-2293, 1986. [PubMed: 2428458]
44. Pernow, B, WALDENSTROM, J: Determination of 5-hydroxytryptamine, 5-hydroxyindole acetic acid and histamine in thirty-three cases of carcinoid tumor (argentaffinoma). *Am J Med* 23:16-25, 1957. [PubMed: 13444287]
45. Feldman, JM: Increased dopamine production in patients with carcinoid tumors. *Metabolism* 34:255-260, 1985. [PubMed: 3974452]
46. Theodorsson-Norheim, E, Norheim, I, Oberg, K, Brodin, E, Lundberg, JM, Tatemoto, K, Lindgren, PG: Neuropeptide K: a major tachykinin in plasma and tumor tissues from carcinoid patients. *Biochem Biophys Res Commun* 131:77-83, 1985. [PubMed: 2412557]
47. Strodel, WE, Vinik, AI, Lloyd, RV, Glaser, B, Eckhauser, FE, Fiddian-Green, RG, Turcotte, JG, Thompson, NW: Pancreatic polypeptide-producing tumors. Silent lesions of the pancreas? *Arch Surg* 119:508-514, 1984. [PubMed: 6143548]
48. Feldman, JM, O'Dorisio, TM: Role of neuropeptides and serotonin in the diagnosis of carcinoid tumors. *Am J Med* 81:41-48, 1986. [PubMed: 2432780]
49. Vinik, AI, Achem-Karam, S, Owyang, C: Gastrointestinal hormones in clinical medicine. *Spec Top Endocrinol Metab* 4:93-138, 1982. [PubMed: 6190239]
50. UDENFRIEND, S, TITUS, E, WEISSBACH, H: The identification of 5-hydroxy-3-indoleacetic acid in normal urine and a method for its assay. *J Biol Chem* 216:499-505, 1955. [PubMed: 13271330]
51. Das, ML: A rapid, sensitive method for direct estimation of serotonin in whole blood. *Biochem Med* 6:299-309, 1972. [PubMed: 5048992]
52. Waalkes T P: The determination of serotonin (5-hydroxytryptamine. in human blood. *J Lab Clin Med* 55:824-829, 1959. [PubMed: 13654927]
53. Modlin, IM: Carcinoid syndrome. *J Clin Gastroenterol* 2:349-354, 1980. [PubMed: 6214577]
54. Sandler, M, Karim, SM, Williams, ED: Prostaglandins in amine-peptide-secreting tumours. *Lancet* 2:1053-1054, 1968. [PubMed: 4176865]
55. Aldrich, LB, Moattari, AR, Vinik, AI: Distinguishing features of idiopathic flushing and carcinoid syndrome. *Arch Intern Med* 148:2614-2610, 1988. [PubMed: 2461688]
56. Ahlman, H, Dahlstrom, A, Gronstad, K, Tisell, LE, Oberg, K, Zinner, MJ, Jaffe, BM: The pentagastrin test in the diagnosis of the carcinoid syndrome. Blockade of gastrointestinal symptoms by ketanserin. *Ann Surg* 201:81-86, 1985. [PMC free article: PMC1250622] [PubMed: 2578277]
57. Kaplan, EL, Jaffe, BM, Peskin, GW: A new provocative test for the diagnosis of the carcinoid syndrome. *Am J Surg* 123:173-179, 1972. [PubMed: 4622195]
58. Tormey, WP, FitzGerald, RJ: The clinical and laboratory correlates of an increased urinary 5-hydroxyindoleacetic acid. *Postgrad Med J* 71:542-545, 1995. [PMC free article: PMC2398246] [PubMed: 7479466]

59. Feldman, JM, Lee, EM: Serotonin content of foods: effect on urinary excretion of 5-hydroxyindoleacetic acid. *Am J Clin Nutr* 42:639-643, 1985. [PubMed: 2413754]
60. Eriksson, B, Oberg, K, Stridsberg, M: Tumor markers in neuroendocrine tumors. *Digestion* 62 Suppl 1:33-38, 2000. [PubMed: 10940685]
61. Goebel, SU, Serrano, J, Yu, F, Gibril, F, Venzon, DJ, Jensen, RT: Prospective study of the value of serum chromogranin A or serum gastrin levels in the assessment of the presence, extent, or growth of gastrinomas. *Cancer* 85:1470-1483, 1999. [PubMed: 10193936]
62. Bernini, GP, Moretti, A, Ferdeghini, M, Ricci, S, Letizia, C, D'Erasmus, E, Argenio, GF, Salvetti, A: A new human chromogranin 'A' immunoradiometric assay for the diagnosis of neuroendocrine tumours. *Br J Cancer* 84:636-642, 2001. [PMC free article: PMC2363780] [PubMed: 11237384]
63. Nehar, D, Lombard-Bohas, C, Olivieri, S, Claustrat, B, Chayvialle, JA, Penes, MC, Sassolas, G, Borson-Chazot, F: Interest of Chromogranin A for diagnosis and follow-up of endocrine tumours. *Clin Endocrinol (Oxf)* 60:644-652, 2004. [PubMed: 15104570]
64. Bajetta, E, Ferrari, L, Martinetti, A, Celio, L, Procopio, G, Artale, S, Zilembo, N, Di, BM, Seregini, E, Bombardieri, E: Chromogranin A, neuron specific enolase, carcinoembryonic antigen, and hydroxyindole acetic acid evaluation in patients with neuroendocrine tumors. *Cancer* 86:858-865, 1999. [PubMed: 10463986]
65. Stridsberg, M, Eriksson, B, Fellstrom, B, Kristiansson, G, Tiensuu, JE: Measurements of chromogranin B can serve as a complement to chromogranin A. *Regul Pept* 139:80-83, 2007. [PubMed: 17116339]
66. Takiyuddin, MA, Cervenka, JH, Hsiao, RJ, Barbosa, JA, Parmer, RJ, O'Connor, DT: Chromogranin A. Storage and release in hypertension. *Hypertension* 15:237-246, 1990. [PubMed: 2406199]
67. Zatelli, MC, Torta, M, Leon, A, Ambrosio, MR, Gion, M, Tomassetti, P, De, BF, Delle, FG, Dogliotti, L, gli Uberti, EC: Chromogranin A as a marker of neuroendocrine neoplasia: an Italian Multicenter Study. *Endocr Relat Cancer* 14:473-482, 2007. [PubMed: 17639060]
68. Kolby, L, Bernhardt, P, Sward, C, Johanson, V, Ahlman, H, Forssell-Aronsson, E, Stridsberg, M, Wangberg, B, Nilsson, O: Chromogranin A as a determinant of midgut carcinoid tumour volume. *Regul Pept* 120:269-273, 2004. [PubMed: 15177946]
69. Modlin, IM, Oberg, K, Chung, DC, Jensen, RT, de Herder, WW, Thakker, RV, Caplin, M, Delle, FG, Kaltsas, GA, Krenning, EP, Moss, SF, Nilsson, O, Rindi, G, Salazar, R, Ruzniewski, P, Sundin, A: Gastroenteropancreatic neuroendocrine tumours. *Lancet Oncol* 9:61-72, 2008. [PubMed: 18177818]
70. Panzuto, F, Severi, C, Cannizzaro, R, Falconi, M, Angeletti, S, Pasquali, A, Corleto, VD, Annibale, B, Buonadonna, A, Pederzoli, P, Delle, FG: Utility of combined use of plasma levels of chromogranin A and pancreatic polypeptide in the diagnosis of gastrointestinal and pancreatic endocrine tumors. *J Endocrinol Invest* 27:6-11, 2004. [PubMed: 15053236]
71. De Block, CE, Colpin, G, Thielemans, K, Coopmans, W, Bogers, JJ, Pelckmans, PA, Van Marck, EA, Van, H, V, Martin, M, De, L, I, Bouillon, R, Van Gaal, LF: Neuroendocrine tumor markers and enterochromaffin-like cell hyper/dysplasia in type 1 diabetes. *Diabetes Care* 27:1387-1393, 2004. [PubMed: 15161793]
72. Conlon, JM, Deacon, CF, Richter, G, Stockmann, F, Creutzfeldt, W: Circulating tachykinins (substance P, neurokinin A, neuropeptide K) and the carcinoid flush. *Scand J Gastroenterol* 22:97-105, 1987. [PubMed: 2882598]
73. Norheim, I, Theodorsson-Norheim, E, Brodin, E, Oberg, K: Tachykinins in carcinoid tumors: their use as a tumor marker and possible role in the carcinoid flush. *J Clin Endocrinol Metab* 63:605-612, 1986. [PubMed: 2426299]
74. Voute, PA, Hoefnagel, CA, Marcuse, HR, de, KJ: Detection of neuroblastoma with <sup>131</sup>I-meta-iodobenzylguanidine. *Prog Clin Biol Res* 175:389-398, 1985. [PubMed: 3991738]
75. National Cancer Institute. Surveillance, Epidemiology, and End Results (SEER) Program ([www.seer.cancer.gov](http://www.seer.cancer.gov)) SEER\*Stat Database: SEER 17 Regs Nov 2006 sub (1973-2004), ed released April 2006, National Cancer Institute, DCCPS, Surveillance Research Program, Cancer Statistic Branch. 2006. National Cancer Institute.
76. Rindi, G, Kloppel, G, Couvelard, A, Komminoth, P, Korner, M, Lopes, JM, McNicol, AM, Nilsson, O, Perren, A, Scarpa, A, Scoazec, JY, Wiedenmann, B: TNM staging of midgut and hindgut (neuro) endocrine tumors: a

- consensus proposal including a grading system. *Virchows Arch* 451:757-762, 2007. [PubMed: 17674042]
77. AJCC: *Cancer Staging Manual*. Chicago, Springer, 2010,
78. Rockall,AG, Reznik,RH: Imaging of neuroendocrine tumours (CT/MR/US). *Best Pract Res Clin Endocrinol Metab* 21:43-68, 2007. [PubMed: 17382265]
79. Gibril,F, Reynolds,JC, Lubensky,IA, Roy,PK, Peghini,PL, Doppman,JL, Jensen,RT: Ability of somatostatin receptor scintigraphy to identify patients with gastric carcinoids: a prospective study. *J Nucl Med* 41:1646-1656, 2000. [PubMed: 11037994]
80. Kumbasar,B, Kamel,IR, Tekes,A, Eng,J, Fishman,EK, Wahl,RL: Imaging of neuroendocrine tumors: accuracy of helical CT versus SRS. *Abdom Imaging* 29:696-702, 2004. [PubMed: 15162235]
81. Gould,M, Johnson,RJ: Computed tomography of abdominal carcinoid tumour. *Br J Radiol* 59:881-885, 1986. [PubMed: 3756383]
82. Pilleul,F, Penigaud,M, Milot,L, Saurin,JC, Chayvialle,JA, Valette,PJ: Possible small-bowel neoplasms: contrast-enhanced and water-enhanced multidetector CT enteroclysis. *Radiology* 241:796-801, 2006. [PubMed: 17053201]
83. Semelka,RC, Custodio,CM, Cem,BN, Woosley,JT: Neuroendocrine tumors of the pancreas: spectrum of appearances on MRI. *J Magn Reson Imaging* 11:141-148, 2000. [PubMed: 10713946]
84. Pamuklar,E, Semelka,RC: MR imaging of the pancreas. *Magn Reson Imaging Clin N Am* 13:313-330, 2005. [PubMed: 15935314]
85. Kelekis,NL, Semelka,RC: MRI of pancreatic tumors. *Eur Radiol* 7:875-886, 1997. [PubMed: 9228103]
86. Dromain,C, de,BT, Lumbroso,J, Caillet,H, Laplanche,A, Boige,V, Ducreux,M, Duvillard,P, Elias,D, Schlumberger,M, Sigal,R, Baudin,E: Detection of liver metastases from endocrine tumors: a prospective comparison of somatostatin receptor scintigraphy, computed tomography, and magnetic resonance imaging. *J Clin Oncol* 23:70-78, 2005. [PubMed: 15625361]
87. Dromain,C, de,BT, Baudin,E, Galline,J, Ducreux,M, Boige,V, Duvillard,P, Laplanche,A, Caillet,H, Lasser,P, Schlumberger,M, Sigal,R: MR imaging of hepatic metastases caused by neuroendocrine tumors: comparing four techniques. *AJR Am J Roentgenol* 180:121-128, 2003. [PubMed: 12490490]
88. Debray,MP, Geoffroy,O, Laissy,JP, Lebtahi,R, Silbermann-Hoffman,O, Henry-Feugeas,MC, Cadiot,G, Mignon,M, Schouman-Claeys,E: Imaging appearances of metastases from neuroendocrine tumours of the pancreas. *Br J Radiol* 74:1065-1070, 2001. [PubMed: 11709476]
89. Kressel,HY: Strategies for magnetic resonance imaging of focal liver disease. *Radiol Clin North Am* 26:607-615, 1988. [PubMed: 2836885]
90. Cangemi,DJ, Patel,MK, Gomez,V, Cangemi,JR, Stark,ME, Lukens,FJ: Small bowel tumors discovered during double-balloon enteroscopy: analysis of a large prospectively collected single-center database. *J Clin Gastroenterol* 47:769-772, 2013. [PubMed: 23426457]
91. Krenning,EP, Kooij,PP, Bakker,WH, Breeman,WA, Postema,PT, Kwekkeboom,DJ, Oei,HY, de,JM, Visser,TJ, Reijs,AE, .: Radiotherapy with a radiolabeled somatostatin analogue, [111In-DTPA-D-Phe1]-octreotide. A case history. *Ann N Y Acad Sci* 733:496-506, 1994. [PubMed: 7978900]
92. O'Steen,WK, Barnard,JL, Jr., Yates,RD: Morphologic changes in skeletal muscle induced by serotonin treatment: a light- and electron-microscope study. *Exp Mol Pathol* 7:145-155, 1967. [PubMed: 6053649]
93. Krenning,EP, Kwekkeboom,DJ, Bakker,WH, Breeman,WA, Kooij,PP, Oei,HY, van,HM, Postema,PT, de,JM, Reubi,JC, .: Somatostatin receptor scintigraphy with [111In-DTPA-D-Phe1]- and [123I-Tyr3]-octreotide: the Rotterdam experience with more than 1000 patients. *Eur J Nucl Med* 20:716-731, 1993. [PubMed: 8404961]
94. Krenning,EP, Kwekkeboom,DJ, Oei,HY, de Jong,RJ, Dop,FJ, Reubi,JC, Lamberts,SW: Somatostatin-receptor scintigraphy in gastroenteropancreatic tumors. An overview of European results. *Ann N Y Acad Sci* 733:416-424, 1994. [PubMed: 7978890]
95. Virgolini,I, Patri,P, Novotny,C, Traub,T, Leimer,M, Fuger,B, Li,SR, Angelberger,P, Raderer,M, Wogritsch,S, Kurtaran,A, Kletter,K, Dudczak,R: Comparative somatostatin receptor scintigraphy using in-111-DOTA-lanreotide and in-111-DOTA-Tyr3-octreotide versus F-18-FDG-PET for evaluation of somatostatin receptor-mediated radionuclide therapy. *Ann Oncol* 12 Suppl 2:S41-S45, 2001. [PubMed: 11762351]

96. Chiti,A, Fanti,S, Savelli,G, Romeo,A, Bellanova,B, Rodari,M, van Graafeiland,BJ, Monetti,N, Bombardieri,E: Comparison of somatostatin receptor imaging, computed tomography and ultrasound in the clinical management of neuroendocrine gastro-entero-pancreatic tumours. *Eur J Nucl Med* 25:1396-1403, 1998. [PubMed: 9818279]
97. Lebtahi,R, Cadiot,G, Sarda,L, Daou,D, Faraggi,M, Petegnief,Y, Mignon,M, Le,GD: Clinical impact of somatostatin receptor scintigraphy in the management of patients with neuroendocrine gastroenteropancreatic tumors. *J Nucl Med* 38:853-858, 1997. [PubMed: 9189129]
98. Lebtahi,R, Cadiot,G, Mignon,M, Le,GD: Somatostatin receptor scintigraphy: a first-line imaging modality for gastroenteropancreatic neuroendocrine tumors. *Gastroenterology* 115:1025-1027, 1998. [PubMed: 9786730]
99. Gibril,F, Reynolds,JC, Doppman,JL, Chen,CC, Venzon,DJ, Termanini,B, Weber,HC, Stewart,CA, Jensen,RT: Somatostatin receptor scintigraphy: its sensitivity compared with that of other imaging methods in detecting primary and metastatic gastrinomas. A prospective study. *Ann Intern Med* 125:26-34, 1996. [PubMed: 8644985]
100. Krenning EP, Kwkkeboom DJ,PSKLRJ: Somatostatin receptor scintigraphy. *Nuclear Medicine Annual*1-50, 1995.
101. Gibril,F, Reynolds,JC, Chen,CC, Yu,F, Goebel,SU, Serrano,J, Doppman,JL, Jensen,RT: Specificity of somatostatin receptor scintigraphy: a prospective study and effects of false-positive localizations on management in patients with gastrinomas. *J Nucl Med* 40:539-553, 1999. [PubMed: 10210211]
102. Janson,ET, Westlin,JE, Eriksson,B, Ahlstrom,H, Nilsson,S, Oberg,K: [<sup>111</sup>In-DTPA-D-Phe<sup>1</sup>]octreotide scintigraphy in patients with carcinoid tumours: the predictive value for somatostatin analogue treatment. *Eur J Endocrinol* 131:577-581, 1994. [PubMed: 7804439]
103. Kvols,LK, Reubi,JC, Horisberger,U, Moertel,CG, Rubin,J, Charboneau,JW: The presence of somatostatin receptors in malignant neuroendocrine tumor tissue predicts responsiveness to octreotide. *Yale J Biol Med* 65:505-518, 1992. [PMC free article: PMC2589749] [PubMed: 1364090]
104. Eriksson,B, Lilja,A, Ahlstrom,H, Bjurling,P, Bergstrom,M, Lindner,KJ, Langstrom,B, Oberg,K: Positron-emission tomography as a radiological technique in neuroendocrine gastrointestinal tumors. *Ann N Y Acad Sci* 733:446-452, 1994. [PubMed: 7978893]
105. Eriksson,B, Bergstrom,M, Lilja,A, Ahlstrom,H, Langstrom,B, Oberg,K: Positron emission tomography (PET) in neuroendocrine gastrointestinal tumors. *Acta Oncol* 32:189-196, 1993. [PubMed: 7686763]
106. Gabriel,M, Decristoforo,C, Kendler,D, Dobrozemsky,G, Heute,D, Uprimny,C, Kovacs,P, Von,GE, Bale,R, Virgolini,IJ: <sup>68</sup>Ga-DOTA-Tyr<sup>3</sup>-octreotide PET in neuroendocrine tumors: comparison with somatostatin receptor scintigraphy and CT. *J Nucl Med* 48:508-518, 2007. [PubMed: 17401086]
107. Orlefors,H, Sundin,A, Garske,U, Juhlin,C, Oberg,K, Skogseid,B, Langstrom,B, Bergstrom,M, Eriksson,B: Whole-body (<sup>11</sup>C-5-hydroxytryptophan positron emission tomography as a universal imaging technique for neuroendocrine tumors: comparison with somatostatin receptor scintigraphy and computed tomography. *J Clin Endocrinol Metab* 90:3392-3400, 2005. [PubMed: 15755858]
108. Sisson,J, Shapiro,B, Beierwaltes,WH, Nakajo,M, Glowniak,J, Mangner,T, Carey,JE, Swanson,DP, Copp,J, Satterlee,W, .: Treatment of malignant pheochromocytoma with a new radiopharmaceutical. *Trans Assoc Am Physicians* 96:209-217, 1983. [PubMed: 6679954]
109. Fischer,M, Kamanabroo,D, Sonderkamp,H, Proske,T: Scintigraphic imaging of carcinoid tumours with <sup>131</sup>I-metaiodobenzylguanidine. *Lancet* 2:165, 1984. [PubMed: 6146062]
110. Shapiro B: MIBG in the diagnosis and therap of neuroblastoma and pheochromocytoma. In *Proceedings of the International Symposium on Recent Advances in Nuclear Medicine*. Cattaruz E, Englaro E, Geatti O, Eds. Surin Biomedica, 1987,
111. Shapiro, B. MIBG in the management of neuroendocrine tumors. 1988.
112. Sinzinger,H, Renner,F, Granegger,S: Unsuccessful iodine-131 MIBG imaging of carcinoid tumors and apudomas. *J Nucl Med* 27:1221-1222, 1986. [PubMed: 3723196]
113. Marx,SJ, Vinik,AI, Santen,RJ, Floyd,JC, Jr., Mills,JL, Green,J: Multiple endocrine neoplasia type I: assessment of laboratory tests to screen for the gene in a large kindred. *Medicine (Baltimore)* 65:226-241, 1986. [PubMed:



2873498]

114. Geatti,O, Shapiro,B, Sisson,JC, Hutchinson,RJ, Mallette,S, Eyre,P, Beierwaltes,WH: Iodine-131 metaiodobenzylguanidine scintigraphy for the location of neuroblastoma: preliminary experience in ten cases. *J Nucl Med* 26:736-742, 1985. [PubMed: 4009283]
115. Lumbroso,J, Guermazi,F, Hartmann,O, Coornaert,S, Rabarison,Y, Lemerle,J, Parmentier,C: [Sensitivity and specificity of meta-iodobenzylguanidine (mIBG) scintigraphy in the evaluation of neuroblastoma: analysis of 115 cases]. *Bull Cancer* 75:97-106, 1988. [PubMed: 3359060]
116. Treuner,J, Feine,U, Niethammer,D, Muller-Schaumburg,W, Meinke,J, Eibach,E, Dopfer,R, Klingebiel,T, Grumbach,S: Scintigraphic imaging of neuroblastoma with [131-I]iodobenzylguanidine. *Lancet* 1:333-334, 1984. [PubMed: 6141395]
117. Roberts,WC: A unique heart disease associated with a unique cancer: carcinoid heart disease. *Am J Cardiol* 80:251-256, 1997. [PubMed: 9230180]
118. Anderson,AS, Krauss,D, Lang,R: Cardiovascular complications of malignant carcinoid disease. *Am Heart J* 134:693-702, 1997. [PubMed: 9351737]
119. Bhattacharyya,S, Toumpanakis,C, Caplin,ME, Davar,J: Usefulness of N-terminal pro-brain natriuretic peptide as a biomarker of the presence of carcinoid heart disease. *Am J Cardiol* 102:938-942, 2008. [PubMed: 18805126]
120. Callahan,JA, Wroblewski,EM, Reeder,GS, Edwards,WD, Seward,JB, Tajik,AJ: Echocardiographic features of carcinoid heart disease. *Am J Cardiol* 50:762-768, 1982. [PubMed: 7124634]
121. Lundin L, Landelius A, Oberg K: Transesophageal echocardiography improves the diagnostic value of cardiac ultrasound in patients with carcinoid heart disease. [article online], 1991, [PMC free article: PMC1024370] [PubMed: 2206710]
122. Pellikka,PA, Tajik,AJ, Khandheria,BK, Seward,JB, Callahan,JA, Pitot,HC, Kvols,LK: Carcinoid heart disease. Clinical and echocardiographic spectrum in 74 patients. *Circulation* 87:1188-1196, 1993. [PubMed: 7681733]
123. Connolly,HM, Crary,JL, McGoon,MD, Hensrud,DD, Edwards,BS, Edwards,WD, Schaff,HV: Valvular heart disease associated with fenfluramine-phentermine. *N Engl J Med* 337:581-588, 1997. [PubMed: 9271479]
124. Connolly,HM, Nishimura,RA, Smith,HC, Pellikka,PA, Mullany,CJ, Kvols,LK: Outcome of cardiac surgery for carcinoid heart disease. *J Am Coll Cardiol* 25:410-416, 1995. [PubMed: 7829795]
125. Lundin,L, Norheim,I, Landelius,J, Oberg,K, Theodorsson-Norheim,E: Carcinoid heart disease: relationship of circulating vasoactive substances to ultrasound-detectable cardiac abnormalities. *Circulation* 77:264-269, 1988. [PubMed: 2448062]
126. Ribiolio P, Wilson J, Harrison J, Sanders L, Bashore T, Feldman J: Carcinoid heart disease. Correlation of high serotonin levels with valvular abnormalities detected by cardiac catheterization and echocardiography. [article online], 1998, [PubMed: 7641358]
127. Perry,RR, Vinik,AI: Endocrine tumors of the gastrointestinal tract. *Annu Rev Med* 47:57-68, 1996. [PubMed: 8712803]
128. Lundin,L, Oberg,K, Landelius,J, Hansson,HE, Wilander,E, Theodorsson,E: Plasma atrial natriuretic peptide in carcinoid heart disease. *Am J Cardiol* 63:969-972, 1989. [PubMed: 2522730]
129. Kvols,LK: Therapy of the malignant carcinoid syndrome. *Endocrinol Metab Clin North Am* 18:557-568, 1989. [PubMed: 2663485]
130. Rayson,D, Pitot,HC, Kvols,LK: Regression of metastatic carcinoid tumor after valvular surgery for carcinoid heart disease. *Cancer* 79:605-611, 1997. [PubMed: 9028374]
131. Jacobsen,MB, Hanssen,LE: Clinical effects of octreotide compared to placebo in patients with gastrointestinal neuroendocrine tumours. Report on a double-blind, randomized trial. *J Intern Med* 237:269-275, 1995. [PubMed: 7534331]
132. Eriksson,B, Oberg,K: Summing up 15 years of somatostatin analog therapy in neuroendocrine tumors: future outlook. *Ann Oncol* 10 Suppl 2:S31-S38, 1999. [PubMed: 10399030]
133. Lee,MV, Fong,EM, Singer,FR, Guenette,RS: Bisphosphonate treatment inhibits the growth of prostate cancer cells. *Cancer Res* 61:2602-2608, 2001. [PubMed: 11289137]

134. Boissier,S, Ferreras,M, Peyruchaud,O, Magnetto,S, Ebetino,FH, Colombel,M, Delmas,P, Delaisse,JM, Clezardin,P: Bisphosphonates inhibit breast and prostate carcinoma cell invasion, an early event in the formation of bone metastases. *Cancer Res* 60:2949-2954, 2000. [PubMed: 10850442]
135. Virtanen,SS, Vaananen,HK, Harkonen,PL, Lakkakorpi,PT: Alendronate inhibits invasion of PC-3 prostate cancer cells by affecting the mevalonate pathway. *Cancer Res* 62:2708-2714, 2002. [PubMed: 11980672]
136. Derenne,S, Amiot,M, Barille,S, Collette,M, Robillard,N, Berthaud,P, Harousseau,JL, Bataille,R: Zoledronate is a potent inhibitor of myeloma cell growth and secretion of IL-6 and MMP-1 by the tumoral environment. *J Bone Miner Res* 14:2048-2056, 1999. [PubMed: 10620064]
137. Senaratne,SG, Pirianov,G, Mansi,JL, Arnett,TR, Colston,KW: Bisphosphonates induce apoptosis in human breast cancer cell lines. *Br J Cancer* 82:1459-1468, 2000. [PMC free article: PMC2363380] [PubMed: 10780527]
138. van der,PG, Vloedgraven,H, van,BE, van,dW-P, Lowik,C, Papapoulos,S: Bisphosphonates inhibit the adhesion of breast cancer cells to bone matrices in vitro. *J Clin Invest* 98:698-705, 1996. [PMC free article: PMC507479] [PubMed: 8698861]
139. Boissier,S, Magnetto,S, Frappart,L, Cuzin,B, Ebetino,FH, Delmas,PD, Clezardin,P: Bisphosphonates inhibit prostate and breast carcinoma cell adhesion to unmineralized and mineralized bone extracellular matrices. *Cancer Res* 57:3890-3894, 1997. [PubMed: 9307266]
140. Rosen,LS, Gordon,D, Kaminski,M, Howell,A, Belch,A, Mackey,J, Apffelstaedt,J, Hussein,M, Coleman,RE, Reitsma,DJ, Seaman,JJ, Chen,BL, Ambros,Y: Zoledronic acid versus pamidronate in the treatment of skeletal metastases in patients with breast cancer or osteolytic lesions of multiple myeloma: a phase III, double-blind, comparative trial. *Cancer J* 7:377-387, 2001. [PubMed: 11693896]
141. Berenson,JR, Lichtenstein,A, Porter,L, Dimopoulos,MA, Bordoni,R, George,S, Lipton,A, Keller,A, Ballester,O, Kovacs,MJ, Blacklock,HA, Bell,R, Simeone,J, Reitsma,DJ, Heffernan,M, Seaman,J, Knight,RD: Efficacy of pamidronate in reducing skeletal events in patients with advanced multiple myeloma. Myeloma Aredia Study Group. *N Engl J Med* 334:488-493, 1996. [PubMed: 8559201]
142. Hortobagyi,GN, Theriault,RL, Porter,L, Blayney,D, Lipton,A, Sinoff,C, Wheeler,H, Simeone,JF, Seaman,J, Knight,RD: Efficacy of pamidronate in reducing skeletal complications in patients with breast cancer and lytic bone metastases. Protocol 19 Aredia Breast Cancer Study Group. *N Engl J Med* 335:1785-1791, 1996. [PubMed: 8965890]
143. Theriault,RL, Lipton,A, Hortobagyi,GN, Leff,R, Gluck,S, Stewart,JF, Costello,S, Kennedy,I, Simeone,J, Seaman,JJ, Knight,RD, Mellars,K, Heffernan,M, Reitsma,DJ: Pamidronate reduces skeletal morbidity in women with advanced breast cancer and lytic bone lesions: a randomized, placebo-controlled trial. Protocol 18 Aredia Breast Cancer Study Group. *J Clin Oncol* 17:846-854, 1999. [PubMed: 10071275]
144. Hortobagyi,GN, Theriault,RL, Lipton,A, Porter,L, Blayney,D, Sinoff,C, Wheeler,H, Simeone,JF, Seaman,JJ, Knight,RD, Heffernan,M, Mellars,K, Reitsma,DJ: Long-term prevention of skeletal complications of metastatic breast cancer with pamidronate. Protocol 19 Aredia Breast Cancer Study Group. *J Clin Oncol* 16:2038-2044, 1998. [PubMed: 9626201]
145. Body,JJ, Dumon,JC, Piccart,M, Ford,J: Intravenous pamidronate in patients with tumor-induced osteolysis: a biochemical dose-response study. *J Bone Miner Res* 10:1191-1196, 1995. [PubMed: 8585422]
146. Saad,F, Gleason,DM, Murray,R, Tchekmedyian,S, Venner,P, Lacombe,L, Chin,JL, Vinholes,JJ, Goas,JA, Chen,B: A randomized, placebo-controlled trial of zoledronic acid in patients with hormone-refractory metastatic prostate carcinoma. *J Natl Cancer Inst* 94:1458-1468, 2002. [PubMed: 12359855]
147. Calis,KA, Pucino,F: Zoledronic acid and secondary prevention of fractures. *N Engl J Med* 357:1861-1862, 2007. [PubMed: 17878150]
148. Carducci,MA, Padley,RJ, Breul,J, Vogelzang,NJ, Zonnenberg,BA, Daliani,DD, Schulman,CC, Nabulsi,AA, Humerickhouse,RA, Weinberg,MA, Schmitt,JL, Nelson,JB: Effect of endothelin-A receptor blockade with atrasentan on tumor progression in men with hormone-refractory prostate cancer: a randomized, phase II, placebo-

- controlled trial. *J Clin Oncol* 21:679-689, 2003. [PubMed: 12586806]
149. Nelson,JB, Nabulsi,AA, Vogelzang,NJ, Breul,J, Zonnenberg,BA, Daliani,DD, Schulman,CC, Carducci,MA: Suppression of prostate cancer induced bone remodeling by the endothelin receptor A antagonist atrasentan. *J Urol* 169:1143-1149, 2003. [PubMed: 12576870]
150. Yin,JI, Mohammad,KS, Kakonen,SM, Harris,S, Wu-Wong,JR, Wessale,JI, Padley,RJ, Garrett,IR, Chirgwin,JM, Guise,TA: A causal role for endothelin-1 in the pathogenesis of osteoblastic bone metastases. *Proc Natl Acad Sci U S A* 100:10954-10959, 2003. [PMC free article: PMC196909] [PubMed: 12941866]
151. Brown,JE, Cook,RJ, Major,P, Lipton,A, Saad,F, Smith,M, Lee,KA, Zheng,M, Hei,YJ, Coleman,RE: Bone turnover markers as predictors of skeletal complications in prostate cancer, lung cancer, and other solid tumors. *J Natl Cancer Inst* 97:59-69, 2005. [PubMed: 15632381]
152. Boudreaux,JP, Putty,B, Frey,DJ, Woltering,E, Anthony,L, Daly,I, Ramcharan,T, Lopera,J, Castaneda,W: Surgical treatment of advanced-stage carcinoid tumors: lessons learned. *Ann Surg* 241:839-845, 2005. [PMC free article: PMC1357164] [PubMed: 15912033]
153. Givi,B, Pommier,SJ, Thompson,AK, Diggs,BS, Pommier,RF: Operative resection of primary carcinoid neoplasms in patients with liver metastases yields significantly better survival. *Surgery* 140:891-897, 2006. [PubMed: 17188135]
154. Kahil,ME, Brown,H, Fred,HL: THE CARCINOID CRISIS. *Arch Intern Med* 114:26-28, 1964. [PubMed: 14156067]
155. Kvols,LK, Martin,JK, Marsh,HM, Moertel,CG: Rapid reversal of carcinoid crisis with a somatostatin analogue. *N Engl J Med* 313:1229-1230, 1985. [PubMed: 2865675]
156. Kunz,PL, Reidy-Lagunes,D, Anthony,LB, Bertino,EM, Brendtro,K, Chan,JA, Chen,H, Jensen,RT, Kim,MK, Klimstra,DS, Kulke,MH, Liu,EH, Metz,DC, Phan,AT, Sippel,RS, Strosberg,JR, Yao,JC: Consensus guidelines for the management and treatment of neuroendocrine tumors. *Pancreas* 42:557-577, 2013. [PMC free article: PMC4304762] [PubMed: 23591432]
157. Moertel,CG: Karmofsky memorial lecture. An odyssey in the land of small tumors. *J Clin Oncol* 5:1502-1522, 1987. [PubMed: 2443618]
158. Maton,PN, Camilleri,M, Griffin,G, Allison,DJ, Hodgson,HJ, Chadwick,VS: Role of hepatic arterial embolisation in the carcinoid syndrome. *Br Med J (Clin Res Ed)* 287:932-935, 1983. [PMC free article: PMC1549228] [PubMed: 6412893]
159. Moertel,CG: Treatment of the carcinoid tumor and the malignant carcinoid syndrome. *J Clin Oncol* 1:727-740, 1983. [PubMed: 6199469]
160. Strodel WE, Strodel WE,OT: Small bowel carcinoid tumors and the carcinoid syndrome. *Endocrine Surgery Update* 293, 1983.
161. Gyr NE, Kayasseh L, Keller U: Somatostatin as a therapeutic agent. In *Gut Hormones. 2nd Ed.* 2 ed. Bloom SR, Polak JM, Eds. Edinburgh, Churchill Livingstone, 1981, p. 581-585.
162. Sheppard,M, Shapiro,B, Pimstone,B, Kronheim,S, Berelowitz,M, Gregory,M: Metabolic clearance and plasma half-disappearance time of exogenous somatostatin in man. *J Clin Endocrinol Metab* 48:50-53, 1979. [PubMed: 422706]
163. Vinik,AI, Tsai,ST, Moattari,AR, Cheung,P, Eckhauser,FE, Cho,K: Somatostatin analogue (SMS 201-995) in the management of gastroenteropancreatic tumors and diarrhea syndromes. *Am J Med* 81:23-40, 1986. [PubMed: 2879447]
164. Kulaksiz,H, Eissele,R, Rossler,D, Schulz,S, Hollt,V, Cetin,Y, Arnold,R: Identification of somatostatin receptor subtypes 1, 2A, 3, and 5 in neuroendocrine tumours with subtype specific antibodies. *Gut* 50:52-60, 2002. [PMC free article: PMC1773091] [PubMed: 11772967]
165. Papotti,M, Croce,S, Bello,M, Bongiovanni,M, Allia,E, Schindler,M, Bussolati,G: Expression of somatostatin receptor types 2, 3 and 5 in biopsies and surgical specimens of human lung tumours. Correlation with preoperative octreotide scintigraphy. *Virchows Arch* 439:787-797, 2001. [PubMed: 11787852]
166. Kvols,LK, Moertel,CG, O'Connell,MJ, Schutt,AJ, Rubin,J, Hahn,RG: Treatment of the malignant carcinoid

- syndrome. Evaluation of a long-acting somatostatin analogue. *N Engl J Med* 315:663-666, 1986. [PubMed: 2427948]
167. Modlin,IM, Pavel,M, Kidd,M, Gustafsson,BI: Review article: somatostatin analogues in the treatment of gastroenteropancreatic neuroendocrine (carcinoid) tumours. *Aliment Pharmacol Ther* 31:169-188, 2010. [PubMed: 19845567]
168. O'Toole,D, Ducreux,M, Bommelaer,G, Wemeau,JL, Bouche,O, Catus,F, Blumberg,J, Ruzniewski,P: Treatment of carcinoid syndrome: a prospective crossover evaluation of lanreotide versus octreotide in terms of efficacy, patient acceptability, and tolerance. *Cancer* 88:770-776, 2000. [PubMed: 10679645]
169. Vinik A, Gomez-Panzani E, Wolin EM, Audry A, on behalf of ELECT investigators: ELECT: A phase 3 study of efficacy and safety of lanreotide Autoge/Depot (LAN) treatment for carcinoid syndrome in patients with neuroendocrine tumors (NETs) (Abstract). *ASCO-GI Symposium* January 16-18, 2014, 2014.
170. Rinke,A, Muller,HH, Schade-Brittinger,C, Klose,KJ, Barth,P, Wied,M, Mayer,C, Aminossadati,B, Pape,UF, Blaker,M, Harder,J, Arnold,C, Gress,T, Arnold,R: Placebo-controlled, double-blind, prospective, randomized study on the effect of octreotide LAR in the control of tumor growth in patients with metastatic neuroendocrine midgut tumors: a report from the PROMID Study Group. *J Clin Oncol* 27:4656-4663, 2009. [PubMed: 19704057]
171. Martin-Richard,M, Massuti,B, Pineda,E, Alonso,V, Marmol,M, Castellano,D, Fonseca,E, Galan,A, Llanos,M, Sala,MA, Pericay,C, Rivera,F, Sastre,J, Segura,A, Quindos,M, Maisonobe,P: Antiproliferative effects of lanreotide autogel in patients with progressive, well-differentiated neuroendocrine tumours: a Spanish, multicentre, open-label, single arm phase II study. *BMC Cancer* 13:427, 2013. [PMC free article: PMC3853091] [PubMed: 24053191]
172. Hofland,LJ, Lamberts,SW: The pathophysiological consequences of somatostatin receptor internalization and resistance. *Endocr Rev* 24:28-47, 2003. [PubMed: 12588807]
173. Rubin,J, Ajani,J, Schirmer,W, Venook,AP, Bukowski,R, Pommier,R, Saltz,L, Dandona,P, Anthony,L: Octreotide acetate long-acting formulation versus open-label subcutaneous octreotide acetate in malignant carcinoid syndrome. *J Clin Oncol* 17:600-606, 1999. [PubMed: 10080605]
174. Colao,A, Petersenn,S, Newell-Price,J, Findling,JW, Gu,F, Maldonado,M, Schoenherr,U, Mills,D, Salgado,LR, Biller,BM: A 12-month phase 3 study of pasireotide in Cushing's disease. *N Engl J Med* 366:914-924, 2012. [PubMed: 22397653]
175. Petersenn,S, Farrall,AJ, Block,C, Melmed,S, Schopohl,J, Caron,P, Cuneo,R, Kleinberg,D, Colao,A, Ruffin,M, Hermosillo,RK, Hughes,G, Hu,K, Barkan,A: Long-term efficacy and safety of subcutaneous pasireotide in acromegaly: results from an open-ended, multicenter, Phase II extension study. *Pituitary* 17:132-140, 2014. [PMC free article: PMC3942632] [PubMed: 23529827]
176. Kvolts,LK, Oberg,KE, O'Dorisio,TM, Mohideen,P, de Herder,WW, Arnold,R, Hu,K, Zhang,Y, Hughes,G, Anthony,L, Wiedenmann,B: Pasireotide (SOM230) shows efficacy and tolerability in the treatment of patients with advanced neuroendocrine tumors refractory or resistant to octreotide LAR: results from a phase II study. *Endocr Relat Cancer* 19:657-666, 2012. [PubMed: 22807497]
177. Wolin,EM, Hu,K, Hughes,G, Bouillaud,E, Giannone,V, Resendiz,KH: Safety, tolerability, pharmacokinetics, and pharmacodynamics of a long-acting release (LAR) formulation of pasireotide (SOM230) in patients with gastroenteropancreatic neuroendocrine tumors: results from a randomized, multicenter, open-label, phase I study. *Cancer Chemother Pharmacol* 72:387-395, 2013. [PMC free article: PMC3719006] [PubMed: 23765178]
178. Frolich,JC, Bloomgarden,ZT, Oates,JA, McGuigan,JE, Rabinowitz,D: The carcinoid flush. Provocation by pentagastrin and inhibition by somatostatin. *N Engl J Med* 299:1055-1057, 1978. [PubMed: 703771]
179. Richter G, Stockman F, LBCJCW: Short-term administration of somatostatin analogue SMS-201-995 in patients with carcinoid tumors. *Scand J Gastroenterol* 21:193, 1986.
180. Santangelo,WC, O'Dorisio,TM, Kim,JG, Severino,G, Krejs,GJ: Pancreatic cholera syndrome: effect of a synthetic somatostatin analog on intestinal water and ion transport. *Ann Intern Med* 103:363-367, 1985. [PubMed: 2862821]

181. Arnold,R, Lankisch,PG: Somatostatin and the gastrointestinal tract. *Clin Gastroenterol* 9:733-753, 1980. [PubMed: 6107192]
182. Stockmann F, Richter G,LBCJCW: Long-term treatment of patients with endocrine gastrointestinal tumors with the somatostatin analogue SMS 201-995. *Scand J Gastroenterol* 21:230, 1986.
183. Hengl,G, Prager,J, Pointner,H: The influence of somatostatin on the absorption of triglycerides in partially gastrectomized subjects. *Acta Hepatogastroenterol (Stuttg)* 26:392-395, 1979. [PubMed: 525216]
184. Kiesewetter,B, Raderer,M: Ondansetron for diarrhea associated with neuroendocrine tumors. *N Engl J Med* 368:1947-1948, 2013. [PubMed: 23675671]
185. Vinik,A, Moattari,AR: Use of somatostatin analog in management of carcinoid syndrome. *Dig Dis Sci* 34:14S-27S, 1989. [PubMed: 2920654]
186. Poole,CJ: Myelopathy secondary to metastatic carcinoid tumour. *J Neurol Neurosurg Psychiatry* 47:1359-1360, 1984. [PMC free article: PMC1028152] [PubMed: 6512559]
187. Berry,EM, Maunder,C, Wilson,M: Carcinoid myopathy and treatment with cyproheptadine (Periactin). *Gut* 15:34-38, 1974. [PMC free article: PMC1412931] [PubMed: 4274414]
188. Green,D, JOYNT,RJ, VANALLEN,MW: NEUROMYOPATHY ASSOCIATED WITH A MALIGNANT CARCINOID TUMOR. A CASE REPORT. *Arch Intern Med* 114:494-496, 1964. [PubMed: 14184637]
189. Wroe,SJ, Ardron,M, Bowden,AN: Myasthenia gravis associated with a hormone producing malignant carcinoid tumour. *J Neurol Neurosurg Psychiatry* 48:719-720, 1985. [PMC free article: PMC1028424] [PubMed: 2411875]
190. Kraenzlin,ME, Ch'ng,JL, Wood,SM, Carr,DH, Bloom,SR: Long-term treatment of a VIPoma with somatostatin analogue resulting in remission of symptoms and possible shrinkage of metastases. *Gastroenterology* 88:185-187, 1985. [PubMed: 2856877]
191. Saltz,L, Trochanowski,B, Buckley,M, Heffernan,B, Niedzwiecki,D, Tao,Y, Kelsen,D: Octreotide as an antineoplastic agent in the treatment of functional and nonfunctional neuroendocrine tumors. *Cancer* 72:244-248, 1993. [PubMed: 8389666]
192. Anthony,L, Johnson,D, Hande,K, Shaff,M, Winn,S, Krozely,M, Oates,J: Somatostatin analogue phase I trials in neuroendocrine neoplasms. *Acta Oncol* 32:217-223, 1993. [PubMed: 7686764]
193. Janson,ET, Oberg,K: Long-term management of the carcinoid syndrome. Treatment with octreotide alone and in combination with alpha-interferon. *Acta Oncol* 32:225-229, 1993. [PubMed: 7686765]
194. McEwan,AJ, Shapiro,B, Sisson,JC, Beierwaltes,WH, Ackery,DM: Radio-iodobenzylguanidine for the scintigraphic location and therapy of adrenergic tumors. *Semin Nucl Med* 15:132-153, 1985. [PubMed: 3890187]
195. Sisson,JC, Shapiro,B, Beierwaltes,WH, Glowniak,JV, Nakajo,M, Mangner,TJ, Carey,JE, Swanson,DP, Copp,JE, Satterlee,WG, .: Radiopharmaceutical treatment of malignant pheochromocytoma. *J Nucl Med* 25:197-206, 1984. [PubMed: 6726430]
196. Sninsky,CA, Wolfe,MM, Martin,JL, Howe,BA, O'Dorisio,TM, McGuigan,JE, Mathias,JR: Myoelectric effects of vasoactive intestinal peptide on rabbit small intestine. *Am J Physiol* 244:G46-G51, 1983. [PubMed: 6849393]
197. Lamberts,SW, Krenning,EP, Klijn,JG, Reubi,JC: The clinical use of somatostatin analogues in the treatment of cancer. *Baillieres Clin Endocrinol Metab* 4:29-49, 1990. [PubMed: 1975166]
198. Schubert,ML: In vivo somatostatin receptor imaging in the detection and treatment of gastrointestinal cancer. *Gastroenterology* 100:1143-1144, 1991. [PubMed: 1848196]
199. Carrasco,CH, Charnsangavej,C, Ajani,J, Samaan,NA, Richli,W, Wallace,S: The carcinoid syndrome: palliation by hepatic artery embolization. *AJR Am J Roentgenol* 147:149-154, 1986. [PubMed: 2424291]
200. Mekhjian,HS, O'Dorisio,TM: VIPoma syndrome. *Semin Oncol* 14:282-291, 1987. [PubMed: 2820063]
201. Nobin,A, Mansson,B, Lunderquist,A: Evaluation of temporary liver dearterialization and embolization in patients with metastatic carcinoid tumour. *Acta Oncol* 28:419-424, 1989. [PubMed: 2742780]
202. Moertel,CG, Johnson,CM, McKusick,MA, Martin,JK, Jr., Nagorney,DM, Kvols,LK, Rubin,J, Kunselman,S: The management of patients with advanced carcinoid tumors and islet cell carcinomas. *Ann Intern Med* 120:302-

- 309, 1994. [PubMed: 8291824]
203. Kennedy,AS, Warner,R: Radioembolisation for neuroendocrine hepatic metastases. *Cancer Investigation* 25:55-56, 2007.
204. Kennedy,AS, Dezarn,WA, McNeillie,P, Coldwell,D, Nutting,C, Carter,D, Murthy,R, Rose,S, Warner,RR, Liu,D, Palmedo,H, Overton,C, Jones,B, Salem,R: Radioembolization for unresectable neuroendocrine hepatic metastases using resin 90Y-microspheres: early results in 148 patients. *Am J Clin Oncol* 31:271-279, 2008. [PubMed: 18525307]
205. Kwekkeboom,DJ, Krenning,EP, Lebtahi,R, Komminoth,P, Kos-Kudla,B, de Herder,WW, Plockinger,U: ENETS Consensus Guidelines for the Standards of Care in Neuroendocrine Tumors: peptide receptor radionuclide therapy with radiolabeled somatostatin analogs. *Neuroendocrinology* 90:220-226, 2009. [PubMed: 19713714]
206. van Hazel,GA, Rubin,J, Moertel,CG: Treatment of metastatic carcinoid tumor with dactinomycin or dacarbazine. *Cancer Treat Rep* 67:583-585, 1983. [PubMed: 6861165]
207. Moertel,CG, Hanley,JA: Combination chemotherapy trials in metastatic carcinoid tumor and the malignant carcinoid syndrome. *Cancer Clin Trials* 2:327-334, 1979. [PubMed: 93982]
208. Melia,WM, Nunnerley,HB, Johnson,PJ, Williams,R: Use of arterial devascularization and cytotoxic drugs in 30 patients with the carcinoid syndrome. *Br J Cancer* 46:331-339, 1982. [PMC free article: PMC2011132] [PubMed: 6181801]
209. Kvols,LK, Buck,M: Chemotherapy of endocrine malignancies: a review. *Semin Oncol* 14:343-353, 1987. [PubMed: 2820064]
210. Kessinger,A, Foley,JF, Lemon,HM: Therapy of malignant APUD cell tumors. Effectiveness of DTIC. *Cancer* 51:790-794, 1983. [PubMed: 6295614]
211. Bukowski,RM, Tangen,CM, Peterson,RF, Taylor,SA, Rinehart,JJ, Eyre,HJ, Rivkin,SE, Fleming,TR, Macdonald,JS: Phase II trial of dimethyltriazenoimidazole carboxamide in patients with metastatic carcinoid. A Southwest Oncology Group study. *Cancer* 73:1505-1508, 1994. [PubMed: 8111718]
212. Moertel,CG, Rubin,J, O'Connell,MJ: Phase II study of cisplatin therapy in patients with metastatic carcinoid tumor and the malignant carcinoid syndrome. *Cancer Treat Rep* 70:1459-1460, 1986. [PubMed: 3791259]
213. Kelsen D, Fiore J,HRCCEMG: Phase II trial of etoposide in APUD tumors. *Cancer Treat Rep* 71:305-307, 1987. [PubMed: 2434226]
214. Mengel C E, Shaffer RD: The carcinoid syndrome. *In Cancer Medicine* 1973.
215. Engstrom,PF, Lavin,PT, Moertel,CG, Folsch,E, Douglass,HO, Jr.: Streptozocin plus fluorouracil versus doxorubicin therapy for metastatic carcinoid tumor. *J Clin Oncol* 2:1255-1259, 1984. [PubMed: 6238136]
216. Bukowski,RM, Johnson,KG, Peterson,RF, Stephens,RL, Rivkin,SE, Neilan,B, Costanzi,JH: A phase II trial of combination chemotherapy in patients with metastatic carcinoid tumors. A Southwest Oncology Group Study. *Cancer* 60:2891-2895, 1987. [PubMed: 2960446]
217. Oberg,K, Norheim,I, Alm,G: Treatment of malignant carcinoid tumors: a randomized controlled study of streptozocin plus 5-FU and human leukocyte interferon. *Eur J Cancer Clin Oncol* 25:1475-1479, 1989. [PubMed: 2480243]
218. Feldman,JM: Carcinoid tumors and the carcinoid syndrome. *Curr Probl Surg* 26:835-885, 1989. [PubMed: 2701223]
219. Moertel C G, May GR,MJRJSA: Sequential hepatic artery occlusion (HAO. and chemotherapy for metastatic carcinoid tumor and islet cell carcinoma. *Proc Am Soc Clin Oncol* 4:80, 1985.
220. Oberg,K, Eriksson,B: Medical treatment of neuroendocrine gut and pancreatic tumors. *Acta Oncol* 28:425-431, 1989. [PubMed: 2472826]
221. Hanssen,LE, Schrupf,E, Kolbenstvedt,AN, Tausjo,J, Dolva,LO: Treatment of malignant metastatic midgut carcinoid tumours with recombinant human alpha2b interferon with or without prior hepatic artery embolization. *Scand J Gastroenterol* 24:787-795, 1989. [PubMed: 2477894]
222. Sisson J C, Hutchinson RJ,JJ: Acute toxicity of therapeutic I-131-MIBG relates more to whole body than to

- blood radiation dosimetry. *J Nucl Med* 23:618, 1987.
223. Oberg,K: The action of interferon alpha on human carcinoid tumours. *Semin Cancer Biol* 3:35-41, 1992. [PubMed: 1353693]
224. Frank,M, Klose,KJ, Wied,M, Ishaque,N, Schade-Brittinger,C, Arnold,R: Combination therapy with octreotide and alpha-interferon: effect on tumor growth in metastatic endocrine gastroenteropancreatic tumors. *Am J Gastroenterol* 94:1381-1387, 1999. [PubMed: 10235222]
225. Moertel,CG, Rubin,J, Kvols,LK: Therapy of metastatic carcinoid tumor and the malignant carcinoid syndrome with recombinant leukocyte A interferon. *J Clin Oncol* 7:865-868, 1989. [PubMed: 2738623]
226. Grozinsky-Glasberg,S, Franchi,G, Teng,M, Leontiou,CA, Ribeiro de,OA, Jr., Dalino,P, Salahuddin,N, Korbonits,M, Grossman,AB: Octreotide and the mTOR Inhibitor RAD001 (Everolimus) Block Proliferation and Interact with the Akt-mTOR-p70S6K Pathway in a Neuro-Endocrine Tumour Cell Line. *Neuroendocrinology* 2007. [PubMed: 18025810]
227. Ajani J, Carrasco C,CC: Islet cell tumors metastatic to the liver: effective palliation by sequential hepatic artery embolization. *Proc Am Soc Clin Oncol* 4:80, 1989.
228. Abrams,TJ, Lee,LB, Murray,LJ, Pryer,NK, Cherrington,JM: SU11248 inhibits KIT and platelet-derived growth factor receptor beta in preclinical models of human small cell lung cancer. *Mol Cancer Ther* 2:471-478, 2003. [PubMed: 12748309]
229. Vignot,S, Faivre,S, Aguirre,D, Raymond,E: mTOR-targeted therapy of cancer with rapamycin derivatives. *Ann Oncol* 16:525-537, 2005. [PubMed: 15728109]
230. Kiepe,D, Ciarmatori,S, Hoeflich,A, Wolf,E, Tonshoff,B: Insulin-like growth factor (IGF)-I stimulates cell proliferation and induces IGF binding protein (IGFBP)-3 and IGFBP-5 gene expression in cultured growth plate chondrocytes via distinct signaling pathways. *Endocrinology* 146:3096-3104, 2005. [PubMed: 15845624]
231. Ha,CH, Bennett,AM, Jin,ZG: A novel role of vascular endothelial cadherin in modulating c-Src activation and downstream signaling of vascular endothelial growth factor. *J Biol Chem* 2008. [PMC free article: PMC4228940] [PubMed: 18180305]
232. Smolewski,P: Recent developments in targeting the mammalian target of rapamycin (mTOR) kinase pathway. *Anticancer Drugs* 17:487-494, 2006. [PubMed: 16702804]
233. Duran,I, Kortmansky,J, Singh,D, Hirte,H, Kocha,W, Goss,G, Le,L, Oza,A, Nicklee,T, Ho,J, Birle,D, Pond,GR, Arboine,D, Dancey,J, viel-Ronen,S, Tsao,MS, Hedley,D, Siu,LL: A phase II clinical and pharmacodynamic study of temsirolimus in advanced neuroendocrine carcinomas. *Br J Cancer* 95:1148-1154, 2006. [PMC free article: PMC2360568] [PubMed: 17031397]
234. Yao JC, Phan A, Chang DZ, Wolff RA, Jacobs C, Mares JE, Gupta S, Meric-Bernstam F, Rashid A: Phase II study of RAD001 (everolimus) and depot octreotide (sandostatin LAR) in patients with advanced low grade neuroendocrine carcinoma (LGNET) (Abstract). *Journal of Clinical Oncology* 25: 18S, 2007.
235. Awada,A, Cardoso,F, Fontaine,C, Dirix,L, De,GJ, Sotiriou,C, Steinseifer,J, Wouters,C, Tanaka,C, Zoellner,U, Tang,P, Piccart,M: The oral mTOR inhibitor RAD001 (everolimus) in combination with letrozole in patients with advanced breast cancer: Results of a phase I study with pharmacokinetics. *Eur J Cancer* 44:84-91, 2008. [PubMed: 18039566]
236. Yao,JC, Shah,MH, Ito,T, Bohas,CL, Wolin,EM, Van,CE, Hobday,TJ, Okusaka,T, Capdevila,J, de Vries,EG, Tomassetti,P, Pavel,ME, Hoosen,S, Haas,T, Lincy,J, Lebwohl,D, Oberg,K: Everolimus for advanced pancreatic neuroendocrine tumors. *N Engl J Med* 364:514-523, 2011. [PMC free article: PMC4208619] [PubMed: 21306238]
237. Strosberg, JR, Weber, JM, Feldman, M, Coppola, D, Meredith, K, Kvols, LK: Prognostic validity of the American Joint Committee on Cancer staging classification for midgut neuroendocrine tumors. *J Clin Oncol* 31:420-425, 2013. [PubMed: 23248248]
238. Jann,H, Roll,S, Couvelard,A, Hentic,O, Pavel,M, Muller-Nordhorn,J, Koch,M, Rocken,C, Rindi,G, Ruszniewski,P, Wiedenmann,B, Pape,UF: Neuroendocrine tumors of midgut and hindgut origin: tumor-node-metastasis classification determines clinical outcome. *Cancer* 117:3332-3341, 2011. [PubMed: 21246527]

239. Godwin,JD: Carcinoid tumors. An analysis of 2,837 cases. *Cancer* 36:560-569, 1975. [PubMed: 1157019]
240. Jensen,EH, Kvols,L, McLoughlin,JM, Lewis,JM, Alvarado,MD, Yeatman,T, Malafa,M, Shibata,D: Biomarkers predict outcomes following cytoreductive surgery for hepatic metastases from functional carcinoid tumors. *Ann Surg Oncol* 14:780-785, 2007. [PubMed: 17146740]
241. Stronge,RL, Turner,GB, Johnston,BT, McCance,DR, McGinty,A, Patterson,CC, Ardill,JE: A rapid rise in circulating pancreastatin in response to somatostatin analogue therapy is associated with poor survival in patients with neuroendocrine tumours. *Ann Clin Biochem* 45:560-566, 2008. [PubMed: 18782815]
242. Bloomston,M, Al-Saif,O, Klemanski,D, Pinzone,JJ, Martin,EW, Palmer,B, Guy,G, Khabiri,H, Ellison,EC, Shah,MH: Hepatic artery chemoembolization in 122 patients with metastatic carcinoid tumor: lessons learned. *J Gastrointest Surg* 11:264-271, 2007. [PubMed: 17458596]

Copyright © 2000-2015, MDText.com, Inc.

This electronic version has been made freely available under a Creative Commons (CC-BY-NC-ND) license. A copy of the license can be viewed at <http://creativecommons.org/licenses/by-nc-nd/2.0/>.

Bookshelf ID: NBK279162 PMID: 25905385