

## Review Article

# Transmissible Spongiform Encephalopathies Affecting Humans

**Dudhatra G. B., Avinash Kumar, Modi C. M., Awale M. M., Patel H. B., and Mody S. K.**

*Department of Pharmacology & Toxicology, College of Veterinary Science & Animal Husbandry, Sardarkrushinagar Dantiwada Agricultural University, Sardarkrushinagar 385506, Gujarat, India*

Correspondence should be addressed to Dudhatra G. B.; [drgvets@gmail.com](mailto:drgvets@gmail.com)

Received 2 April 2012; Accepted 5 May 2012

Academic Editors: A. Carvalho, K. Peoc'H, and T. A. Rupprecht

Copyright © 2013 Dudhatra G. B. et al. This is an open access article distributed under the Creative Commons Attribution License, which permits unrestricted use, distribution, and reproduction in any medium, provided the original work is properly cited.

Transmissible spongiform encephalopathies (TSEs) or prion diseases are group of rare and rapidly progressive fatal neurologic diseases. The agents responsible for human prion diseases are abnormal proteins or prion that can trigger chain reactions causing normal proteins in the brain to change to the abnormal protein. These abnormal proteins are resistant to enzymatic breakdown, and they accumulate in the brain, leading to damage. TSEs have long incubation periods followed by chronic neurological disease and fatal outcomes, have similar pathology limited to the CNS including convulsions, dementia, ataxia, and behavioral or personality changes, and are experimentally transmissible to some other species.

## 1. Introduction

Human transmissible spongiform encephalopathies (TSEs or prion diseases) include Creutzfeldt-Jakob disease (CJD), Gerstmann-Straussler-Scheinker disease (GSS), fatal familial insomnia (FFI), kuru, and variant CJD (vCJD). CJD has several subcategories: Sporadic (sCJD, accounting for 80–90% of CJD cases); Familial (hereditary CJD); Iatrogenic (associated with treatment and transplant, such as use of infected dura mater patches or administration of human pituitary-derived hormones); and variant (vCJD, associated with exposure to bovine spongiform encephalopathy [BSE]). Uniquely, they may arise spontaneously, be genetically inherited, or acquired via infection, and they all have the potential to be transmissible. Clinical features comprise rapidly progressive dementia accompanied by cerebellar ataxia and myoclonus.

Definitive diagnosis can be made from postmortem examination of brain tissue showing the classical histopathological triad: spongiform change, severe neuronal loss, and marked astrogliosis; these are sometimes accompanied by PrP<sup>Sc</sup>-containing amyloid plaque deposits. Inherited forms of prion disease support the protein-only hypothesis of prion propagation and highlight the importance of PrP<sup>C</sup> in disease. A polymorphism at amino acid residue 129 of the prion protein [which encodes methionine (M) or valine (V)] confers genetic susceptibility for development of prion disease. 38% of Europeans are homozygous for M at codon

129, 51% are heterozygous, and 11% are homozygous for V [1].

Methionine homozygotes (codon 129MM) are at a higher risk of developing prion disease, which may be explained by the increased propensity of PrP to form PrP<sup>Sc</sup>-like structures (Figure 1) *in vitro* [2], whereas heterozygosity (codon 129MV) is thought to confer resistance to disease by inhibiting homologous PrP protein-protein interactions [1].

## 2. Creutzfeldt-Jakob Disease (CJD)

Creutzfeldt-Jakob disease or CJD is a degenerative neurological disorder that is incurable and invariably fatal. It is the most common among the types of transmissible spongiform encephalopathy found in humans. Patients with rapidly progressive neurodegenerative illnesses were first reported by the German neurologists Creutzfeldt and Jakob in the early 1920s.

*2.1. Cause of CJD.* The prion that is believed to cause Creutzfeldt-Jakob exhibits at least two stable conformations. One is water soluble and present in healthy cells. The other conformational state is very poorly water soluble and readily forms protein aggregates. People can also acquire CJD genetically through a mutation of the gene that codes for the prion protein (PRNP). This occurs in only 5–10% of all CJD cases.

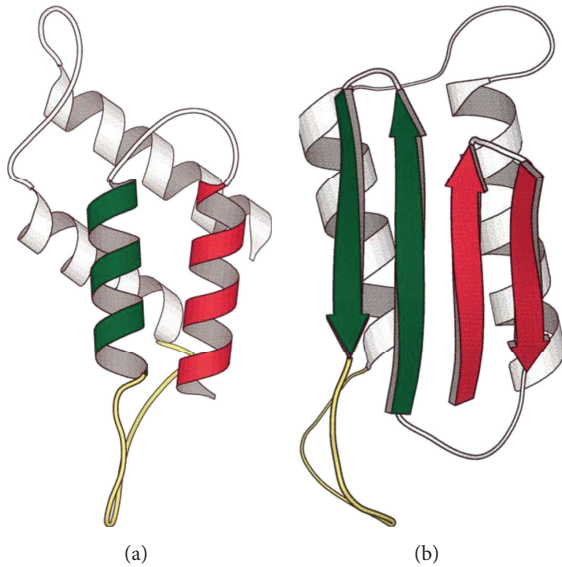


FIGURE 1: The structure of PrP. (a) The normal PrP structure and it consists of alpha helices and (b) the structure of PrP<sup>Sc</sup> structure and it consists of beta sheets.

The CJD prion is dangerous because it promotes refolding of native proteins into the diseased state. The number of misfolded protein molecules will increase exponentially, and the process leads to a large quantity of insoluble prions in affected cells. This mass of misfolded proteins disrupts cell function and causes cell death. Mutations in the gene for the prion protein can cause a misfolding of the dominantly  $\alpha$ -helical regions into  $\beta$ -pleated sheets. This change in conformation disables the ability of the protein to undergo digestion. Once the prion is transmitted, the defective proteins invade the brain and are produced in a self-sustaining feedback loop, causing exponential spread of the prion, leading to death within a few months, although a few patients have lived as long as two years.

**2.2. Incidence of CJD.** CJD is the most common form of TSEs in humans and occurs worldwide, with an estimated incidence of one case/million populations/year. CJD is reported in almost equal ratios between the sexes, although older males ( $\geq 60$  years of age) appear to have a higher incidence of disease [3]. Brown et al. [4] have reported a peak age of onset between 55 and 75 years (mean: 61.5 years).

**2.3. Transmission of CJD.** The defective protein can be transmitted by contaminated harvested human growth hormone (HGH) products, immunoglobulins (Igs), corneal grafts, dural grafts, or electrode implants (acquired or iatrogenic form: iCJD); it can be inherited (hereditary or familial form: fCJD), or it may appear for the first time in the patient (sporadic form: sCJD). In the hereditary form, a mutation occurs in the gene for PrP and PRNP. 10–15% of CJD cases are inherited.

It is thought that humans can contract the disease by consuming material from animals infected with the bovine form of the disease. The only suspected cases to arise thus far

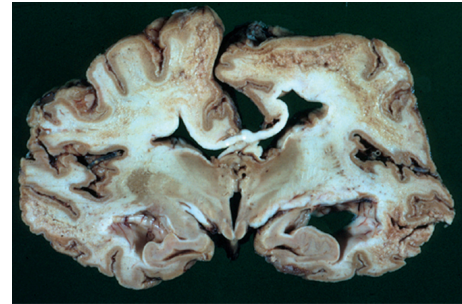


FIGURE 2: Brain atrophy in CJD.

have been vCJD, although there are fears based on animal studies that consuming beef or beef products containing prion particles can also cause the development of classic CJD. When BSE material infects humans, the resulting disease is known as (new) variant CJD Disease (nvCJD) [5].

Prions, the infectious agent of CJD, may not be inactivated by means of routine surgical instrument sterilization procedures. The World Health Organization and the U.S. Centers for Disease Control and Prevention recommend that instrumentation used in such cases be immediately destroyed after use; secondary to destruction, it is recommended that heat and chemical decontamination be used in combination to process instruments that come in contact with high-infectivity tissues. Copper-hydrogen peroxide has been suggested as an alternative to the current recommendation of sodium hydroxide or sodium hypochlorite [6]. Thermal depolymerization also destroys prions in infected organic and inorganic matter, since the process dissolves protein at the molecular level.

**2.4. Clinical Features of CJD.** CJD has been recognized to occur sporadically, through iatrogenic transmission, as a familial form. The pathological feature in CJDs is represented in Table 1. Affected patients usually present with a rapidly progressive dementia, visual abnormalities, atrophy of brain (Figure 2), or cerebellar dysfunction (Figure 3), including muscle incoordination and gait and speech abnormalities. During the course of the disease, most patients develop pyramidal and extrapyramidal dysfunction with abnormal reflexes, spasticity, tremors, and rigidity; some patients may also show behavioral changes with agitation, depression, or confusion. These symptoms often deteriorate very rapidly, and patients develop a state of akinetic mutism during the terminal stages of the illness. Myoclonus, the most constant physical sign, is present in nearly 90% of CJD patients [7].

CJD is invariably fatal, with a median illness duration of 4 months (mean: 7.6 months); death occurs within 12 months of illness onset in  $\sim 85$ –90% of patients. Although a nonspecific, diffusely abnormal electroencephalogram (EEG) tracing is seen in all patients, serial EEG recordings will demonstrate the typical diagnostic pattern in  $\sim 75$ –85% of patients toward the latter part of the illness [4]. The diagnostic EEG tracing shows one cycle to two cycles per second triphasic sharp-wave discharges [8], which in conjunction with the clinical picture is considered to be diagnostic of CJD.

TABLE 1: Pathological features in CJSs [35].

Characteristic	Typical sporadic CJD	Variant CJD
Median age at death	68 years	28 years
Median duration of illness	4-5 months	13-14 months
Clinical signs and symptoms	Dementia: early neurologic signs	Prominent psychiatric/behavioral symptoms: painful dysesthesias: delayed neurologic signs
Periodic sharp waves on electroencephalogram	Often present	Often absent
Signal hyperintensity in the caudate nucleus and putamen on diffusion-weighted and FLAIR MRI	Often present	Often absent
Pulvinar signon MRI	Not reported	Present in >75% of cases
Immunohistochemical analysis of brain tissue	Variable accumulation	Marked accumulation of protease-resistant prion protein
Presence of agent in lymphoid tissue	Not readily detected	Readily detected
Increased glycoform ratio on immunoblot analysis of protease-resistant prion protein	Not reported	Marked accumulation of protease-resistant prion protein
Presence of amyloid plaques in brain tissue	May be present	May be present

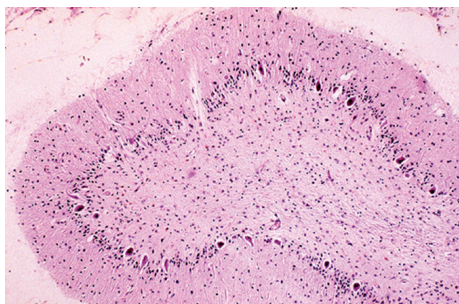


FIGURE 3: Cerebellar degeneration with loss of Purkinje and granular neurons in CJD.

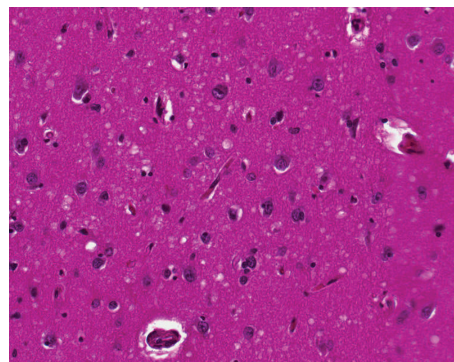


FIGURE 4: Spongiform changes in CJD.

The immunoassay has been developed to detect the presence in the cerebrospinal fluid of 14-3-3 protein, which appears to be a marker for CJD. The 14-3-3 protein is a highly conserved protein found in insects, plants, and mammals. In humans and other mammals, 14-3-3 is a normal neuronal protein consisting of several isoforms. Antibodies against the 14-3-3 protein do not cross-react with PrP<sup>res</sup>, confirming that these two proteins are different. In patients with dementia, the sensitivity of the 14-3-3 immunoassay in detecting CJD patients was reported to be 96%; the specificity varied from 96–99% [9].

However, confirmatory diagnosis of CJD requires demonstration of the typical neuropathology or the presence of PrP<sup>res</sup> in brain tissue obtained at biopsy or autopsy. The typical neuropathology consists of a microscopic picture of spongiform changes (Figure 4), vacuolation (Figure 5), gliosis, and neuronal loss in the absence of inflammatory reaction [10]. The presence of amyloid plaques can be demonstrated in ~5% of CJD patients [11]. The presence of PrP<sup>res</sup> in biopsy or autopsy brain samples can be demonstrated by immunodiagnostic tests, such as immunohistochemical staining, histoblot, or Western blot techniques [10].

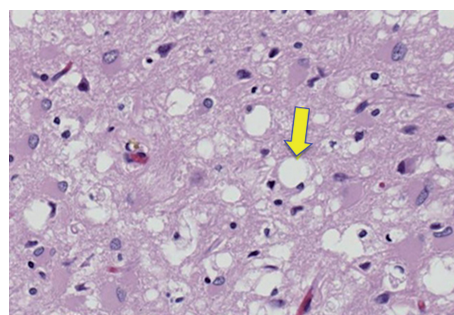


FIGURE 5: Vacuolation in brain in CJD.

### 3. Variant Creutzfeldt-Jakob Disease (vCJD)

**3.1. Sporadic Creutzfeldt-Jakob Disease (sCJD).** Sporadic CJD (sCJD) affects one per million populations per year worldwide [12]. It is a rapidly progressive multifocal dementia with an age of onset between 45–75 years and a mean duration of 5 months [13]. Individuals initially experience insomnia, depression, and ill-defined pain sensations, as well as manifesting movement disorders. Definitive diagnosis



of sCJD is by postmortem or brain biopsy. PrP amyloid plaques are not typically present in sCJD, but PrP immunohistochemistry is nearly always positive [14].

sCJD accounts for 85% of human prion disease cases, all of which have been documented in patients with no family history of prion disease and no known exposure to prions. Therefore, although a genetic or infectious cause cannot be excluded in all cases, the etiology of sCJD is uncertain. The two main possible causes are either spontaneous somatic PRNP mutation [15] or spontaneous conversion of PrP<sup>C</sup> to PrP<sup>Sc</sup> as a rare stochastic event [16]. As aforementioned, susceptibility to human prion disease is influenced by a polymorphism at residue 129 of human PrP [17], and homozygosity predisposes to sporadic and acquired forms of CJD. Moreover, genetic studies have revealed polymorphisms upstream of exon 1 of the PRNP gene [18] and a 129MV independent polymorphism in the 5' untranslated region (UTR) of the PRNP gene [19], both of which have been associated with sCJD.

Histologic examination of the brain and immunostaining for PrP<sup>res</sup> is the gold standard for diagnosis. The crucial features are spongiform change accompanied by neuronal loss and gliosis; amyloid plaques are found in 10% of brains in the sporadic form of the disease. In contrast, plaques are common in kuru, some familial spongiform encephalopathies, and new variant Creutzfeldt-Jakob disease. In all cases, immunocytochemical staining for PrP<sup>res</sup> shows diffuse synaptic and perivacuolar staining, with striking staining of plaques when they are present [20].

**3.2. Familial Creutzfeldt-Jakob Disease (fCJD).** About 10–15% of persons with Creutzfeldt-Jakob disease have a family history consistent with an autosomal dominant inheritance of the disease. In most of these kindreds, point mutations, deletions, or insertions are found in the coding sequence of the gene for PrP on the short arm of chromosome 20. More than 20 mutations in this gene have been described that are associated with phenotypes mimicking typical Creutzfeldt-Jakob disease or that induce distinctive progressive diseases with spongiform changes in the nervous system. In general, familial Creutzfeldt-Jakob disease has an earlier age of onset and a more protracted course than sporadic disease. The typical electroencephalographic changes are often missing, and the 14-3-3 protein is not detected in cerebrospinal fluid in about half of cases [21].

The neuropathological changes may vary in topographic distribution and in the prevalence of amyloid plaques, but the essential changes of vacuolization of neural cells with gliosis and neuronal loss are generally present. Several mutations are of special note. The most common mutation leading to the typical clinical and pathological findings of Creutzfeldt-Jakob disease is at codon 200. The disease has a prolonged course of 5 to 11 years, yet the mean age at death is only 48 years. The neuropathological findings are distinct, with many PrP<sup>res</sup>-positive amyloid plaques throughout the brain [22].

**3.3. Iatrogenic Creutzfeldt-Jakob Disease (iCJD).** Routes of unintentional inoculation documented include (a) use of inappropriately sterilized surgical instruments or intracerebral electroencephalogram (EEG) electrodes, (b) duramater grafts, (c) corneal grafting, and (d) use of human cadaveric pituitary-derived growth hormone or gonadotropin. The two most frequent causes of iatrogenic CJD (iCJD) are from dura mater grafts and hormone administration [23].

Interestingly, cases in which prion disease was acquired via an intracerebral or optic route clinically present with a rapidly progressive dementia, similar to sCJD [24]. In contrast, cases from peripheral inoculation manifest with progressive ataxia as a prominent early symptom, rather than dementia, in a manner similar to kuru [25].

**Surgical Transmission.** The first suspected human transmission was reported in 1974 when rapidly progressive disease developed in a woman 18 months after she received a corneal transplant. The donor had died of undiagnosed Creutzfeldt-Jakob disease [26].

Human transmission was more dramatically and convincingly demonstrated when Creutzfeldt-Jakob disease developed in two young patients 16 and 20 months after they underwent surgery to excise epileptic foci. Contaminated neurosurgical instruments have been suspected as modes of transmission in other patients [27].

**Transmission by Pituitary Hormones.** In 1985 Creutzfeldt-Jakob disease developed in four patients who had received human growth hormone, all of them under 40 years of age. Injection of the hormone, which was derived from pooled cadaveric human pituitary glands, had been discontinued 4 to 15 years before the onset of disease [28].

The differences in the frequency of transmission and the length of incubation probably reflect variable contamination resulting from different protocols for hormone extraction. Nevertheless, in all affected countries, growth-hormone-related disease begins with cerebellar ataxia and movement disorders, with dementia developing late. Pathological changes in the cerebellum and basal ganglia are prominent on autopsy.

**Risks Associated with Blood Products.** Although the hazards of injection or transplantation of affected human tissues are obvious, the possible hazards of transmission through human blood products are debatable. Several sorts of evidence have failed to demonstrate a role of human blood products. No epidemiologic evidence has incriminated a history of blood transfusion. The disease has not been found in patients with hemophilia. Intravenous drug use does not increase the risk. Tracking of blood donated by those in whom Creutzfeldt-Jakob disease subsequently developed has not uncovered the disease in recipients [29].

However, anecdotal reports of disease after the administration of blood products to humans [30], and several reports of disease in mice inoculated intracerebrally with blood from patients with Creutzfeldt-Jakob disease [31], have led to concern.

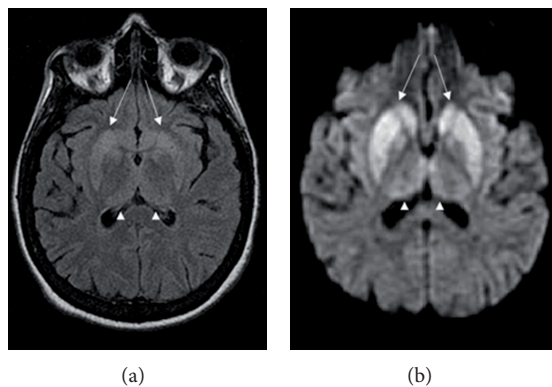


FIGURE 6: Changes in the basal ganglia seen in CJD. (a) Fluid-attenuated inversion recovery MRI and (b) diffusion-weighted MRI of the same patient demonstrate bilateral basal ganglia hyperintensities (arrows).

### 3.4. Diagnosis and Treatment of CJD for Sections 2 and 3

**3.4.1. Diagnosis of CJD.** The diagnosis of CJD is suspected when there are typical clinical symptoms and signs such as rapidly progressing dementia with myoclonus. Further investigation can then be performed to support the diagnosis including what follows.

- (i) Electroencephalography often has characteristic triphasic waves.
- (ii) Cerebrospinal analysis for detection of 14-3-3 protein.
- (iii) MRI (Figure 6) of the brain often shows high signal intensity in the caudate nucleus and putamen bilaterally on  $T_2$ -weighted images.

Diffusion-Weighted Imaging (DWI) images are the most sensitive. In about 24% of cases DWI shows only cortical hyperintensity; in 68%, cortical and subcortical abnormalities and in 5%, only subcortical anomalies. The involvement of the thalamus can be found in sCJD, is even stronger and more constant in vCJD [32].

In recent years, studies have shown that the tumor marker Neuron-specific enolase (NSE) is often elevated in CJD cases; however, its diagnostic utility is primarily seen when combined with a test for the 14-3-3 protein [33]. Screening tests to identify infected asymptomatic individuals, such as blood donors, are not yet available, though methods have been proposed and evaluated [34].

In one-third of patients with sporadic CJD, deposits of “prion protein (scrapie),” PrP<sup>Sc</sup>, can be found in the skeletal muscle and/or the spleen. Diagnosis of vCJD can be supported by biopsy of the tonsils, which harbor significant amounts of PrP<sup>Sc</sup>; however, biopsy of brain tissue is the definitive diagnostic test.

The classic histologic appearance is the spongiform change in the gray matter: the presence of many round vacuoles from 1–50  $\mu\text{m}$  in the neuropil, in all six cortical layers in the cerebral cortex or with diffuse involvement of the cerebellar molecular layer. These vacuoles appear glassy

or eosinophilic and may coalesce. Neuronal loss and gliosis are also seen. Plaques of amyloid-like material can be seen in the neocortex in new variant CJD. An abnormal signal in the posterior thalami on  $T_2$ , diffusion-weighted images and fluid-attenuated inversion recovery sequences on brain magnetic resonance imaging (MRI); in appropriate clinical context is highly specific for vCJD.

**3.4.2. Treatment of CJD.** No generally accepted treatment for CJD exists; the disease is invariably fatal and research continues. The medication, called pentosan polysulphate (PPS) and used to treat interstitial cystitis, is infused into the patient’s lateral ventricle within the brain. PPS does not seem to stop the disease from progressing, and both brain function and tissue continue to be lost. Scientists have investigated using RNA interference to slow the progression of scrapie in mice. The RNA blocks production of the protein that the CJD process transforms into prions. This research is unlikely to lead to a human therapy for many years [36]. Both amphotericin B and doxorubicin have been investigated as potentially effective against CJD, yet there is no strong evidence that either drug is effective. Further study has been taken with other medical drugs, but none are effective. Pilot studies showed quinacrine permanently cleared abnormal prion proteins from cell cultures, but results have not yet been published on the clinical study.

## 4. Gerstmann-Straussler-Scheinker Syndrome (GSS)

Gerstmann-Straussler-Scheinker syndrome (GSS) is a very rare, usually familial, fatal neurodegenerative disease that affects patients from 20–60 years in age. This extremely rare disease is classified as a transmissible spongiform encephalopathy (TSE). The exact incidence of GSS is unknown but is estimated to be between 1–10/100 million. GSS, a familial disease with autosomal dominant inheritance, was first described in 1936 by Gerstmann et al. [37]. Familial cases are associated with autosomal dominant inheritance [38].

**4.1. Causes.** GSS is considered a variant of the familial form of CJD, but it is primarily associated with mutations at codon 102 and less frequently with mutations at codon 105, 117, 145, 198, or 217 of the prion protein gene [39].

A change in codon 102 from proline to leucine on chromosome 20 has been found in the prion protein gene (PRNP) of most affected individuals [40]. Therefore, it appears this genetic change is usually required for the development of the disease. It occurs at an estimated annual incidence of 5 cases/100 million populations. GSS is one of a small number of diseases which are caused by prions, a class of pathogenic proteins highly resistant to proteases.

**4.2. Codon 102.** The prion protein gene mutation at codon 102, the most frequently seen mutation in GSS, is associated with a predominantly cerebellar dysfunction at the time of

clinical presentation, early age at onset (mean, 48 years), and a prolonged duration of illness (mean, 5 years) [39]; patients commonly present with slowly progressive gait abnormalities and ataxia. This form of GSS has been reported in families from Austria, Britain, Canada, France, Germany, Israel, Italy, Japan, and the United States [41]. Pedigree and genetic analyses of a 39-year-old woman with GSS indicated that the original Austrian family reported by Gerstmann and co-workers carries a prion protein mutation at codon 102 [42].

**4.3. Symptoms.** Neurologic signs and symptoms that are commonly reported in GSS patients include cerebellar ataxia, gait abnormalities, dementia, dysarthria, ocular dysmetria, and hyporeflexia or areflexia in the lower extremities [7].

Loss of memory can be the first symptom of GSS. The neuropathological findings of GSS include widespread deposition of amyloid plaques comprised of abnormally folded prion protein [43]. However, the different prion protein gene mutations in GSS patients are associated with a widely variable clinical presentation, age at onset, and duration of illness.

**4.4. Prognosis.** There is no cure or treatment for GSS. Symptoms may appear as early as 25 years of age, but usually in the late 50's. Duration of illness can range from 3 months to 13 years, with an average duration of 5 or 6 years [43].

## 5. Fatal Familial Insomnia (FFI)

The descriptive diagnosis FFI was first used in 1986 to depict an illness afflicting five members of a large Italian family [44] but it was not until 1992 that the disorder was proposed as a novel, genetically determined prion disease [45]. Sequencing of PRNP (Figure 7) in three symptomatic members of the family confirmed a GAC-to-AAC mutation at codon 178 of the gene, causing substitution of asparagine for aspartic acid (D178N). The brains of typical D178N FFI patients show a characteristic-restricted degeneration, largely confined to the thalami, especially the mediodorsal and anteroventral nuclei, as well as the inferior olivary nuclei [45].

A family history of similar disorder may be absent in FFI patients carrying the D178N mutation [46], and rarely, close clinicopathological phenocopies are encountered in individuals without a PRNP mutation [47], and also in patients with other PRNP mutations, such as E200K usually found in association with familial CJD [48]. Of importance, retrospective geneticopathological analysis of families classified generically as "selective thalamic degeneration" showed the majority of pedigrees examined to harbor the same D178N PRNP mutation, prompting their more correct classification as FFI [49].

Of interest, the same (D178N) mutation had previously been described as the cause of familial CJD in a number of unrelated kindreds, stimulating discussion as to explanations for this apparent clinicogenetic disparity [50]. The answer was postulated to reside in the modifying influence of a normal polymorphism at codon 129 of PRNP; FFI was found to segregate with the D178N mutation when combined in *cis*

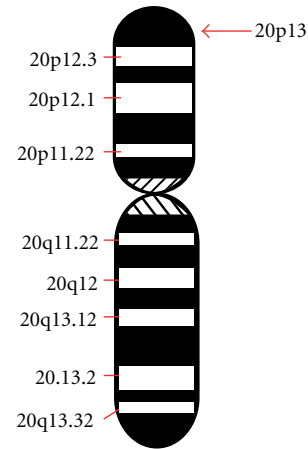


FIGURE 7: Location of the PRNP gene in chromosome 20 in FFI.

with methionine at codon 129 (D178N-129M), whereas CJD was linked to valine at the latter coding position (D178N-129V) [51].

Subsequent investigations revealed subtle differences in the cellular metabolism of D178N-129M and D178N-129V gene products after transfection into human neuroblastoma cells [52] as well as more clear-cut differences in the glycoform ratios and electrophoretic mobilities of their protease-resistant derivatives [53]. In association with the CJD phenotype coupled to the D178N-129V genotype, the relative mobility of deglycosylated PrP<sup>Sc</sup> is approximately 21 kDa, whereas in FFI linked to D178N-129M, the analogous fragment runs at around 19 kDa [54].

Certainly, very modest or absent insomnia and essentially normal sleep electroencephalographic studies are well described throughout the illnesses of symptomatic D178N-129M patients [55].

**5.1. Clinical Features.** Nonspecific symptoms such as marked weight loss can be an early feature as well as lethargy and tiredness [56]. The core clinical features of FFI consist of profound disruption of the normal sleep-wake cycle (with complete disorganization of the electroencephalographic patterns of sleep), sympathetic over activity, diverse endocrine abnormalities (particularly attenuation of the normal circadian oscillations), and markedly impaired attention. The manifestations of defective homeostasis are subserved by the severe, selective loss of the thalamic mediodorsal and anteroventral nuclei which have prominent integrative and relay functions between the cerebral cortex and brain stem within the limbic system and central autonomic network. Dysfunction of the mediodorsal nucleus is believed to be most closely linked to the disordered sleep, with failure of transmission of spindling activity from the reticular nucleus of the thalamus thought to explain its absence at the cerebral cortex. Analogously, this functional disconnection between the limbic cortex and the hypothalamus is postulated to explain the autonomic dysregulation and endocrine disturbances. Degeneration of the thalamic anteroventral nucleus is proposed to underlie the behavioral changes and attention deficits [57].



Sleep disruption, characterized by prominent nocturnal insomnia, constitutes the salient clinical hallmark of this disorder. The disturbance may initially be relatively minor but usually progresses over weeks to months until in its fully developed form of normal sleep may not be possible, supplanted by stupor usually accompanied by frequent, vivid dreams which may be acted upon while still somnolent [44]. Prompt arousal with light stimuli remains characteristic but not invariable [58], and as cognition fails, patients may not be able to recall their intrusive dreams. A variety of probable (auditory, visual, and tactile) hallucinations may occur in addition to the parasomnias and further contribute to the bizarre nocturnal behaviors and oneiric automatisms which can be observed [59].

Dysautonomia is the other major distinguishing clinical feature of FFI, and may be noticeably episodic. Often reflecting sympathetic overactivity, its broader manifestations include impotence; sphincteric dysfunction; excessive salivation; rhinorrhea; lacrimation; hyperthermia; hyperhidrosis; tachycardia; hypertension. Autonomic dysfunction tends to occur relatively early in the clinical course and may be the presenting symptom. As the illness evolves, a range of motor abnormalities usually evolve in variable combinations. Cerebellar and pyramidal dysfunction culminates in prominent limb, gait, and bulbar difficulties, accompanied by hyperreflexia, up going plantar responses, intention tremor, and dysmetria. Spontaneous and reflex myoclonus is commonly present. Disorders of ocular movement and generalized hypertonia may also be seen. Respiration is frequently altered and may display tachypnoea or an irregular noisy pattern with intermittent apnea and hypoventilation [60]. Cognitive impairment usually develops later in the evolution of the illness, but may remain relatively mild and restricted to amnesive difficulties on formal neuropsychological testing [61].

**5.2. Treatment.** There is no cure or treatment for FFI. Gene therapy is so far unsuccessful. While it is not currently possible to reverse the underlying illness, there is some evidence that treatments that focus upon the symptoms can improve quality of life [62].

Recently, a mouse model was made for FFI. These mice express a humanized version of the PrP protein that also contains the D178N FFI mutation [63]. These mice appear to have progressively fewer and shorter periods of uninterrupted sleep, damage in the thalamus, and early deaths, similar to people with FFI.

## 6. Kuru

Kuru was the first known human-acquired prion disease, which emerged as a major epidemic in the 1950s as a result of endocannibalism in the Fore linguistic tribe of the Eastern Highlands of Papua New Guinea [64]. Kuru represents the only known example of a human prion disease epidemic and has provided much of the knowledge we have regarding acquired human prion disease. Kuru predominantly affected women and children who practiced cannibalism as a sign

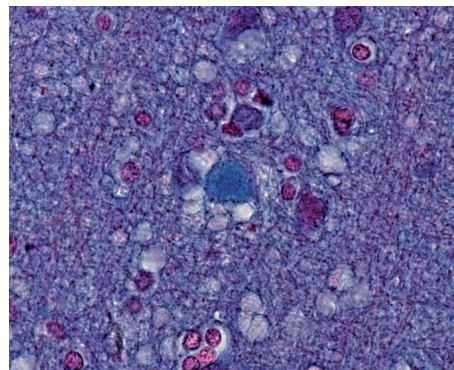


FIGURE 8: Amyloid plaques in kuru.

of respect and mourning for deceased relatives [65]. The epidemic is thought to have started when an individual with sCJD was consumed at one of these ritual feasts. Thereafter, prion recycling is the most likely reason for the extent of the epidemic. Following the ban of cannibalism by the Australian government in the late 1950s, there have been no new kuru cases [66].

Clinically, kuru is a cerebellar syndrome with an almost complete absence of dementia [65]. Amyloid plaques (Figure 8) are also seen in this disease. Disease onset ranges from 5 to >60 years, whilst its duration can last from 3 months to 3 years. Kuru incubation periods vary from as little as 4.5 years to over 50 years [67]. The residue 129 genotype has a profound effect on incubation period and susceptibility to kuru, with the MM genotype having the shortest incubation period [68], followed by VV homozygotes; MV heterozygotes (the most resistant genotype) have been reported to show incubation times >50 years [67]. Strikingly, 129 homozygotes have been essentially eliminated as kuru imposed a strong balancing selection on the Fore population. Elderly women survivors of the kuru epidemic, who were previously exposed to mortuary feasts, are predominantly PRNP129 heterozygotes [64].

## 7. Therapeutic Strategies in Transmissible Spongiform Encephalopathies

TSEs or prion diseases are currently incurable and there are no available effective drugs for individuals who are already infected [69]. If prion propagation depends on the conversion of PrP<sup>C</sup> to PrP<sup>Sc</sup>, then the prevention of this conversion should prevent disease progression and early neuronal changes should be reversed. Prion therapeutics should therefore aim for the design of compounds that prevent disease onset and/or alter progression, or for the use of neuronal precursor cells. To date, therapeutic approaches include the use of compounds such as Congo red, polyanionic compounds, amphotericin B, porphyrins, and quinacrine, each of which has been shown to reduce accumulation of PrP<sup>Sc</sup> in prion-infected cell models [70]. However, such models are not stringent screens and these compounds have produced only modest effects *in vivo* [71]. Targeting

endogenous PrP<sup>C</sup> in mice with early prion infection reverses spongiform change and prevents clinical symptoms, neuronal loss, and cognitive and behavioural deficits [72]. Strategies to prevent the conversion process may also include the use of antibodies to bind and stabilise PrP<sup>C</sup> [73], but the use of large quantities of anti-PrP antibodies in the CNS is not feasible as yet as they have been reported to lead to marked neurodegeneration in mice [74]. The use of RNA interference (RNAi) has been demonstrated to inhibit PrP<sup>C</sup> expression in neuroblastoma cells [75]. In a recent study using a single administration of lentivirus-expressing shRNA targeting PrP into each hippocampus of mice with established prion disease resulted in significantly prolonged survival times compared to control mice [76].

Some research suggests prions aggregate by forming beta barrel structures, work done *in vitro* has shown that peptides made up of beta barrel-incompatible amino acids can help break up accumulations of prion. Yet a third idea concerns genetic therapy, whereby the gene for encoding protease-resistant protein is considered to be an error in several species and therefore something to be inhibited.

Research from the University of Toronto and Caprion Pharmaceuticals has discovered one possible avenue which might lead to quicker diagnosis, a vaccine or possibly even treatment for prion diseases. The abnormally folded proteins which cause the disease have been found to expose a side chain of amino acids which the properly folded protein does not expose. Antibodies specifically coded to this side chain amino acid sequence have been found to stimulate an immune response to the abnormal prions and leave the normal proteins intact [77].

The antiprion antibodies capable of crossing the blood-brain barrier and targeting cytosolic prion protein (an otherwise major obstacle in prion therapeutics) have been described [78]. In 2011 it was discovered that prions could be degraded by lichens [79, 80].

In 2010, A team from New York described detection of PrP<sup>Sc</sup> even when initially present at only one part in a hundred thousand million ( $10^{-11}$ ) in brain tissue. The method combines amplification with a novel technology called Surround Optical Fiber Immunoassay (SOFIA) and some specific antibodies against PrP<sup>Sc</sup>. After amplifying and then concentrating any PrP<sup>Sc</sup>, the samples are labelled with a fluorescent dye using an antibody for specificity and then finally loaded into a microcapillary tube. This tube is placed in a specially constructed apparatus so that it is totally surrounded by optical fibres to capture all light emitted once the dye is excited using a laser. The technique allowed detection of PrP<sup>Sc</sup> after many fewer cycles of conversion than others have achieved, substantially reducing the possibility of artefacts, as well as speeding up the assay. The researchers also tested their method on blood samples from apparently healthy sheep that went on to develop scrapie. The animals' brains were analysed once any symptoms became apparent. The researchers could therefore compare results from brain tissue and blood taken once the animals exhibited symptoms of the diseases, with blood obtained earlier in the animals' lives, and from uninfected animals. The results showed very

clearly that PrP<sup>Sc</sup> could be detected in the blood of animals long before the symptoms appeared [81, 82].

## 8. Conclusion

TSEs are the fatal degenerative neurologic diseases which are not having specific treatment. There continues to be a very practical problem with diagnosis of prion diseases. They have an incubation period of months to decades during which there are no symptoms, even though the pathway of converting the normal brain PrP protein into the toxic, disease-related PrP<sup>Sc</sup> form has started. At present, there is virtually no way to detect PrP<sup>Sc</sup> reliably except by examining the brain using neuropathological and immunohistochemical methods after death. Accumulation of the abnormally folded PrP<sup>Sc</sup> form of the PrP protein is a characteristic of the disease, but it is present at very low levels in easily accessible body fluids like blood or urine. Researchers have tried to develop methods to measure PrP<sup>Sc</sup>, but there are still no fully accepted methods for use in materials such as blood.

## Abbreviations

- PrP: Prion protein  
 PrP<sup>Sc</sup>: Scrapie prion protein  
 PrP<sup>C</sup>: Cellular prion protein  
 PrP<sup>res</sup>: Protease resistant prion protein.

## References

- [1] M. S. Palmer, A. J. Dryden, J. T. Hughes, and J. Collinge, "Homozygous prion protein genotype predisposes to sporadic Creutzfeldt-Jakob disease," *Nature*, vol. 352, no. 6333, pp. 340–342, 1991.
- [2] A. Tahiri-Alaoui, A. C. Gill, P. Disterer, and W. James, "Methionine 129 variant of human prion protein oligomerizes more rapidly than the valine 129 variant. Implications for disease susceptibility to Creutzfeldt-Jakob disease," *Journal of Biological Chemistry*, vol. 279, no. 30, pp. 31390–31397, 2004.
- [3] R. C. Holman, A. S. Khan, E. D. Belay, and L. B. Schonberger, "Creutzfeldt-Jakob disease in the United States, 1979–1994: using national mortality data to assess the possible occurrence of variant cases," *Emerging Infectious Diseases*, vol. 2, no. 4, pp. 333–337, 1996.
- [4] P. Brown, F. Cathala, P. Castaigne, and D. C. Gajdusek, "Creutzfeldt-Jakob disease: clinical analysis of a consecutive series of 230 neuropathologically verified cases," *Annals of Neurology*, vol. 20, no. 5, pp. 597–602, 1986.
- [5] R. K. Obi and F. C. Nwanebu, "Prions and Prion diseases," *African Journal of Clinical and Experimental Microbiology*, vol. 9, no. 1, pp. 38–52, 2008.
- [6] J. Solassol, M. Pastore, C. Crozet, V. Perrier, and S. Lehmann, "A novel copper-hydrogen peroxide formulation for prion decontamination," *Journal of Infectious Diseases*, vol. 194, no. 6, pp. 865–869, 2006.
- [7] H. A. Kretzschmar, "Human prion diseases (spongiform encephalopathies)," *Archives of Virology*, vol. 7, pp. 261–293, 1993.



- [8] P. Brown, "EEG findings in Creutzfeldt-Jakob disease," *Journal of the American Medical Association*, vol. 269, no. 24, p. 3168, 1993.
- [9] G. Hsich, K. Kenney, C. J. Gibbs, K. H. Lee, and M. G. Harrington, "The 14-3-3 brain protein in cerebrospinal fluid as a marker for transmissible spongiform encephalopathies," *New England Journal of Medicine*, vol. 335, no. 13, pp. 924–930, 1996.
- [10] H. A. Kretschmar, J. W. Ironside, S. J. DeArmond, and J. Tateishi, "Diagnostic criteria for sporadic Creutzfeldt-Jakob disease," *Archives of Neurology*, vol. 53, no. 9, pp. 913–920, 1996.
- [11] S. J. DeArmond and S. B. Prusiner, "Etiology and pathogenesis of prion diseases," *American Journal of Pathology*, vol. 146, no. 4, pp. 785–811, 1995.
- [12] M. Caramelli, G. Ru, P. Acutis, and G. Forloni, "Prion diseases: current understanding of epidemiology and pathogenesis, and therapeutic advances," *CNS Drugs*, vol. 20, no. 1, pp. 15–28, 2006.
- [13] S. J. Collins, P. Sanchez-Juan, C. L. Masters et al., "Determinants of diagnostic investigation sensitivities across the clinical spectrum of sporadic Creutzfeldt-Jakob disease," *Brain*, vol. 129, no. 9, pp. 2278–2287, 2006.
- [14] H. Budka, "Neuropathology of prion diseases," *British Medical Bulletin*, vol. 66, pp. 121–130, 2003.
- [15] J. D. F. Wadsworth, S. Joiner, J. M. Linehan et al., "Phenotypic heterogeneity in inherited prion disease (P102L) is associated with differential propagation of protease-resistant wild-type and mutant prion protein," *Brain*, vol. 129, no. 6, pp. 1557–1569, 2006.
- [16] J. Collinge, "Human prion diseases and bovine spongiform encephalopathy (BSE)," *Human Molecular Genetics*, vol. 6, no. 10, pp. 1699–1705, 1997.
- [17] S. Mead, "Prion disease genetics," *European Journal of Human Genetics*, vol. 14, no. 3, pp. 273–281, 2006.
- [18] S. Mead, S. P. Mahal, J. Beck et al., "Sporadic—But not variant—Creutzfeldt-Jakob disease is associated with polymorphisms upstream of *PRNP* exon 1," *American Journal of Human Genetics*, vol. 69, no. 6, pp. 1225–1235, 2001.
- [19] C. Vollmert, O. Windl, W. Xiang et al., "Significant association of a M129V independent polymorphism in the 5' UTR of the *PRNP* gene with sporadic Creutzfeldt-Jakob disease in a large German case-control study," *Journal of medical genetics*, vol. 43, no. 10, article e 53, 2006.
- [20] H. Budka, A. Aguzzi, P. Brown et al., "Neuropathological diagnostic criteria for Creutzfeldt-Jakob disease (CJD) and other human spongiform encephalopathies (prion diseases)," *Brain Pathology*, vol. 5, no. 4, pp. 459–466, 1995.
- [21] I. Zerr, M. Bodemer, O. Gefeller et al., "Detection of 14-3-3 protein in the cerebrospinal fluid supports the diagnosis of Creutzfeldt-Jakob disease," *Annals of Neurology*, vol. 43, no. 1, pp. 32–40, 1998.
- [22] C. L. Masters, D. C. Gajdusek, and C. J. Gibbs, "Creutzfeldt-Jakob disease virus isolations from the Gerstmann-Sträussler syndrome. With an analysis of the various forms of amyloid plaque deposition in the virus-induced spongiform encephalopathies," *Brain*, vol. 104, no. 3, pp. 559–588, 1981.
- [23] P. Brown, M. Preece, J. P. Brandel et al., "Iatrogenic Creutzfeldt-Jakob disease at the millennium," *Neurology*, vol. 55, no. 8, pp. 1075–1081, 2000.
- [24] C. A. Heath, R. A. Barker, T. F. G. Esmonde et al., "Dura mater-associated Creutzfeldt-Jakob disease: experience from surveillance in the UK," *Journal of Neurology, Neurosurgery and Psychiatry*, vol. 77, no. 7, pp. 880–882, 2006.
- [25] J. D. F. Wadsworth and J. Collinge, "Update on human prion disease," *Biochimica et Biophysica Acta*, vol. 1772, no. 6, pp. 598–609, 2007.
- [26] P. Duffy, J. Wolf, G. Collins, A. G. DeVoe, B. Streeten, and D. Cowen, "Letter: possible person-to-person transmission of Creutzfeldt-Jakob disease," *New England Journal of Medicine*, vol. 290, no. 12, pp. 692–693, 1974.
- [27] C. Masters, J. O. Harris, and D. C. Gajdusek, "Creutzfeldt-Jakob disease: patterns of worldwide occurrence and the significance of familial and sporadic clustering," *Annals of Neurology*, vol. 5, no. 2, pp. 177–188, 1979.
- [28] P. Brown, D. C. Gajdusek, C. J. Gibbs, and D. M. Asher, "Potential epidemic of Creutzfeldt-Jakob disease from human growth hormone therapy," *New England Journal of Medicine*, vol. 313, no. 12, pp. 728–731, 1985.
- [29] M. N. Ricketts, N. R. Cashman, E. E. Stratton, and S. ElSaadany, "Is Creutzfeldt-Jakob disease transmitted in blood?" *Emerging Infectious Diseases*, vol. 3, no. 2, pp. 155–163, 1997.
- [30] A. Créange, F. Gray, P. Cesaro et al., "Creutzfeldt-Jakob disease after liver transplantation," *Annals of Neurology*, vol. 38, no. 2, pp. 269–272, 1995.
- [31] E. E. Manuelidis, J. H. Kim, J. R. Mericangas, and L. Manuelidis, "Transmission to animals of Creutzfeldt-Jakob disease from human blood," *Lancet*, vol. 2, no. 8460, pp. 896–897, 1985.
- [32] H. J. Tschampa, P. Mürtz, S. Flacke, S. Paus, H. H. Schild, and H. Urbach, "Thalamic involvement in sporadic Creutzfeldt-Jakob disease: a diffusion-weighted MR imaging study," *American Journal of Neuroradiology*, vol. 24, no. 5, pp. 908–915, 2003.
- [33] P. Sanchez-Juan, A. Green, A. Ladogana et al., "CSF tests in the differential diagnosis of Creutzfeldt-Jakob disease," *Neurology*, vol. 67, no. 4, pp. 637–643, 2006.
- [34] M. H. Tattum, S. Jones, S. Pal, A. Khalili-Shirazi, J. Collinge, and G. S. Jackson, "A highly sensitive immunoassay for the detection of prion-infected material in whole human blood without the use of proteinase K," *Transfusion*, vol. 50, no. 12, pp. 2619–2627, 2010.
- [35] E. D. Belay and L. B. Schonberger, "Variant Creutzfeldt-Jakob disease and bovine spongiform encephalopathy," *Clinics in Laboratory Medicine*, vol. 22, no. 4, pp. 849–862, 2002.
- [36] A. Pfeifer, S. Eigenbrod, S. Al-Khadra et al., "Lentivector-mediated RNAi efficiently suppresses prion protein and prolongs survival of scrapie-infected mice," *Journal of Clinical Investigation*, vol. 116, no. 12, pp. 3204–3210, 2006.
- [37] E. P. Richardson and C. L. Masters, "The nosology of Creutzfeldt-Jakob disease and conditions related to the accumulation of PrPC<sup>JD</sup> in the nervous system," *Brain Pathology*, vol. 5, no. 1, pp. 33–41, 1995.
- [38] G. De Michele, M. Pocchiari, R. Petraroli et al., "Variable phenotype in a P102L Gerstmann-Sträussler-Scheinker Italian family," *Canadian Journal of Neurological Sciences*, vol. 30, no. 3, pp. 233–236, 2003.
- [39] D. C. Gajdusek, "Infectious amyloides: subacute spongiform encephalopathies as transmissible cerebral amyloidoses," in *Fields Virology*, B. N. Fields, D. M. Knipe, and P. M. Howley, Eds., pp. 2851–2900, 3rd edition, 1996.
- [40] H. Arata, H. Takashima, R. Hirano et al., "Early clinical signs and imaging findings in Gerstmann-Sträussler-Scheinker syndrome (Pro102Leu)," *Neurology*, vol. 66, no. 11, pp. 1672–1678, 2006.
- [41] B. Ghetti, P. Piccardo, B. Frangione et al., "Prion protein amyloidosis," *Brain Pathology*, vol. 6, no. 2, pp. 127–145, 1996.

- [42] H. A. Kretzschmar, G. Honold, F. Seitelberger et al., "Prion protein mutation in family first reported by Gerstmann, Straussler, and Scheinker," *Lancet*, vol. 337, no. 8750, p. 1160, 1991.
- [43] S. Collins, C. A. McLean, and C. L. Masters, "Gerstmann-Sträussler-Scheinker syndrome, fatal familial insomnia, and kuru: a review of these less common human transmissible spongiform encephalopathies," *Journal of Clinical Neuroscience*, vol. 8, no. 5, pp. 387–397, 2001.
- [44] E. Lugaresi, R. Medori, and P. Montagna, "Fatal familial insomnia and dysautonomia with selective degeneration of thalamic nuclei," *New England Journal of Medicine*, vol. 315, no. 16, pp. 997–1003, 1986.
- [45] R. Medori, H. J. Tritschler, A. LeBlanc et al., "Fatal familial insomnia, a prion disease with a mutation at codon 178 of the prion protein gene," *New England Journal of Medicine*, vol. 326, no. 7, pp. 444–449, 1992.
- [46] I. Zerr, A. Giese, O. Windl et al., "Phenotypic variability in fatal familial insomnia (D178N-129M) genotype," *Neurology*, vol. 51, no. 5, pp. 1398–1405, 1998.
- [47] P. Parchi, S. Capellari, S. Chin et al., "A subtype of sporadic prion disease mimicking fatal familial insomnia," *Neurology*, vol. 52, no. 9, pp. 1757–1763, 1999.
- [48] J. Chapman, A. Arlazoroff, L. G. Goldfarb et al., "Fatal insomnia in a case of familial Creutzfeldt-Jakob disease with the codon 200Lys mutation," *Neurology*, vol. 46, no. 3, pp. 758–761, 1996.
- [49] R. B. Petersen, M. Tabaton, L. Berg et al., "Analysis of the prion protein gene in thalamic dementia," *Neurology*, vol. 42, no. 10, pp. 1859–1863, 1992.
- [50] L. G. Goldfarb, M. Haltia, P. Brown et al., "New mutation in scrapie amyloid precursor gene (at codon 178) in finnish Creutzfeldt-Jakob kindred," *Lancet*, vol. 337, no. 8738, p. 425, 1991.
- [51] L. G. Goldfarb, R. B. Petersen, M. Tabaton et al., "Fatal familial insomnia and familial Creutzfeldt-Jakob disease: disease phenotype determined by a DNA polymorphism," *Science*, vol. 258, no. 5083, pp. 806–808, 1992.
- [52] R. B. Petersen, P. Parchi, S. L. Richardson, C. B. Urig, and P. Gambetti, "Effect of the D178N mutation and the codon 129 polymorphism on the metabolism of the prion protein," *Journal of Biological Chemistry*, vol. 271, no. 21, pp. 12661–12668, 1996.
- [53] L. Monari, S. G. Chen, P. Brown et al., "Fatal familial insomnia and familial Creutzfeldt-Jakob disease: different prion proteins determined by a DNA polymorphism," *Proceedings of the National Academy of Sciences of the United States of America*, vol. 91, no. 7, pp. 2839–2842, 1994.
- [54] P. Gambetti, P. Parchi, R. B. Petersen, S. G. Chen, and E. Lugaresi, "Fatal familial insomnia and familial Creutzfeldt-Jakob disease: clinical, pathological and molecular features," *Brain Pathology*, vol. 5, no. 1, pp. 43–51, 1995.
- [55] Y. Taniwaki, H. Hara, K. Doh-Ura et al., "Familial Creutzfeldt-Jakob disease with D178N-129M mutation of PRNP presenting as cerebellar ataxia without insomnia," *Journal of Neurology Neurosurgery and Psychiatry*, vol. 68, no. 3, p. 388, 2000.
- [56] G. Almer, J. A. Hainfellner, T. Brücke et al., "Fatal familial insomnia: a new Austrian family," *Brain*, vol. 122, no. 1, pp. 5–16, 1999.
- [57] E. Lugaresi, I. Tobler, P. Gambetti, and P. Montagna, "The pathophysiology of fatal familial insomnia," *Brain Pathology*, vol. 8, no. 3, pp. 521–526, 1998.
- [58] P. Silburn, L. Cervenáková, P. Varghese, A. Tannenber, P. Brown, and R. Boyle, "Fatal familial insomnia: a seventh family," *Neurology*, vol. 47, no. 5, pp. 1326–1328, 1996.
- [59] C. A. McLean, E. Storey, R. J. M. Gardner, A. E. G. Tannenber, L. Cervenáková, and P. Brown, "The D178N (cis-129M) 'fatal familial insomnia' mutation associated with diverse clinicopathologic phenotypes in an Australian kindred," *Neurology*, vol. 49, no. 2, pp. 552–558, 1997.
- [60] C. Taberner, J. Figols, N. Cuadrado et al., "Fatal familial insomnia: clinical, neuropathological, and genetic description of a Spanish family," *Journal of Neurology Neurosurgery and Psychiatry*, vol. 68, no. 6, pp. 774–777, 2000.
- [61] V. Manetto, R. Medori, P. Cortelli et al., "Fatal familial insomnia: clinical and pathologic study of five new cases," *Neurology*, vol. 42, no. 2, pp. 312–319, 1992.
- [62] J. Schenkein and P. Montagna, "Self-management of fatal familial insomnia. Part 2: case report," *Medscape General Medicine*, vol. 8, no. 3, article 66, 2006.
- [63] W. S. Jackson, A. W. Borkowski, H. Faas et al., "Spontaneous generation of prion infectivity in fatal familial insomnia Knockin Mice," *Neuron*, vol. 63, no. 4, pp. 438–450, 2009.
- [64] S. Mead, M. P. H. Stumpf, J. Whitfield et al., "Balancing selection at the prion protein gene consistent with prehistoric Kurulike epidemics," *Science*, vol. 300, no. 5619, pp. 640–643, 2003.
- [65] M. Alpers, "Epidemiology and clinical aspects of Kuru," in *Prions: Novel Infectious Pathogens Causing Scrapie and Creutzfeldt-Jakob Disease*, S. B. Prusiner and M. P. McKinley, Eds., pp. 451–465, Academic Press, San Diego, Calif, USA, 1987.
- [66] S. Lindenbaum, *Kuru Sorcery: Disease and Danger in the New Guinea Highlands*, Mayfield, Palo Alto, Calif, USA, 1979.
- [67] J. Collinge, J. Whitfield, E. McKintosh et al., "Kuru in the 21st century—an acquired human prion disease with very long incubation periods," *Lancet*, vol. 367, no. 9528, pp. 2068–2074, 2006.
- [68] H. S. Lee, P. Brown, L. Cervenáková et al., "Increased susceptibility to kuru of carriers of the PRNP 129 methionine/methionine genotype," *Journal of Infectious Diseases*, vol. 183, no. 2, pp. 192–196, 2001.
- [69] G. Mallucci and J. Collinge, "Rational targeting for prion therapeutics," *Nature Reviews Neuroscience*, vol. 6, no. 1, pp. 23–34, 2005.
- [70] C. R. Trevitt and J. Collinge, "A systematic review of prion therapeutics in experimental models," *Brain*, vol. 129, no. 9, pp. 2241–2265, 2006.
- [71] A. Aguzzi, M. Glatzel, F. Montrasio, M. Prinz, and F. L. Heppner, "Interventional strategies against prion diseases," *Nature Reviews Neuroscience*, vol. 2, no. 10, pp. 745–749, 2001.
- [72] G. R. Mallucci, M. D. White, M. Farmer et al., "Targeting cellular prion protein reverses early cognitive deficits and neurophysiological dysfunction in prion-infected mice," *Neuron*, vol. 53, no. 3, pp. 325–335, 2007.
- [73] A. R. White, P. Enever, M. Tayebi et al., "Monoclonal antibodies inhibit prion replication and delay the development of prion disease," *Nature*, vol. 422, no. 6927, pp. 80–83, 2003.
- [74] L. Solforosi, J. R. Criado, D. B. McGavern et al., "Cross-linking cellular prion protein triggers neuronal apoptosis in vivo," *Science*, vol. 303, no. 5663, pp. 1514–1516, 2004.
- [75] G. Tilly, J. Chapuis, D. Vilette, H. Laude, and J. L. Vilotte, "Efficient and specific down-regulation of prion protein expression by RNAi," *Biochemical and Biophysical Research Communications*, vol. 305, no. 3, pp. 548–551, 2003.
- [76] M. D. White, M. Farmer, I. Mirabile, S. Brandner, J. Collinge, and G. R. Mallucci, "Single treatment with RNAi against prion protein rescues early neuronal dysfunction and prolongs

- survival in mice with prion disease,” *Proceedings of the National Academy of Sciences of the United States of America*, vol. 105, no. 29, pp. 10238–10243, 2008.
- [77] E. Paramithiotis, M. Pinard, T. Lawton et al., “A prion protein epitope selective for the pathologically misfolded conformation,” *Nature Medicine*, vol. 9, no. 7, pp. 893–899, 2003.
- [78] D. R. Jones, W. A. Taylor, C. Bate, M. David, and M. Tayebi, “A camelid anti-PrP antibody abrogates PrP replication in prion-permissive neuroblastoma cell lines,” *PLoS One*, vol. 5, no. 3, article e9804, 2010.
- [79] C. J. Johnson, J. P. Bennett, S. M. Biro et al., “Degradation of the disease-associated prion protein by a serine protease from lichens,” *PLoS One*, vol. 6, no. 5, Article ID e19836, 2011.
- [80] P. Yam, “Natural born prion killers: lichens degrade ”mad cow” related brain pathogen,” *Scientific American*, 2011, <http://www.scientificamerican.com/blog/post.cfm?id=natural-born-prion-killers-lichens-2011-05-19>.
- [81] R. Rubenstein, B. Chang, P. Gray et al., “A novel method for preclinical detection of PrP<sup>Sc</sup> in blood,” *Journal of General Virology*, vol. 91, no. 7, pp. 1883–1892, 2010.
- [82] “SOFIA: an assay platform for ultrasensitive detection of PrP<sup>Sc</sup> in brain and blood,” Suny Downstate Medical Center, 2011, <http://www.bionosis.com/news/Bionosis%20PrioNet%20Poster.pdf>.





**Hindawi**  
Submit your manuscripts at  
<http://www.hindawi.com>

