

Capillary leak syndrome: etiologies, pathophysiology, and management



Eric Siddall¹, Minesh Khatri² and Jai Radhakrishnan¹

¹Columbia University Medical Center, New York, New York, USA; and ²Winthrop University Hospital, Mineola, New York, USA

In various human diseases, an increase in capillary permeability to proteins leads to the loss of protein-rich fluid from the intravascular to the interstitial space. Although sepsis is the disease most commonly associated with this phenomenon, many other diseases can lead to a “sepsis-like” syndrome with manifestations of diffuse pitting edema, exudative serous cavity effusions, noncardiogenic pulmonary edema, hypotension, and, in some cases, hypovolemic shock with multiple-organ failure. The term *capillary leak syndrome* has been used to describe this constellation of disease manifestations associated with an increased capillary permeability to proteins. Diseases other than sepsis that can result in capillary leak syndrome include the idiopathic systemic capillary leak syndrome or Clarkson’s disease, engraftment syndrome, differentiation syndrome, the ovarian hyperstimulation syndrome, hemophagocytic lymphohistiocytosis, viral hemorrhagic fevers, autoimmune diseases, snakebite envenomation, and ricin poisoning. Drugs including some interleukins, some monoclonal antibodies, and gemcitabine can also cause capillary leak syndrome. Acute kidney injury is commonly seen in all of these diseases. In addition to hypotension, cytokines are likely to be important in the pathophysiology of acute kidney injury in capillary leak syndrome. Fluid management is a critical part of the treatment of capillary leak syndrome; hypovolemia and hypotension can cause organ injury, whereas capillary leakage of administered fluid can worsen organ edema leading to progressive organ injury. The purpose of this article is to discuss the diseases other than sepsis that produce capillary leak and review their collective pathophysiology and treatment.

Kidney International (2017) **92**, 37–46; <http://dx.doi.org/10.1016/j.kint.2016.11.029>

KEYWORDS: acute kidney injury; capillary leak syndrome; capillary permeability; cytokines

Copyright © 2017, International Society of Nephrology. Published by Elsevier Inc. All rights reserved.

Correspondence: Jai Radhakrishnan, Columbia University Medical Center, 622 West 128th Street, New York, New York 10032, USA. E-mail: jr55@cumc.columbia.edu

Received 1 August 2016; revised 25 October 2016; accepted 15 November 2016; published online 17 March 2017

In various human diseases, an increase in capillary permeability to proteins leads to the loss of protein-rich fluid from the intravascular to the interstitial space. Although sepsis is the disease most commonly associated with this phenomenon, many other diseases can lead to a “sepsis-like” syndrome with manifestations of diffuse pitting edema, exudative serous cavity effusions, noncardiogenic pulmonary edema, hypotension, and, in some cases, hypovolemic shock with multiple-organ failure. The term *capillary leak syndrome* has been used to describe this constellation of disease manifestations associated with an increased capillary permeability to proteins. Diseases other than sepsis that can result in capillary leak syndrome include the idiopathic systemic capillary leak syndrome (SCLS) or Clarkson’s disease, engraftment syndrome, differentiation syndrome, ovarian hyperstimulation syndrome (OHSS), hemophagocytic lymphohistiocytosis (HLH), viral hemorrhagic fevers (VHFs), autoimmune diseases, snakebite envenomation, and ricin poisoning. Drugs, including some interleukins (ILs), certain monoclonal antibodies, and gemcitabine can also cause capillary leak syndrome. Acute kidney injury (AKI) is commonly seen in all of these diseases. In addition to hypotension, cytokines are likely to be important in the pathophysiology of AKI in capillary leak syndrome. Fluid management is a critical part of the treatment of capillary leak syndrome; hypovolemia and hypotension can cause organ injury, whereas capillary leakage of administered fluid can worsen organ edema, leading to progressive organ injury. The purpose of this article is to discuss the diseases other than sepsis that produce capillary leak and review their collective pathophysiology and treatment.

Epidemiology

The true incidence of capillary leak syndrome is unknown. It is likely that many cases of capillary leak are unrecognized and labeled as culture-negative sepsis or are attributed to an alternate pathophysiology such as hypoalbuminemia. Many of the diseases leading to capillary leak syndrome are uncommon, and in only a variable proportion of those with a predisposing condition will a clinically significant capillary leak develop. Over a 26-year period at the Mayo Clinic, only 25 cases of SCLS (or Clarkson’s disease) were documented.¹ Drug-induced capillary leak syndrome has a variable incidence depending on the specific drug studied. In a study of interleukin (IL)-2 administration to cancer patients, severe fluid retention developed in 16 of 25 patients.² Conversely, there are only a handful of case reports of

gemcitabine-induced capillary leak. In the case of rituximab treatment for chronic lymphocytic leukemia, the risk of severe capillary leak is universal when the lymphocyte count is $>50.0 \times 10^9/l$.³ Capillary leak due to engraftment syndrome following hematopoietic stem cell transplantation has an incidence of 7% to 55%, depending on the definition of engraftment syndrome used.⁴ Capillary leak due to differentiation syndrome following the treatment of acute promyelocytic leukemia with retinoic acid or arsenic trioxide occurs in ~25% of cases.⁵ In the example of OHSS, severe capillary leak is seen in only 2% of cases.⁶ The incidence of adult HLH was estimated to be 1 in 800,000 in Japan.⁷ Because the signs and symptoms of HLH overlap with those of many other diseases, it is likely that HLH is underdiagnosed. The proportion of individuals with HLH in whom capillary leak develops is unknown. Viral hemorrhagic fever is relatively uncommon, though most of these patients demonstrate capillary leak. In summary, the incidence of capillary leak syndrome varies from common to very rare, depending on the disease or drug in question. Patients with severe capillary leak syndrome are likely to cluster in the intensive care unit, and thus, practitioners who frequently round in the intensive care unit will encounter these patients.

Idiopathic SCLS (i.e., Clarkson's disease)

SCLS is a rare disorder characterized by episodic increases in vascular permeability resulting in acute losses of protein-rich fluid from the intravascular to the interstitial space.^{1,8,9} A typical presentation begins with a prodrome of fatigue, dizziness, and flulike symptoms followed by the rapid-onset of shock, systemic pitting edema, hemoconcentration, and hypoalbuminemia. Other common disease manifestations include AKI, pleural and pericardial effusions, rhabdomyolysis, and sometimes compartment syndrome of the extremities.¹ After a variable number of days, the vascular permeability spontaneously improves, and the blood pressure stabilizes. During this recovery phase, life-threatening pulmonary edema can develop.^{1,10–12} The frequency of episodes can vary widely between patients, with intervals ranging from days to years.¹³ The majority of patients have a detectable monoclonal protein in the serum, although the importance of the monoclonal protein in the disease pathogenesis is unclear.^{1,14,15} SCLS is a diagnosis of exclusion and is often confused with sepsis, angioedema, or anaphylactic shock.¹⁶ The elevation of multiple cytokines has been discovered in the acute serum of patients with SCLS, although only CXCL10 (C-X-C motif chemokine ligand 10) was shown to be elevated in both the quiescent and acute sera compared with controls.¹⁶ In another study, angiopoietin-2 and vascular endothelial growth factor were increased in acute SCLS sera compared with control sera.¹⁷ The finding that acute serum from SCLS patients induces hyperpermeability in human microvascular endothelial cells suggests that a soluble factor is important in the capillary leak pathophysiology.¹⁷ The appropriate disease-specific treatment of SCLS is currently unknown. Successful abortive therapy with i.v. Ig has been

described in 6 patients,^{18–21} whereas theophylline treatment to maintain high trough levels was successful in aborting attacks in 2 patients.²² Successful abortive therapy with the tumor necrosis factor- α (TNF- α) antagonist infliximab was described in a single case report.²² Prophylactic treatment with i.v. Ig prevented further attacks in 15 of 18 patients in 1 series²³ and successfully prevented recurrent attacks in multiple case series.^{18–21,24–29} Combined treatment with terbutaline and aminophylline or theophylline decreased the frequency and severity of attacks in 2 small series,^{11,22} although another series questioned the benefits of this combination therapy.¹⁴

Drug-induced capillary leak syndrome

Several drugs have been shown to cause capillary leak syndrome. The cytokine IL-2 administered for the treatment of malignancy has been shown to cause edema, dyspnea, fever, chills, nausea, vomiting, and diarrhea.² In an animal model, IL-2 caused an increase in the vascular permeability to albumin.³⁰ The cytokines IL-11 and IL-12 have also been associated with capillary leak syndrome.^{31,32} The use of gemcitabine for malignant diseases has resulted in systemic edema, hypotension, noncardiogenic pulmonary edema, and AKI.^{33–36} Studies of gemcitabine in lung cancer patients demonstrated significant increases in IL-2 and TNF- α in response to therapy.³⁷

Monoclonal antibodies can acutely activate large numbers of immune cells leading to abrupt increases in several cytokines.³⁸ This form of capillary leak syndrome, or cytokine release syndrome, is characterized by the onset of symptoms minutes to hours after the monoclonal antibody has been administered. OKT3 is a monoclonal antibody that inhibits CD3 on T cells. OKT3 administration causes fever, chills, dyspnea, wheezing, hypotension, tachycardia, nausea, and vomiting.³⁹ The first dose reaction to OKT3 is associated with increases in TNF- α , IL-2, and interferon- γ .⁴⁰ More severe reactions have been correlated with greater increases in serum TNF- α .³⁹ The treatment of hematologic malignancies with the monoclonal antibodies rituximab and alemtuzumab has resulted in the cytokine release syndrome.³⁸ Rituximab has been shown to increase TNF- α and IL-6 associated with capillary leak syndrome in B-cell leukemia patients,³ whereas alemtuzumab has been shown to increase TNF- α , interferon- γ , and IL-6.⁴¹ Perhaps the best example of acute drug-induced capillary leak with multiple-organ injury comes from the study of the anti-CD-28 monoclonal antibody TGN1412.⁴² Within hours of the administration of TGN1412 to 6 healthy volunteers, hypotension, bilateral pulmonary infiltrates, disseminated intravascular coagulation, and acute kidney injury with metabolic acidosis requiring continuous renal replacement therapy developed in all patients. There were large increases of multiple cytokines in all patients. In the 2 most critically ill patients, IL-6 and IL-4 were increased out of proportion to other patients. Steroids have been shown to be effective in ameliorating the signs and symptoms of drug-induced capillary leak syndrome.^{30,33–35,38,42}

Engraftment syndrome

Engraftment syndrome occurs after hematopoietic stem cell transplantation, usually within 4 days of granulocyte recovery, and is mediated by the release of inflammatory cytokines such as IL-1, TNF- α , and interferon- γ .⁴ Clinical manifestations include fever, hypotension, edema, ascites, pleural effusions, noncardiogenic pulmonary edema, and variable renal dysfunction.⁴ The incidence of engraftment syndrome varies with the type of transplant (e.g., autologous, allogeneic, syngeneic) and has widely discrepant estimations and outcome data due to differing definitions and overlap with other similar syndromes. AKI is common, with an incidence of 26% in 1 study of autologous stem cell transplantation patients.⁴³ Capillary leak due to engraftment syndrome responds to treatment with steroids.⁴⁴

Differentiation (retinoic acid) syndrome

Differentiation syndrome is a complication occurring in ~25% of patients with acute promyelocytic leukemia who undergo induction treatment with either all-trans retinoic acid or arsenic trioxide. This complication usually occurs 10 to 12 days after initiating treatment and is characterized by pulmonary infiltrates, fever, pulmonary edema, pleural effusions, systemic edema, hypotension, and AKI.⁵ AKI can be seen in 28% of cases.⁵ The pathophysiology of differentiation syndrome involves chemokine release from differentiated acute promyelocytic leukemia cells and the upregulation of integrins and adhesion molecules on differentiated acute promyelocytic leukemia cells as well as target tissues. These events facilitate the infiltration of leukemic cells into target organs, particularly the lungs.⁵ Steroids are effective in the treatment of capillary leak caused by the differentiation syndrome.^{5,45}

Ovarian hyperstimulation syndrome

OHSS is a rare complication that occurs as a result of the induction of ovulation with ovary-stimulating agents.⁴⁶ OHSS is characterized by abdominal pain and ovarian enlargement in mild cases and in capillary leak with subsequent edema formation in the abdominal, pleural, and pericardial spaces in severe cases.⁴⁷ Although mild forms of ovarian hyperstimulation syndrome are common, severe ovarian hyperstimulation syndrome occurs in only 2% of patients.⁶ In 1 study of 209 patients with severe and critical OHSS, oliguria developed in 29.7% and renal failure in 1.4%.⁴⁸ The pathophysiology is believed to stem from exogenous human chorionic gonadotropin administration, which causes the development of multiple ovarian follicles that release large amounts of vascular endothelial growth factor.⁴⁹ Vascular endothelial growth factor concentrations are significantly greater in the abdominal cavity compared with serum, resulting in capillary leak focused in the abdominal cavity.⁴⁹ The development of a large volume of ascites coupled with massive ovarian enlargement causes respiratory distress, increased abdominal pressure, and AKI. Two different time courses of OHSS have been described: early OHSS occurs at 3 to 9 days after human

chorionic gonadotropin administration, whereas late OHSS has an onset at 12 to 17 days after human chorionic gonadotropin and is due to early pregnancy-induced human chorionic gonadotropin production.⁵⁰ Risk factors for OHSS include young age, low body weight, previous OHSS, and the presence of polycystic ovarian syndrome.⁴⁷ The ovarian hyperstimulation syndrome is generally self-limited and requires only supportive care; paracentesis may be necessary in selected cases.⁵¹

Hemophagocytic lymphohistiocytosis

Hemophagocytic lymphohistiocytosis is a multisystem disorder caused by a hyperactive, unregulated immune response.⁵² The normal immune response to an infectious agent involves the termination of infected antigen-presenting cells; this both resolves the infection and facilitates the downregulation of the immune response. Termination of infected antigen-presenting cells occurs by cytotoxic T-lymphocytes and natural killer cells through the release of cytotoxic granules containing perforin and granzymes. Genetic forms of HLH are caused by defects in the cytotoxic granules such that antigen-presenting cells cannot be terminated and the immune response continues to increase.⁵² The importance of infections in the pathophysiology of HLH is underscored by findings in mouse models that show a viral trigger is necessary to initiate HLH.⁵² Acquired forms of HLH can occur secondary to infectious (particularly Epstein-Barr virus), autoimmune, or malignant causes. The exact mechanism of HLH in secondary causes is unknown, but immune hyperactivity is a consequence. In both primary and secondary forms of HLH, activation of large numbers of lymphocytes and macrophages results in hypercytokinemia, leading to the multisystem abnormalities in HLH.⁵² TNF- α , IFN- γ , and IL-18 are commonly increased in patients with HLH. The diagnostic criteria for HLH include identification of a known genetic mutation or fulfillment of 5 of 8 criteria: fever; splenomegaly; cytopenias of at least 2 of 3 lineages in the peripheral blood-hemoglobin <9 g/100 ml; platelets <100 X 10³/ml; neutrophils <1 X 10³/ml; hypertriglyceridemia (fasting \geq 265 mg/100 ml); hypofibrinogenemia (\leq 150 mg/100 ml); hemophagocytosis in the bone marrow, spleen, or lymph nodes; low or absent natural killer cell activity; ferritin \geq 500 ng/ml or soluble CD25 >2400 U/ml.⁵³ A study of intensive care unit patients with HLH compared with those without HLH suggested that a ferritin level of 3951 ng/ml was the optimal maximum level for diagnosis based on a receiver-operator curve.⁵⁴ Pulmonary involvement and renal involvement are also common manifestations of HLH.⁵⁵ Intensive care unit admission is required in as many as 50% of patients⁵⁵; indications for intensive care unit admission include acute respiratory failure, shock, altered mental status, and AKI.⁵⁶ AKI has been found in 16% to 62% of patients with HLH.^{55,57} The most common causes of AKI in HLH are prerenal and acute tubular necrosis (ATN), although cases due to tumor lysis syndrome, collapsing focal segmental glomerulosclerosis, minimal change disease, and thrombotic microangiopathy have been described.^{57,58} The initial treatment of HLH depends

on the suspected cause and clinical stability of the patient.⁵³ Those with HLH secondary to a rheumatologic condition or infection who are clinically stable can be treated with disease-specific therapy with or without steroids.⁵³ In cases related to infection, antibiotics and i.v. Ig can be beneficial. Rituximab has been advocated for HLH secondary to Epstein-Barr virus infection. The current standard of care for HLH in patients who are unstable, have a malignant cause of HLH, or are deteriorating despite disease-specific therapy and steroids is a combination of dexamethasone and etoposide; intrathecal methotrexate can be added for those with central nervous system involvement.^{53,59} Once HLH secondary to a malignancy is controlled with steroids and etoposide, disease-specific chemotherapy can be initiated.⁵³

Hemorrhagic fever

VHF is another cause of capillary leak and is associated with shock, thrombocytopenia, coagulopathy, and hemorrhage.^{60,61} Studies of patients with epidemic hemorrhagic fever, hantavirus, and dengue hemorrhagic fever demonstrate similar clinical courses. It should be noted that hantavirus can cause 2 distinct clinical syndromes depending on the strain of infecting virus (which has a geographic variation); hemorrhagic fever with renal syndrome and hantavirus pulmonary syndrome.⁶¹ Renal failure is a less common manifestation in hantavirus pulmonary syndrome infections. During the hypotensive phase of VHF, there is a significant decrease in blood pressure accompanied by hemoconcentration and a stable plasma protein concentration (reflective of capillary leakage of plasma).^{61–63} Direct evidence of capillary leak is derived from studies in patients with epidemic hemorrhagic fever who demonstrate an increase in the albumin disappearance rate from the plasma in the setting of an increasing hematocrit.⁶⁴ Although the hematocrit increases early in the course of VHF due to capillary leak, it often becomes subnormal after fluid resuscitation and the development of hemorrhage. The incidence of AKI varies among the hemorrhagic fevers, being relatively uncommon in dengue hemorrhagic fever but common in hantavirus hemorrhagic fever with renal syndrome.^{65–67} Proteinuria and hematuria can be seen in patients with VHF in both the presence⁶⁶ and absence of glomerular abnormalities^{62,65,68}; acute interstitial nephritis has been seen with the Puumala hantavirus.⁶⁹ Most patients with AKI will spontaneously recover with supportive care, although a minority may temporarily require renal replacement.^{61,65,70} Capillary leak is also believed to be important in the pathophysiology of Ebola and Marburg viruses, although fewer data are available in these patients.^{71,72} Treatment is supportive in VHF.

Miscellaneous

Snakebite envenomation commonly causes coagulopathy, hemorrhage, hypovolemic shock, and AKI.^{73,74} In these patients, AKI is due to a combination of shock and pigment-induced tubular injury (hemoglobinuria or myoglobinuria depending on the type of venom). In a series of

200 patients from South India with venomous snakebites, capillary leak syndrome developed in 2 of 200, although the definition of capillary leak was not provided.⁷⁴ Treatment of snakebite envenomation includes administration of the appropriate snake antivenom. Ricin is a highly potent toxin derived from castor beans that targets ribosomes and subsequently inhibits protein synthesis causing cell death.⁷⁵ Damage to endothelial cells leads to capillary leak, hemorrhage, and multiple organ failure.⁷⁵ Use of the ricin A chain conjugated to a monoclonal antibody as a chemotherapeutic agent causes hypotension, edema, effusions, and AKI.^{76,77} AKI is common regardless of the route of ricin administration and is most commonly ATN due to shock, although proteinuria and hematuria have been reported.⁷⁵ Capillary leak syndrome has also rarely been reported in autoimmune diseases including Kawasaki disease,⁷⁸ antiphospholipid antibody syndrome,⁷⁹ Sjögren syndrome, systemic sclerosis, and polymyositis.⁸⁰

Pathophysiology

All of the diseases causing capillary leak syndrome share the same underlying pathophysiologic abnormality—an increase in capillary permeability to proteins.^{8,9,18,30,64} As a result, there is a loss of protein-rich fluid from the intravascular to the interstitial space. In all cases, hypercytokinemia is believed to be the underlying cause of capillary leak. In a study of a patient with SCLS, Atkinson *et al.*⁹ estimated that substances in the plasma of at least 200 kDa, but not more than 900 kDa, were leaked into the interstitial space. (For comparison, albumin has a molecular weight of 66.5 kDa.) In their study, Atkinson *et al.*⁹ measured a 30% to 50% loss of albumin from the intravascular space during the first 12 hours of the capillary leak phase.

The ability of the endothelium to serve as a barrier between the intravascular and interstitial spaces depends on the integrity of binding between neighboring endothelial cells.^{81,82} Endothelial cells bind to neighboring cells through 2 types of cell junctions: adherens junctions (AJs) and tight junctions. In addition to the brain, AJs appear to be the most important component of endothelial cell-to-cell binding and thus permeability.⁸² Vascular endothelial cadherin is a major component of the AJ.⁸¹ Administration of blocking antibodies to vascular endothelial cadherin in mice increases vascular permeability in the heart and lungs.⁸³ Mild inflammatory stimuli cause vascular endothelial cadherin internalization, which weakens the AJ and increases permeability but maintains the integrity of the endothelial architecture.⁸⁴ Greater inflammatory stimuli cause endothelial cell separation, resulting in gaps between endothelial cells and in significant increases in permeability.⁸⁴ Sepsis and individual cytokines have been shown to increase vascular permeability via disruption of the AJ.^{81,84,85} Incubation of human microvascular endothelial cells with serum obtained from patients during an acute attack of SCLS caused reduced vascular endothelial cadherin localization at the AJ, decreased the integrity of the AJ, and increased microvascular permeability.¹⁷ Incubation of human

microvascular endothelial cells with quiescent serum did not affect the AJ. The authors hypothesize that during the capillary leak phase, a soluble factor in the plasma increases endothelial permeability leading to capillary leak. Although alterations in endothelial cell junctions have not been studied in other causes of capillary leak syndrome, the common clinical phenotype among the diseases suggests a similar molecular pathophysiology.

Hemodynamic manifestations

Loss of protein-rich fluid from the intravascular space leads to intravascular volume depletion, resulting in secondary activation of the renin, angiotensin, and aldosterone system; the sympathetic nervous system; and the release of vasopressin.^{6,9} The resulting sodium and water retention results in systemic edema and exudative serous cavity effusions.^{6,51,86} (Figure 1). When the capillary leak is abrupt in onset and severe, as in SCLS, viral hemorrhagic fever, OHSS, and ricin poisoning, significant hemoconcentration can occur.^{1,8,9,63,65,87–90} This hemoconcentration can serve as an indicator of capillary leak

severity. Diseases that are slower in onset or that have hematologic involvement do not demonstrate hemoconcentration. In the most severe cases, all causes of capillary leak syndrome can result in hypovolemic shock (SCLS,^{8,9,14} HLH,^{56,91,92} differentiation syndrome,⁵ OHSS,⁶ hemorrhagic fever,^{63,65} engraftment syndrome,⁴⁴ ricin,⁷⁵ drug-induced capillary leak [OKT3,³⁹ gemcitabine,³⁴ IL-2,⁹³ anti-CD28 Ab,⁴² rituximab³]).

Pulmonary manifestations

Pleural effusions, which are exudative in nature,⁸⁶ have been demonstrated in all causes of capillary leak syndrome. Non-cardiogenic pulmonary edema is also seen in severe cases of capillary leak syndrome. In the case of SCLS, as capillary permeability normalizes, fluid that had accumulated in the interstitial space is mobilized back into the intravascular space. In patients who receive large volumes of i.v. fluids during resuscitation, life-threatening pulmonary edema once the blood pressure stabilizes can develop.^{1,10–12} Non-cardiogenic pulmonary edema after i.v. fluid resuscitation is

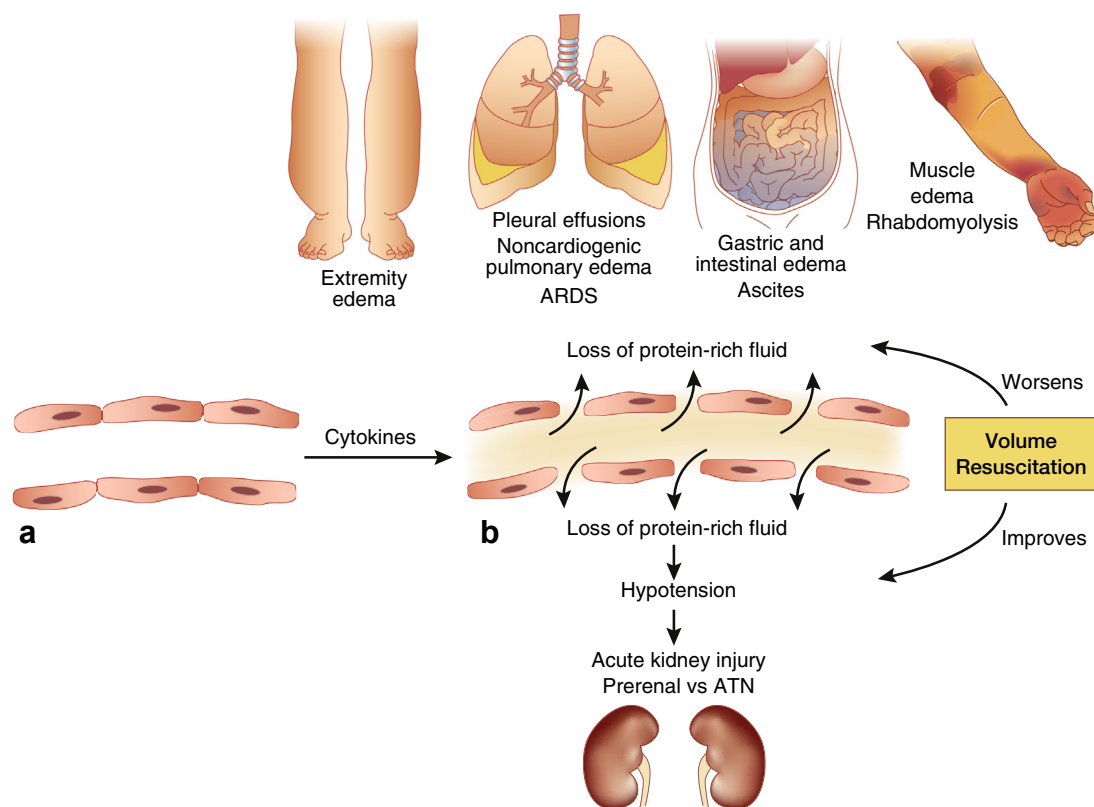


Figure 1 | Clinical manifestations of capillary leak syndrome. (a) In the resting state, capillary permeability is normal, and there is limited movement of fluid and proteins from the intravascular to the interstitial space. (b) In response to cytokines, vascular permeability increases. The increase in capillary permeability facilitates the movement of protein-rich fluid from the intravascular to the interstitial space. Subsequent intravascular volume depletion causes hypotension of varying severity. Hypotension causes decreased perfusion to the kidneys, resulting in prerenal acute kidney injury or acute tubular necrosis (ATN) in more severe cases. Cytokines themselves may also contribute to renal injury. Accumulation of protein-rich fluid in the interstitial space causes systemic pitting edema, effusions of the thoracic and abdominal cavities, noncardiogenic pulmonary edema, and/or acute respiratory distress syndrome (ARDS) in the lung, gastric, and intestinal edema, and muscle edema, which can rarely lead to rhabdomyolysis. Volume resuscitation can increase the intravascular volume and thus improve blood pressure and renal function. Volume resuscitation also expands the interstitial volume and thus potentially worsens systemic edema, increases effusions, and worsens pulmonary, gut, and muscle edema.

also associated with the hemorrhagic fevers.^{62,63} In other diseases, noncardiogenic pulmonary edema can occur early in the course of the disease or after large volumes of fluid have been administered. Additional pulmonary manifestations include pulmonary hemorrhage in HLH^{45,94} and differentiation syndrome,⁴⁵ as well as acute respiratory distress syndrome in SCLS, HLH, OHSS, engraftment syndrome, and drug-induced capillary leak syndrome.^{12,42,44,94,95} Although pleural effusions and noncardiogenic pulmonary edema can be seen in OHSS,^{88,96} the most common respiratory abnormalities observed are dyspnea and mild hypoxia due to the presence of large-volume ascites that restricts diaphragmatic descent.⁹⁶ This leads to an increase in the work of breathing, as well as low lung volumes.

Renal manifestations

AKI is a common manifestation of capillary leak syndrome. The most common causes of AKI are prerenal due to intravascular volume depletion followed by ATN.^{1,8,9,42,45,57,73} Animal models in other diseases suggest that cytokines contribute to renal tubular injury.^{97–100} As such, in addition to hypotension, a role for cytokines in the development of ATN in capillary leak syndrome seems likely. In some cases of SCLS, the development of rhabdomyolysis with resultant myoglobinuria contributes to ATN.¹ Myoglobinuria, intravascular hemolysis with hemoglobinuria, and, rarely, cortical necrosis are additional causes of AKI in patients with snake-bite envenomation.^{73,74} Glomerular lesions associated with nephrotic syndrome develop in a minority of patients with HLH,⁵⁷ whereas in patients with VHF and ricin poisoning, an active urine sediment early in the course of their disease can transiently develop, suggesting mild glomerular injury (superimposed on prerenal and acute tubular necrosis).^{61,62,65} In addition to intravascular volume depletion, abdominal compartment syndrome due to tense ascites may occur in OHSS and contribute to AKI.^{95,101}

Other systems

Because edema develops throughout the body, it is likely that most systems are affected by edema accumulation. However, large data sets on other organ systems in capillary leak syndrome are not available. Rhabdomyolysis and compartment syndrome due to muscle edema can develop in patients with SCLS.¹ Abdominal pain, nausea, and vomiting are common in patients with capillary leak. The documentation of intestinal edema in a case of SCLS¹¹ and the observation that abdominal pain can worsen with progressive fluid resuscitation in patients with hemorrhagic fever⁶² suggest that edema of the gastrointestinal tract is a mediator of abdominal pain in capillary leak syndrome.

Differential diagnosis

The manifestations of moderate to severe capillary leak syndrome are often indistinguishable from sepsis and septic shock.^{14,42,45,65,92,102} As such, empirical antimicrobial therapy is generally warranted in patients suspected of having

capillary leak syndrome. Anaphylactic shock is also a differential diagnosis of acute hemodynamic collapse and should be considered in the differential diagnosis of SCLS.¹⁶ Finally, hereditary angioedema, acquired angioedema (C1 inhibitor deficiency), as well as Gleich syndrome (angioedema with eosinophilia) can present with edema of the skin, upper airway, and gastrointestinal tract and be confused with capillary leak syndrome.¹³

Management

Fluid management is the most critical element in the treatment of capillary leak syndrome (Figure 2). The hemodynamic profile of patients with capillary leak can vary from stable blood pressure with intact perfusion and fluid overload to fulminant hypovolemic shock. In those with mild hypotension, blood pressure often responds to i.v. fluids in the form of crystalloids. In patients with severe shock, blood pressure may be only partially responsive or refractory to i.v. fluid.^{8,9,11,42,62} Given the small number of patients with capillary leak syndrome in the literature, there is a lack of sufficient evidence to guide the choice of fluid therapy. Case studies have tried albumin or plasma infusions in those in who fail to respond to crystalloids.^{8,62} Although albumin is theoretically an attractive choice for volume expansion in these patients, its efficacy is expected to be attenuated due to ongoing albumin loss from the vascular space. High molecular weight starches such as pentastarch (molecular weight, 264 kDa) and hetastarch (molecular weight, 450 kDa) are theoretically attractive resuscitative fluids in those with capillary leak given that their size may exceed that of the endothelial defect. A report of 2 patients with SCLS showed that 10% pentastarch was successful at increasing the central venous pressure and systemic blood pressure.¹⁰³ One of the 2 patients was hypotensive with a low central venous pressure despite receiving 9 L of normal saline solution. She subsequently received pentastarch, which normalized her hemodynamics. Another case report details a patient with a history of SCLS and lower extremity compartment syndrome due to massive fluid resuscitation during a previous admission. During a second episode, the administration of hydroxyethyl starch reduced the crystalloid requirement and prevented complications of fluid overload.²⁷ Notably, volume resuscitation with hydroxyethyl starch has been associated with increased mortality and AKI in critically ill patients compared with other resuscitative fluids.¹⁰⁴ Because a significant number of patients with capillary leak die during the shock phase, the potential benefit of high molecular weight starches probably outweighs the risk in those with refractory shock. Vasopressors can be administered to those who remain hypotensive despite the perception of adequate volume resuscitation, although they are expected to be less effective given that intravascular volume depletion underlies the shock in these patients.^{56,62,103} Patients with capillary leak syndrome are at high risk of noncardiogenic pulmonary edema during fluid resuscitation. In some patients, pulmonary edema develops after the blood pressure has stabilized due to the return

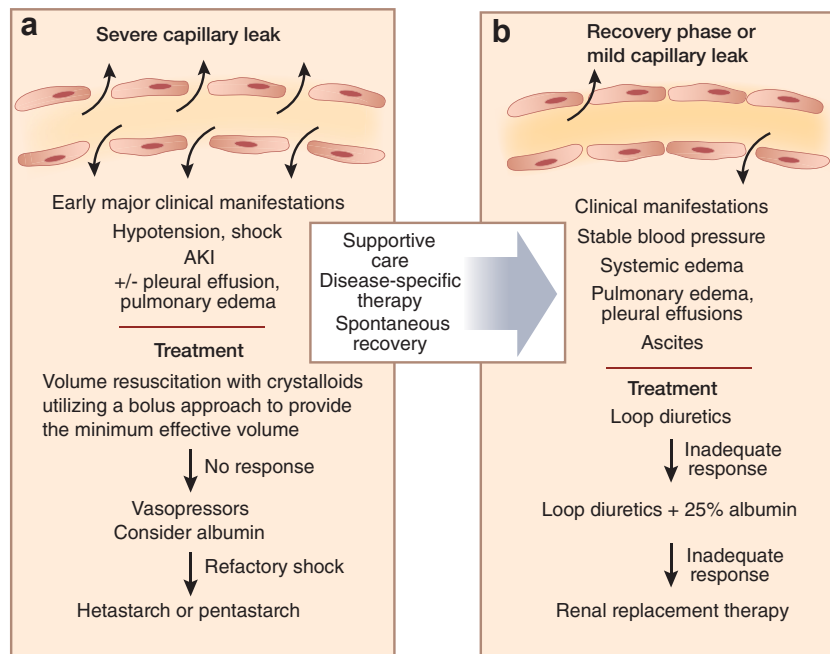


Figure 2 | Management of capillary leak syndrome. (a) In cases of severe capillary leak, there is marked disruption of endothelial cell-to-cell binding resulting in massive losses of protein-rich fluid into the interstitial space. Hypotension, shock, and acute kidney injury (AKI) often dominate the initial clinical picture. In these patients, the priority is to increase the blood pressure in order to optimize organ perfusion. The initial strategy is to administer boluses of crystalloids with a goal of providing the minimum effective volume that optimizes blood pressure. A fluid-restrictive strategy is advocated to limit interstitial fluid volume expansion. The next step in the management of persistent hypotension is the administration of vasopressors. A trial of 25% albumin i.v. is an additional option, although its efficacy is limited in those with a severe capillary leak. In those who remain with refractory shock in the setting of low filling pressures, high molecular weight starches such as hetastarch and pentastarch may be effective in expanding the intravascular volume. Supportive care with invasive and noninvasive ventilation as well as renal replacement may be necessary in severe cases. When available, disease-specific therapy should be initiated as soon as possible to facilitate recovery. (b) In cases of mild capillary leak or during the recovery phase from severe capillary leak, the endothelial injury is less, resulting in stable blood pressure. In this setting, fluid overload symptoms predominate (e.g., pulmonary edema, pleural effusions, acute respiratory distress syndrome, systemic edema, ascites). Volume removal with loop diuretics is the first-line therapy in these patients. In those with marginal blood pressure and fluid overload, the combination of loop diuretics and 25% albumin i.v. may facilitate volume removal. Patients with AKI refractory to diuretics will require renal replacement.

of interstitial fluid to the intravascular space. For these reasons, a fluid-restrictive strategy is advocated during volume resuscitation.^{1,8,9,11,12,62,63} This is best achieved by administering a fluid bolus, followed by reassessment of the intravascular volume and pulmonary status before further i.v. fluid administration. Once the blood pressure has stabilized for a period of time, diuretic therapy should be initiated to prevent the development of pulmonary edema.^{10,11,62}

In patients who present with a stable blood pressure and show signs of fluid overload, loop diuretics are the first-line therapy.^{34,35} In some patients with marginal blood pressure and fluid overload, but intact perfusion, the combination of albumin and diuretics has been successful for removing volume.⁶ Patients in whom AKI with oliguria develops are likely to require renal replacement therapy. In those with hemodynamic instability, continuous renal replacement is favored over intermittent hemodialysis. In addition, continuous renal replacement therapy may be preferable to intermittent hemodialysis in those with marked anasarca to allow more rapid control of fluid overload. In the case of patients with OHSS who present with hypovolemia and respiratory distress due to massive ascites, paracentesis with colloid replacement has improved hemodynamics and relieved respiratory distress.^{95,101}

In addition to fluid therapy, steroid therapy has demonstrated efficacy in capillary leak syndrome due to drugs, engraftment syndrome, differentiation syndrome, HLH, and autoimmune diseases. Because capillary leak syndrome is generally believed to be a cytokine-mediated disease, the benefit of steroids presumably relates to their ability to reduce the expression of multiple cytokines.¹⁰⁵ The reason that steroids are ineffective in some cases of capillary leak syndrome is unknown. It is possible that diseases causing capillary leak syndrome unresponsive to steroids are due to endothelium-damaging substances that are not affected by steroids.

In patients with SCLS, i.v. Ig is currently the most promising therapy for both acute treatment and long-term prevention. Although data are limited and no guidelines exist, the available data suggest that i.v. Ig should be initiated immediately in a patient suspected of having SCLS. Case studies have used a dose of 1 g/kg per day for 2 days.^{18,21} Mounting data suggest that i.v. Ig is the treatment of choice for the prevention of recurrent SCLS attacks and should be offered to all patients. Doses of 2 g/kg monthly of i.v. Ig are the most commonly used for prevention.²³ Beyond the use of i.v. Ig in patients with HLH who have active infections, there are no available data on i.v. Ig in other forms of capillary leak.

Summary

A diverse set of diseases can give rise to capillary leak syndrome. The common pathophysiologic abnormality in each disease is an increase in the vascular permeability to proteins due to hypercytokinemia. Evidence derived from SCLS suggests that disruption of the endothelial AJ may be the mechanism by which cytokines increase vascular permeability.¹⁷ This increase in vascular permeability results in the loss of protein-rich fluid from the intravascular to the interstitial space and thus are signs and symptoms due to intravascular volume depletion and interstitial volume expansion. Loss of fluid from the intravascular space results in hypovolemia and prerenal azotemia in mild cases, whereas hypovolemic shock and AKI occur in severe cases. Accumulation of fluid in the interstitial space results in systemic pitting edema and visceral effusions in mild cases, whereas noncardiogenic pulmonary edema, acute respiratory distress syndrome, rhabdomyolysis, and gut edema develop in severe cases. AKI appears to be a consequence of hypovolemia and hypotension in most cases, although cytokine-induced injury may also be important. In select cases, intra-abdominal hypertension, rhabdomyolysis, and glomerular disease may also contribute to AKI. Fluid management is the most important component of therapy in patients with capillary leak. Judicious use of resuscitative crystalloid fluids may stabilize blood pressure and ameliorate AKI in mild cases of capillary leak, although fluids can lead to progressive interstitial fluid accumulation with subsequent organ injury. In patients with shock refractory to crystalloids and vasopressors, high molecular weight starches may have a role in volume resuscitation despite the risk of AKI. Given the propensity for life-threatening pulmonary edema and acute respiratory distress syndrome, diuretics should be instituted once hemodynamic stability is achieved. When available, disease-specific therapy to reduce cytokine production and thus reverse the capillary leak is indicated. Steroids are effective in several causes of capillary leak syndrome. An effective abortive treatment in some patients with SCLS appears to be i.v. Ig and seems to be the most effective agent for preventing further attacks. It is important to consider capillary leak syndrome in any patient who presents with sepsis syndrome, in particular, when no clear infectious process can be identified. Increased awareness of this problem will lead to increased identification of cases and eventually better insight into the pathogenesis and treatment of capillary leak syndrome.

DISCLOSURE

All the authors declared no competing interests.

REFERENCES

- Kapoor P, Greipp PT, Schaefer EW, et al. Idiopathic systemic capillary leak syndrome (Clarkson's disease): the Mayo clinic experience. *Mayo Clin Proc.* 2010;85:905–912.
- Rosenberg SA, Lotze MT, Muul LM, et al. Observations on the systemic administration of autologous lymphokine-activated killer cells and recombinant interleukin-2 to patients with metastatic cancer. *N Engl J Med.* 1985;313:1485–1492.
- Winkler U, Jensen M, Manzke O, et al. Cytokine-release syndrome in patients with B-cell chronic lymphocytic leukemia and high lymphocyte counts after treatment with an anti-CD20 monoclonal antibody (rituximab, IDEC-C2B8). *Blood.* 1999;94:2217–2224.
- Spitzer TR. Engraftment syndrome: double-edged sword of hematopoietic cell transplants. *Bone Marrow Transplant.* 2015;50:469–475.
- Luesink M, Jansen JH. Advances in understanding the pulmonary infiltration in acute promyelocytic leukaemia. *Br J Haematol.* 2010;151:209–220.
- Fabregues F, Balasch J, Gines P, et al. Ascites and liver test abnormalities during severe ovarian hyperstimulation syndrome. *Am J Gastroenterol.* 1999;94:994–999.
- Ishii E, Ohga S, Imashuku S, et al. Nationwide survey of hemophagocytic lymphohistiocytosis in Japan. *Int J Hematol.* 2007;86:58–65.
- Clarkson B, Thompson D, Horwith M, Luckey EH. Cyclical edema and shock due to increased capillary permeability. *Am J Med.* 1960;29:193–216.
- Atkinson JP, Waldmann TA, Stein SF, et al. Systemic capillary leak syndrome and monoclonal IgG gammopathy; studies in a sixth patient and a review of the literature. *Medicine (Baltimore).* 1977;56:225–239.
- Chihara R, Nakamoto H, Arima H, et al. Systemic capillary leak syndrome. *Intern Med.* 2002;41:953–956.
- Tahirkheli NK, Greipp PR. Treatment of the systemic capillary leak syndrome with terbutaline and theophylline. A case series. *Ann Intern Med.* 1999;130:905–909.
- Bouhaja B, Somrani N, Thabet H, et al. Adult respiratory distress syndrome complicating a systemic capillary leak syndrome. *Intensive Care Med.* 1994;20:307–308.
- Druey KM, Greipp PR. Narrative review: the systemic capillary leak syndrome. *Ann Intern Med.* 2010;153:90–98.
- Amoura Z, Papo T, Ninet J, et al. Systemic capillary leak syndrome: report on 13 patients with special focus on course and treatment. *Am J Med.* 1997;103:514–519.
- Gousseff M, Arnaud L, Lambert M, et al. The systemic capillary leak syndrome: a case series of 28 patients from a European registry. *Ann Intern Med.* 2011;154:464–471.
- Xie Z, Chan E, Yin Y, et al. Inflammatory markers of the systemic capillary leak syndrome (Clarkson disease). *J Clin Cell Immunol.* 2014;5:1000213.
- Xie Z, Ghosh CC, Patel R, et al. Vascular endothelial hyperpermeability induces the clinical symptoms of Clarkson disease (the systemic capillary leak syndrome). *Blood.* 2012;119:4321–4332.
- Lambert M, Launay D, Hachulla E, et al. High-dose intravenous immunoglobulins dramatically reverse systemic capillary leak syndrome. *Crit Care Med.* 2008;36:2184–2187.
- Ledochowski S, Freichet M, Prieur C, et al. An uncommon cause of distributive shock: Lessons from two consecutive cases of idiopathic systemic capillary leak syndrome (Clarkson's disease). *Anaesth Crit Care Pain Med.* 2015;34:251–253.
- Almagro P, Marti JM, Garcia Pascual L, Rodriguez-Carballeira M. Successful treatment of systemic capillary leak syndrome with intravenous immunoglobulins. *Rev Clin Esp.* 2012;212:218–219.
- Marra AM, Gigante A, Rosato E. Intravenous immunoglobulin in systemic capillary leak syndrome: a case report and review of literature. *Expert Rev Clin Immunol.* 2014;10:349–352.
- Dowden AM, Rullo OJ, Aziz N, et al. Idiopathic systemic capillary leak syndrome: novel therapy for acute attacks. *J Allergy Clin Immunol.* 2009;124:1111–1113.
- Xie Z, Chan EC, Long LM, et al. High-dose intravenous immunoglobulin therapy for systemic capillary leak syndrome (Clarkson disease). *Am J Med.* 2015;128:91–95.
- Scanvion Q, Lefevre G, Hachulla E, et al. Subcutaneous immunoglobulin therapy prevents systemic capillary leak syndrome attack. *Am J Med.* 2016;129:e77–e78.
- Lassoued K, Clauvel JP, Similowski T, et al. Pulmonary infections associated with systemic capillary leak syndrome attacks in a patient with hypogammaglobulinemia. *Intensive Care Med.* 1998;24:981–983.
- Abgueguen P, Chennebault JM, Pichard E. Immunoglobulins for treatment of systemic capillary leak syndrome. *Am J Med.* 2010;123:e3–e4.
- Govig BA, Javaheri S. The systemic capillary leak syndrome. *Ann Intern Med.* 2010;153:764.

28. Pecker M, Adams M, Graham W. The systemic capillary leak syndrome. *Ann Intern Med.* 2011;155:335; author reply 335–336.
29. Rabbolini DJ, Ange N, Walters GD, et al. Systemic capillary leak syndrome: recognition prevents morbidity and mortality. *Intern Med J.* 2013;43:1145–1147.
30. Rosenstein M, Ettinghausen SE, Rosenberg SA. Extravasation of intravascular fluid mediated by the systemic administration of recombinant interleukin 2. *J Immunol.* 1986;137:1735–1742.
31. Kai-Feng W, Hong-Ming P, Hai-Zhou L, et al. Interleukin-11-induced capillary leak syndrome in primary hepatic carcinoma patients with thrombocytopenia. *BMC Cancer.* 2011;11:204.
32. Hurteau JA, Blessing JA, DeCesare SL, Creasman WT. Evaluation of recombinant human interleukin-12 in patients with recurrent or refractory ovarian cancer: a gynecologic oncology group study. *Gynecol Oncol.* 2001;82:7–10.
33. Biswas S, Nik S, Corrie PG. Severe gemcitabine-induced capillary-leak syndrome mimicking cardiac failure in a patient with advanced pancreatic cancer and high-risk cardiovascular disease. *Clin Oncol (R Coll Radiol).* 2004;16:577–579.
34. De Pas T, Curigliano G, Franceschelli L, et al. Gemcitabine-induced systemic capillary leak syndrome. *Ann Oncol.* 2001;12:1651–1652.
35. Casadei Gardini A, Aquilina M, Oboldi D, et al. Separate episodes of capillary leak syndrome and pulmonary hypertension after adjuvant gemcitabine and three years later after nab-paclitaxel for metastatic disease. *BMC Cancer.* 2013;13:542.
36. Pulkkanen K, Kataja V, Johansson R. Systemic capillary leak syndrome resulting from gemcitabine treatment in renal cell carcinoma: a case report. *J Chemother.* 2003;15:287–289.
37. Levitt ML, Kassem B, Gooding WE, et al. Phase I study of gemcitabine given weekly as a short infusion for non-small cell lung cancer: results and possible immune system-related mechanisms. *Lung Cancer.* 2004;43:335–344.
38. Lee DW, Gardner R, Porter DL, et al. Current concepts in the diagnosis and management of cytokine release syndrome. *Blood.* 2014;124:188–195.
39. Gaston RS, Deierhoi MH, Patterson T, et al. OKT3 first-dose reaction: association with T cell subsets and cytokine release. *Kidney Int.* 1991;39:141–148.
40. Abramowicz D, Schandene L, Goldman M, et al. Release of tumor necrosis factor, interleukin-2, and gamma-interferon in serum after injection of OKT3 monoclonal antibody in kidney transplant recipients. *Transplantation.* 1989;47:606–608.
41. Wing MG, Moreau T, Greenwood J, et al. Mechanism of first-dose cytokine-release syndrome by CAMPATH 1-H: involvement of CD16 (FcγRIII) and CD11a/CD18 (LFA-1) on NK cells. *J Clin Invest.* 1996;98:2819–2826.
42. Suntharalingam G, Perry MR, Ward S, et al. Cytokine storm in a phase 1 trial of the anti-CD28 monoclonal antibody TGN1412. *N Engl J Med.* 2006;355:1018–1028.
43. Carreras E, Fernandez-Aviles F, Silva L, et al. Engraftment syndrome after auto-SCT: analysis of diagnostic criteria and risk factors in a large series from a single center. *Bone Marrow Transplant.* 2010;45:1417–1422.
44. Spitzer TR. Engraftment syndrome following hematopoietic stem cell transplantation. *Bone Marrow Transplant.* 2001;27:893–898.
45. Frankel SR, Eardley A, Lauwers G, et al. The “retinoic acid syndrome” in acute promyelocytic leukemia. *Ann Intern Med.* 1992;117:292–296.
46. Schenker JG. Prevention and treatment of ovarian hyperstimulation. *Hum Reprod.* 1993;8:653–659.
47. Whelan JG 3rd, Vlahos NF. The ovarian hyperstimulation syndrome. *Fertil Steril.* 2000;73:883–896.
48. Abramov Y, Elchalal U, Schenker JG. Febrile morbidity in severe and critical ovarian hyperstimulation syndrome: a multicentre study. *Hum Reprod.* 1998;13:3128–3131.
49. Elchalal U, Schenker JG. The pathophysiology of ovarian hyperstimulation syndrome—views and ideas. *Hum Reprod.* 1997;12:1129–1137.
50. Lyons CA, Wheeler CA, Frishman GN, et al. Early and late presentation of the ovarian hyperstimulation syndrome: two distinct entities with different risk factors. *Hum Reprod.* 1994;9:792–799.
51. Delvigne A, Rozenberg S. Review of clinical course and treatment of ovarian hyperstimulation syndrome (OHSS). *Hum Reprod Update.* 2003;9:77–96.
52. Janka GE, Lehmbert K. Hemophagocytic lymphohistiocytosis: pathogenesis and treatment. *Hematology Am Soc Hematol Educ Program.* 2013;2013:605–611.
53. Jordan MB, Allen CE, Weitzman S, et al. How I treat hemophagocytic lymphohistiocytosis. *Blood.* 2011;118:4041–4052.
54. Saeed H, Woods RR, Lester J, et al. Evaluating the optimal serum ferritin level to identify hemophagocytic lymphohistiocytosis in the critical care setting. *Int J Hematol.* 2015;102:195–199.
55. Ramos-Casals M, Brito-Zeron P, Lopez-Guillermo A, et al. Adult haemophagocytic syndrome. *Lancet.* 2014;383:1503–1516.
56. Buysse S, Teixeira L, Galicier L, et al. Critical care management of patients with hemophagocytic lymphohistiocytosis. *Intensive Care Med.* 2010;36:1695–1702.
57. Aulagnon F, Lapidus N, Canet E, et al. Acute kidney injury in adults with hemophagocytic lymphohistiocytosis. *Am J Kidney Dis.* 2015;65:851–859.
58. Thauan O, Delahousse M, Fakhouri F, et al. Nephrotic syndrome associated with hemophagocytic syndrome. *Kidney Int.* 2006;69:1892–1898.
59. Henter JL, Arico M, Egeler RM, et al. HLH-94: a treatment protocol for hemophagocytic lymphohistiocytosis. HLH study Group of the Histiocyte Society. *Med Pediatr Oncol.* 1997;28:342–347.
60. Giles RB, Sheedy JA, Ekman CN, et al. The sequelae of epidemic hemorrhagic fever; with a note on causes of death. *Am J Med.* 1954;16:629–638.
61. Peters CJ, Simpson GL, Levy H. Spectrum of hantavirus infection: hemorrhagic fever with renal syndrome and hantavirus pulmonary syndrome. *Annu Rev Med.* 1999;50:531–545.
62. Earle DP. Analysis of sequential physiologic derangements in epidemic hemorrhagic fever; with a commentary on management. *Am J Med.* 1954;16:690–709.
63. *Dengue: Guidelines for Diagnosis, Treatment, Prevention and Control.* Geneva: World Health Organization; 2009:1–160.
64. Giles RB, Langdon EA. Blood volume in epidemic hemorrhagic fever. *Am J Med.* 1954;16:654–661.
65. Sheedy JA, Froeb HF, Batson HA, et al. The clinical course of epidemic hemorrhagic fever. *Am J Med.* 1954;16:619–628.
66. Lima EQ, Nogueira ML. Viral hemorrhagic fever-induced acute kidney injury. *Semin Nephrol.* 2008;28:409–415.
67. van Ypersele de Strihou C. Clinical features of hemorrhagic fever with renal syndrome in Europe. *Kidney Int Suppl.* 1991;35:S80–S83.
68. Lukes RJ. The pathology of thirty-nine fatal cases of epidemic hemorrhagic fever. *Am J Med.* 1954;16:639–650.
69. Miettinen MH, Makela SM, Ala-Houhala IO, et al. Ten-year prognosis of Puumala hantavirus-induced acute interstitial nephritis. *Kidney Int.* 2006;69:2043–2048.
70. Krautkramer E, Kruger DH, Zeier M. Recent outbreaks of hantavirus disease in Germany and in the United States. *Kidney Int.* 2012;82:1243–1245.
71. Bray M, Mahanty S. Ebola hemorrhagic fever and septic shock. *J Infect Dis.* 2003;188:1613–1617.
72. Uyeki TM, Mehta AK, Davey RT Jr., et al. Clinical Management of Ebola Virus Disease in the United States and Europe. *N Engl J Med.* 2016;374:636–646.
73. Chugh KS. Snake-bite-induced acute renal failure in India. *Kidney Int.* 1989;35:891–907.
74. Suchithra N, Pappachan JM, Sujathan P. Snakebite envenoming in Kerala, South India: clinical profile and factors involved in adverse outcomes. *Emerg Med J.* 2008;25:200–204.
75. Bradberry SM, Dickers KJ, Rice P, et al. Ricin poisoning. *Toxicol Rev.* 2003;22:65–70.
76. Engert A, Diehl V, Schnell R, et al. A phase-I study of an anti-CD25 ricin A-chain immunotoxin (RFT5-SMPT-dgA) in patients with refractory Hodgkin’s lymphoma. *Blood.* 1997;89:403–410.
77. Baluna R, Sausville EA, Stone MJ, et al. Decreases in levels of serum fibronectin predict the severity of vascular leak syndrome in patients treated with ricin A chain-containing immunotoxins. *Clin Cancer Res.* 1996;2:1705–1712.
78. Natterer J, Perez MH, Di Bernardo S. Capillary leak leading to shock in Kawasaki disease without myocardial dysfunction. *Cardiol Young.* 2012;22:349–352.
79. Prete M, Urso L, Fatone MC, et al. Antiphospholipids syndrome complicated by a systemic capillary leak-like syndrome treated with steroids and intravenous immunoglobulins: a case report. *Medicine (Baltimore).* 2016;95:e2648.
80. Guffroy A, Dervieux B, Gravier S, et al. Systemic capillary leak syndrome and autoimmune diseases: a case series [e-pub ahead of print]. *Semin*

- Arthritis Rheum*. <http://dx.doi.org/10.1016/j.semarthrit.2016.08.001>. 2016. Accessed October 16, 2016.
81. Dejana E, Tournier-Lasserre E, Weinstein BM. The control of vascular integrity by endothelial cell junctions: molecular basis and pathological implications. *Dev Cell*. 2009;16:209–221.
 82. Komarova Y, Malik AB. Regulation of endothelial permeability via paracellular and transcellular transport pathways. *Annu Rev Physiol*. 2010;72:463–493.
 83. Corada M, Mariotti M, Thurston G, et al. Vascular endothelial-cadherin is an important determinant of microvascular integrity in vivo. *Proc Natl Acad Sci U S A*. 1999;96:9815–9820.
 84. Dejana E, Orsenigo F, Lampugnani MG. The role of adherens junctions and VE-cadherin in the control of vascular permeability. *J Cell Sci*. 2008;121:2115–2122.
 85. London NR, Zhu W, Bozza FA, et al. Targeting Robo4-dependent Slit signaling to survive the cytokine storm in sepsis and influenza. *Sci Transl Med*. 2010;2:23ra19.
 86. Dhir V, Arya V, Malav IC, et al. Idiopathic systemic capillary leak syndrome (SCLS): case report and systematic review of cases reported in the last 16 years. *Intern Med*. 2007;46:899–904.
 87. Navot D, Bergh PA, Laufer N. Ovarian hyperstimulation syndrome in novel reproductive technologies: prevention and treatment. *Fertil Steril*. 1992;58:249–261.
 88. Delvigne A, Demoulin A, Smits J, et al. The ovarian hyperstimulation syndrome in in-vitro fertilization: a Belgian multicentric study. I. Clinical and biological features. *Hum Reprod*. 1993;8:1353–1360.
 89. Borenstein R, Ashkenazy M, Rozenman D, et al. Ovarian hyperstimulation syndrome after different treatment schedules. *Int J Fertil*. 1981;26:279–282.
 90. Kopferschmitt J, Flesch F, Lugnier A, et al. Acute voluntary intoxication by ricin. *Hum Toxicol*. 1983;2:239–242.
 91. Ohta H, Yumara-Yagi K, Sakata N, et al. Capillary leak syndrome in patients with hemophagocytic lymphohistiocytosis. *Acta Paediatr*. 1994;83:1113–1114.
 92. Besset S, Schnell D, Azoulay E. Hemophagocytic lymphohistiocytosis mimicking septic shock. *Chest*. 2012;141:835; author reply 836.
 93. Lotze MT, Matory YL, Ettinghausen SE, et al. In vivo administration of purified human interleukin 2. II. Half life, immunologic effects, and expansion of peripheral lymphoid cells in vivo with recombinant IL 2. *J Immunol*. 1985;135:2865–2875.
 94. Fitzgerald NE, MacClain KL. Imaging characteristics of hemophagocytic lymphohistiocytosis. *Pediatr Radiol*. 2003;33:392–401.
 95. Borenstein R, Elhalah U, Lunenfeld B, Schwartz ZS. Severe ovarian hyperstimulation syndrome: a reevaluated therapeutic approach. *Fertil Steril*. 1989;51:791–795.
 96. Abramov Y, Elchalal U, Schenker JG. Pulmonary manifestations of severe ovarian hyperstimulation syndrome: a multicenter study. *Fertil Steril*. 1999;71:645–651.
 97. Ramesh G, Reeves WB. TNF-alpha mediates chemokine and cytokine expression and renal injury in cisplatin nephrotoxicity. *J Clin Invest*. 2002;110:835–842.
 98. Justo P, Sanz AB, Sanchez-Nino MD, et al. Cytokine cooperation in renal tubular cell injury: the role of TWEAK. *Kidney Int*. 2006;70:1750–1758.
 99. Sanz AB, Santamaria B, Ruiz-Ortega M, et al. Mechanisms of renal apoptosis in health and disease. *J Am Soc Nephrol*. 2008;19:1634–1642.
 100. Yang Y, Zhang ZX, Lian D, et al. IL-37 inhibits IL-18-induced tubular epithelial cell expression of pro-inflammatory cytokines and renal ischemia-reperfusion injury. *Kidney Int*. 2015;87:396–408.
 101. Padilla SL, Zamaria S, Baramki TA, Garcia JE. Abdominal paracentesis for the ovarian hyperstimulation syndrome with severe pulmonary compromise. *Fertil Steril*. 1990;53:365–367.
 102. Raschke RA, Garcia-Orr R. Hemophagocytic lymphohistiocytosis: a potentially underrecognized association with systemic inflammatory response syndrome, severe sepsis, and septic shock in adults. *Chest*. 2011;140:933–938.
 103. Lee YS, Kim SY, Kwon CW, et al. Two cases of systemic capillary leak syndrome that were treated with pentastarch. *Korean J Intern Med*. 2007;22:130–132.
 104. Zarychanski R, Abou-Setta AM, Turgeon AF, et al. Association of hydroxyethyl starch administration with mortality and acute kidney injury in critically ill patients requiring volume resuscitation: a systematic review and meta-analysis. *JAMA*. 2013;309:678–688.
 105. Almawi WY, Beyhum HN, Rahme AA, Rieder MJ. Regulation of cytokine and cytokine receptor expression by glucocorticoids. *J Leukoc Biol*. 1996;60:563–572.