

## Case Report

# Secondary mixed phenotype acute leukemia following chemotherapy for diffuse large B-cell lymphoma: a case report and review of the literature

Xubo Gong<sup>1</sup>, Lijuan Yan<sup>2</sup>, Xibin Xiao<sup>3</sup>, Qiusu Tang<sup>4</sup>, Xiaoying Zhao<sup>3</sup>

Departments of <sup>1</sup>Clinical Laboratory, <sup>2</sup>Gastroenterology, <sup>3</sup>Hematology, The Second Affiliated Hospital, School of Medicine, Zhejiang University, Hangzhou, China; <sup>4</sup>Department of Pathology, The First Affiliated Hospital, School of Medicine, Zhejiang University, Hangzhou, China

Received February 7, 2018; Accepted March 20, 2018; Epub June 1, 2018; Published June 15, 2018

**Abstract:** Therapy-related mixed phenotype acute leukemia (MPAL) following non-Hodgkin's lymphoma (NHL) is extremely rare. We present here the case of an elderly man, diagnosed with diffuse large B-cell lymphoma (DLBCL) through a tonsil biopsy. After treatment with seven cycles of CHOP (cyclophosphamide, doxorubicin, vincristine and prednisolone) like regimen, the patient developed to MPAL (B/myeloid) with del(7)(q22), t(6;9)(p23;q34), *DEK/NUP214* fusion, as well as *EZH2* and *TET2* mutations. The patient was successively treated with chemotherapy and allogeneic hematopoietic stem cell transplantation. Until recently he is still alive more than 23 months without relapse.

**Keywords:** Diffuse large B-cell lymphoma, mixed phenotype acute leukemia, CHOP

## Introduction

Diffuse large B-cell lymphoma (DLBCL) is an aggressive non-Hodgkin's lymphoma (NHL), which represents approximately 25-30% of all lymphomas and is the most common subtype throughout the world [1]. DLBCL is aggressive but potentially curable with multi-agent chemotherapy [1, 2]. The CHOP (cyclophosphamide, doxorubicin, vincristine, and prednisolone) regimen has been the mainstay of therapy for several decades, and the addition of the anti-CD20 monoclonal antibody rituximab to CHOP has led to a marked improvement in survival [2-4].

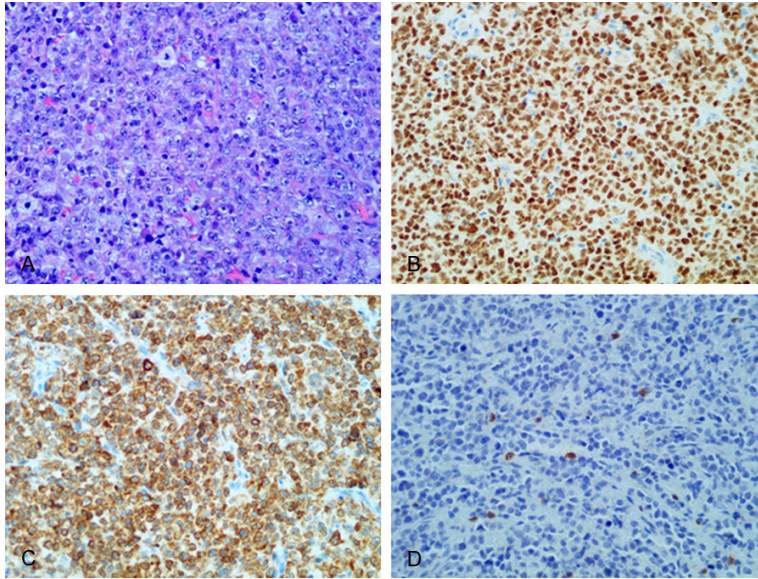
However, several studies have reported an elevated risk of therapy-related malignancy overall following DLBCL or other NHL, such as solid and hematological tumors [3-8]. The risk of secondary acute leukemia after long-term treatment for NHL has been estimated at 1-1.5% per year from 2-10 years after the start of primary chemotherapy [8, 9]. Secondary acute myeloid leukemia (AML) following NHL was relatively less frequently reported than secondary acute lymphoid leukemia (ALL), and

secondary mixed phenotype acute leukemia (MPAL) following NHL was much more rarely reported [9, 10].

In this paper, we describe a patient with DLBCL without chromosomal aberration at primary diagnosis. After treatment with a CHOP-like regimen, the patient developed a secondary mixed phenotype acute leukemia (MPAL) with chromosomal abnormalities and gene mutations. Our patient was successfully treated with chemotherapy and allogeneic hematopoietic stem cell (allo-HSC) transplantation.

## Case report

In March 2012, a 56-year-old Chinese man was admitted with two weeks' history of fever, tonsil pain, and enlargement of multiple cervical lymph nodes. Histological analysis of biopsied tonsil demonstrated DLBCL expressing CD20, CD79a, Bcl-2, Bcl-6, and PAX-5, but not CD3, CD30 (Ki-1), CD5, ALK, MPO, EBV, CD21 or CD10 (**Figure 1**). Laboratory data revealed that hemoglobin (Hb) was 112 g/L, red blood cell (RBC) count  $3.54 \times 10^9/L$ , white blood cell



**Figure 1.** Diffuse large B-cell lymphoma (DLBCL) with tonsil involvement. Tonsil biopsies showed a diffuse proliferation of DLBCL cells with oval to round size, significantly basophilic cytoplasm and a central nucleolus (A) (Hematoxylin-Eosin staining); they were positive for CD79a (B), PAX-5 (C), but negative for CD3 (D) ( $\times 400$ ).

(WBC) count  $6.5 \times 10^9/L$ , and platelet (PLT) count  $137 \times 10^9/L$ . Both bone marrow (BM) smears and biopsies showed no abnormalities. Immunophenotyping and chromosomal analysis of BM aspirate was normal. In addition, computerized tomography (CT) of the chest, abdomen and pelvis did not reveal any changes suspicious for disease spread. Subsequently, chemotherapy according to the standard CHOP scheme was promptly administered leading to a rapid and progressive improvement. After treatment with six courses of CHOP regimen, the patient was asymptomatic.

In October 2014, he was hospitalized again for one month history of lower abdominal pain and lump. Abdominal CT scan showed intestinal obstruction. Laboratory data revealed that Hb was 108 g/L, WBC count  $7.2 \times 10^9/L$ , and PLT count  $96 \times 10^9/L$ . A abdominal operation was performed immediately. A biopsy sample obtained from the small intestine showed diffuse infiltration by DLBCL cells, which was confirmed by immunohistochemistry. In addition, histopathological examination showed DLBCL in 3 of 27 peri-intestinal lymph nodes. After surgical excision and elective lymph nodes dissection, the patient's symptoms gradually improved. Subsequently, the patient received one cycle of standard CHOP chemotherapy plus rituximab.

In December 2014, he developed general weakness, malaise and fever. On examination he was pale, and had dental ulcers but no icterus. Ultrasound diagnosis showed enlargement of the bilateral axillary lymph nodes, but no lymphadenectasis was found in the lower jaw, cervical region and inguinal groove. Abdominal CT scan revealed no hepatosplenomegaly or other abnormality.

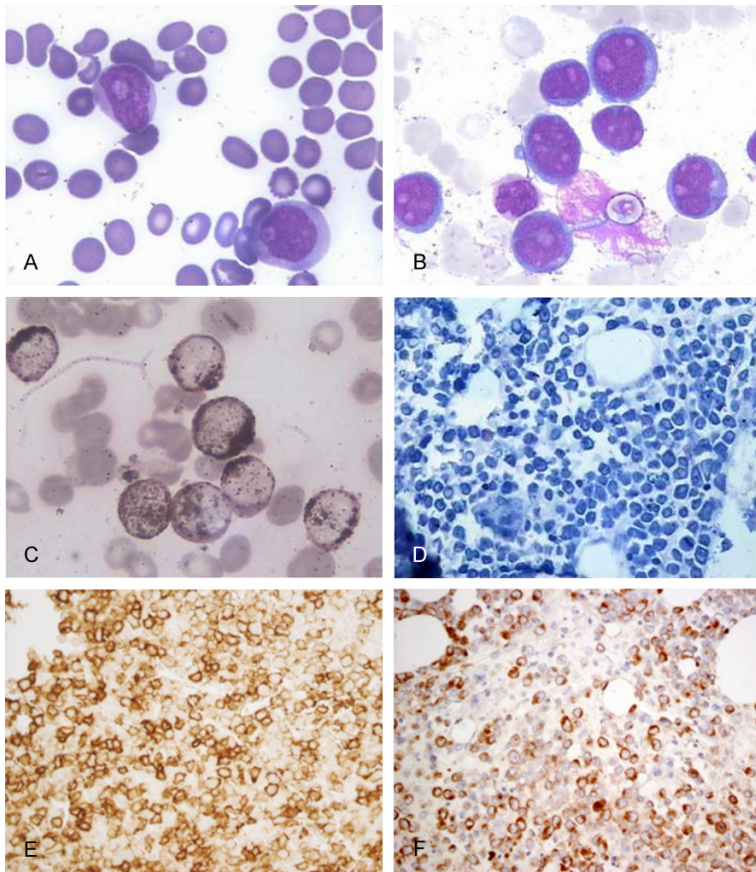
Complete blood count showed that Hb was decreased to 59 g/L, RBC count  $2.02 \times 10^9/L$ , WBC count  $6.7 \times 10^9/L$ , and PLT count was reduced to  $18 \times 10^9/L$ . Serum  $\beta 2$ -microglobulin and immunoglobulin G levels were 4.3  $\mu g/L$  and 19.53 g/L, respectively. Coombs' test was negative, and no other

special biochemical or immune abnormalities were found.

Peripheral blood (PB) smears revealed 75% blasts, 12% neutrophils, 6% immature granulocyte, 6% lymphocyte, 1% basophilic granulocyte. The blasts were characterized by fine azurophilic granules with abundant cytoplasm, and irregular nuclei with 1-2 nucleoli.

BM smears were hypercellular with 85.5% blasts; the morphologic features were similar to those on PB smears. In addition, erythroid dysplasia was frequently observed. The blasts were 86% positive for myeloperoxidase staining, 92% for sudan black-B staining, and 82% for naphthol-AS-D chloracetate esterase staining, but they were negative for alpha-naphthyl butyrate esterase (**Figure 2**). BM trephine sections showed that blasts were positive for MPO, CD19 and CD22, but were negative for CD7 and CD3 (**Figure 2**).

Flow cytometric analysis of the BM aspirate showed that the blasts were positive for CD13 (94.46%), cMPO (67.61%), CD15 (45.36%), CD19 (64.92%), cCD79a (29.30), CyCD22 (31.3%), CD117 (48.61%), CD34 (98.62%) and HLA-DR (93.49%), but were negative for CD14, CD10, CD20, CD7, CD2, CD3, CD56 and CD61 (**Figure 3**).



**Figure 2.** Morphological findings of mixed phenotype acute leukemia. Blasts on peripheral blood smears (A) and bone marrow smears (B) were characterized by fine azurophilic granules with abundant cytoplasm. The nuclei were always irregular with 1-2 nucleoli (Wright-Giemsa stain). They were positive by Sudan black-B staining (C) ( $\times 1000$ ). Bone marrow sections showed a diffuse proliferation of blasts (D) (Hematoxylin-Giemsa-Fuchsin staining), which were positive for MPO (E) and CD19 (F) ( $\times 400$ ).

Cytogenetic analysis of BM cells revealed 46, XY, del(7)(q22), t(6;9)(p23;q34) (**Figure 4**). Multiplex-nested reverse transcription PCR assay for *DEK/NUP214* was positive, but for *CBFB/MYH11*, *FLT3/ITD*, *TEL-AML1*, *MLL/AFX*, *MLL/AF4*, *MLL/AF6*, *MLL/AF9*, *MLL/AF10*, *MLL/ELL*, *MLL/AF1P*, *MLL/AF17*, *E2A/PBX1*, *BCR/ABL1*, *SIL/TAL1*, *AML1/ETO*, *MLL/ENL*, *NPM/ALK*, *PRKARIA/RAR $\alpha$* , *FIPIL1/RAR $\alpha$* , *NuP98/PMX1*, *NuP98/HOxD13*, *NuP98/HOxC11*, *NuP98/HOxA13*, *NuP98/HOxA11*, *NuP98/HOxA9*, *ETV6/PDGFR $\beta$* , *ETV6/RUNX1*, *ETV6-PDGFR $\alpha$* , *FIPIL1/PDGFR $\alpha$* , *NPM/RAR $\alpha$* , *PML/RAR $\alpha$* , *SET/CAN*, *DEK/CAN*, *TLS/ERG*, *PLZF/RAR $\alpha$* , *STAT5b/RAR $\alpha$* , *NuMA1/RAR $\alpha$* , *MLL/AF1Q*, *NPM/MLF1*, *TEL/ABL1*, *AML1/MDS1*, *E2A/HLF*, *dupMLL*, *HOX11*, *EVI1* and *TEL/PDGFR* were all negative. Fluorescence in situ hybridization analyses with probes for *DEK/NUP214*

was positive, but probes for *CCND1/IGH*, *IGH/BCL-2*, and *PML/RARA* were all negative. (**Figure 5**)

Genomic DNA for *C-KIT*, *NPM1*, *FLT3-TKD*, *FLT3-ITD*, *EZH2*, *RUNX1*, *ASXL1*, *IDH1*, *IDH2*, *CBL*, *WT1*, *TET2*, *DNMT3A*, *PHF6*, *FBXW7*, *NOTCH1*, *ETV6*, *JAK2V617F* and *TET3* were amplified, then the PCR products were sequenced. We observed *EZH2* and *TET2* mutations.

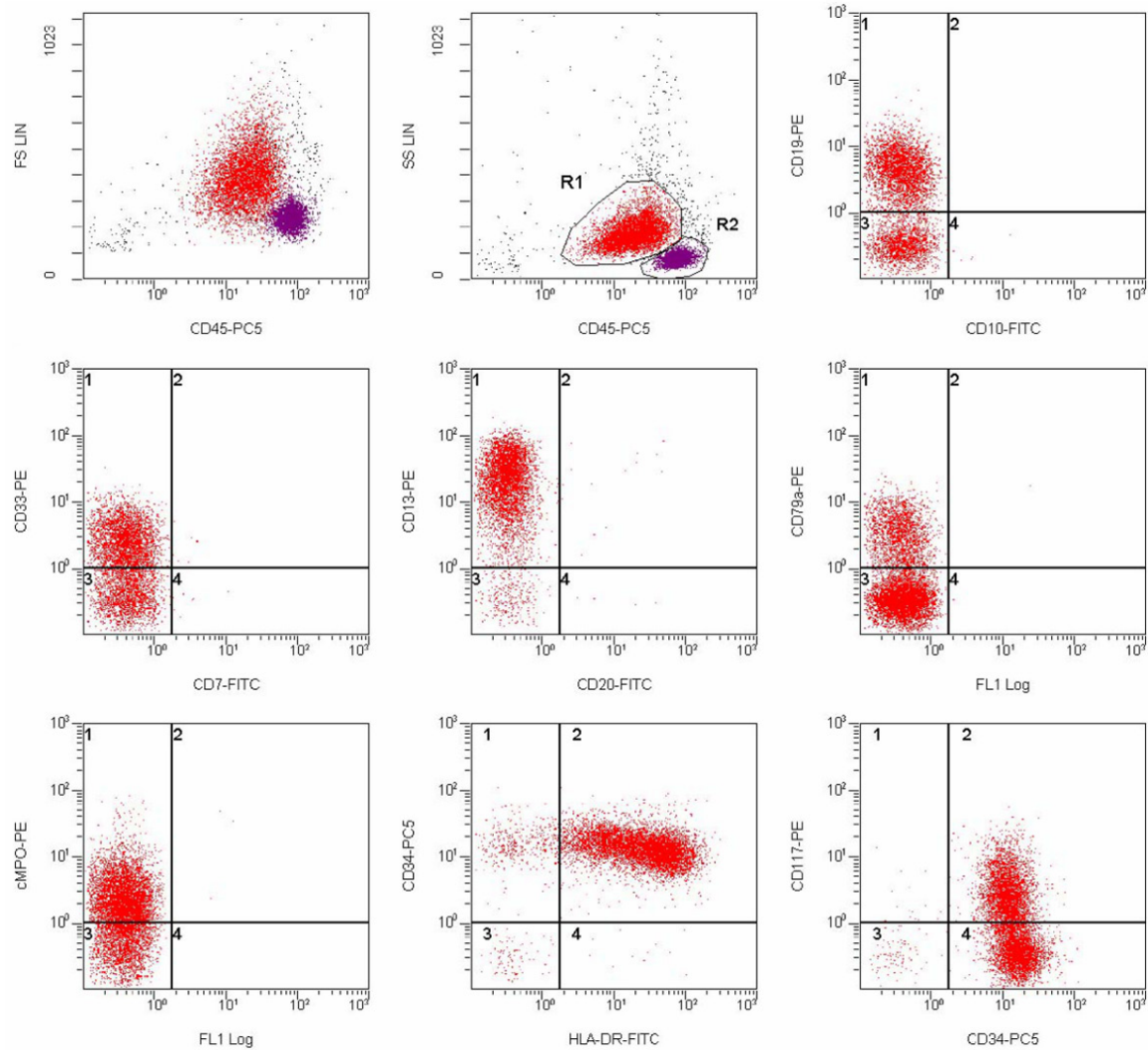
Based on the revised 2016 WHO criteria, the patient was diagnosed as therapy-related mixed phenotype acute leukemia (MPAL), B/myeloid, with del(7)(q22), t(6;9)(p23;q34), *DEK/NUP214* fusion, as well as *EZH2* and *TET2* mutations.

After two course of induction chemotherapy with vincristine, daunorubicin, L-asparaginase, prednisone (VDLP) and Ara-c, the patient achieved complete remission. Then he received four courses of consolidation chemotherapy with DVP (daunorubicin, vincristine, and prednisone). After preconditioning with an improved busulfan and cyclophosphamide (Bu/Cy) regimen, the patient was successively treated with allogeneic hematopoietic stem cells (HSC) transplantation. At present he is alive more than 23 months without relapse.

## Discussion

We present a unique case of secondary mixed phenotypic acute leukemia (MPAL) with del(7)(q22), t(6;9)(p23;q34), and *DEK/NUP214* fusion after DLBCL. Immunophenotyping findings of our case show that the blasts co-expressed myeloid and B-lymphoid differentiation antigens. Morphologically, the blasts present with myeloid features, which can be easily mistaken for AML. We indicate that flow cytometry and immunohistochemistry should be the preferred method for establishing the diagnosis of MPAL.

## Therapy-related mixed phenotype acute leukemia

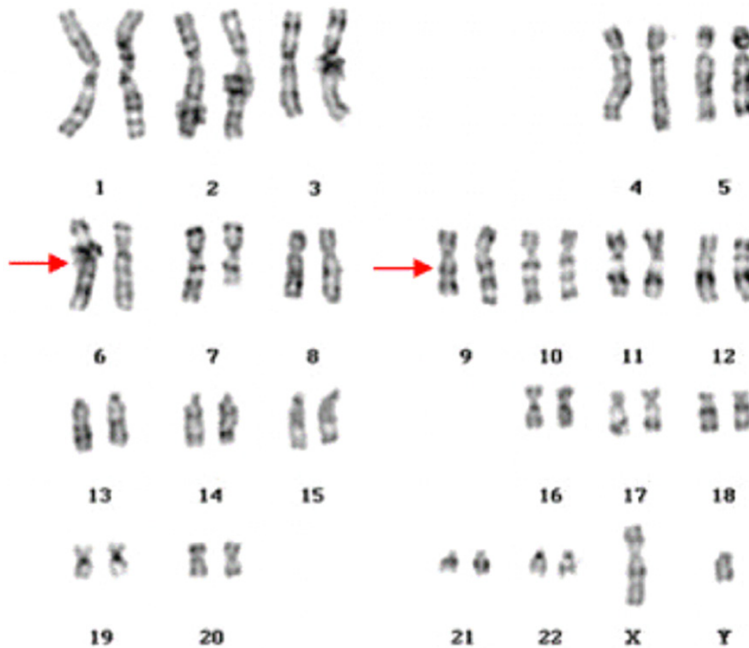


**Figure 3.** Flow cytometric findings of mixed phenotype acute leukemia. Cell suspension immunophenotypic studies were performed on BM aspirate. Region 1 (R1) counted for 60.93% of all nucleated cells. In R1, the majority of the cells co-expressed myeloid (cMPO, CD13) and lymphoid antigens (CD19, cCD79a).

Our patient has a history of DLBCL about three years. It is reported that NHL survivors have approximately twice the increased risk of secondary malignant neoplasm compared with the general population [7-9]. Young age, male sex, total body irradiation, alkylating agents and topoisomerase II inhibitors are the major risk factors associated with ANLL for NHL [6, 9], and the median time to development of therapy-related ANLL is 3 to 5 years [9, 10]. Our patient is an elderly man, who did not receive irradiation treatment; he received 7 courses of CHOP-like chemotherapy. Cyclophosphamide (alkylating agent) and (or) doxorubicin (topoisomerase II inhibitor), two important compo-

nents of CHOP, may be highly associated with the development of MPAL for our patient.

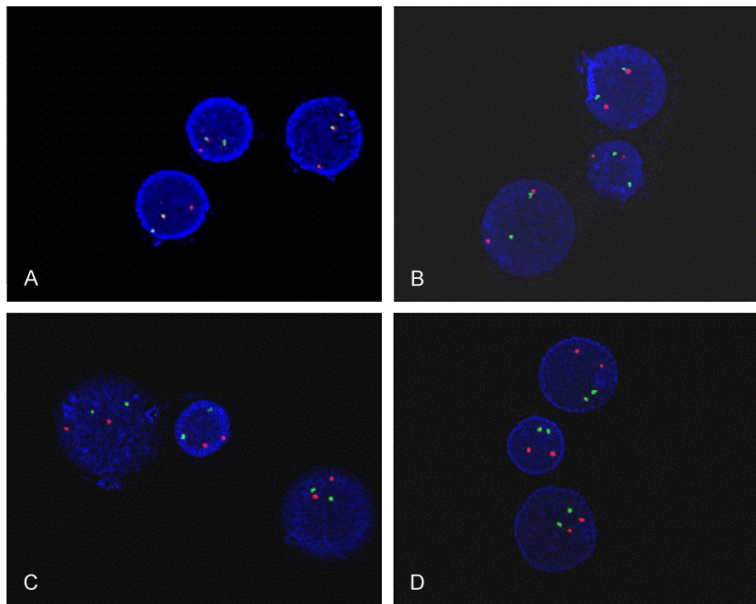
In addition to chromosome abnormalities, *EZH2* and *TET2* mutations were also observed in our patient with secondary MPAL. But it is still uncertain whether the mutations have been present at the time of primary diagnosis for DLBCL. So we extracted genomic DNA from the patient's paraffin-embedded bone marrow biopsies at the first diagnosis of DCBCL for comparison. After DNA amplification for *EZH2* and *TET2*, the PCR products were sequenced, but no *EZH2* or *TET2* mutation was detected. Thus, besides *del(7)(q22)* and *t(6;9)(p23;q34)*, the acquisition of *EZH2* and *TET2* mutations were



**Figure 4.** G-banded karyogram of the bone marrow cells at the initial diagnosis. The karyotype is 46, XY, del(7)(q22), t(6;9)(p23;q34). Arrows indicate rearranged chromosomes.

related MPAL is even more rare; only four cases have been reported until recently [11-14]. Three cases were secondary after solid tumors (breast cancer, seminoma, and uterine cancer, respectively) [12-14], and the other case was secondary after NHL [11]. One common feature is that all four cases were treated with alkylating agent (cyclophosphamide or cisplatin). Many reports showed that MPAL had a high incidence of abnormal karyotype, especially positive Ph chromosome (Ph+) and 11q23 abnormality [14-16]. To the best of our knowledge, MPAL with del(7)(q22), t(6;9)(p23;q34) and *DEK/NUP214* fusion have not been reported in the literature.

Due to its heterogeneity, overlapping features with other types of ALL and AML, and lineage plasticity, MPAL has a poor prognosis particularly in adults, and secondary MPAL seems to have a worse clinical outcome compared with de novo cases [15, 16]. Currently, there are no special treatment guidelines for MPAL [16-18]. It is suggested that ALL-directed treatment seems more effective with a higher response rate and better outcome compared with AML or to an AML + ALL schedule, and tyrosine kinase inhibitors seems to be more effective to Ph+ MPAL [17-19]. Our patient achieved complete remission with chemotherapy and allogeneic HSC transplantation, and maintained a good quality of life without serious adverse events.



**Figure 5.** Fluorescence in situ hybridization analyses. The probes for *DEK/NUP214* (A) on interphase nuclei were positive, but probes for *CCND1/IGH* (B), *IGH/BCL-2* (C), and *PML/RARA* (D) were all negative.

critical drivers of secondary MPAL to our patient.

MPAL is a rare disorder with an incidence of less than 2% of all acute leukemia. Therapy-

In summary, we report one unique case of therapy-related MPAL with del(7)(q22), t(6;9)(p23;q34), and *DEK/NUP214* fusion, as well as *EZH2* and *TET2* mutations, following DLBCL with CHOP-like treatment. The clinical courses of the

present case suggests that allogeneic HSC transplantation is a safe and effective method for secondary MPAL.

#### Acknowledgements

This work was supported by National Natural Science Foundation of China (No. 81400107), Health and Family Planning Commission of Zhejiang province (2015KYA110).

#### Disclosure of conflict of interest

None.

**Address correspondence to:** Xiaoying Zhao, Department of Hematology, The Second Affiliated Hospital, School of Medicine, Zhejiang University, 88 Jiefang Road, Hangzhou 310009, China. Tel: +86-571-87783672; Fax: +86-571-87074866; E-mail: zrxz@zju.edu.cn

#### References

- [1] In: Gascoyne RD, Campo E, Jaffe ES, Chan JKC, Rosenwald A, Stein H, Swerdlow SH, editors. Diffuse large B-cell lymphoma, not otherwise specified. World Health Organization classification of haematopoietic and lymphoid tissues of tumors. 4th edition. IARC Press; 2016. pp. 291-297.
- [2] Persky DO, Li H, Rimsza LM, Barr PM, Poplewell LL, Bane CL, Von Gehr A, LeBlanc M, Fisher RI, Smith SM, Friedberg JW. A phase I/II trial of vorinostat (SAHA) in combination with rituximab-CHOP in patients with newly diagnosed advanced stage diffuse large B-cell lymphoma (DLBCL): SWOG S0806. *Am J Hematol* 2018; 93: 486-493.
- [3] Phipps C, Lee YS, Ying H, Nagarajan C, Grigoriopoulos N, Chen Y, Tang T, Goh AZ, Ghosh A, Ng HJ, Gopalakrishnan S, Loh Y, Lim ST, Hwang W, Tan D, Goh YT. The impact of time from diagnosis to treatment in diffuse large B-cell lymphoma. *Leuk Lymphoma* 2018; 1-6.
- [4] Dada R. Lenalidomide maintenance after R-CHOP therapy in diffuse large B-cell lymphoma: can it be a standard of care? *Acta Haematol* 2017; 138: 216-220.
- [5] Witzig TE, Johnston PB, LaPlant BR, Kurtin PJ, Pederson LD, Moore DF Jr, Nabbut NH, Nikcevic DA, Rowland KM, Grothey A. Long-term follow-up of chemoimmunotherapy with rituximab, oxaliplatin, cytosine arabinoside, dexamethasone (ROAD) in patients with relapsed CD20+ B-cell non-Hodgkin lymphoma: results of a study of the mayo clinic cancer center research consortium (MCCRC) MC-0485 now known as academic and community cancer research united (ACCRU). *Am J Hematol* 2017; 92: 1004-1010.
- [6] Morton LM, Curtis RE, Linet MS, Bluhm EC, Tucker MA, Caporaso N, Ries LA and Fraumeni JF. Second malignancy risks after non-Hodgkin's lymphoma and chronic lymphocytic leukemia: differences by lymphoma subtype. *J Clin Oncol* 2010; 28: 4935-4944.
- [7] Tadmor T, Liphshitz I, Silverman B, Polliack A. Incidence and epidemiology of non-Hodgkin lymphoma and risk of second malignancy among 22 466 survivors in Israel with 30 years of follow-up. *Hematol Oncol* 2017; 35: 599-607.
- [8] Armitage JO, Carbone PP, Connors JM, Levine A, Bennett JM and Kroll S. Treatment-related myelodysplasia and acute leukemia in non-Hodgkin's lymphoma patients. *J Clin Oncol* 2003; 21: 897-906.
- [9] Chien SH, Liu CJ, Hong YC, Teng CJ, Yeh CM, Chiou TJ, Gau JP, Tzeng CH. Development of second primary malignancy in patients with non-Hodgkin lymphoma: a nationwide population-based study. *J Cancer Res Clin Oncol* 2015; 141: 1995-2004.
- [10] Bhatia S. Therapy-related myelodysplasia and acute myeloid leukemia. *Semin Oncol* 2013; 40: 666-675.
- [11] Roberts E, Oncale M, Safah H and Schmiegl J. Therapy-related T/myeloid mixed phenotype acute leukemia in a patient treated with chemotherapy for cutaneous diffuse large B cell lymphoma. *J La State Med Soc* 2016; 168: 16-20.
- [12] Briasoulis E, Tzouvara E, Tsiara S, Vartholomatos G, Tsekeris P and Bourantas K. Biphenotypic acute leukemia following intensive adjuvant chemotherapy for breast cancer: case report and review of the literature. *Breast J* 2013; 9: 241-245.
- [13] Yamamoto K, Sada A, Kawano Y, Katayama Y, Shimoyama M and Matsui T. Therapy-related, mixed phenotype acute leukemia with t(1;21)(p36;q22) and RUNX1 rearrangement. *Cancer Genet Cytogenet* 2010; 201: 122-127.
- [14] Cho JH, Hur M, Moon HW, Yun YM, Ko YS, Kim WS and Lee MH. Therapy-related acute leukemia with mixed phenotype and t(9;22)(q32;q11.2): a case report and review of the literature. *Hum Pathol* 2012; 43: 605-609.
- [15] Munker R, Labopin M, Esteve J, Schmid C, Mohty M, Nagler A. Mixed phenotype acute leukemia: outcomes with allogeneic stem cell transplantation. a retrospective study from the acute leukemia working party of the EBMT. *Haematologica* 2017; 102: 2134-2140.
- [16] Getta BM, Roshal M, Zheng J, Park JH, Stein EM, Levine R, Papadopoulos EB, Jakubowski AA, Kernan NA, Steinherz P, O'Reilly RJ, Perales

## Therapy-related mixed phenotype acute leukemia

- MA, Giralt SA, Tallman MS, Shaffer BC. Allogeneic hematopoietic stem cell transplantation with myeloablative conditioning is associated with favorable outcomes in mixed phenotype acute leukemia. *Biol Blood Marrow Transplant* 2017; 23: 1879-1886.
- [17] Wolach O, Stone RM. Mixed-phenotype acute leukemia: current challenges in diagnosis and therapy. *Curr Opin Hematol* 2017; 24: 139-145.
- [18] Takata H, Ikebe T, Sasaki H, Miyazaki Y, Ohtsuka E, Saburi Y, Ogata M and Shirao K. Two elderly patients with philadelphia chromosome positive mixed phenotype acute leukemia who were successfully treated with dasatinib and prednisolone. *Intern Med* 2016; 55: 1177-1181.
- [19] Wolach O and Stone RM. How to treat mixed-phenotype acute leukemia. *Blood* 2015; 125: 2477-2485.