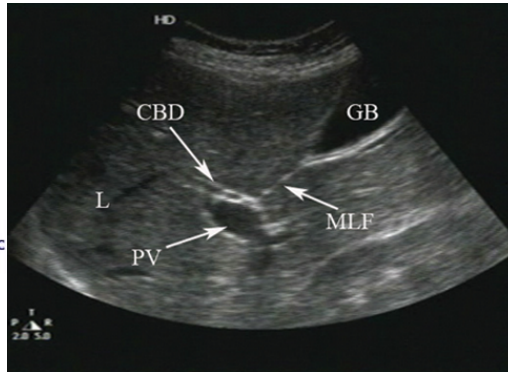
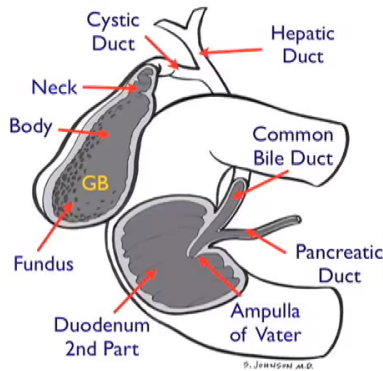


# UCSF ED Liver and Gallbladder/Biliary Ultrasound Protocol

**Indications:** 1) Abdominal pain suggestive of cholelithiasis or cholecystitis, 2) Acute pancreatitis not clearly related to alcohol, 3) Jaundice of unclear cause

## Liver and Biliary Anatomy



GB=Gallbladder  
CBD=Common Bile  
Duct  
MLF=Median Lobar  
Fissure  
PV=Portal Vein  
L=Liver

**Patient positioning:** Supine with right arm bent at elbow and forearm above head. If views are limited, place patient in L lateral decubitus with right arm overhead as described.

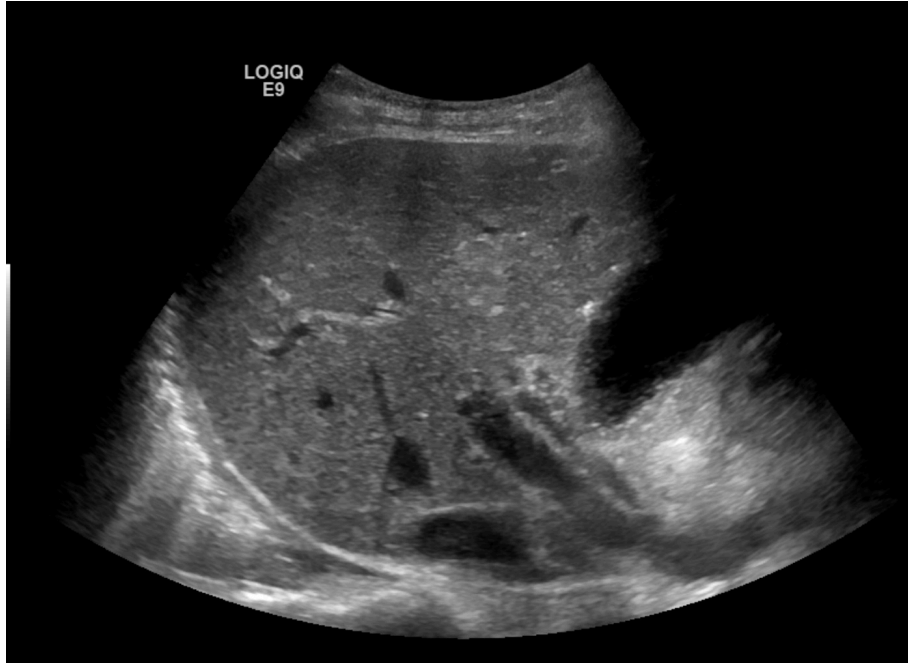**Transducer:** 5-2 Mhz curvilinear transducer; this is preferred over the phased array transducer. Mode should be set to "Abdomen."

## Technique Guidelines:

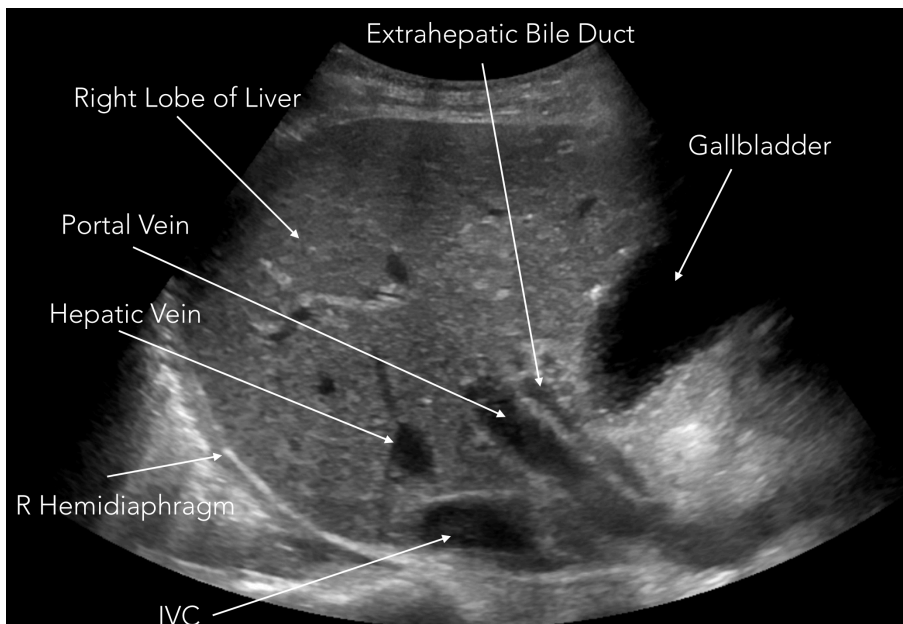
- 1) Gallbladder/biliary sonograms are among the most technically challenging studies we perform in the ED. A quality study often requires patience and multiple views of the structures of interest. Thus, it's important to obtain images from several perspectives as described below.
- 2) A study aimed at identifying gallstones is not complete unless the neck of the gallbladder is clearly visualized. If you see the majority of the gallbladder but not the neck, indicate that in your interpretation (this is a choice on the interpretation template). Stones impacted in the gallbladder neck are more likely to cause acute cholecystitis than mobile stones freely floating within the gallbladder.
- 3) Sonographic findings consistent with acute cholecystitis include stones, wall thickening, pericholecystic fluid, focal gallbladder tenderness, and gallbladder distension. Normal long-axis is up to 10cm, normal short-axis dimension is up to 4cm. Emphasis should be on the short axis measurement when assessing dilation.
- 4) Intuitively, most providers will want to obtain images with the transducer placed below the ribs. In fact, in most patients the most helpful images are obtained several rib spaces above the costal margin. Begin your study there.

## Scanning Protocol:

**Views #1-5:** With the transducer just lateral to the midclavicular line approximately 2-3 rib spaces above the costal margin, obtain at least 3 still images and 2 cine clips of the right lobe of the liver. The transducer should be roughly parallel to the course of the ribs. You should see the arc of the right hemidiaphragm on the left of the screen, the main portal vein extending upward at a 45deg angle into the liver, and the IVC. The gallbladder may or may not be seen in these views.



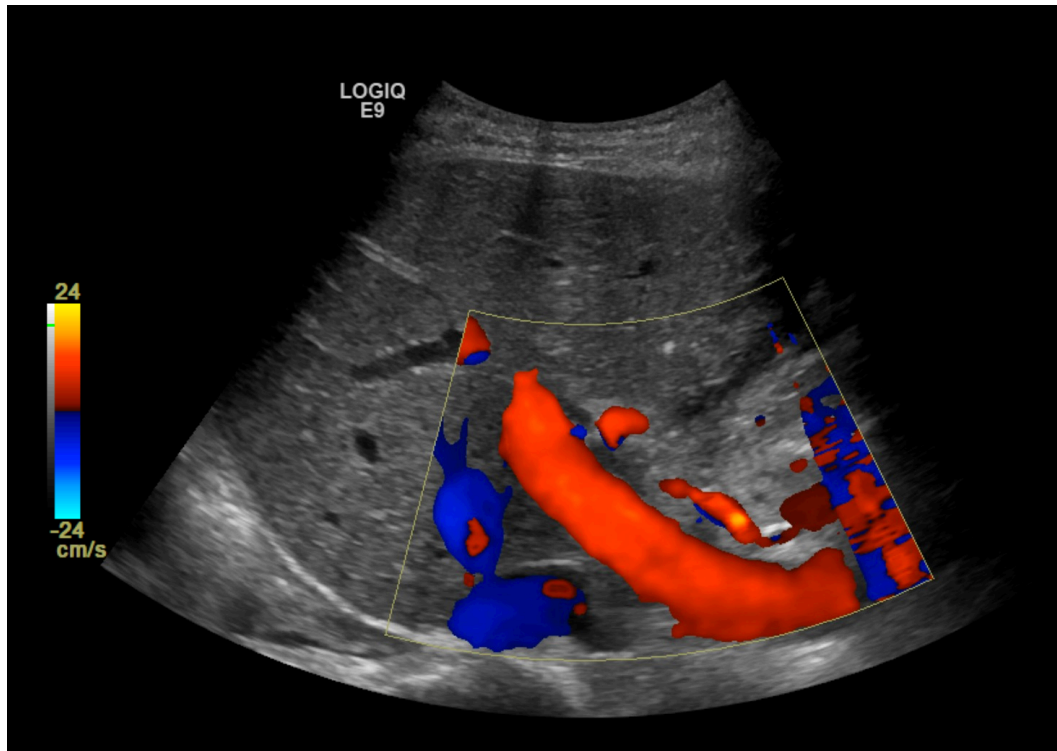
**Left: Transverse sonogram of the right lobe of the liver.** You should aim to see 1) the liver, 2) the IVC, and 3) the main portal vein, which will be the large vascular structure travelling upward into the liver at a 45deg angle. Ideally, the CBD will also be seen just above the PV. It is not necessary to visualize the gallbladder in this view.



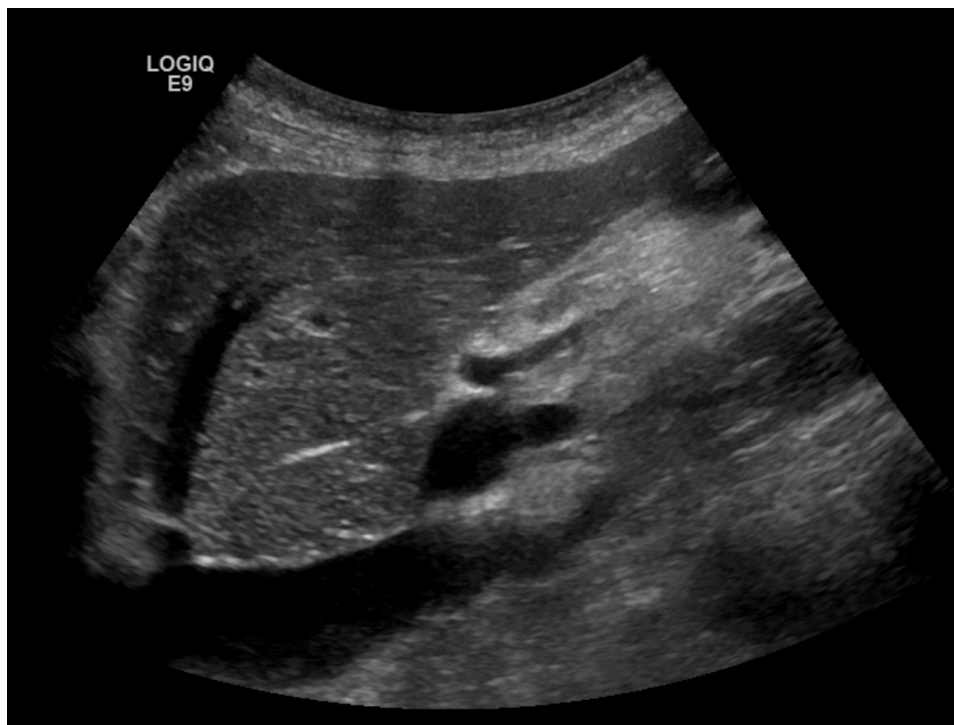**Left: Above image with labels.** Note that the portal vein and its branches have thick, echogenic walls. The walls of the hepatic veins are thin and nearly imperceptible. The IVC is seen in the far field and will normally have a complex “pulsatile” appearance due to both respiratory changes and to the influence of the central venous pressure (recall the a, c, x, and y waves of the CVP). If seen, the CBD will run just anterior to the portal vein.



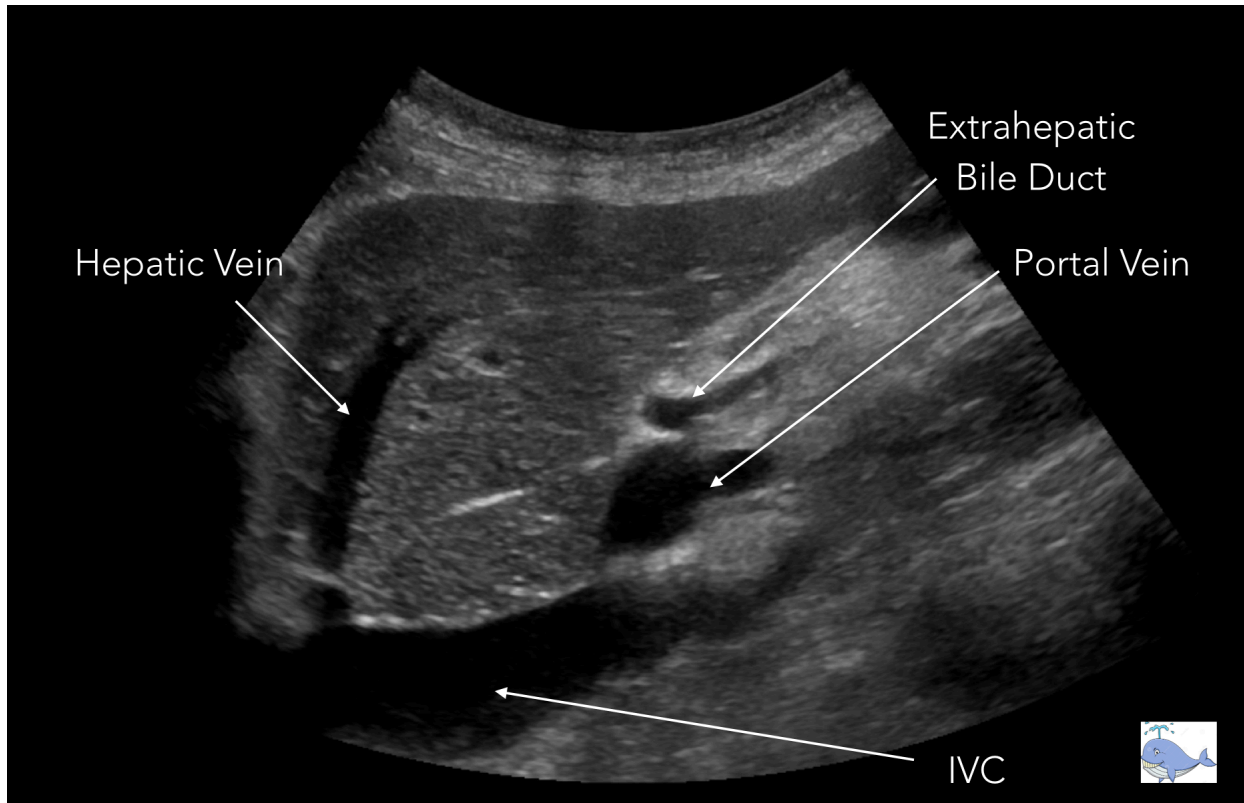
**View #6:** Obtain one still image of the right lobe of the liver with color Doppler to confirm normal hepatopedal (into the liver) flow in the portal vein. Adjust your color scale accordingly (usually between 15-30cm/sec).



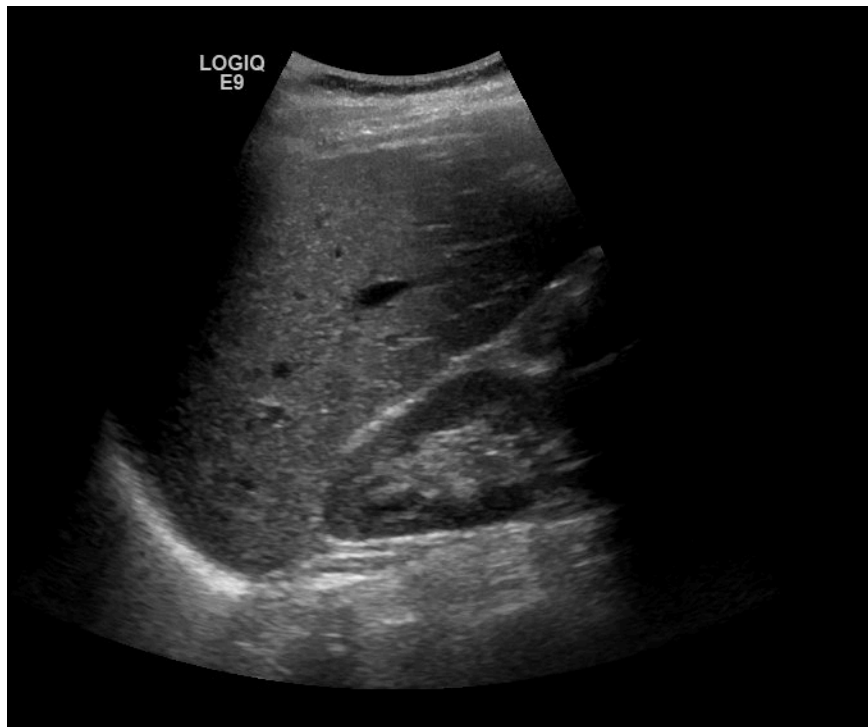
**Left: Color Doppler** reveals normal portal venous blood flow into the liver (red = flow towards the transducer) and normal hepatic vein blood flow towards and into the IVC (blue = flow away from the transducer).



**View #7-8:** Keeping the transducer in the same location, rotate the probe marker slightly anteriorly to obtain a view of the right lobe of the liver with the IVC seen in a long axis. Take 1 still image and 1 cine clip.



**Above: Image with labels.** This is sometimes referred to as the “happy whale” view, with the whale’s smile = IVC, eye = portal vein, eyebrow = bile duct, hepatic vein = water spout emerging from blowhole. Note that the anatomic relationship between the IVC, PV, and bile duct is always the same: IVC = most posterior, then PV above, then bile duct above that.

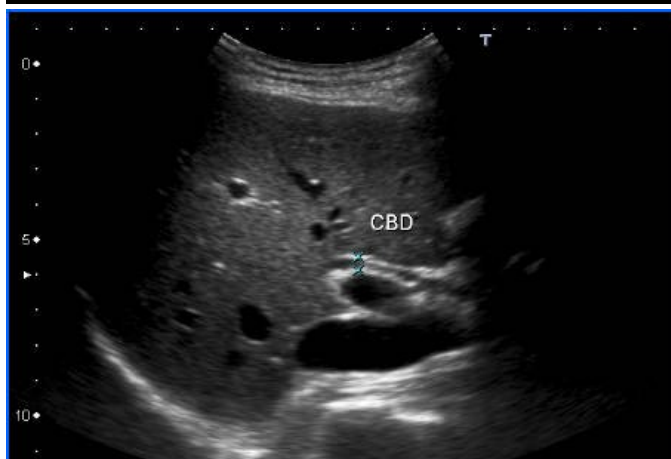
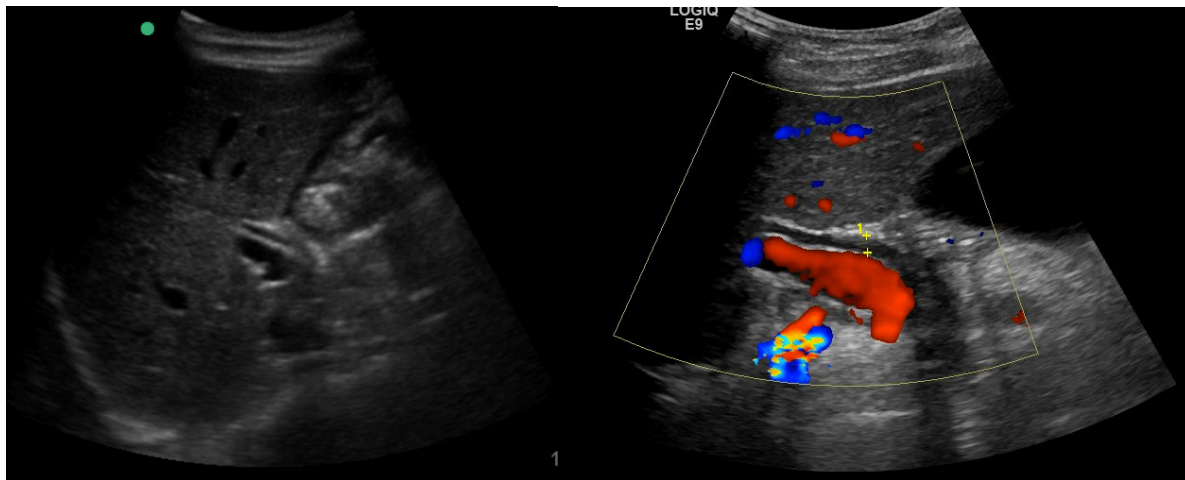


**Left: Views #9-10:** Move the transducer slightly lateral and caudal to obtain a standard FAST view of Morrison’s pouch as shown below. Take 1 still image and 1 clip.

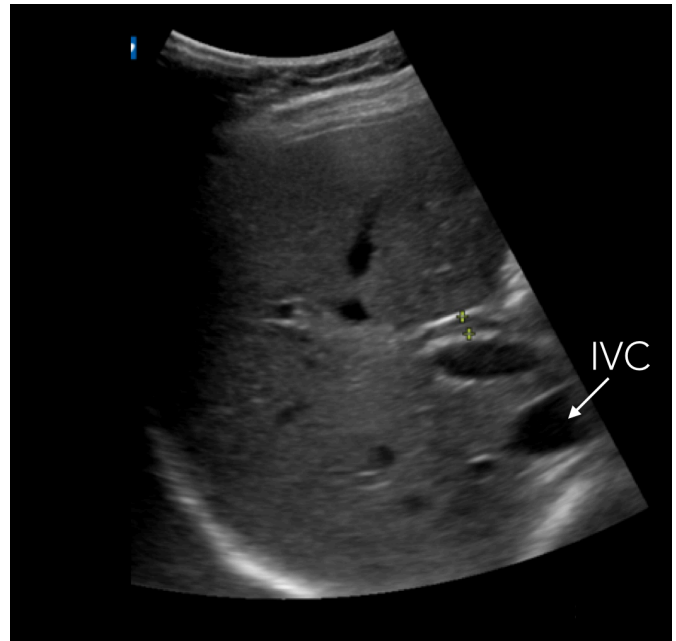
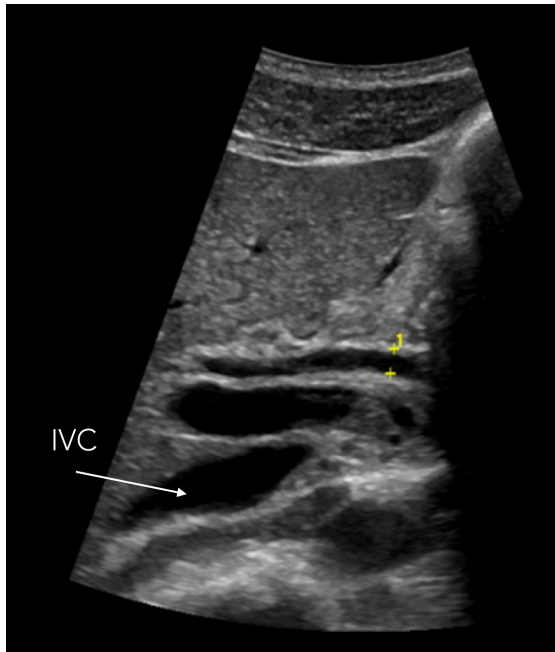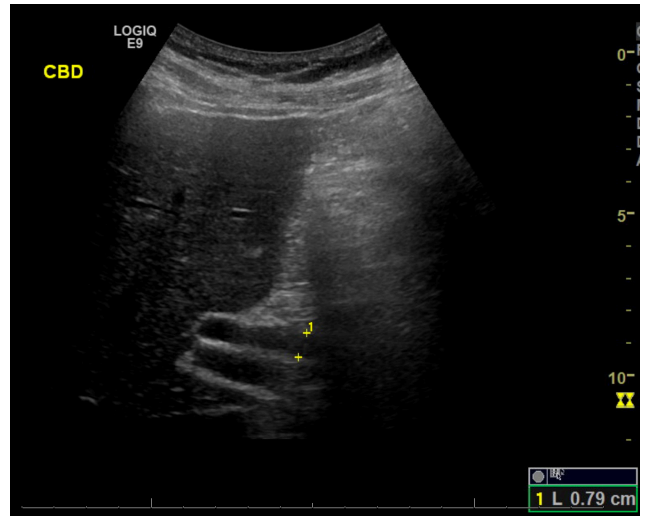
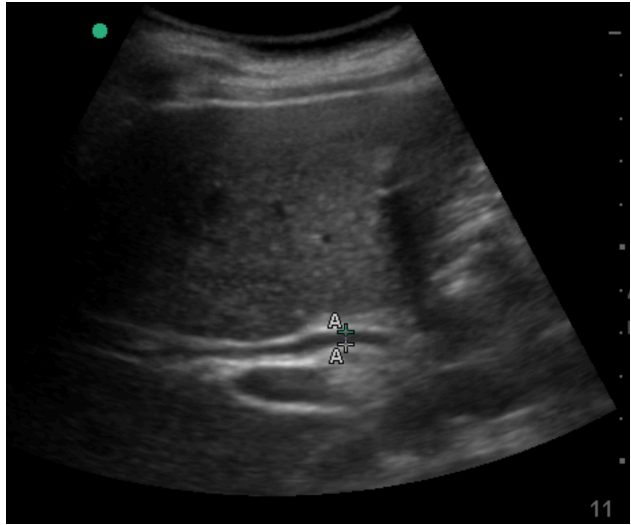
**After obtaining the above images, you will have a good overview of the RUQ and know where to locate both the gallbladder and bile duct.**

**Views #11-12:** Now it's time to find the extrahepatic bile duct. Note that because it's usually impossible to locate the exact point where the cystic duct joins with the common hepatic duct to form the common bile duct, the term "extrahepatic bile duct" is generally preferred, but CBD is also fine. This structure may be difficult to visualize in some patients and causes great gnashing of teeth among novice sonographers, but do not fear. It can usually be identified using the following steps.

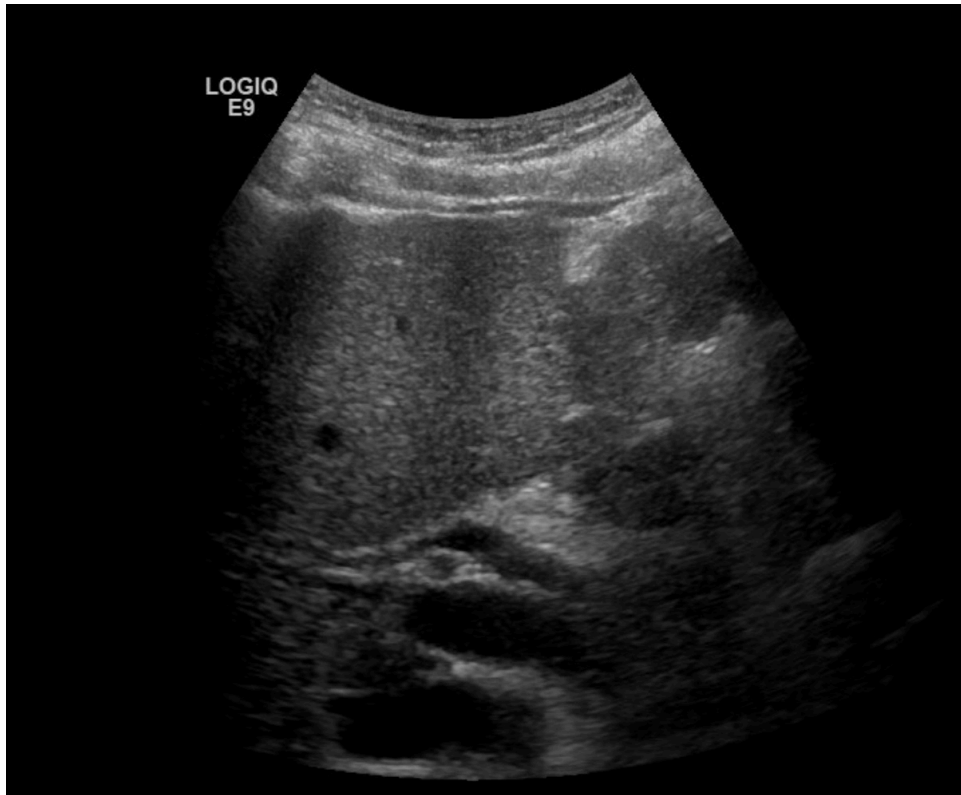First, let go of your desire to find the gallbladder. Depending on its position, you may or may not see the GB in the same view, but you must think of locating the bile duct as a completely separate exercise. Here's what to do: Return to view #1 above and find the portal vein. Then follow it along its course toward the midline as much as you can - it will become more horizontally oriented as you go. Now look for the bile duct above the main portal vein. It will appear as the top barrel of a parallel "double barrel" structure as in the images below. *You cannot claim to have found the bile duct unless you are also clearly visualizing the main portal vein beneath it.* Take at least 2 still images and use color Doppler if needed to differentiate between the CBD (will not have any color flow) and the PV. Normal extrahepatic bile duct = 4-7mm and is measured from **inner wall to inner wall** as shown.



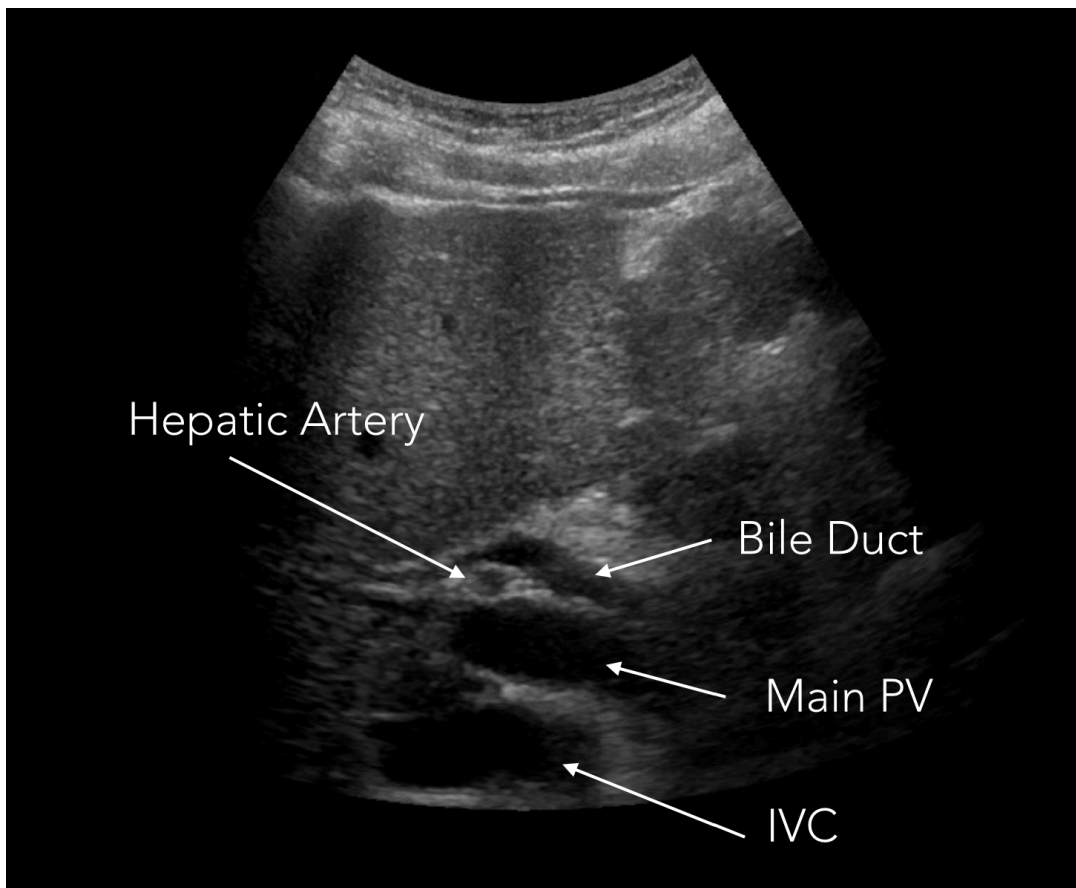
**Above and Left: Sonograms of the IVC, main portal vein, and extrahepatic bile duct.** Note the "double barrel" appearance of the bile duct stacked on top of, and running parallel to, the portal vein. The ability to find the CBD rests on an understanding of the anatomic relationship between these 3 structures, which form the classic "3-toed sloth" appearance shown in the image on the left. (bottom toe = IVC, middle toe = PV, top toe = bile duct).



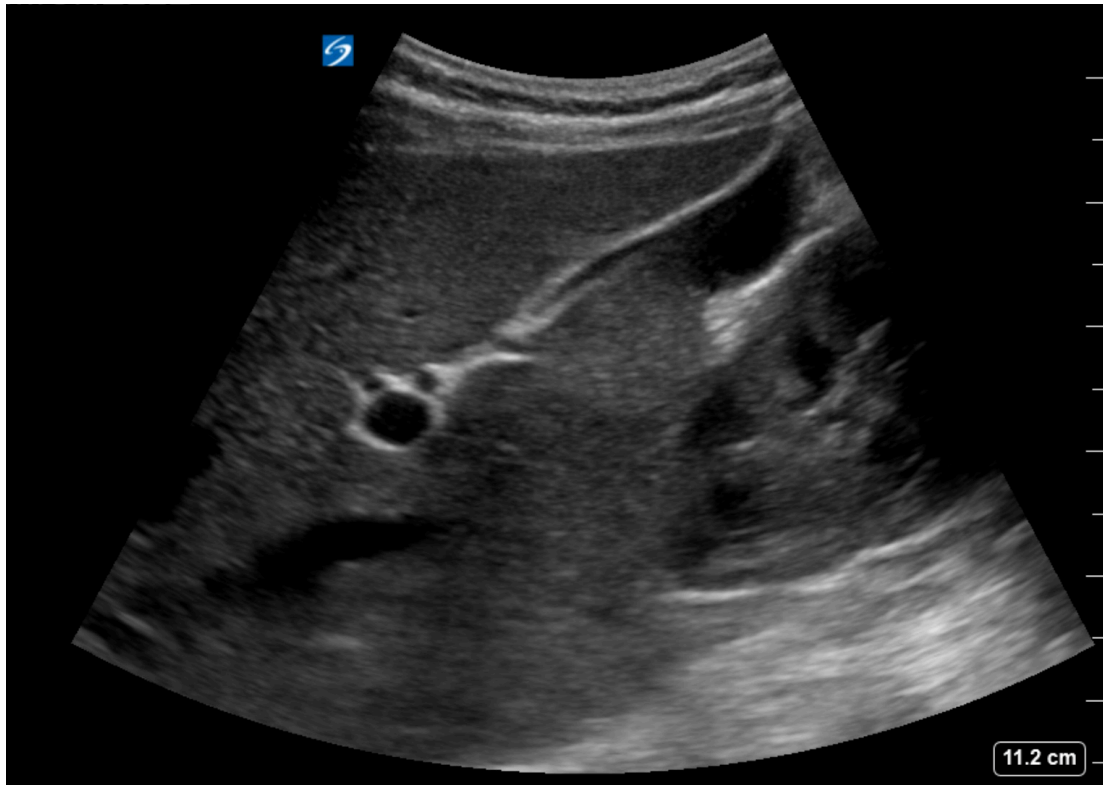
**Above: Correctly measured extrahepatic bile ducts in 4 different patients.** Note the classic “double barrel” appearance of the PV and BD in the top 2 images. The IVC is also clearly seen in the bottom 2 images and forms the posterior-most “toe” of the 3-toed sloth.



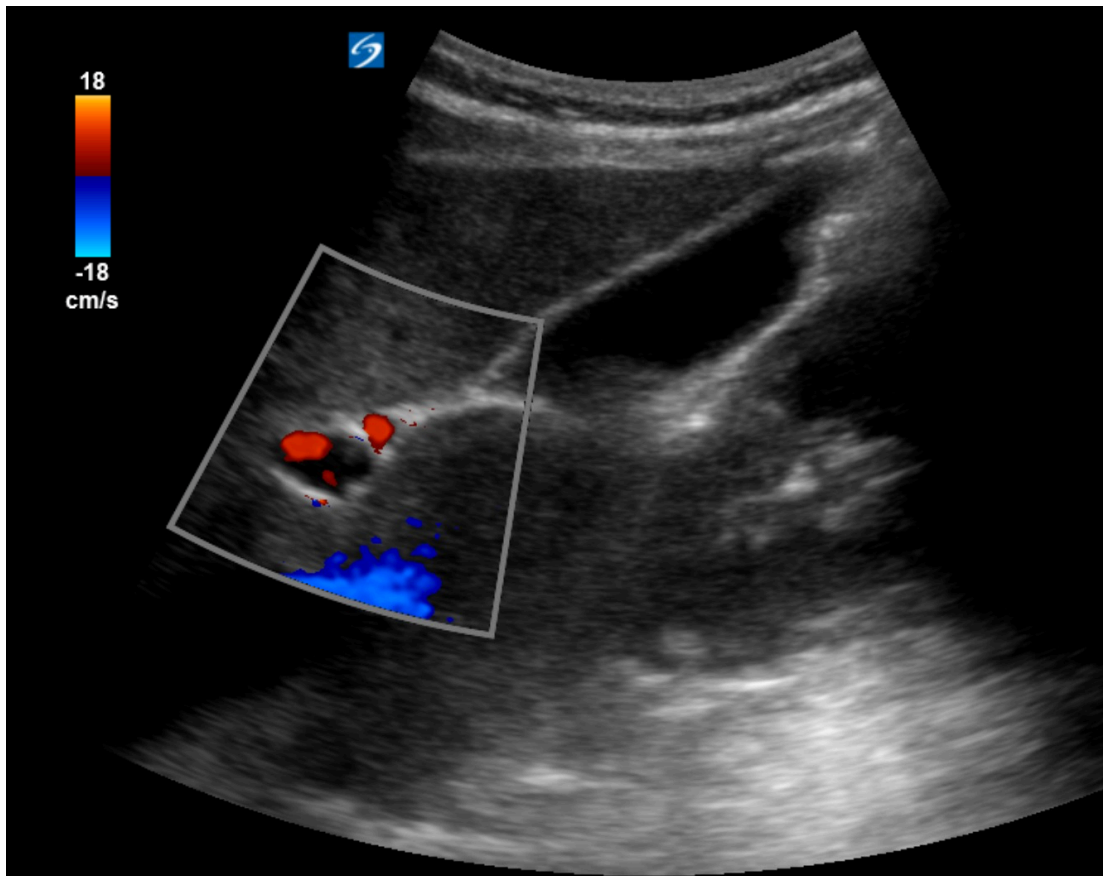
**Left: Sonogram of the IVC, PV, bile duct and hepatic artery at the porta hepatis.** Note how the hepatic artery can be seen running between and orthogonal to the bile duct and the PV, thus appearing as a circular or oval structure. The basic BD-PV-IVC arrangement (from anterior to posterior) remains the same.







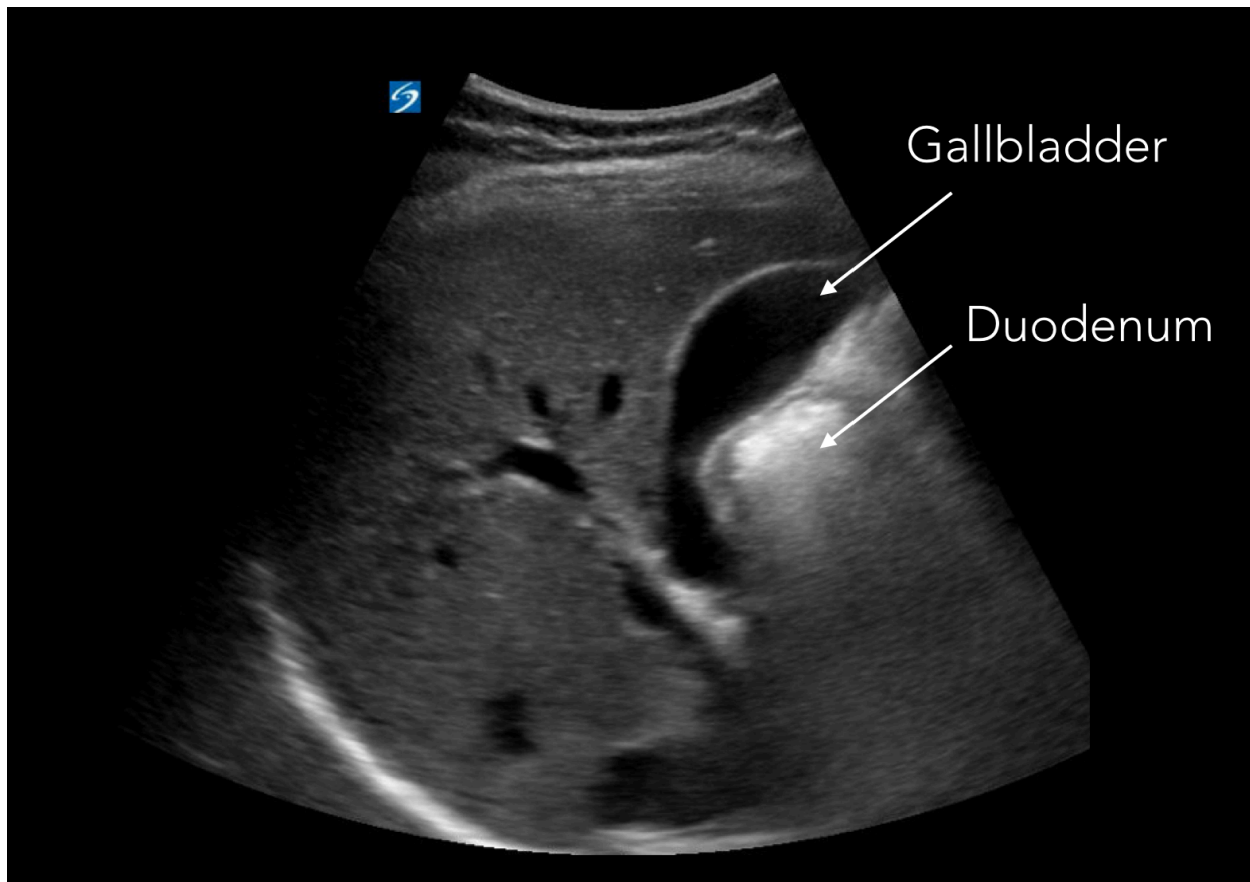
**Left: View of the PV, bile duct and hepatic artery in a transverse orientation,** obtained by rotating the transducer 90deg. This is the so called “Mickey Mouse” view; the PV is the head and the bile duct and hepatic artery are the ears.



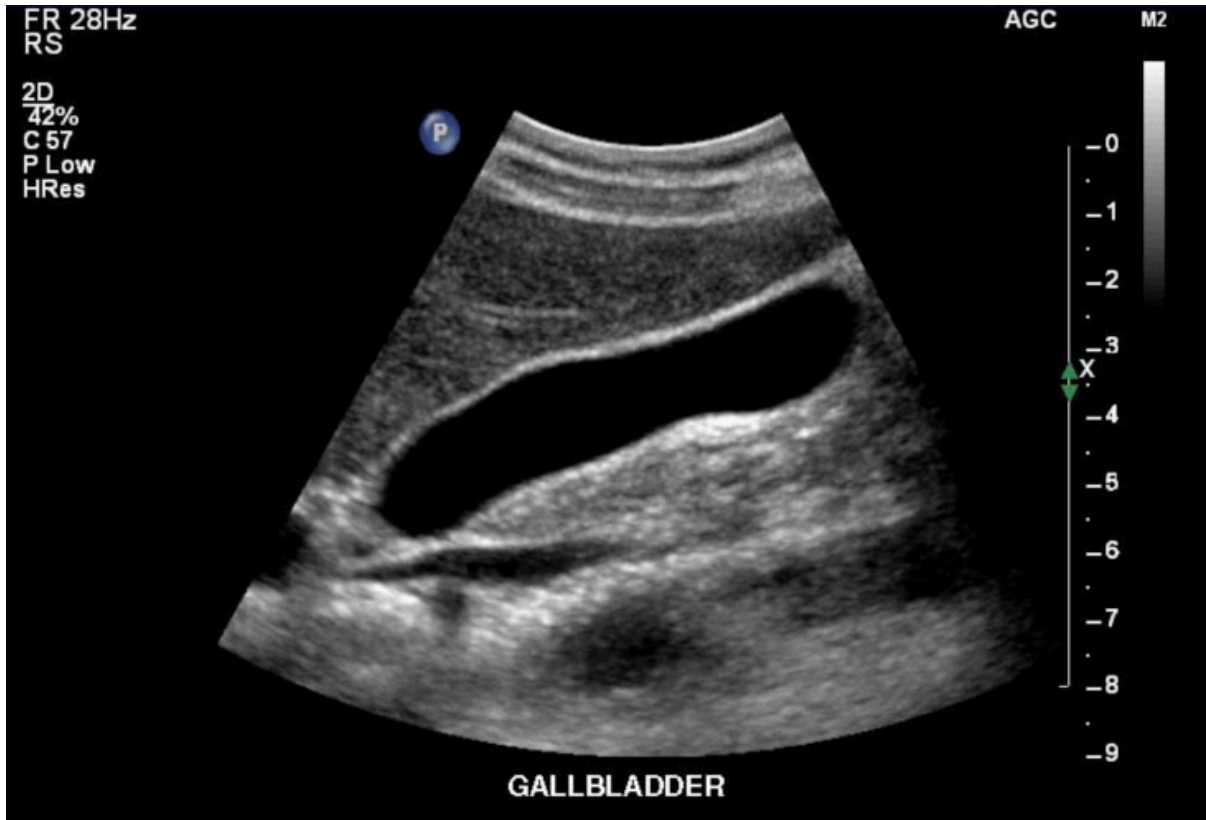**Left: color Doppler** reveals that Mickey’s left ear (right on screen) is the hepatic artery, which fills in with color flow. In general, since it allows for a longer section of the bile duct to be assessed, a view of the PV and bile duct in a longitudinal orientation as shown on the previous page is preferable to the short-axis view shown here.



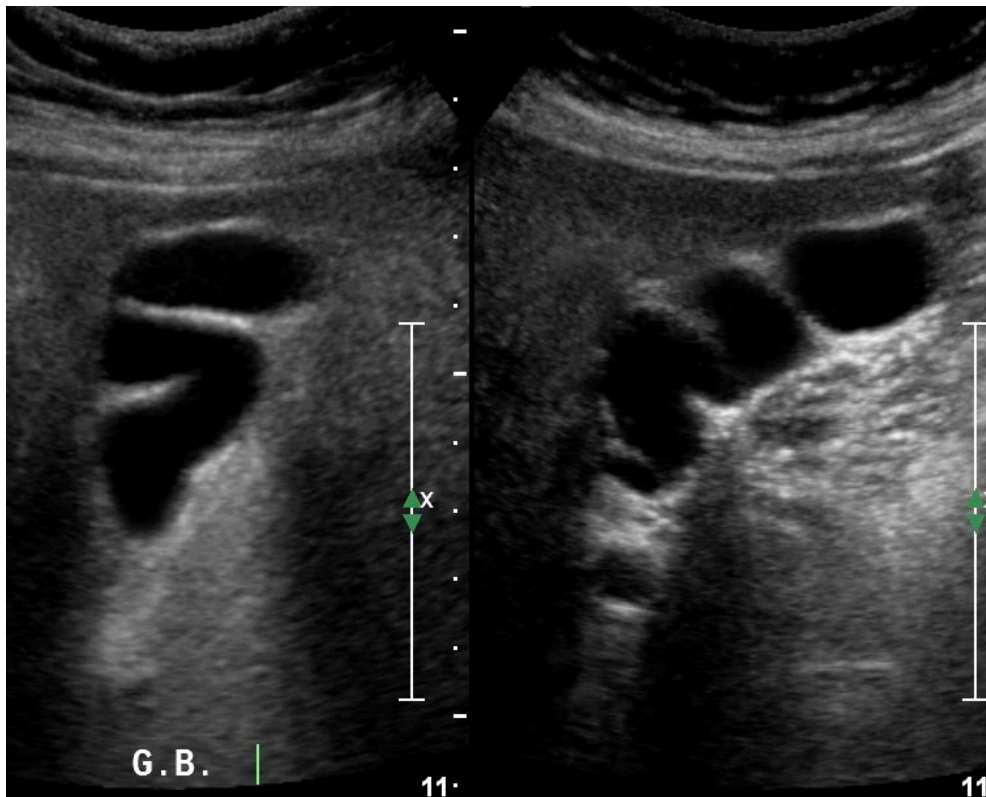
**Views 13-18:** Now turn your attention to the gallbladder itself. Obtain several still images and cine clips (at least 5) of the gallbladder without any measurements, ideally from slightly different windows and with the GB in different orientations. Look from above and below the costal margin. Try coaching the patient to take a deep breath, which will pull everything caudally and may open up your subcostal window. Also try turning the patient on their left side. Be patient and thorough. **It is absolutely essential that at least one image clearly demonstrates the GB neck.**

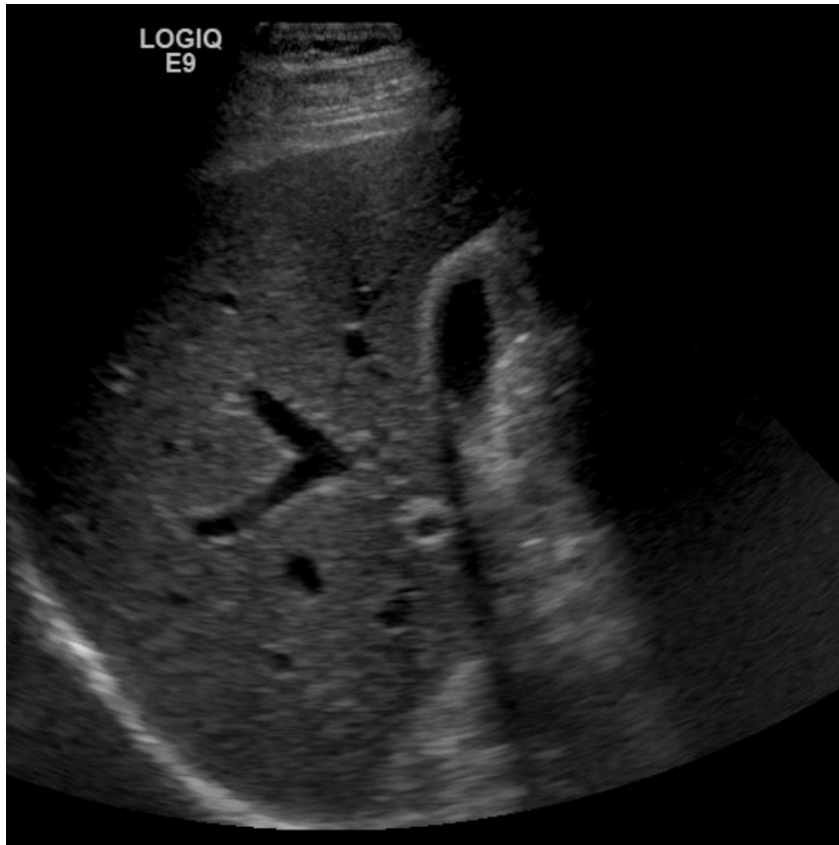


**Above: A normal gallbladder.** Note also the duodenum which appears to indent the GB wall from below. It is important to differentiate between any intraluminal gallstones and the extraluminal duodenum, which also appears echogenic and causes a characteristic “dirty” shadow due to air within its lumen. A normal duodenum may be misidentified as a large gallstone by the novice sonographer. Scan carefully looking for the crisp edge of the gallbladder wall to avoid being fooled.

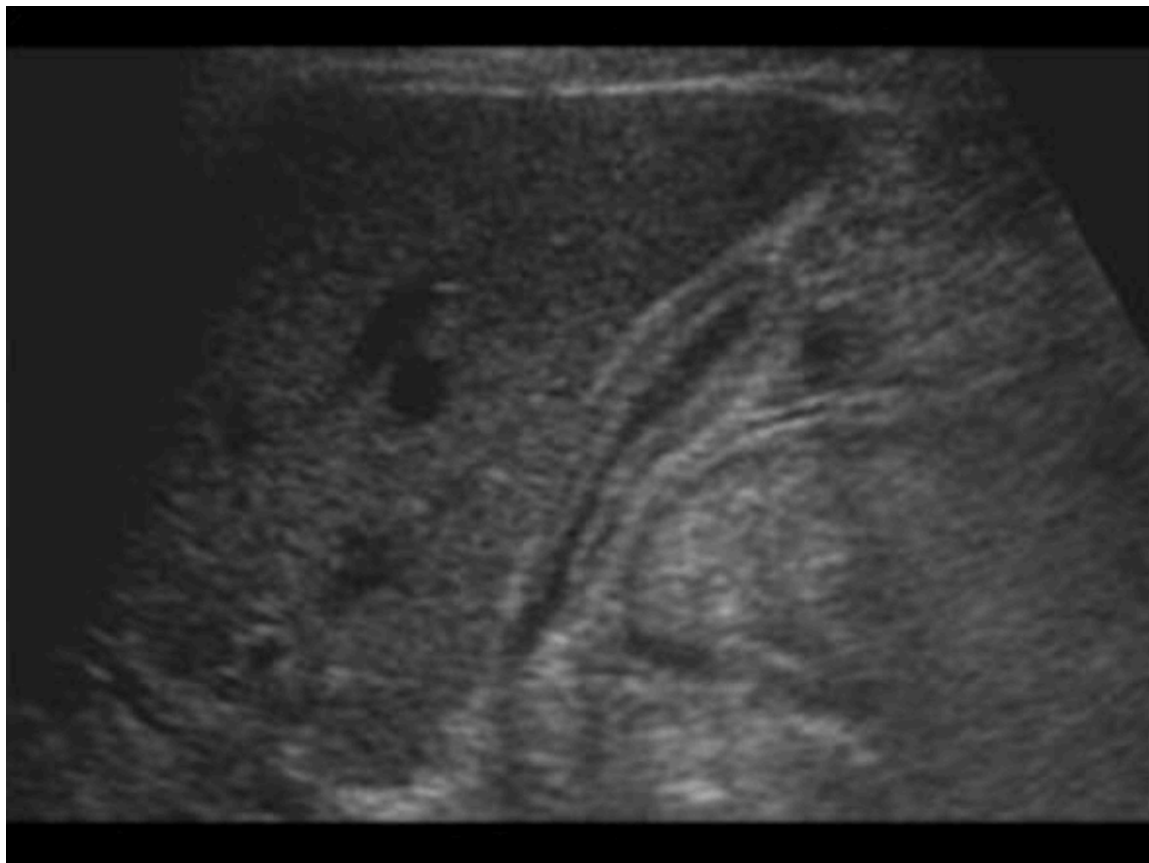

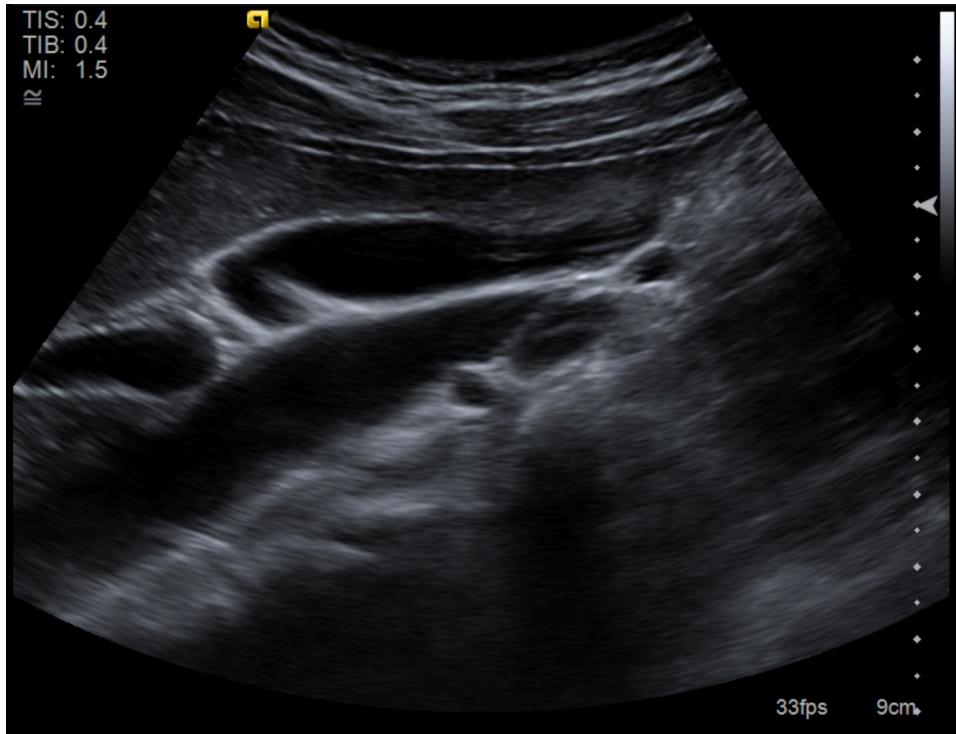
Above: A normal gallbladder. Below: Folds are common and normal.



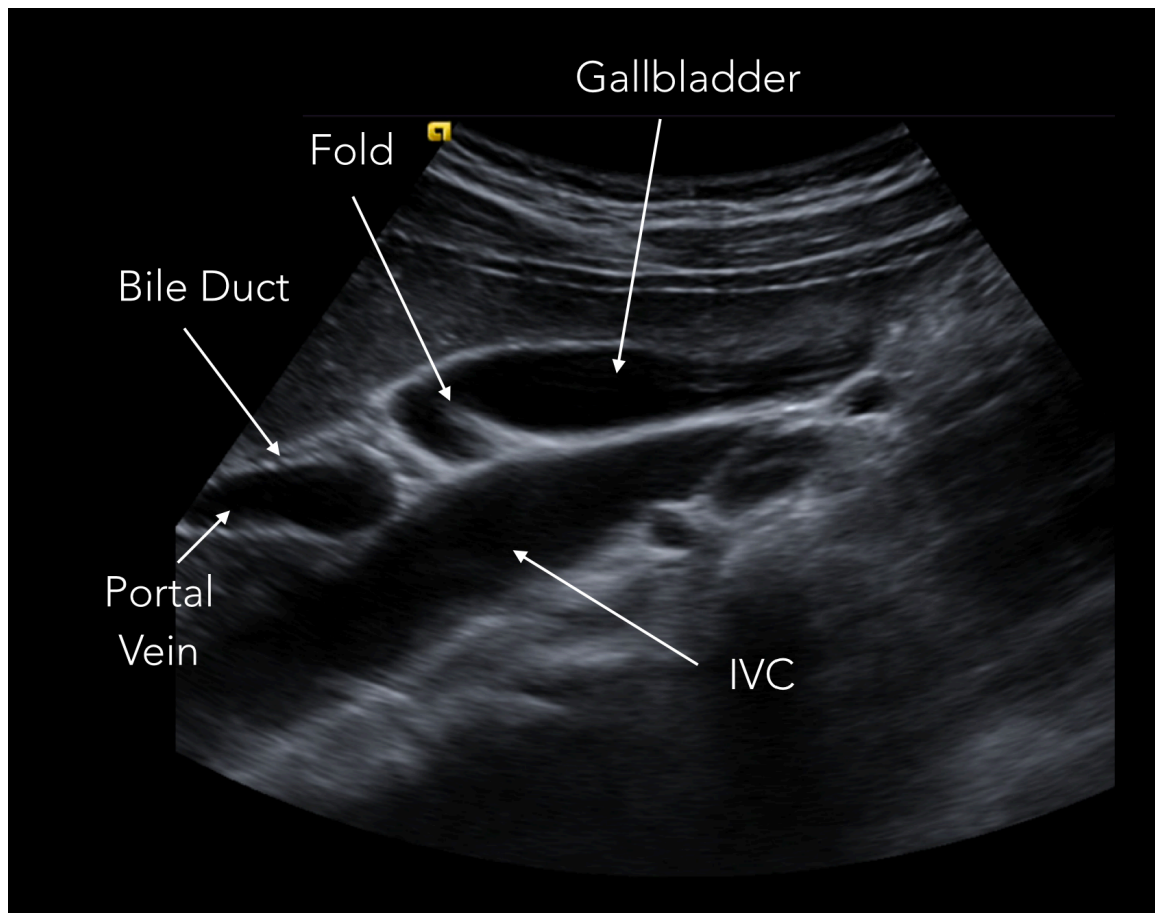


**Left and Below:**  
**Normal postprandial**  
**gallbladders.** After eating, the gallbladder becomes contracted and its wall becomes thicker. Note the shadowing off of the side of the gallbladder in the image on the left. This is edge artifact, not a shadow from a stone.



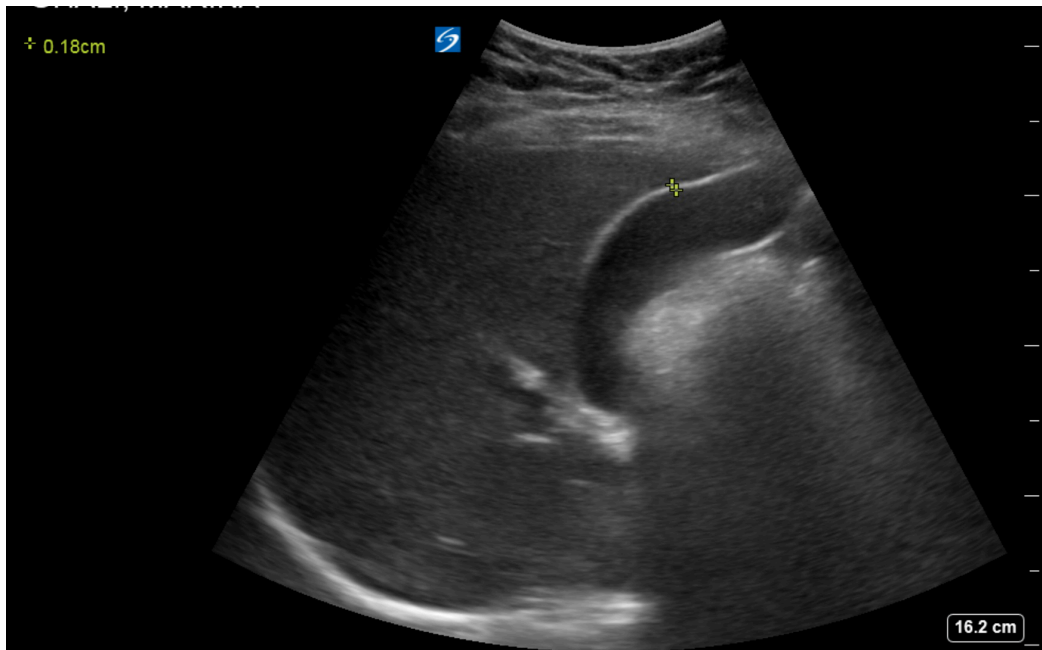
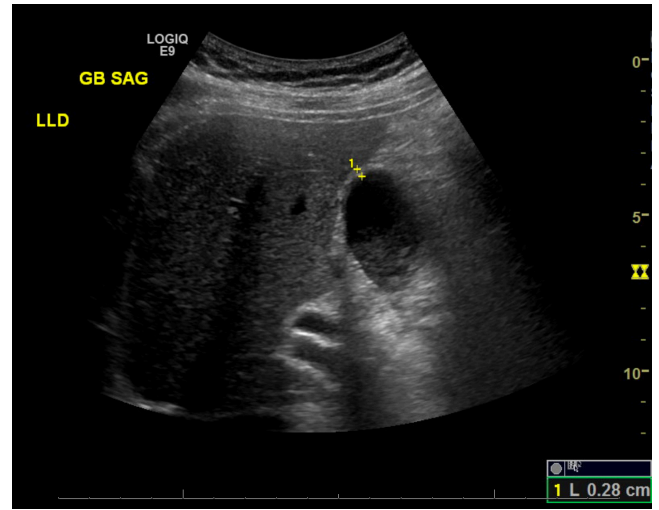
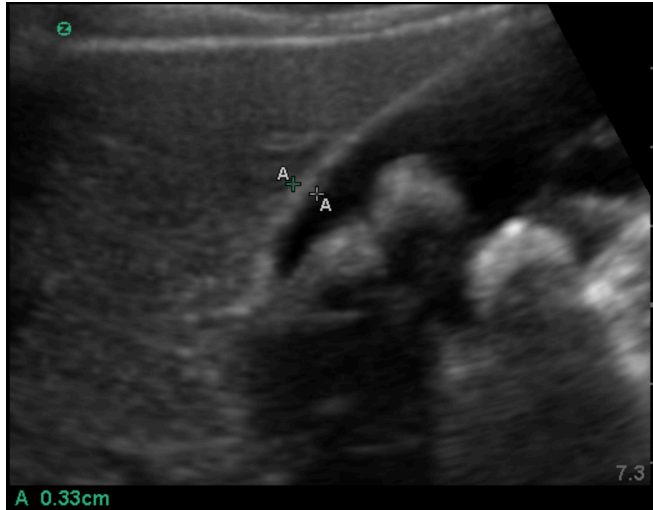


**Below and Left: A normal gallbladder.** Note that the position of the gallbladder within the RUQ can be highly variable. In this case, it's resting on top of the IVC like a harbor seal. It's common to see one or more folds in normal gallbladders.



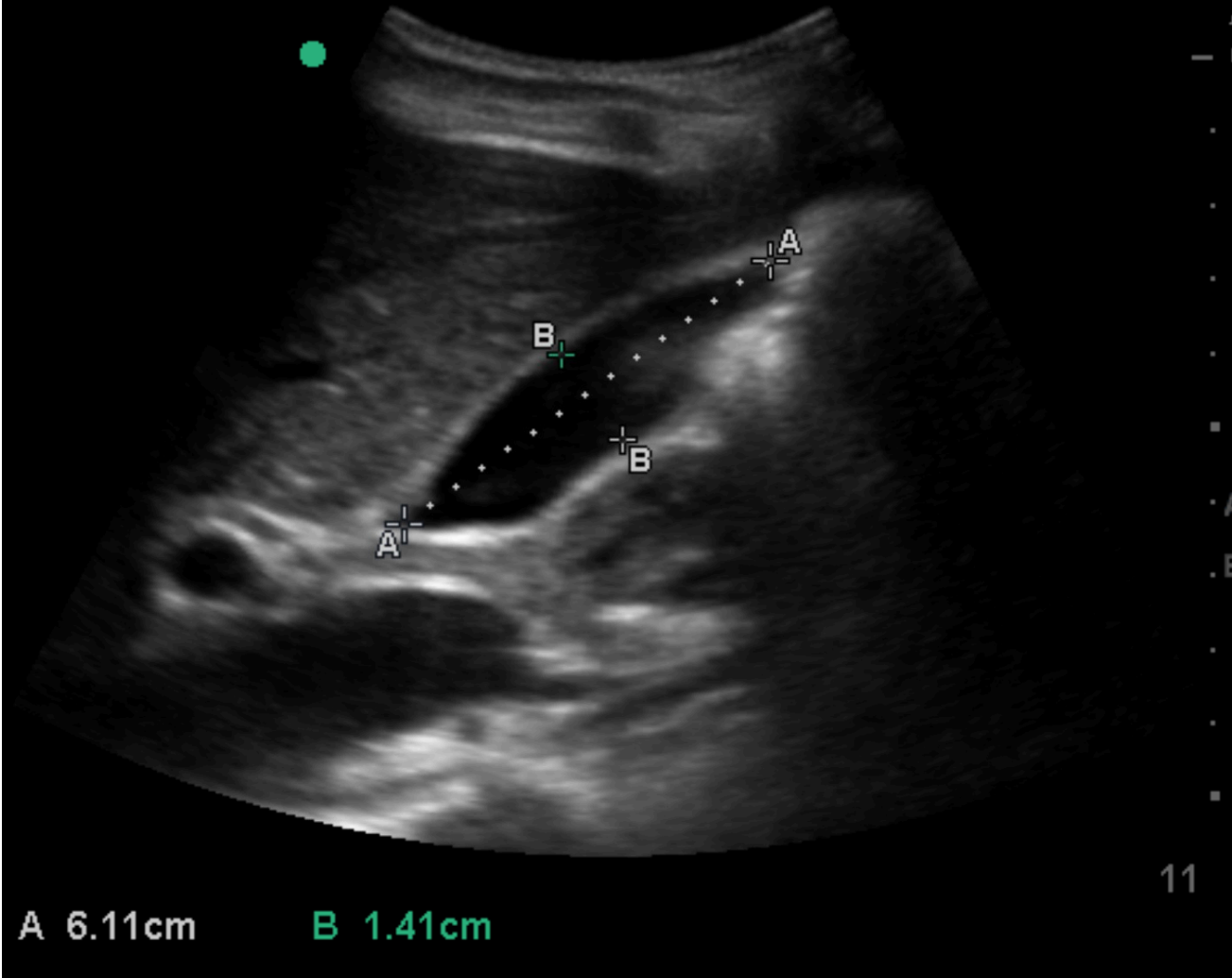


**View 16:** Obtain one still image with a clear gallbladder wall measurement. Correct technique for this is to find an area where the wall is crisp and distinct, sandwiched between the GB lumen and the liver. The wall should be measured **in the near field** as shown. Normal wall thickness = 3-4mm or less. Pericholecystic fluid and/or fluid within the GB wall itself should be noted if present.



**Above and Left:** Correctly measured gallbladder walls in 3 different patients. Note the PV and bile duct (which appears dilated) are clearly seen in the image immediately above.

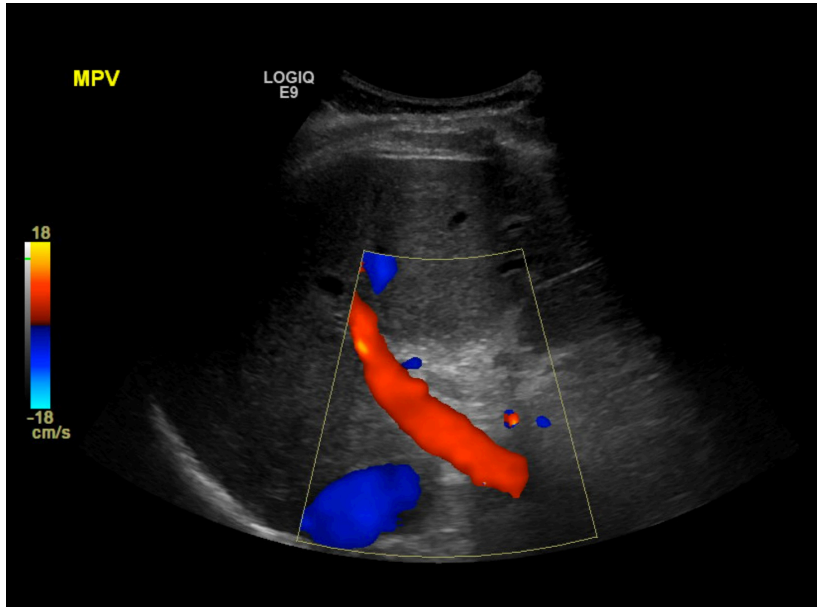
**View 17:** Obtain one still image of the gallbladder with long and short axis dimensions measured as shown below. If you can't really get a good long-axis measurement, it's not a big deal since the short-axis measurement (normal is approximately 4cm or less) is a more important marker of dilation.



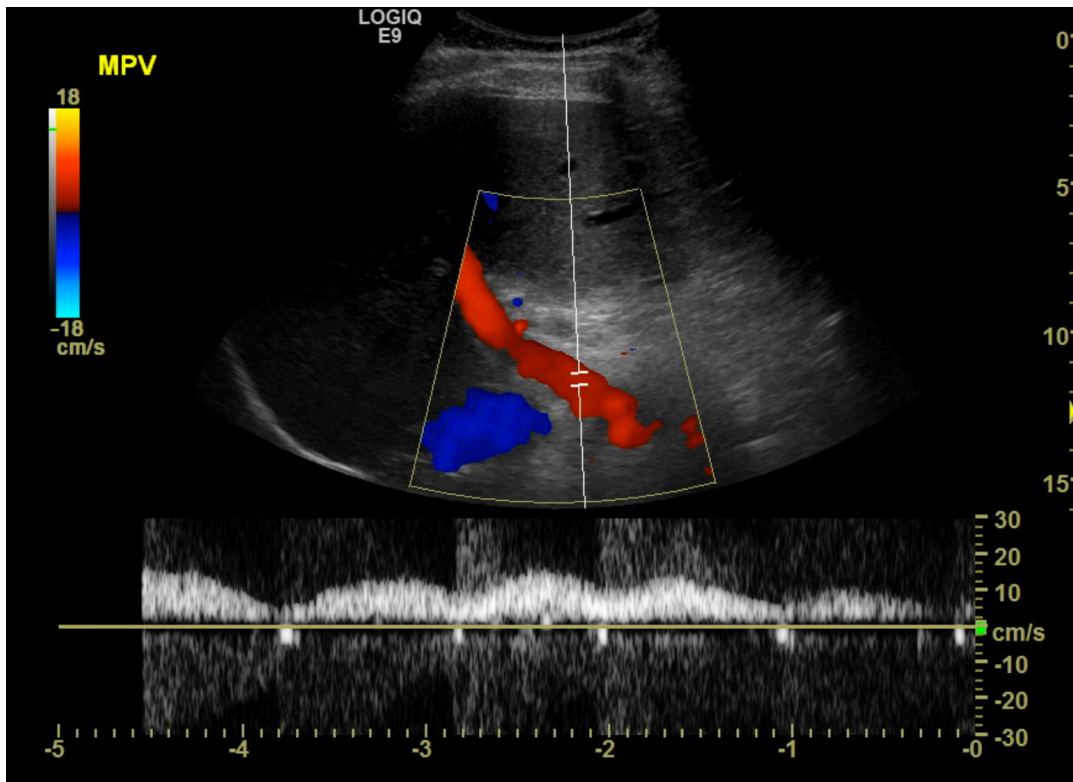


**Advanced Views – \*Not considered part of a standard POC study\***

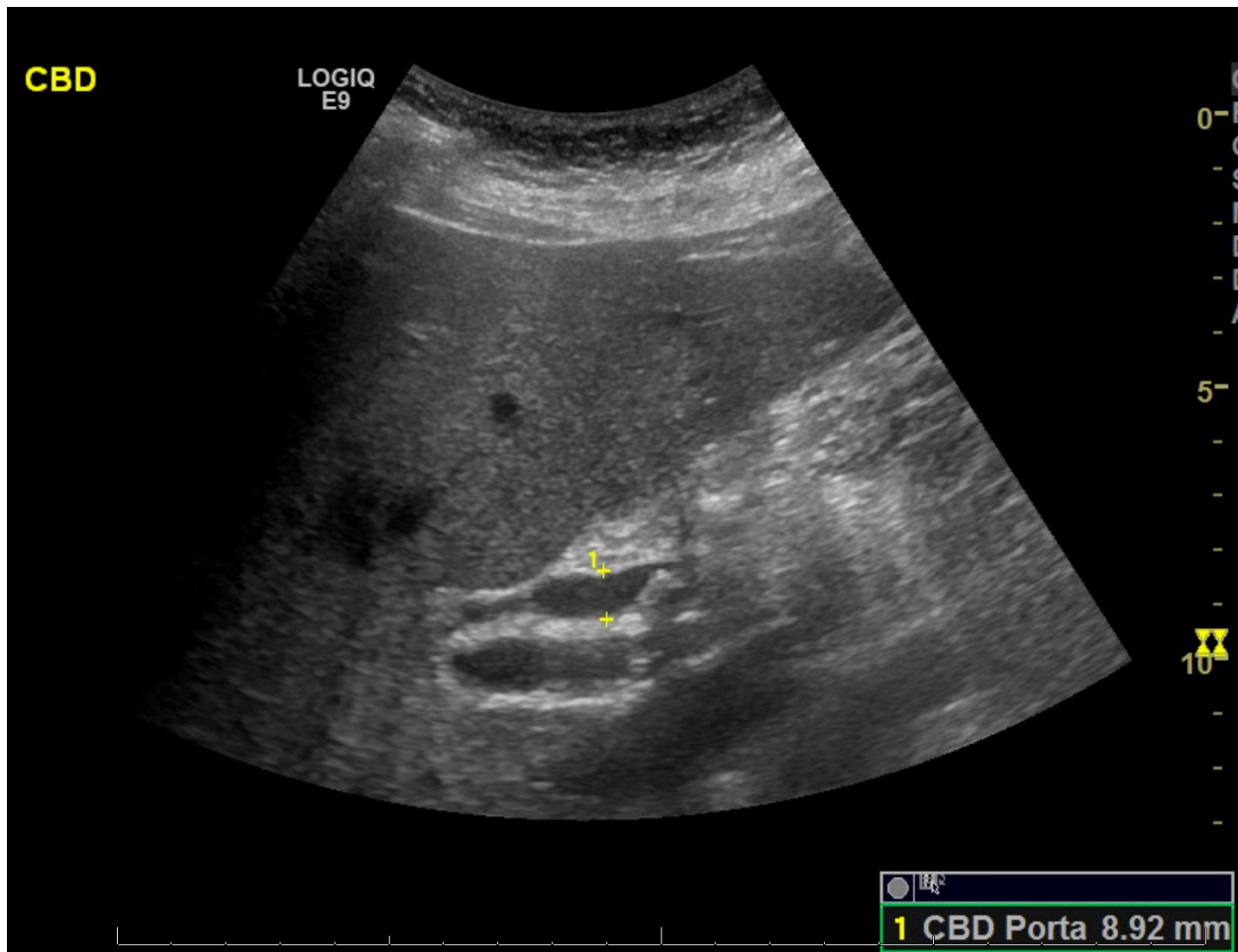
**View 18: Portal Venous Waveform.** Return to view #6 above (portal vein with color Doppler). Superimpose a pulsed Doppler gate over the portal vein to obtain the portal venous waveform. In cirrhosis, the PV velocities decrease and the waveform loses its normal sinusoidal appearance. Hepatofugal flow (flow reversal in the portal vein) is seen with severe portal hypertension after portal-systemic collaterals have opened up.



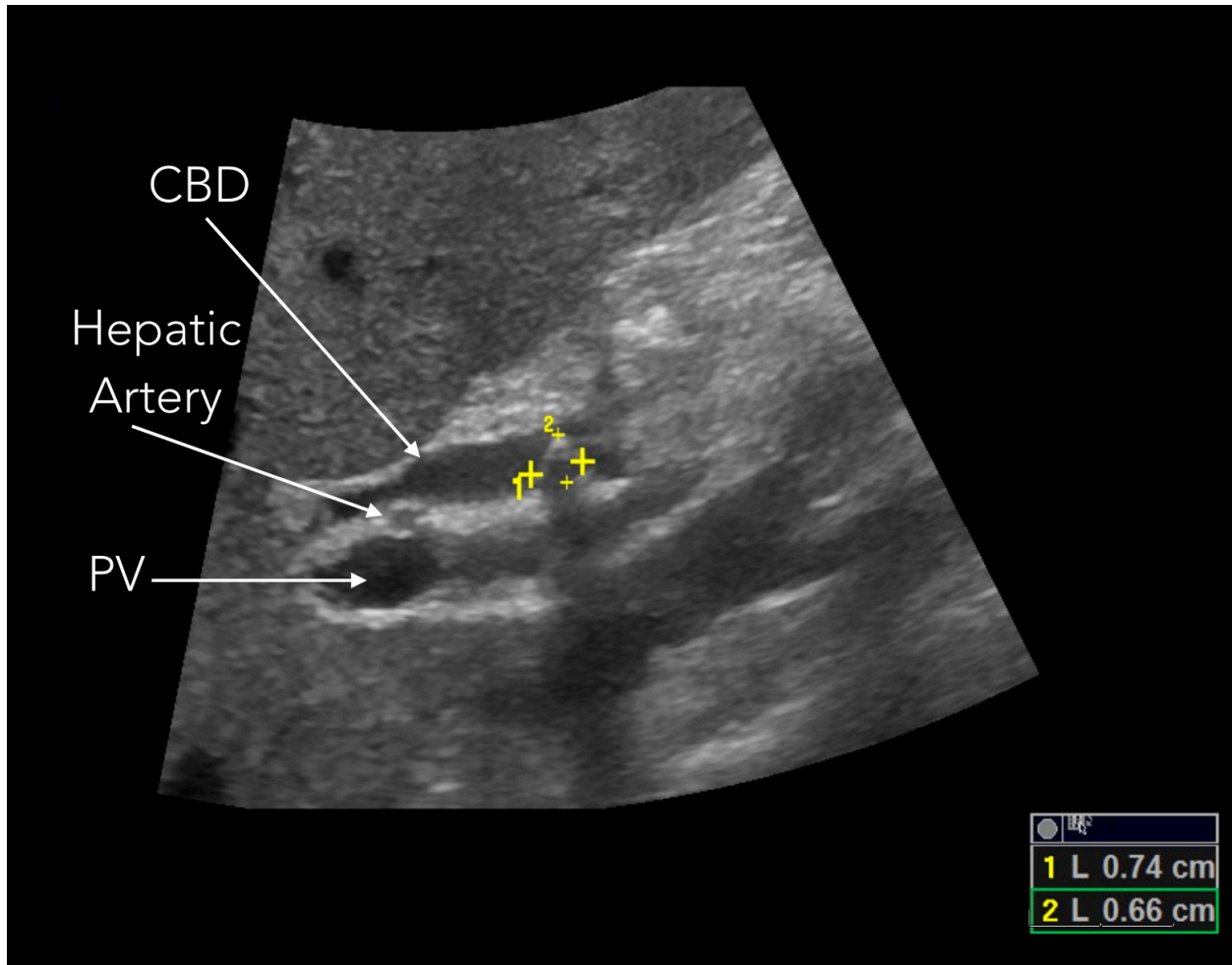
**Left and Below: Sonogram with Color Doppler only (left) and with color and pulsed-wave Doppler over the main PV.** Decreased PV velocity and flattening of the waveform are seen with chronic liver disease.



**View #19: Distal CBD.** If there is suspicion for choledocholithiasis, attempt to directly visualize the impacted stone(s) by following the CBD as distal (nearest to the ampulla of Vater) as possible. This will usually require you to place the transducer at or nearly at the midline below the xiphoid (as if you were obtaining a subcostal view of the heart) with the transducer angled slightly cephalad and towards the patient's right side. Using a L lateral position and coaching the patient to take a deep breath may be helpful. Again, you are looking to find the main portal vein and then identify the CBD just anterior to it. Stones in the CBD should cast an acoustic shadow, just as they do within the gallbladder.



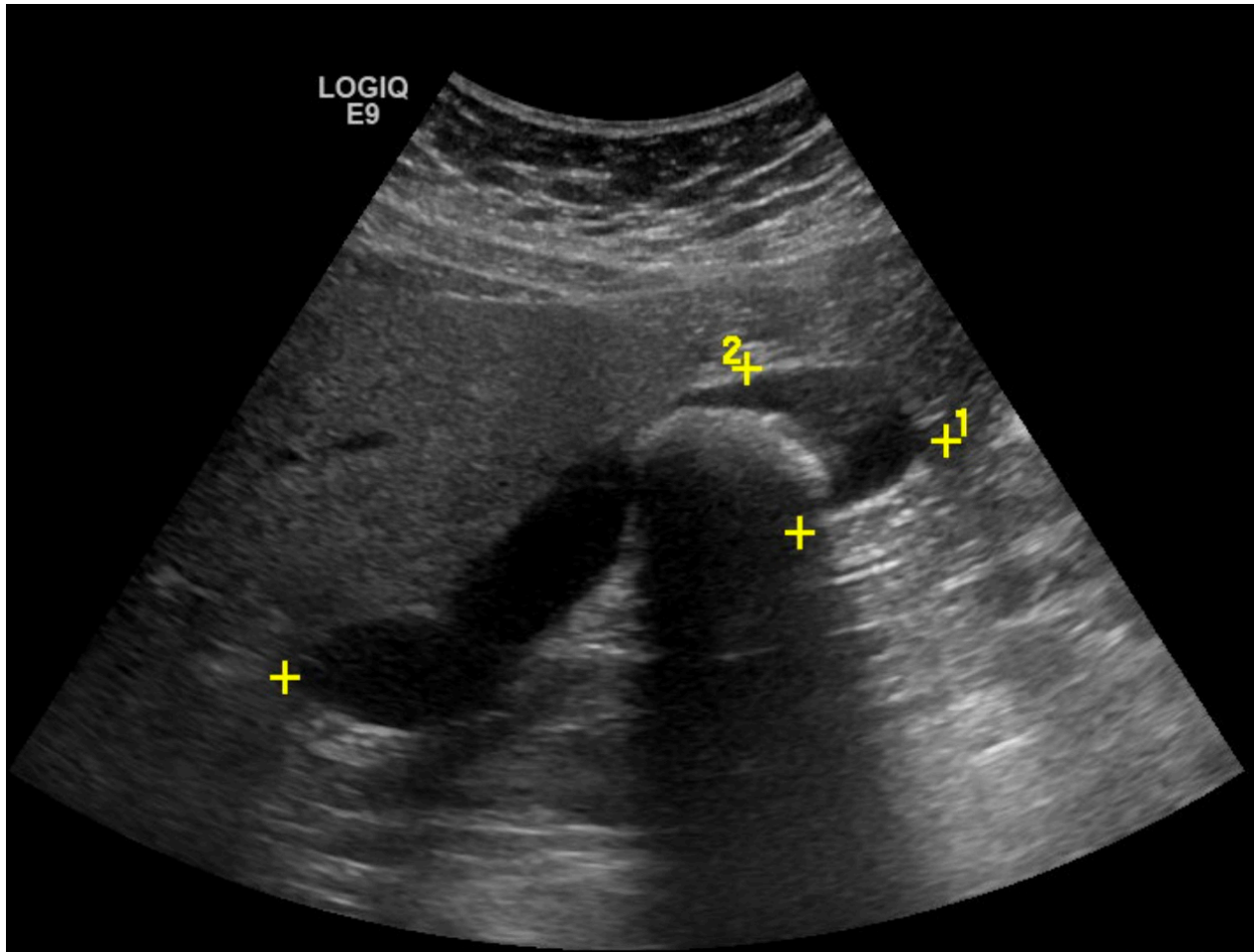
**Above: Main PV and bile duct at the porta hepatis.** There is a round, echogenic structure in the CBD which casts a subtle shadow. Note the extrahepatic biliary dilation (CBD = nearly 9mm).



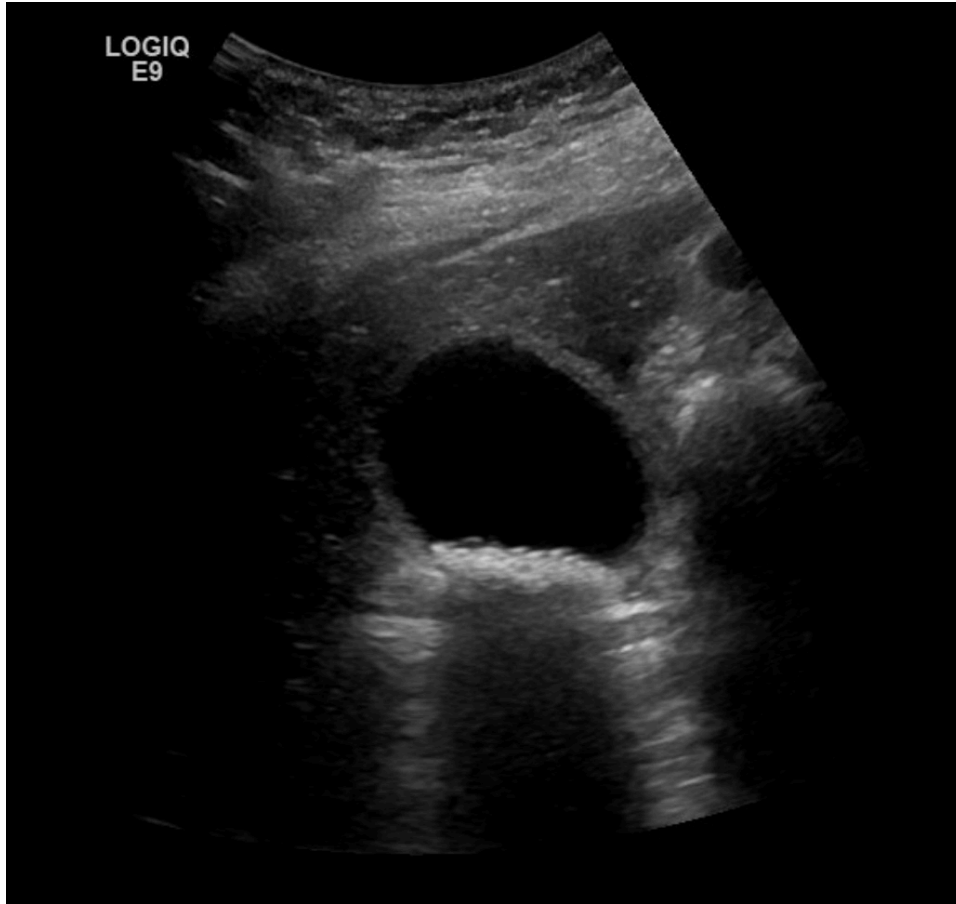**Above: Same patient, now with a 6x7mm stone clearly identified within the bile duct. Note the acoustic shadow.**

## Identifying gallstones

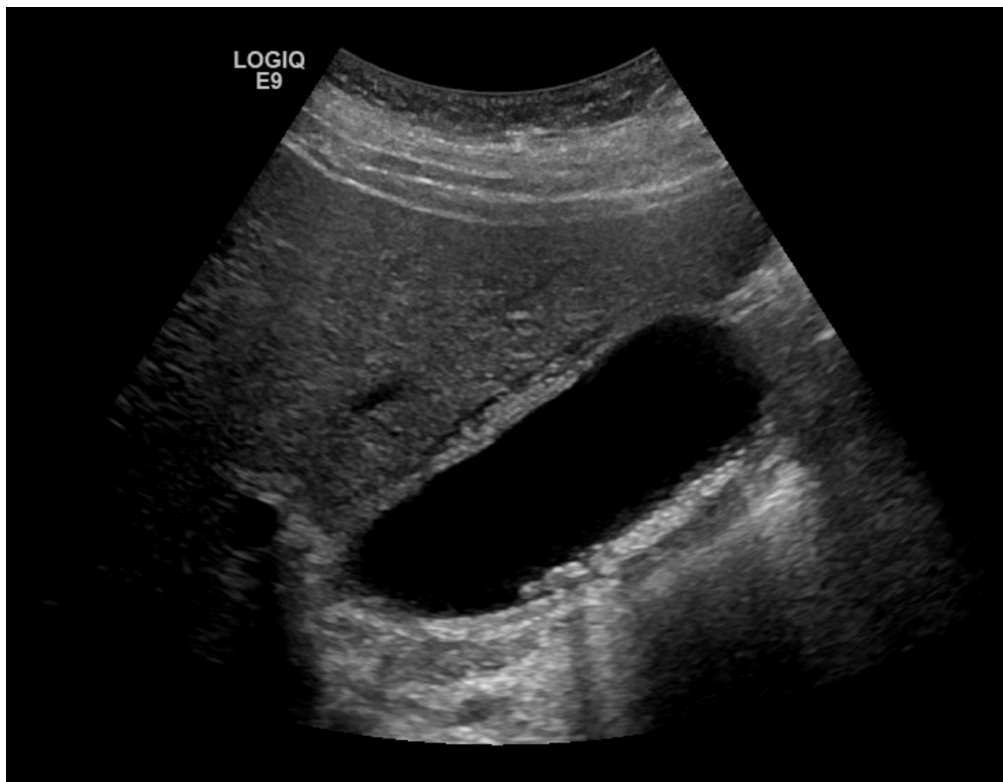
Gallstones have the following characteristics: 1) round, 2) echogenic, 3) gravity dependent, 4) shadowing. They can be single or multiple, come in any size, and be located in any part of the gallbladder. The ones that are most often missed on our ED studies are small and hidden in the gallbladder neck. As discussed above, it's also important to recognize that the air in the 2<sup>nd</sup> portion of the duodenum, which is often immediately adjacent to the gallbladder, may have a similar appearance.



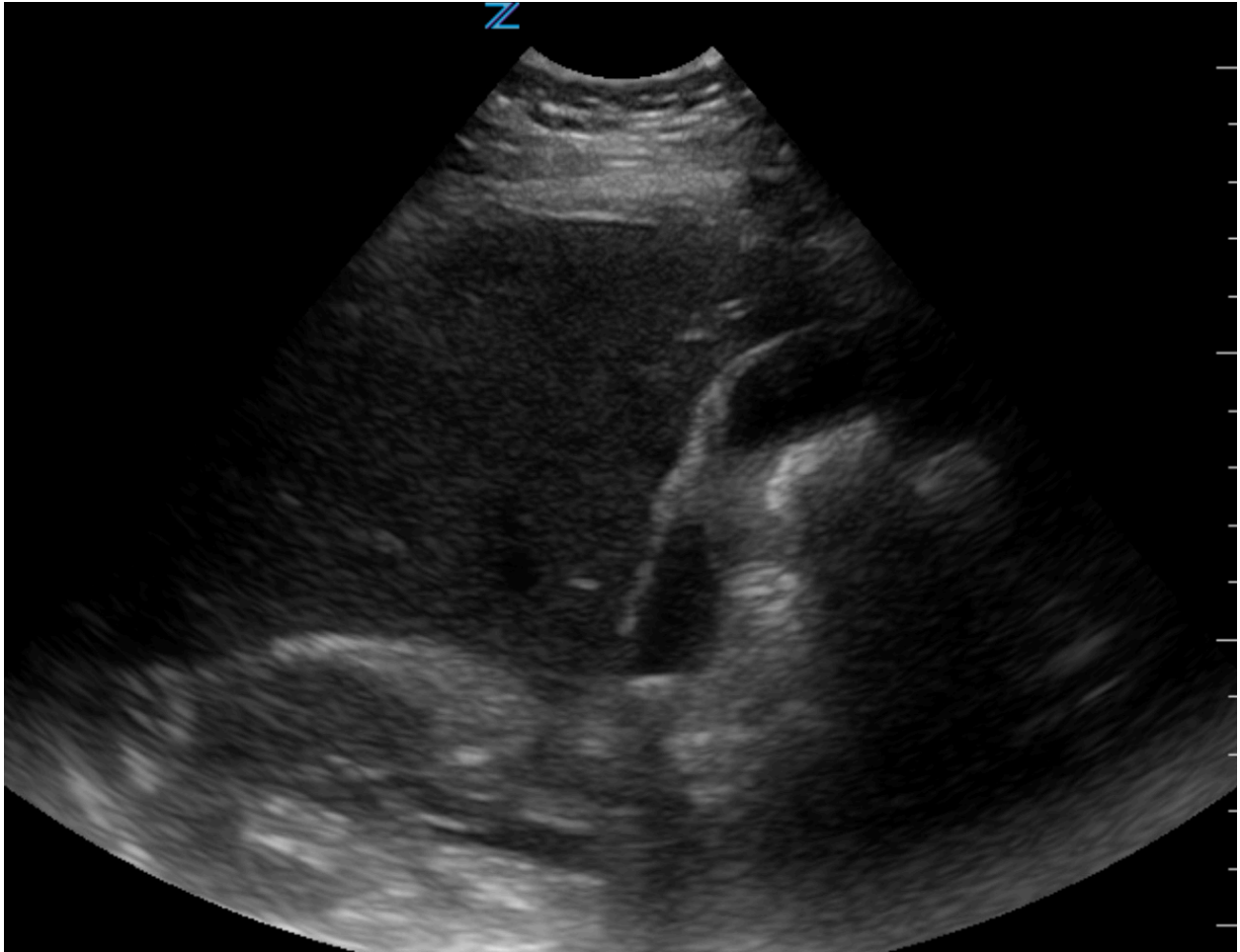
**Above: A single large stone in the body of the gallbladder.**



**Left: Multiple small gallstones.**

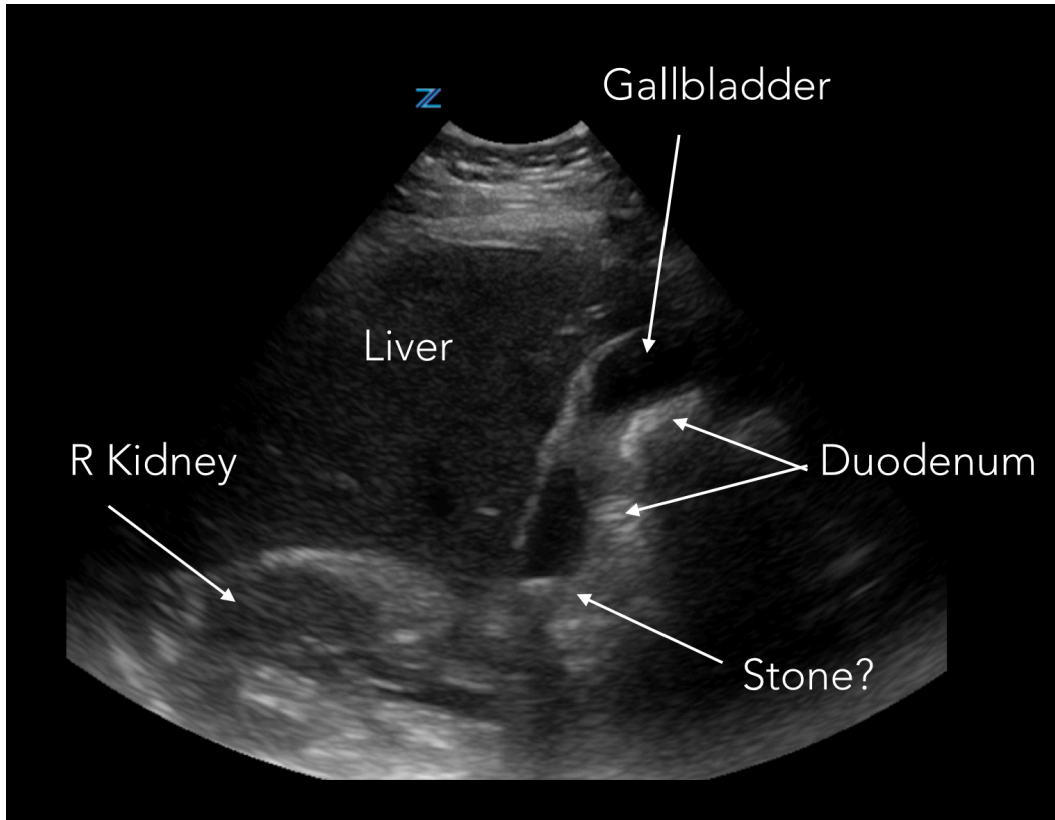


**Above: A long-axis view of the same patient.** In addition to the multiple small gallstones, there is evidence of gallbladder wall edema and possibly pericholecystic fluid along the anterior aspect of the GB wall.

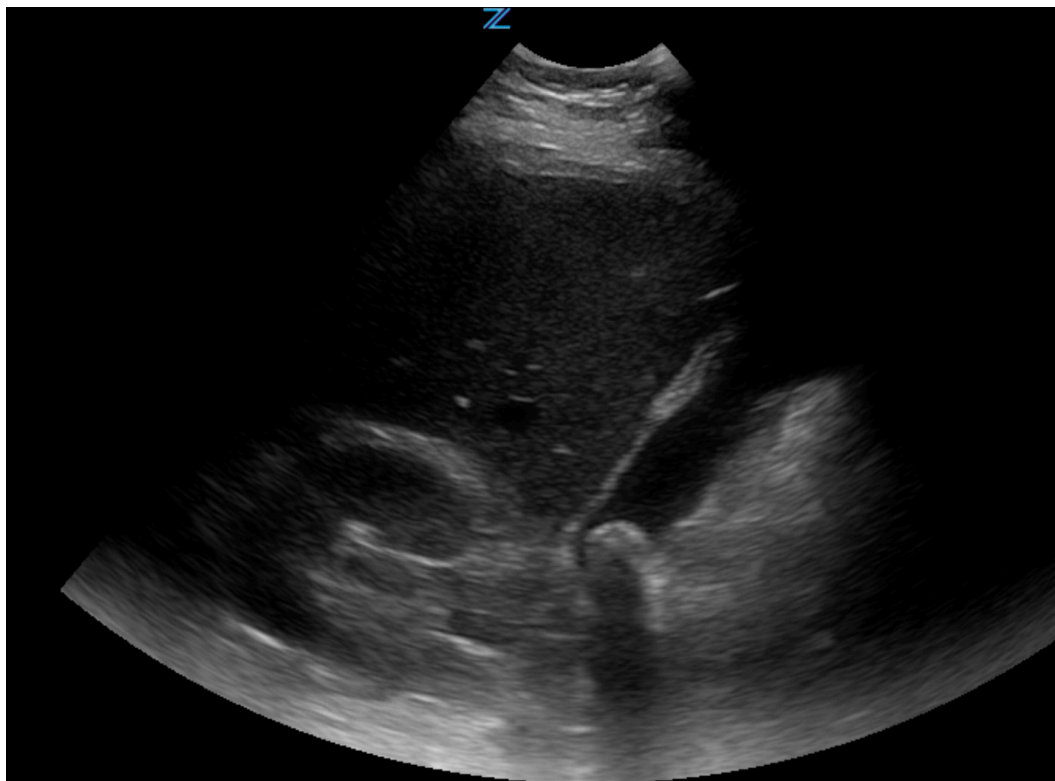


**Above: Does this patient have stones?**





**Left: Image with labels.**



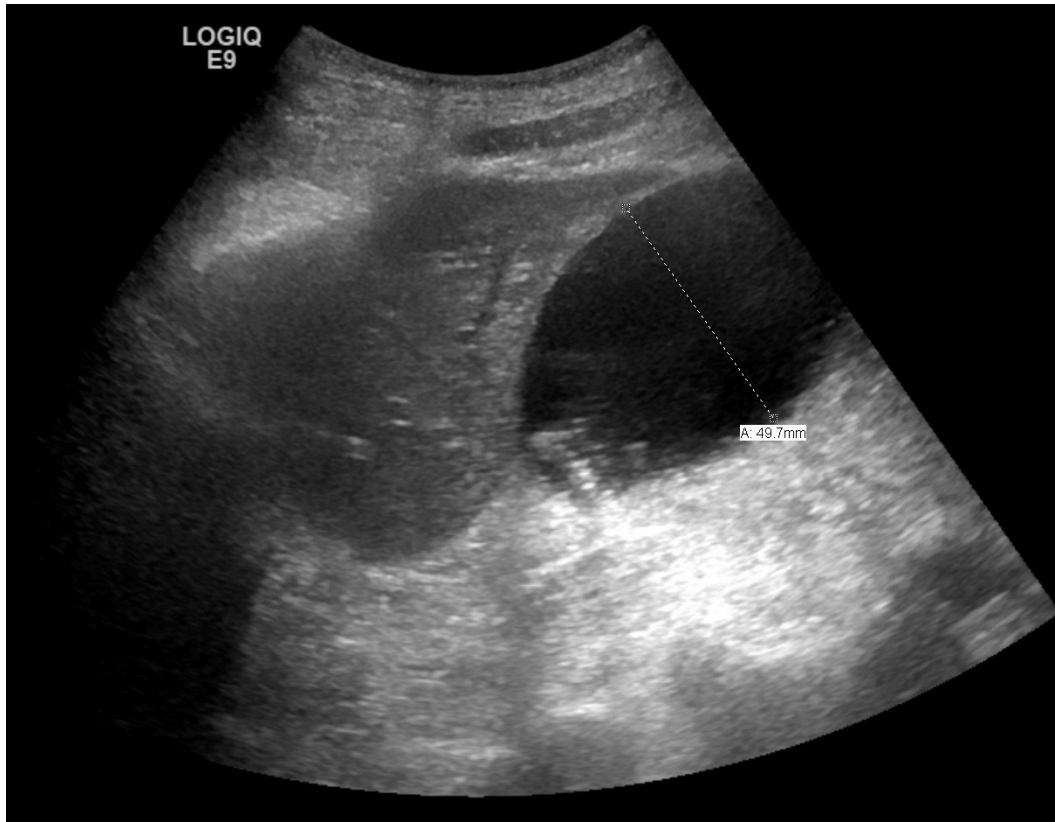
**Answer: Yes. There is a single, ~1cm stone in the GB neck.** Careful inspection reveals that what had appeared to be at least additional 2 additional stones in the body of the gallbladder were in fact just shadowing from duodenal air. Obtaining this view required L lateral decubitus positioning and a deep breath hold.

## Sonographic Findings in Cholecystitis

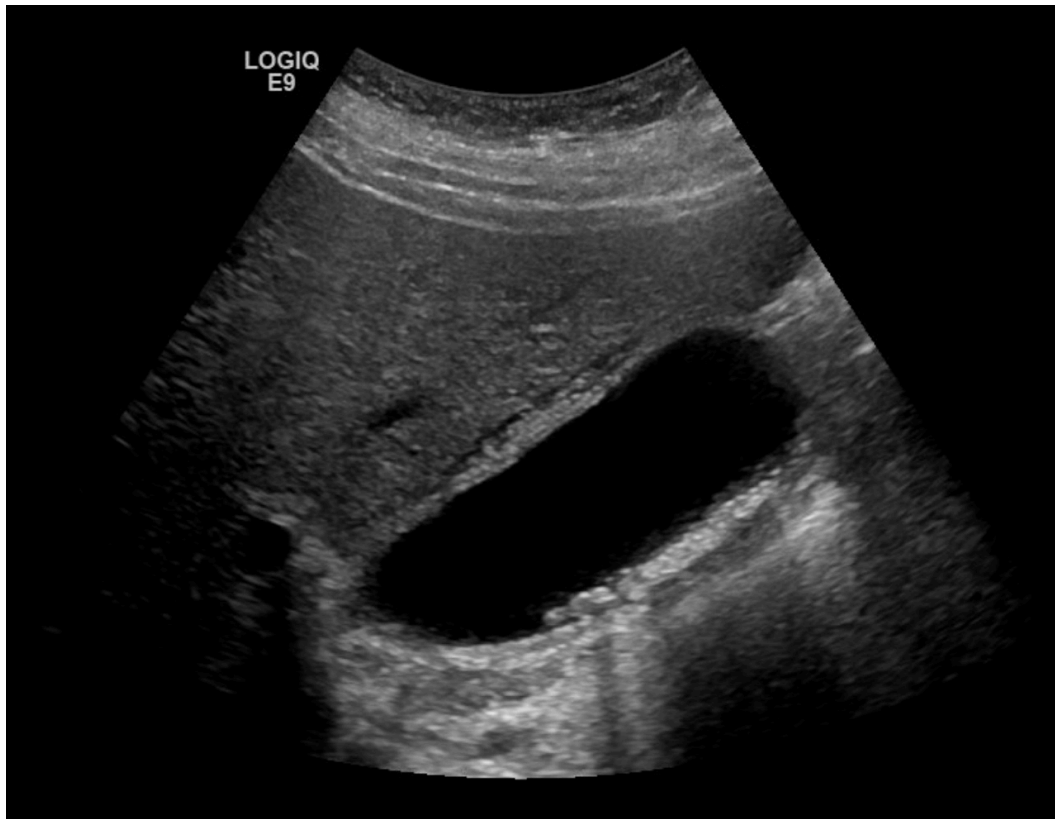Diagnosing acute cholecystitis with ultrasound is challenging for several reasons. First, patients may lack classic findings, especially early in their course. Second, many of the sonographic features are nonspecific; for instance, thickening/edema of the gallbladder wall may be seen in cirrhosis or CHF. Similarly, in patients with longstanding stones and some degree of chronic cholecystitis, it may also be difficult to sort out acute vs old findings. Finally, it may be technically challenging to identify stones at the GB neck, as discussed above. For all these reasons, it should be remembered that acute cholecystitis remains a clinical diagnosis, and thus the imaging should always be considered as playing a supporting role.

That said, the following sonographic findings should be sought in cases where acute cholecystitis is suspected clinically:

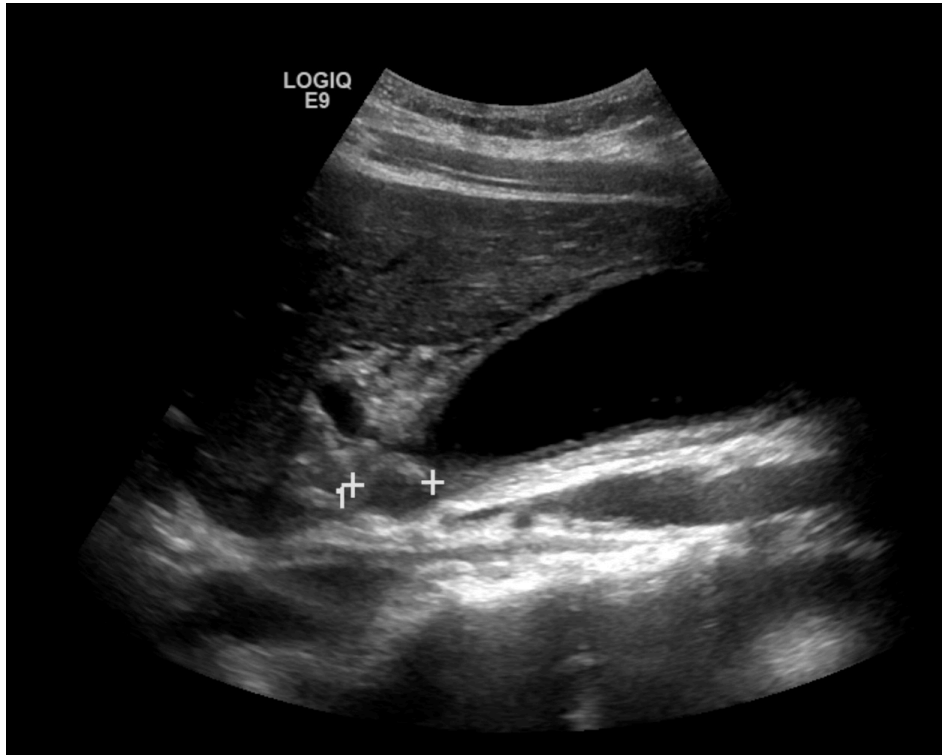
- 1) **Gallstones.** Generally considered a prerequisite for this diagnosis. Acute acalculous cholecystitis is rare in otherwise healthy patients but should be considered in elderly/debilitated pts who are not eating, those on TPN, etc.
- 2) **Gallbladder tenderness** (i.e. a Sonographic Murphy's sign).
- 3) **Gallbladder distention** (>4cm short axis). Especially if coexisting with tenderness and a stone at the GB neck. These 3 findings together should be considered highly suggestive of acute cholecystitis.
- 4) **Wall thickening/edema.** May be a late finding. Since the venous drainage of the gallbladder is to the IVC, wall edema can be seen with other conditions associated with elevated CVP (CHF, pulmonary HTN with R heart failure, etc) and in conditions associated with low protein states, like cirrhosis.
- 5) **Pericholecystic fluid.** As with wall thickening, may be a late finding.
- 6) Although NOT a feature of acute cholecystitis, **bile duct dilation** should always be assessed. If present, this suggests either an alternative diagnosis (eg choledocholithiasis or some other cause of biliary obstruction) OR a co-existing CBD stone which needs to be addressed before operative management (ie, requires either pre-op ERCP or intra-op cholangiogram).



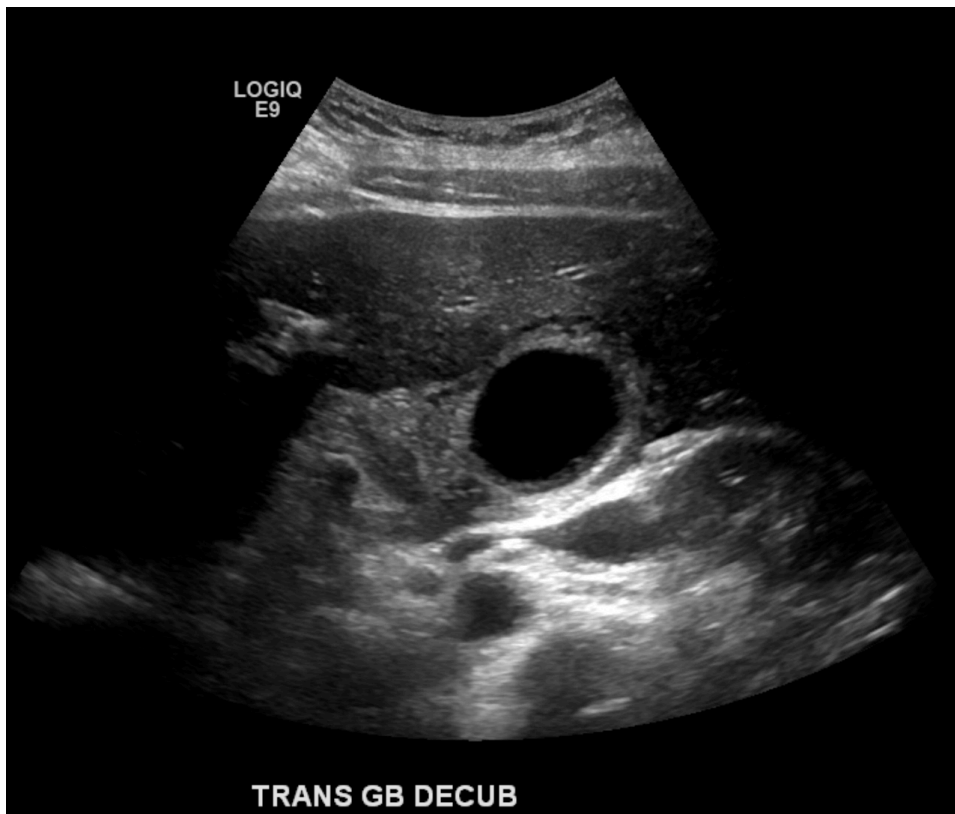
**Left: Gallbladder distention (short-axis measurement = 5cm) in a patient with acute cholecystitis.**



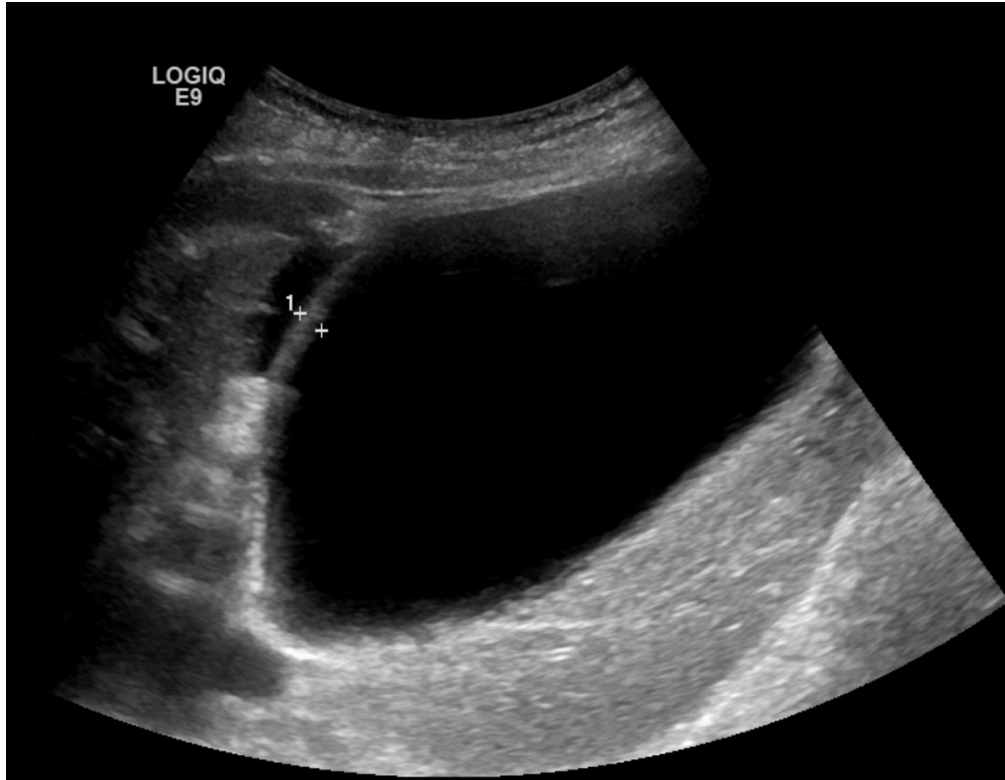
**Left: A thickened, edematous gallbladder wall in a patient with an acute chole.**



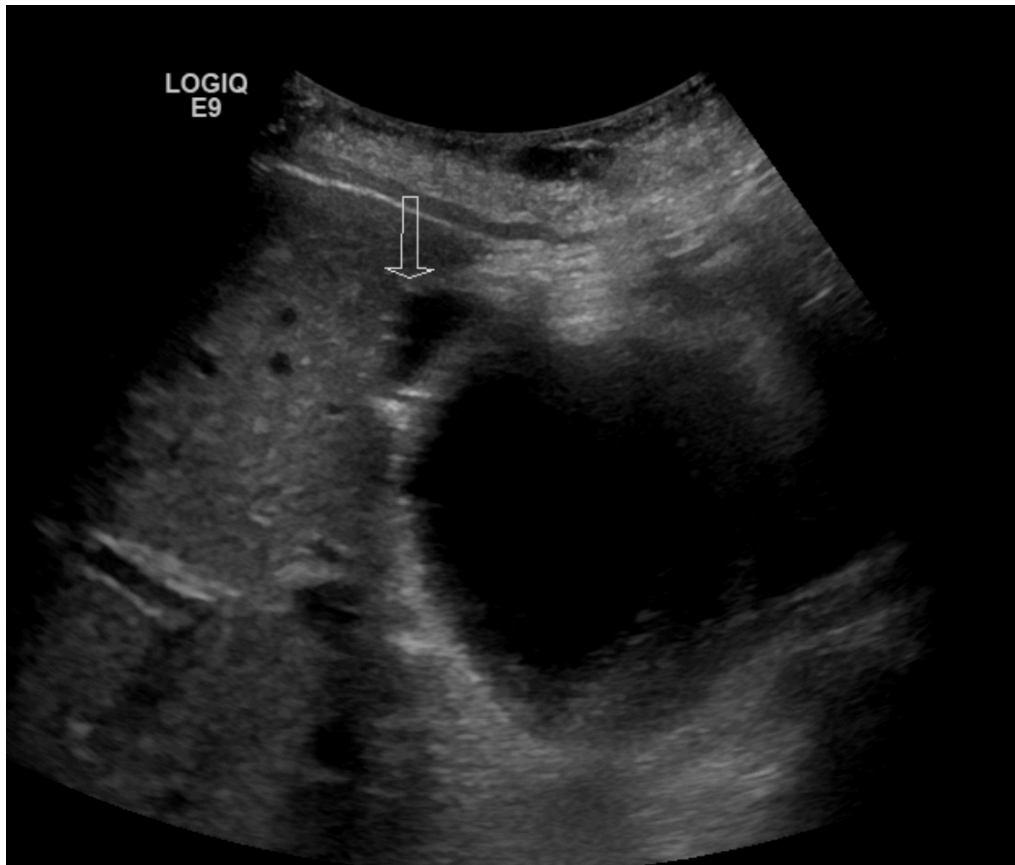
**Left: Wall edema and a stone in the gallbladder neck.** This patient also had focal tenderness over the gallbladder, further suggesting a diagnosis of acute cholecystitis.



**Left: A short axis view of the gallbladder in the same patient.** The anterior wall measured about 6mm.



**Left: Wall edema, gallbladder distention, and pericholecystic fluid** in a patient with acute cholecystitis. Wall measurement was 5mm.



**Left: Pericholecystic fluid** (arrow) in the same patient.