

Imaging of Otosclerosis: Radio-surgical Correlation

Malika El Omri, Bellakhdher Mouna, Souhir Chelly, Monia Ghammem, Jihene Haouas, Abir Meherzi, Wassim Kermani, Mohamed Mahjoub* and Mohamed Abdelkefi*

Original
Article

*Department of Ear, Nose, Throat and Head and Neck Surgery, Farhat Hached University Hospital, Sousse,*Hospital Hygiene Service, University Hospital Centre Farhat Hached, Sousse, Tunisia.*

ABSTRACT

Background: Otosclerosis is a primary dystrophy affecting the otic capsule bone. Computed Tomography (CT) has crucial role in its management.

Aim: To assess the diagnostic value of CT scan by comparing its results to operating data, to define the imaging use in the preoperative anatomic assessment and to assess the prognostic input of CT scan.

Patients and Methods: A retrospective study from January 2012 to December 2019 at the Ear Nose and Throat (ENT) department of Farhat Hached Hospital in Sousse, Tunisia. It included patients explored by CT scan for otosclerosis. We sought to verify CT scan findings during middle ear exploration and concordance or discordance between both was recorded.

Results: A total of 50 patients were included and 56 ears were operated. Mean age of the patients was 38 years (15-64 years). A female predominance was noted with 39 women (78%) and 11 men (22%). Hearing loss was the dominant symptom. The sensitivity of CT scan for the diagnosis was 87.5%. CT scan had a statistically significant value in the diagnosis of thickening footplate with a sensitivity of 63% and a specificity of 88% ($p = 0.001$). The extent of otosclerosis represented a poor prognostic factor with a statistically significant value ($p = 0.030$).

Conclusion: CT scan not only confirms the diagnosis of otosclerosis and eliminates differential diagnoses, but also establish a precise anatomical review and assess the prognosis in cases of planned surgery.

Key Words: CT scan, hearing loss, otosclerosis, prognosis, surgery, temporal bone.

Received: 26 October 2022, **Accepted:** 30 December 2022

Corresponding Author: Malika El Omri, PhD, Department of Ear, Nose, Throat and Head and Neck Surgery, Farhat Hached University Hospital, Sousse, Tunisia. **Tel.:** 56043690, **E-mail:** Omri.malika6@gmail.com

ISSN: 2090-0740, 2023

INTRODUCTION

Otosclerosis is a temporal bone disease with focal remodeling and immobilization of the stapes within the oval window. Its symptoms include progressive, usually bilateral, asymmetric hearing loss and persistent tinnitus^[1]. Otosclerosis is clinically evoked when patient suffered from conductive hearing loss (CHL) with a normal tympanic membrane and no previous significant middle-ear disease^[2]. Although a family history of otosclerosis, negative Rinne, and absent reflexes and conductive or mixed hearing loss (MHL) often with a Carhart's notch at 2000 Hz found on an audiogram strengthens clinical suspicion of otosclerosis^[3]. The diagnosis of otosclerosis can only be established by surgery^[4]. Fine-cut Computed Tomography (CT) images have been proven to demonstrate otosclerotic foci around the oval and round windows, as well as the otic capsule. So far, the clinical role of CT scanning in otosclerosis remains controversial. High-Resolution Computed Tomography

(HRCT) scanning may be helpful in differentiating these middle ear disorders and confirming the diagnosis of otosclerosis before operative treatment, thereby helping in surgical planning and patient counseling^[3,5]. The aim of our study was to assess the diagnostic value of CT scan by comparing its results to operating data, to define the imaging use in the preoperative anatomic assessment and to assess the prognostic input of CT scan.

PATIENTS AND METHODS:

It was a retrospective study, performed from January 2012 to December 2019 at the Ear, Nose and Throat (ENT) department of Farhat Hached Hospital in Sousse, including patients diagnosed with otosclerosis and explored by CT scan. We collected data on consecutive patients with normal findings on otoscopic examination and long-standing progressive unilateral or bilateral hearing loss suggestive of otosclerosis. Inclusion criteria were patients operated for otosclerosis with pre-operative CT scan. Negative CT scan

(absence of otosclerotic foci) is also included in the study. The initial workup for hearing loss included otoscopy, audiometry, a tympanogram, and stapedial reflex testing. All patients suspected of having otosclerosis and scheduled for a surgical middle ear exploration were included. Suspicion of otosclerosis was based upon CHL or MHL with normal tympanic membrane and abnormal stapedial reflex in at least one ear. Exclusion criteria were patients with congenital malformations, other middle and/or inner ear abnormalities (including tympanosclerosis, ossicular chain fixation, superior canal dehiscence, modiolus dysplasia, and enlarged vestibular aqueduct), a history of chronic ear infections, previous surgery, or sudden hearing loss of the affected ear and the postoperative failure due to technical complications of the surgical procedure.

In our institution, HRCT scan is systematically performed in the preoperative assessment in cases of mixed or conductive hearing loss with normal tympanic membrane. Axial and coronal sections were obtained with 0.6-1 mm slice thickness in all patients.

CT scan results were defined based on the site of otosclerotic lesions, Veillon classification (Ia : isolated thickening of the footplate hypodensity, Ib : isolated anterior fenestral hypodensity <1mm, II : isolated anterior fenestral hypodensity >1mm, III : anterior fenestral hypodensity >1mm, hypodensity extends to the endosteum of cochlea, IVa : hypodense foci in the entire middle layer of the otic capsule: pericochlear hypodensity, internal auditory canal hypodensity, IVb : involvement of the entire otic capsule including the vestibule and semicircular canals), anatomical variants with surgical risk and poor prognosis : The extension of otosclerotic lesions, the cochlear window and endosteal invasion.

We divided the cases of otosclerosis on CT into two groups: Group 1: includes localized otosclerosis, i.e. types Ia, Ib and II of Veillon and Group 2: includes extensive otosclerosis, i.e. types III, IVa and IVb.

Positive surgical diagnosis of otosclerosis was confirmed by the presence of macroscopic otosclerotic foci on the oval window, with stapes fixation. In confirmed otosclerosis cases, stapedotomy, partial or total stapedectomy was performed using skeeter microdrill.

The preoperative air conduction (AC) and bone conduction (BC) thresholds for the speech frequencies of 500, 1000, 2000, and 4000 Hertz (Hz) were recorded, and the air-bone gap (ABG) (preoperative values) was calculated in all patients the day before surgery and 2 months later. Results of clinical and audiometric monitoring: We divided the audiometric results into two groups: Group 1: Good results: postoperative ABG ≤ 20 dB or postoperative average hearing gain ≥ 10 dB. Group 2: Average or poor results: postoperative ABG > 20 dB or postoperative average hearing gain < 10 dB.

CT scan sensitivity and specificity were evaluated by comparing CT scan results to the surgical findings.

Statistical analysis was performed using SPSS software (version 22). Qualitative variables were expressed in frequency, percentage and Chi-square tests were used to compare percentage. The p-value lesser or equal to 0.05 was considered statistically significant.

The diagnostic performance of CT and its prognostic contribution were evaluated by calculating sensitivity, specificity, positive predictive value (PPV), and negative predictive value (NPV).

RESULTS:

The studied population included 50 patients (100 ears explored by CT scan and 56 operated ears) with clinical diagnosis of otosclerosis. Bilateral otosclerosis was found for 39 cases (78 ears). Mean age was 38 years ranged between 15 and 64 years. A female predominance was noted with 39 women (78%) and 11 men (22%) with sex ratio of 0,28.

Mean duration of disease was 5.5 years ranged from one year to 15 years. Family history of otosclerosis was found in 10 patients (20%).

Hearing loss was the dominant symptom found in all patients. It was associated with tinnitus in 39 cases (78%). The otoscopy was normal in all patients.

A preoperative audiogram was performed in all patients. For the 56 ears explored surgically, there was CHL in 73% of cases and mixed hearing loss (MHL) in 27% of cases. The threshold for deafness varied between 40 and 90 dB with an average of 65 dB.

The preoperative air-bone gap (ABG) of the 56 operated ears was 43 dB.

The tympanogram was central and normal in amplitude in all 78 cases and decreased in amplitude in 22 cases. The stapedial reflex was absent in all cases.

The CT scan was performed for all patients. Bilateral otosclerosis was identified in 39 cases (78 ears) and it was normal in 22 ears.

The Veillon classification was used to classify otosclerosis lesions. The most common type was type II (46,4%).

For the 56 ears that were operated, hypodensity in the ante-fenestrum fissula region was found in 33 cases (59%) (Figure 1, 2, 3).

The main characteristics of otosclerotic according to Veillon Classification are described in (Table I).

The CT scan revealed 12 cases of facial nerve canal procidence, 3 cases of narrow vestibular window and no chain abnormalities.

Bilateral otosclerosis was found in 78 ears, but surgery was performed for only 56 ears due to the refusal of second operation by the other cases. The stapedotomy was performed for 24 cases, partial stapedectomy for 20 cases and total stapedectomy for 12 cases. The Stapes prosthesis was inserted for all the cases.

The post-operative audiogram showed a good audiometric result in 41 cases (73%) and an average or poor result in 15 cases (27%).

We sought to verify CT scan findings during middle ear exploration and concordance or disaccordance between both was recorded. We found 44 of the 56 operated ears presented otosclerosis lesions on preoperative CT and 12 patients presented otosclerosis thus a normal CT, so sensitivity of the scanner in detecting otosclerosis was 78.5% and PPV was 100% in this disease.

The sensitivity and specificity of the CT scan in detecting footplate thickening were 63% and 88%, respectively: We found 24 cases of thick footplate on CT and intraoperatively, 16 cases of normal footplate on CT scan but normal intraoperatively and 14 cases of normal footplate on CT scan but thick intraoperatively (Table II). The PPV and NPV were 92% and 53% respectively.

After statistical study, a significant difference was found between the radiological and surgical diagnosis of footplate thickening with $p < 0.01$.

A study of the environment of the otosclerotic foci was carried out, investigating the displacement of the facial nerve, the narrowness of the vestibular window and abnormalities of the ossicular chain.

Among the eight facial nerve canal procidences discovered intraoperatively, four were noted in the radiological reports, so the sensitivity of CT scan in detecting facial nerve canal procidence was 33%. CT therefore identified 8 false negatives and 36 true negatives (Table III), a specificity of 81% with a PPV of 33% and a NPV of 81% in detecting facial nerve canal procidence.

There was no significant relationship between surgery and radiological reports ($p = 0.265$).

The sensitivity of CT in detecting narrow vestibular window was therefore 100%: 53 large intraoperative vestibular windows were all identified as such on CT scans and 3 vestibular windows were narrow on CT and intraoperatively. CT therefore has a statistically significant diagnostic value for the diagnosis of a narrow vestibular window with $p < 0.001$.

No anomalies of the ossicular chain were reported on the CT reports or intraoperatively. The sensitivity and specificity of the CT scan were 100%.

In this study, we tried to assess the contribution of preoperative CT in predicting postoperative outcome based on audiometric assessment (ABG).

There were 47 cases of localized otosclerosis on CT and 9 cases of extensive otosclerosis.

A good audiometric result was observed in 41 cases (73%) and an average or poor result in 15 cases (27%). The results are shown in (Table IV).

Localized otosclerosis presented 80.8% of good postoperative responses, while extensive otosclerosis presented only 33%.

There were a significant positive relationship between lesion type and postoperative outcome ($p = 0.03$).

Table I: Distribution of tomodesitometric lesions according to the Veillon classification

Type	Number of ears	Percentage
Type 0	12	21.4 %
Type Ia	4	7.1 %
Type Ib	5	9.2 %
Type II	26	46.4 %
Type III	2	3.5 %
Type IVa	4	7.1 %
Type IVb	3	5.3 %
Total	56	100%

Table II: Radiosurgical concordance of footplate thickening

CT Scan		Surgery		Total
		Thick footplate	Normal footplate	
CT Scan	Thick footplate	True Positive 24 (92.3%)	False Positive 2 (7.3%)	26
	Normal footplate	False Negative 14 (46.7%)	True Negative 16 (53.3%)	30
Total		38	18	56

Table III: Facial nerve canal prociidence CT Scan-surgery concordance

CT Scan		Surgery		Total
		Prociident	Normal	
CT Scan	Prociident	True Positive 4 (33.3%)	False Positive 8 (66.7%)	12
	Normal	False Negative 8 (18.2%)	True Negative 36 (81.8%)	44
Total		12	44	56

Table IV: Postoperative audiometric results according to the extent of otosclerotic sites on CT

Site on CT		Postoperative audiometric result		Total
		Good	Average or poor	
Site on CT	Localized	38	9	47
	Extensive	3	6	9
Total		41	15	56

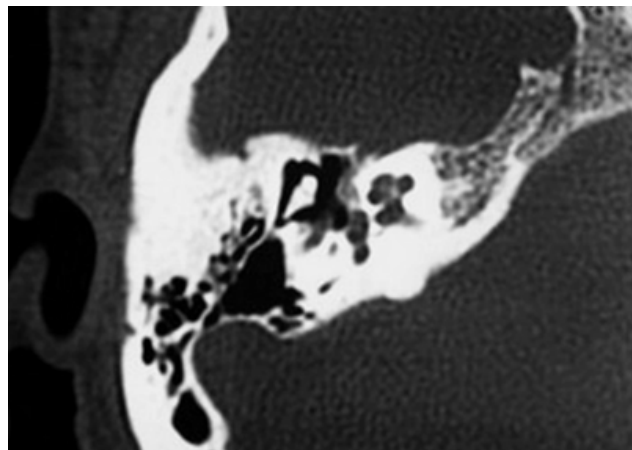


Fig. 1: Axial section showing an anterior fenestral hypodensity with a diameter greater than one millimeter and not reaching the cochlea corresponding to type II otosclerosis.

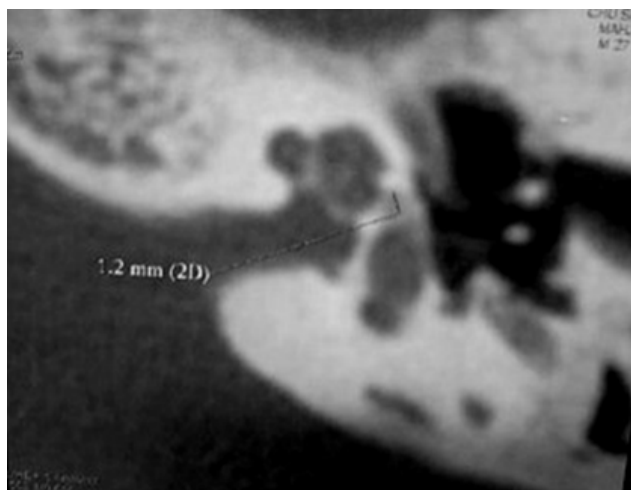


Fig. 2: Axial section showing an anterior fenestral hypodensity of 1.2 mm keeping with the cochlear cleft corresponding to type III otosclerosis

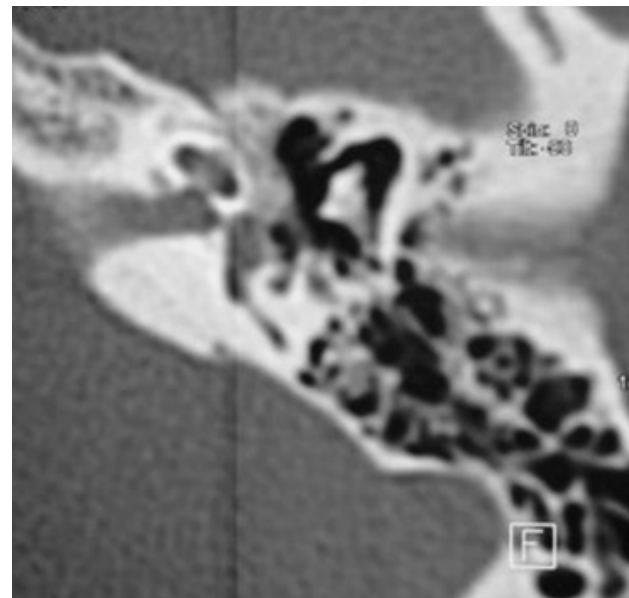


Fig. 3: Axial section showing prestapedial hypodensity, associated with posterior labyrinthine hypodensity (Arrow) related to type IVb otosclerosis.

DISCUSSION

Similarly to the epidemiological data reported in the literature^[3,6,7], we found predominance of female patients in our study. In our study, we had 39 women (78%) and 11 men (22%), with a male: female ratio of 0.28. Mean age of patients was 38 years and the average duration of the disease was 5.5 years.

The incidence of otosclerosis patients with family history of otosclerosis ranged from 49 to 58%, according to epidemiological clinical studies reported

in the literature^[8]. In our study, the presence of positive family history for otosclerosis was detected in 20% of the cases. It is difficult to estimate the real incidence of family history of otosclerosis, especially because it has variable expression and penetration and it is asymptomatic in most cases^[4].

Hearing loss is the most frequent revealing symptom^[9]. It is an acquired deafness which is progressively progressing. It's often bilateral and symmetrical^[9]. However, it can be unilateral at the onset and become secondarily bilateral. According to Gros, 60 to 70% of the attacks are bilateral^[9]. In our serie, they were 76%, thus agreeing with the data in the literature.

Tinnitus is frequently associated and may be the first sign of the disease^[9]. In our series 78% of the patients complained of tinnitus and hypoacusis.

The audiogram shows in general CHL or MHL^[10]. In our serie, we found 73% CHL and 23% MHL.

Histopathologically, otosclerosis is characterized by two types of lesions. An early active phase, Otospongiotic lesions are spongy hypervascular regions of bony demineralization and inactive phase, where lesions attack dense sclerotic bone. These two phases have differing radiographic results with the otospongiotic demineralized foci showing hyperlucency contrasted with the less radiographically apparent inactive dense foci that may be considered as normal otic capsule bone^[11].

After the advent of HRCT, the radiological study of otosclerosis became more accurate, and we could detect abnormalities in the region of the oval window or close to it in 80 to 90% of the confirmed surgical cases^[12,13].

In the literature, sensitivity of CT scan in the diagnosis of otosclerosis ranges from 34 to 90%, but in most recent studies, positivity of CT scan was demonstrated in about 90% of the fenestral cases^[3,13-15]. The presence of infra-millimeter lesions and/or inactive otosclerotic foci (sclerotic) in the otic capsule is the main cause of negative CT scan. For Mafee *et al.*^[16], CT may be normal in case of superficial and isolated otosclerosis lesions of the antefenestramfissula causing simple fibrous fixation of the footplate.

In our study, the sensitivity was 89%. The specificity could not be calculated since all of our patients were selected after operative confirmation of otosclerosis. There are two essential radiological signs: the footplate thickening >0,6mm and the presence of perilabyrinthine hypodensities^[4,12]. In our

series, preoperative CT had a good diagnostic value for footplate thickening with sensitivity and specificity of 76% and 92%, respectively. These figures are comparable to data in the literature^[2,4,5].

There are four sites of predilection which are the fissulaantefenestrum, cochlear window, the pericochlear capsule and the anterior wall of the internal auditory meatus. In the serie of Lagleyre^[5], the antefenestramfissula was the main CT location. It represented 74.6 and 95.9% of the locations respectively for Shin *et al.*^[15] and for Schuknecht and Barber^[11]. In our series, it was observed in 33 cases (59% of cases).

The region of the round window can also be a target for otosclerotic lesions and according to histology findings described in the literature, this is the second most affected area, whose incidence ranges from 20 to 50%^[7,9,11].

The main surgical techniques used are as follows^[4] Stapedotomy, calibrated stapedotomy with transplatinary piston adapted to the diameter of the orifice and partial or total stapedectomy with piston.

In our study, stapedotomy with a micro burr constituted the majority of footplate procedures performed by the surgeon (24 cases), partial stapedectomy was performed for 20 cases and total stapedectomy was performed for 12 cases.

CT can also guide the surgical procedure through affording a precise anatomical assessment. Indeed, the various problems that may be encountered by the surgeon are as follows: Anomalies of the facial canal (providence or dehiscence), narrowness of the vestibular window, otosclerosis obliterans, anomalies of the ossicular chain, the persistent stapedia artery and the ear geysers^[4,12,17].

The study of the fallopian canal is facilitated by the possibility of a multi-planar study.

For Ukkola-Pons^[18], CT can correctly show the relationship between the facial nerve and the vestibular window. However, the reliability of CT in detecting facial canal providence at the vestibular window has never been seriously assessed, which would require a prospective approach.

In our study, CT identified 12 cases of facial nerve canal prolapse out of the 8 found intraoperatively, ie a sensitivity of 33% according to the Ukkola-Pons method^[18]. A dehiscence of the tympanic portion of the facial canal was not found either intraoperatively or on CT.

The narrowness of the vestibular window is the most frequently encountered intraoperative abnormality^[17]. In a retrospective study made on 293 ears operated on for otosclerosis, carried out from January 1990 to December 1996, Ayache found, intraoperatively, 36 cases of narrow vestibular window, ie 12.3%^[17]. In the study by Ukkola-Pons *et al.* eight patients (14%) out of 56 had a narrow vestibular window intraoperatively^[18]. The mean window measurement was 1.1 mm for the group with a narrow window and 1.8 mm for the patients with a wide window. Thus, the threshold between narrow and wide vestibular window was calculated at 1.4 mm.

By applying this method, we identified in our serie three narrow vestibular windows, which were confirmed intraoperatively. The sensitivity of CT in detecting a narrow vestibular window was therefore 100%.

The prognosis depends essentially on three factors which are the extension of the otosclerotic foci, involvement of the cochlear window and cochlear endosteal effraction^[17].

In our study, we observed that patients operated on for localized otosclerosis had better results than those operated on for extensive otosclerosis.

In fact, Beigner^[19], in a study published in 2012 including 88 cases, concluded that a large focus (type III and more according to the Veillon classification) led to bone conduction thresholds less than those obtained with an isolated focus or with normal CT. He also concluded that with normal CT, postoperative hearing gain is significantly less than with positive CT.

Marx^[20] also showed, in a serie of 200 patients, that the group with extensive involvement has a low threshold of bone and air conduction pre and postoperatively and therefore a reduced chance of improving the threshold of bone conduction compared to the group of patients with localized radiological otosclerosis (Veillon type I and II).

Mansour^[21] showed that patients with type I and type II generally had an improvement in postoperative audiometry. In contrast, the group of patients with types III and IV affected had worsening of bone and air conduction and widening of the Rinne.

In our series, we found that patients with type III and IV had less improvement in bone conduction and audiometric Rinne compared to those with a type I or II involvement of Veillon.

Involvement of both windows is, in general, of a less favorable prognosis than an isolated localization at the level of the stapes and its immediate environment^[3,17]. It is therefore important to inform the patient, before any surgical procedure, of the relative effectiveness of an operative treatment in the event of double involvement of the windows.

Shin^[15], in a study made from 437 scans carried out on otosclerotic patients, detected 14 cases of obliteration of the round window, with a statistically significant decrease in air and bone thresholds preoperative, postoperative and gain in conduction bone compared to the group made up of all patients who do not have an obliteration of the cochlear window.

Cochlear endosteal involvement is not assessed by the Veillon classification. This factor represents 26.4% of pericochlear foci and 3.2% of the population studied according to Shin^[15]. Labyrinthine involvement by invasion of otosclerotic foci in the cochlear endosteum has a poor prognosis. In fact, this phenomenon causes the release of enzymes in the labyrinthine fluid responsible for inflammation and degeneration of intracochlear structures which can lead to cophosis or deep sensorineural hearing loss^[20,21].

A relationship between endosteal damage and impaired bone conduction has been researched by several authors. Kiyomizu^[22] found a correlation between the degree of endosteal involvement and loss of bone conduction. According to Young^[15], there is a statistically significant correlation between the extent of impaired bone conduction and the endosteal extension of pericochlear foci.

Lagleyere^[5] found that the group with endosteal invasion had low pre- and postoperative bone conduction thresholds in comparison to the group without endosteal invasion on CT. In our serie, the endosteal invasion was not studied.

CONCLUSION

CT scan was important in the diagnosis of otosclerosis, presenting high level of positive responses. CT scan findings were often statistically significant. The fissa antefenestram was the predominant focus and it can be considered a highly suggestive CT scan finding of otosclerosis. CT scan proved to be extremely useful in preoperative assessment of patients with otosclerosis.

CONFLICT OF INTEREST

There are no conflicts of interest.

REFERENCES

1. Gristwood RE, Venables WN. Otosclerosis and Chronic Tinnitus. *Ann OtolRhinolLaryngol.* 2003;112(5):398-403.
 2. Kanona H, Rana I, Offiah C, Patel N. Importance of a dedicated neuroradiologist in reporting high-resolution computed tomography for otosclerosis: a retrospective comparison study of 40 patients. *J Laryngol Otol.* 2017;131(6):492-6.
 3. Maxwell AK, Shokry MH, Master A, Slattery WH. Sensitivity of High-Resolution Computed Tomography in Otosclerosis Patients undergoing Primary Stapedotomy. *Ann OtolRhinolLaryngol.* 2020;129(9):918-23.
 4. Purohit B, Hermans R, Op de beeck K. Imaging in otosclerosis: A pictorial review. *Insights Imaging.* 2014;5(2):245-52.
 5. Lagleyre S, Sorrentino T, Calmels MN, Shin YJ, Escudé B, Deguine O, *et al.* Reliability of High-Resolution CT Scan in Diagnosis of Otosclerosis. *OtolNeurotol.* 2009;30(8):1152-9.
 6. Shea JJ Jr. Forty years of stapes surgery. *Am J Otol.* 1998;19:52-5.
 7. Niedermeyer HP, Arnold W. Etiopathogenesis of otosclerosis. *ORL J OtorhinolaryngolRelat Spec.* 2002;64:114-9.
 8. EL Maraghy A, Aboelwafa W, Abdel Monem M, Abdul Ghany A, Sheref H, Mahmoud A. Role of high resolution multislice CT scan in otosclerosis. *Egypt J Ear Nose Throat Allied Sci.* 2015;16(3):247-54.
 9. Gros A, Vatovec J, Šereg-Bahar M. Histologic Changes on Stapedial Footplate in Otosclerosis: Correlations Between Histologic Activity and Clinical Findings. *OtolNeurotol.* 2003;24(1):43-7.
 10. Salvinelli F, Casale M, Peco VD, Greco F, Trivelli M. Stapedoplasty in patients with small air-bone gap: why not? *MedHypotheses.* 2003;60(4):535-7.
 11. Schucknecht HF: Pathology of the ear. 2nd ed., Lea &Febiger, Philadelphia, 1993, p.365-379.
 12. Veillon F, Stierle JL, Dussaix J, Ramos-Taboada L, Riehm S. Imagerie de l'otospongiose : confrontation clinique et imagerie. *J Radiol.* 2006;87(11):1756-64.
 13. Berrettini S, Ravecca F, Volterrani D, Forli F, Boni G, Neri E, *et al.* Single Photon Emission Computed Tomography in Otosclerosis: Diagnostic Accuracy and Correlation with Age, Sex, and Sensorineural Involvement. *OtolNeurotol.* 2002;23(4):431-8.
 14. Naumann IC, Porcellini B, Fisch U. Otosclerosis: Incidence of Positive Findings on High-Resolution Computed Tomography and Their Correlation to Audiological Test Data. *Ann OtolRhinolLaryngol.* 2005;114(9):709-16.
 15. Young Je Shin, Bernard Fraysse, Oli. Sensorineural Hearing Loss and Otosclerosis: A Clinical and Radiologic Survey of 437 Cases. *Acta Otolaryngol (Stockh).* 2001;121(2):200-4.
 16. Mafee MF, Henrikson GC, Deitch RL, Norouzi P, Kumar A, Kriz R, *et al.* Use of CT in stapedial otosclerosis. *Radiology.* 1985;156(3):709-14.
 17. Ayache D, Corre A, van Prooyen S, Elbaz P. Surgical Treatment of Otosclerosis in Elderly Patients. *Otolaryngol Neck Surg.* 2003;129(6):647-77.
 18. Ukkola-Pons E, Ayache D, Pons Y, Ratajczak M, Nioche C, Williams M. Oval Window Niche Height: Quantitative Evaluation with CT before Stapes Surgery for Otosclerosis. *Am J Neuroradiol.* 2013;34(5):1082-5.
 19. Beigner B, David A, Chobaut J, Tavernier L. Corrélation des résultats scanographiques et audiométriques dans la chirurgie stapédienne pour otospongiose. *AnnalesFrancaises d'Oto-Rhino-Laryngologie et de Pathologie Cervico-Faciale.* 2012;129(4):A75
 20. Marx M, Lagleyre S, Escudé B, Demeslay J, Elhadi T, Deguine O, *et al.* Correlations between CT scan findings and hearing thresholds in otosclerosis. *Acta Otolaryngol (Stockh).* 2011;131(4):351-7.
 21. Mansour S, Nicolas K, Ahmad HH. Round Window Otosclerosis: Radiologic Classification and Clinical Correlations. *OtolNeurotol.* 2011;32(3):384-92.
 22. Kiyomizu K, Tono T, Yang D, Haruta A, Kodama T, Komune S. Correlation of CT analysis and audiometry in Japanese otosclerosis. *Auris Nasus Larynx.* 2004;31(2):125-9.
-