

Ultrasonographic features of pharyngoesophageal diverticulum in a case misdiagnosed as a thyroid nodule: a case report and review of the literature

Burak Çildağ¹, Özüm Tunçyürek¹, Ersen Ertekin¹, Songül Çildağ²

¹Department of Radiology, Faculty of Medicine, Adnan Menderes University, Aydın, Turkey

²Department of Internal Medicine/Allergy and Clinical Immunology, Faculty of Medicine, Adnan Menderes University, Aydın, Turkey

Abstract

Ultrasonography technique is generally used for head and neck lumps. As pharyngoesophageal diverticula reach large sizes, it might project toward the thyroid gland which can be confused with thyroid nodule during thyroid ultrasonography, leading to unnecessary fine needle aspiration biopsy. In this report, we present a case of pharyngoesophageal diverticulum that mimicked thyroid nodule in ultrasonography together with literature knowledge and ultrasonographic signs.

Keywords: Diverticulum, nodule, thyroid, ultrasound.

Özet: Tiroid nodülü olarak yanlış tanı alan faringoözefageal divertikül olgusunun ultrasonografik özellikleri: Olgu sunumu ve literatürün gözden geçirilmesi

Baş ve boyun şişlikleri için genellikle ultrasonografi tekniği kullanılır. Faringoözefageal divertikül büyük boyutlara ulaştığında, tiroid beze yansiyabilir, ultrasonografi sırasında tiroid nodül ile karıştırılabilir, gereksiz ince iğne aspirasyon biyopsisine neden olabilir. Bu çalışmada, ultrasonda tiroid nodülünü taklit eden faringoözefageal divertikül olgusunu, literatür bilgisi ve ultrasonografik işaretlerle birlikte sunduk.

Anahtar sözcükler: Divertikül, nodül, tiroid, ultrason.

Killian-Jamieson diverticulum is an infrequent, pulsion type of diverticulum which derived from the anterolateral wall of the cervical esophagus in a gap below the cricopharyngeus and lateral to the longitudinal tendon of the esophagus. Zenker's diverticulum originates from the posterior wall of the pharyngoesophageal part in a midline zone of weakness above the cricopharyngeus.^[1]

Diverticulus can mimic thyroid nodule in ultrasonography due to its large size. In this paper, we discuss cases of Killian-Jamieson diverticulum that originate from the esophagus and mimic thyroid nodule, and we present ultrasonographic findings together with literature knowledge in order to prevent unnecessary biopsies.

Case Report

A 62-year-old female patient was referred from the endocrinology department ward to the ultrasonography unit of radiology clinic for the evaluation of a biopsy because of her previous ultrasonography results, performed at an external center. The woman had occasional difficulty in swallowing, no family history of thyroid disease, negative laboratory tests and a normal physical examination. A thyroid ultrasonography was carried out with 10 MHz linear transducer and showed a heterogeneous nodular lesion (21×16 mm) with hypoechoic borders posterior to the left lobe of thyroid gland and a hyperechogenic center that casted shadow behind (Fig. 1). Diverticulum was suspected

Correspondence: Özüm Tunçyürek, MD, Assist. Prof., EDIR, Department of Radiology, Faculty of Medicine, Adnan Menderes University, Aydın, Turkey.
e-mail: ozum.tuncyurek@gmail.com

Received: May 13, 2016; **Accepted:** June 15, 2016

Online available at:
www.entupdates.org
doi:10.2399/jmu.2016001007
QR code:



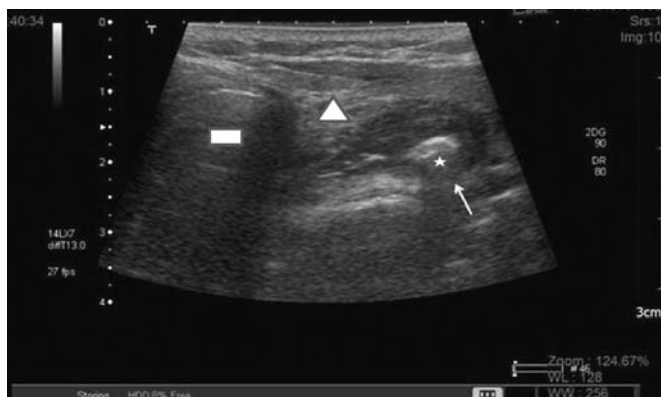


Fig. 1. In the axial section US image, there is centrally hyperechogenic lumen (asterisk) and peripherally hypoechoic (arrow) diverticulum located laterally at left. Triangle is on the thyroid tissue and rectangle is on the trachea.

because of its relation to the esophagus at axial sections. When the patient was asked to swallow, the shape of the diverticulum changed. To confirm diverticulum the patient underwent barium esophagography examination. The barium examination revealed an esophageal diverticulum at C5–6 level, located left to the median line, which was filled with barium contrast agent (Fig. 2).

Discussion

This gap was first described by Killian as corresponding to the area where the recurrent laryngeal nerve enters the pharynx. This finding was later confirmed by Jamieson and is now termed the Killian-Jamieson triangle.^[2-4]

Diagnosis of diverticulum is made upon detection of diverticular filling of contrast agent at the pharyngo-esophageal junction in barium esophagography, together

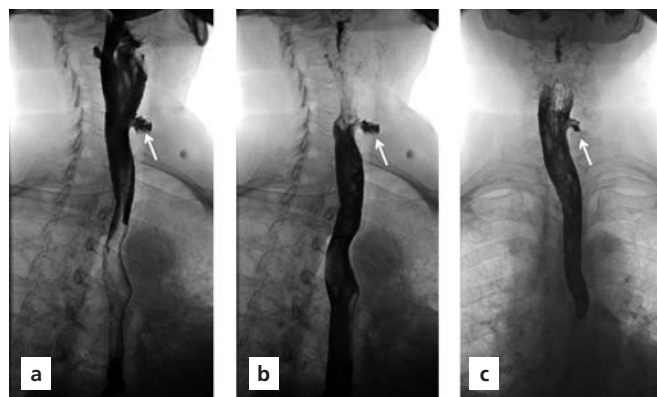


Fig. 2. Laterally located diverticulum is observed at left, at oblique (a and b) and AP (c) radiograms (arrow).

with the weight loss, regurgitation, cough, and aspiration symptoms of the patient.^[5]

Diverticulum may mimic thyroid nodule in ultrasonographic examination because of its large size and location toward the thyroid leading to inadvertently fine needle aspiration biopsy (FNA). According to the review of literature, some patients underwent FNA after the initial diagnosis of thyroid nodule.^[6-8] Therefore it is important to know the ultrasonographic appearance of diverticulum in order to prevent unnecessary FNA. Killian-Jamieson diverticulum cases with ultrasound findings were demonstrated in Table 1.

Important signs of diverticulum during ultrasonography are motion of air bubbles inside the diverticulum, changes in shape during swallowing, and observation of the connection to the esophagus in dynamic examination. Additionally, presence of peripheral echogenic line,

Table 1. US examination of pharyngo-esophageal diverticulum cases in the literature.

Case	Ultrasound finding	Sex	Diverticulum size (cm)	Age (years)	FNA application (+)/(-)	Number of cases
Mercer et al. ^[15]	Hypoechoic lesion containing some bright foci/ left side	F	NA	58	(-)	1
Pang et al. ^[16]	Hypoechoic nodule with internal-hyperechoic foci and hypoechoic rim	M	1	54	(-)	1
Kim et al. ^[17]	Bilateral hyperechoic lesion	M	NA	71	(-)	1
Kim et al. ^[18]	Echogenic masses with echogenic foci and hypoechoic rim	7/6	1.5	41-70	7(+)/6(-)	13
Mimatsu K ^[14]	Hypoechoic lesion containing echogenic foci	F	4	74	(-)	1
Cildag MB (Present case)	Heterogeneous nodular lesion with hypoechoic rim and hyperechogenic center	F	2	62	(-)	1

F: female; M: male

hypochoic rims and central or peripheral echogenic foci are signs suggesting that this structure originates from gastrointestinal system.^[9,10]

Because of the echogenic foci inside, this structure could be confused with thyroid nodules contain punctuate micro-calcification foci as found in papillary thyroid carcinoma. Air bubbles inside the diverticulum create comet-tail artifact or reverberation artifact in ultrasonography. This appearance is due to presence of air, water or debris inside the diverticulum. The diverticulum can change shape by compression of the probe or by swallowing.^[11,12]

The aspects of a Killian- Jamieson diverticulum and a Zenker's diverticulum are similar; they cannot be differentiated on ultrasonography but can be differentiated on barium esophagography.^[13] Barium esophagography is still considered the gold standard test for diagnosis of diverticulum. It reveals filling of contrast near the pharyngoesophageal junction, close to posterior aspect of distal pharynx. This is best observed at lateral view, at the level of C5-6 vertebrae during swallowing.

Misdiagnosis of diverticulum includes thyroid nodules, adenomas, thyroid abscess, parathyroid hyperplasia or adenoma, lymphadenopathy, pharyngeal or paratracheal air abscess.^[14] Asymptomatic small diverticula are followed up with imaging techniques in combination with clinical evaluations, whereas surgical treatment is considered in cases with clinically serious dysphagia, weight loss, aspiration and recurrent pulmonary infections.

In conclusion, although pharyngoesophageal diverticulum is seen rarely, it may be confused with thyroid nodule during thyroid ultrasonography. Therefore, it is important to know the ultrasonographic signs of diverticulum in order to prevent unnecessary biopsies.

Conflict of Interest: No conflicts declared.

References

- Rubesin SE, Levine MS. Killian-Jamieson diverticula: radiographic findings in 16 patients. *AJR Am J Roentgenol* 2001;177:85-9.
- Killian G. Über den Mund der Speiseröhre. *Zeitschrift für Ohrenheilkunde* 1908;55:1-44
- Jamieson EB. Illustrations of regional anatomy. Edinburgh: E&S Livingstone Ltd; 1934. Section 2:44.
- Zaino C, Jacobson HG, Lepow H, Ozturk C. The pharyngoesophageal sphincter. Springfield, IL: CC Thomas; 1950. p. 29-144.
- Ferreira LE, Simmons DT, Baron TH. Zenker's diverticula: pathophysiology, clinical presentation, and flexible endoscopic management. *Dis Esophagus* 2008;21:1-8.
- Walts AE, Braunstein G. Fine-needle aspiration of a paraesophageal diverticulum masquerading as a thyroid nodule. *Diagn Cytopathol* 2006;34:843-5.
- Oertel YC, Khedmati F, Bernanke AD. Esophageal diverticulum presenting as a thyroid nodule and diagnosed on fine-needle aspiration. *Thyroid* 2009;19:1121-3.
- Jeong HK, Young SC, Bu KK, Jun SL, Yo-Han P, Bang H. Zenker's diverticulum suspected to be a thyroid nodule diagnosed on fine needle aspiration: a case report. *Journal of Medical Cases* 2012;3:261-3.
- Komatsu M, Komatsu T, Inoue K. Ultrasonography of Zenker's diverticulum: special reference to differential diagnosis from thyroid nodules. *Eur J Ultrasound* 2000;11:123-5.
- Ko HM, Boerner SL, Geddie WR. Fine-needle aspiration of a pharyngoesophageal diverticulum mimicking a calcified thyroid nodule on ultrasonography. *Diagn Cytopathol* 2013;41:752-3.
- Lixin J, Bing H, Zhigang W, Binghui Z. Sonographic diagnosis features of Zenker diverticulum. *Eur J Radiol* 2011;80:e13-9.
- Shao Y, Zhou P, Zhao Y. Ultrasonographic findings of pharyngoesophageal diverticulum: two case reports and review of literature. *J Med Ultrason* 2001;42:553-7.
- Wang Y, Song Y. Sonographic characteristics of pharyngoesophageal diverticula: report of 14 cases and review of the literature. *J Clin Ultrasound* 2016;44:333-8.
- Mimatsu K, Oida T, Kano H, et al. Killian-Jamieson diverticula presenting synchronously with thyroid adenoma. *Case Rep Gastroenterol* 2013;7:188-94.
- Mercer D, Blachar A, Khafif A, Weiss J, Kessler A. Real-time sonography of Killian-Jamieson diverticulum and its differentiation from thyroid nodules. *J Ultrasound Med* 2005;24:557-60.
- Pang JC, Chong S, Na HI, Kim YS, Park SJ, Kwon GY. Killian-Jamieson diverticulum mimicking a suspicious thyroid nodule: sonographic diagnosis. *J Clin Ultrasound* 2009;37:528-30.
- Kim MH, Kim EK, Kwak JY, Kim MJ, Moon HJ. Bilateral Killian-Jamieson diverticula incidentally found on thyroid ultrasonography. *Thyroid* 2010;20:1041-2.
- Kim HK, Lee JI, Jang HW, et al. Characteristics of Killian-Jamieson diverticula mimicking a thyroid nodule. *Head Neck* 2012;34:599-603.

This is an open access article distributed under the terms of the Creative Commons Attribution-NonCommercial-NoDerivs 3.0 Unported (CC BY-NC-ND3.0) Licence (<http://creativecommons.org/licenses/by-nc-nd/3.0/>) which permits unrestricted noncommercial use, distribution, and reproduction in any medium, provided the original work is properly cited.

Please cite this article as: Çildağ B, Tunçyürek Ö, Ertekin E, Çildağ S. Ultrasonographic features of pharyngoesophageal diverticulum in a case misdiagnosed as a thyroid nodule: a case report and review of the literature. *ENT Updates* 2016;6(2):101-103.