



Title	HISTOLOGICAL AND CYTOLOGICAL CHANGES IN THE OVARY OF A VIVIPAROUS TELEOST, NEODITREMA RANSONNETI STEINDACHNER DURING GESTATION
Author(s)	IGARASHI, Takao
Citation	北海道大學水産學部研究彙報, 12(3), 181-188
Issue Date	1961-11
Doc URL	http://hdl.handle.net/2115/23136
Type	bulletin (article)
File Information	12(3)_P181-188.pdf



[Instructions for use](#)

HISTOLOGICAL AND CYTOLOGICAL CHANGES IN THE OVARY OF
A VIVIPAROUS TELEOST, *NEODITREMA RANSONNETI*
STEINDACHNER DURING GESTATION

Takao IGARASHI

Faculty of Fisheries, Hokkaido University

Introduction

The habits of viviparity and the structures of the gonads have been noticed by many authors, i. e. Eigenmann (1892), Hubbs (1917), Turner (1933, '37, '38 a, '38 b, '40, '52), Mendoza (1937, '39, '40, '41, '43, '56), etc. in several families of teleostean fishes. Concerning Embiotocidae which is among the families, Hubbs (1917) described the habits of viviparity, Eigenmann (1892) the development of embryos while Turner (1938 a) wrote on the histological changes occurring in the ovary during gestation of *Cymatogaster aggregatus*. Uchida (1938) treated some characteristics of viviparity in his paper on the life history of a Japanese embiotocid, *Ditrema temmincki*. Ishii (1957, '60) also recently reported on the seasonal changes in the ovary of the same species.

Neoditrema ransonneti STEINDACHNER, Japanese name "Oki-tanago" which belongs to the same family, has remained quite unknown as to the detailed mechanism of viviparity. The author, therefore, investigated functional relationships between the ovary and the embryos of the species, especially from the histological and cytological points of view.

Before going further, the author wishes to express his hearty thanks to the late Prof. S. I. Sato of the Zoological Laboratory, Faculty of Fisheries, Hokkaido University under whose guidance and criticism the presently described work was done. Thanks are also offered to Prof. S. Okada of the same laboratory for his kind revision of the manuscript.

Materials and Methods

The materials, *Neoditrema ransonneti* STEINDACHNER utilized in the study were collected during the months from April 1959 to August 1960 on the coast in the vicinity of Hakodate. The ovaries of about forty yearlings in various stages during the resting and gestation periods were fixed in Bouin's fixative fluid after the length and the greatest width of the ovaries had been measured. Then the middle part of each ovary was sectioned transversely and longitudinally in the thickness of 6-10 μ by ordinary paraffin method. Delafield's haematoxylin and eosin were used for staining.

Observations

1. General external features of ovary

In young of *Neoditrema* just after birth, the ovaries of females are decidedly smaller in size than the testes of males. In August a female sample of 42 mm length which was just born had an ovary of only 3 mm, together with the posterior extension of the ovarian duct. The ovaries of samples in December or January measure about 8 mm in length and 4 mm in diameter. Probably fertilization of eggs takes place first at this period when the young are about 5 months old. By early April the ovary grows rapidly to about 18 mm in length and about 8 mm in diameter. At this time the embryos which measure 2 or 3 mm length with a small yolk sac are found in the ovary. In late May the ovary measures about 22 mm in length and embryos in the ovary have grown to attain 15 mm in total length. By this time the ovary with its ovarian duct changes from pear shape to oval in form. In the period from late July to early August the ovary is about 32 mm in length and 14 mm in diameter. At this stage the embryos are discharged from the maternal body. The young just after birth from yearling females range normally 27-30 mm in length while those from larger females may measure 38 mm or more.

The spatulate extensions of the vertical fins are evident when embryos measure 15 mm length in late May in the ovary and remain almost to the end of foetal life. Just before birth the extensions are normally absorbed. After the embryos are born the maternal ovary begins to decrease in size and shrinks to 22 mm length and 12 mm diameter in a month.

2. General histological structures of ovary

The ovary of *Neoditrema ransonneti* resembles that of *Cymatogaster aggregatus* and *Ditrema temmincki* in structure. The ovary consists of three parts, viz. ovarian wall, ovarian cavity and ovigerous folds (Plate I: Fig. 4; Plate II: Fig. 1).

The ovarian wall is composed of an epithelium of outer surface, a subepithelial layer of connective tissue, circular and longitudinal muscle layers and an epithelium of inner surface.

The ovigerous folds consist of 6 lamellae projecting from the inner dorsal surface of the ovarian cavity. The anterior and ventral margins of 3 lamellae fuse together, so it seems to be 2 folds externally. Posteriorly interlamellar spaces communicate directly with the oviduct. The lamellae are covered with a cuboidal epithelium and inside the epithelial surface there are formed, stroma cells, con-

nective tissue fibers, small young cells and larger oocytes which are surrounded by a follicular epithelium.

During gestation, embryos are found between two lamellae of the fold or between the lamella and ovarian wall.

3. Histological structures of early ovary

The ovary of 3 mm length from a young collected on the 15th August which is soon after birth, is quite immature and shows no general arrangement of the tissue such as is found in matured ovaries. The anterior one-third of the ovary is swollen and contains ovigerous tissues but the posterior portion is composed of a thin wall duct only. The swollen part measures about 0.8 mm in diameter. The ovarian wall is very thin. The ovigerous tissues are separated into right and left masses by a septum. Each of the masses is divided into three lamellae by two internal dorsoventral, longitudinal clefts which are open posteriorly (Plate I: Fig. 1). The lamellae are composed of superficial epithelium, stroma cells, connective tissue fibers, germ cells and developing oocytes. There can not yet be observed any tissue spaces which appear later under the epithelium of the ovigerous folds (Plate I: Figs. 2, 3).

The ovaries of the young collected on the 20th September are about 5 mm in length and have the same thin ovarian walls as the ovary of 3 mm (Plate I: Fig. 4). A simple low cuboidal epithelium lines the internal surface of the wall and connective tissue which contains elastic fibers is going to develop between the epithelium and muscular layers. Small blood vessels are distributed richly in the muscular layer. The ovigerous folds are six in number and the septum has disappeared. The folds are filled with spindle-like or round stroma cells with pale nuclei and conspicuous cytoplasm. Some of these cells gather particularly around germ cells and developing oocytes (Plate I: Figs. 5, 6).

Blood vessels distributed within the stroma and in some cases in the connective tissue layer are slender and not numerous. Small germ cells lie in the stroma near the connective tissue layer and protrude into the tissue spaces which are produced by an expansion of the fold. The oocytes protrude further and the largest ones measuring about 0.1 mm in diameter fill the tissue spaces. At this time spermatozoa are found mostly at the dorsal and ventral blind ends of the ovarian cavity in masses.

In the young collected on the 6th December the ovaries are 8 mm in length and 4 mm in diameter. Noticeable changes begin to occur in the histological structures of the ovary after this stage. The muscular layers of the ovarian wall are

developing and distinctly thicker than the previous samples (Plate II: Fig. 1). The epithelium lining the inner surface of the wall is composed of high columnar cells in irregular arrangement and now contains a large number of secretory reservoir cells. The connective tissue under the epithelium is remarkably thick and very rich in blood vessels. On the inner surface of the wall, low ridges are formed richly; they protrude into the ovarian cavity. This is because the inner surface of the walls increases in area due to the remarkable development of the secretory reservoir cells. The ovigerous folds are more extensive and highly wrinkled than previous samples. The ovarian cavity is mostly occupied by them. The tissue spaces in the folds are very extensive.

The stroma cells and connective tissue are reduced in number (Plate II: Figs. 2, 3). The epithelium of the ovigerous folds shows a little evidence of secretory activity. Some of the cells in the epithelium of both ovigerous folds and ovarian wall are being separated from the underlying connective tissues because of the accumulation of secreted material. Small patches of such cells are desquamated in the ovarian cavity. Both immature and fully grown oocytes are observed scattered in the ovigerous folds (Plate II: Fig. 4).

The fully developed oocytes surrounded by follicles lie under the epithelium. Sperm masses are distributed more widely than in earlier stage (Plate II: Figs. 5, 6).

4. Histological structures of gravid ovary

Fertilization is completed by a process during which sperms pass directly through the epithelium of the ovigerous folds and get to the mature eggs. The ovary when the fertilization is first performed is about 8 mm in length and 4 mm in diameter in early December. Immediately after the fertilization eggs are extruded from the ovigerous folds into the nearest tissue space, so that some of them come to lie between the ovarian wall and the ovigerous fold while others are within the cleft or space between two folds.

In the young collected on the 10th April the ovaries are 18 mm in length, containing embryos which are visible to the naked eye through the ovarian wall. At this same time, the ovigerous folds contain degenerating oocytes in large tissue spaces (Plate III: Figs. 1, 2). The epithelium of ovigerous folds consists of high columnar cells with round nuclei. The cytoplasm of the cell is strongly stained with haematoxylin. Some of the epithelial cells are desquamating into the ovarian cavity whilst others are enlarging in the epithelial layer (Plate III: Figs. 3, 4). The inner epithelium of the ovarian wall is undergoing the same great changes as the active ovigerous folds are. The epithelium is rugged due to the existence

of wrinkles and the subepithelial connective tissue layer is thick (Plate III: Fig. 6). The epithelial cells of the ovarian wall and the ovigerous folds are almost the same in histological characteristics. Peculiar thick-wall blood vessels are distributed inside the ovigerous folds (Plate III: Fig. 2). An artery and vein are always bound together by a thick sheath composed principally of longitudinal elastic connective fibers (Plate III: Fig. 5).

In the young collected on the 22th May the ovaries measure about 22 mm in length and are extremely distended with embryos. The ovigerous folds have large tissue spaces filled with fluid and blood vessels surrounded by a connective tissue membrane (Plate IV: Figs. 1, 2). A network of small capillaries is seen in the subepithelial connective tissue of both the ovigerous folds and ovarian wall (Plate IV: Fig. 3). The epithelial cells of the inner surface of the ovarian wall are high columnar and hypertrophic, having a round nucleus (Plate IV: Fig. 4). Some of the cells are broken and cell contents have flowed out into the ovarian cavity (Plate IV: Fig. 5). Other cells in the epithelial layer are columnar and greatly swollen. This means that secretory activity is at maximum (Plate IV: Fig. 6).

The late period of the gestation which comes in June and July is marked by the growth of the embryos, the shrinkage of the tissue spaces in both ovigerous folds and ovarian wall. In the young collected on the 16th July the ovary is 32 mm in length and 14 mm in maximum width. The fluid in the tissue spaces has been lost. The ovigerous folds are thin and fairly solid. Scattered stroma cells, connective tissue fibers, and large granular free cells are found as the principal structures in the shrunken folds. Numerous large blood vessels run in the tissue of the folds and branch off in a network just beneath the epithelium (Plate V: Figs. 1, 2). The epithelium of the ovigerous folds are restored to normal condition; the epithelial surface is flat and smooth, the cells are columnar. Small fluid reservoirs remain at the bases of the cells. This fact means that the secretion activity is greatly reduced (Plate V: Fig. 3). The inner epithelium of the ovarian wall is still wrinkled.

After the birth of the embryos the ovary undergoes a rapid shrinking. The ovary of a female collected on the 5th August which is in postpartum stage is rapidly shrinking, measuring 22 mm in length.

The epithelia of both ovigerous folds and ovarian wall are being restored to the normal condition; the nuclei of the epithelial cells are irregular and flat in form (Plate V: Fig. 6). A large number of free cells containing many large granules are seen in small tissue spaces of ovigerous folds and the subepithelial connective tissue layer of ovarian wall.

The large blood vessels remain without any reduction in thickness of wall,

being surrounded by connective tissue in spite of the reduction of most other structures (Plate V: Figs. 4, 5). Some small oocytes are still alive during the changes of the ovary and now begin to grow. No spermatozoa are found in the ovarian cavity.

5. Functional relationships between embryo and ovary

Discussions have been offered on the functional relationships between embryo and ovary especially by Blake (1867), Eigenmann (1892), Turner (1938a) and Mendoza (1956), making valuable suggestions. The writer's observations on the structure of the ovary and its histological changes in *Neoditrema* are in good agreement with those in *Cymatogaster* by Turner (1938 a).

Copulation in *Neoditrema* seems to take place in late September. Spermatozoa are found in the ovarian cavity of females collected in late September, but never found in females collected at an earlier time. The writer's observation suggests that fertilization takes place in December or in January and that eggs are discharged from the ovigerous folds into the ovarian cavity soon after fertilization.

In the present species, the gestation period seems to last from January to July or to August. During this period, the ovaries undergo marked changes in structure and function. The epithelia both of the ovarian wall and ovigerous folds become remarkably hypertrophic and many large tissue spaces filled with fluid appear in the ovigerous folds at an early stage of gestation. Vascular development in the ovary is not yet very prominent. Late in the gestation period, the secretory activity is reduced and the fluid in the tissue spaces disappears. On the contrary, vascularity of the ovarian wall and the ovigerous folds develops remarkably. Such development seems indicate that the methods of food and oxygen supply to young embryos differ considerably in the early and late stages. The early embryo would have comparatively few needs and could be easily satisfied by the fluid contained in the tissue spaces and the epithelial reservoir cells. The decreased secretory activity and the disappearance of the fluid in the tissue spaces during late gestation bring about a remarkable development in vascularity of the ovary. The late embryos would be supplied the greater part of their demands directly from their mother through the vascular system rather than from the secretions of the ovary. At this period, the first gill cleft is formed in the embryos, the alimentary canal begins to function and desquamated cells, unused sperm and blood cells are utilized as food. Long villi located in the hind gut evidently facilitate absorption of digested materials. The absorption of the embryo's needs is augmented externally by spatulated extensions on the vertical fins.

Summary

1. Structures of the ovary of *Neoditrema ransonneti* are essentially the same as those of *Cymatogaster aggregatus* and *Ditrema temmincki*.
2. Oocytes of *Neoditrema* begin to develop in August and become fully grown in December. During this period, both the ovarian wall and ovigerous folds remain rather undeveloped.
3. The testes of males are clearly distinct just after birth. The females are inseminated soon after birth which occurs in July or in August. The spermatozoa remain in the ovarian cavity.
4. Fertilization takes place in December or in January. Fertilized eggs are discharged from the ovigerous fold into the ovarian cavity soon after fertilization and continue to develop there until July or August in which months the embryos are discharged.
5. In early gestation the ovigerous tissues become considerably swollen and the tissue spaces are filled with fluid. In late gestation these tissue spaces shrink and fluid disappears.
6. The epithelia both of the ovarian wall and ovigerous folds are fairly simple during resting stage of the ovary but greatly increase their secretory activity during the period from just before gestation and early gestation.
7. The blood vessels gradually enlarge and capillaries develop well in networks during gestation.

Literature

- Blake, J.E. (1867). On the nourishment of the foetus in Embiotocoid fishes. *Proc. Cal. Acad. Nat. Sci.* 3, 314-317.
- Eigenmann, C.H. (1892). On the viviparous fishes of the Pacific coast of North America. *Bull. U. S. Fish. Comm.* (1894) 12, 381-478.
- Hubbs, C.L. (1917). The breeding habits of *Cymatogaster aggregatus*. *Copeia* 47, 72-74.
- (1921). The ecology and life-history of *Amphigonopterus aurora* and of other viviparous perches of California. *Biol. Bull.* 40(4), 181-209.
- Ishii, S. (1957). Seasonal changes in the ovary and testis of the viviparous teleost, *Ditrema temmincki*. *Annot. Zool. Japon.* 30(4), 204-210.
- (1960). Effects of testosterone on the *Ditrema temmincki*. *Annot. Zool. Japon.* 33(3), 172-177.
- Mendoza, G. (1937). Structural and vascular changes accompanying the resorption of the proctodaeal processes after birth in the embryos of the Goodeidae, a family of viviparous fishes. *Jour. Morph.* 61, 95-125.
- (1939). The reproductive cycle of the viviparous teleost, *Neotoca bilineata*, a member of the family Goodeidae. I. The breeding cycle. *Biol. Bull.* 76, 359-370.

- (1940). The reproductive cycle of the viviparous teleost, *Neotoca bilineata*, a member of the family Goodeidae. II. The cycle changes in the ovarian soma during gestation. *Biol. Bull.* 78, 349-365.
- (1941). The reproductive cycle of the viviparous teleost, *Neotoca bilineata*, a member of the family Goodeidae. III. The germ cell cycle. *Biol. Bull.* 81, 70-79.
- (1943). The reproductive cycle of the viviparous teleost, *Neotoca bilineata*, a member of the family Goodeidae. IV. The germinal tissue. *Biol. Bull.* 84, 87-97.
- (1956). Adaptation during gestation in the viviparous Cyprinodont teleost, *Hubbsina turneri*. *Jour. Morph.* 99, 73-95.
- Turner, C.L. (1933). Viviparity superimposed upon ovo-viviparity in the Goodeidae, a family of Cyprinodont teleost fishes of the Mexican Plateau. *Jour. Morph.* 55, 207-251.
- (1937). Reproductive cycles and superfetation in Poeciliid fishes. *Biol. Bull.* 72, 145-164.
- (1938a). Histological and cytological changes in the ovary of *Cymatogaster aggregatus* during gestation. *Jour. Morph.* 62, 351-373.
- (1938b). The reproductive cycle of *Brachyrhaphis episcopi*, an ovo-viviparous poeciliid fish, in the natural tropical habitat. *Biol. Bull.* 75, 56-65.
- (1940). Adaptation for viviparity in Jenynsiid fishes. *Jour. Morph.* 67, 291-297.
- (1952). An accessory respiratory device in embryos of the embiotocid fish, *Cymatogaster aggregatus*, during gestation. *Copeia* (3), 146-174.
- Uchida, K. (1938). [Life history of a viviparous teleost, *Ditrema temmincki* BLEEKER.] (in Japanese). *Dobutsugaku Zasshi* (Zool. Mag.) 50, 194.

Explanation of Plates

PLATE I

Fig. 1. Cross-section of the ovary of a young female collected on the 15th August $\times 55$
Ovigerous folds are unfolded and in simple condition.

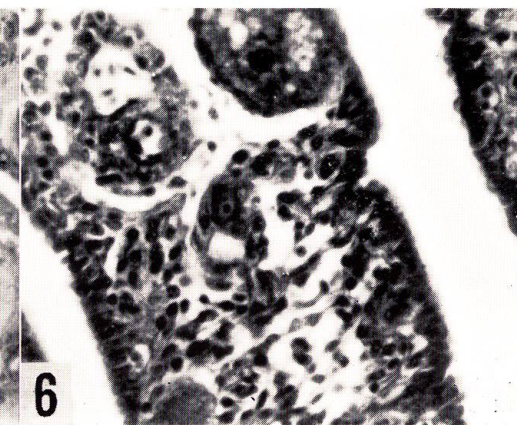
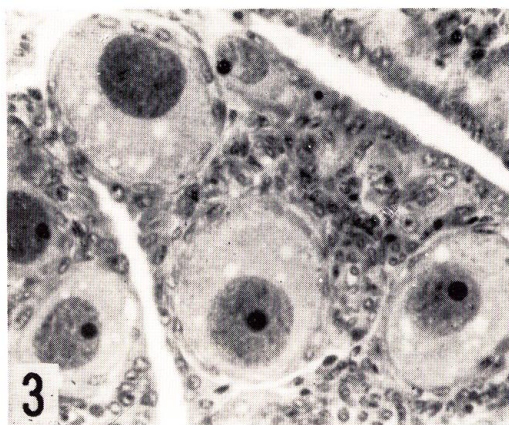
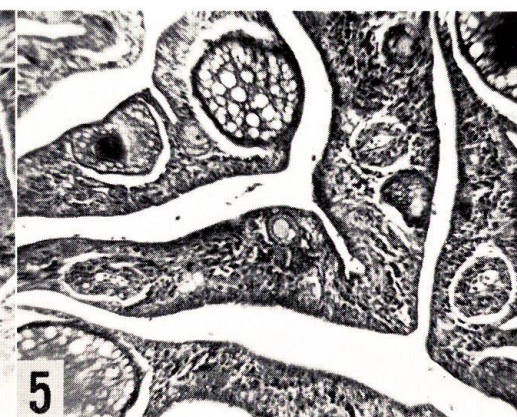
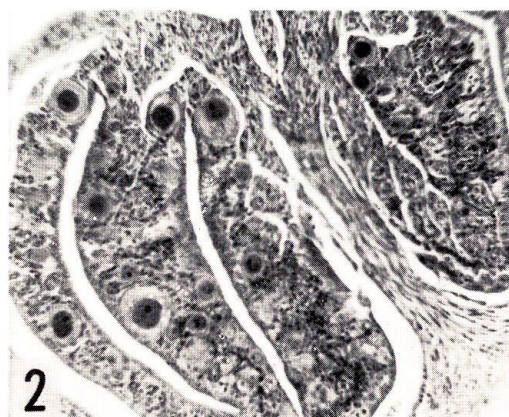
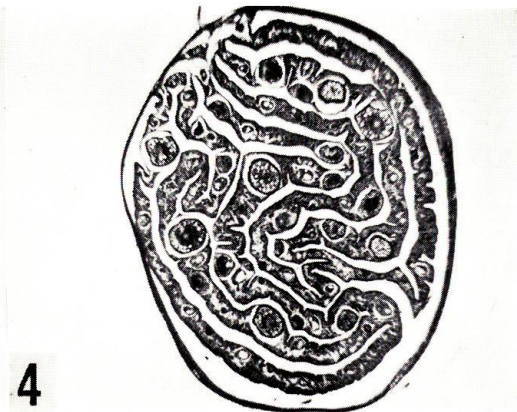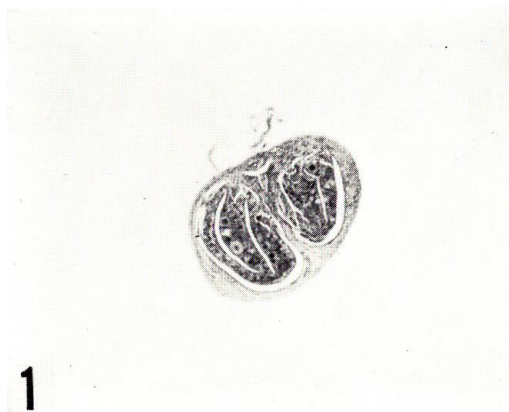
Fig. 2. Magnification of Fig. 1 $\times 270$

Fig. 3. Further magnified view of Fig. 2 $\times 680$ The folds contain stroma cells, connective tissue fibers and developing oocytes.

Fig. 4. Cross-section of the ovary of a female collected on the 20th September $\times 55$
Ovigerous folds are much folded and voluminous.

Fig. 5. Magnification of Fig. 4 $\times 270$ Oocytes are developing further within the ovigerous folds.

Fig. 6. Further magnified view of Fig. 5 $\times 680$ The folds are filled with spindle-like or round stroma cells of which nuclei are pale in color. The epithelial cells are low in height.



T. IGARASHI: Changes in the ovary of *Neoditrema*

PLATE II

All figures were obtained from sections of the ovary of a female collected on the 6th December.

Fig. 1. View of cross-section of the ovary $\times 55$ The muscular layer of ovarian wall is thick.

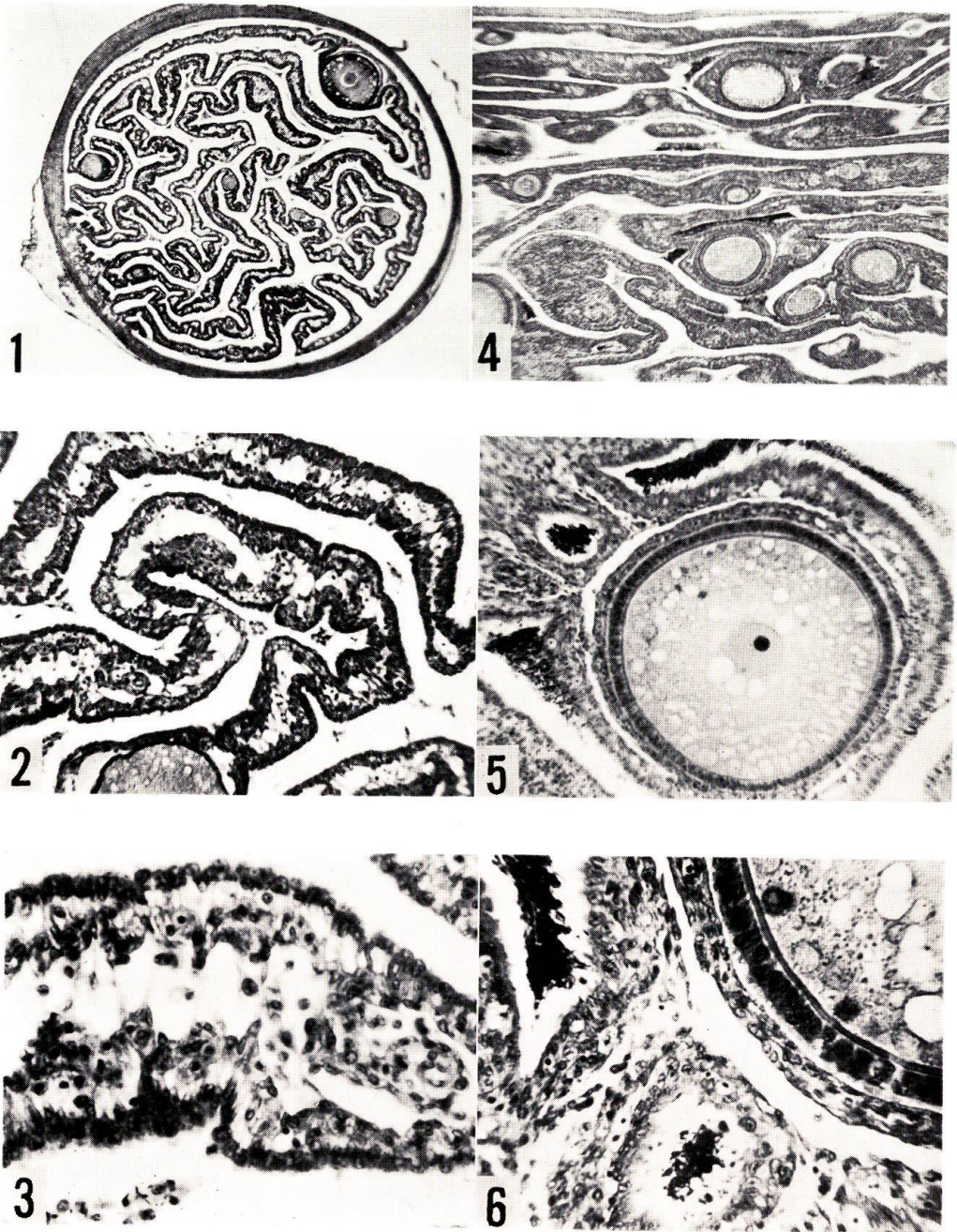
Fig. 2. Magnification of Fig. 1 showing a part of ovigerous folds especially $\times 270$ Tissue spaces are observed extensively in the ovigerous folds.

Fig. 3. Further magnified view of Fig. 2 $\times 680$ Stroma cells and connective tissue fibers are much reduced in number. The epithelial cells are preparing for secretory activity.

Fig. 4. View of a longitudinal section of the ovary $\times 80$ A large number of oocytes are maturing. Sperm masses are found in the ovarian cavity.

Fig. 5. Magnification of Fig. 4 showing one of the oocytes especially $\times 300$

Fig. 6. Further magnified view of Fig. 5 $\times 720$ The oocyte is surrounded by columnar epithelium.



T. IGARASHI: Changes in the ovary of *Neoditrema*

PLATE III

All figures were obtained from cross-sections of the ovary of a female collected on the 10th April.

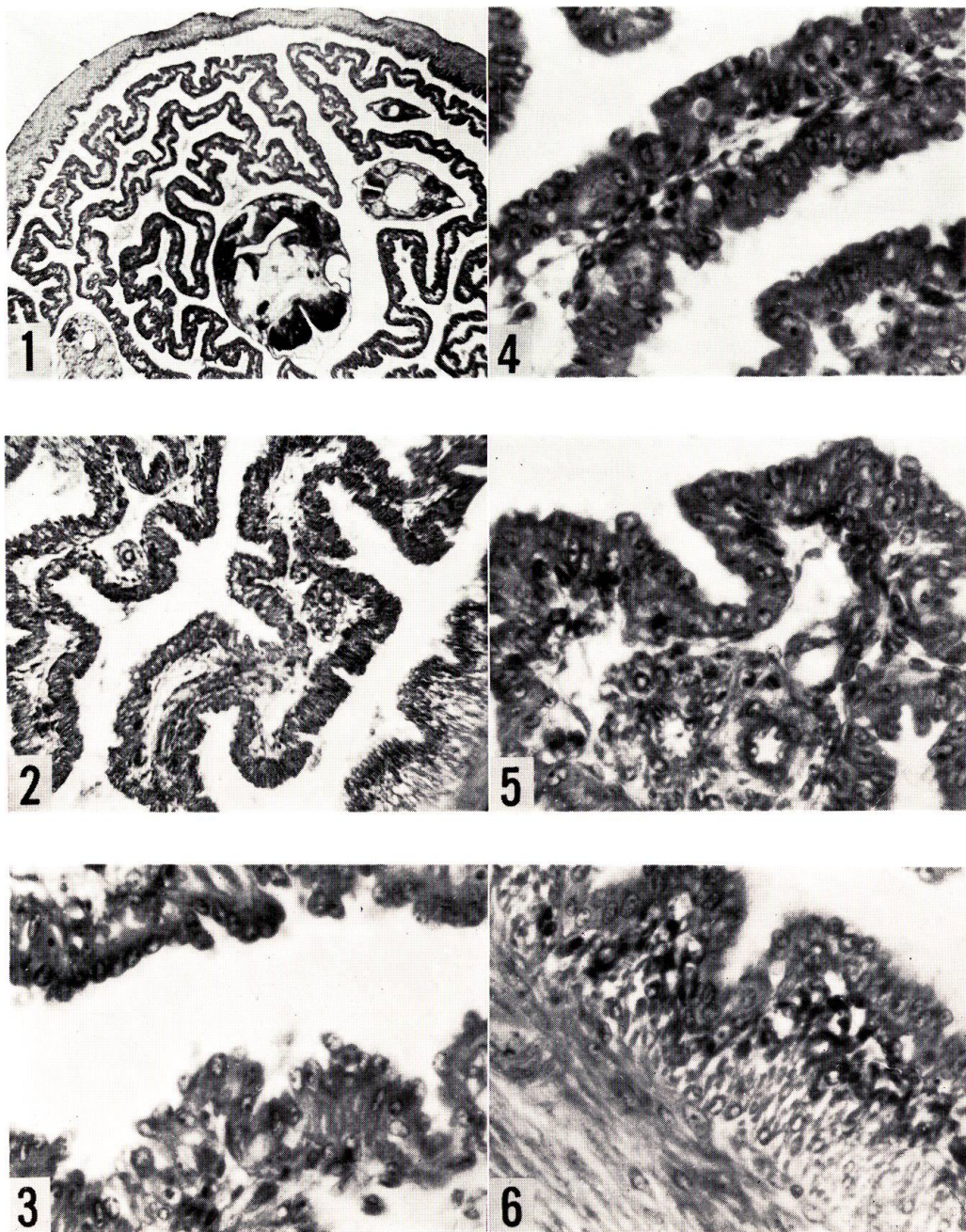
Fig. 1. View of a part of the ovary $\times 55$ Ovarian cavity is mostly occupied by highly wrinkled ovigerous folds. Three embryos are visible.

Fig. 2. Magnification of Fig. 1 $\times 270$ The ovigerous folds are covered with high columnar epithelial cells. Fine blood vessels present in the folds.

Figs. 3 and 4. Further magnified view of Fig. 2 showing a part of the epithelium of the ovigerous folds especially $\times 680$ The cells of the epithelium are large. The epithelium shows that secretory function is carried on actively.

Fig. 5. Further magnified view of Fig. 2 showing the epithelium of the ovigerous fold and blood vessels especially $\times 680$

Fig. 6. Further magnified view of Fig. 2 showing a part of ovarian wall especially. $\times 680$ Inner surface of the ovarian wall is highly rugged. Subepithelial connective tissue layer of the wall is thick.



T. IGARASHI: Changes in the ovary of *Neoditrema*

PLATE IV

All figures were obtained from cross-sections of the ovary of a female collected on the 22th May.

Fig. 1. View of a part of the ovary $\times 55$ Ovigerous folds are still swollen. Three embryos are visible.


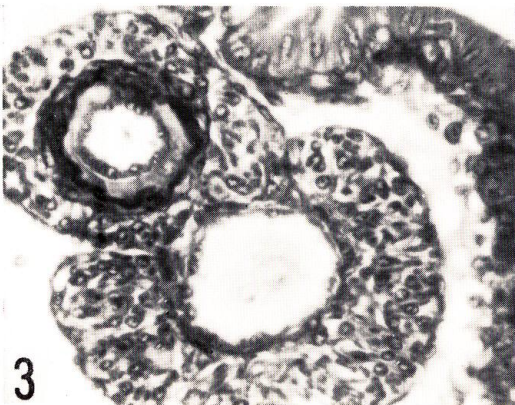
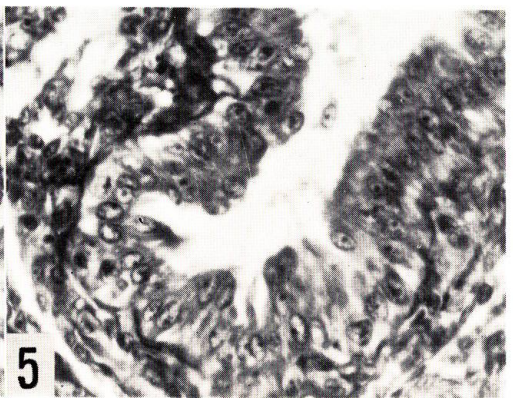
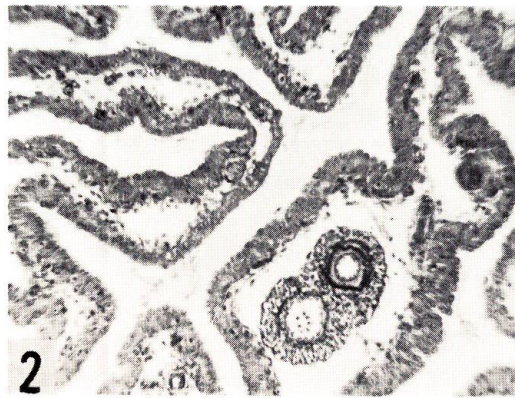
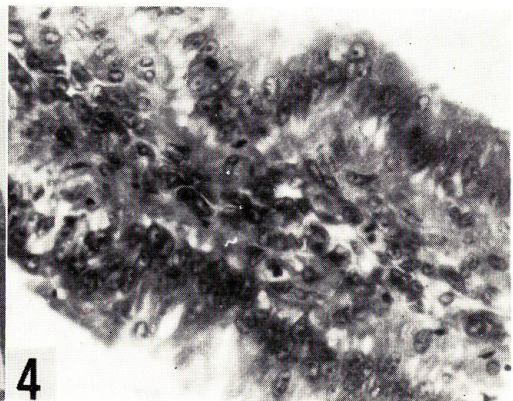
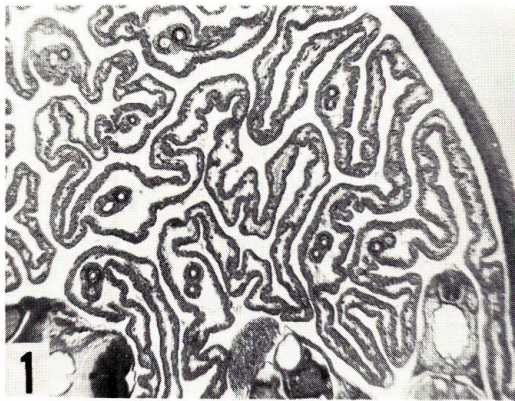
Fig. 2. Magnification of Fig. 1 showing a part of the ovigerous folds especially $\times 270$ The tissue spaces of the ovigerous folds are very large, being filled with fluid. Blood vessels are surrounded by a connective tissue membrane.

Fig. 3. Further magnified view of Fig. 2 showing the blood vessels in the ovigerous fold especially $\times 680$

Fig. 4. Further magnified view of Fig. 2 showing a part of the ovigerous fold especially $\times 680$ The epithelial cells covering the surface are high columnar and hypertrophic.

Fig. 5. Further magnified view of Fig. 2 showing the epithelium of the ovigerous fold especially $\times 680$ The cells of the epithelium are large. Secretory activity is at maximum. Some of the epithelial cells are desquamating into the ovarian cavity and others undergoing vacuolation.

Fig. 6. Further magnified view of Fig. 2 showing a part of the inner surface of ovarian wall especially $\times 680$ State of the epithelium and vascularization are like those of the ovigerous fold shown in Fig. 5.



T. IGARASHI: Changes in the ovary of *Neoditrema*

PLATE V

Fig. 1. View of cross-section of the ovary of a female collected on the 16th July $\times 55$ Embryos are large and at just before birth. Tissue spaces of ovigerous folds are shrinking.

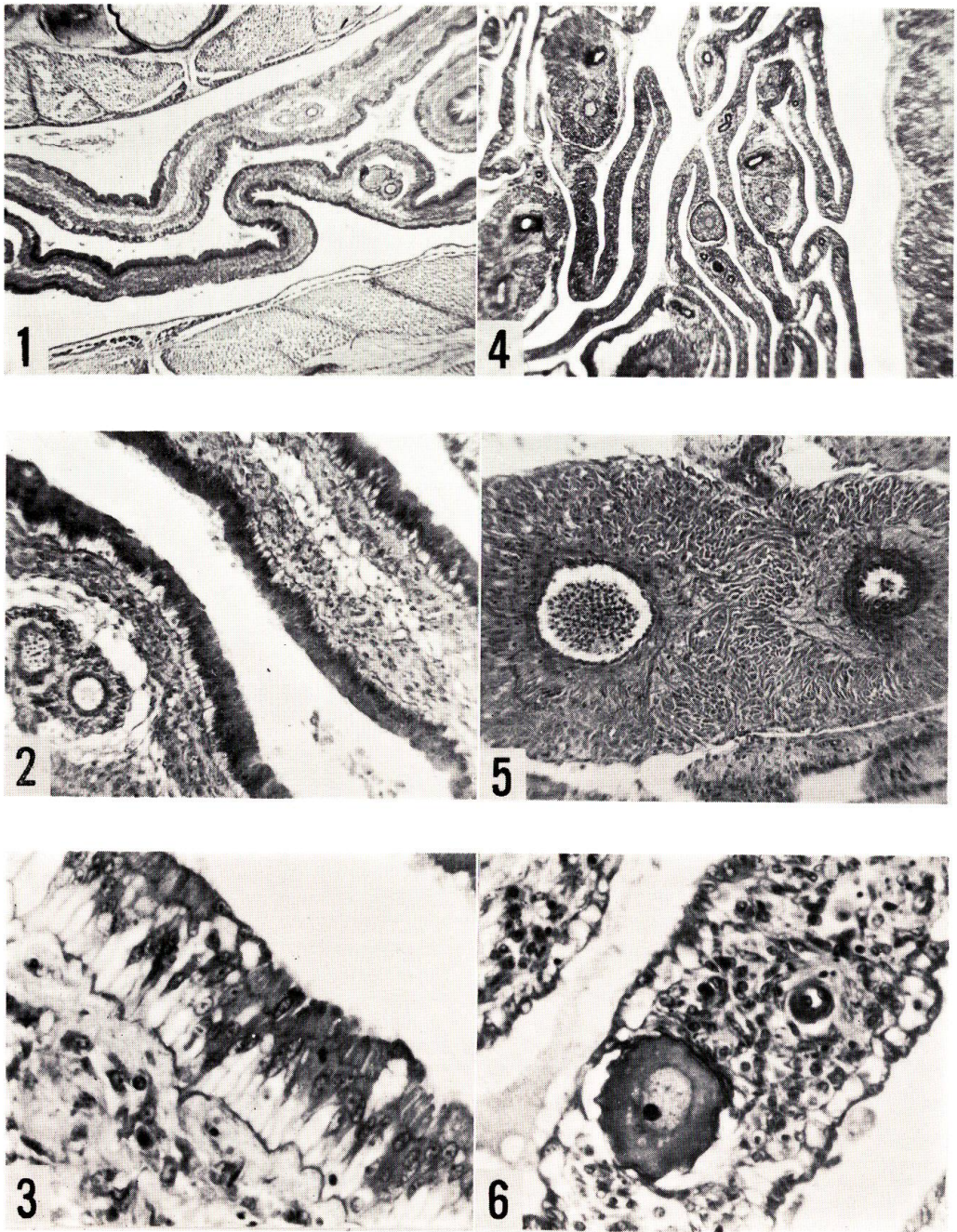
Fig. 2. Magnification of Fig. 1 $\times 270$ Numerous large blood vessels and their fine branches run through the internal tissue of the folds.

Fig. 3. Further magnified view of Fig. 2 showing the epithelium of the ovigerous fold especially $\times 680$ Tissue spaces shrink. Epithelium of ovigerous fold is also shrinking but small fluid reservoirs present at the bases.

Fig. 4. View of cross-section of the ovary of a female collected on the 15th August $\times 55$ An ovary after the discharge of embryos. Epithelia both of ovigerous folds and ovarian wall are being restored to normal condition. Large blood vessels surrounded by a thick connective tissue sheath present.

Fig. 5. Magnification of Fig. 4 showing especially the arteries and veins restored to normality $\times 270$ Arteries and veins are permanently thick and large.

Fig. 6. Further magnified view of Fig. 4 showing a part of the ovigerous folds especially $\times 680$ Epithelial cells are irregular and flat in form. A few small growing oocytes are found in the ovigerous folds.



T. IGARASHI: Changes in the ovary of *Neoditrema*