

Chronic paracoccidioidomycosis in a woman with Crohn Disease

Harim Tavares dos Santos¹ DDS MSc, Bruno Augusto Benevenuto de Andrade² DDS PhD, Darcy Fernandes³ DDS MSc, Daphine Caxias Travassos³ DDS MSc, Andreia Bufalino³ DDS PhD

Affiliations: ¹Department of Oral Pathology, Piracicaba Dental School, State University of Campinas, São Paulo, Brazil, ²Department of Pathology, Rio de Janeiro Dental School, Federal University of Rio de Janeiro, Rio de Janeiro, Brazil, ³Department of Diagnosis and Surgery, Araraquara Dental School, UNESP - Univ Estadual Paulista, Araraquara, São Paulo, Brazil

Corresponding Author: Darcy Fernandes, Department of Diagnosis and Surgery, Univ Estadual Paulista (UNESP), CEP 14801-903, Araraquara, São Paulo, Brazil, E-mail: darcyfernandes@foar.unesp.br

Abstract

We report a rare case of chronic paracoccidioidomycosis (PCM) in a woman with Crohn disease in the setting of treatment with azathioprine and mesalazine. Serum tests for antigens to *Paracoccidioides brasiliensis*, *Histoplasma capsulatum*, and *Aspergillus fumigatus* were negative. An incisional biopsy of an oral lesion with periodic acid-schiff and Grocott-methenamine-silver stains revealed chronic granulomatous inflammation with multinucleated giant cells with *Paracoccidioides brasiliensis* within the cytoplasm, confirming the diagnosis of PCM.

Keywords: paracoccidioidomycosis, Crohn disease, immunosuppressive

Introduction

Paracoccidioidomycosis (PCM) is a common systemic deep fungal infection in Latin America caused by *Paracoccidioides brasiliensis*. Currently, PCM is classified into two main clinical presentations including acute/subacute (juvenile type) and chronic (adult type) forms [1]. Approximately 5% of cases present as the acute form that usually affects children, adolescents, and young adults (under 35 years of age); it affects men and women equally [2]. Symptoms and signs observed in this form include fever, weight loss, mild/moderate anemia, and enlargement of multiple lymph nodes. In addition, organs including liver, spleen, bone marrow, and digestive tract may be affected [2]. The chronic form is the most common presentation (occurs in 90% of cases) and predominantly affects men between the

age of 30-60 years [1, 3]. Clinical manifestations of the chronic form show extensive lung alterations in chest X-ray images with minimal or no respiratory symptoms, and extrapulmonary lesions [1]. However, the findings observed on chest X-ray may display non-specific alterations and chest computed tomography may identify lesions that are imperceptible in plain radiography.

Oral mucosa or skin lesion are characterized by a solitary or multiple mulberry-like or ulcerated lesions and may be the first clinical sign indicating the disease in both forms [4]. Histopathologically, pseudoepitheliomatous hyperplasia, epithelioid granulomas, and polygemmulating yeasts that range from 6µm to 20µm are typically observed [5]. Another microscopic finding is the presence of multiple spores that can be up to 60µm in diameter [5]. Oral itraconazole is the treatment of choice for PCM [1].

Crohn disease (CD) is a chronic inflammatory condition that can affect any part of the digestive tract. Most of the patients are women diagnosed before the age of 40 [6]. Oral manifestations include cobblestoning, ulceration, mucosal tags, and mucogingivitis [7]. Microscopically, CD is characterized by non-necrotizing granulomatous inflammation in the connective tissue [7]. Therapeutic management comprises a wide range of drugs, including immunosuppressive agents, such as azathioprine (AZA). Immunosuppressive medications like azathioprine can increase a patient's risk for opportunistic oral infections [8].

To the best of our knowledge, no case of concomitant

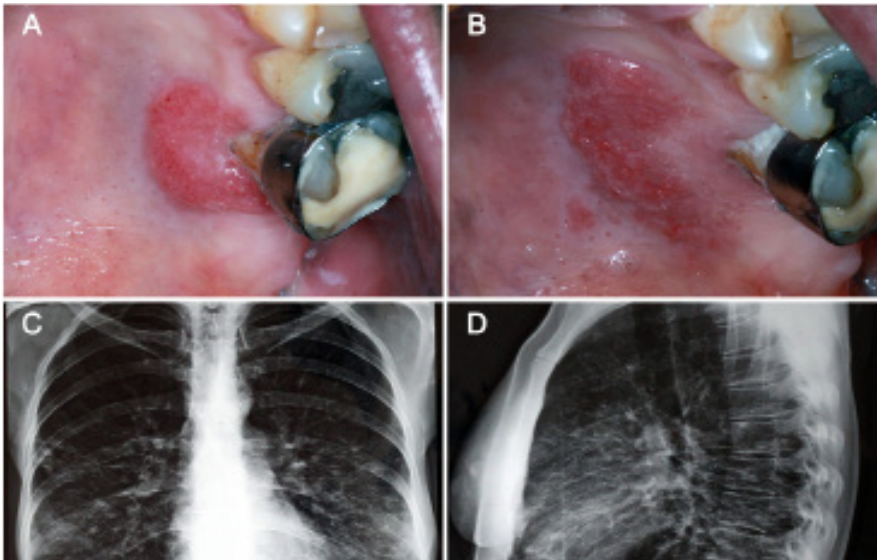


Figure 1. Clinical aspect of oral paracoccidioidomycosis. (A) Initial presentation of the lesion. (B) One month later an expansion of the eroded area was observed. Radiographic aspect of lungs with radiopaque diffuse areas. (C) Posteroanterior view. (D) Lateral chest x-ray.

erythematous 2.5cm erosion on the palatine gingiva bearing the first left superior molar (**Figure 1A**). The patient had noticed the lesion 20 days prior. Her medical history was significant for tobacco use and a 10 year history of treatment with azathioprine (100mg/day) and mesalazine (150mg/day) for CD. Based on the clinical presentation, oral manifestation of CD, fungal infection, and syphilis were included in the main differential diagnosis. Our patient refused biopsy initially. Chest X-ray and blood tests were obtained. Blood tests included hemogram, fungal serology, erythrocyte sedimentation rate (ESR), serum glutamic oxaloacetic transaminase (SGOT), serum glutamic pyruvate transaminase (SGPT), gamma glutamyl transferase, alkaline, potassium, and sodium phosphate.

One month later, the lesion had enlarged, measuring 3 cm, with migration toward the median palatine raphe (**Figure 1B**). The blood test results were within normal limits, except for ESR (1^o hour – 37mm / 2^o hour – 72mm) that was above reference normal values. Chest x-ray showed radiopaque diffuse areas in both lungs (**Figure 1 C and D**). An incisional biopsy of the hard palate was performed. Pathology demonstrated epithelial pseudoepitheliomatous hyperplasia with intraepithelial microabscesses (**Figure 2 A and B**). The connective tissue subjacent to the mucosa epithelium was characterized by densely inflamed granulomatous tissue with lymphocytic infiltrate, epithelioid macrophages, and multinucleated giant cells containing yeasts that were

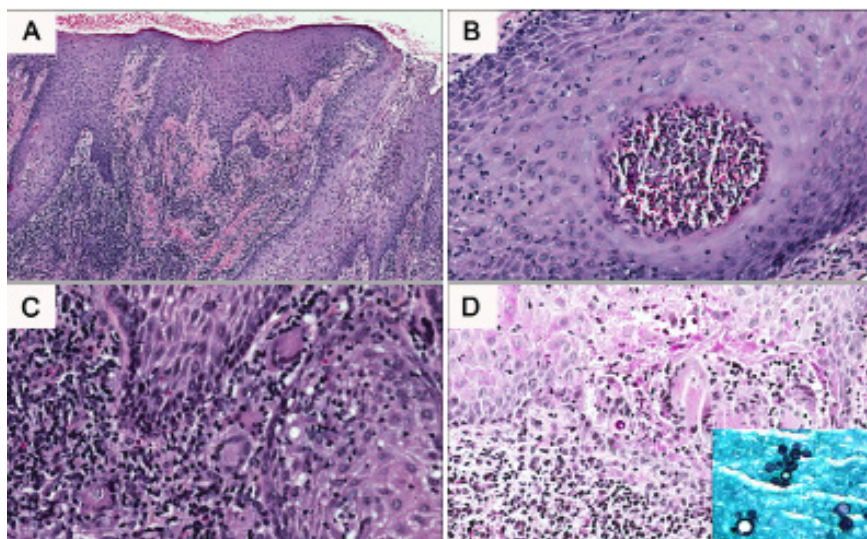


Figure 2. Histopathological aspects of oral paracoccidioidomycosis. (A) Oral mucosa fragment presenting pseudoepitheliomatous hyperplasia and diffuse inflammatory infiltrate in the submucosa (H&E, 100x). (B) Intraepithelial microabscess (H&E, 200x). (C) Granulomatous inflammation composed by lymphocytes, epithelioid macrophages, and multinucleated giant cells with phagocytosed *P. brasiliensis* (H&E, 200x). (D) - PAS staining evidencing the presence of the fungus (200x). In detail, Grocott staining showing budding cells.

occurrence of CD and oral PCM has been described in the literature. We report a rare case of a chronic paracoccidioidomycosis (PCM) in a woman with Crohn disease controlled for 10 years with immunosuppressive drugs.

Case Synopsis

A 48-year-old woman was referred to our clinic for a nonbleeding, painless, rough, granular

double-contoured with round structures (**Figure 2C**). Periodic acid–Schiff (PAS) staining confirmed the presence of fungus in the specimen (**Figure 2D**). The clinical and histopathological features rendered the final diagnosis of paracoccidioidomycosis. Review of intestinal biopsy was performed and it showed granulomas with lymphoid aggregates and epithelioid macrophages without the presence of giant cells, confirming the diagnosis of CD and

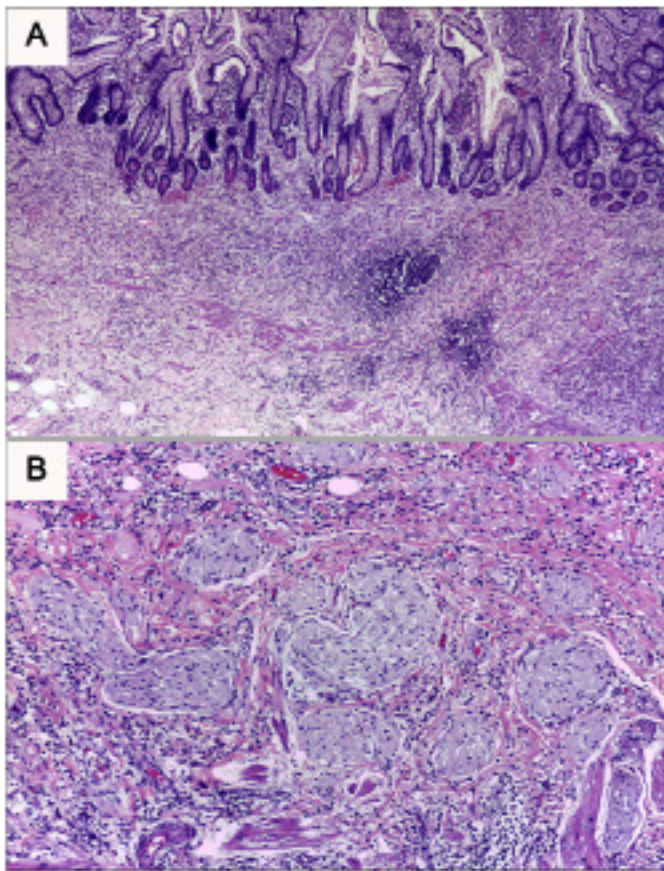


Figure 3. Histopathological aspects of small intestine of the patient. (A) Small intestine fragment with a mixed inflammatory cell infiltrate affecting all layers of the bowel wall. Lymphoid follicles are also seen in the lamina propria (H&E, 100x). (B) The granulomas can be observed in some areas of the intestine fragment (H&E, 200x).

ruling out the possibility of PCM in the intestinal mucosa (**Figure 3** A and B). Currently, the patient has temporarily suspended the use of mesalazine and has started paracoccidioidomycosis treatment with itraconazole (400mg/day). A second fungal serology test was performed and, in contrast to the first exam, the result was positive. In the 6-month follow up, there was remarkable decrease in size of the lesion (**Figure 4**).

Case Discussion

Paracoccidioidomycosis is an endemic systemic mycosis in Latin America caused by a dimorphic microorganism with the capability of complex modifications in vivo. In the chronic (adult) form, which accounts for up to 90% of cases, there is a predilection to males between 30 and 60 years of age [1]. A possible explanation is that estradiol, a female hormone, prevents the phenotypic transformation of mycelia to the pathogenic yeast form [9]. As

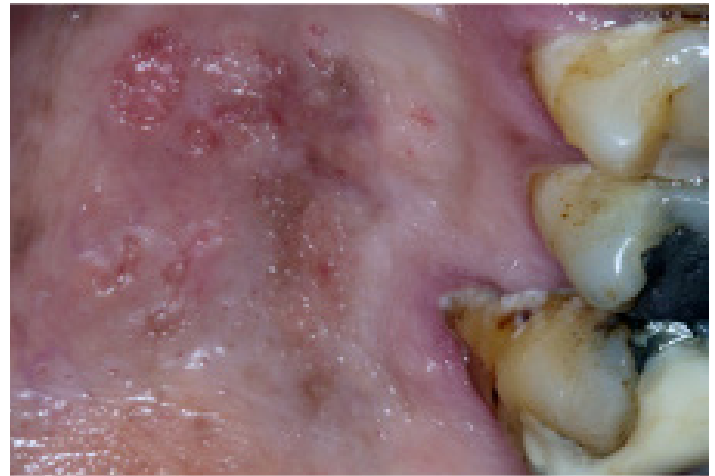

Figure 4. A marked improvement in the lesions was observed at 6 months follow-up of treatment with a dose of 400mg/day of itraconazole.

such, menopause may be the explanation as to why PCM occurs in older women. It could be that the deficiency in estradiol production leads to decreased hormonal protection [4]. However, our patient denied menopause and other possible predisposing factors were evaluated.

A wide variety of drugs are used in the treatment of CD, including mesalazine, corticosteroids, immunosuppressive drugs, and biologic agents [8]. In patients treated with azathioprine, an immunosuppressant, opportunistic infection may be an adverse complication in 6% of cases [10]. A case-control study demonstrated that the myelosuppression mediated by active metabolites of AZA therapy was mainly related to the development of viral infections, including herpes simplex, varicella zoster, cytomegalovirus, and Epstein-Barr virus [11]. AZA treatment was also related to the development of opportunistic fungal infection, such as cryptococcosis [12]. We believe that impaired immunity caused by AZA therapy predisposed our patient to the *Paracoccidioides brasiliensis* infection.

The gold standard for PCM diagnosis is culture, but other diagnostic methods include histopathological, serological (immunodiffusion), and molecular studies [13]. Our patient had two serological tests for *Paracoccidioides brasiliensis*. The first test was negative, but the second showed a positive result. The histopathological presentation of the lesion led us to the diagnosis of PCM; we considered the first serological test to be a false-negative result. PCM

serology exams with false negative results may occur in limited lesions as well as in immunosuppressed patients [14]. Interestingly, CD could cause a decreased response and delayed hypersensitivity [15]. Additionally, AZA is a drug with side effects such as leukopenia and inhibition and apoptosis of T cells causing an anergic status [16]. Thus, we propose that CD and therapy with AZA caused our patient to be in a state of immunodeficiency that resulted in chronic PCM infection and a false-negative status in the first serologic test for paracoccidioidomycosis.

Additionally, the involvement of the intestinal mucosa by PCM may be misdiagnosed as CD, as shown in a previous case report [17]. Therefore, reevaluation of the intestinal mucosa biopsy that was previously diagnosed with CD in our patient was necessary to rule out PCM. This fungal infection may have similar clinical manifestations of CD in the gastrointestinal mucosa.

The treatment of PCM requires drug therapy with loading doses, nutritional support, management of sequelae, and rigorous follow-up. The choice of drug and treatment duration will depend on the severity of the disease and general health state of the patient. A wide variety of drugs can be used to treat PCM. Sulphone derivatives were the first drugs ever used for PCM treatment but an extended treatment time is required with many daily administrations. Amphotericin B is indicated in severe cases but toxicity and side effects are inherent to its intravenous administration, requiring patient hospitalization. Ketoconazole also is an alternative but is not the first-choice drug because of its important side effects, like the high rate of hepatotoxicity when used for extended periods. Ketoconazole also has significant rates of failure and relapse. Voriconazole is indicated, especially in neuro-paracoccidioidomycosis, even though its elevated cost is a disadvantage compared with the other drugs. As nephrotoxicity is an important side effect in most of these drugs, monitoring of renal function is crucial in these patients [2, 18]. Oral itraconazole is the drug indicated for treatment of PCM in mild and moderate cases as the first choice for either acute or chronic forms [19]. However, administration of itraconazole can result in several side effects, like hepatotoxicity [20]. Mesalazine is a drug with anti-inflammatory

and immunomodulatory properties used in the treatment of CD [21]. Despite its benefits, it also can cause hepatotoxicity [22]. Hence, the decision to discontinue mesalazine during itraconazole treatment was made to avoid a possible synergistic effect, particularly hepatotoxicity, as a result of the drug combination. Interestingly, the concomitant use of corticosteroids during antifungal therapies has showed clinical improvement and prevention of fibrosis and retraction in severe and disseminated PCM forms [23].

Conclusion

In summary, we reported a rare case of a patient with Crohn disease and concomitant oral paracoccidioidomycosis. The immunity suppression caused by treatment with azathioprine may have predisposed our patient to the PCM infection. Furthermore, it is necessary to be aware of false negative results in serology tests, highlighting the value of the histopathologic assessment to make the correct diagnosis.

References

1. Shankar J, Restrepo A, Clemons KV, Stevens DA. Hormones and the resistance of women to paracoccidioidomycosis. *Clin Microbiol Rev.* 2011 Apr;24(2):296-313. doi:10.1128/CMR.00062-10. [PMID: 21482727]
2. Bocca AL, Amaral AC, Teixeira MM, Sato PK, Shikanai-Yasuda MA, Soares Felipe MS. Paracoccidioidomycosis: eco-epidemiology, taxonomy and clinical and therapeutic issues. *Future Microbiol.* 2013 Sep;8(9):1177-91. doi:10.2217/fmb.13.68. [PMID: 24020744]
3. Meneses-García A, Mosqueda-Taylor A, Morales-de la Luz R, Rivera LM. Paracoccidioidomycosis: report of 2 cases mimicking squamous cell carcinoma. *Oral Surg Oral Med Oral Pathol Oral Radiol Endod.* 2002 Nov;94(5):609-13. [PMID: 12424456]
4. Bicalho RN, Santo MF, de Aguiar MC, Santos VR. Oral paracoccidioidomycosis: a retrospective study of 62 Brazilian patients. *Oral Dis.* 2001 Jan;7(1):56-60. [PMID: 11354923]
5. Fernandez-Flores A, Saeb-Lima M, Arenas-Guzman R. Morphological findings of deep cutaneous fungal infections. *Am J Dermatopathol.* 2014 Jul;36(7):531-53; quiz 554-6. doi: 10.1097/DAD.0b013e31829cc6f3. [PMID: 24950417]
6. Freeman HJ. Application of the Vienna Classification for Crohn's disease to a single clinician database of 877 patients. *Can J Gastroenterol.* 2001 Feb;15(2):89-93. [PMID: 11240378]
7. Plauth M, Jenss H, Meyle J. Oral manifestations of Crohn's disease. An analysis of 79 cases. *J Clin Gastroenterol.* 1991 Feb;13(1):29-37. [PMID: 2007740]
8. Fatahzadeh M. Inflammatory bowel disease. *Oral Surg Oral Med Oral Pathol Oral Radiol Endod.* 2009 Nov;108(5):e1-10. doi: 10.1016/j.tripleo.2009.07.035. [PMID: 19836703]
9. Borges-Walmsley MI, Chen D, Shu X, Walmsley AR. The pathobiology of Paracoccidioides brasiliensis. *Trends Microbiol.* 2002 Feb;10(2):80-7. [PMID: 11827809]
10. Singh G, Fries JF, Spitz P, Williams CA. Toxic effects of azathioprine in rheumatoid arthritis. A national post-marketing perspective.

- Arthritis Rheum. 1989 Jul;32(7):837-43. [PMID: 2751718]
11. Toruner M, Loftus EV Jr, Harmsen WS, Zinsmeister AR, Orenstein R, Sandborn WJ, Colombel JF, Egan LJ. Risk factors for opportunistic infections in patients with inflammatory bowel disease. *Gastroenterology*. 2008 Apr;134(4):929-36. doi:10.1053/j.gastro.2008.01.012. [PMID: 18294633]
 12. Fraison JB, Guilpain P, Schiffmann A, Veyrac M, Le Moing V, Rispaïl P, Le Quellec A. Pulmonary cryptococcosis in a patient with Crohn's disease treated with prednisone, azathioprine and adalimumab: exposure to chicken manure as a source of contamination. *J Crohns Colitis*. 2013 Feb;7(1):e11-4. doi:10.1016/j.crohns.2012.04.016. [PMID: 22647638]
 13. Marques SA. Paracoccidioidomycosis. *Clin Dermatol*. 2012 Nov-Dec;30(6):610-5. doi:10.1016/j.clindermatol.2012.01.006. [PMID: 23068148]
 14. Shikanai-Yasuda MA, Telles Filho Fde Q, Mendes RP, Colombo AL, Moretti ML. [Guidelines in paracoccidioidomycosis] *Rev Soc Bras Med Trop*. 2006 May-Jun;39(3):297-310. Portuguese. [PMID: 16906260]
 15. Cardoso IP, de Almeida NP, Gotardo DR, Cardeal M, Santana GO. Tuberculin skin testing in inflammatory bowel disease patients from an endemic area of Brazil. *Braz J Infect Dis*. 2014 Jan-Feb;18(1):60-4. doi: 10.1016/j.bjid.2013.05.008. [PMID: 24055308]
 16. Aberra FN, Stettler N, Brensinger C, Lichtenstein GR, Lewis JD. Risk for active tuberculosis in inflammatory bowel disease patients. *Clin Gastroenterol Hepatol*. 2007 Sep;5(9):1070-5. [PMID: 17627901]
 17. Cury MS, Ribeiro BS, Costa PP, de Lima VM, Mizsputen SJ, Ferrari AP. Paracoccidioidomycosis masquerading as Crohn's disease. *Gastrointest Endosc*. 2000 Jun;51(6):722-3. [PMID: 10840309]
 18. Abreu e Silva MÃ, Salum FG, Figueiredo MA, Cherubini K. Important aspects of oral paracoccidioidomycosis--a literature review. *Mycoses*. 2013 May;56(3):189-99. doi: 10.1111/myc.12017. [PMID: 23088400]
 19. Queiroz-Telles F, Goldani LZ, Schlamm HT, Goodrich JM, Espinel-Ingroff A, Shikanai-Yasuda MA. An open-label comparative pilot study of oral voriconazole and itraconazole for long-term treatment of paracoccidioidomycosis. *Clin Infect Dis*. 2007 Dec 1;45(11):1462-9. [PMID: 17990229]
 20. Amichai B, Grunwald MH. Adverse drug reactions of the new oral antifungal agents--terbinafine, fluconazole, and itraconazole. *Int J Dermatol*. 1998 Jun;37(6):410-5. [PMID: 9646122]
 21. Hanauer SB, Sandborn W; Practice Parameters Committee of the American College of Gastroenterology. Management of Crohn's disease in adults. *Am J Gastroenterol*. 2001 Mar;96(3):635-43. [PMID: 11280528]
 22. Deltenre P, Berson A, Marcellin P, Degott C, Biour M, Pessayre D. Mesalazine (5-aminosalicylic acid) induced chronic hepatitis. *Gut*. 1999 Jun;44(6):886-8. [PMID: 10323894]
 23. Benard G, Campos AF, Netto LC, Gonçalves LG, Machado LR, Mimicos EV, França FO, Gryscek RC. Treatment of severe forms of paracoccidioidomycosis: is there a role for corticosteroids? *Med Mycol*. 2012 Aug;50(6):641-8. doi:10.3109/13693786.2011.654135. [PMID: 22309459]