

Vulvar edema: diagnostic clue to Crohn disease

Maria Garayar Cantero MD, Jara Valtueña PhD, Daniel Ruiz-Sánchez PhD, Pilar Manchado López MD, Alicia Pérez-Bustillo PhD

Affiliations: Hospital Clínico Universitario de Valladolid, Calle Ramón y Cajal 3, Valladolid, Spain

Corresponding Author: Maria Garayar Cantero, Calle Ramón y Cajal 3, 47003 Valladolid, Spain, Tel: 34-680711173, Mariagarayar@gmail.com

Abstract

Vulvar lesions are clinically challenging for physicians because the differential diagnosis may include many entities. Vulvar edema is one of the most frequent symptoms and is normally attributed to a local cause. Herein, we present a case report of vulvar Crohn disease (VCD) in a 9-year-old girl, in which skin lesions preceded the systemic gastrointestinal symptoms. Both clinical features and histopathological findings guided us to an early Crohn disease (CD) diagnosis. Dermatologists often have the opportunity to detect systemic diseases at early stages. A good knowledge of the CD skin manifestations could lead to an early CD diagnosis, especially in children. The suspicion of CD in those cases in which cutaneous involvement precedes digestive symptoms is crucial to prevent future psychological and physical consequences.

Keywords: Crohn disease, vulvar edema, swelling

Introduction

Vulvar lesions are clinically challenging for physicians because signs and symptoms in this area can suggest a number of entities in the differential diagnosis. Vulvar edema is associated with a wide range of medical conditions (**Table 1**), [1].

Table 1. Etiology of vulvar edema [1].

Inflammatory etiology	Tumoral pathology	Infectious etiology	Mechanical etiology
Irritant contact dermatitis	Ectopic mammary gland tissue	Recurrent vulvovaginal candidiasis	Edema associated with pregnancy
Allergic contact dermatitis	Subcutaneous tumors mimicking edema (e.g.: lymphatic malformations)	Herpes simplex virus	Edema associated with delivery
Hidradenitis suppurative	Tumors causing pelvic obstruction		
	Post-radiation therapy or post-surgery changes		

Case Synopsis

A 9-year-old girl was referred to our clinic with a 12-month history of fluctuating asymmetrical vulvar swelling. Her past medical history was unremarkable. A family history of psoriasis and CD in her father was reported. Review of systems revealed no abdominal pain and no diarrhea or altered stooling pattern at that time.

On physical examination a marked nontender edema of the right labia majora with erythematous overlying skin was seen (**Figure 1**). No other skin abnormalities were found. An ultrasound showed a non-encapsulated hypertrophy of the vulvar adipose tissue. Histological analysis identified multiple non-necrotizing granulomas with multinucleated giant cells in the dermis (**Figure 2**). Staining for fungi and atypical mycobacteria were negative. On further questioning, she admitted to episodes of abdominal pain, diarrhea, and occasional bloody stools that had just started during the last three weeks. The diagnosis of vulvar metastatic CD was then seriously considered. An upper endoscopy and colonoscopy were requested and no abnormalities were observed. In order to rule out bowel involvement, our patient underwent a capsule endoscopy which confirmed the diagnosis of small bowel CD.

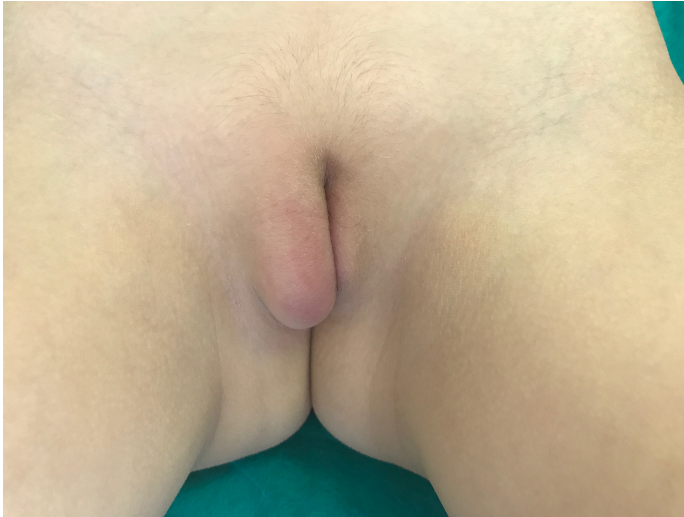

Figure 1. Marked edema of the right labia majora with erythematous overlying skin.

Once the diagnosis of metastatic vulvar Crohn disease (VCD) prior to the onset of bowel CD was established, the patient began treatment with azathioprine 50mg and metronidazole 250mg per day with resolution of the recurrent vulvar edema and improvement of her gastrointestinal symptoms.

Case Discussion

Vulvar Crohn disease (VCD) is an infrequent entity occurring in approximately 2% of women with CD and it is even more rarely described in children [2]. Contrary to our case, VCD occurs in more than 75% of the cases after the confirmation of CD [3]. However, skin involvement could be the first and only sign, greatly increasing the difficulty of an early CD recognition.

We describe a child with asymmetrical recurrent labial swelling without the accompanying perianal lesions that are typically observed in 90% of patients with VCD [4]. Our case became even more challenging because in addition to skin involvement preceding digestive symptoms, the upper endoscopy and colonoscopy did not show any relevant findings. An endoscopic capsule was required to reach the final diagnosis. The suspicion of CD in those cases in which cutaneous involvement occurs prior to gastrointestinal symptoms is crucial to prevent future psychological and physical consequences.

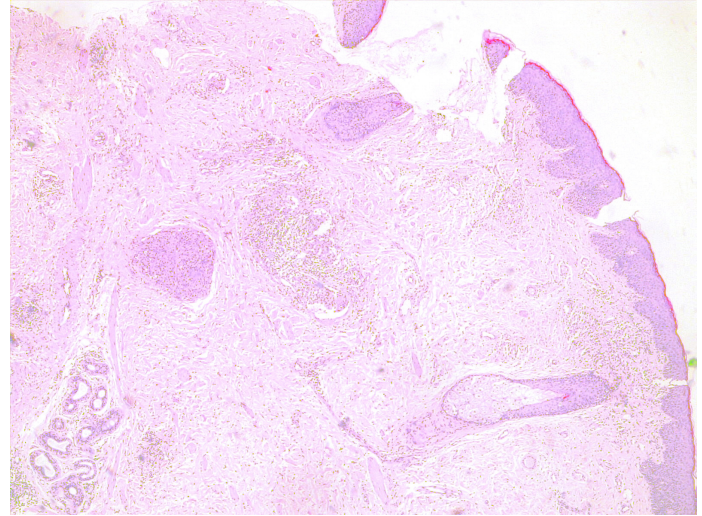


Figure 2. Multiple dermal non-necrotizing granulomas with multinucleated giant cells. H&E, 4x.

Apart from vulvar edema, other vulvar clinical manifestations can be found: superficial, deep or “knife-like” ulcerations, hypertrophic plaques, and chronic suppuration. Cutaneous manifestations related to CD appear in approximately 22–40% of patients [2]. These can be classified into five types [5].

Firstly, disease-specific lesions. These are caused by direct extension of intestinal involvement or non-contiguous (metastatic disease) in which there is no connection between the inflamed bowel and the skin lesions. Their main characteristic is that cutaneous changes share same histopathologic findings as the underlying GI disease.

Secondly, reactive lesions as neutrophilic entities such as pyoderma gangrenosum or Sweet syndrome, which have their own diagnostic histopathology. Thirdly, one must be aware of other associated conditions, believed to be linked by the same HLA pattern such as erythema nodosum.

Finally, one must be aware of conditions related to complications. On the one hand, complications related to the disease such as perianal, perivaginal, enterovaginal, and enterocutaneous fistulas or abscesses. On the other hand, some complications are related to treatments, such as exanthematous drug eruptions.

Medical therapeutic alternatives for VCD include metronidazole, corticosteroids, sulfasalazine, azathioprine, cyclosporine, and anti-TNF biologics. In

our experience, treatment of VCD was successful with metronidazole and azathioprine. When medical management fails, surgery could be considered in selected cases [6].

Conclusion

Dermatologists often have the opportunity to detect systemic diseases at early stages. A good knowledge of CD skin manifestations could lead to an early CD

diagnosis, especially in children. In our opinion, this report illustrates a characteristic clinical appearance of VCD and presents the peculiarity that it is a child-aged patient in whom skin involvement preceded the digestive symptoms.

Potential conflicts of interest

The authors declare no conflicts of interests.

References

1. Amankwah Y, Haefner H. Vulvar edema. *Dermatol Clin*. 2010;28:765-777. [PMID: 20883919].
2. Granese R, Calanga G, Morabito G, et al. Vulvar involvement in pediatric Crohn's disease: a systematic review. *Arch Gynecol Obstet*. 2018;297:3-11. [PMID: 28948431].
3. Das D, Gupta B, Saha M. Metastatic vulvar Crohn's disease-a rare case report and short review of literature. *Indian J Dermatol*. 2016;61:70-74. [PMID: 26955098].
4. Bouzidi H, Chakiri R, Amraoui N, et al. Crohn's disease presenting as vulvar edema in a 15-year-old Girl. *Dermatol Case Rep*. 2014;8:75-7. [PMID: 25324909].
5. Barret M, deParades V, Battistella M, et al. Crohn's disease of the vulva. *J Crohns Colitis*. 2014;8:563-7. [PMID: 24252167].
6. Corbett SL, Walsh CM, Spitzer RF, et al. Vulvar inflammation as the only clinical manifestation of Crohn disease in an 8-year-old girl. *Pediatrics*. 2010;125:e1518-22. [PMID: 20457677].