



ELSEVIER

## Genetics of Craniosynostosis

Virginia Kimonis, MD, MRCP,\* June-Anne Gold, MD, MRCPCH,\*

Trevor L. Hoffman, MD, PhD,<sup>†</sup> Jayesh Panchal, MD, MBA,<sup>‡</sup> and Simeon A. Boyadjiev, MD<sup>§</sup>

**Craniosynostosis is a defect of the skull caused by early fusion of one or more of the cranial sutures and affects 3 to 5 individuals per 10,000 live births. Craniosynostosis can be divided into two main groups: syndromic and nonsyndromic. Nonsyndromic craniosynostosis is typically an isolated finding that is classified according to the suture(s) involved. Syndromic craniosynostosis is associated with various dysmorphisms involving the face, skeleton, nervous system, and other anomalies and is usually accompanied by developmental delay. More than 180 syndromes exist that contain craniosynostosis. Secondary effects of craniosynostosis may include vision problems and increased intracranial pressure, among others. The molecular basis of many types of syndromic craniosynostosis is known, and diagnostic testing strategies will often lead to a specific diagnosis.**

**Semin Pediatr Neurol 14:150-161 © 2007 Elsevier Inc. All rights reserved.**

Craniosynostosis, the premature fusion of one or more cranial sutures, is a common malformation occurring in 1 of 2,000 live births. Calvarial sutures are articulations along the margins of adjacent intramembranous bones. The function of the suture is to permit molding at the birth canal, adjustment for the expanding brain, and absorption of mechanical trauma in childhood. Fontanelles are formed at the junctional boundaries of the cranial sutures where larger areas of connective tissue occur without underlying bone. The fusion of sutures that accompanies normal development leads to closure of the posterior (formed at the junction of sagittal and lambdoid sutures) and anterior (formed at the junction of sagittal, coronal, and frontal sutures) fontanelles by 3 and 20 months, respectively. Craniosynostosis results from premature ossification and fusion of the skull sutures and generally results in alteration of the shape of the cranial vault and/or premature closure of the fontanelles. Craniosyn-

ostosis may be characterized as simple (involving 1 suture) or complex (involving two or more sutures), primary (caused by an intrinsic defect in the suture) or secondary (premature closure of normal sutures because of another medical condition such as deficient brain growth), and isolated (occurring without other anomalies) or syndromic (accompanied by other dysmorphic features or developmental defects). All subclassifications of craniosynostosis can be genetic. The following are the frequencies of the various sutures involved: (1) sagittal: 40% to 58%, etiology unknown; (2) coronal: 20% to 29%, estimated one third caused by single-gene mutations; (3) metopic: 4% to 10%, etiology unknown; and (5) lambdoid: 2% to 4%, etiology unknown.

The alteration in shape of the cranial vault varies with sutures fused, such that compensatory growth occurs in dimensions not restricted by sutures. Normally, the skull grows in planes perpendicular to the sutures, but premature fusion forces growth in a plane parallel to the closed suture.

When associated anomalies or delays are present, the possibility of a syndrome should be considered. There are more than 180 syndromes that manifest craniosynostosis, and significant progress has been made in understanding their clinical and molecular aspects. Mutations in the *FGFR1*, *FGFR2*, *FGFR3*, *TWIST1*, and *MSX2* genes cause the most common and/or well-characterized syndromes. Approximately 85% of cases are believed to be nonsyndromic with no identifiable gene mutation. Recent studies have found an unexpectedly high incidence of medical problems among children with nonsyndromic craniosynostosis (NSC), such as increased intracranial pressure (ICP),<sup>1-3</sup> learning disabilities in sagittal craniosynostosis,<sup>4,5</sup> and strabismus and amblyopia in coronal

\*Division of Genetics and Metabolism, Department of Pediatrics, University of California, Irvine, CA.

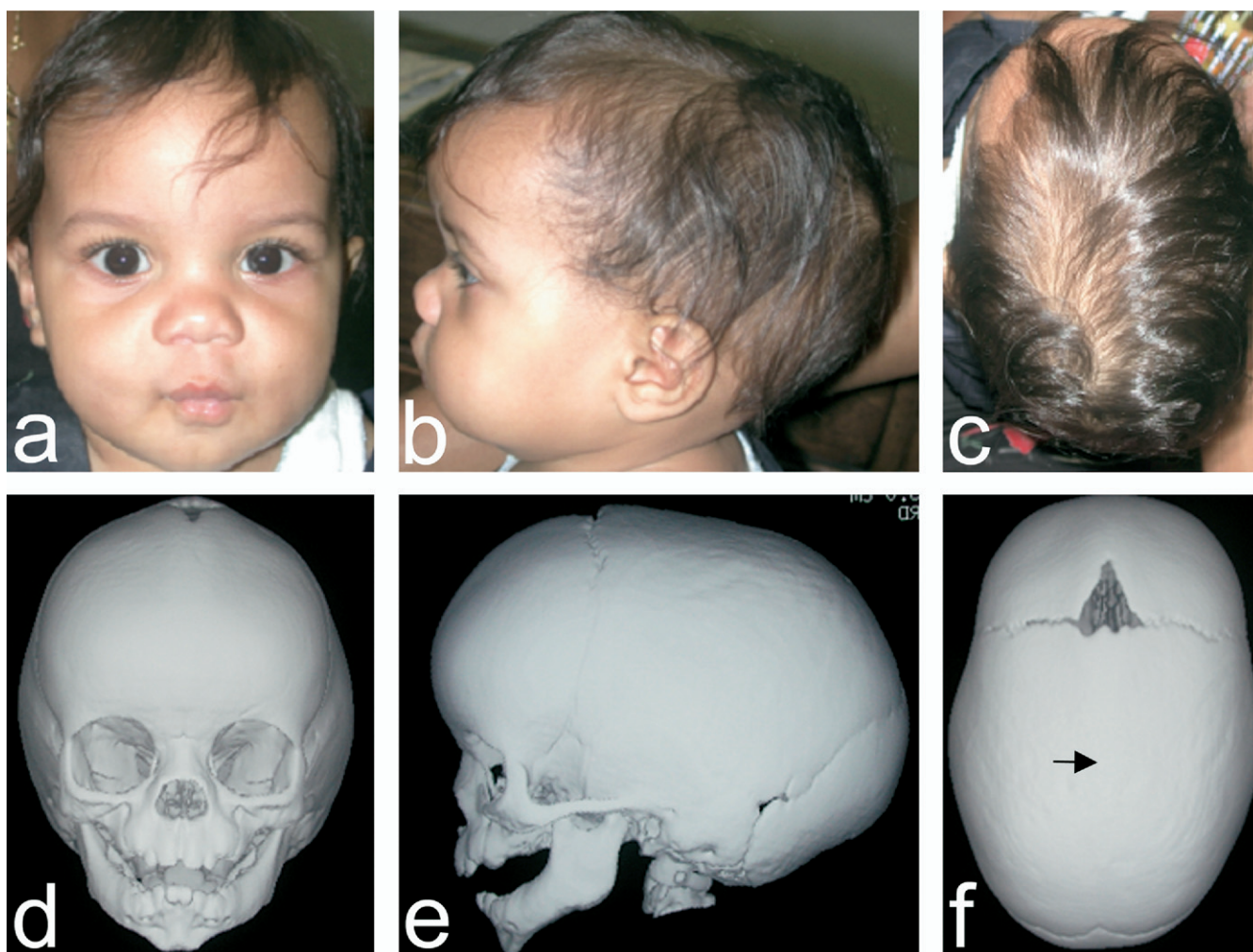
<sup>†</sup>Department of Developmental and Cell Biology, University of California, Irvine, CA.

<sup>‡</sup>Department of Surgery, University of Oklahoma, Oklahoma City, OK.

<sup>§</sup>Section of Genetics, Department of Pediatrics, University of California Davis, Sacramento, CA.

VK and JAG are supported in part by R01 DE016886 from NIDCD, and R01AR050236 from NIAMS, National Institutes of Health. SAB is partially funded through a Children's Miracle Network Endowed Chair and through grants K23 DE00462, R03 DE016342, and R01 DE016886 from NIDCD/NIH and M01-RR00052 from NCRR/NIH.

Address reprint requests to Virginia Kimonis, MD, MRCP, University of California, Irvine, Division of Genetics and Metabolism, Department of Pediatrics, 101 The City Drive, ZOT 4482, Orange, CA 92868. E-mail: vkimonis@uci.edu



**Figure 1** Patient with sagittal synostosis. (A) Frontal, (B) lateral, and (C) superior views of a child with sagittal synostosis. (C) Note the dolichocephalic shape of the cranial vault; 3D-CT reconstructions from the same patient shows dolichocephalic skull resulting from premature fusion of the sagittal suture (C, arrowhead). (Color version of figure is available online.)

craniosynostosis.<sup>6</sup> It is highly likely that the cognitive profile of NSC is a direct reflection of the under recognized increase in ICP and/or intrinsic changes in the brain. However, these associations remain to be confirmed. The true incidence of associated anomalies in NSC is unknown because most of these studies are retrospective, use small samples, and are based on incomplete clinical evaluations. Thus, there is much to be learned about the frequency and severity of the involvement of different organ systems, the extent and the causes of the clinical variability, and the natural progression of NSC.

## Classification Based on Suture Involvement

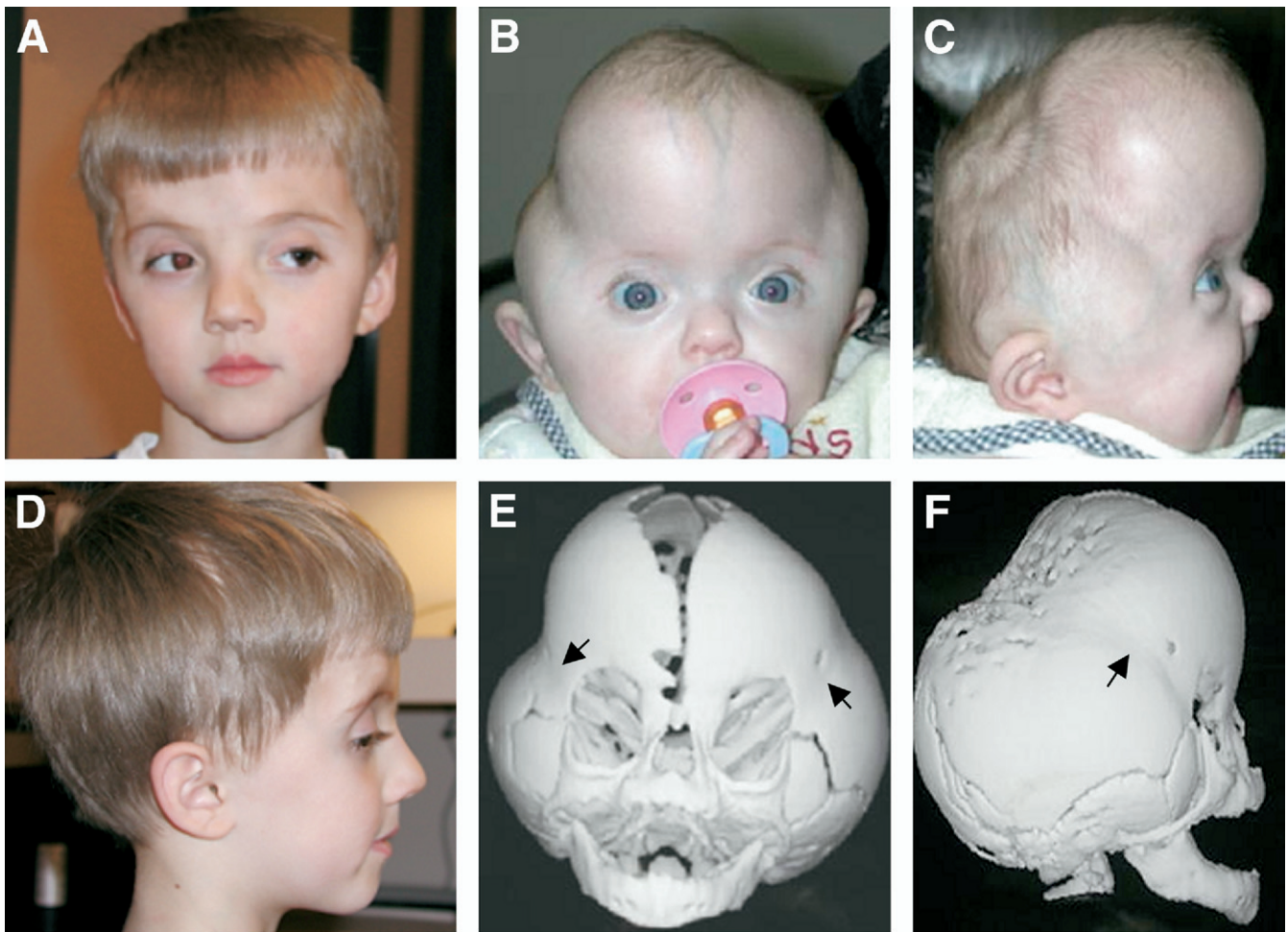
### Sagittal

Craniosynostosis of the sagittal suture is the most commonly affected suture and shows a strong male predominance (male:female ratio of 3.5:1). It accounts for 40% to 58% of all cases of craniosynostosis and has an estimated birth prevalence of 1.9 to 2.3 per 10,000 live births.<sup>7</sup> Only 2% of cases

involving sagittal synostosis are thought to be familial.<sup>7,8</sup> The fusion of the sagittal suture results in an increase of the anterior-posterior diameter of the skull called dolichocephaly or scaphocephaly (Fig 1). Twinning, increased parity, maternal smoking, and intrauterine head constraint have been suggested as risk factors.<sup>9</sup>

### Coronal

This is the second most common form of craniosynostosis, with an estimated incidence of 0.8 to 1 per 10,000 live births. Approximately 60% to 75% of cases are female,<sup>10</sup> and about 8% to 10% have a positive family history. The higher proportions of familial cases and association with advanced paternal age may indicate a stronger genetic component for coronal synostosis. Unilateral coronal craniosynostosis results in an asymmetric skull referred as anterior plagiocephaly (Fig 2A and D and Fig 5A). Unilateral coronal craniosynostosis needs to be differentiated from positional plagiocephaly, and a 3-dimensional computed tomography (3D-CT) scan is useful in differentiating between these 2 conditions. Bilateral fusion of



**Figure 2** Clinical variability of Muenke Syndrome (*FGFR3* P250R). (A) Frontal and (D) lateral views of a male child with unicoronal synostosis are shown. (B) Frontal and (C) lateral views of a young child with severe bicoronal synostosis resulting in cloverleaf skull; 3D-CT reconstructions show premature fusion of coronal sutures (arrowheads in E and F). Both children were carriers of the *FGFR3* P250R mutation, which is causative of Muenke syndrome. (Color version of figure is available online.)

the coronal suture results in brachycephaly and in severe cases results in cloverleaf skull (Fig 2B, C, E, and F). It is important to recognize that patients with minimal manifestations of Muenke syndrome (with only coronal synostosis) may mimic non-syndromic craniosynostosis; however, these patients with *FGFR3* P250R mutations often have minor defects on x-ray (brachyphalangia, metatarsal or metacarpal osseous fusion, and cervical spine abnormalities), developmental delay, or low frequency hearing loss.

Recently, Merrill et al (2006)<sup>11</sup> reported heterozygous mutations in *EFNA4* in three of 81 patients with non-syndromic coronal synostosis.

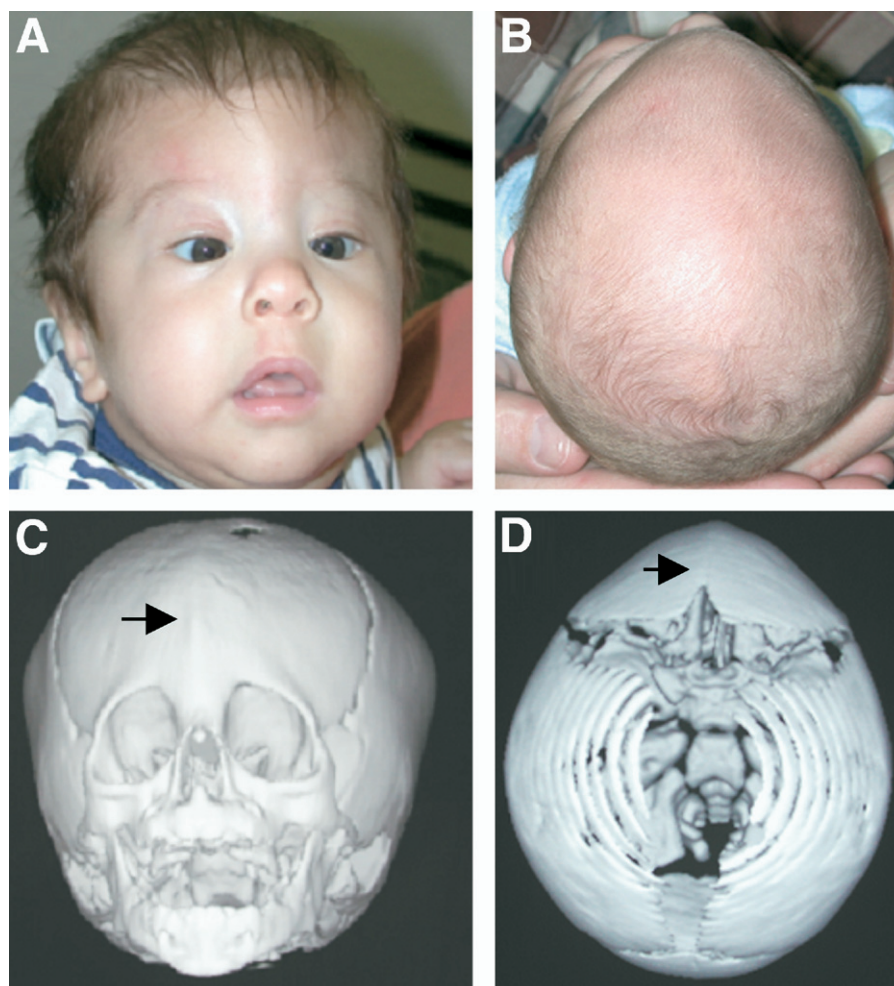
### Metopic

Metopic synostosis is associated with trigonocephaly (Fig 3) and has an incidence of 1 per 10,000 to 15,000 births with a male preponderance. Several syndromes are associated with metopic synostosis, including Baller-Gerold, Jacobsen (11q23 deletion), chromosome 9p deletion, and Opitz C syndrome; therefore, genetic testing of such patients is warranted, including a karyotype analysis, possible microarray

analysis for microdeletions, and/or selected mutation analysis depending on the clinical scenario.

### Lambdoid

Lambdoid craniosynostosis is the least common type of craniosynostosis, accounting for only 2% to 4% of all NSC.<sup>12</sup> In bilateral lambdoid synostosis, the entire occipital region is flattened and widened (Fig 4). Most cases of lambdoid craniosynostosis are unilateral and result in asymmetric posterior plagiocephaly that needs to be differentiated from positional plagiocephaly. These two conditions pose a significant diagnostic dilemma that requires careful clinical and radiologic differentiation and different therapeutic approaches. 3D-CT has proved to be the most useful modality for documenting lambdoid fusion because lambdoid sutures are not readily visualized on skull radiographs and routine computed tomography study may not detect partial sutural fusion.<sup>13</sup> In cases of severe and progressive plagiocephaly with open lambdoid sutures, synostoses of the asterion region<sup>14</sup> or the mendosal suture<sup>15</sup> must be excluded by a detailed 3D-CT scan. Associations of lambdoid synostosis with intrauterine



**Figure 3** Metopic synostosis. (A) Frontal and (B) superior views of a child with metopic synostosis; 3D-CT reconstructions (C,D) show premature fusion of the metopic suture (arrow). Note the trigonicephalic shape of the cranial vault. (Color version of figure is available online.)

constraint, preterm labor, and male gender have been suggested.<sup>16</sup>

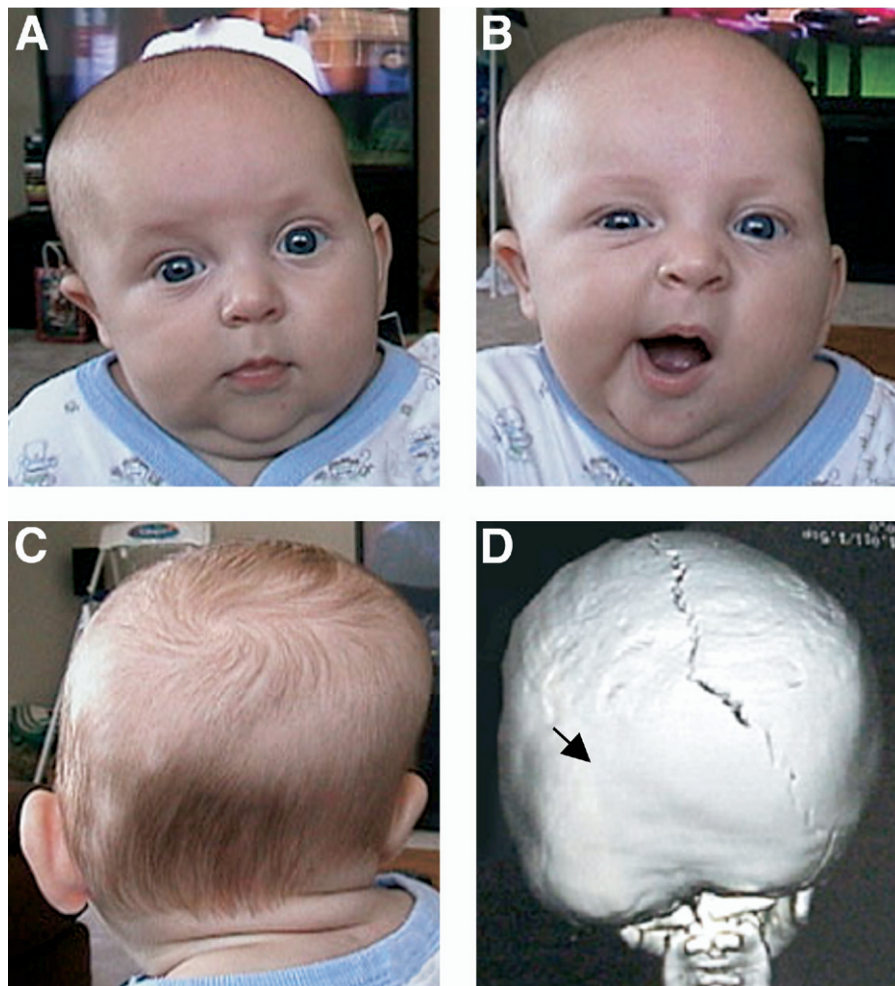
### Multiple

Craniosynostosis of multiple sutures accounts for approximately 5% of craniosynostosis. It is clinically separated into two groups: 2-suture disease (including bicoronal synostosis) and complex craniosynostosis with fusion of more than 2 sutures. Patients with 2-suture fusion typically have a similar long-term neurodevelopmental outcome to those with single-suture involvement, except for a higher rate of reoperation because of poor morphologic results and/or elevated ICP.<sup>17</sup> Complex craniosynostosis frequently causes increased ICP and is associated with developmental delay and a high rate of reoperation.<sup>17</sup> In patients with complex craniosynostosis involving both coronal and sagittal sutures, increased ICP was present in two thirds, whereas three quarters had Chiari I anomaly on magnetic resonance imaging.<sup>18</sup> Numerous patients with elevated ICP secondary to craniosynostosis had normal funduscopy, indicating the need for a diagnostic computed tomography scan when evaluating these patients. Complex synostosis involving all sutures is known as pan-

synostosis, which is frequently associated with a genetic syndrome.<sup>19</sup> Kleeblattschädel or cloverleaf skull deformity is a phenotypic description seen in severe pansynostosis, causing protrusion of the brain through the open anterior and parietal fontanelles (Fig 2B, C, E, and F). This deformity is associated with multiple syndromes, including thanatophoric dysplasia, Crouzon, Pfeiffer, and Carpenter syndromes.

## Molecular Genetics of Craniosynostosis

In the past decade, significant progress has been made in understanding the genetic basis of certain craniosynostosis syndromes, with mutations in the fibroblast growth factor (FGF) signaling pathway playing a central role. FGFs are a family of at least 22 known signaling molecules that function to regulate cell proliferation, differentiation, and migration through a variety of complex pathways.<sup>20,21</sup> They are important in angiogenesis, wound healing, limb development, mesoderm induction/patterning, neuronal differentiation, malignant transformation, and skeletogenesis. They act through the fibroblast growth factor



**Figure 4** Posterior plagiocephaly caused by lambdoidal synostosis. (A and B) Frontal and (C) posterior views of an infant with left lambdoidal synostosis; the 3D-CT reconstruction (D, posterior view) shows premature fusion of the left lambdoidal suture (arrow). Note the facial asymmetry of the patient secondary to the lambdoidal synostosis (panel B) that does not occur in positional plagiocephaly. (Color version of figure is available online.)

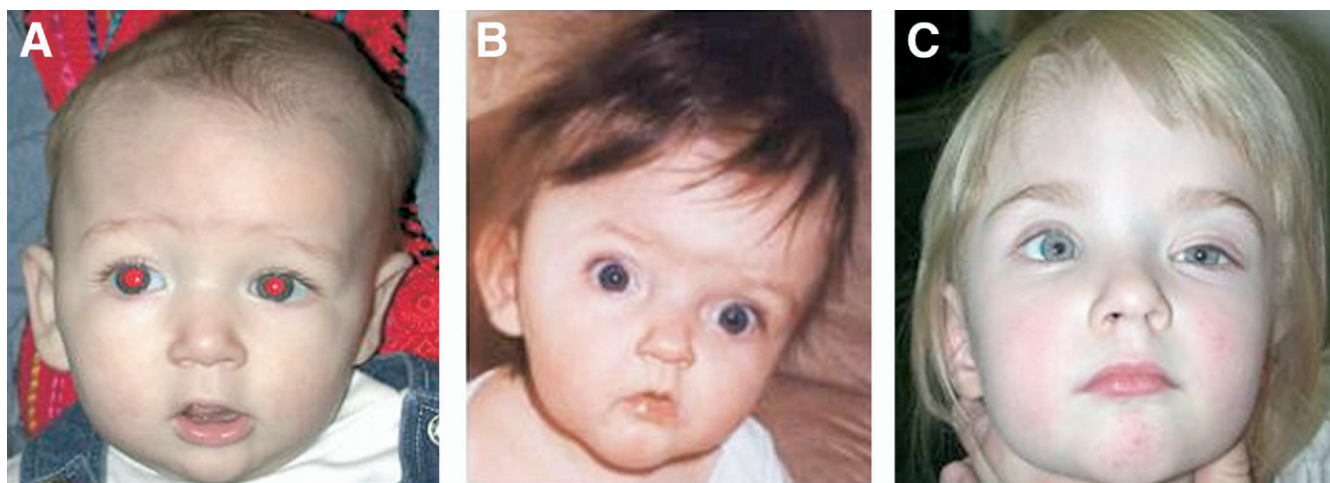
receptors (FGFRs), a family of 4 tyrosine kinase receptors. The FGFRs share the general structure of a split cytoplasmic tyrosine kinase domain, a transmembrane domain, and an extracellular domain that contains 3 immunoglobulin-like repeats (Fig 10). Gain-of-function mutations in *FGFR1* to 3 have been associated with Pfeiffer, Apert, Crouzon, Beare-Stevenson, Jackson-Weiss, and Muenke syndromes. All the above syndromes are most frequently characterized by bicoronal craniosynostosis or cloverleaf skull, distinctive facial features, and variable hand and foot findings. Interestingly, identical *FGFR2* mutations (eg, C278F, G298P, and C342T) have been found in patients carrying the diagnosis of Crouzon, Pfeiffer, and Jackson-Weiss craniosynostosis syndromes, suggesting that these entities may represent a clinical spectrum with possible genetic modifiers.<sup>22-24</sup> It has also been shown that the same clinical phenotype can result from mutations in different genes, such as cases of Pfeiffer syndrome with mutations in *FGFR1* and *FGFR2*,<sup>23</sup> suggesting functional redundancy among different *FGFR* molecules.

In addition to the disorders of the *FGFR*-related craniosynostosis spectrum, mutations in several transcription factors have also been implicated in syndromic craniosynostosis. The major-

ity of patients with Saethre-Chotzen syndrome have loss-of-function mutations in *TWIST1*,<sup>25,26</sup> which is thought to negatively regulate *FGFR1*, 2 and 3 and the osteogenic transcription factor *Runx2*. Boston-type craniosynostosis caused by a gain-of-function mutation in *MSX2* has been described in a single family with variable phenotype ranging from metopic ridging to cloverleaf skull and digital abnormalities.<sup>27</sup> Animal models indicate that *MSX2* is expressed in osteoblasts adjacent to the calvarial sutures, and loss-of-function mutations in this gene cause skull ossification defects in humans, consistent with a role of this gene in bone formation.<sup>28</sup>

## Common Syndromic Craniosynostoses

Well over 180 different syndromes involve craniosynostosis.<sup>29</sup> The following clinical descriptions are intended to cover the more common and well-characterized forms of craniosynostosis.



**Figure 5** Mild cases of Muenke and Saethre-Chotzen syndrome may mimic nonsyndromic coronal craniosynostosis. (A) A young child with nonsyndromic right unicoronal synostosis. (B) A child with coronal synostosis caused by Muenke syndrome (*FGFR3* P250R). Note the midfacial hypoplasia and downsloping palpebral fissures. (C) A young girl with Saethre-Chotzen syndrome caused by intragenic deletion of the *TWIST1* gene. Characteristic features in this patient include low set frontal hairline, facial asymmetry, and ptosis of the left eye. (Color version of figure is available online.)

### Muenke *FGFR3*-Associated Coronal Synostosis Syndrome

Muenke syndrome is characterized by unicoronal or bicoronal craniosynostosis with midfacial hypoplasia and ocular hypertelorism (Fig 2 and Fig 5B). Limb involvement may include brachydactyly, carpal bone fusion, and coned epiphyses. Intelligence is usually normal. There is significant phenotypic overlap with other craniosynostosis syndromes particularly Saethre-Chotzen (Fig 5C), Pfeiffer (Fig 6D) and Jackson-Weiss (Fig 6B). Extreme clinical variability of this syndrome exists as we have observed craniosynostosis phenotypes ranging from isolated unicoronal craniosynostosis resulting in relatively mild anterior plagiocephaly (Fig 2A and D and Fig 5B), mild brachycephaly due to bicoronal craniosynostosis, to the most extreme manifestation of cloverleaf skull deformity due to multiple suture involvement (Fig 2B, C, E, and F). Clinically apparent features may be absent, and diagnosis may only be made after radiographic investigation and molecular studies. Variable expressivity within families may mean that diagnosis in a mild case may only be made after the birth of a more severely affected individual. A single mutation in *FGFR3* (P250R) is the defining molecular characteristic of Muenke syndrome, and inheritance is autosomal dominant.

### Saethre-Chotzen Syndrome

Craniosynostosis is usually unicoronal or bicoronal but may also occur in metopic or sagittal sutures (Fig 5C). Craniofacial features include low-set hairline, parrot-beaked nose with deviation, ptosis, abnormal ears (small with a prominent horizontal crus), prominent chin, and minor skeletal anomalies. Syndactyly of digits 2 and 3 of the hand is variably present. Although a mild to moderate developmental delay and mental retardation have been reported (especially with deletion of entire *TWIST1* gene), intelligence is typically normal. Less common manifestations of Saethre-Chotzen syn-

drome include short stature, parietal foramina, radioulnar synostosis, cleft palate, maxillary hypoplasia, ocular hypertelorism, hallux valgus, hearing loss, and congenital heart malformations. Variable expressivity is seen with some affected parents only identified after the diagnosis of a more severely affected child.

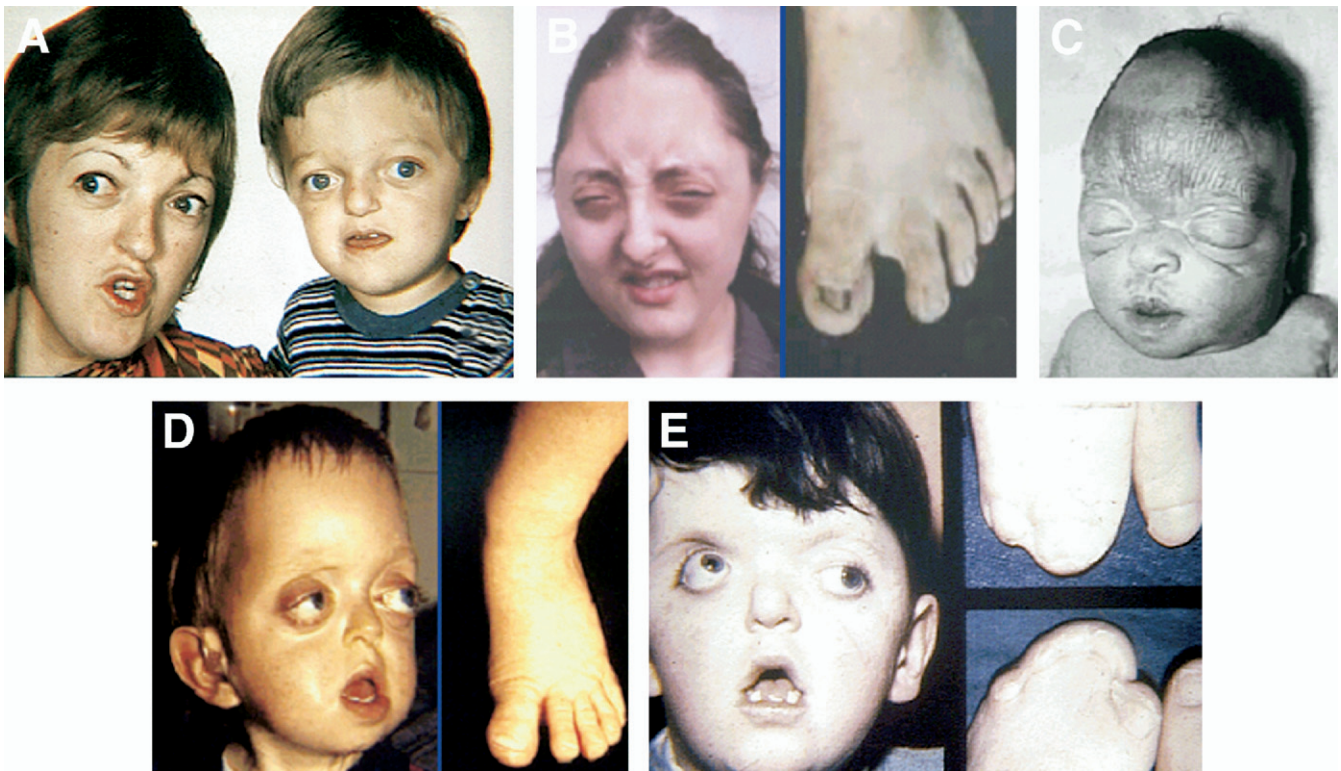The majority of cases of Saethre-Chotzen syndrome are caused by mutations in *TWIST1*, which are seen in ~40% to 80% of individuals.<sup>25,26</sup> Inheritance is autosomal dominant. Mutations include nucleotide substitutions (missense and nonsense), small deletions/insertions, and gross deletions/insertions/duplications and/or complex rearrangements throughout the gene resulting in functional haploinsufficiency of *TWIST1*, a basic helix-loop-helix transcription factor.<sup>30-34</sup>

### Crouzon Syndrome

Characteristic facial features include hypertelorism, beaking of the nose, proptosis, and midface hypoplasia (Fig 6A). Craniosynostosis is bicoronal with occasional pansynostosis developing in infancy or childhood. Intellect is maintained. There is no extremity involvement, although Murdoch-Kinch and Ward<sup>35</sup> showed metacarpal-phalangeal shortening. Progressive hydrocephalus is common and is seen in 30% of patients.<sup>36</sup> Mutations in *FGFR2* are causative with autosomal dominant inheritance.

### Beare-Stevenson Cutis Gyrate

Clinical manifestations include craniosynostosis, with frequent cloverleaf skull and ear defects (Fig 7C). Facial features are often described as crouzonoid in nature. The most striking aspects of this syndrome are the skin manifestations consisting of corrugated skin furrows (cutis gyrate), acanthosis nigricans, and skin tags. Cutis gyrate variably affects the hands, feet, trunk, neck, forehead, face, and scalp. Anogenital anomalies have also been reported.<sup>37</sup> Two separate muta-



**Figure 6** FGFR2 craniosynostosis syndromes. (A) A mother and son with Crouzon syndrome. (B) A woman with Jackson-Weiss syndrome. Note the characteristic broad first toe and mild syndactyly of the first and second toes. (C) An infant with Beare-Stevenson syndrome. Note the corrugated skin of the forehead and philtrum. The darkened areas of skin may represent acanthosis nigricans, which is frequently seen in this disorder. (D) A young boy with Pfeiffer syndrome. Note the widened first toe. (E) A young boy with Apert syndrome. Severe syndactyly of hands and feet are shown caused by underlying fusion of bony structures. Reprinted with permission: Figures 6A, C-E from Winter-Baraitser Dismorphology Database, London Medical Databases, Ltd; 38 Chalcot Crescent, London N'W1 8YD, UK and Figure 6B from Jackson CE, Weiss L, Reynolds WA, et al: Craniosynostosis, midfacial hypoplasia and foot abnormalities: an autosomal dominant phenotype in a large Amish kindred. *J Pediatr* 88;963-968, 1976. (Color version of figure is available online.)

tions have been identified in *FGFR2* (Y375C, S372C),<sup>38</sup> although an additional locus may exist. Inheritance is autosomal dominant.

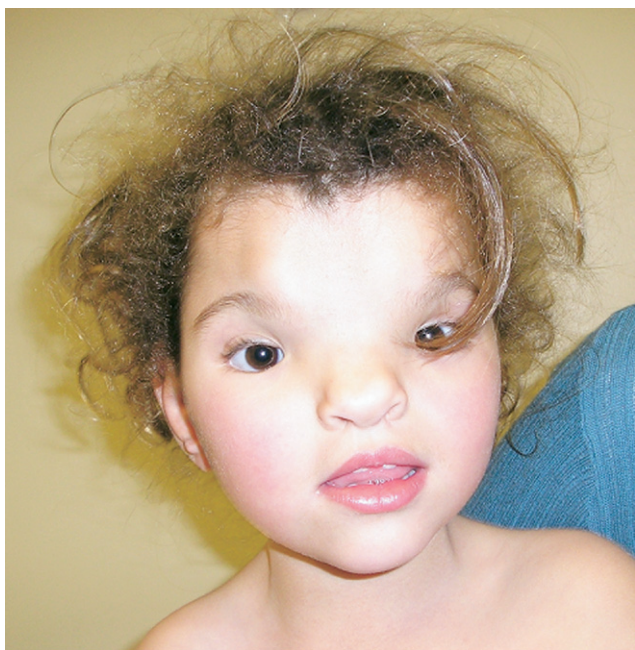### Pfeiffer Syndrome

The main characteristics are craniosynostosis; midface deficiency; unusually broad, short, great toes; broad thumbs; and variable brachydactyly (Fig 7D).<sup>19</sup> Pfeiffer syndrome can be further delineated into 3 subgroups, although there is overlap particularly between types 2 and 3. Type 1 is the most common and has a good prognosis. Impairment of intellect is unlikely without other associated malformations such as hearing loss or hydrocephalus. Type 2 is more severe and associated with a poor prognosis. Presentation is at birth or prenatally with cloverleaf skull, severe ocular proptosis, and broad thumbs and great toes with medial deviation. Additional malformations may include choanal stenosis or atresia, laryngotracheal abnormalities, elbow ankylosis/synostosis, hydrocephalus, seizures, and intellectual disability. Type 3 has a similar facial appearance to type 2 but without cloverleaf skull. Intellectual disability is common. The majority of patients with Pfeiffer syndrome have mutations in *FGFR2*, although a small

number have also been identified in *FGFR1* (<5%). Inheritance is autosomal dominant.

### Apert Syndrome

The typical facial features of this syndrome include a characteristic break in the eyebrows, ocular hypertelorism, downslanting palpebral fissures, and thin upper lip with a trapezoid or tented appearance (Fig 6E). Head shape can be extremely turri-brachycephalic with moderate to severe midface hypoplasia. Initially, there is a wide calvarial defect from the posterior fontanel to the glabella, and the anterior portion of the defect is sometimes described as an "encephalocele," which is a misnomer because bony obliteration eventually occurs. The malformations of the central nervous system seen in this disorder are numerous, including hydrocephalus, ventriculomegaly, megalencephaly, gyral malformations, and defects in the corpus callosum, septum pellucidum, hippocampus, and cerebral cortex.<sup>39,40</sup> Cleft palate and hearing loss because of fused ossicles are also observed. There are varying degrees of developmental delay. Generally, IQ correlates inversely with ICP<sup>41</sup>; however, the developmental delay may be unrelated to the increased ICP because of the fact that the large midline skull defect



**Figure 7** Typical facial features of craniofrontonasal dysplasia. A young girl with associated marked hypertelorism, broad nose, and widow's peak. (Color version of figure is available online.)

and widely patent fontanels do not give rise to ICP early in development. Skeletal problems are severe and multiple, including bony syndactyly of the hands and feet with sparing of the thumb, giving the impression of a "mitten hand." Fused cervical vertebrae (68%, usually C5-C6) and elbow ankylosis are seen. Other congenital anomalies can occur such as cardiac (10%) and genitourinary (9.6%) defects, which need to be assessed in the initial workup.<sup>42</sup>

Two *FGFR2* mutations, S252W and P253R, account for the majority of cases (71% and 26%, respectively).<sup>43</sup> Some genotype-phenotype associations have been suggested (eg, the severity of the syndactyly with the P253R<sup>44</sup> and the presence of cleft palate in S252W<sup>45</sup>). A paternal age effect in *de novo* mutations in *FGFR2* has been conclusively shown at the molecular level in Apert syndrome. It has been hypothesized that *FGFR2* mutations may convey an advantage in sperm because the *FGF/FGFR* pathway is known to be important in maintaining and initiating spermatogenesis.<sup>46</sup>

#### Crouzon With Acanthosis Nigricans

Approximately 5% of individuals with crouzonoid features including hypertelorism, beaking of the nose, proptosis, and midface hypoplasia with normal extremities have acanthosis nigricans with pigmentary changes in deep tissue folds such as the axilla and the groin. Crouzon syndrome with acanthosis nigricans is caused by the *FGFR3* A391E mutation. Associated skeletal features include choanal atresia, narrow sacrosciatic notches, short vertebral bodies, and lack of the normal increase in interpediculate distance from the upper lumbar vertebrae caudally.<sup>47</sup>

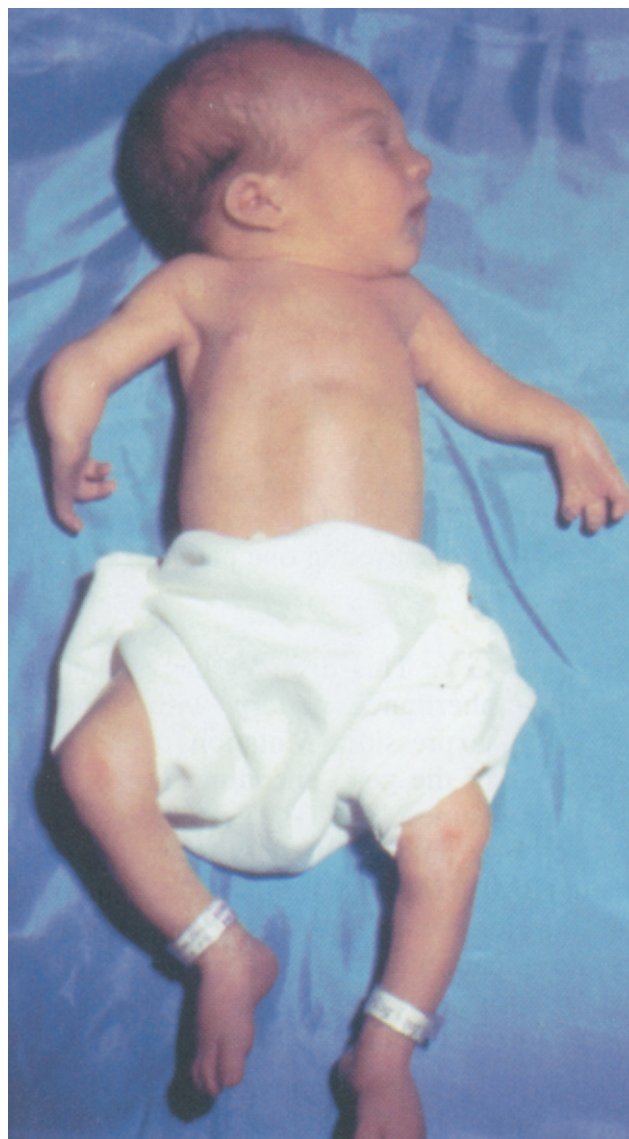#### Craniofrontonasal Dysplasia

This is an X-linked dominant disorder that affects females more severely (Fig 7).<sup>48</sup> Features include coronal synostosis

with brachycephaly and features of frontonasal dysplasia including hypertelorism, anterior widow's peak, downslanting palpebral fissures, clefting of the nasal tip, and occasionally cleft lip and palate. Other digital and joint anomalies, abnormal clavicles, and raised scapulae are associated with Sprengel deformity. Longitudinally grooved fingernails are characteristic of this disorder. Mutations in *EFNB1* located at Xq12 are causative.

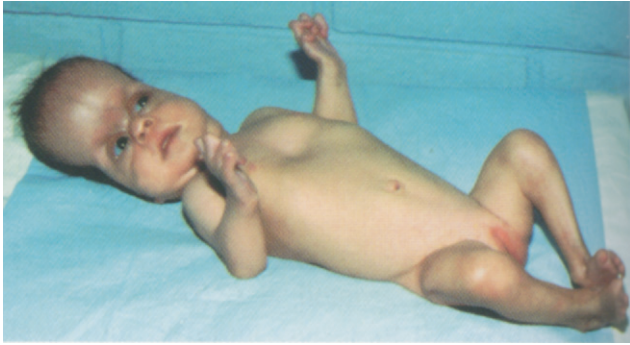
#### Baller-Gerold Syndrome

Baller-Gerold syndrome (Fig 8) typically involves the coronal sutures. The most unique feature is a radial ray defect, which may be asymmetric and result in mild hypoplasia to complete aplasia. Thumbs, metacarpals, and carpal bones may be absent with a shortened and curved ulna. Occasional findings include ocular hypertelorism, epicanthic folds, a prominent nasal bridge, midline capillary hemangiomas, genitourinary



**Figure 8** Baller-Gerold syndrome. Reprinted with permission from Kenneth Lyons Jones (ed): *Smith's Recognizable Patterns of Human Malformation*, Sixth Edition, Elsevier Saunders, 2006. (Color version of figure is available online.)





**Figure 9** Antley-Bixler syndrome. Reprinted with permission from Kenneth Lyons Jones: *Smith's Recognizable Patterns of Human Malformation*, Sixth Edition, New York, NY, Elsevier Saunders, 2006, p 954. (Color version of figure is available online.)

malformations, and intellectual disability.<sup>49</sup> Autosomal recessive inheritance of mutations in the DNA helicase gene *RECQL4* have been identified in a subgroup of Baller-Gerold patients.<sup>50</sup> Interestingly, mutations in *TWIST1* have been identified in some patients with suspected Baller-Gerold syndrome and has suggested that some patients with this syndrome may overlap with Saethre-Chatzen syndrome.<sup>51</sup>

### Antley-Bixler Syndrome

Antley-Bixler syndrome (trapezoidocephaly, multiple synostosis syndrome) is caused by a sterol biosynthesis defect (Fig 9).<sup>19</sup> This syndrome involves premature closure of the coronal and lambdoidal sutures, brachycephaly with frontal bossing, proptosis, downsloping palpebral fissures, severe depression of the nasal bridge (with or without choanal stenosis or atresia), and low-set protruding ears. The main limb features are radiohumeral synostosis, medial bowing of the ulnae, bowing of the femora, slender hands and feet, contractures at the proximal interphalangeal joints, fractures, and advanced bone age. Some individuals have congenital heart disease, renal anomalies, and abnormalities of the female genitalia.<sup>52</sup> Mutations in the gene encoding cytochrome P450 reductase (POR) are causative. Inheritance is autosomal recessive.

### Boston-Type Craniosynostosis

This is an autosomal dominant disorder identified in 19 affected individuals in 1 family,<sup>53</sup> in whom variable phenotypes were reported including fronto-orbital recession, frontal bossing, and turribrachycephaly as a result of coronal craniosynostosis, cloverleaf skull, and asymptomatic individuals. A mutation in *MSX2* was shown.<sup>27</sup> Further families have not been identified, and mutations in *MSX2* were not found in 211 individuals with craniosynostosis in whom mutations in the major genes were excluded.<sup>54</sup>

### Carpenter Syndrome

Carpenter syndrome is an autosomal recessive craniosynostosis syndrome associated with obesity; cardiac defects; preaxial polydactyly of the feet; and brachydactyly, syndactyly, and aplasia or hypoplasia of the middle phalanges of the hands. Mental retardation is variable.<sup>55</sup> Presumed loss-of-

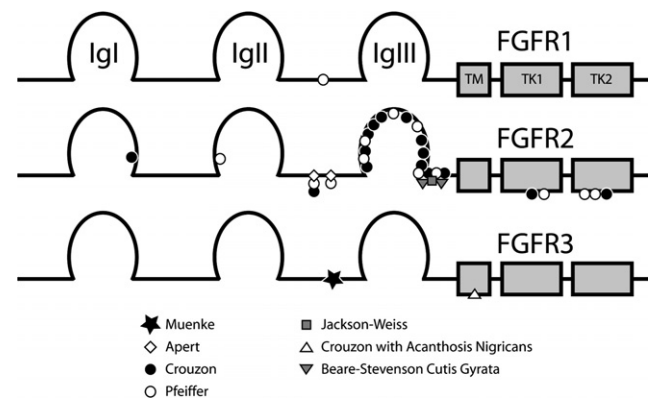
function mutations have been identified in *RAB23*, which encodes a member of the RAB guanosine triphosphatase family of vesicle transport proteins and acts as a negative regulator of hedgehog signaling.<sup>56</sup>

## General Approaches to the Patient With Craniosynostosis

### History and Physical Examination

Clinical evaluations should include in-depth antenatal history and documentation of any teratogenic exposure because drugs such as sodium valproate and fluconazole are associated with craniosynostosis.<sup>57,58</sup> A 3-generation family history should be obtained. Because of the pleiotropic effects of various craniosynostosis syndromes, a comprehensive review of systems should be performed for other associated medical problems. The autosomal dominant inheritance and variable expressivity of many disorders mandates that patients and available first-degree relatives should undergo detailed clinical examination, including subtle malformations of the eyes, eyelids, hair, ears, nose, palate, and teeth. Objective measurements should include head circumference; interpupillary, inner canthal, and outer canthal eye measurements; palpebral fissure length; and ear and philtrum lengths. Eye examination including ocular movement and funduscopy should be performed. Abnormalities of the trunk, including pectus and scoliosis, should be assessed. Extremities should be examined for proportions; joint mobility, digital, and nail abnormalities; hand/finger length ratio; and foot length. A general physical examination of other organ systems will be performed including the heart, lungs, abdomen, muscle tone and reflexes, and genitalia.

An age-appropriate clinical neurologic assessment should be performed for evaluation for seizures, evidence of intracranial pressure alterations, facial palsies, sensory impairment, and other signs and symptoms. Chiari I malformation



**Figure 10** The position of craniosynostosis syndrome mutations on FGFR1 to 3. FGFRs each contain 3 immunoglobulin-like domains (Ig I-III), a single transmembrane domain (TM), and 2 tyrosine kinase domains (TK1-2). The location of various mutations is shown. Different syndromes may result from identical mutations in *FGFR2*, whereas mutations in *FGFR1* and *FGFR2* are able to cause the same clinical phenotype. (Adapted with permission.<sup>61</sup>)

Table 1 Molecular Testing

Disorder	Gene (% responsible)	Locus	Mutations	Mutation Detection Rate
Pfeiffer	<i>FGFR1</i> (<5%) <i>FGFR2</i> (>95%)		Several	67%
Apert	<i>FGFR2</i> (100%)		Ser252Trp, Pro253Arg	>98%
Crouzon	<i>FGFR2</i> (100%)		Several	>50%
Crouzon with acanthosis	<i>FGFR3</i> (100%)		Ala391Glu	100%
Muenke	<i>FGFR3</i> (100%)		Pro250Arg	100%
Saethre Chotzen	<i>TWIST1</i>		Several mutations & deletions	46% to 80%

may be asymptomatic in the first years of life or may present with signs of increased ICP (headache and vomiting), ataxia, spasticity, breathing, swallowing, or sleep abnormalities. There is a 7% chance of increased ICP with a single-affected suture, and, in cases of multiple suture synostosis, the incidence of increased ICP can be as high as 62%.<sup>59</sup> A thorough ophthalmologic evaluation should be performed with a standard protocol with cycloplegic retinoscopy to assess visual acuity, ocular motility, anterior segment structures, the retina, and the optic disc for signs of papilledema, although, as stated previously, papilledema is not a sensitive indicator for elevated ICP so other assessments may be necessary for screening. Detailed neurobehavioral assessment may be warranted for patients experiencing difficulties in regular classroom as learning disabilities have been reported in cases with sagittal craniosynostosis.<sup>4,5</sup>

Recent data indicates that there is a high incidence of low frequency hearing loss among patients with Muenke *FGFR3*-associated coronal synostosis syndrome.<sup>60</sup> Thus, audiological evaluation should be considered in all patients with coronal synostosis, especially those with *FGFR3* P250R mutations, and in any other patient in whom hearing loss cannot be ruled out as a cause of speech delay.

### Radiologic Studies

The initial diagnosis of craniosynostosis necessitates investigation for hydrocephalus and structural anomalies by a brain computed tomography scan or magnetic resonance imaging; 3D-CT, allowing 3-dimensional reconstructions of the bony anatomy of both endo- and ectocranial surfaces of the skull, has become the gold standard for diagnosing craniosynostosis. Plain radiographs of the axial skeleton and limbs such as syndactyly, carpal and tarsal fusions, and cervical spine abnormalities remain an integral part of the evaluation of the craniosynostosis syndromes. Further studies (eg, assessment for other for upper airway obstruction) are undertaken as needed and depend in part on the specific diagnosis.

### Management

Patients with craniosynostosis syndromes are typically evaluated in craniofacial centers by a multidisciplinary team including plastic surgeons, neurosurgeons, dentists, medical geneticists, otolaryngologists, ophthalmologists, audiologists, speech pathologists, nurses, developmental pediatricians, and social workers. Other disciplines are involved as needed in syndromic craniosynostosis with extracranial manifestations (eg, a cardiologist and urologist in Apert syndrome).

The typical corrective surgery involves a bilateral craniotomy with a fronto-orbital advancement to expand the cranial vault. In contrast to individuals with nonsyndromic craniosynostosis, in whom the first surgery is usually performed between 6 months and 1 year of age, children with syndromic craniosynostosis often have their first surgery as early as 3 months of age. Individuals with Apert syndrome have the highest incidence of repeat surgery to correct forehead contour.<sup>61</sup> Surgical correction of severe limb defects is usually not possible because the skeletal anomalies are developmental and the structures have never formed normally. For example, surgical separation of the digits in the mitten-glove syndactyly of Apert syndrome often provides little functional improvement. Some less severe skeletal anomalies, such as the elbow ankylosis seen in Pfeiffer syndrome types 2 and 3, do provide some functional improvement by altering the angle at which the elbows are fixed such that the angle of each arm can be differentially positioned for various activities of daily living.

### Genetic Testing Strategy

A strategy to increase efficiency and cost-effectiveness of molecular testing in craniosynostosis disorders involves initial performance of sequence analysis of recurrent mutations (Table 1 and Fig 10). More than 98% of Apert syndrome cases are associated with 2 mutation hotspots in *FGFR2* (P253R and S252W). In Crouzon patients with acanthosis, testing for the *FGFR3* A391E mutation will identify all cases (although acanthosis may not be present until early childhood). Interestingly, the common *FGFR2* mutations seen in patients with Apert syndrome are in the identical domain as mutations in *FGFR1* and *FGFR3* associated with Crouzon, Pfeiffer, and Muenke syndromes. This is the linker region between Ig-like loops 2 and 3, the area thought to be critical in ligand binding,<sup>20</sup> and allows targeted mutation scanning. Patients with isolated Crouzon or Pfeiffer syndrome should have guided *FGFR2* mutation testing, with *FGFR1* mutation testing in Pfeiffer patients with no identifiable *FGFR2* mutation. Patients with Saethre-Chotzen syndrome should undergo *TWIST1* mutation testing, followed by southern blot, multiplex ligation-dependent probe amplification, or equivalent analysis in mutation-negative individuals because of the high incidence of gene deletion/duplication in this disorder (estimated in up to 30% of patients).<sup>32</sup> An individual with apparently isolated unilateral or bilateral coronal craniosynostosis merits the testing of hotspots for *FGFR1*, 2, and 3 and *TWIST1*. A stepwise approach could be used with initial test-

ing for *FGFR3* P250R, which accounts for 7% of craniosynostosis, followed by *FGFR2*, and *FGFR1* and *TWIST1* hotspot analysis. Currently, mutation testing is not indicated for the patients with isolated sagittal synostosis (no mutations detected in more than 150 tested patients; SA Boyadjiev, unpublished data, July 2007). Individuals with metopic or lambdoidal synostosis may also need hotspot analysis, but the data at this time are inconclusive. Selective full-length gene sequencing for additional mutations in *FGFR1*, 2, and 3 and *EFNA4* may be available in research laboratories.

### Genetic Counseling

The majority of craniosynostosis are autosomal dominant. Because of variable expressivity, the identification of a mutation in an affected individual should be followed by parental testing. Many mild cases of craniosynostosis are identified after the identification of a more severely affected child. In more severe types of craniosynostosis, the *de novo* mutation rate is high. Although varying phenotypes have been seen with identical mutations (eg, identical *FGFR2* mutations seen in patients with Crouzon, Pfeiffer, and Jackson-Weiss craniosynostosis), the clinical syndrome within a particular family usually remains constant (with variable expressivity possible). In autosomal dominant types of craniosynostosis, mutation carriers have a 50% risk of passing the affected gene to their offspring. Negative parental mutation testing still leaves a small (<1%) risk of recurrence because of potential gonadal mosaicism. "Truly nonsyndromic craniosynostosis is thought to be a multifactorial trait with recurrent risk around 5% for coronal and around 1% for sagittal suture fusion." From Peter Harper: Practical Genetic Counseling (ed 5). Butterworth and Heinemann, 1998. Prenatal testing strategies include chorionic villus sampling (typically at 10-14 weeks gestation) or amniocentesis (typically at 16-18 weeks gestation). Preimplantation genetic diagnosis is a valuable option available for those who have been identified as carriers of the mutation but are interested in ensuring that their children are unaffected without making the decision to terminate a pregnancy in the event of a positive prenatal diagnosis. Molecular testing enables the selection of only genetically normal embryos for use in in vitro fertilization.

### References

- Shimoji T, Tomiyama N: Mild trigonocephaly and intracranial pressure: report of 56 patients. *Childs Nerv Syst* 20:749-756, 2004
- Thompson DN, Harkness WJ, Jones BM, et al: Subdural intracranial pressure monitoring in craniosynostosis: Its role in surgical management. *Childs Nerv Syst* 11:269-275, 1995
- Thompson DN, Malcolm GP, Jones BM, et al: Intracranial pressure in single-suture craniosynostosis. *Pediatr Neurosurg* 22:235-240, 1995
- Shipster C, Hearst D, Somerville A, et al: Speech, language, and cognitive development in children with isolated sagittal synostosis. *Dev Med Child Neurol* 45:34-43, 2003
- Magge S, Westerveld M, Pruzinsky T, et al: Long-term neuropsychological effects of sagittal craniosynostosis on child development. *J Craniofac Surg* 13:99-104, 2002
- Gupta P, Foster J, Crowe S, et al: Ophthalmologic findings in patients with nonsyndromic plagiocephaly. *J Craniofac Surg* 14:529-532, 2003
- Hunter A, Rudd N: Craniosynostosis. I. Sagittal synostosis: Its genetics and associated clinical findings in 214 patients who lacked involvement of the coronal suture. *Teratology* 14:185-193, 1976
- Lajeunie E, Le Merrer M, Bonaiti-Pellie C, et al: Genetic study of scaphocephaly. *Am J Med Genet* 62:282-285, 1996
- Kallen K: Maternal smoking and craniosynostosis. *Teratology* 60:146-150, 1999
- Lajeunie E, Le Merrer M, Bonaiti-Pellie C, et al: Genetic study of non-syndromic coronal craniosynostosis. *Am J Med Genet* 55:500-504, 1995
- Merrill AE, Bochukova EG, Brugger SM, et al: Cell mixing at a neural crest-mesoderm boundary and deficient ephrin-Eph signaling in the pathogenesis of craniosynostosis. *Hum Mol Genet.* 15:1319-28, 2006
- Huang M, Gruss JS, Clarren SK, et al: The differential diagnosis of posterior plagiocephaly: True lambdoid synostosis versus positional molding. *Plast Reconstr Surg* 98:765-774, 1996; discussion 775-776
- Goodrich J, Argamaso R: Lambdoid stenosis (posterior plagiocephaly) and craniofacial asymmetry: Long-term outcomes. *Childs Nerv Syst* 12:720-726, 1996
- Jimenez D, Barone CM, Argamaso RV, et al: Asterion region synostosis. *Cleft Palate Craniofac J* 31:136-141, 1994
- Tubbs R, Wellons JI, Oakes W: Unilateral lambdoidal synostosis with mendosal suture involvement. *Pediatr Neurosurg* 39:55, 2003
- Shahinian H, Jaekle R, Suh RH, et al: Obstetrical factors governing the etiopathogenesis of lambdoid synostosis. *Am J Perinatol* 15:281-286, 1998
- Chumas P, Cinalli G, Arnaud E, et al: Classification of previously unclassified cases of craniosynostosis. *J Neurosurg* 86:177-181, 1997
- Renier D, Cinalli G, Lajeunie E, et al: Oxycephaly, a severe craniosynostosis. Apropos of a series of 129 cases. *Arch Pediatr* 4:722-729, 1997
- Cohen MJ: Craniosynostosis: Diagnosis, Evaluation, and Management. New York, NY, Oxford University Press, 2000
- Wilkie AO: Craniosynostosis: Genes and mechanisms. *Hum Mol Genet* 6:1647-1656, 1997
- Wilkie AO, Patey SJ, Kan S, et al: FGFs, their receptors, and human limb malformations: Clinical and molecular correlations. *Am J Med Genet* 112:266-278, 2002
- Jabs E: Toward understanding the pathogenesis of craniosynostosis through clinical and molecular correlates. *Clin Genet* 53:79-86, 1998
- Rutland P, Pulleyn LJ, Reardon W, et al: Identical mutations in the *FGFR2* gene cause both Pfeiffer and Crouzon syndrome phenotypes. *Nat Genet* 9:173-176, 1995
- Meyers G, Day D, Goldberg R, et al: *FGFR2* exon IIIa and IIIc mutations in Crouzon, Jackson-Weiss, and Pfeiffer syndromes: Evidence for missense changes, insertions, and a deletion due to alternative RNA splicing. *Am J Hum Genet* 58:491-498, 1996
- Ghouzzi VE, Le Merrer M, Perrin-Schmitt F, et al: Mutations of the *TWIST* gene in the Saethre-Chotzen syndrome. *Nat Genet* 15:42-46, 1997
- Howard T, Paznekas WA, Green ED, et al: Mutations in *TWIST*, a basic helix-loop-helix transcription factor, in Saethre-Chotzen syndrome. *Nat Genet* 15:36-41, 1997
- Jabs E, Muller U, Li X, et al: A mutation in the homeodomain of the human *MSX2* gene in a family affected with autosomal dominant craniosynostosis. *Cell* 75:443-450, 1993
- Wilkie AO, Tang Z, Elanko N, et al: Functional haploinsufficiency of the human homeobox gene *MSX2* causes defects in skull ossification. *Nat Genet* 24:387-390, 2000
- Online Mendelian Inheritance In Man (OMIM) www.ncbi.nlm.nih.gov/sites/entrez?db Accessed May 2007.
- Johnson D, Horsley SW, Moloney DM, et al: A comprehensive screen for *TWIST* mutations in patients with craniosynostosis identifies a new microdeletion syndrome of chromosome band 7p21.1. *Am J Hum Genet* 63:1282-1293, 1998
- Zackai EH, Stolle CA: A new twist: some patients with Saethre-Chotzen syndrome have a microdeletion syndrome. *Am J Hum Genet* 63:1277-1281, 1998
- Gripp KW, Zackai EH, Stolle CA: Mutations in the human *TWIST* gene. *Hum Mutat* 15:150-155, 2000
- Chun K, Teebi AS, Jung JH, et al: Genetic analysis of patients with the Saethre-Chotzen phenotype. *Am J Med Genet* 110:136-143, 2002
- de Heer IM, de Klein A, van den Ouweland AM, et al: Clinical and

- genetic analysis of patients with Saethre-Chotzen syndrome. *Plast Reconstr Surg* 115:1894-1902, 2005; discussion 1903-1905
35. Murdoch-Kinch CA, Ward RE: Metacarpophalangeal analysis in Crouzon syndrome: Additional evidence for phenotypic convergence with the acrocephalosyndactyly syndromes. *Am J Med Genet* 73:61-66, 1997
  36. Cinalli G, Renier D, Sebag G, et al: Chiari "malformation" in Crouzon syndrome. *Arch Pediatr* 3:433-439, 1996
  37. Hall BD, Cadle RG, Golabi M, et al: Beare-Stevenson cutis gyrata syndrome. *Am J Med Genet* 44:82-89, 1992
  38. Przylepa K, Paznekas W, Zhang M, et al: Fibroblast growth factor receptor 2 mutations in Beare-Stevenson cutis gyrata syndrome. *Nat Genet* 13:492-494, 1996
  39. Yacubian-Fernandes A, Palhares A, Giglio A, et al: Apert syndrome: Factors involved in the cognitive development. *Ar Neuropsiquiatr* 63: 963-968, 2005
  40. Quintero-Rivera F, Robson CD, Reiss RE, et al: Intracranial anomalies detected by imaging studies in 30 patients with Apert syndrome. *Am J Med Genet A* 140:1337-1338, 2006
  41. Renier D, Arnaud E, Cinalli G, et al: Prognosis for mental function in Apert's syndrome. *J Neurosurg* 85:66-72, 1996
  42. Cohen MM Jr, Kreiborg S: Visceral anomalies in the Apert syndrome. *Am J Med Genet* 45:758-760, 1993
  43. Ferreira JC, Carter SM, Bernstein PS, et al: Second-trimester molecular prenatal diagnosis of sporadic Apert syndrome following suspicious ultrasound findings. *Ultrasound Obstet Gynecol* 14:426-430, 1999
  44. Wilkie AO, Slaney SF, Oldridge M, et al: Apert syndrome results from localized mutations of FGFR2 and is allelic with Crouzon syndrome. *Nat Genet* 9:165-172, 1995
  45. Slaney SF, Oldridge M, Hurst JA, et al: Differential effects of FGFR2 mutations on syndactyly and cleft palate in Apert syndrome. *Am J Hum Genet* 58:923-932, 1996
  46. Van Dissel-Emiliani FM, De Boer-Brouwer M, De Rooij DG: Effect of fibroblast growth factor-2 on Sertoli cells and gonocytes in coculture during the perinatal period. *Endocrinology* 137:647-654, 1996
  47. Schweitzer DN, Graham JM Jr, Lachman RS, et al: Subtle radiographic findings of achondroplasia in patients with Crouzon syndrome with acanthosis nigricans due to an Ala391Glu substitution in FGFR3. *Am J Med Genet* 98:75-91, 2001
  48. Saavedra D, Richieri-Costa A, Guion-Almeida ML, et al: Craniofronto-nasal syndrome: Study of 41 patients. *Am J Med Genet* 61:147-151, 1996
  49. Anyane-Yeboah K, Gunning L, Bloom AD: Baller-Gerold syndrome craniosynostosis-radial aplasia syndrome. *Clin Genet* 17:161-166, 1980
  50. Van Maldergem L, Siitonen HA, Jalkh N, et al: Revisiting the craniosynostosis-radial ray hypoplasia association: Baller-Gerold syndrome caused by mutations in the RECQL4 gene. *J Med Genet* 43:148-152, 2006
  51. Seto ML, Lee SJ, Sze RW, et al: Another TWIST on Baller-Gerold syndrome. *Am J Med Genet* 104:323-330, 2001
  52. Bottero L, Cinalli G, Labrune P, et al: Antley-Bixler syndrome. Description of two new cases and a review of the literature. *Childs Nerv Syst* 13:275-280, 1997; discussion 281
  53. Warman M, Mulliken JB, Hayward PG, et al: Newly recognized autosomal dominant disorder with craniosynostosis. *Am J Med Genet* 46: 444-449, 1993
  54. Wilkie AOM, Marvrogianis LA (Updated 2006): Enlarged Parietal Foramina/Cranium Bifidum. In: *GeneReviews* at GeneTests: Medical Genetics Information Resource (database online). Copyright, University of Washington, Seattle. 1997-2005. Available at <http://www.genetests.org>. Accessed October 2, 2007.
  55. Cohen M: *Craniosynostosis. Diagnosis, Evaluation, and Management*. New York, NY, Raven Press, 1986
  56. Jenkins D, Seelow D, Jehee FS, et al: RAB23 mutations in Carpenter syndrome imply an unexpected role for hedgehog signaling in cranial-suture development and obesity. *Am J Hum Genet* 80:1162-1170, 2007
  57. Lajeunie E, Le Merrer M, Marchac D, et al: Syndromal and nonsyndromal primary trigonocephaly: Analysis of a series of 237 patients. *Am J Med Genet* 75:211-215, 1998
  58. Lopez-Rangel E, Van Allen MI: Prenatal exposure to fluconazole: An identifiable dysmorphic phenotype. *Birth Defects Res A Clin Mol Teratol* 73:919-923, 2005
  59. Renier D, Lajeunie E, Arnaud E, et al: Management of craniosynostoses. *Childs Nerv Syst* 16:645-658, 2000
  60. Doherty E, Lacbawan F, Hadley D, et al: Muenke syndrome (FGFR3-related craniosynostosis): Expansion of the phenotype and review of the literature. *Am J Med Genet* 2007, (in press)
  61. Wong GB, Kakulis EG, Mulliken JB: Analysis of fronto-orbital advancement for Apert, Crouzon, Pfeiffer, and Saethre-Chotzen syndromes. *Plast Reconstr Surg* 105:2314-2323, 2000