

# Chondrodermatitis nodularis helicis in a teenager caused by frequent headphone use

Carli P Whittington<sup>1</sup> MD, Anne M Stowman<sup>2</sup> MD, Keith W Morley<sup>1</sup> MD

Affiliations: <sup>1</sup>Division of Dermatology, Department of Medicine, University of Vermont Medical Center, Burlington, Vermont, USA, <sup>2</sup>Division of Dermatopathology, Department of Laboratory Medicine and Pathology, University of Vermont Medical Center, Burlington, Vermont, USA

Corresponding Author: Keith W Morley, 111 Colchester Avenue, Dermatology (EP3), Burlington, VT 05401, Tel: 802.847.4570, Email: [keith.morley@uvmhealth.org](mailto:keith.morley@uvmhealth.org)

## Abstract

Chondrodermatitis nodularis helicis is a benign condition that presents as a painful ear nodule and is commonly seen in older adults. Herein, we highlight a pediatric case of chondrodermatitis nodularis helicis caused by an increasingly common age-related behavior of frequent headphone use.

*Keywords: helix, antihelix, pediatric, benign neoplasm, repetitive behaviors*

## Introduction

Chondrodermatitis nodularis helicis (CNH) commonly manifests in adults as a painful, firm, skin-colored papule or nodule on the ear. There are very few documented pediatric CNH cases. Herein, we report biopsy-proven CNH in a teenager related to a specific repetitive behavior.

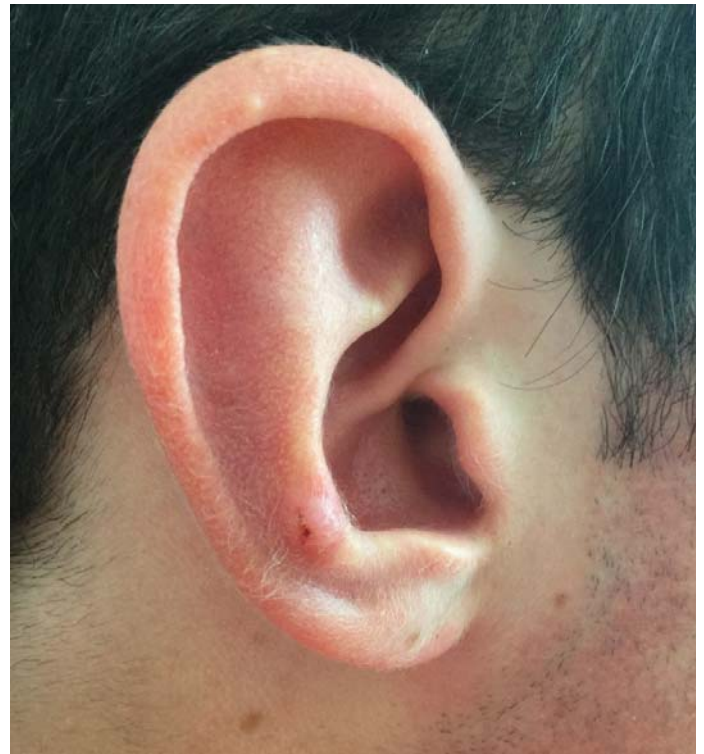## Case Synopsis

A healthy 15-year-old boy presented with a painful bump on his right antihelix of 9 months' duration. The nodule had grown larger and developed ulceration with hemorrhagic crust (**Figure 1**). A diagnostic and initially therapeutic biopsy was performed and showed an acanthotic, reactive-appearing epidermis with parakeratosis and orthokeratosis consistent with CNH (**Figure 2**). The nodule on the patient's right ear recurred 5 months later. He reported sleeping on his right side and

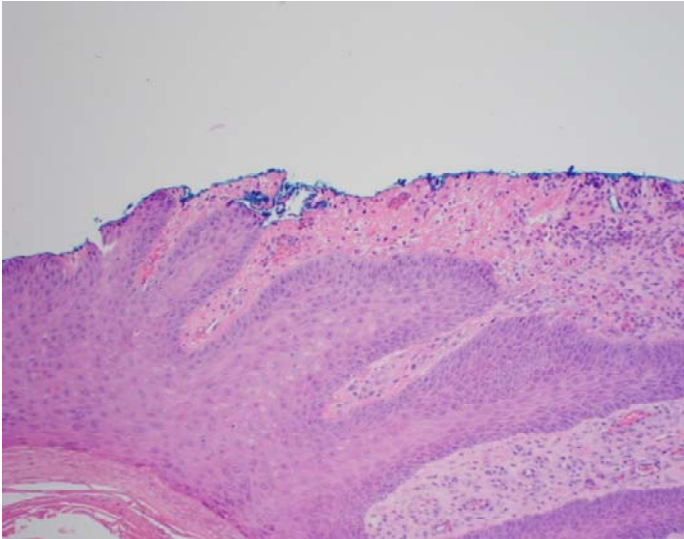
wearing over-the-ear headphones up to 8 hours a day playing video games. The area was successfully treated with liquid nitrogen with no known recurrence to date.

## Case Discussion

First described in the early 1900s, CNH is a benign, inflammatory condition of unknown etiology and likely develops when pressure on anatomically protuberant regions of the ear, such as the helix or



**Figure 1.** Right antihelix with pink, fibrotic papule with central overlying crust.



**Figure 2.** Biopsy from the right antihelix shows epidermal hyperplasia with reactive cytologic changes. There is overlying hyperkeratosis and focal parakeratosis. Scattered dyskeratotic keratinocytes can be seen within the epidermis. Within the dermis, there are increased numbers of small thin-walled blood vessels lined by reactive-appearing endothelial cells. Fibrin is seen at the base of the biopsy, and adjacent to an area of sinus tract formation (not pictured). H&E, 10 $\times$ .

antihelix, contributes to mechanical stress and decreased blood flow leading to focal tissue ischemia and a reactive inflammatory process. Other contributing factors have been reported, such as chronic photodamage, cold temperature exposure, abnormal or variant external ear anatomy, and conditions that involve vascular injury or compromise. Histologically, CNH appears as a well-demarcated region of epidermal acanthosis, overlying parakeratosis or orthokeratosis, and occasionally sinus tract formation. The dermis may exhibit degenerative and fibrotic changes with fibrin deposition, small vessel proliferation, and inflammatory infiltrate that involves underlying perichondrium.

There are very few reported pediatric cases of CNH. Some were associated with subacute cutaneous lupus erythematosus, dermatomyositis, and Beckwith-Wiedemann syndrome with macrotia [1-4],

## References

1. Rogers NE, Farris PK, Wang AR. Juvenile chondrodermatitis nodularis helicis: a case report and literature review. *Pediatr Dermatol.* 2003;20:488-90. [PMID: 14651566].
2. Fix WC, Cornejo C, Duffy KA, et al. Pediatric chondrodermatitis nodularis helicis (CNH) in a child with Beckwith-Wiedemann syndrome (BWS). *Pediatr Dermatol.* 2019;36:388-90. [PMID: 31111111].

but CNH may affect healthy children in the setting of repetitive ear trauma. Unlike adults, it would be unusual for children to have enough photodamage to develop malignant neoplasms like squamous or basal cell carcinoma, although viral warts could be mistaken for CNH.

Various CNH treatments exist, ranging from observation to surgical removal. If any suspicion for malignancy or dermatologic entity other than CNH exists, biopsy should be considered and can be therapeutic. Other options include topical non-steroidal anti-inflammatory agents, liquid nitrogen, laser ablation, topical or intralesional corticosteroids, and surgical excision of skin and/or cartilage. Behavioral changes are recommended to decrease risk of CNH progression and recurrence. Frequent repositioning of headphones, cell phones, hats, helmets, or straps that apply pressure to the ear may help. In addition, utilization of padding, silk pillows, and/or especially designed doughnut (CNH) pillows while sleeping may also be beneficial. Repetitive picking or rubbing should be avoided.

## Conclusion

Chondrodermatitis nodularis helicis classically presents as a painful ear nodule in adults. This report presents a healthy teenager who developed CNH after a specific repetitive behavior (e.g. wearing over-the-ear headphones) and was successfully treated with biopsy and eventual cryosurgery. This case is significant because CNH is rare but likely underreported in children and highlights the importance of counseling regarding increasingly common, age-related repetitive behaviors that can induce trauma to the ear.

## Potential conflicts of interest

The authors declare no conflicts of interests.

- 30773672].
3. Sasaki T, Nishizawa H, Sugita Y. Chondrodermatitis nodularis helices in childhood dermatomyositis. *Br J Dermatol.* 1999;141:363-65. [PMID: 10468826].
  4. Grigoryants V, Qureshi H, Patterson JW, Lin KY. Pediatric chondrodermatitis nodularis helices. *J Craniofac Surg.* 2007;18:228-31. [PMID: 17251869].