

# Sleep and Epilepsy, Clinical Spectrum and Updated Review



Ting Wu, MD<sup>a</sup>, Alon Y. Avidan, MD, MPH<sup>b,\*</sup>, Jerome Engel Jr, MD, PhD<sup>c</sup>

## KEYWORDS

- Epilepsy • Interictal discharges • Sleep-related hypermotor epilepsy • Parasomnias
- Sleep-related movement disorder

## KEY POINTS

- Among the epilepsy syndromes, self-limited epilepsy with centrotemporal spikes and Panayiotopoulos syndrome have seizures that occur more often during sleep whereas seizures associated with juvenile myoclonic epilepsy (JME) occur in general within 2 hours of awakening.
- Disturbed sleep as manifested by reduced sleep efficiency and decreased percentage of slow wave sleep commonly is found in patients with Lennox-Gastaut syndrome as well as focal epilepsy.
- Non-rapid eye movement parasomnia preferentially arise out of stage N3, do not manifest with hyperkinetic automatism, are not stereotyped, and are much less frequent compared with seizures associated with sleep-related hypermotor epilepsy.
- Blowing, deep inspiration, sniffing, coughing, and changes in respiratory rate and volume were seen more often with seizures than with rapid eye movement sleep behavior disorder (RBD), whereas dream recollection is more suggestive of RBD.

## INTRODUCTION

Recording of brain wave patterns during sleep often is essential in the evaluation of patients presenting for complex nocturnal behaviors. It is helpful particularly when sleep-related epilepsy is on the differential diagnosis. This is because for certain epilepsy syndromes, the awake electroencephalogram (EEG) may be entirely normal during the day, with epileptiform discharges and/or seizures manifesting only during sleep. In this review, the role of sleep in facilitating the activation of epileptiform discharges is discussed briefly. This is followed by examining, in more detail, those epilepsy types and syndromes whose presentation are strongly influenced by the sleep-wake cycle. Finally, in the last part, clinical manifestations of parasomnias and sleep-related movement

disorders are contrasted with typical semiology of sleep-related hypermotor seizures.

## SLEEP AND INTERICTAL DISCHARGES

In general, epileptiform discharges are more common and facilitated during non-rapid eye movement (NREM) sleep compared with rapid eye movement (REM) sleep. Spikes have been shown to exhibit homeostatic pattern similar to that of slow waves of sleep, occurring with greater density in the first few cycles of sleep and decreasing in frequency and abundance as sleep continues.<sup>1,2</sup> Although coupling with slow wave is noted in most epilepsies, coupling of interictal discharges with spindles also has been reported, for example, in self-limited epilepsy with centrotemporal spikes.<sup>3</sup> The preponderance of epileptiform discharges

<sup>a</sup> Ronald Reagan Medical Center, David Geffen School of Medicine at UCLA, 710 Westwood Plaza, Room 1-240, Los Angeles, CA 90095, USA; <sup>b</sup> UCLA Sleep Disorders Center, UCLA Department of Neurology, David Geffen School of Medicine at UCLA, 710 Westwood Boulevard, RNRC, C153, Mail Code 176919, Los Angeles, CA, USA; <sup>c</sup> UCLA Seizure Disorder Center, Brain Research Institute, David Geffen School of Medicine at UCLA, 10833 Le Conte Avenue, Los Angeles, CA 90095, USA

\* Corresponding author.

E-mail address: [avidan@mednet.ucla.edu](mailto:avidan@mednet.ucla.edu)

during NREM sleep has been attributed to hypersynchrony. In particular, during NREM sleep, there is reduced input from the brainstem reticular activating system, which results in progressive hyperpolarization and synchronization of the thalamocortical circuits.<sup>4</sup> This state of synchronization facilitates the occurrence of epileptiform discharges. On the other hand, although seen much more rarely, epileptiform discharges also may occur during REM sleep, where the EEG is desynchronized, and muscle tone is attenuated. Studies have found that ictal discharges persisting during REM sleep more diagnostic valuable for seizure localization.<sup>5,6</sup>

## SLEEP AND SELECT EPILEPSY SYNDROMES

Approximately 12% to 20% of seizures occur exclusively at night.<sup>1,7,8</sup> This section reviews in brief the epilepsy syndromes whose seizures have a strong correlation with sleep, focusing mostly on the role sleep plays in the clinical or EEG manifestations of these seizures.

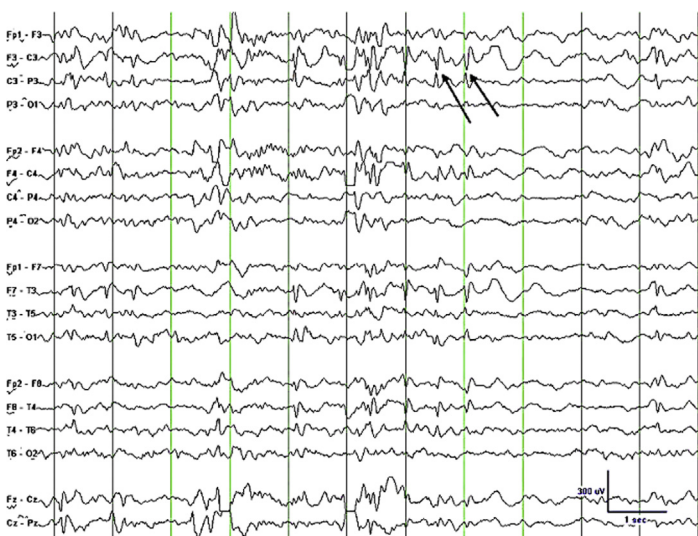
### *Self-limited Epilepsy with Centrotemporal Spikes*

Self-limited epilepsy with centrotemporal spikes, previously known as benign rolandic epilepsy or benign epilepsy with centrotemporal spikes, is one of the most common childhood epilepsy syndromes (Fig. 1). Onset usually is between ages 3 years and 13 years, with remission before the age of 16.<sup>9-12</sup> Paresthesia involving cheeks, tongue, and lips may precede the seizure. Three types of semiology have been described<sup>13</sup>: (1) hemifacial seizures with speech arrest and

drooling with preserved awareness; (2) hemifacial seizures with loss of awareness, gurgling-grunting, and postictal emesis; and (3) hemibody tonic-clonic seizures. On EEG, high-amplitude spike or spike-and-wave discharges with a transverse dipole in the centrotemporal region, which may shift or spread from side to side, are activated by drowsiness and NREM sleep.<sup>7-9</sup> Work by Varotto and colleagues<sup>9</sup> was suggestive that a state of reduced local connectivity and diffuse disconnection during light sleep may be responsible for epileptogenesis. Although remission rate is high, behavioral and neuropsychological problems are reported and may be correlated with intermittent slow waves noted during wakefulness and high number of spikes in the first hour of sleep as well as high index of multiple asynchronous bilateral spike waves in the first hours of sleep.<sup>14</sup>

### *Panayiotopoulos Syndrome*

Panayiotopoulos syndrome primarily affects children between 1 year and 14 years of age, with 76% of the cases between ages 3 years and 6 years<sup>15</sup>; 70% of the seizures occur during sleep, with another 13% upon awakening.<sup>16</sup> More than 80% have nausea, retching, and emesis with preserved consciousness at the beginning of a seizure. Autonomic symptoms, such as pallor, flushing, cyanosis, incontinence, hypersalivation, mydriasis or miosis, temperature dysregulation, and cardiorespiratory irregularities, also are common. These may be followed by loss of consciousness, eye and head deviation, speech arrest, hemifacial convulsions, or visual hallucinations, which may proceed into hemibody or generalized convulsions. Prolonged seizures, some lasting for



**Fig. 1.** Repetitive centrotemporal spikes (arrows) in an 8-year-old boy with benign rolandic epilepsy. (From Bazil, Carl W. "Effects of Sleep on the Postictal State." *Epilepsy & Behavior* 19, no. 2 (2010): 146 to 50. <https://doi.org/10.1016/j.yebeh.2010.06.022>. <http://www.sciencedirect.com/science/article/pii/S1525505010004439>" (requires permission).)

more than 30 minutes and even hours, may be common.<sup>15</sup> Interictal EEG may demonstrate multifocal spike with a shifting focus, with occipital spikes the most commonly encountered (76%), followed by discharges in temporal (24%), parietal (16%), central (14%), and frontal (10%) regions, either alone or in combination.<sup>16</sup> Occasionally, no interictal discharges are present. A majority of patients have fewer than 5 seizures prior to remission, which usually is within 1 year to 2 years of onset.<sup>15</sup> Fig. 2 illustrates an EEG notable for occipital spikes from a patient who presented with the typical autonomic symptoms.

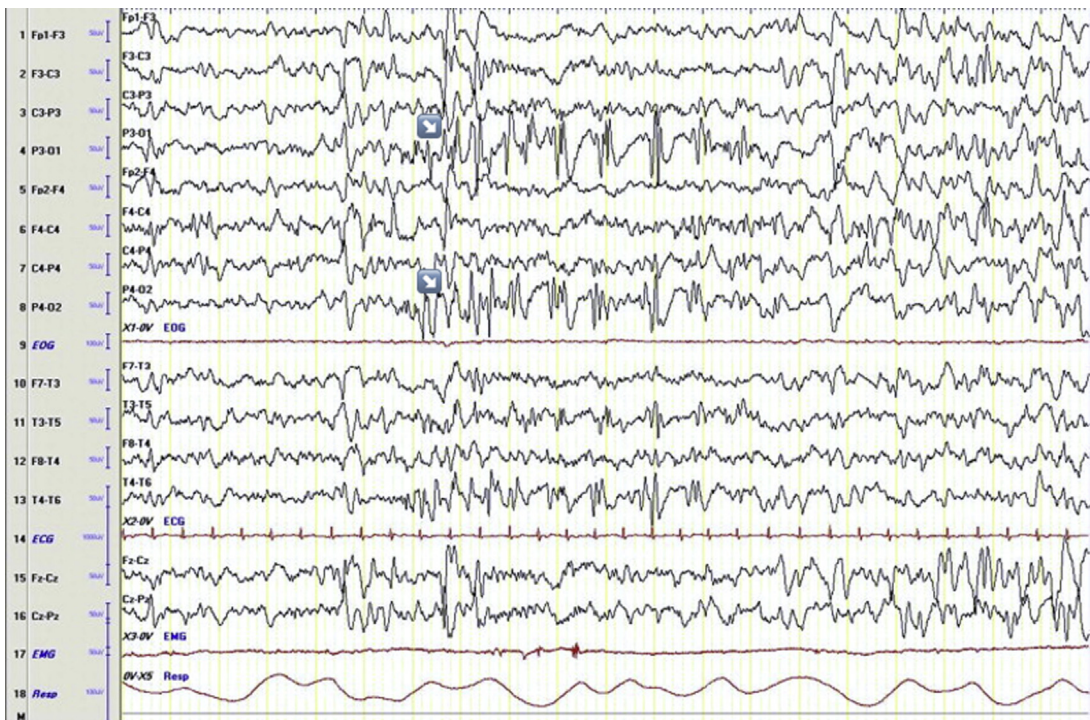
### West Syndrome

West syndrome is characterized by triad of infantile spasm, intellectual disability and a specific EEG pattern, termed *hypsarrhythmia* (Fig. 3). An electrodecremental response characterized by relative diffuse attenuation may be noted with spasms. Onset usually is between 3 months to 12 months of age and presents clinically with brief postarousal, synchronous spasms of head, trunk, and limbs,

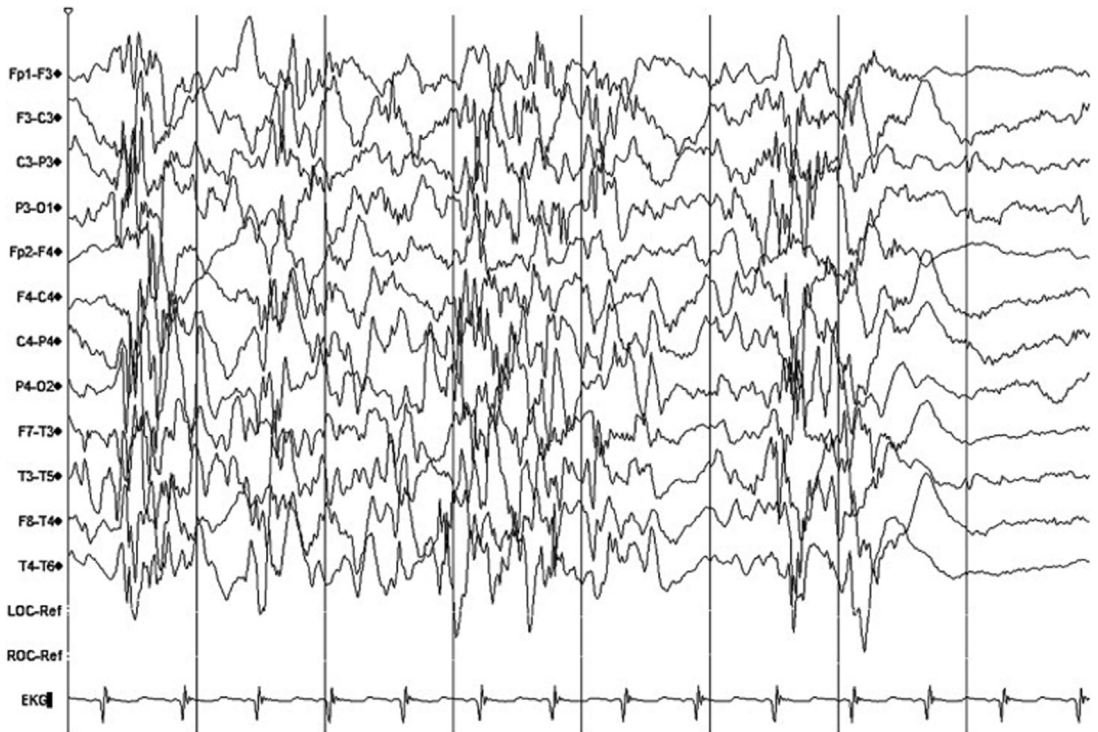
which often occur in clusters and may be associated with a stereotypical cry.<sup>7,8</sup> Studies have shown that *hypsarrhythmia* interferes with the physiologic decrease in slow waves in NREM sleep throughout the night and consequently disrupts memory consolidation that normally takes place during sleep.<sup>17</sup>

### Lennox-Gastaut Syndrome

With Lennox-Gastaut syndrome, the typical onset is between 3 years and 5 years of age. Characteristically, multiple seizure types may be present, including tonic, tonic-clonic, myoclonic, atonic, and atypical absences.<sup>18,19</sup> On EEG, slow spikes and sharp waves (Fig. 4) as well as polyspikes are common. Disruptions in sleep include reduced sleep efficiency and increased number of awakenings as well as increased NREM stages N1 and N2 and decreased slow wave sleep. Studies have found that the number of interictal discharges peak during the first 3 hours and decrease throughout the night, possibly related to the natural homeostatic process of sleep.<sup>20</sup> Lifelong intellectual disability is common.



**Fig. 2.** Panayiotopoulos syndrome: this is an EEG from a toddler who presented with episodes before going to bed, of nausea and vomiting followed by loss of consciousness, clonic movements of lower extremities, tonic deviation of gaze, and fecal incontinence. The sleep EEG is noted for numerous spike-and-wave paroxysms in that predominate in occipital regions (arrows) with spread to anterior region (time constant: 0.3 s; high-frequency filter: 35 Hz). (From Martín del Valle, F., A. Díaz Negrillo, G. Ares Mateos, F. J. Sanz Santaefemia, T. Del Rosal Rabes, and F. J. González-Valcárcel Sánchez-Puelles. "Panayiotopoulos Syndrome: Probable Genetic Origin, but Not in Scn1a." *European Journal of Pediatric Neurology* 15, no. 2 (2011): 155-57. <https://doi.org/10.1016/j.ejpn.2010.08.002> <http://www.sciencedirect.com/science/article/pii/S1090379810001510>" (requires permission).)



**Fig. 3.** Classic interictal EEG in a patient with infantile spasm highlighting hypersarrhythmia. The EEG depicted multifocal or generalized spikes, intermixed with a rather chaotic and asynchronous mixture of high-voltage slow wave activity and sharp waves. Focal slow activity is apparent on the right centrotemporal and occipital regions. Attenuated slow waves may be noted intermittently. (From: Journal of Experimental & Clinical Medicine. Kuo, Yung-Ting, Ying-Tzu Chen, Geng-Chang Yeh, Hsiao-Feng Chou, Chuan-Yu Wang, and Chuang Chin Chiueh. "Theta Power Spectral Analysis of Electroencephalography in Infantile Spasms: Before and after Acth Treatment." Journal of Experimental & Clinical Medicine 4, no. 6 (2012): 330-33. <https://doi.org/10.1016/j.jecm.2012.10.009>. <http://www.sciencedirect.com/science/article/pii/S1878331712001325>. (requires permission).)

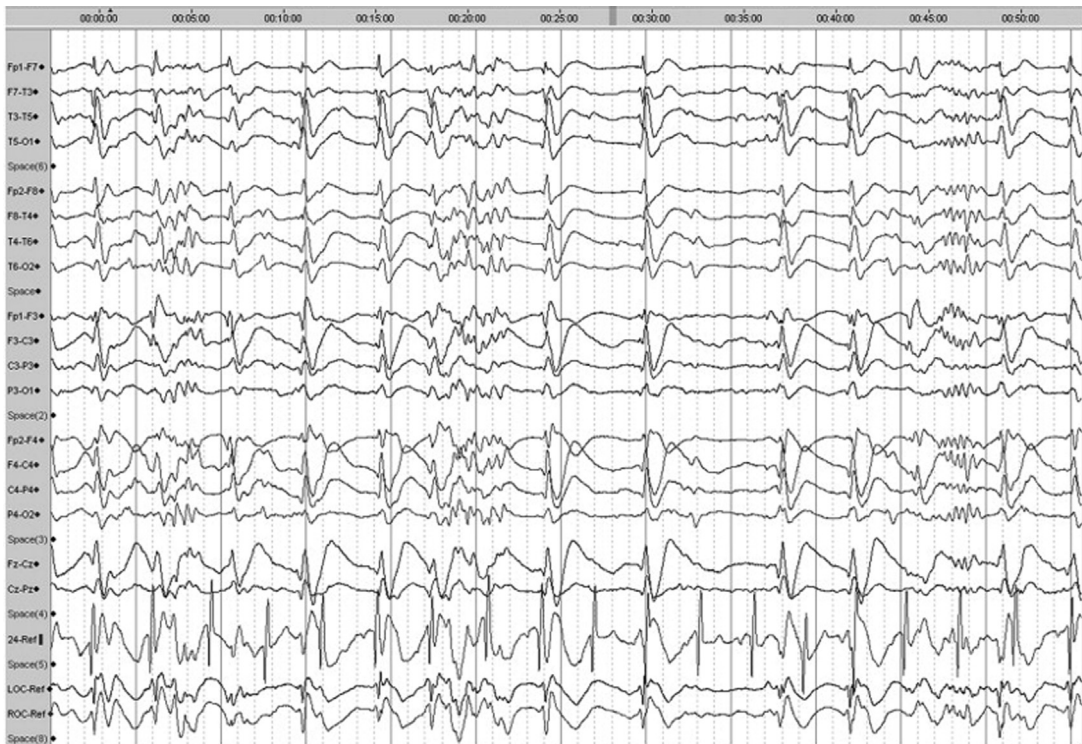### **Childhood Absence Epilepsy**

Most common between the ages of 4 years and 14 years, absence epilepsy is characterized by brief (usually <10 seconds) pauses in activity, sometimes with associated eyelid fluttering. The EEG demonstrates characteristic "typical 3 Hz Spike-and-wave complexes (SWC)" discharges are pathognomonic (Fig. 5). Particularly during the first cycle of sleep, generalized spike waves are common, and polyspikes as well as focal spike waves with frontal predominance also may be seen.<sup>7,8</sup> Studies have suggested these interictal discharges may have preference for the transition periods between wakefulness to sleep as well as between stages of NREM sleep.<sup>21,22</sup>

### **Juvenile Myoclonic Epilepsy**

Juvenile myoclonic epilepsy (JME) has onset between 8 years and 26 years of age and is characterized by seizures generally within 2 hours of awakening.<sup>7,8</sup> Common triggers include sleep deprivation and sudden arousals.<sup>18,19</sup> Prior to a first-time seizure, brief myoclonic jerks, especially

affecting the upper extremities, but also that may affect the lower extremities, with retained consciousness may be reported; the presence of myoclonus is essential to making the diagnosis (Fig. 6).<sup>23</sup> Other than the most common generalized tonic-clonic seizures, absence as well as perioral reflex myoclonia (precipitated by reading, speaking, and other neuropsychological activation) and praxis-induced seizures also may be seen. EEG is characterized by greater than 3.5 Hz (on average) spike and slow wave and/or polyspike discharges, more frequent at sleep onset or on arousal (Fig. 7).<sup>18,19</sup> Mekky and colleagues<sup>24</sup> have shown that compared with control population, JME patients reported more insomnia and excessive daytime sleepiness. In terms of sleep parameters, reduced sleep efficiency, increased wake after sleep onset, prolonged REM latency, and, interestingly, prolonged REM duration were reported. The arousal index during both NREM and REM sleep also was significantly higher compared with control, in line with significantly disrupted sleep.<sup>24</sup> Other studies have confirmed these findings except that REM



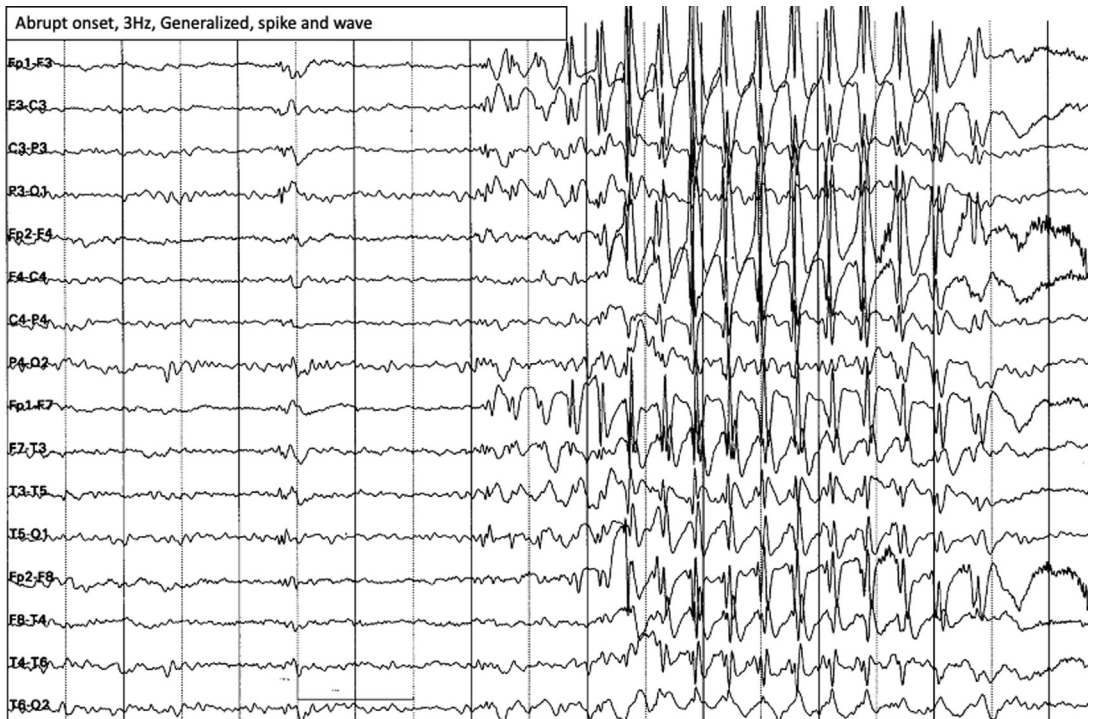
**Fig. 4.** Representative electroencephalogram of Lennox-Gastaut syndrome, demonstrating the characteristic slow spike-and-wave complexes. (From: VanStraten, Amanda F, and Yu-Tze Ng. "Update on the Management of Lennox-Gastaut Syndrome." *Pediatric Neurology* 47, no. 3 (2012): 153-61. <https://doi.org/10.1016/j.pediatrneurol.2012.05.001>. <http://www.sciencedirect.com/science/article/pii/S0887899412002147>. (Requires permission).)

percentage generally was decreased compared with control.<sup>24,25</sup> A majority of patients have no reported neuropsychiatric deficits.

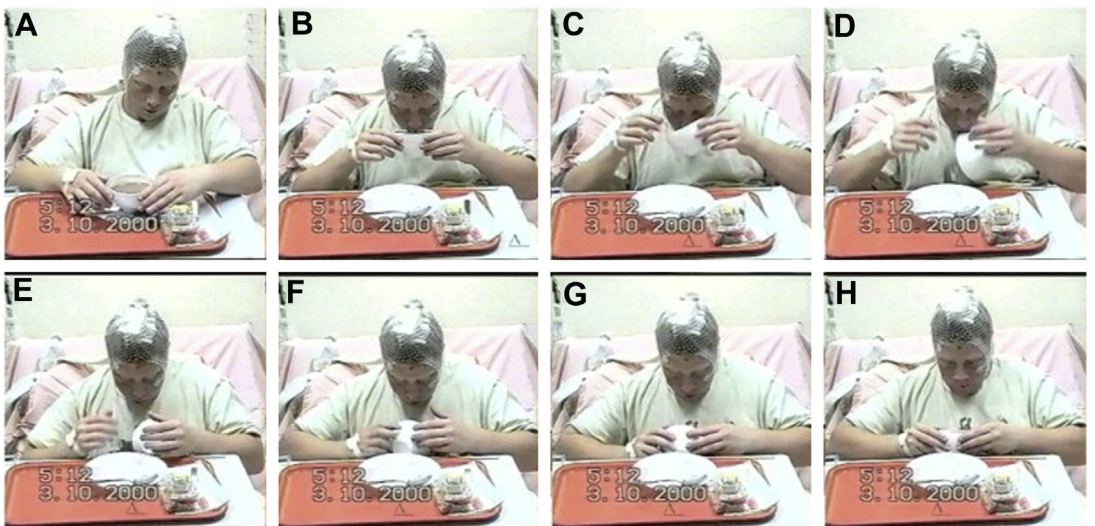
### **Electrical Status Epilepticus During Slow Wave Sleep**

Electrical status epilepticus during slow wave sleep (ESES) and continuous spike-and-wave discharges during sleep (CSWS) are used interchangeably and described by the International League Against Epilepsy as follows: "Epilepsy with continuous spike-and-waves during slow sleep results from the association of various seizure types, partial or generalized, occurring during sleep, and atypical absences when awake. Tonic seizures do not occur, differentiating this from Lennox-Gastaut syndrome. The characteristic EEG pattern consists of continuous diffuse spike-and-waves during slow wave sleep. Duration varies from months to years. Despite the usually benign evolution of seizures, prognosis is guarded because of the appearance of neuropsychological disorders."<sup>26</sup> Onset usually is between 2 months to 2 years of age with peak between 2 years to 4 years of age.<sup>27</sup> The absence of tonic seizures differentiates this from Lennox-

Gastaut syndrome. On EEG, there is a characteristic increase with sleep onset of bilateral high amplitude 1.5-Hz to 2.5-Hz slow spike-and-wave discharges, at times with anterior predominance (Fig. 8). Classically, a spike-and-wave index (SWI) of greater than 85% during NREM sleep has been used.<sup>27</sup> Gencpinar and colleagues<sup>28,29</sup> have demonstrated that the physiologic decrease in slow waves throughout the night is disturbed in patients with ESES/CSWS with a higher SWI, resulting in a greater degree of sleep disruption. Malformations or cortical lesions may be found in approximately half of the patients with ESES/CSWS.<sup>30</sup> Mutations in GR1N2A, which encodes for the GLuN2A subunit of the *N*-methyl *D*-aspartate receptor, have been found in patients with ESES/CSWS, self-limited epilepsies with centrotemporal spikes, and Landau-Kleffner syndrome, suggesting the 3 entities may be related as continuation on a spectrum.<sup>31,32</sup> Attention deficits and hyperactivity are common, although the overall prognosis depends on the etiology, duration of ESES, and treatment response. Behavioral deficits can recover soon after normalization of EEG, although long-term cognitive deficits may remain.<sup>33</sup>



**Fig. 5.** Illustrative EEG from a patient with juvenile absence epilepsy; the ictal recording showing abrupt 3-Hz spike and slow wave discharges. (From: Zeliha Matur, Betül Baykan, Nerses Bebek, Candan Gürses, Ebru Altındağ, Ayşen Gökyiğit, The evaluation of interictal focal EEG findings in adult patients with absence seizures, *Seizure*, Volume 18, Issue 5, 2009, Pages 352-358, ISSN 1059-1311, <https://doi.org/10.1016/j.seizure.2009.01.007>. <http://www.sciencedirect.com/science/article/pii/S1059131109000041> (Requires permission).)



**Fig. 6.** The figure depicts nocturnal polygraphic recording lasting 2 seconds of an 18-year-old man with juvenile myoclonic epilepsy (JME). The panel illustrates the patient following and early morning provoked awakening during breakfast. The patient is seen lifting a cup of beverage (A,B), a myoclonic jerk event (C) makes him drop his cup of coffee (D-H). The patient also experiences mild extension and elevation of his hands (D-F). He quickly picks it up again (F-H). The whole sequence lasts 2 seconds. (From Pierre Genton, Pierre Thomas, Dorothee G.A. Kasteleijn-Nolst Trenité, Marco Tulio Medina, Javier Salas-Puig, Clinical aspects of juvenile myoclonic epilepsy, *Epilepsy & Behavior*, Volume 28, Supplement 1, 2013, Pages S8-S14, ISSN 1525-5050, <https://doi.org/10.1016/j.yebeh.2012.10.034>. (<http://www.sciencedirect.com/science/article/pii/S152550501300005X>) (Requires permission).)

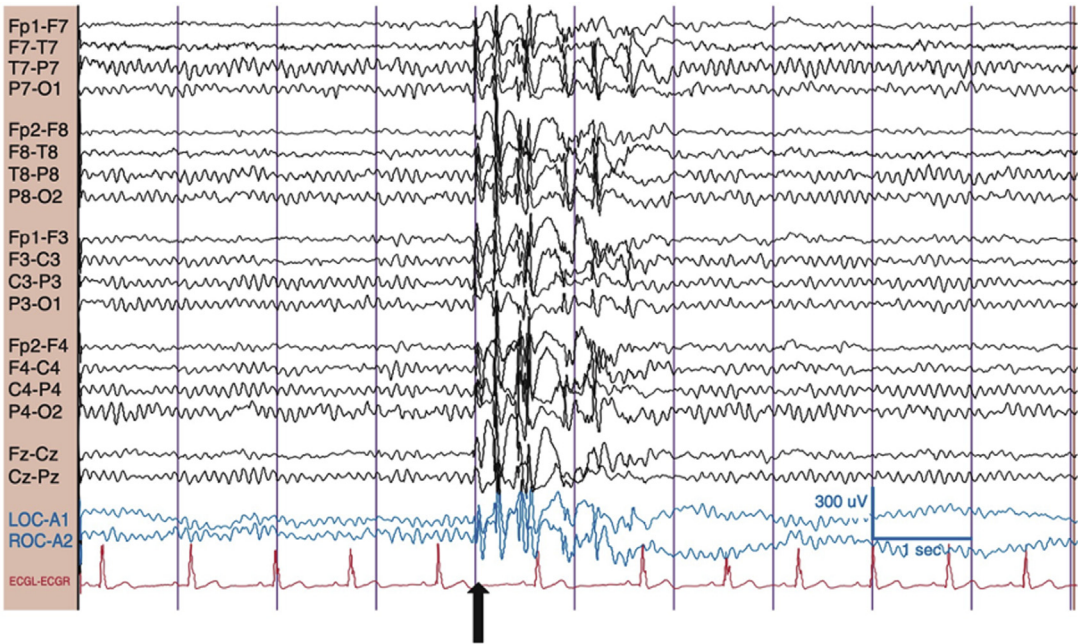


Fig. 7. Representative EEG in a 17-year-old girl with JME, highlighting the generalized irregular 4-Hz spike and polyspike and wave (arrow) in the setting of a normal background. The arrow highlights an episode of a jerk document by the technician during this discharge. (From: Marcuse, Lara V, MD; Fields, Madeline C, *The EEG and epilepsy*, Pages 121-155. In Rowan's Primer of EEG Second Edition © 2016, Elsevier. (Requires permission).)

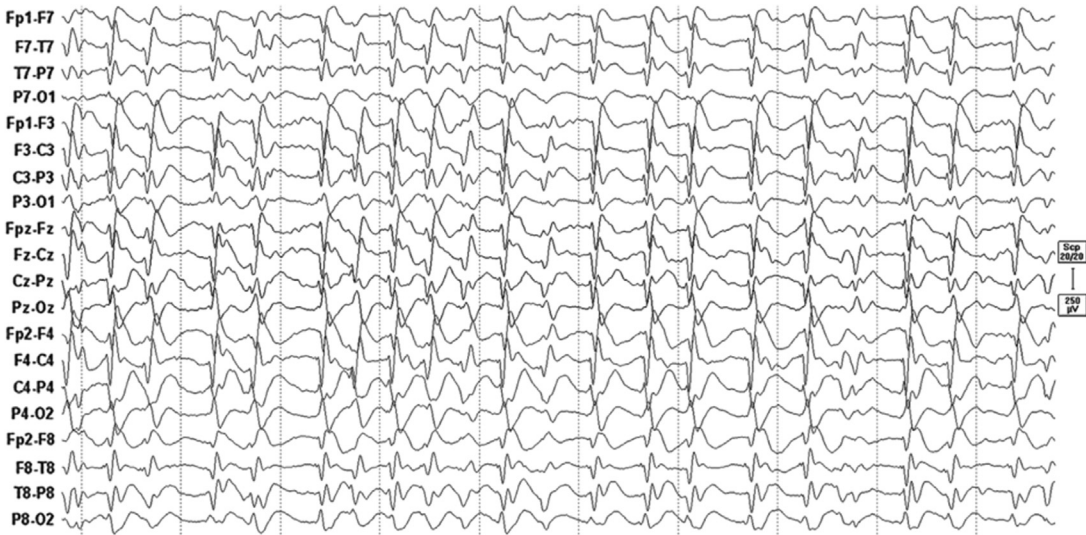


Fig. 8. Electrical status epilepticus during NREM sleep. (From: Liukkonen, Elina, and Madeleine M. Grigg-Damberger. "Electrical Status Epilepticus in Sleep." *Sleep Medicine Clinics* 7, no. 1 (2012): 147-56. <https://doi.org/10.1016/j.jsmc.2011.12.003>. <http://www.sciencedirect.com/science/article/pii/S1556407X11001159> (Requires permission).)

### Landau-Kleffner Syndrome

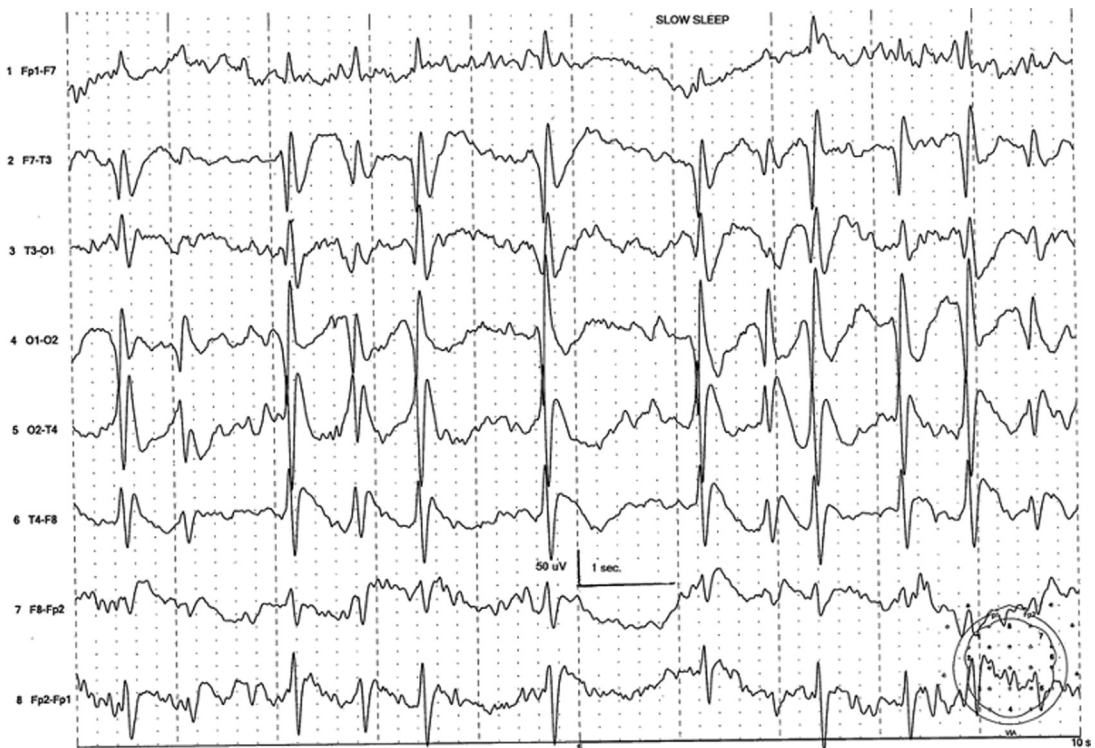
Landau-Kleffner syndrome, or acquired epileptic aphasia, has onset generally between 3 years and 9 years of age.<sup>18,19</sup> EEG is characterized by continuous spike-and-waves during NREM sleep, often with SWI of less than 85% (Fig. 9).<sup>7,8</sup> Brain imaging is normal.<sup>34</sup> Prior to onset, patients were developing normally and reaching language milestones appropriately. With onset, acute or gradual language regression is essential to diagnosis. Seizures often are focal onset with or without secondary generalization or atypical absence; approximately 20% to 30% of the patients may not have any seizures. Aphasia was thought to be related to hearing agnosia and may improve with normalization of EEG although there may be residual language and cognitive deficits.

### Focal Epilepsies

In general, seizures arising out of the temporal lobes occur more frequently during wakefulness whereas those with onset in the frontal and to a lesser extent parietal lobes occur more often

during early NREM sleep.<sup>35</sup> Miller and colleagues<sup>36</sup> found that compared with healthy controls, patients with focal epilepsy averaged less slow wave sleep, especially in the first hour of sleep, and the presence (not the number of) nocturnal discharges was associated with a longer REM latency. In their work studying ripples (80–150 Hz) occurring during sleep, Song and colleagues<sup>37</sup> found that there was a preferred phase angle of coupling between ripples and slow waves between areas of seizure onset in the frontal and parietal lobes versus areas not involved in seizure onset. Their work is based on the theory that trough to peak transition is mediated by synchronous summation of miniature excitatory postsynaptic potentials whereas peak to trough transitions are mediated by hyperpolarization of large neuronal networks.<sup>38</sup> Rates of trough to peak transitions were increased in the seizure-onset zone whereas rates of peak to trough transitions were not increased in the same area.

Among the frontal lobe seizures, those arising from the supplementary motor area may occur in both sleep and wakefulness whereas those arising



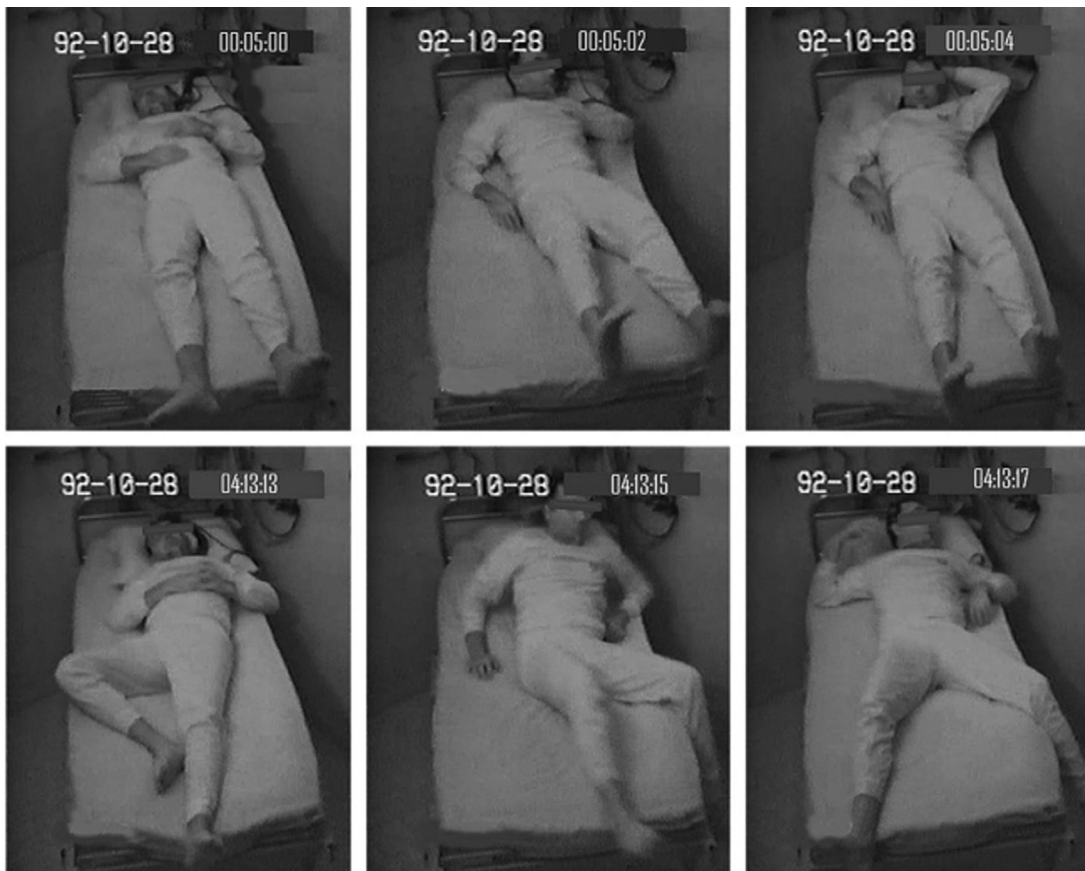**Fig. 9.** Illustrative EEG recording from a patient with Landau-Kleffner syndrome depicting the characteristic continuous spike-and-wave activity in more than 85% of slow sleep. (From: Roberto Horacio Caraballo, Natalia Cejas, Noelia Chamorro, María C. Kaltenmeier, Sebastian Fortini, Ana María Soprano, Landau-Kleffner syndrome: A study of 29 patients, *Seizure*, Volume 23, Issue 2, 2014 Pages 98-104, ISSN 1059-1311, <https://doi.org/10.1016/j.seizure.2013.09.016> .(<http://www.sciencedirect.com/science/article/pii/S105913111300277X>) (Requires permission).



from the prefrontal region, including anterior frontomesial, anterior frontolateral, and orbitofrontal cortices occur more often during NREM sleep.<sup>21</sup> In their review of orbitofrontal epilepsies, Chibane and colleagues<sup>39</sup> found that approximately 50% of the patients had sleep-related seizures, 56% either did not have an aura or reported nonspecific auras, and 62.5% had hypermotor manifestations, mostly of the hyperkinetic type. Semiology also may include autonomic disturbance, fear/anxiety, oroalimentary automatism, vocalization, and so forth, depending on propagation pathway. Epileptiform discharges in frontal and temporal leads can be seen on EEG.<sup>39</sup>

Nocturnal frontal lobe epilepsy (NFLE), renamed sleep-related hypermotor epilepsy (SRHE),<sup>40</sup> usually has onset in the second decade of life, although adult onset also has been reported.<sup>41</sup>

The change in name was an effort to bring to attention the key features of this clinical entity, namely the association of the seizures with sleep (rather than circadian rhythm of the day), the possibility of having onset external to the frontal lobes, and its distinct hypermotor semiology.<sup>40</sup> Temporal and insular-opercular are the most common regions of seizure onset after the frontal lobes, although onset from parietal, posterior cingulate, and occipital regions also has been reported.<sup>42–44</sup> Initially, seizure frequency may be high, with mean  $3 \pm 3$  seizures per night and  $20 \pm 11$  seizures per month.<sup>45</sup> Nearly all seizures occur during NREM sleep, particularly during stage 2 sleep.<sup>45</sup> Interictal EEG may be normal, and at times surface EEG may fail to capture any abnormality during an ictal event, which contributes to the difficulty in differentiating these from sleep disorders. Several



**Fig. 10.** Paroxysmal arousals in SRHE. The photographic sequences list still images taken at regular intervals during the video sequence), highlighting the semiology of the episode: simple paroxysmal arousals consisting of abrupt/sudden awakening, followed with sitting up on the bed and extending the head and trunk with the arms raised forward, facial grimacing demonstrating frightened expression, proceeding to ballistic and choreoathetotic movements. (From: Provini, Federica, Francesca Bisulli, and Paolo Tinuper. "Nocturnal Frontal Epilepsies: Diagnostic and Therapeutic Challenges for Sleep Specialists." *Sleep Medicine Clinics* 7, no. 1 (2012): 105-12. <https://doi.org/10.1016/j.jsmc.2011.12.007>. <http://www.sciencedirect.com/science/article/pii/S1556407X11001196>. (Requires permission).)

genetic mutations have been found to be associated, including mutations involving genes (CHRNA4 and CHRNB2) that encode for the subunits of the heteromeric neuronal nicotinic acetylcholine receptors, in which the autosomal dominant form is the most well-known (ADNFLE), although a recessive form due to mutation in *PRI-MA1* gene also has been described.<sup>41,46,47</sup> *PRI-MA1* is a transmembrane protein anchoring acetylcholinesterase to neuron membranes; the mutation results in an increase in cholinergic response.<sup>47</sup> Mutations in other genes (*KCNT1* and *DEPDC5*) also have been reported.<sup>48,49</sup> Based on the known mutations involving the acetylcholine system in ADNFLE, Halász and colleagues<sup>21</sup> examined the role of arousal and sleep in the activation of seizures of absence epilepsy and NFLE. Acetylcholine activating the frontal cortex is essential to arousal and with SRHE, an overactive cholinergic system results in abnormal arousals, which often are noted on EEG prior to an attack.

Therefore, this raises the possibility that SRHE may be an epilepsy related to pathology of the ascending reticular activating system.<sup>21</sup>

### SEMIOLOGY OF SLEEP-RELATED HYPERMOTOR EPILEPSY AND PARASOMNIAS

The semiology of SRHE is grouped into 3 categories, with increasing levels of complexity.<sup>21,45</sup> Paroxysmal arousals are frequent, abrupt, and brief (ranging 2–20 seconds), during which patients suddenly open their eyes, raise their heads or sit up in bed, often with dystonic posture of limbs; have a frightened or surprised expression; and scream (Fig. 10). Following the event, patients may return to sleep quickly. Minimal motor events with stereotyped movements of the limbs, axial muscles, and/or the head lasting 2 seconds to 4 seconds is another variant. The second type is paroxysmal dystonia, which usually begins with paroxysmal arousal, followed by hypermotor

05:14:25



05:15:24

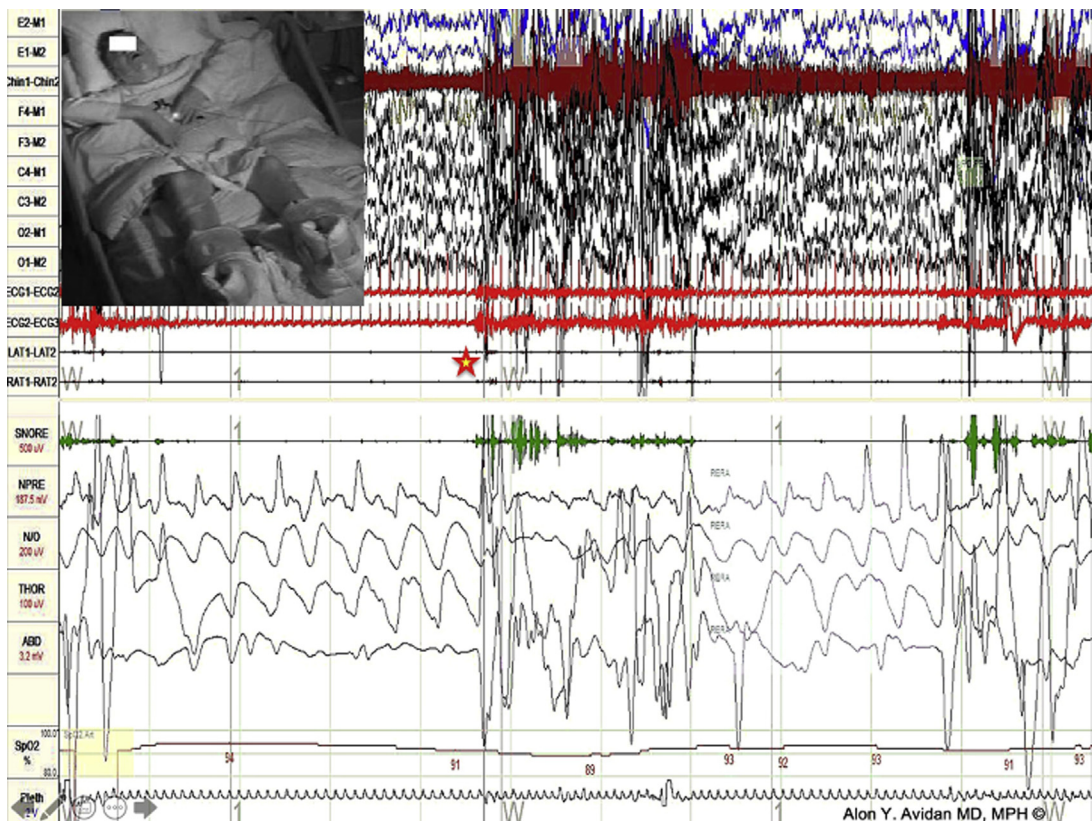


**Fig. 11.** Complex paroxysmal arousals in the setting of SRHE (previously classified as nocturnal paroxysmal dystonia because the episodes were thought to represent a movement disorder). Episodes are characterized by more rapid, vigorous, bordering on appearing combative involving the extremities (legs > arms) and along with dystonic asymmetric posturing, unintelligible vocalizations, cursing, whistling, or spitting. Epileptic nocturnal wandering is the most complex type of seizure and consists of abrupt dystonic posturing, dyskinetic gesticulation, displacement from bed, ambulation, dystonic postures jumping, yelling, and assuming an expression of dread. The episodes are on the differential diagnosis of somnambulism. (From: Provini, Federica, Francesca Bisulli, and Paolo Tinuper. "Nocturnal Frontal Epilepsies: Diagnostic and Therapeutic Challenges for Sleep Specialists." *Sleep Medicine Clinics* 7, no. 1 (2012): 105-12. <https://doi.org/10.1016/j.jsmc.2011.12.007>. <http://www.sciencedirect.com/science/article/pii/S1556407X11001196>. (Requires permission).)

behavior, which may include dystonic posturing, ballistic movement, body rocking, kicking, cycling, automatism, and head or eye deviation (Fig. 11). The episodes usually last between 20 seconds and 2 minutes. Awareness may be retained. The third type is episodic nocturnal wandering, in which the patients may exhibit various combination of stereotyped, agitated ambulation with sudden changes in direction, jumping and screaming, or other unintelligible vocalization, lasting 1 minute to 3 minutes in duration. Autonomic fluctuations in heart rate and respiratory rate also may be present. The events are highly stereotypical in the same patient, although all 3 types may manifest during different times. The variability in semiology may be due to the duration and length of the propagation pathway from the seizure-onset zone.<sup>40</sup>

### EPILEPSY VERSUS NON-RAPID EYE MOVEMENT PARASOMNIAS

Clinical manifestation of SRHE may overlap with parasomnias, in particular confusional arousal (CA), sleep terror, and sleepwalking (somnambulism). Common features shared by the 3 most common NREM parasomnias include initiation from stage N3 sleep, relatively brief duration (although may be as long as 15–20 minutes in children), and absence of higher cognitive functions, such as attention, intent, social interactions, and so forth. Patients often are difficult to arouse during the event and likely to be confused or aggressive when awakened; amnesia of the event is a universal feature.<sup>50</sup> According to the *International Classification of Sleep Disorders – Third Edition*



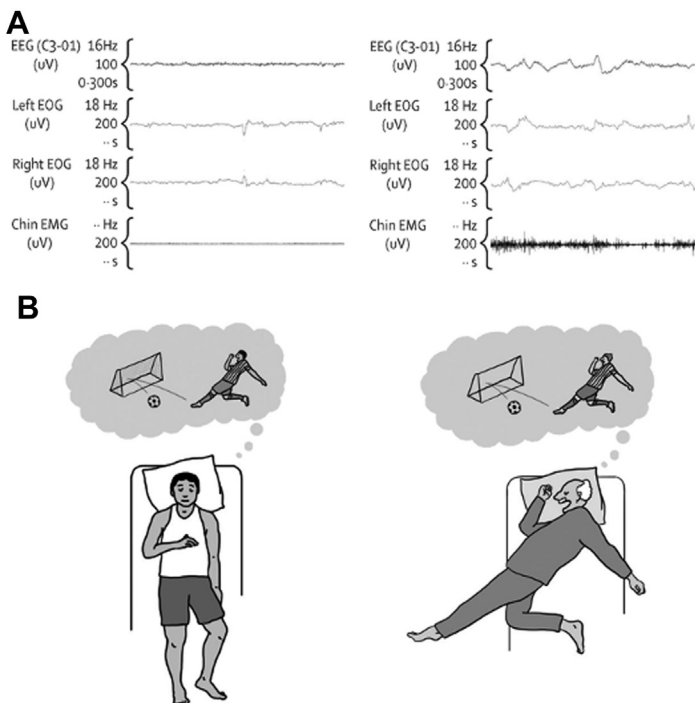
**Fig. 12.** A 120-second epoch of a diagnostic polysomnogram from a 54-year-old man conducted to evaluate for arousals with confusion and singing behavior. The figure highlights one of the patient's representative events depicted in an embedded video during his event illustrating an arousal from stage N3 sleep, as demarcated by the star, with the patient's arms abducted (flapping his arms and described by the technicians to be "quacking like a duck"). Channels are as follows: electro-oculogram (left: E1-M2; right: E2-M1), chin electromyogram (chin1-chin2), EEG (left: frontal-F3, central-C3, occipital-O1, left mastoid-M1; right: frontal-F4, central-C4, occipital-O2, right mastoid-M2), 2 ECG channels, 2 limb electromyogram (LAT and RAT), snore channel, nasal-oral airflow (N/O), nasal pressure signal (NPRES), respiratory effort (thoracic, abdominal), and oxygen saturation (Sao<sub>2</sub>). LAT, left anterior tibialis electromyogram; RAT, right anterior tibialis electromyogram. (Previously published in: Avidan, A.Y. and N. Kaplish, The parasomnias: epidemiology, clinical features, and diagnostic approach. *Clin Chest Med*, 2010. 31(2): p. 353-70. Source: Alon Y. Avidan, MD, MPH © Copyright to remain with author.)

(ICSD-3), CA (as illustrated in Fig. 12) is characterized by “mental confusion or confused behavior that occurs while the patient is in bed. There is an absence of terror or ambulation outside of the bed. There is typically a lack of autonomic arousal such as mydriasis, tachycardia, tachypnea, and diaphoresis during an episode.”<sup>50</sup> Patients with sleep terror present with an abrupt scream, autonomic activation, confusion, and inconsolability, and attempts at consolation may prolong the episode and may result in injury because the patient may become more aggressive.<sup>51</sup> The diagnostic criteria for sleep terror are as follows: “the arousals are characterized by episodes of abrupt terror, typically beginning with an alarming vocalization such as a frightening scream. There is intense fear and signs of autonomic arousal, including mydriasis, tachycardia, tachypnea, and diaphoresis during an episode.”<sup>50</sup> In adults, bolting out of bed and violent behaviors may be observed. With sleepwalking, complex and amnesic ambulation may occur along with highly inappropriate behaviors, such as urinating into a waste basket. A subtype of sleep walking is sleep-related eating disorder, which includes somnambulism along with amnesic sleep eating, often of inappropriate food items, such as a cat food/dish soap sandwich.

There are a few key features used to differentiate parasomnias from epilepsy. Parasomnias

usually occur less frequently, averaging a few times per week, rarely more than once per night, and generally less than 4 times a month. This is in contrast with nocturnal seizures, which may occur multiple times per night. Although both conditions have onset in childhood, NREM parasomnias usually manifest at a younger age and are seen much less commonly among the adult patient population (where they are likely facilitated through sleep deprivation, sleep apnea, and central nervous system active medications, in particular hypnotics and antidepressants).<sup>50</sup> Finally, compared with the epileptic episodes, NREM parasomnias preferentially arise out of stage N3 (in particular the first few hours), do not manifest with hyperkinetic automatism (such as kicking, rocking, or cycling movements), and are not stereotyped.<sup>51–53</sup> Dystonic posturing can occur in both epilepsy and NREM parasomnias. REM parasomnias, occurring during the second half of the night, are likely to manifest with abnormalities in dream content and muscle tone (augmentation in the setting of REM sleep behavior disorder [RBD] and persistent atonia/paralysis in isolated sleep paralysis).

Peter-Derex and colleagues<sup>54</sup> retrospectively analyzed the nocturnal recordings of 50 patients, 10 each among temporal lobe epilepsy (TLE), frontal lobe epilepsy (FLE), nocturnal terrors (NTs), CA, and normal arousal (NA). Their primary objective

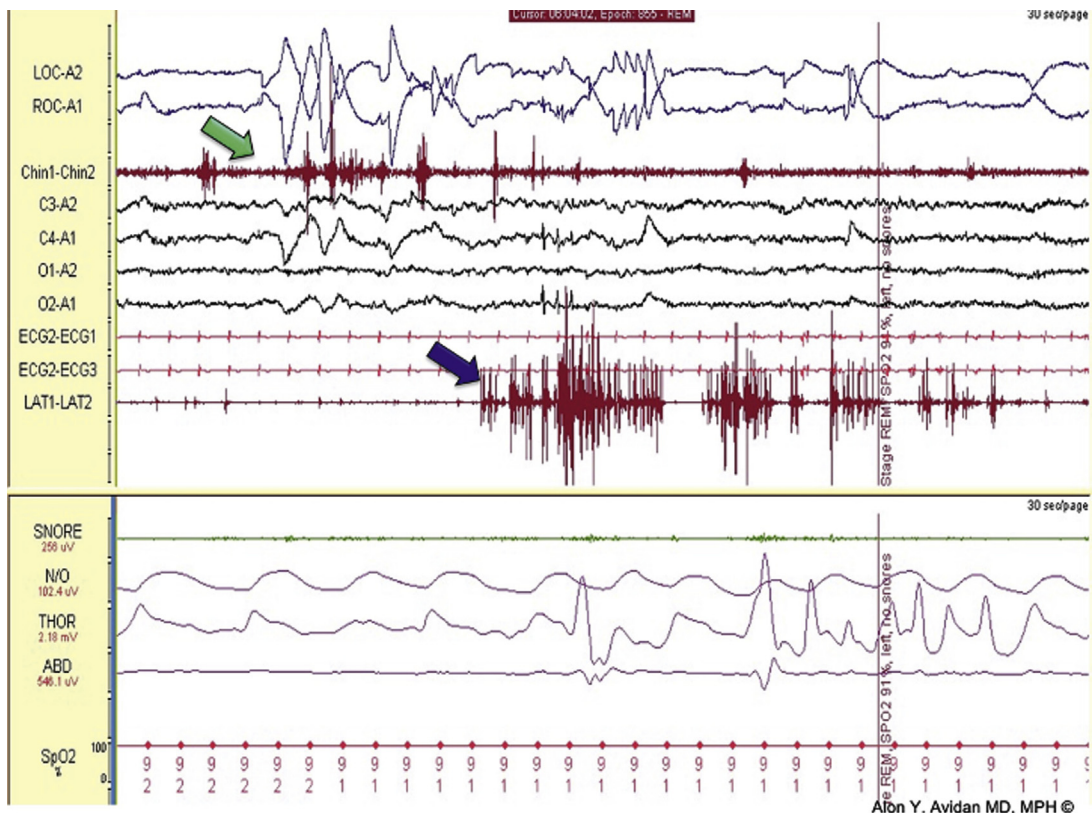


**Fig. 13.** (A) REM RSWA is depicted by a tonic and phasic muscle tone augmentation on the EMG signals of the polysomnography; normal REM sleep (left) depicts normal muscle atonia (paralysis) the chin in contrast to the abnormal muscle tone in the setting of RBD. (B) The corresponding dream enactment of hitting a soccer ball (right) in contrast to the normal sleeper who essentially is paralyzed and remains quiet and relaxed while dreaming of scoring a goal (left). Too often, patients with RBD have more aggressive dreaming (such as defending themselves against intruders, leading to injury). EMG, electromyography; EOG, electrooculography. (Francesca Siclari, Katja Valli, Isabelle Arnulf, Dreams and nightmares in healthy adults and in patients with sleep and neurological disorders, *The Lancet Neurology*, Volume 19, Issue 10, 2020, Pages 849-859, ISSN 1474-4422; with permission.)

was to study the beat-to-beat RR interval (RRI) as well as heart rate variability over a period of 60 heart beats before and after the first motor manifestation. Although the RRI was significantly lower for TLE compared with the other conditions, analysis of the slope demonstrated faster cardiac change in NTs and FLE compared with TLE and NA. There was no significant difference between NTs and FLE.

The relationship between parasomnias and epilepsy has been examined in a few studies. Provini and colleagues,<sup>45</sup> in their review of 100 cases of NFLE, found that approximately 40% of the patients had at least 1 first-degree relative with probable parasomnia. In a prospective familial aggregation study, the lifetime prevalence of sleep-walking, sleep terror, or CA was significantly higher among NFLE probands as well as their healthy relatives compared with control

population.<sup>55</sup> Cornejo-Sanchez and colleagues<sup>56</sup> studied the prevalence of sleep walking and sleep paralysis among Colombian patients with genetic epilepsy (including, JME, juvenile absence epilepsy, childhood absence epilepsy, and genetic epilepsy with febrile seizures plus). The prevalence of sleep walking was 11.6% in patients with epilepsy; this compared with a prevalence in the general Colombian population of 12.3% and 9% in 2004 and 2008, respectively. In addition, 46.3% of the patients with genetic generalized epilepsy reported having at least 1 relative with sleepwalking. Examining the microstructure of sleep have provided a potential explanation for the higher prevalence of parasomnias among epilepsy patients and their families. Two commonly used parameters used to characterize sleep microstructure are the arousal index and cyclic alternating pattern (CAP). The arousal index is



**Fig. 14.** A 30-second epoch from the diagnostic polysomnogram of an 80-year-old man who was referred to the sleep disorders clinic for evaluation of recurrent violent nighttime awakenings. Illustrated in this figure is a typical spell that this patient was experiencing. He was noted to yell, jump from bed, and have complex body movements. RSWA was noted in both the chin (*green arrow*) as well as the anterior tibialis electromyography (EMG) (*blue arrow*). Channels are as follows: electrooculogram (left: LOC-A2; right: ROC-A1), chin EMG, EEG (left central, right central, left occipital, and right occipital), 2 ECG channels, limb EMG (LAT), snore channel, nasal-oral airflow, respiratory effort (thoracic, abdominal), and oxygen saturation (Sao<sub>2</sub>). (Source: Alon Y. Avidan, MD, MPH © Copyright to remain with author.)

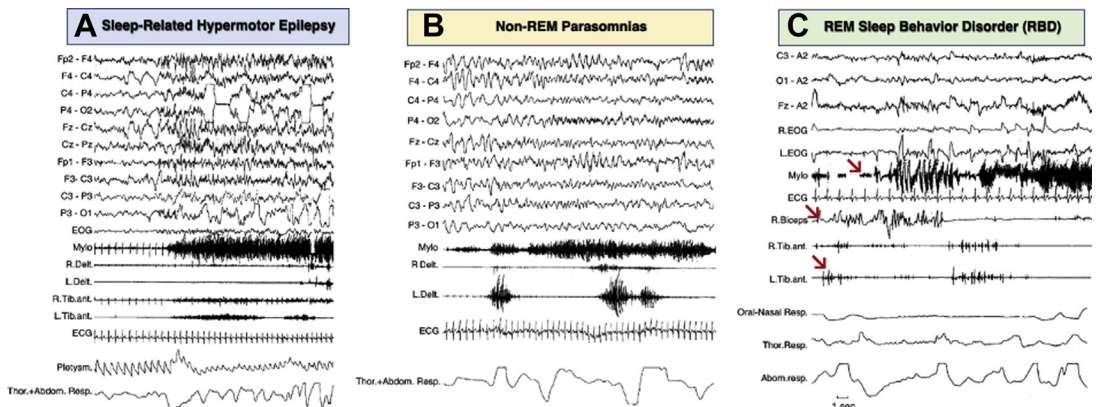
defined as the number of arousal per hour of sleep whereas CAP is periodic EEG activity during NREM, where the CAP rate is the percentage ratio of CAP time to total NREM sleep time.<sup>57</sup> Patients with SRHE have a high CAP rate, which translates into more microarousal and disturbed sleep.<sup>58</sup> NREM parasomnias also have been found to be associated with significant NREM fragmentation and instability.<sup>59</sup> Therefore, a dysfunction in the mechanism that normally balances arousal and sleep maintenance is likely to be present in both disorders.

Electrodes implanted intracranially for the evaluation of medically refractory epilepsy have offered insight into NREM parasomnias when both happen to be present in the same patient. This was reviewed in detail by Gibbs and colleagues.<sup>60</sup> The key finding is the presence of electrophysiologically diverse local states occurring simultaneously during sleep. Specifically, fast wake-like activity is recorded in certain regions, for example, motor and cingulate cortices, whereas delta sleep-like activity continues in other regions for example, frontal cortex. This discrepancy may be missed on surface EEG, where traditionally, only generalized slow wave and/or muscle and movement artifacts are captured during NREM parasomnias.<sup>61</sup> This differential activation of select brain regions may help explain certain features of

NREM parasomnias, for example, activation of amygdala results in emotional response whereas deactivation of hippocampus results in amnesia of the event afterward.<sup>62</sup>

## EPILEPSY VERSUS RAPID EYE MOVEMENT SLEEP BEHAVIOR DISORDER

Although much less common, seizures also may occur during REM sleep. Nguyen-Michel and colleagues<sup>63</sup> compared dream-enactment motor events in the setting of REM sleep behavior disorders (RBDs) with those of sleep-related seizures (arising out of either REM or NREM). They found that during epileptic events, patients more often woke up abruptly, opened their eyes, raised head/trunk, had whole-body movements or dystonic posturing, and interacted with objects in the environment, whereas patients with RBD were more likely to have their eyes closed and exhibited more jerky, nonstereotypical movements. Blowing, deep inspiration, sniffing, coughing, and changes in respiratory rate and volume were seen more often with seizures than with RBD. Semiology was similar between seizures arising out of NREM and REM, although the latter occurred more often during the second half of the night, similar to RBDs. Among the seizures associated with REM sleep, 88% occurred during



**Fig. 15.** Polysomnographic epochs highlighting (A) the unique features of SRHE; (B) an NREM parasomnia, sleep terror type; and (C) an episode of DEB and REM RSWA in the setting of RBD. (A) The EEG channels depict an ictal paroxysmal EEG discharge, mainly over the frontal regions during the seizure. (B) The abrupt arousal during the NREM parasomnia event of sleep terror highlights a nonepileptiform diffuse hypersynchronous activity that defines the underlying sleep-state instability, a hallmark of NREM parasomnias. (C) RBD is demarcated by the mixed frequency EEG pattern of REM stage. Instead of the expected EEG atonia, however, the patient's polysomnogram illustrates RSWA (arrows) during the DEB episode. From the polysomnographic perspective, the epileptic seizure manifests as stereotyped motor activation. The SRHE as well as NREM parasomnia, sleep terror type, will present with autonomic activation. (From: Nocturnal frontal lobe epilepsy to Sleep-Related Hypermotor Epilepsy: A 35-year diagnostic challenge, Seizure: Paolo Tinuper, Francesca Bisulli, From nocturnal frontal lobe epilepsy to Sleep-Related Hypermotor Epilepsy: A 35-year diagnostic challenge, Seizure, Volume 44, 2017, Pages 87-92, ISSN 1059-1311, <https://doi.org/10.1016/j.seizure.2016.11.023>. (<http://www.sciencedirect.com/science/article/pii/S1059131116302916>). © 2016. Requires Permissions)

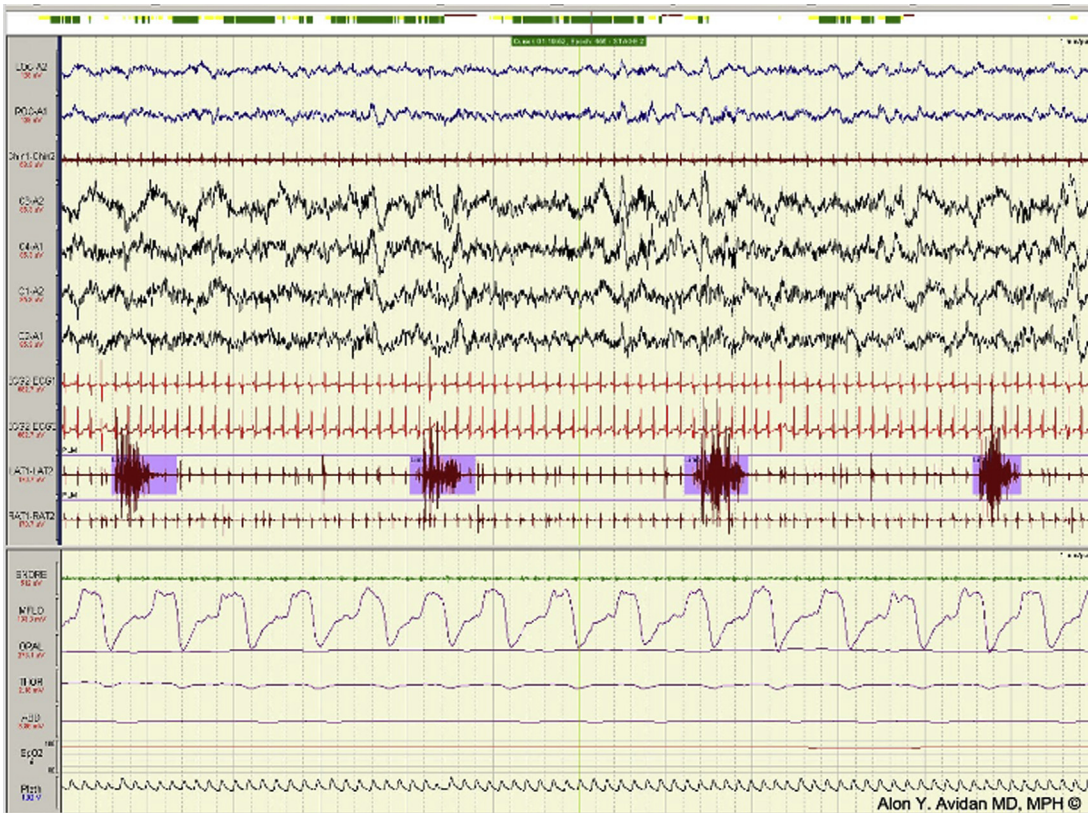
or near bursts of REMs noted in the anterior frontal leads. Another key feature for distinguishing RBD from seizures is dream recollection associated with the former. Specifically, when awakened during an episode of RBD, patients often are able to recount the dream immediately prior to arousal. The dreams are related to the patients' need to protect themselves against intruders or animals. In the process of defending themselves, patients may demonstrate behaviors, such as punching and kicking, that may result in injury to the patient or bed partner. Although such dreams are the majority, a minority of patients with RBD experience spots dreams or more adventurous dreaming.

On polysomnography, substantially augmented phasic or tonic muscle activity can be seen on electromyography channels during polysomnography (Figs. 13 and 14). REM sleep without atonia

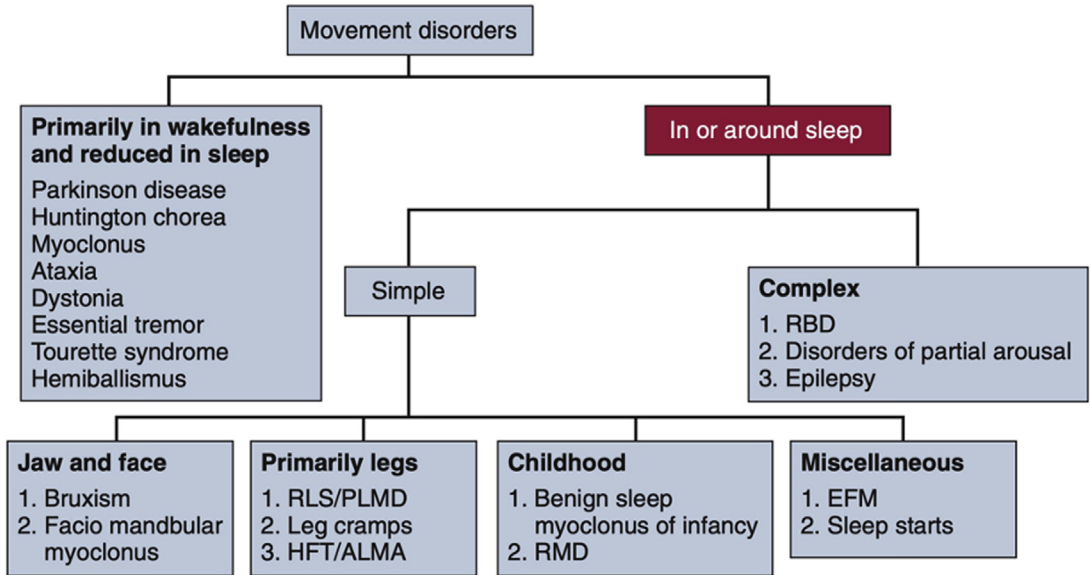
(RSWA) corresponding to the dream enactment behavior (DEB) is required to make the diagnosis of RBD, although DEB may be diagnosed based solely on observation during the polysomnogram or on clinical history by a bed partner.

Autonomic activation usually is only mild or entirely absent.<sup>53</sup> Upon awakening, alertness usually is immediate, which may help differentiate from seizures, where often a postictal state may be present. Unlike NREM parasomnias and sleep-related epilepsy, RBD usually affects patients older than 50 years of age, where there is strong association with neurodegenerative conditions, such as parkinsonism.

Fig. 15 summarizes the polysomnographic signature markers of sleep-related epilepsy, NREM parasomnias (disorders of arousal), and REM parasomnias (such as RBD).



**Fig. 16.** This is a 60-second sleep epoch from a diagnostic polysomnogram of a 66-year-old woman with difficulties falling asleep, excessive daytime sleepiness, and uncomfortable sensation in her legs associated with an irresistible urge to move her legs. Her husband reports that she has frequent night-time kicking and jerking movements, which disrupt his sleep. Illustrated in this figure is a succession of 5 periodic limb movements occurring in the right and left anterior tibialis muscles. Channels are as follows: electrooculogram (left: LOC-A2; right: ROC-A1), chin electromyography (EMG) (chin-chin), EEG (left central [C3-A2], right central [C4-A1], left occipital [O1-A2], right occipital [O2-A1]), electrocardiogram (ECG), limb EMG (left leg [LAT], right leg [RAT]), patient position, snoring (SNORE), nasal-oral airflow (N/O), respiratory effort (thoracic [THOR], abdominal [ABD]), nasal pressure (NP), and oxygen saturation (SpO<sub>2</sub>) and plethysmography channel. (Source: Alon Y. Avidan, MD, MPH © Copyright to remain with author.)



**Fig. 17.** Flowchart for the approach to the differential diagnosis of sleep-related movement disorders. ALMA, alternating leg muscle activation; EFM, excessive fragmentary myoclonus; HFT, hypnagogic foot tremor; PLMD, periodic limb movement disorder; RLS, restless legs syndrome; RMD, rhythmic movement disorder. (From: Allen, R, Salas, R and Gamaldo, C Movement Disorders in Sleep, in Atlas of Clinical Sleep Medicine, Second Edition Kryger, Meir H., Avidan, AY, Berry, R editors, Copyright © 2014, 2010 by Saunders, an imprint of Elsevier Inc. p.162 Requires Permissions.)



**Fig. 18.** Cataplexy. A classic representation of a complete cataplectic episode in an adult. The episodes generally follow a strong emotional stimulus, such as laughter. The example demonstrates the gradual onset of buckling of the knees and falling to the floor. (From: Ruoff C, Mignot, E. Central Nervous System Hypersomnias, in Atlas of Clinical Sleep Medicine, Second Edition Kryger, Meir H., Avidan, AY, Berry, R editors, Copyright © 2014, 2010 by Saunders, an imprint of Elsevier Inc. p.16 Requires Permissions.)





daytime function, or injury.<sup>50</sup> The movements also may be observed during quiet wakefulness.

**Fig. 17** highlights a conceptualized flowchart in the approach to the differential diagnosis of sleep-related movement disorders.

Cataplexy refers to an abrupt but brief (<2 minutes) loss or decrease of voluntary skeletal muscle tone with retained consciousness precipitated by strong emotions, such as anger, laughter, joy, elation, or surprise<sup>65–67</sup> (**Figs. 17–19**). It is estimated to be present in 65% to 75% of patients with narcolepsy<sup>68,69</sup> and is the most specific symptom of narcolepsy type I.

## SUMMARY

Much progress has been made in elucidating the relationship between epilepsy and sleep. This review seeks to summarize the current state of understanding of the interplay between the 2, from the preponderance of epileptiform discharges during NREM sleep to the sleep-related electrophysiologic manifestations of multiple epilepsy types and syndromes. In addition, certain key features for differentiating parasomnias from SRHE also are discussed. Because sleep disorders and epilepsy are not exclusive of each other, familiarity with these conditions is essential to both sleep specialist and neurologist for the appropriate diagnosis and management of the affected patient population.

## DISCLOSURE

Wu: None.

Avidan: Harmony, Eisai, Merck.

Engel: R01 NS033310 and U54 NS100064.

## REFERENCES

1. Terzano MG, Parrino L, Smerieri A, et al. CAP and arousals are involved in the homeostatic and ultradian sleep processes. *J Sleep Res* 2005;14:359–68.
2. Halász P, Bódizs R, Ujma PP, et al. Strong relationship between NREM sleep, epilepsy and plastic functions - a conceptual review on the neurophysiology background. *Epilepsy Res* 2019;150:95–105.
3. Nobili L, Ferrillo F, Baglietto MG, et al. Relationship of sleep interictal epileptiform discharges to sigma activity (12–16 Hz) in benign epilepsy of childhood with Rolandic spikes. *Clin Neurophysiol* 1999;110:39–46.
4. Steriade M, Contreras D, Amzica F. Synchronized sleep oscillation and paroxysm development. *Trend Neurosci* 1994;17:199–208.
5. Malow BA, Aldrich MS. Localizing value of rapid eye movement sleep in temporal lobe epilepsy. *Sleep Med* 2000;1:57–60.
6. Okanari K, Baba S, Otsubo H, et al. Rapid eye movement sleep reveals epileptogenic spikes for resective surgery in children with generalized interictal discharges. *Epilepsia* 2015;56:1445–53.
7. Schmitt B. Sleep and epilepsy syndromes. *Neuropediatrics* 2015;46(3):171–80.
8. Xu L, Guo D, Liu YY, et al. Juvenile myoclonic epilepsy and sleep. *Epilepsy Behav* 2018;80:326–30.
9. Varotto G, Franceschetti S, Caputo D, et al. Network characteristics in benign epilepsy with centrotemporal spikes patients indicating defective connectivity during spindle sleep: a partial directed coherence study of EEG signals. *Clin Neurophysiol* 2018;129(11):2372–9.
10. Bouma PA, Bovenkerk AC, Westendorp RG, et al. The course of benign partial epilepsy of childhood with centrotemporal spikes: a meta-analysis. *Neurology* 1997;48:430–7.
11. Callenbach PM, Bouma PA, Geerts AT, et al. Long-term outcome of benign childhood epilepsy with centrotemporal spikes: Dutch Study of Epilepsy in Childhood. *Seizure* 2010;19:501–6.
12. Kellaway P. The electroencephalographic features of benign centrotemporal (rolandic) epilepsy of childhood. *Epilepsia* 2000;41:1053–6.
13. Lerman P. Benign partial epilepsy with centrotemporal spikes. In: Roger J, Dravet C, Bureau M, et al, editors. *Epileptic syndromes in infancy, childhood and adolescence*. London and Paris: John Libbey Eurotext Ltd; 1985. p. 150–8.
14. Nicolai J, van der Linden I, Arends JB, et al. EEG characteristics related to educational impairments in children with benign childhood epilepsy with centrotemporal spikes. *Epilepsia* 2007;48(11):2093–100.
15. Panayiotopoulos CP, Michael M, Sanders S, et al. Benign childhood focal epilepsies: assessment of established and newly recognized syndromes. *Brain* 2008;131(Pt 9):2264–86.
16. Specchio N, Trivisano M, Di Ciommo V, et al. Panayiotopoulos syndrome: a clinical, EEG, and neuropsychological study of 93 consecutive patients. *Epilepsia* 2010;51(10):2098–107.
17. Fattinger S, Schmitt B, Bölsterli Heinzle BK, et al. Impaired slow wave sleep downscaling in patients with infantile spasms. *Eur J Paediatr Neurol* 2015;19(2):134–42.
18. Carreño M, Fernández S. Sleep-related epilepsy. *Curr Treat Options Neurol* 2016;18(5):23.
19. Tinuper P, Bisulli F. From nocturnal frontal lobe epilepsy to Sleep-Related Hypermotor Epilepsy: a 35-year diagnostic challenge. *Seizure* 2017;44:87–92.
20. Sforza E, Mahdi R, Roche F, et al. Nocturnal interictal epileptic discharges in adult Lennox-Gastaut syndrome: the effect of sleep stage and time of night. *Epileptic Disord* 2016;18(1):44–50.

21. Halász P, Kelemen A, Szűcs A. The role of NREM sleep micro-arousals in absence epilepsy and in nocturnal frontal lobe epilepsy. *Epilepsy Res* 2013; 107(1–2):9–19.
22. Halász P, Dévényi É. Petit mal absence in night-sleep with special reference to transitional sleep and REM periods. *Acta Med Acad Sci Hung* 1974;31:31–45.
23. Kasteleijn-Nolst Trenite DG, Schmitz B, Janz D, et al. Consensus on diagnosis and management of JME: from founder's observations to current trends. *Epilepsy Behav* 2013;28(Suppl 1):S87–90.
24. Mekky JF, Elbhrawy SM, Boraey MF, et al. Sleep architecture in patients with juvenile myoclonic epilepsy. *Sleep Med* 2017;38:116–21.
25. Roshan S, Puri V, Chaudhry N, et al. Sleep abnormalities in juvenile myoclonic epilepsy—a sleep questionnaire and polysomnography based study. *Seizure* 2017;50:194–201.
26. Commission on Classification and Terminology of the International League Against Epilepsy. Proposal for revised classification of epilepsies and epileptic syndromes. *Epilepsia* 1989;30(4):389–99.
27. Tassinari CA, Rubboli G, Volpi L, et al. Electrical status epilepticus during slow sleep (ESES or CSWS) including acquired epileptic aphasia (Landau-Kleffner syndrome). In: Roger J, Bureau M, Dravet C, et al, editors. *Epileptic syndromes in infancy, childhood and adolescence*. London and Paris: John Libbey Eurotext Ltd; 2005. p. 295–314.
28. Bölsterli BK, Schmitt B, Bast T, et al. Impaired slow wave sleep downscaling in encephalopathy with status epilepticus during sleep (ESES). *Clin Neurophysiol* 2011;122(9):1779–87.
29. Gencpinar P, Dundar NO, Tekgul H. Electrical status epilepticus in sleep (ESES)/continuous spikes and waves during slow sleep (CSWS) syndrome in children: an electroclinical evaluation according to the EEG patterns. *Epilepsy Behav* 2016;61:107–11.
30. Galanopoulou AS, Bojko A, Lado F, et al. The spectrum of neuropsychiatric abnormalities associated with electrical status epilepticus in sleep. *Brain Dev* 2000;22(5):279–95.
31. Carvill GL, Regan BM, Yendle SC, et al. GRIN2A mutations cause epilepsy-aphasia spectrum disorders. *Nat Genet* 2013;45(9):1073–6.
32. Lemke JR, Lal D, Reinthaler EM, et al. Mutations in GRIN2A cause idiopathic focal epilepsy with rolandic spikes. *Nat Genet* 2013;45(9):1067–72.
33. Pera MC, Brazzo D, Altieri N, et al. Long-term evolution of neuropsychological competences in encephalopathy with status epilepticus during sleep: a variable prognosis. *Epilepsia* 2013;54(Suppl 7):77–85.
34. Caraballo RH, Cejas N, Chamorro N, et al. Landau-Kleffner syndrome: a study of 29 patients. *Seizure* 2014;23(2):98–104.
35. Herman ST, Walczak TS, Bazil CW. Distribution of partial seizures during the sleep–wake cycle: differences by seizure onset site. *Neurology* 2001; 56:1453–9.
36. Miller LA, Ricci M, van Schalkwijk FJ, et al. Determining the relationship between sleep architecture, seizure variables and memory in patients with focal epilepsy. *Behav Neurosci* 2016;130(3):316–24.
37. Song I, Orosz I, Chervoneva I, et al. Bimodal coupling of ripples and slower oscillations during sleep in patients with focal epilepsy. *Epilepsia* 2017;58(11):1972–84.
38. Timofeev IV, Grenier F, Steriade M. Disfacilitation and active inhibition in the neocortex during the natural sleep–wake cycle: an intracellular study. *Proc Natl Acad Sci USA* 2001;98:1924–9.
39. Chibane IS, Boucher O, Dubeau F, et al. Orbitofrontal epilepsy: case series and review of literature. *Epilepsy Behav* 2017;76:32–8.
40. Tinuper P, Bisulli F, Cross JH, et al. Definition and diagnostic criteria of sleep-related hypermotor epilepsy. *Neurology* 2016;86(19):1834–42.
41. Scheffer IE, Bhatia KP, Lopes-Cendes I, et al. Autosomal dominant nocturnal frontal lobe epilepsy. A distinctive clinical disorder. *Brain* 1995;118(Pt 1): 61–73.
42. Mai R, Sartori I, Francione S, et al. Sleep related hyperkinetic seizures: always a frontal onset? *Neurol Sci* 2005;26(Suppl 3):s220–4.
43. Enatsu R, Bulacio J, Nair DR, et al. Posterior cingulate epilepsy: clinical and neurophysiological analysis. *J Neurol Neurosurg Psychiatry* 2014;85:44–50.
44. Montavont A, Kahane P, Catenox H, et al. Hypermotor seizures in lateral and mesial parietal epilepsy. *Epilepsy Behav* 2013;28:408–12.
45. Provini F, Plazzi G, Tinuper P, et al. Nocturnal frontal lobe epilepsy. A clinical and polygraphic overview of 100 consecutive cases. *Brain* 1999;122(Pt 6): 1017–31.
46. Berkovic SF, Scheffer IE. Genetics of the epilepsies. *Epilepsia* 2001;42:16–23.
47. Hildebrand MS, Tankard R, Gazina EV, et al. PRIMA1 mutation: a new cause of nocturnal frontal lobe epilepsy. *Ann Clin Transl Neurol* 2015;2:821–30.
48. Heron SE, Smith KR, Bahlo M, et al. Missense mutations in the sodium-gated potassium channel gene KCNT1 cause severe autosomal dominant nocturnal frontal lobe epilepsy. *Nat Genet* 2012;44(11):1188–90.
49. Picard F, Makrythanasis P, Navarro V, et al. DEPDC5 mutations in families presenting as autosomal dominant nocturnal frontal lobe epilepsy. *Neurology* 2014;82(23):2101–6.
50. American Academy of Sleep Medicine. *International Classification of sleep disorders*. 3rd edition. Darien, IL: American Academy of Sleep Medicine; 2014.
51. Tinuper P, Provini F, Bisulli F, et al. Movement disorders in sleep: guidelines for differentiating epileptic from non-epileptic motor phenomena arising from sleep. *Sleep Med Rev* 2007;11(4):255–67.

52. Ekambaram V, Maski K. Non-rapid eye movement arousal parasomnias in children. *Pediatr Ann* 2017; 46(9):e327–31.
53. Bisulli F, Vignatelli L, Provini F, et al. Parasomnias and nocturnal frontal lobe epilepsy (NFLE): lights and shadows—controversial points in the differential diagnosis. *Sleep Med* 2011;12(Suppl 2):S27–32.
54. Peter-Derex L, Catenoix H, Bastuji H, et al. Parasomnia versus epilepsy: an affair of the heart? *Neurophysiol Clin* 2018;48(5):277–86.
55. Bisulli F, Vignatelli L, Naldi I, et al. Increased frequency of arousal parasomnias in families with nocturnal frontal lobe epilepsy: a common mechanism. *Epilepsia* 2010;51:1852–60.
56. Cornejo-Sanchez DM, Carrizosa-Moog J, Cabrera-Hemer D, et al. Sleepwalking and sleep paralysis: prevalence in Colombian families with genetic generalized epilepsy. *J Child Neurol* 2019;34(9): 491–8.
57. Parrino L, Grassi A, Milioli G. Cyclic alternating pattern in polysomnography: what is it and what does it mean? *Curr Opin Pulm Med* 2014;20:533–41.
58. Parrino L, Halasz P, Tassinari CA, et al. CAP, epilepsy and motor events during sleep: the unifying role of arousal. *Sleep Med Rev* 2006;10:267–85.
59. Espa F, Ondze B, Deglise P, et al. Sleep architecture, slow wave activity, and sleep spindles in adult patients with sleepwalking and sleep terrors. *Clin Neurophysiol* 2000;111:929–39.
60. Gibbs SA, Proserpio P, Terzaghi M, et al. Sleep-related epileptic behaviors and non-REM-related parasomnias: insights from stereo-EEG. *Sleep Med Rev* 2016;25:4–20.
61. Schenck CH, Pareja JA, Patterson AL, et al. Analysis of polysomnographic events surrounding 252 slow-wave sleep arousals in thirty eight adults with injurious sleepwalking and sleep terrors. *J Clin Neurophysiol* 1998;15: 159–66.
62. Nobili L, De Gennaro L, Proserpio P, et al. Local aspects of sleep: observations from intracerebral recordings in humans. *Prog Brain Res* 2012;199: 219–32.
63. Nguyen-Michel VH, Solano O, Leu-Semenescu S, et al. Rapid eye movement sleep behavior disorder or epileptic seizure during sleep? A video analysis of motor events. *Seizure* 2018;58:1–5.
64. Woolfe M, Prime D, Tjoa L, et al. Nocturnal motor events in epilepsy: is there a defined physiological network? *Clin Neurophysiol* 2019;130(9):1531–8.
65. Slowik JM, Collen JF, Yow AG. *Narcolepsy*. Treasure Island, FL: StatPearls; 2020.
66. Reading PJ. Update on narcolepsy. *J Neurol* 2019; 266(7):1809–15.
67. Nallu S, Guerrero GY, Lewis-Croswell J, et al. Review of narcolepsy and other common sleep disorders in children. *Adv Pediatr* 2019;66:147–59.
68. Leschziner G. Narcolepsy: a clinical review. *Pract Neurol* 2014;14(5):323–31.
69. Akintomide GS, Rickards H. Narcolepsy: a review. *Neuropsychiatr Dis Treat* 2011;7:507–18.