

Associated conditions in patients with multiple dermatofibromas: Case reports and literature review

Surget V Beatrous¹, Ryan R Riahi², Stratton B Grisoli³, Philip R Cohen⁴

Affiliations: ¹Department of Internal Medicine, Scripps Mercy Hospital, San Diego, California, ²DermSurgery Associates, Houston, Texas, ³Department of Dermatology, Louisiana State University, New Orleans, Louisiana, ⁴Department of Dermatology, University of California San Diego, San Diego, California

Corresponding Author: Surget V. Beatrous, Department of Internal Medicine, Scripps Mercy Hospital, San Diego, California, Email: surgetbeatrous@gmail.com

Abstract

Dermatofibromas are benign, fibrohistiocytic, dermal tumors. Solitary dermatofibromas may be incidental findings, whereas multiple dermatofibromas may be associated with systemic conditions or previous therapies. Two women and one man with multiple dermatofibromas and an associated systemic condition, immunosuppression, or both, are described. Nine dermatofibromas developed in a woman with hypothyroidism, optic neuritis, and Arnold Chiari I malformation. Five dermatofibromas developed in a woman with breast cancer who had received several systemic antineoplastic therapies. Eleven dermatofibromas developed in a man with HIV whose systemic therapies included acyclovir, darunavir/cobicistat, dolutegravir, etravirine, and ritonavir. Conditions associated with multiple dermatofibromas include autoimmune diseases, cancer, chromosomal abnormalities, immunodeficiencies, metabolic disturbances, and altered physiologic states such as pregnancy. Medications received by patients with multiple dermatofibromas included immunosuppressive agents, psoriasis therapies, and antineoplastic drugs. Multiple dermatofibromas can be observed in patients with associated medical conditions, systemic therapies, or both. Therefore, in individuals presenting with multiple dermatofibromas, not only evaluation for associated disorders, but also review of prior and current drug therapies, should be considered.

Keywords: angiohistiocytoma, autoimmune, benign fibrous histiocytoma, breast cancer, dermal dendrocytoma, dermatofibroma, fibroma simplex, histiocytoma, HIV, immunodeficiency,

immunosuppression, multiple, nodular subepidermal fibrosis, sclerosing hemangioma

Introduction

A dermatofibroma is a benign histiocytic tumor whose pathogenesis remains to be definitively established [1]. Multiple dermatofibromas have previously been observed in patients with autoimmune diseases, immunosuppressive therapies, or both [2-5]. Three patients with multiple dermatofibromas are described and the conditions and medications associated in individuals with multiple dermatofibromas are reviewed.

Case Reports

Patient 1

A 48-year-old woman presented for evaluation of multiple pigmented lesions that had been present for at least five years. Her past medical history was remarkable for hypothyroidism, optic neuritis, and Arnold Chiari I malformation. Her current medications included alprazolam 0.5 mg as needed, cholecalciferol 1000 units twice daily, levothyroxine 88 mcg daily, norethindrone 0.35 mg daily, omega-3 fatty acids 1000 mg daily, and a daily multivitamin.

Cutaneous examination showed nine hyperpigmented dermal papules and nodules ranging in size from 3 millimeters to 8 millimeters on her right posterior shoulder, central chest, right flank, right leg, left leg (**Figure 1**), and right calf. The lesions demonstrated dimpling when the skin lateral to them was pressed towards the lesion.

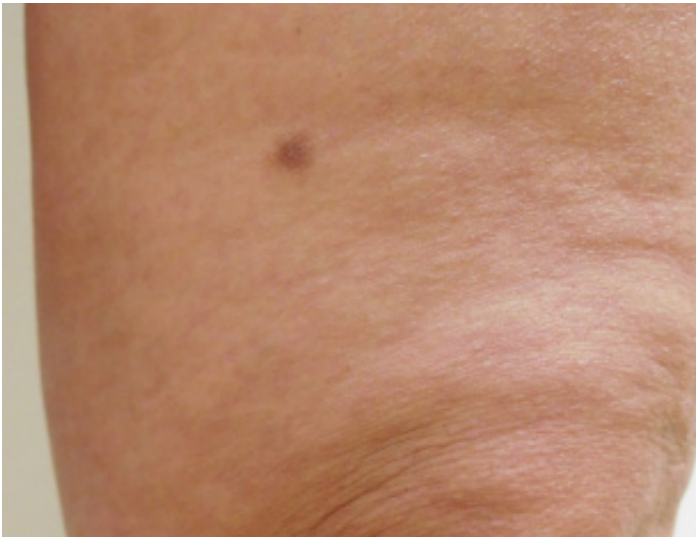

Figure 1. Dermatofibromas in a 48-year-old woman with a past medical history of hypothyroidism, optic neuritis, and Arnold Chiari I malformation. A hyperpigmented dermal nodule is shown on the left medial thigh above the knee.

A diagnosis of multiple dermatofibromas was made based on the morphologic features and positive dimple sign.

Patient 2

A 43-year-old woman diagnosed with stage IV estrogen receptor/progesterone receptor/HER2 positive breast cancer eight years earlier presented for evaluation of multiple skin lesions. Past treatments included doxorubicin-cyclophosphamide, bilateral mastectomy, docetaxel, tamoxifen, capecitabine, goserelin, letrozole, exemestane, and the globo

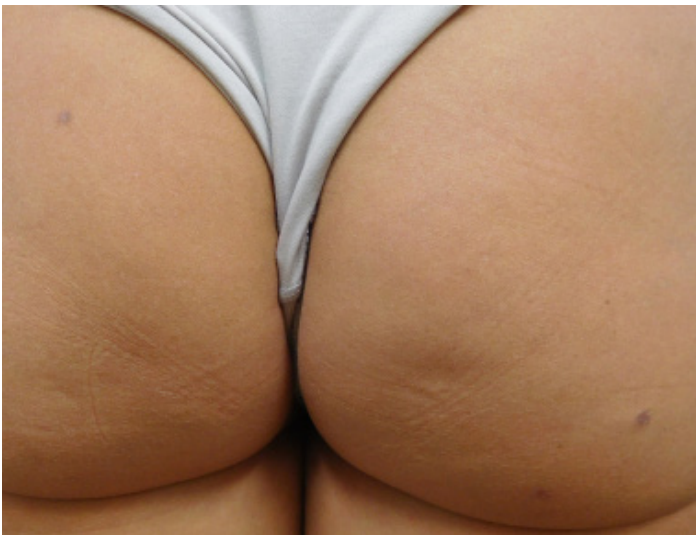

Figure 2. Dermatofibromas in a 43-year-old woman with stage IV estrogen receptor/progesterone receptor/HER2 positive breast cancer treated with anastrozole and denosumab. View of the single dermatofibroma on the left buttock and two dermatofibromas on the right buttock.

H-keyhole limpet hemocyanin vaccine trial. At the time of presentation, systemic therapies included anastrozole 1 mg daily and denosumab 120 mg injected every eight weeks. Following her breast cancer diagnosis, she developed five pigmented, dermal nodules. At the time of examination, these lesions had been present for seven years.

Cutaneous examination revealed hyperpigmented dermal papules and nodules ranging in size from 2 millimeters to 5 millimeters on her right knee, left leg, and bilateral buttocks (**Figure 2**). Dimpling was observed in all of the lesions when the skin lateral to them was pressed towards the lesion.

Based on the morphologic features and positive dimple sign, a diagnosis of multiple dermatofibromas was made.

Patient 3

A 60-year-old man with a diagnosis of HIV since 2010 (most recent CD4 count of 525 and viral load of 286) presented for evaluation of multiple pigmented skin lesions. The lesions were asymptomatic and had developed over the course of the prior six months. His current medications included acyclovir 400 mg daily, atorvastatin 10 mg daily, darunavir 800mg/cobicistat 150 mg twice daily, dolutegravir 50 mg daily, etravirine 200 mg twice daily, and ritonavir 100 mg twice daily.

Cutaneous examination showed eleven scattered, purple, dermal papules on the right arm (**Figure 3**), left arm, and one on the right leg. A punch biopsy was performed on the right leg papule, which was the largest of his lesions. It revealed a fibrous spindle cell proliferation in the superficial and deep dermis. The spindle cells had a fibrohistiocytic appearance in a storiform arrangement and the periphery had entrapment of dermal collagen fibers (**Figure 4**).

The diagnosis of multiple dermatofibromas was made based on the clinical presentation with histopathological confirmation.

Discussion

Dermatofibromas present as asymptomatic, indurated, hyperpigmented, dermal lesions. Microscopic examination demonstrates proliferation

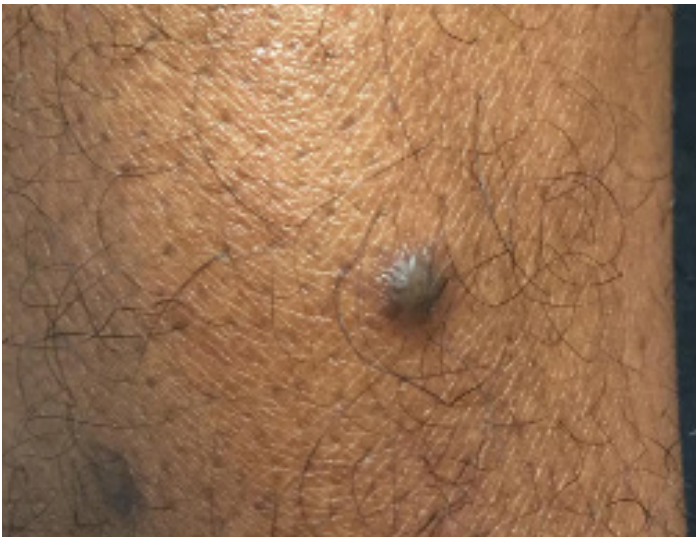

Figure 3. Dermatofibromas in an HIV-infected 60-year-old man. View of one of the patient's dermatofibromas located on the right arm.

of benign fibroblasts in the dermis, with collagen bundles located at the periphery of the lesion [1]. Immunohistochemistry may demonstrate positive staining for factor XIIIa [6]. Solitary dermatofibromas are often located on the lower extremities. The lesions may result from an arthropod assault [1]. Although solitary lesions are a routine finding, greater than five dermatofibromas is uncommon, and greater than fifteen is rare [7].

Multiple dermatofibromas have been observed in several clinical settings: the multiple nucleated angiohistiocytomas variant, clustered dermatofibromas, and non-clustered dermatofibromas [2, 8, 9]. Multiple nucleated angiohistiocytomas develop over the course of months and present as asymptomatic, grouped papules with a red to violaceous hue. Histopathologic examination reveals abundant blood vessels with interspersed inflammatory cells and large histiocytes in the mid-dermis [9, 10]. Clustered dermatofibromas often appear in adolescents at the onset of puberty, although congenital forms have been described [2]. This paper focuses on multiple non-clustered dermatofibromas, henceforth referred to as multiple dermatofibromas.

Multiple dermatofibromas have not only been associated with autoimmune diseases, but have also been observed in patients receiving either immunosuppressive agents or other systemic

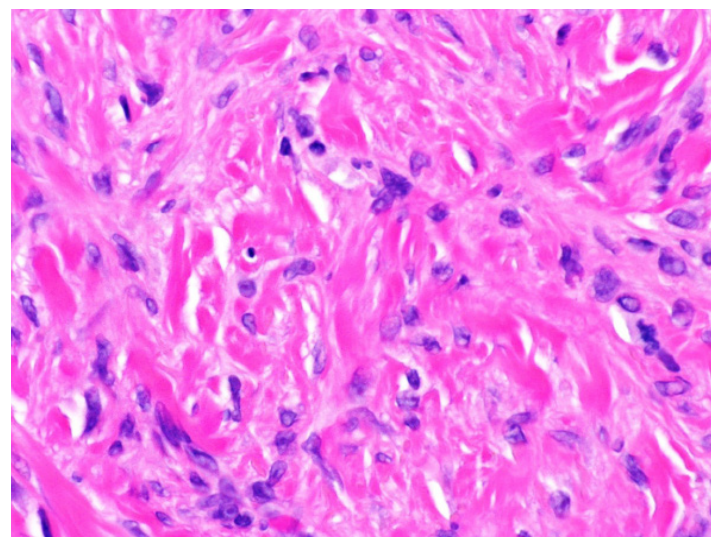
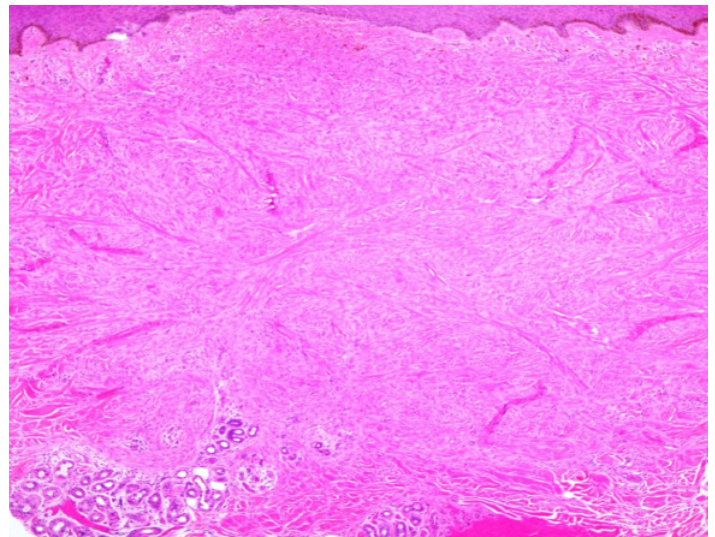


Figure 4. Microscopic examination of the dermatofibroma from the man with the HIV infection shows a proliferation of spindle cells in the dermis. The spindle cells have a fibrohistiocytic appearance and a storiform arrangement. The periphery of the dermal tumor has entrapment of the dermal collagen fibers. The overlying epidermis is hyperplastic. H&E, A, 4x; B, 40x.

medications (**Tables 1 and 2**) [2-5, 11-36]. Indeed, some of the patients with autoimmune diseases were concomitantly receiving immunosuppressive therapies for management of their autoimmune conditions such as patients with systemic lupus erythematosus or pemphigus vulgaris being treated with systemic corticosteroid therapy [8].

The diagnosis of dermatofibroma may be confirmed by microscopic examination of a lesional biopsy similar to our third patient; however, similar to our first and second patients, the diagnosis of multiple dermatofibromas can be established by the clinical presentation [5, 8, 12, 19, 30].

Table 1. Cases of multiple dermatofibromas and associated systemic conditions [A, B]

C	A/R/G	DF #	Location	Assoc Cond [C]	Med	Bx	Ref
1	15/J/W	6	T/Ar/L	Down's syndrome		+	[11]
2	20/DA/W	4	T/L	SLE	SC	+	[8]
3	25/NR/W	NR	NR	Pregnancy		-	[12]
4	28/Ca/W	15	Ar/L	Dermatomyositis	MTX, SC	+	[13]
5	30/Ca/W	18	Ar/L	GBD		+	[14]
6	31/Ca/W	60	L	Anticardiolipin S	Warfarin	+	[15]
7	31/Ca/W	35	T/Ar/L	PP HTN		+	[16]
8	32/NR/W	12	L	HT, MG	Cyclosp, SC	+	[17]
9	33/AA/W	15	NR	HIV, SLE	SC	-	[5]
10	33/NR/W	120	Ar/L	SLE, SS	SC	-	[8]
11	34/J/W	NR	NR	Hypertriglyceridemia		+	[18]
12	34/NR/W	NR	NR	Psoriasis, SLE	Ada, Eta, MTX, Ust	-	[19]
13	35/Ca/W	11	F/T/Ar/L	Folliculitis, SLE	SC	+	[20]
14	40/Ca/W	7	T/L	UC, HS	SC, Mino	+	[21]
15	42/NR/W	20-30	T/Ar/L	SS		+	[2]
16	43/Ca/W	5	T/L	Breast Ca	ANTX	-	[CR 2]
17	44/Ca/W	7	L	Psoriasis	Efa	+	[3]
18	47/NR/W	5	T	M IgA M	Ida, SC, Vin	+	[22]
19	48/NR/W	NR	NR	SLE	Aza	NR	[23]
20	48/Ca/W	9	T/Ar/L	Hypo T, ON, ACM I		-	[CR 1]
21	50/Ca/W	NR	T/Ar	Vitiligo		+	[24]
22	51/Ca/W	14	L	DM II, HTN, MF, IP	PUVA, SC, UVB, α -block, β -block, SU	+	[25]
23	52/J/W	13	T/Ar	C thyroiditis, SLE	SC	+	[26]
24	54/NR/W	90	T/Ar/L	H chol, H lip, HTN, Obesity, Xan		+	[27]
25	61/Ca/W	Multiple	T/Ar	PS		+	[28]
26	62/Ca/W	7	L	Sèz S	Gemcitabine	+	[22]
27	67/NR/W	Multiple	F	TCL	Chemostatic A	+	[29]
28	71/Ca/W	>30	L	DM, Glyco, Hydro	Insulin	-	[30]
29	24/AA/M	11	T/L	Hep B, HIV	D-HIV, INF α	+	[31]
30	29/Ca/M	Dozens	F/T/Ar/L	AD	TS	+	[32]
31	36/NR/M	Multiple	Ar	OT, SVT	Cyclosp, SC	+	[33]
32	48/Ca/M	24	T/L	CML	Ima	+	[34]

C	A/R/G	DF #	Location	Assoc Cond [C]	Med	Bx	Ref
33	52/Ca/M	40	T/Ar/L	MDS		+	[4]
34	53/NR/M	50-70	T/Ar/L	MG, Thymoma	Cyclosp, SC	-	[8]
35	53/NR/M	60	Ar/L	MG, Thymoma	AC, Cycloph	+	[35]
36	60/AA/M	11	T/Ar/L	HIV	D-HIV	+	[CR 3]
37	60/NR/M	NR	T/L	AML	Cycloph, SC	NR	[36]

[A] Abbreviations: A = age (years); AA = African American; ACMI = Arnold Chiari I malformation; AD = atopic dermatitis; Ada = adalimumab; AML = acute myeloid leukemia; Anticardiolipin S = antiphospholipid syndrome; ANTX = antineoplastic therapy (anastrozole, capecitabine, denosumab, docetaxel, doxorubicin-cyclophosphamide, exemestane, globo H-keyhole limpet hemocyanin vaccine, goserelin, letrozole, tamoxifen); Ar = arms; Assoc Cond = associated conditions; Bx = biopsy; C = case; C thyroiditis = chronic thyroiditis; Ca = Caucasian; Chemostatic A = chemostatic agents; CML = chronic myeloid leukemia; CR = Current Report; Cycloph = Cyclophosphamide; Cyclosp = Cyclosporine; DA = Dominican American; DFs = dermatofibromas; D-HIV = drugs for HIV infection; DM = diabetes mellitus type II; Efa = Efalizumab; Eta = etanercept; F = face; G = gender; GBD = Graves-Basedow disease; Glyco = glycosuria; H chol = hypercholesterolemia; H lip = hyperlipidemia; Hep B = hepatitis B; HIV = human immunodeficiency virus; HS = hidradenitis suppurativa; HT = Hashimoto's thyroiditis; HTN = hypertension; Hydro = hydronephrosis; Hypo T = hypothyroidism; Ida = Idarubicin; Ima = Imatinib; INFa = interferon alpha; IP = interstitial pneumonia; J = Japanese; L = legs; M = man; Mino = minocycline; MDS = myelodysplastic syndrome; Med = medications; M IgA M = multiple IgA myeloma; MF = mycosis fungoides; MG = myasthenia gravis; MTX = methotrexate; NR = not reported; ON = optic neuritis; OT = organ transplantation; PP HTN = primary pulmonary hypertension; PS = pulmonary sarcoidosis; PUVA = psoralen and UVA; R = race; Ref = References; SC = systemic corticosteroids; Sèz S = Sèzary syndrome; SLE = systemic lupus erythematosus; SS = Sjogren's syndrome; SU = sulfonyleurea; SVT = superficial venous thrombosis; T = trunk; TCL = T-cell lymphoma; TS = topical steroids; UC = ulcerative colitis; Ust = Ustekinumab; Vin = Vincristine; W = woman; α -block = α -blocker; β -block = β -blocker; # = number (of dermatofibromas); + = performed; - = not performed.

[B] This table includes selected examples of patients with multiple DFs and associated conditions: either an associated medical disorder, or a systemic medication, or both. This list is not inclusive of all patients with multiple DFs reported in the literature with each respective condition, but includes at least one person with each medical disorder or systemic medication that has been observed in these individuals.

Similar to previously reported patients with multiple dermatofibromas, one of our patients had hypothyroidism. She also had a history of optic neuritis and Arnold Chiari I malformation, which have not been previously described in association with multiple dermatofibromas. The second patient had a history of breast cancer and had received several systemic antineoplastic therapies. Another report also describes multiple dermatofibromas in a man with acute myeloid leukemia who was treated with cyclophosphamide and prednisolone [36]. Multiple dermatofibromas have also been described in a man with myelodysplastic syndrome receiving no treatment [4], a woman with Sèzary syndrome receiving gemcitabine [22], and a woman with mycosis fungoides treated intermittently with ultraviolet B radiation and psoralen plus ultraviolet A radiation [25].

The third patient had a history of HIV treated with antiretroviral therapy, increasing his risk for medication-associated dyslipidemia for which he

was receiving atorvastatin. Previously reported patients with multiple dermatofibromas have been HIV seropositive and had hypertriglyceridemia [5, 18].

Conclusion

Multiple dermatofibromas can be associated with several systemic conditions including physiologic changes of pregnancy [12], chromosomal abnormalities such as Down syndrome [11], metabolic disturbances such as hypertriglyceridemia [18], hematologic malignancies [4, 36], immunodeficiencies such as HIV [5], and autoimmune diseases such as myasthenia gravis [35], pemphigus vulgaris [8], and systemic lupus erythematosus [5, 8]. Medications received by patients with multiple dermatofibromas included immunosuppressive agents, psoriasis therapies, and antineoplastic drugs. Therefore, in individuals presenting with multiple cutaneous dermatofibromas, evaluation for systemic conditions, prior therapies, or both, should be considered.

Table 2. Multiple dermatofibromas: associated medical conditions and medications

Medical Conditions	Medications
Autoimmune	Adrenocorticotrophic hormone
Chronic thyroiditis	Adalimumab
Graves-Basedow disease	Antineoplastic therapy [b]
Hashimoto's thyroiditis	Azathioprine
Hypothyroidism	Corticosteroids (systemic)
Myasthenia gravis	Cyclophosphamide
Pemphigus vulgaris	Cyclosporine
Systemic lupus erythematosus	Efalizumab
Sjogren's syndrome	Etanercept
Vitiligo	Gemcitabine
Neoplastic [a]	Idarubicin
Acute myeloid leukemia	Imatinib
Breast cancer	Interferon alpha
Myelodysplastic syndrome	Methotrexate
Mycosis fungoides	Minocycline
Multiple myeloma (IgA)	Psoralen and ultraviolet A
Sézary syndrome	Sulfonylurea
T-cell lymphoma	Ustekinumab
Thymoma	Ultraviolet B
Other	Vincristine
Arnold Chiari I malformation	alpha-blocker
Diabetes mellitus type II	beta-blocker
Down's syndrome	
Folliculitis	
Hepatitis B	
Hidradenitis suppurativa	
Human immunodeficiency virus	
Hypertension	
Hypercholesterolemia	
Hyperlipidemia	
Obesity	
Optic neuritis	
Organ transplantation	
Pregnancy	
Psoriasis	
Sarcoidosis	

[a] These include benign neoplasms, hematologic malignancies and solid tumors.

[b] These include several treatments received by a 43 year old woman with breast cancer: anastrozole, capecitabine, denosumab, docetaxel, doxorubicin-cyclophosphamide, exemestane, globo H-keyhole limpet hemocyanin vaccine, goserelin, letrozole, and tamoxifen.

References

1. Parish LC, Yazdanian S, Lambert WC, Lambert PC. Dermatofibroma: a curious tumor. *Skimmed*. 2012;10(5):268-270. [PMID: 23163067].
2. Pinto-Almeida T, Caetano M, Alves R, Selores M. Congenital multiple clustered dermatofibroma and multiple eruptive dermatofibromas--unusual presentations of a common entity. *An Bras Dermatol*. 2013;88(6 Suppl 1):63-66. [PMID: 24346882].
3. Santos-Juanes J, Coto-Segura P, Mallo S, Galache C, Soto J. Multiple eruptive dermatofibromas in a patient receiving efalizumab. *Dermatology*. 2008;216(4):363. [PMID: 18292655].
4. Bhattacharjee P, Umar SA, Fatteh SM. Multiple eruptive dermatofibromas occurring in a patient with myelodysplastic syndrome. *Acta Derm Venereol*. 2005;85(3):270-271. [PMID: 16040422].
5. Lu I, Cohen PR, Grossman ME. Multiple dermatofibromas in a women with HIV infection and systemic lupus erythematosus. *J Am Acad Dermatol*. 1995;32(5 Pt 2):901-903. [PMID: 7722054].
6. Hsi ED, Nickoloff BJ. Dermatofibroma and dermatofibrosarcoma protuberans: an immunohistochemical study reveals distinctive antigenic profiles. *J Dermatol Sci*. 1996;11(1):1-9. [PMID: 8867761].
7. Baraf CS, Sharp L. Multiple histiocytomas. Report of a case. *Arch Dermatol*. 1970;101(5):588-590. [PMID: 4315412].

8. Cohen PR. Multiple dermatofibromas in patients with autoimmune disorders receiving immunosuppressive therapy. *Int J Dermatol*. 1991;30(4):266-270. [PMID: 2050454].
9. Frew JW. Multinucleate cell angiohistiocytoma: clinicopathological correlation of 142 cases with insights into etiology and pathogenesis. *Am J Dermatopathol*. 2015;37(3):222-228. [PMID: 25140659].
10. Smith NP, Wilson-Jones E. Multinucleate cell angiohistiocytoma: a new entity. *Br J Dermatol*. 1985. 113(suppl 29):15.
11. Tanaka M, Hoashi T, Serizawa N, Okabe K, Ichiyama S, Shinohara R, Funasaka Y, Saeki H. Multiple unilaterally localized dermatofibromas in a patient with Down syndrome. *J Dermatol*. 2016 Sep 26 [Epub ahead of print]. [PMID: 27665731].
12. Stainforth J, Goodfield MJ. Multiple dermatofibromata developing during pregnancy. *Clin Exp Dermatol*. 1994;19(1):59-60. [PMID: 8313640].
13. Huang PY, Chu CY, Hsiao CH. Multiple eruptive dermatofibromas in a patient with dermatomyositis taking prednisolone and methotrexate. *J Am Acad Dermatol*. 2007;57(5 Suppl):S81-84. [PMID: 17097372].
14. Lopez N, Fernandez A, Bosch RJ, Herrera E. Multiple eruptive dermatofibromas in a patient with Graves-Basedow disease. *J Eur Acad Dermatol Venereol*. 2008;22:402-403. [PMID: 18269629].
15. Dyal-Smith D. Signs, syndromes and diagnoses in dermatology. Multiple eruptive dermatofibromas associated with the anticardiolipin syndrome. *Australas J Dermatol*. 1993;34(3):131-133. [PMID: 8080418].
16. Lee HW, Lee DK, Oh SH, Choi JC, Lee MW, Choi JH, Moon KC, Koh JK. Multiple eruptive dermatofibromas in a patient with primary pulmonary hypertension. *Br J Dermatol*. 2005;153(4):845-847. [PMID: 16181476].
17. Kimura Y, Kaneko T, Akasaka E, Nakajima K, Aizu T, Nakano H, Sawamura D. Multiple eruptive dermatofibromas associated with Hashimoto's thyroiditis and myasthenia gravis. *Eur J Dermatol*. 2010;20(4):538-539. [PMID: 20406729].
18. Tsunemi Y, Ihn H, Hattori N, Saeki H, Tamaki K. Multiple eruptive dermatofibromas with CD34+ cells in a patient with hypertriglyceridemia. *Dermatology*. 2003;207(3):319-321. [PMID: 14571078].
19. Callahan S, Matires K, Shvartsbeyn M, Brinster N. Multiple eruptive dermatofibromas. *Dermatol Online J*. 2015;16(21):12. [PMID: 26990339].
20. Yamamoto T, Sumi K, Yokozeki H, Nishioka K. Multiple cutaneous fibrous histiocytomas in association with systemic lupus erythematosus. *J Dermatol* 2005;32:645-649. [PMID: 16334865].
21. Hiraiwa T, Hanami Y, Yamamoto T. Hidradenitis suppurativa and multiple dermatofibromas in a patient with ulcerative colitis. *J Dermatol*. 2013;40(12):1071-1072. [PMID: 24330184].
22. Zaccaria E, Rebora A, Rongioletti F. Multiple eruptive dermatofibromas and immunosuppression: report of two cases and review of the literature. *Int J Dermatol*. 2008;47(7):723-727. [PMID: 18613883].
23. Niiyama S, Happle R, Hoffmann R. Guess What! Multiple disseminated dermatofibromas in a woman with systemic lupus erythematosus. *Eur J Dermatol*. 2001;11(5):475-476. [PMID: 11525961].
24. Jaconelli L, Kanitakis J, Ktiouet S, Faure M, Claudy A. Multinucleate cell angiohistiocytoma: Report of three new cases and literature review. *Dermatol Online J* 2009; 15(2):4. [PMID: 19336021].
25. Gualandri L, Betti R, Cerri A, Pazzini C, Crosti C. Eruptive dermatofibromas and immunosuppression. *Eur J Dermatol* 1999;9:45-47. [PMID: 9920988].
26. Yamamoto T, Katayama I, Nishioka K. Mast cell numbers in multiple dermatofibromas. *Dermatology* 1995;190:9-13. [PMID: 7894111].
27. Marks R. Multiple histiocytomata: A report of 3 patients. *Trans St Johns Hosp Dermatol Soc* 1971;57:197-201. [PMID: 4328222].
28. Goldbach H, Wanat K, Rosenbach M. Multiple eruptive dermatofibromas in a patient with sarcoidosis. *Cutis*. 2016;98(2):E15-E19. [PMID: 27622262].
29. Arnold ML, Anton-Lamprecht I. Multiple eruptive cephalic histiocytomas in a case of T-cell lymphoma. A xanthomatous stage of benign cephalic histiocytosis in an adult patient? *Am J Dermatopathol*. 1993;15(6):581-586. [PMID: 8311192].
30. Gelfarb M, Hyman AB. Multiple Noduli Cutanei. An unusual case of multiple noduli cutanei in a patient with hydronephrosis. *Arch Dermatol*. 1962;85:89-94. [PMID: 13897602].
31. Murphy SC, Lowitt MH, Kao GF. Multiple eruptive dermatofibromas in an HIV positive man. *Dermatology* 1995; 190:309-312. [PMID: 7655112].
32. Ashworth J, Archard L, Woodrow D, Cream JJ. Multiple eruptive histiocytoma cutis in atopic. *Clin Exp Dermatol* 1990; 15:454-456. [PMID: 2177688].
33. Viseux V, Chaby G, Agbalika F, Luong MS, Chatelain D, Westeel PF. Multiple clustered dermatofibromas on a superficial venous thrombosis in a kidney-transplanted patient. *Dermatology* 2004; 209:156-157. [PMID: 15316173].
34. Llamas-Velasco M, Fraga J, Solano-López GE, Steegmann JL, García Díez A, Requena L. Multiple eruptive dermatofibromas related to imatinib treatment. *J Eur Acad Dermatol Venereol*. 2014;28(7):979-981. [PMID: 24321053].
35. Bargman HB, Fefferman I. Multiple dermatofibromas in a patient with myasthenia gravis treated with prednisone and cyclophosphamide. *J Am Acad Dermatol*. 1986; 14:351-352. [PMID: 3950136].
36. Chang SE, Choi JH, Sung KJ, Moon KC, Koh JK. Multiple eruptive dermatofibromas occurring in a patient with acute myeloid leukaemia. *Br J Dermatol* 1986; 14:351-352. [PMID: 10809884].