

## Editor's Choice — Management of the Diseases of Mesenteric Arteries and Veins


### Clinical Practice Guidelines of the European Society of Vascular Surgery (ESVS)

M. Björck<sup>a</sup>, M. Koelemay<sup>a</sup>, S. Acosta<sup>a</sup>, F. Bastos Goncalves<sup>a</sup>, T. Kölbel<sup>a</sup>, J.J. Kolkman<sup>a</sup>, T. Lees<sup>a</sup>, J.H. Lefevre<sup>a</sup>, G. Menyhei<sup>a</sup>, G. Oderich<sup>a</sup>,  
ESVS Guidelines Committee<sup>b</sup>, P. Kolh, G.J. de Borst, N. Chakfe, S. Debus, R. Hinchliffe, S. Kakkos, I. Koncar, J. Sanddal Lindholt, M. Vega de Ceniga, F. Vermassen, F. Verzini,  
Document Reviewers<sup>c</sup>, B. Geelkerken, P. Gloviczki, T. Huber, R. Naylor

**Keywords:** Guidelines, Acute mesenteric ischaemia, Arterial thrombosis, Arterial embolism, Chronic mesenteric ischaemia, Non-occlusive mesenteric ischaemia, Venous mesenteric ischaemia, Mesenteric venous thrombosis, Mesenteric arterial aneurysms, Isolated dissections of the mesenteric arteries

## Dedication

These guidelines are dedicated to Paola De Rango, University of Perugia, Italy. She participated very actively in the process of developing these guidelines, in particular the important chapters on chronic arterial and venous mesenteric ischaemia. Six days after the second meeting of the task force she died unexpectedly, to our great despair and loss. We honour her dedication and scientific integrity by completing these guidelines. Among many other commitments she was a very productive reviewer and an associate editor of this journal. You can read more about Paola's important contributions to science and to the vascular community in the April 2016 issue of the *European Journal of Vascular and Endovascular Surgery*.<sup>1</sup>



Dr Paola De Rango, July 28, 1966 — February 21, 2016

## TABLE OF CONTENTS

1. Introduction and general aspects	462
1.1. Introduction and methods	462
1.1.1. The purpose of these guidelines	462
1.2. Methodology	463
1.2.1. Strategy	463
1.2.2. Literature search and selection	463
1.2.3. Weighing the evidence	463
1.3. Terminology and definitions	463
1.4. Epidemiology	464
1.5. Anatomy and pathophysiology	465
1.6. Intestinal salvage	466
1.7. Benefit versus harm, the patient's perspective	467

<sup>a</sup> **Writing Committee:** M. Björck\* (Chair) (Sweden), M. Koelemay (Co-chair) (The Netherlands), S. Acosta (Sweden), F. Bastos Goncalves (Portugal), T. Kölbel (Germany), J.J. Kolkman (The Netherlands), T. Lees (UK), J.H. Lefevre (France), G. Menyhei (Hungary), G. Oderich (USA).

<sup>b</sup> **ESVS Guidelines Committee:** P. Kolh (Chair) (Belgium), G.J. de Borst (Co-chair and Review Coordinator) (The Netherlands), N. Chakfe (France), S. Debus (Germany), R. Hinchliffe (UK), S. Kakkos (Greece, UK), I. Koncar (Serbia), J. Sanddal Lindholt (Denmark), M. Vega de Ceniga (Spain), F. Vermassen (Belgium), F. Verzini (Italy).

<sup>c</sup> **Document Reviewers:** B. Geelkerken (The Netherlands), P. Gloviczki (USA), T. Huber (USA), R. Naylor (UK).

\* [martin.bjorck@surgsci.uu.se](mailto:martin.bjorck@surgsci.uu.se)

1078-5884/© 2017 European Society for Vascular Surgery. Published by Elsevier Ltd. This article is made available under the Elsevier license (<http://www.elsevier.com/open-access/userlicense/1.0/>).

<http://dx.doi.org/10.1016/j.ejvs.2017.01.010>

2.	Arterial ischaemia, acute mesenteric ischaemia	467
2.1.	Introduction	467
2.2.	Diagnosis	467
2.2.1.	Clinical presentation: embolism	467
2.2.2.	Clinical presentation: thrombosis	468
2.2.3.	Laboratory markers	468
2.2.4.	Computed tomography angiography	469
2.2.5.	Duplex ultrasound	469
2.2.6.	Digital subtraction angiography	469
2.3.	Treatment of acute superior mesenteric artery occlusion	470
2.3.1.	Current approaches	470
2.3.2.	Acute mesenteric arterial revascularisation	470
2.3.3.	Open superior mesenteric artery embolectomy	470
2.3.4.	Open vascular surgery for acute thrombotic superior mesenteric artery occlusion	470
2.3.5.	Assessment of bowel viability	471
2.3.6.	Second look laparotomy	471
2.3.7.	Damage control surgery	472
2.4.	Endovascular therapeutic options in acute mesenteric ischaemia	472
2.4.1.	Access to the superior mesenteric artery	472
2.4.2.	Aspiration embolectomy of the superior mesenteric artery	472
2.4.3.	Local superior mesenteric artery thrombolysis	472
2.4.4.	Antegrade recanalisation and stenting of the superior mesenteric artery	472
2.4.5.	Retrograde recanalisation and stenting of the superior mesenteric artery	473
2.4.6.	Outcomes after open versus endovascular revascularisation for acute mesenteric ischaemia	473
2.5.	Follow-up	474
2.6.	Medical treatment of mesenteric arterial disease	475
3.	Arterial ischaemia, chronic mesenteric ischaemia	475
3.1.	Symptoms and signs	475
3.2.	Anatomy and symptomatology	475
3.2.1.	Diagnostic imaging	476
3.2.1.1.	Abdominal X-ray	476
3.2.1.2.	Ultrasound	476
3.2.2.	Angiography	477
3.2.2.1.	Computed tomography angiography	477
3.2.2.2.	Magnetic resonance angiography	477
3.2.2.3.	Proof of ischaemia (functional evaluation)	477
3.2.3.	Treatment	478
3.2.4.	Treatment strategies	479
3.2.5.	Endovascular revascularisation	479
3.2.6.	Open surgery	480
3.2.6.1.	Pre-operative evaluation prior to open surgery	481
3.2.7.	Open surgical techniques	481
3.2.7.1.	Antegrade bypass	481
3.2.7.2.	Retrograde bypass	481
3.2.7.3.	Retrograde open mesenteric stenting	481
3.2.7.4.	Endarterectomy	481
3.3.	Results and follow-up	482
4.	Arterial ischaemia, non-occlusive mesenteric ischaemia	483
4.1.	Background and definition	483
4.2.	Diagnosis	484
4.3.	The role of imaging	484
4.4.	Treatment	486
5.	Venous mesenteric ischaemia	487
5.1.	Introduction	487
5.2.	Diagnosis	487
5.3.	Risk factors	487
5.4.	Laboratory testing	489
5.5.	Clinical manifestations	489
5.6.	Differential diagnosis	490
5.7.	Imaging	491
5.8.	Treatment	493
5.8.1.	Supportive treatment	493
5.8.2.	Anticoagulation	493
5.8.3.	Endovascular options	493
5.8.4.	Open surgery	494
5.9.	Follow-up	494
6.	Mesenteric arterial aneurysms	495
6.1.	Diagnosis	495
6.2.	Treatment	496
6.3.	Follow-up after treatment	497
7.	Isolated dissections of the mesenteric arteries	498

7.1.	Introduction	498
7.2.	Patient characteristics	498
7.2.1.	Diagnosis	498
7.3.	Treatment	498
7.4.	Follow-up	500
8.	Future research	500
8.1.	Acute and chronic mesenteric ischaemia	500
8.2.	Venous mesenteric ischaemia	500
8.3.	Mesenteric artery aneurysms	501
8.4.	Isolated dissections of the mesenteric arteries	501
	Appendix A. Supplementary data	501
	References	501

## LIST OF ABBREVIATIONS

AAA	abdominal aortic aneurysm	MALS	median arcuate ligament syndrome (the synonym coeliac artery compression syndrome, CACS, is not used in these guidelines)
ACS	abdominal compartment syndrome	MRA	magnetic resonance angiography
AMI	acute mesenteric ischaemia	MVT	mesenteric venous thrombosis (often associated with mesenteric venous ischaemia)
APLAS	antiphospholipid antibody syndrome	NOMI	non-occlusive mesenteric ischaemia
CA	coeliac artery	NOAC	new oral anticoagulants (also named direct oral anticoagulants - DOAC)
CMI	chronic mesenteric ischaemia	PP	primary patency
CO	cardiac output	PROM	patient reported outcome measure
CRP	C-reactive protein	PSV	peak systolic velocity
CTA	computed tomography angiography	PV	portal vein
DSA	digital subtraction angiography	PVT	portal vein thrombosis
DUS	duplex ultrasound	RCT	randomised controlled trial
EDV	end-diastolic velocity	ROMS	retrograde open mesenteric artery stenting
ePTFE	expanded polytetrafluoroethylene	RRT	renal replacement therapy
ESVS	European Society for Vascular Surgery	rtPA	recombinant tissue plasminogen activator
GWC	guideline writing committee	SA	splenic artery
HA	hepatic artery	SMA	superior mesenteric artery
IAH	intra-abdominal hypertension	SMV	superior mesenteric vein
IAP	Intra-abdominal pressure	SV	splenic vein
ICU	intensive care unit	TBAD	type B aortic dissection
I-FABP	intestinal fatty acid binding globulin	TIPS	transjugular intrahepatic portosystemic shunting
IMA	inferior mesenteric artery	VKA	vitamin K antagonist
IMAD	isolated mesenteric artery dissections	WSACS	World Society of the Abdominal Compartment Syndrome
JAK2	Janus-activated kinase gain of function substitute of valine to phenylalanine at position 617		
LMWH	low molecular weight heparin		

## 1. INTRODUCTION AND GENERAL ASPECTS

### 1.1. Introduction and methods

Members of this Guideline Writing Committee (GWC) were selected by the European Society for Vascular Surgery (ESVS) to represent physicians involved in the management of patients with diseases of the mesenteric arteries and veins. The members of the GWC have provided disclosure statements of all relationships that might be perceived as real or potential sources of conflict of interest. These disclosure forms are kept on file at the headquarters of the ESVS. The GWC report did not receive financial support from any pharmaceutical, device, or surgical company.

The ESVS Guidelines Committee was responsible for the endorsement process of this guideline. All experts involved in the GWC have approved the final document. All versions of the guideline were reviewed internally by the GWC and

the ESVS Guidelines Committee, externally by invited external reviewers, and approved by the Editors of the *European Journal of Vascular and Endovascular Surgery*.

**1.1.1. The purpose of these guidelines.** The ESVS has developed clinical practice guidelines for the care of patients with diseases of the mesenteric arteries and veins, with the aim of assisting physicians in selecting the best management strategy. This guideline, established by members of the GWC, who are members of the ESVS or non-members with specific expertise in the field, is based on scientific evidence completed with expert opinion on the matter. By summarising and evaluating the best available evidence, recommendations for the evaluation and treatment of patients have been formulated.

The recommendations are valid only at the time of publication, as technology and disease knowledge in this

field changes rapidly and recommendations can become outdated. It is an aim of the ESVS to revise the guidelines every 3 years or when important new insights in the evaluation and management of diseases of the mesenteric arteries and veins become available.

Although guidelines have the purpose of promoting a standard of care according to specialists in the field, under no circumstance should this guideline be seen as the legal standard of care in all patients. As the word “guideline” implies, the document is a guiding principle, but the care given to a single patient is always dependent on the individual patient (symptom variability, comorbidities, age, level of activity, etc.), treatment setting (techniques available), and other factors.

## 1.2. Methodology

**1.2.1. Strategy.** The GWC was convened on October 9, 2015 during a meeting in Brussels. At that meeting the tasks in creating the guideline were evaluated and distributed among the committee members. The same methodology for guideline development, as proposed by the ESVS guideline committee, was followed as for the development of ESVS guidelines for venous disease.<sup>2</sup> The final version of the guideline was submitted on November 26, 2016.

**1.2.2. Literature search and selection.** Members of the GWC, supported by clinical librarians performed the literature search for this guideline systematically in Medline (through PubMed), Embase, Cinahl, and the Cochrane Library up to December 1, 2015. Reference checking and hand search by the GWC members added other relevant literature. A second literature search on papers published between 2015 and 2016 was performed in August 2016. The members of the GWC performed the literature selection based on information provided in the title and abstract of the retrieved studies.

Several relevant articles published after the search date or in another language were included, but only if they were of paramount importance to this guideline.

Criteria for search and selection were:

<u>Languages:</u>	English, German, and French
<u>Level of evidence:</u>	Selection of the literature was performed following the pyramid of evidence, with aggregated evidence in the top of the pyramid (multiple randomised trials, meta-analyses), then single randomised controlled trials, then observational studies (Table 1). Single case reports, animal studies, and <i>in vitro</i> studies were excluded, leaving expert opinions at the bottom of the pyramid. The level of evidence per section in the guideline is dependent on the level of evidence available on the specific subject.
<u>Sample size:</u>	If there were relatively large studies available, with a minimum of 20 subjects per research group, only these were included. If not available, smaller studies were also included.

**Table 1.** Levels of evidence.

Level of evidence A	Data derived from multiple randomised clinical trials or meta-analyses
Level of evidence B	Data derived from a single randomised clinical trial or large non-randomised studies
Level of evidence C	Consensus of opinion of the experts and/or small studies, retrospective studies

**Table 2.** Classes of recommendations.

Classes of recommendations	Definitions
Class I	Evidence and/or general agreement that a given treatment or procedure is beneficial, useful, effective
Class II	Conflicting evidence and/or a divergence of opinion about the usefulness/efficacy of the given treatment or procedure
Class IIa	Weight of evidence/opinion is in favour of usefulness/efficacy
Class IIb	Usefulness/efficacy is less well established by evidence/opinion
Class III	Evidence and/or general agreement that the given treatment or procedure is not useful/effective, and in some cases may be harmful

**1.2.3. Weighing the evidence.** To define the current guidelines, members of the GWC reviewed and summarised the selected literature. Conclusions were drawn based on the scientific evidence.

The recommendations in these guidelines are based on the European Society of Cardiology grading system.<sup>3</sup> For each recommendation, the letter A, B, or C marks the level of current evidence (Table 1). Weighing the level of evidence and expert opinion, every recommendation is subsequently marked as class I, IIa, IIb, or III (Table 2). More information on the process of how guidelines are developed by the ESVS can be found on the ESVS web-site ([esvs.org](http://esvs.org)).

## 1.3. Terminology and definitions

The commonly used nomenclature is confusing, and for this guideline choices have had to be made. For a disease that is under-appreciated, recognition is important. Well-established terms were therefore chosen over ‘anatomically more correct’ terms. Thus, ‘*mesenteric*’ and not ‘*splanchnic*’ was used to indicate the coeliac artery (CA), the superior (SMA) and inferior mesenteric arteries (IMA), and ischaemia in that region, as it is used five times more often in the literature. Diseases of the renal arteries are not covered by these guidelines.

Mesenteric disease can be divided according to three characteristics: (i) presence of symptoms (or not); (ii) clinical presentation: acute, chronic, and acute on chronic ischaemia; and (iii) vessel involvement (the identification

and number of involved arteries, venous obstruction, or external compression).

Acute mesenteric ischaemia (AMI) is defined as the occurrence of an abrupt cessation of the mesenteric blood flow with development of symptoms that may vary in time of onset from minutes (in embolism) to hours (in atherothrombosis). The leading symptom is severe abdominal pain that may progress to bowel necrosis and peritonitis in days, if left untreated.

Chronic mesenteric ischaemia (CMI) is defined as ischaemic symptoms caused by insufficient blood supply to the gastrointestinal tract with a duration of at least 3 months. The typical presentation includes postprandial pain, weight loss resulting from fear of eating, or unexplained diarrhoea.

Acute on chronic ischaemia is defined as AMI in patients who previously had typical symptoms of CMI. Often, the symptoms of CMI worsened over the preceding weeks with periods of prolonged and more severe pain, pain even without eating, onset of diarrhoea, or inability to eat at all.

Mesenteric ischaemia can be caused by obstruction of arteries and/or veins, and by vasoconstriction of structurally normal vessels: non-occlusive mesenteric ischaemia (NOMI).

The main causes of mesenteric arterial obstruction are atherosclerotic disease, athero-thrombosis, arterial dissection, and arterial embolism. The main sources of embolism are the heart, especially in atrial fibrillation, and the aortic arch. Vasculitis of the mesenteric vasculature is rare, and can lead to abdominal complaints and bowel infarction, but this condition is not covered by these guidelines. Extrinsic compression of the mesenteric vessels can be caused by the crura of the diaphragm, or by tumour invasion, especially in pancreatic cancer. Congenital malformations (such as the mid-aortic syndrome or gut malrotation), and strangulation resulting from hernia are not covered by these guidelines.

NOMI is the ultimate consequence of circulatory failure. During low flow states blood flow is redistributed to maintain perfusion of vitally important organs (brain, kidneys, and heart), at the expense of the mesenteric circulation. The clinical scenarios include heart and aortic surgery, abdominal compartment syndrome (ACS), as well as all shock states. This condition is prevalent in critically ill patients.

The main causes of AMI are embolism, atherothrombosis, NOMI, and dissection. In CMI atherosclerosis is the predominant cause.

Symptomatic or asymptomatic compression of the CA is referred to as the median arcuate ligament syndrome (MALS), which is a synonym for coeliac axis compression syndrome.

Arterial aneurysms may be either true or false. True aneurysms are usually caused by weakening of the vessel wall and dilatation with involvement of all three wall layers. A pseudoaneurysm, or false aneurysm, can develop after injury

to the vessel wall or a penetrating atherosclerotic ulcer, and the blood leakage is confined to the vessel wall by surrounding tissue. Causes of aneurysmal degeneration in the mesenteric circulation include traumatic or inflammatory injury (e.g. in pancreatitis), as well as high flow in dilated collaterals. Aneurysms may become symptomatic by thrombosis, embolism, or rupture.

Venous mesenteric ischaemia is usually caused by thrombosis, and consequently is usually referred to as mesenteric venous thrombosis (MVT), and these are often used as synonymous terms. In these guidelines MVT is used. The causes of MVT include intra-abdominal inflammatory conditions and malignancy, thrombophilic disorders, trauma, and myeloproliferative (haematological) neoplasms. In this guideline MVT is referred to for thrombosis of mesenteric veins, which may be associated with splenic and portal vein thrombosis. Isolated thrombosis of the hepatic veins, the Budd-Chiari syndrome, isolated portal vein thrombosis (very seldom associated with mesenteric ischaemia), and aneurysms of the portal vein, are not covered by these guidelines.

#### 1.4. Epidemiology

Mesenteric ischaemia is a group of disorders with incidence rates that may vary according to the acute or chronic presentation and the aetiology (arterial, non-occlusive, venous).

It has been estimated that around 1% of all patients with an acute abdomen have arterial AMI.<sup>4</sup> The incidence increases exponentially with age and AMI is the cause of acute abdomen in up to 10% of patients aged over 70 years. The prevalence of acute mesenteric occlusion among patients with an acute abdomen may vary from 2.1% in suspected appendicitis to 17.7% in emergency laparotomy and 31.0% in laparotomy for non-trauma patients.<sup>5</sup> Cardiac failure, a history of atrial fibrillation, peripheral artery occlusions, and recent surgery have all been associated with an increased incidence.<sup>4,6</sup>

Reports on the incidence based on hospital admissions associated with AMI may have underestimated the prevalence of the disease. In a study based on a high autopsy rate (87%) an overall incidence rate of AMI of 12.9/100,000 person years was estimated in the population of Malmö, Sweden between 1970 and 1982, diagnosed either at autopsy or operation. Arterial thromboembolic occlusion was the most common type found in approximately 68% of acute cases with an embolism to thrombosis ratio of 1.4:1 based on autopsy results.<sup>7</sup> A recent study from Finland reported an incidence rate of AMI of 7.3/100,000 person years, with a 65% arterial, 28% venous and 7% non-occlusive aetiology.<sup>8</sup>

Contemporary incidences of CMI and NOMI are unknown, as only case series or incidences in treated patients have been reported. CMI accounts for less than 1 per 100,000 admissions, but there has been a steady

increase in recent years in the USA.<sup>9,10</sup> However, these figures may simply reflect an increasing number of re-interventions in recent years rather than an actual increase in the prevalence. Indeed, because atherosclerosis is the most common cause, the majority of patients have no symptoms and the development of CMI may take months or years to become clinically apparent and the diagnosis to become clear. In patients with known atherosclerotic disease, the prevalence may range from 8% to 70% and a >50% stenosis of more than one mesenteric artery may be detected in up to 15% of cases. Specifically, in patients with abdominal aortic aneurysms (AAA) and peripheral artery disease, a significant stenosis or occlusion of at least one mesenteric artery may be found in around 40% and 25–29%, respectively.<sup>11</sup>

MVT is a rare condition that accounts for 6–28% of all the cases of AMI and 1 in 1000 emergency department admissions,<sup>12,13</sup> but it can also cause CMI. The mean age of patients at presentation is 45–60 years with a slight male to female preponderance. The overall incidence of MVT in the Swedish population between 1970 and 1982 was estimated to be 2 per 100,000 compared with 2.7 per 100,000 between 2000 and 2006.<sup>14</sup> In Finland the incidence of acute MVT was 0.5/100,000 person years.<sup>8</sup> However, the incidence is probably underestimated, given the heterogeneous clinical presentation and the rate of asymptomatic incidental findings. The widespread use of abdominal imaging, in particular computed tomography angiography (CTA), results in an increasing number of cases being diagnosed incidentally. The prevalence of incidentally detected abdominal venous thrombosis, has been reported to be 45/2619 (1.74%, 95% CI 1.29–2.34%).<sup>15</sup> Some 26 patients had portal vein thrombosis (PVT) and eight had symptomatic MVT. MVT and PVT are the most common causes of mesenteric venous ischaemia. PVT was found 10 times more often than MVT at autopsy, but these cases were often asymptomatic, and were seldom considered to be the cause of death.<sup>16</sup>

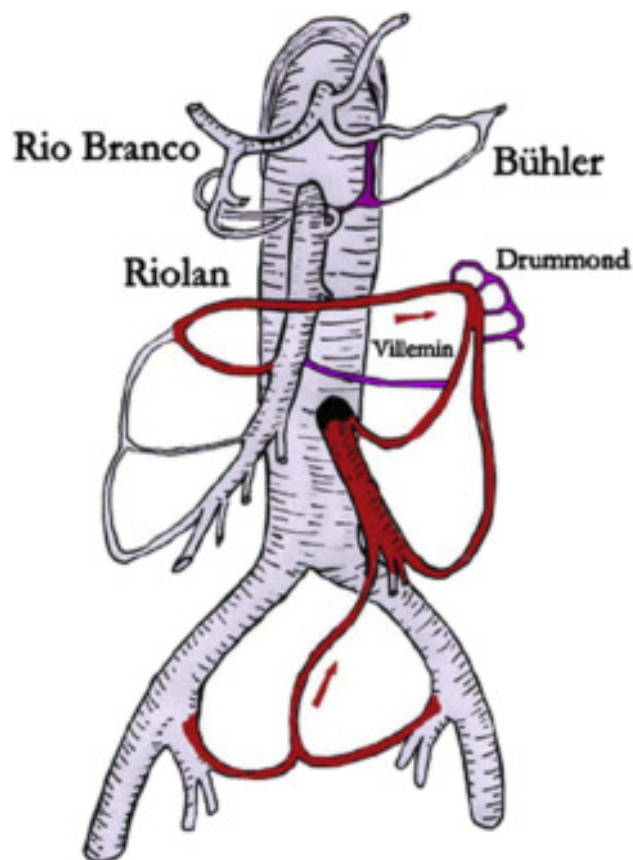
In Table 5, (page 31) diagnostic differentiation among venous, arterial occlusive, and non-occlusive mesenteric ischaemia is summarised.

True aneurysms of the mesenteric arteries and its branches are not common, with an estimated prevalence of 0.1–2%.<sup>17–19</sup> With the increasing use of abdominal imaging, the majority are asymptomatic at diagnosis. The true prevalence of pseudoaneurysms is not well defined, but they are more common in patients with acute or chronic abdominal inflammatory or infectious conditions, abdominal trauma, and after hepatobiliary interventions.<sup>20,21</sup>

### 1.5. Anatomy and pathophysiology

The mesenteric arteries include the three ventral branches of the abdominal aorta, supplying blood flow to the viscera. The anatomy of the mesenteric arteries shows great variability, in particular the CA.<sup>22,23</sup> The CA is the most proximal mesenteric artery followed distally by the SMA and the IMA. The CA originates from the distal

thoracic or proximal abdominal aorta, at the level of the diaphragm, often with an up to 2 cm course parallel to the aorta. The arterial blood supply of the bowel is characterised by extensive collateralisation, which varies considerably and requires individual assessment. The CA and the SMA are connected by the pancreaticoduodenal arteries described by Rio Branco and by Bühler<sup>23</sup> (Fig. 1). The SMA and the IMA are anastomosed by the Riolan and the Villemain arcades at a central mesenteric level, while the marginal arcade of Drummond is peripheral, close to the intestine.<sup>23</sup> These macroscopic anastomoses between the three major vessels create a significant tolerance for central obstructions of the vessels: each one has the ability to supply the entire viscera with the help of these anastomoses depending on the rate of the obstructive process. The Sudeck point describes the junction in the recto-sigmoid region, where arterial blood supply changes from the most distal branches of the IMA to the branches of the internal iliac artery. This segment is most prone to colonic ischaemia.



**Figure 1.** Collateral arcades between the main mesenteric arterial trunks: the pancreaticoduodenal arcades described by Rio Branco and Bühler between the superior mesenteric artery and the coeliac trunk; the Riolan, Villemain, and Drummond arcades between the inferior and superior mesenteric arteries. The mesenteric artery ends with the superior rectal arteries which originate from the internal iliac arteries via the middle rectal arteries.

On a microscopic level a capillary network in the sub-mucosal layer provides blood supply to the villi and microvilli of the intestine, which is the most metabolically active layer. This network also includes anastomoses at the base of the villi, which allow redirection of a compromised blood flow away from the mucosa while continuing to perfuse the muscularis and serosa, leading to ischaemic necrosis of the mucosa but preserving the integrity of the bowel, which may be life saving.<sup>24</sup> This adaptive principle is known as the counter current mechanism.<sup>25</sup>

The viscera receive 10–20% of the cardiac output (CO) in the resting state, and 35% postprandially starting 10–30 minutes after a meal and continuing for up to 3 hours to meet the increased metabolic demand.<sup>9,26</sup> At the start of the meal the CA flow increases and returns to baseline within an hour. The SMA flow increases after the meal, peaks in the first hour and returns to baseline after 2–3 hours.<sup>27</sup> The arterial perfusion is regulated by various intrinsic and extrinsic factors with overlapping controls and restrictions such as the autonomic nervous regulation, the haemodynamic condition, local metabolites and hormones.<sup>24</sup>

Venous drainage of the viscera does not impact on blood flow under normal physiological conditions. However, an increase in the resistance of the venous outflow can significantly influence hydrostatic pressure and fluid balance in the intestines.<sup>24</sup>

Mesenteric ischaemia is predominantly caused by atherosclerosis affecting the ostia of the mesenteric arteries.<sup>9,22,26</sup> These lesions are often associated with other manifestations of atherosclerotic disease, such as coronary artery disease.<sup>28,29</sup> MALS, external compression of the coeliac artery by the median arcuate ligament is a common, but mostly asymptomatic, finding. When causing symptoms of postprandial intestinal ischaemia, MALS is also known as the Dunbar syndrome. The clinical significance of this external compression, which may even lead to occlusion of the CA remains unclear, although case series of successful treatment have been reported.<sup>9,30</sup> Less common causes of mesenteric occlusive disease include previous arterial embolism, arterial dissection, fibromuscular dysplasia, vasculitis, Takayasu's disease, Cogan's syndrome and Behçet's disease. NOMI is characterised by incomplete interruption of intestinal perfusion caused by hypoperfusion, secondary to low CO, often combined with arterial spasm.<sup>31</sup>

True aneurysms and pseudoaneurysms in the mesenteric arteries are most common in the splenic, hepatic, and coeliac arteries. Pseudoaneurysms are caused by iatrogenic injury, trauma, or pancreatitis.<sup>32,33</sup>

### 1.6. Intestinal salvage

This section summarises some fundamental principles in saving as much of the threatened bowel as possible, an inter-disciplinary collaboration engaging many groups of surgeons. More details and references are given in Chapter 2, on AMI.

A general surgical principle is to perform laparotomy in the presence of peritonitis, and mesenteric ischaemia is no exception to this rule.<sup>34</sup> In the era before CTA and endovascular treatment, AMI could only be reliably diagnosed by laparotomy. Treatment consisted of removal of all necrotic bowel first, with the aim of performing open revascularisation later. In many centres this policy is still the dominant approach. As the diagnosis is now usually made by CTA it has been strongly argued, however, that this approach should be changed and blood flow should be restored as a first step, and then as a second step bowel viability should be assessed and any necrotic bowel resected.<sup>6,35,36</sup> How the revascularisation should take place is dealt with in later chapters of these guidelines.

Generally speaking, AMI patients should be treated in centres with experience in both open and endovascular revascularisation,<sup>36</sup> and performing laparotomy first may add to the duration of the AMI. Experience is crucial, because although the number of patients treated by endovascular means for mesenteric ischaemia is rapidly increasing,<sup>10</sup> it is still a relatively rare disorder. It has been suggested that in centres where these options are not available, it would be reasonable to perform bowel resection first, and transport the patient thereafter to a vascular centre. The disadvantages of this policy are: first, the extra hours it takes to perform laparotomy without revascularisation are lost as far as restoring blood flow is concerned; second, it is often difficult to distinguish between reversible and irreversible ischaemic bowel, especially before revascularisation, carrying the risk of resecting potentially viable bowel. When deciding how to manage the patient with AMI, these considerations have to be weighed against the logistical challenges of transporting a seriously ill patient.

In patients with AMI and signs of peritonitis, laparotomy is mandatory. All gangrenous bowel must be removed. Anastomoses are not recommended in this emergency setting because of a major risk of leakage. Bowel with no obvious sign of necrosis should be left in the abdomen and the viability should be assessed at a second look laparotomy.<sup>6,35</sup> The length of the remaining bowel should be measured at each procedure.

After extensive small bowel necrosis and resection short bowel syndrome may ensue. The remaining small bowel will become hypertrophic with enlarged villi, with increased absorption capacity, a process known as adaptation. This process can take up to 1 year. In some patients, parenteral nutrition may be needed, either for a limited period or indefinitely. As a general rule, the length of small bowel that is sufficient to allow enteral nutrition depends mainly on the ileocaecal valve: 50 cm suffices with and 100 cm without the ileocaecal valve, respectively. Another factor affecting the quality of life in patients with short bowel syndrome is the length of remaining colon.

It should be kept in mind that the quality of life on home parenteral nutrition is moderate to good,<sup>37</sup> and the outcome of intestinal transplantation is slowly improving,<sup>38</sup>

the latter may therefore become a future possibility for young patients with short bowel syndrome.

### 1.7. Benefit versus harm, the patient's perspective

Although guidelines are written for medical professionals to guide them through the decision process using the best available evidence, there is increasing emphasis on the patient perspective, and rightly so. In other words: patency and clinical success may be central in a guideline, but the quality of life for a specific patient will define the patient's true perspective. The three steps needed to match medical knowledge with a patient's expectation and perspective are: 1) provide information about the risks, benefits, and uncertainties of treatment (this aspect is of particular importance in the elective setting), 2) clarify the individual patient's preferences to personalise these risks and benefits, and 3) aim to apply these insights in a shared decision making process.<sup>39</sup>

It is expected that in most cases of AMI, application of these principles of patient involvement in decision making, or making decisions based on patient preferences and values, will be very difficult because of the urgent nature of the disorder. For example, although there are ample data showing that quality of life with parenteral nutrition is moderate to good,<sup>37</sup> this information is often not taken into account in the patient with AMI who on laparotomy has extensive bowel necrosis. In the chronic patient with single vessel stenosis, the uncertainty of a vascular procedure should be discussed. Moreover, a centre's outcome parameters including patency rates, morbidity, and mortality, should be weighed against the risk of non-treatment. Consideration also may need to be given to referring the patient to a centre with greater experience and caseload. In this guideline the GWC has tried to provide available data for the three 'patient perspective steps'.

#### i) Informing the patients

In AMI it will be very hard to inform patients adequately before commencing treatment, as the patients are very often in a condition that makes it difficult to understand complex information. In this acute situation it is important to discuss the risks and benefits with the relatives. There may be opportunity, however, after this first phase to discuss the options and potential risks and benefits such as the reduced long-term survival in patients having suffered AMI (50% after 5 years<sup>8</sup>). The moderate to good quality of life on parenteral nutrition<sup>37</sup> should be taken into account.

For patients with chronic ischemia, the benefit of treatment includes pain relief, and improved survival, which should be weighed against the morbidity and mortality associated with treatment.<sup>40</sup> When making decisions about treatment, patient preferences and life values should be considered alongside the data on potential physiological benefit.

Patients with mesenteric artery aneurysms may benefit from intervention while asymptomatic, to prevent death from rupture. The majority, however, may be safely observed. This requires detailed information on the potential risks and

benefits of repair and may lead to anxiety in patients who are aware of the diagnosis but do not require treatment.

In highly specialised centres, which receive patients with CMI, it would seem reasonable to develop leaflets that provide objective information on the potential risks, benefits, and harm of intervention. Such information should be easily understandable and ideally be scrutinised by an expert in communication.

#### ii) Personalising risks and benefits and clarification of patient preferences

Providing patients with a broad overview of the risks and benefits, of both treatment and non-treatment, is a daily challenge for all clinicians. In a relatively rare disease like mesenteric ischaemia, assumptions outnumber hard data, making this challenge greater. Many factors may influence the individual patient perspective. These include uncertainty about the future, side effects of drugs, morbidity and mortality of treatment, expected symptom relief, and the chance of improved survival. It is a general observation that most patients are able to make well balanced decisions.

#### iii) Shared decision making

Quite often, no single best solution for a problem is available. Under these circumstances the clinician should provide all the abovementioned data with an emphasis on the patient's perspective to help the patient to make the best decision.

## 2. ARTERIAL ISCHAEMIA, ACUTE MESENTERIC ISCHAEMIA

### 2.1. Introduction

Acute thromboembolic occlusion of the mesenteric arteries most commonly affects the SMA. Symptomatic acute occlusions of the CA and/or its branches and IMA are rare and very seldom lead to intestinal infarction<sup>7,41</sup> because of the extensive collateral arterial network from a patent SMA. Spontaneous dissection of the mesenteric arteries is covered in Chapter 7. These guidelines do not cover traumatic occlusion.

### 2.2. Diagnosis

**2.2.1. Clinical presentation: embolism.** A high index of suspicion and awareness among physicians who see patients who may have acute thromboembolic occlusion of the SMA is important. A history of previous embolism is common. A major cause of mesenteric embolism is atrial fibrillation. Development of cardiac thrombi also may be associated with valvular disease, a dilated left atrium, recent myocardial infarction, and ventricular dilatation with mural thrombus.

The typical clinical triad for an acute embolic SMA occlusion is (i) severe abdominal pain with minimal findings on examination (pain out of proportion to clinical signs), (ii) bowel emptying, and (iii) the presence of a source of embolus, most often atrial fibrillation. This clinical triad is,



however, not a consistent finding, but was present in 80% of patients in a prospective study.<sup>42</sup> The often sudden onset of abdominal pain (*phase 1; reversible ischaemia*) may decrease in intensity (*phase 2*), followed by an increase in abdominal pain associated with clinical deterioration and progression towards generalised peritonitis (*phase 3; irreversible ischaemia*). Every patient with atrial fibrillation and acute abdominal pain should be suspected of having acute SMA embolism.

The presence of synchronous ischaemic symptoms from other arterial segments such as extremity ischaemia or stroke/transient ischaemic attack may indicate synchronous embolism, which may be a diagnostic aid. In an autopsy series of patients with fatal occlusion of the SMA, 19% had an acute myocardial infarction, 48% had residual cardiac thrombus, and 68% had synchronous embolism, mainly to arteries supplying the brain, abdominal viscera, and legs.<sup>7</sup> The embolus may occlude the arterial lumen completely or partially. Emboli tend to lodge at points of normal anatomical narrowing, usually immediately distal to the origin of a major branch. Typically, the embolus lodges a few centimetres distal to the origin of the SMA, sparing the proximal jejunal branches, and thereby allowing preservation of the proximal jejunum.

**2.2.2. Clinical presentation: thrombosis.** At first evaluation acute thrombotic SMA occlusion is more difficult to diagnose than acute embolic SMA occlusion. Thrombosis occurs at areas of severe atherosclerotic narrowing, most often where the SMA and CA originate from the aorta.<sup>7</sup> Occlusive atherosclerotic lesions in the SMA are clinically more important, compared with those in the CA. Prior history of other atherosclerotic manifestations such as coronary, cerebrovascular, or peripheral arterial occlusive disease is common. Every patient with such a history together with acute abdominal pain should be suspected of having SMA thrombosis. In a substantial proportion of these patients, progressive atherosclerosis at the SMA origin may have developed over many years, resulting in collateral circulation to the SMA, mainly from the CA and IMA. Dehydration, low CO, and hypercoagulable states are major contributing factors to thrombosis. In the case of a thrombotic occlusion at the origin of the SMA, ischaemia usually develops from the proximal jejunum to the mid-transverse colon.

In retrospect, a high proportion of the often misunderstood and misdiagnosed patients with acute thrombotic SMA occlusion may have had long-standing pre-existing symptoms of CMI, including postprandial abdominal pain (abdominal angina), fear of eating, diarrhoea, and weight loss. Indeed, 80% of patients were misdiagnosed and inappropriately treated medically with proton pump inhibitors, cortisone, or antibiotics in the diagnostic phase in a recent series.<sup>43</sup> This series did not support the view that the majority of these patients suffer from cachexia at diagnosis. Weight loss is a consistent finding in patients with two or three vessel disease. A proportion of patients were overweight when they fell ill; however, decreasing in weight to

normal at the time of diagnosis.<sup>43</sup> Patients diagnosed with advanced symptomatic CMI should be treated subacutely as transition from CMI to AMI is unpredictable.<sup>36,43</sup> Further recommendations regarding this group of patients are given in Chapter 3.

**2.2.3. Laboratory markers.** No plasma marker is accurate for diagnosis in the acute setting.<sup>8,44–56</sup> D-dimer has been found to be a consistent highly sensitive early marker, but the specificity was low. The high sensitivity, approaching 100%, makes it an excellent exclusion test, but many other conditions are associated with high D-dimer values.<sup>44,45</sup> Hence, a normal D-dimer at presentation most probably excludes acute SMA occlusion. In series with acute SMA occlusion including patients with MVT<sup>46,47</sup> and NOMI,<sup>48</sup> the sensitivity for D-dimer has been reported to be around 95%. In a recent publication plasma intestinal fatty acid binding protein (I-FABP) was reported to be much higher among 19 patients with vascular intestinal ischaemia than among 26 patients with non-vascular irreversible intestinal ischaemia.<sup>48</sup> Receiver operating characteristics curve analysis suggested that plasma I-FABP was accurate at diagnosing a vascular cause of intestinal ischaemia with an area under the curve of 0.88. Another report found that diagnostic accuracy was better for I-FABP in urine compared with plasma, with an area under the curve of 0.93 versus 0.70, respectively.<sup>49</sup> Currently, no recommendation on the use of I-FABP can be issued, because these very small series need confirmation.

Lactate is an end product of glycolysis under anaerobic conditions and exists in two isomers: L-lactate (primary isomer produced in humans) and D-lactate (produced by bacteria in the human colon). Plasma lactate (L-Lactate) concentration has been reported to have a high sensitivity, 91–100%,<sup>54,55</sup> but a low specificity, 42%,<sup>55,47</sup> for early diagnosis of intestinal ischaemia. The sensitivity of isomeric D-lactate for early diagnosis of intestinal ischaemia appears to be low.<sup>52,53</sup> In one study the mean plasma lactate level was doubled from the upper reference limit late in the course after a median symptom duration of 43 hours, which probably explains the elevated lactate levels and the high (90%) post-operative 30 day mortality.<sup>55</sup> Lactate levels were normal early in the course, 48–50%,<sup>53,56</sup> in two recent reports, suggesting that plasma lactate is a poor marker of early AMI. In a series of 34 patients with at least two available arterial blood gas lactate measurements within 24 hours before surgery, 17 (50%) exhibited an increase, and 17 (50%) a decrease in lactate levels. The authors concluded that the value of serial lactate and pH measurements in predicting the extent of intestinal ischaemia seems to be very limited.<sup>56</sup> There is common agreement that lactate is a marker of general deterioration, systemic hypoperfusion, and death, no matter the cause.<sup>56,57</sup> Experimental work suggests, however, that lactate produced within the porto-mesenteric venous circulation is effectively metabolised by the liver.<sup>58</sup> Hence, plasma levels of lactate do not reflect the lactate levels within the gastrointestinal tract. Most importantly, clinicians should be

aware of diagnostic pitfalls that may be encountered in patients with acute SMA occlusion such as elevated troponin I and elevated pancreatic amylase and normal plasma lactate, which may lead the clinician away from the correct diagnosis.<sup>53</sup>

look at the imaging may detect overlooked radiological findings associated with AMI at the initial reading,<sup>65</sup> and such diagnostic delay undoubtedly has a negative impact on prognosis. In addition, the radiologists' experience and expertise have an impact on their performance in diagnosing

Recommendation 1	Class	Level of evidence	References
In patients with acute abdominal pain, D-dimer measurement is recommended to exclude acute mesenteric ischaemia	I	B	44,46–48,51
Recommendation 2			
Use of L-lactate measurement is not recommended to diagnose or rule out acute occlusive mesenteric ischaemia	III	B	8,53,55,56

**2.2.4. Computed tomography angiography.** Diagnosis of acute SMA occlusion and severity of intestinal ischaemia has been greatly facilitated by the evolution and availability of high resolution CTA around the clock.<sup>59</sup> Intravenous contrast enhanced CT with a slice thickness of 1 mm or thinner, performed with and without contrast in both the arterial and portal venous phases (triphasic protocol) is currently recommended as the first line imaging technique to best diagnose occlusive pathology in the arteries and intestinal pathologies, respectively.<sup>60</sup> Reconstructions of images in the sagittal, coronal, and transverse planes are often helpful.

Embolic occlusion often appears as an oval-shaped filling defect surrounded by contrast in a non-calcified arterial segment located in the middle and distal part of the main stem of the SMA. The presence of synchronous emboli to the other visceral, limb, or cerebral arteries is a common finding.<sup>61</sup> Increased awareness of the high likelihood of atrial fibrillation related causes for acute abdominal pain may improve diagnostic performance of CTA and triage of patients with acute embolic SMA occlusion.<sup>62</sup>

Thrombotic occlusion usually appears as clot superimposed on a heavily calcified occlusive lesion at the origin of the SMA. The presence of vascular pathology precedes the intestinal pathology, which is of crucial importance when the images are studied.<sup>61</sup> Even patients with impaired renal function or increased creatinine values should undergo CTA if there is a suspicion of acute SMA occlusion, accepting the risk of contrast induced renal failure,<sup>63</sup> to improve diagnostic accuracy and chances of survival.

If no clinical suspicion of AMI is mentioned in the information provided to the radiologist, the condition is highly likely to be under-diagnosed.<sup>64</sup> It is not unusual that a second

AMI.<sup>66</sup> In the absence of intestinal findings on CT or peritonitis on clinical examination, patients with acute abdominal pain and CTA verified occlusion of the SMA are unlikely to be diagnosed in time to allow intestinal revascularisation. Diagnostic accuracy and specificity for CTA in diagnosing acute SMA occlusion is very good, and is superior to any of the plasma biomarker candidates.<sup>67</sup> Reconstructed images using maximum intensity projection, volume rendering, and multiplanar volume reconstruction have been found to perform better for the detection of vascular abnormalities and to improve the diagnostic confidence of radiologists in the evaluation of bowel and mesenteric abnormalities.<sup>68</sup> In series of suspected cases with AMI including a high proportion of cases with acute SMA occlusion, the sensitivity of CTA in diagnosing AMI ranged from 73% to 100%, and the specificity from 90% to 100%.<sup>46,68–72</sup>

**2.2.5. Duplex ultrasound.** Duplex ultrasound (DUS) of the visceral arteries is an operator-dependent imaging modality, and it may not be possible to obtain accurate assessments around the clock. Furthermore, bowel paralysis associated with acute intestinal ischaemia precludes accurate ultrasound scanning in many patients. Although proximal occlusive lesions of the visceral arteries can be identified, distal occlusions cannot. DUS is not an appropriate imaging method to assess acute occlusive lesions of the visceral arteries.

**2.2.6. Digital subtraction angiography.** Digital subtraction angiography (DSA) is a diagnostic method that can differentiate occlusive, embolic, and thrombotic from non-occlusive AMI, but it is seldom used for diagnostic purposes alone.

In Table 5, (page 31) diagnostic differentiation of venous, arterial occlusive, and non-occlusive mesenteric ischaemia are summarised.

Recommendation 3	Class	Level of evidence	References
In patients with suspected AMI, triphasic CTA with 1 mm slices (or thinner) should be used to detect mesenteric arterial occlusion	I	B	46,68,70–72
Recommendation 4			
In patients with suspected AMI and elevated creatinine values, CTA might be considered, accepting the risk of contrast induced renal failure, to save life	IIb	C	53,55

AMI = acute mesenteric ischaemia; CTA = computed tomography angiography.

### 2.3. Treatment of acute superior mesenteric artery occlusion

**2.3.1. Current approaches.** Intestinal revascularisation is necessary in most patients with acute SMA occlusion. The only situation in which a bowel resection without revascularisation may save the life of the patient is in the case of a distal embolus, with a widely open proximal artery. The extent of intestinal infarction involves the jejunum, ileum, and colon in 50% of the patients, and at least two of these intestinal segments in 82%,<sup>7</sup> which means that bowel resection alone would be life saving for a minority of patients. Optimal treatment may include both open and endovascular surgery, and patients are best treated in a vascular centre with a hybrid operating room, although logistical aspects must be taken into consideration in this urgent situation. From pre-operative clinical and radiological evaluation, it should be determined whether or not the patient has peritonitis, and whether the occlusion is embolic or thrombotic. The presence of intestinal wall or portomesenteric gas on CTA is a sign of severe transmural ischaemia, but is not necessarily associated with a fatal outcome if treated in a timely fashion.<sup>56</sup> Laparotomy is indicated if there are signs of peritonitis and suspicion of intestinal infarction, unless a palliative approach has been chosen. Laparotomy aims to assess the extent and severity of intestinal ischaemia and vessel patency, although the latter may require peri-operative angiography. Laparotomy, rather than laparoscopy, is usually safer and quicker to evaluate the visceral organs. Extensive intestinal paralysis with dilated bowel loops may be impossible to evaluate at laparoscopy, even by an expert. Elderly patients with complete transmural infarction of the small bowel up to the mid-transverse colon would need extensive bowel resection that would lead to short bowel syndrome and increased morbidity. Survival in these patients is poor and surgery may be inappropriate for ethical reasons. In the event of bowel perforation, the affected intestinal segment is resected, leaving the reconstruction of the intestines or stoma formation until a second look laparotomy after 18–36 hours.

**2.3.2. Acute mesenteric arterial revascularisation.** Acute mesenteric arterial revascularisation is preferably done before any bowel surgery, even if there is a limited length of necrotic bowel that could be rapidly resected. If laparotomy has been performed because of an uncertain diagnosis of peritonitis in a hospital where there is no vascular surgeon available, it may be preferable to resect necrotic bowel without reconstruction, close the abdomen, and transport the patient to a vascular centre for revascularisation.

According to the Swedish National Registry for Vascular Surgery (Swedvasc),<sup>45</sup> there has been a steady increase in mesenteric revascularisation for AMI since 2004. In 2009, endovascular treatment overtook open surgery in Sweden: 29 endovascular versus 24 open revascularisations. In contrast, this shift in treatment modality has not taken place in North America.<sup>73</sup> The 30 day mortality rate in Swedvasc was similar after open versus endovascular surgery for embolic occlusions (37% vs. 33%), whereas the mortality rate was significantly

higher after open than endovascular treatment for thrombotic occlusions (56% vs. 23%). Of note, no patient had completion angiography after open surgical treatment, whereas completion angiography is part of the procedure after endovascular surgery. There may have been differences in disease severity between the treatment groups, but it remains possible that the endovascular approach is better for thrombotic occlusions in elderly, frail patients.<sup>45</sup>

There is rarely any indication for revascularisation of both the SMA and the CA, and SMA revascularisation seems to be more important. Even after successful endovascular recanalisation of the mesenteric arteries, patients may still require laparotomy when persisting signs of peritoneal irritation indicate the presence of non-viable bowel.

### 2.3.3. Open superior mesenteric artery embolectomy.

Open SMA embolectomy remains a good treatment option.<sup>74,75</sup> When laparotomy has been performed in a patient with peritonitis, exposure of the SMA is performed. A 5 cm transverse incision in the visceral peritoneum/transverse mesocolon in the root of the mesentery, just below the body of the pancreas, is performed. If the embolus is distal in the artery, the pulse in the SMA can easily be palpated, and the artery is located dorsally to the left of the often easily recognised superior mesenteric vein (SMV). After arteriotomy, balloon embolectomy with a 3 or 4 Fr Fogarty catheter is indicated. The result should be checked by some form of completion control, such as angiography of the SMA with antero-posterior and lateral views, or transit time flow measurement. If none of these modalities are available, pulse palpation distally in the mesentery can be performed. Comparative data regarding which completion control method to use are lacking. The presence or absence of stenosis and dissection at the arteriotomy closure site, residual peripheral embolus in arterial branches not cleared, and venous return to the portal vein can only be assessed by DSA.

### 2.3.4. Open vascular surgery for acute thrombotic superior mesenteric artery occlusion.

Division of the SMA distal to the occlusive lesion and re-implantation into the infrarenal aorta, thromboendarterectomy with patch angioplasty, and bypass distal to the occlusive atherosclerotic lesion are the open surgical options.<sup>76</sup> If available, the pre-operative CTA can be very useful to determine the source of inflow artery and sites with extensive atherosclerotic lesions which can be avoided. Bypass with a short synthetic graft from the infrarenal aorta to the SMA is the simplest procedure and may be most appropriate in the emergency setting,<sup>77</sup> but it is seldom possible because the aorta is often heavily calcified. With co-existing extensive atherosclerotic lesions in the infrarenal aorta, the supracoeliac aorta or the anterior part of the common iliac artery may be used as the inflow for the graft. Autologous reversed saphenous vein may be the preferred conduit, especially in case of bacterial contamination. Vein grafts originating from the infrarenal aorta or the common iliac artery are, however, prone to kinking when the intestines are moved back into the abdomen after

completion of the bypass. A long C-shaped saphenous vein conduit joining the SMA at its origin and running parallel to the point of anastomosis could reduce the risk of kinking. Polyethylene terephthalate (e.g. Dacron®) or expanded polytetrafluoroethylene (ePTFE) reinforced with rings might be a preferred conduit material, especially in the emergency setting in a non-contaminated peritoneal cavity, to prevent kinking of the graft. The SMA can be transected distal to the occlusive lesion, anastomosed end to end to the ringed ePTFE bypass graft, after which the graft can be routed and anastomosed to the selected take off arterial site. If the graft is sutured end to side to the SMA, a Miller vein cuff between the SMA and graft may be of benefit. It is important to cover the graft with an omental flap if possible, to prevent contact between the graft and the intestines, which otherwise may result in a graft-enteric fistula.

why no recommendation can be made regarding their applicability. Clinical assessment at laparotomy has remained the preferred method for assessment of bowel viability.<sup>82</sup>

Although laparoscopy is a minimally invasive method, it cannot safely assess the entire length of the intestines for ischaemia. Ischaemic bowel may be paralytic and distended, not allowing safe inspection. Laparoscopic manipulation of the fragile bowel may expose the patient to an increased risk of perforation. If a laparotomy has been performed, there is no justification to perform a second look with laparoscopy in the emergency setting. In patients undergoing successful endovascular revascularisation early in the course without intestinal lesions on CTA, however, diagnostic laparoscopy might have a role in assessing bowel viability.<sup>83</sup>

Recommendation 5	Class	Level of evidence	References
In patients with acute mesenteric arterial ischaemia, open or endovascular revascularisation should be considered before bowel surgery	IIa	B	10,45,73,78,79
Recommendation 6			
In patients undergoing mesenteric revascularisation, completion imaging with angiography or transit time flow measurements should be considered	IIa	C	44,46–48,51

Recommendation 7	Class	Level of evidence	References
In patients undergoing laparotomy for AMI, clinical judgement should be considered as the preferred method for assessing bowel viability	IIa	C	80,82

AMI = acute mesenteric ischaemia.

**2.3.5. Assessment of bowel viability.** Intestinal ischaemia may be extensive, ranging from lesions in the jejunum, ileum, and colon, to a normal appearance of the serosa. Ischaemic changes are more extensive on the mucosal side. Intestinal ischaemia is characterised by patchy cyanosis, reddish black discolouration, decreased or absent peristalsis, and no palpable pulsation in the mesentery. The use of intra-operative Doppler for detection of pulsatile mural blood flow and intravenous injection of fluorescein for assessment of ultraviolet fluorescence pattern in the assessment of bowel viability has been compared with clinical judgement,<sup>80</sup> and the fluorescence pattern method was more accurate than both clinical judgement and Doppler. However, the fluorescence pattern method has not been established as the method of choice in a centre that has used both these non-clinical methods.<sup>73</sup> The accuracy of laser Doppler flowmetry and clinical assessment was reported to be 100% and 87%, respectively, in one study.<sup>81</sup> There has been a paucity of studies concerning laser Doppler flowmetry, however, questioning its clinical applicability. None of the described adjunctive methods have become established in clinical practice, which is the reason

**2.3.6. Second look laparotomy.** Clinical re-assessment of bowel viability may be necessary, sometimes repeatedly. It depends on the initial extent and severity of intestinal ischaemia prior to revascularisation, the expected effect of the revascularisation procedure, any bowel resection performed, and the physiological condition of the patient. The need to perform a second look laparotomy and bowel resection may indicate a more severe state of ischaemia and this may therefore be associated with a higher mortality.<sup>84</sup> However, a second look laparotomy is the safest way to establish the extent of advanced transmural intestinal ischaemia, and several authors recommend its liberal use because of the high frequency of bowel resection required at a second look laparotomy.<sup>73,85</sup> The decision to undertake a second look is taken according to the surgeon's interpretation at the initial laparotomy, or if the patient's condition does not improve after 48 hours in the intensive care unit (ICU).<sup>35</sup> Bowel resection managed with intestinal infarction and also peritonitis should be treated with broad spectrum intravenous antibiotics,<sup>86</sup> but no specific recommendation can be made as to which type of antibiotics should be administered as different antibiotics showed equivocal results in terms of clinical outcome.

Recommendation 8	Class	Level of evidence	References
Patients requiring bowel resection because of intestinal infarction should be treated with antibiotics	I	A	86

**2.3.7. Damage control surgery.** Laparotomy after mesenteric revascularisation serves to evaluate the possible damage to the visceral organs. Bowel resection and organ removal (e.g. a necrotic gall bladder) should be carried out according to the principles of damage control surgery.<sup>87</sup> Bowel resections can be performed with staplers, delaying the creation of anastomoses or stomas until the second or third look laparotomy. In case of necrosis of the gall bladder, prolonged drainage is an alternative to cholecystectomy. The abdominal wall can be left unsutured when repeat laparotomy is planned. In this situation, skin only closure or temporary abdominal closure using a negative pressure wound therapy device may be applied. The protocol for AMI in some centres is to create a temporary stoma after intestinal resection, and to administer parenteral nutrition until the surgical recovery phase is over.<sup>35</sup> In patients undergoing extensive bowel resections, including proximal resection of the jejunum or multiple resections, bowel anastomosis after effective intestinal revascularisation may be beneficial in avoiding a high output stoma, short bowel syndrome, and the increased mortality rate associated with intestinal failure.<sup>45</sup> Such anastomoses should probably not be performed during the primary laparotomy, however, because of a high risk of anastomotic breakdown. No comparative studies have been published on this controversial issue.

clot, which is aspirated with a 20 mL syringe as the catheter is withdrawn. The hub of the introducer is removed to allow clearance of residual clots. Angiography is performed, usually followed by repeated aspirations. An alternative is to use an over the wire double lumen aspiration catheter, which may allow removal of smaller peripheral clots.

**2.4.3. Local superior mesenteric artery thrombolysis.** In cases of incomplete aspiration embolectomy or distal embolisation, local thrombolysis is a viable treatment alternative in patients without peritonitis.<sup>93,94</sup> With the introducer placed in the proximal SMA, a multiple sidehole catheter delivering thrombolytic agents over 10 cm, or an end hole catheter, is advanced to within the embolus. Local thrombolysis is most often achieved by administration of recombinant tissue plasminogen activator (rtPA) at a rate of 0.5–1 mg/h (or other agents, at different dosages, e.g. urokinase 120,000 IU/h), checking the patency with repeated angiograms once or twice per day (Fig. 2A–E). Bleeding complications during local thrombolysis are uncommon and usually self limiting.<sup>93</sup> Small peripheral residual emboli can be treated conservatively with heparin anticoagulation as the marginal arteries in the mesentery may provide sufficient collateral circulation to the affected intestinal segment.<sup>88</sup> In one large population based study only 38% of patients needed to undergo laparotomy for inspection of the in-

Recommendation 9	Class	Level of evidence	References
In patients undergoing acute intestinal revascularisation, second look laparotomy and damage control surgery should be considered	Ila	C	45,85

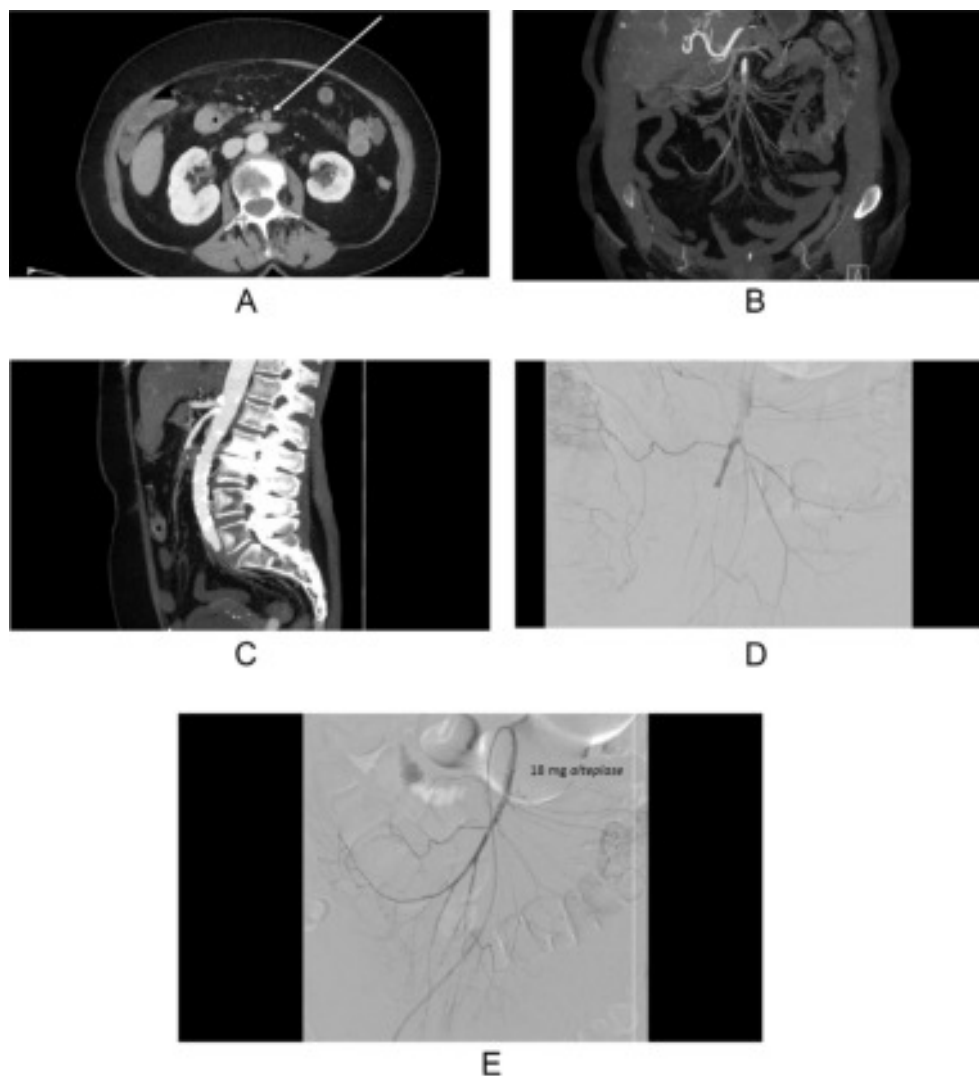
## 2.4. Endovascular therapeutic options in acute mesenteric ischaemia

**2.4.1. Access to the superior mesenteric artery.** The SMA can be reached via the femoral and brachial routes, although sometimes local exposure of the SMA in the abdomen is also needed. Brachial access may be preferable if there is a sharp downward angle between the aorta and the SMA, or if the ostium of the SMA is calcified. If an antegrade approach from the femoral or brachial artery fails, a retrograde approach through the exposed SMA after laparotomy can be attempted, unless open revascularisation is preferred.<sup>88</sup>

**2.4.2. Aspiration embolectomy of the superior mesenteric artery.** Endovascular aspiration embolectomy is a treatment option in patients without peritonitis.<sup>86–90</sup> Usually an appropriate catheter and a hydrophilic 0.035 inch guidewire is passed into the ileocolic branch of the SMA. The wire is then replaced with a stiffer wire to achieve stability. With the wire in place, typically an introducer with a removable hub is placed proximal to the embolus in the SMA. Inside this, a smaller guiding catheter<sup>91,92</sup> is introduced into the

testines after local thrombolysis.<sup>93</sup> This low occurrence is probably explained by peritonitis or other signs of bowel gangrene being considered as contraindications to thrombolysis. Endovascular rheolytic thromboembolectomy may be a supplementary technique to aspiration thromboembolectomy in cases where thrombolysis is contraindicated.

**2.4.4. Antegrade recanalisation and stenting of the superior mesenteric artery.** Treatment of underlying stenotic or occlusive lesions is most often achieved during the same procedure, after removal of a thrombotic clot by aspiration or thrombolysis.<sup>88</sup> The sequence of endovascular intervention versus exploratory laparotomy depends on the clinical state of the patient. When a stable wire has been placed in the ileocolic artery, an introducer is advanced across the atherosclerotic lesion. Balloon expandable stents are better to maintain lumen diameter after stent deployment across hard, calcified ostial lesions than self expanding stents. The balloon expandable stent is placed at the level of the stenosis, followed by retraction of the protective introducer sheath, thus exposing the stent, which is deployed by inflating the balloon.



**Figure 2.** Patient with an acute embolic occlusion of the SMA. CTA images in transverse (A), coronal (B), and sagittal (C) projection. The typical oval-shaped embolic occlusion is best seen in the sagittal projection (C). SMA angiography prior to (D) and after (E) local administration of 18 mg of alteplase with clearance of embolus. Laparoscopy was negative, and recovery was uneventful.

Unfavourable artery angulation or a potential risk of arterial dissection at the distal end of the stent is treated by extension with a self expanding stent into the mid-SMA. Results after stenting are checked by angiography, as well as by pressure measurement. If there is a residual pressure gradient across the stent exceeding 12 mmHg, additional angioplasty and/or stenting is performed.<sup>95</sup>

**2.4.5. Retrograde recanalisation and stenting of the superior mesenteric artery.** If percutaneous access fails, laparotomy and exposure of the SMA is performed for retrograde SMA recanalisation and stenting.<sup>88,96–98</sup> This approach offers the opportunity to inspect the abdominal viscera, to have distal control of the SMA, and to avoid bypass surgery in the setting of necrotic bowel. A puncture is made in the vessel in its main trunk or in one of its major branches with a micro puncture needle; the occlusion is often recanalised easily with a guidewire placed into the aorta. The SMA is clamped distally to avoid distal embolisation if there is fresh thrombus at the occlusion site. The proximal SMA lesion is then crossed with a stiff catheter, exchanging for a hydrophilic guidewire. The wire is snared in the aorta using a snare passed through a brachial

or femoral access and then brought out, creating through and through access. An introducer is placed antegradely in the SMA over the through and through wire, followed by stenting. The access puncture in the SMA is treated by manual compression or interrupted suture(s). Antegrade stenting is better than retrograde stenting, because the procedure can be performed with standard devices without exposing the operators to a higher dose of radiation.

**2.4.6. Outcomes after open versus endovascular revascularisation for acute mesenteric ischaemia.** Five non-randomised studies<sup>10,45,73,78,79</sup> have compared open versus endovascular revascularisation for arterial AMI. These studies have shown a benefit for endovascular therapy compared to open surgery in terms of lower bowel resection rates (Fig. 3; OR 0.37 [95% CI 0.23–0.59],  $p=.03$ ;  $I^2=63\%$ ) and lower 30 day mortality rates (Fig. 4; OR 0.50 [95% CI 0.30–0.83];  $p=.002$ ;  $I^2=76\%$ ). In these five studies, the pooled overall 30 day mortality rate after endovascular therapy was 17.2% (367/2131), compared with 38.5% after open surgery (1582/4111) (Fig. 4). One retrospective single centre experience<sup>73</sup> showed no difference in mortality between the two treatment

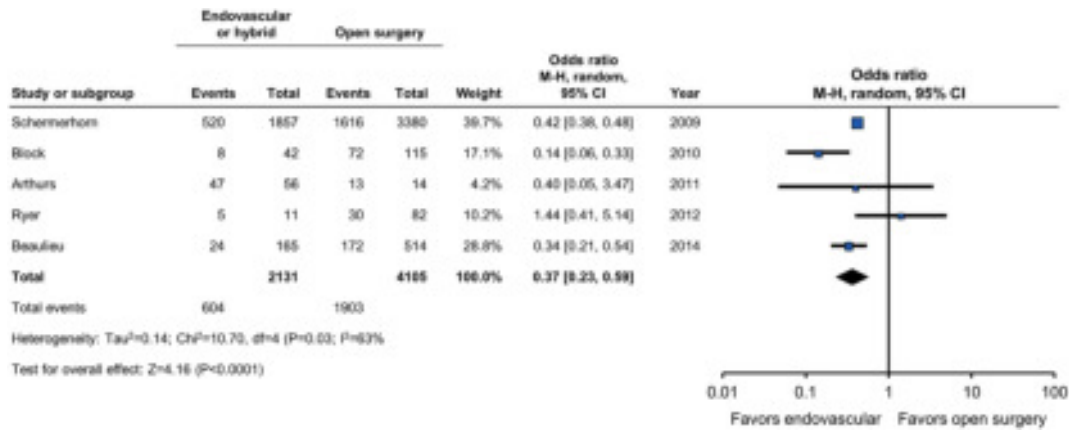


Figure 3. Meta-analysis of bowel resection rates after open and endovascular therapy of AMI.

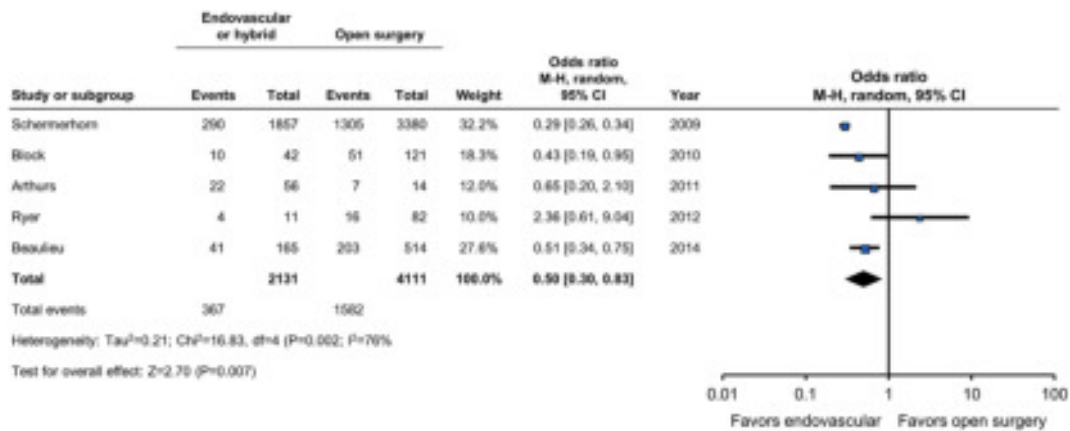

Figure 4. Meta-analysis of 30-day mortality rates after open and endovascular therapy of AMI.

modalities, whereas the other single centre study showed lower bowel morbidity and mortality after endovascular therapy for acute thrombotic occlusions compared with open surgery.<sup>78</sup> The other three multicentre studies are nationwide reports.<sup>10,45,79</sup> These studies showed a lower frequency of bowel resection, and lower short-term<sup>10,45,79</sup> and long-term<sup>45</sup> death rates after endovascular compared with open surgical therapy for acute thrombotic occlusion. It is important to note that these five non-randomised studies express high levels of heterogeneity, are prone to bias, and it is possible that patients undergoing open repair have more advanced states of intestinal ischaemia, resulting in higher bowel resection rates and poorer outcome. The long-term survival 5 years after endovascular treatment and open vascular surgery was 40% and 30%, respectively.<sup>45</sup> Independent risk factors for decreased long-term survival were short bowel syndrome and age. In patients with acute embolic SMA occlusion there are no data to suggest that open or endovascular treatment is superior.

publications reporting on the risk of restenosis, re-occlusion, and bowel gangrene after treatment focus on the technique that was used (such as stenting) rather than whether the patient suffered acute, chronic, or acute on chronic mesenteric ischaemia.

In the next chapter (3, on CMI), follow-up after endovascular treatment such as SMA or CA stenting is discussed. Patients who have a stent inserted in the SMA after treatment for CMI or AMI may be followed repeatedly by either DUS or CTA because of the high risk of in-stent restenosis, 36% after a mean follow-up of 29 months.<sup>99</sup> In a large series of patients undergoing endovascular revascularisation for CMI, five patients (3.4%) died during the follow-up period of 64 months because of recurrence of AMI, according to a review of death certificates or autopsy reports.<sup>100</sup> If the risk of dying from AMI is so high after re-occlusion of a stent inserted for CMI, the risk is likely to be even higher after occlusion of a stent used to treat AMI, because of less well-developed

Recommendation 10	Class	Level of evidence	References
In patients with acute thrombotic SMA occlusion, endovascular therapy should be considered as first line therapy because of lower mortality and bowel resection rates compared with open revascularisation	Ila	B	10,45,78,79

SMA = superior mesenteric artery.

### 2.5. Follow-up

A methodological problem when discussing the data on follow-up after treatment for mesenteric ischaemia is that

collateral circulation. Emergency stenting for AMI may be performed under inferior radiological conditions compared with elective stenting, and the clinical consequences of a restenosis or re-occlusion are probably more severe.

One paper reported a mortality rate of 50% after SMA stent occlusion in patients treated for AMI.<sup>43</sup> The most optimal follow-up interval has not been established. A factor to take into account is neointimal hyperplasia, which typically develops 3–15 months after stenting. One centre advocates imaging prior to discharge, and then every 6 months during the first year, and annually thereafter,<sup>99</sup> whereas another centre advocates follow-up at 1, 3, 6, and 12 months, and then yearly thereafter.<sup>101</sup> If the patient was treated for embolic disease (with an open or endovascular technique), there is probably no indication for follow-up (other than for the underlying cardiac disease that generated the embolus) after 30 days.

CMI is possible in the presence of normal weight. The diagnosis of CMI is often delayed as patients undergo extensive investigations for possible malignancy or are classified as having functional abdominal disorders. Atypical symptoms like constant abdominal discomfort, nausea, vomiting, diarrhoea, or constipation occasionally can be present, and may indicate end stage ischaemia, that is a risk of developing bowel gangrene. Clinical history and physical examination may reveal atherosclerotic involvement in other locations.<sup>29,105</sup> Abdominal examination may reveal an epigastric bruit. Laboratory findings are not specific, but may include anaemia, leukopenia, electrolyte abnormalities, and hypoalbuminaemia secondary to chronic malnutrition.

Recommendation 11	Class	Level of evidence	References
In patients with AMI and stented mesenteric arteries, imaging follow-up should be considered	IIa	C	99,101

AMI = acute mesenteric ischaemia.

### 2.6. Medical treatment of mesenteric arterial disease

Patients who survive after acute mesenteric vascular occlusion need lifelong medical treatment. After thrombotic arterial occlusion, patients should have the best medical therapy against atherosclerosis, including smoking cessation, an antiplatelet agent, and a statin. A meta-analysis of data from >170,000 participants in 26 randomised studies of statin treatment demonstrated a 10% proportional reduction in total mortality per 1.0 mmol/L reduction of LDL-cholesterol.<sup>102</sup> In a recent meta-analysis on dual versus single antiplatelet therapy after endovascular arterial procedures in the lower limb, carotid, and coronary arteries, no significant superiority was found for dual over single antiplatelet therapy, but there was also no evidence of an increased bleeding risk.<sup>103</sup> There are no specific data on secondary prophylaxis in patients with mesenteric arterial disease, however. In the case of embolic arterial occlusion, treatment with a lifelong vitamin K antagonist (VKA) or a New Oral AntiCoagulant (NOAC) for non-valvular atrial fibrillation is usually indicated.<sup>104</sup>

### 3.2. Anatomy and symptomatology

The anatomy of the three mesenteric arteries CA, SMA, IMA is discussed in Chapter 1.5. A number of collateral pathways provide arterial supply when one or two of the mesenteric arteries are occluded or significantly stenotic (Fig. 1, page 6). It is assumed that the abundant arterial collateral circulation of the mesenteric tract prevents gastrointestinal ischaemia in single vessel disease. This can be demonstrated by stenosis in a single mesenteric artery often being found in the general population (up to 18%), but the diagnosis of mesenteric ischaemia being very rare.<sup>11,106,107</sup> Symptoms of mesenteric ischaemia are usually not present until at least two of the three mesenteric arteries are significantly stenosed or occluded. Single vessel atherosclerotic occlusion, however, can occasionally cause symptomatic disease.<sup>30,108</sup>

The most common cause of single vessel abdominal arterial stenosis is extrinsic compression of the CA by the median arcuate ligament, often named median arcuate

Recommendation 12	Class	Level of evidence	References
In patients surviving AMI, secondary medical prevention, including smoking cessation, statin therapy, and antiplatelet or anticoagulation treatment, is recommended	I	C	104

AMI = acute (arterial, occlusive) mesenteric ischaemia.

## 3. ARTERIAL ISCHAEMIA, CHRONIC MESENTERIC ISCHAEMIA

### 3.1. Symptoms and signs

CMI is commonly characterised by postprandial abdominal pain, and when severe, food aversion and weight loss. The typical pain is mid-abdominal or epigastric and can be sharp or dull, usually beginning 20–30 minutes after eating and lasting 1–2 hours. The abdominal pain associated with eating causes patients to reduce food intake and this leads to significant weight loss. Patients presenting with a possible diagnosis of CMI without substantial weight loss should be further investigated for an alternative diagnosis, although

ligament syndrome (MALS). The median arcuate ligament passes over the aorta at the level of the first lumbar vertebral body, superior to the origin of the coeliac axis. An anomalous fibrous diaphragmatic band compresses the CA in patients with a relatively low insertion of the diaphragm. The existence of this disease is still controversial and the diagnosis depends on elimination of other possible causes of abdominal pain. The symptoms in this condition may not be caused by CMI and the pathophysiology is poorly understood. Despite this, in a prospective cohort study using an ischaemia function test, treatment offered a long-term benefit in approximately 80% of cases.<sup>30</sup>



Recommendation 13	Class	Level of evidence	References
The diagnosis of CMI should be considered less likely in the absence of multi-vessel stenosis or occlusion, and warrants careful investigation for alternative causes	Ila	C	11,30,106–108
Recommendation 14			
In patients with otherwise unexplained abdominal symptoms, and occlusive disease of two or three mesenteric arteries, CMI should be considered to be the cause of the symptoms	Ila	C	11,30,106–108

CMI = chronic mesenteric ischaemia.

### 3.2.1. Diagnostic imaging

**3.2.1.1. Abdominal X-ray.** Plain abdominal X-ray has no role in the diagnosis of CMI. As patients do not develop bowel necrosis the X-rays are usually normal or show nonspecific findings. Vascular calcification may indicate atherosclerotic disease, which can be a clue to the diagnosis, but a normal examination does not exclude CMI.

**3.2.1.2. Ultrasound.** DUS is most often used as the first screening imaging study to diagnose the presence of significant mesenteric arterial stenosis or occlusion. It may also be used to evaluate open and endovascular interventions. The investigation may be technically challenging and requires a skilled specialist. This technique provides the benefit of dynamic assessment of flow through narrowed arterial segments. In one study, 83% of CAs and 93% of SMAs were visualised on the initial DUS, compared with 100% of CAs and 99% of SMAs visualised on DSA.<sup>109</sup>

DUS interpretation criteria have been defined in several studies, with somewhat diverging results, partly a result of studying different patient populations. Peak systolic velocity (PSV) and end-diastolic velocity (EDV) can be used to predict significant stenosis of the CA and SMA (Table 3). Comparing DUS evaluation to DSA, a diagnostic accuracy of 85–90% was confirmed for the detection of >70% mesenteric artery stenosis.<sup>110</sup> Postprandial testing with

administration of a test meal can be helpful and provides justification for additional imaging of the mesenteric arteries. Interpretation of flow velocities in the mesenteric vessels should take into account both the respiratory cycle and the presence of stenoses in the “other” vessel.<sup>111,112</sup>

DUS is also useful for intra-operative assessment of open surgical procedures on mesenteric arteries. One single centre study reported an 8% incidence of technical errors using routine intra-operative DUS.<sup>109–111,113–117</sup>

DUS evaluation following endovascular interventions on visceral arteries may be used as an adjunct to clinical assessment. There is no consensus on velocity measurements that define the presence of high grade mesenteric arterial restenosis following open or endovascular revascularisation, but an increase of PSV or EDV in repeated standardised DUS indicates progressive stenosis of the mesenteric arteries.<sup>118</sup> Most centres use similar criteria to those used for native arterial lesions. In the case of abnormal findings, DSA or CTA of the restenosis may be necessary, DSA having the advantage of permitting pressure measurements.

There is some evidence to suggest that endoscopic ultrasound might be an accurate test to evaluate chronic abdominal pain and to exclude CMI, avoiding the limitations of the trans-abdominal technique; however, this has not been confirmed in larger prospective studies.<sup>119</sup>

**Table 3.** Duplex criteria of mesenteric artery stenosis.

First author (publication year)	SMA PSV ≥ 50% stenosis	SMA PSV ≥ 70% stenosis	CA PSV ≥ 50% stenosis	CA PSV ≥ 70% stenosis	SMA EDV ≥ 50% stenosis	SMA EDV ≥ 70% stenosis	CA EDV ≥ 50% stenosis	CA EDV ≥ 70% stenosis
Moneta 1993 <sup>109</sup> (n=100)		275 cm/s sens 92% spec 96%		200 cm/s sens 87% spec 80%				
AbuRahma 2012 <sup>113</sup> (n=150)	295 cm/s sens 87% spec 89%	400 cm/s sens 72% spec 93%	240 cm/s sens 87% spec 83%	320 cm/s sens 80% spec 89%	45 cm/s sens 79% spec 79%	70 cm/s sens 65% spec 95%	40 cm/s sens 84% spec 48%	100 cm/s sens 58% spec 91%
van Petersen 2013 <sup>111</sup> (n=324)	≥ 220 cm/s (expiration) sens 84% spec 76%	≥ 268 cm/s (expiration) sens 75% spec 86%	≥ 268 cm/s (expiration) sens 66% spec 80%	≥ 280 cm/s (expiration) sens 66% spec 77%	≥ 62 cm/s (expiration) sens 75% spec 94%	≥ 101 cm/s (expiration) sens 74% spec 96%	≥ 64 cm/s (expiration) sens 78% spec 65%	≥ 57 cm/s (expiration) sens 83% spec 56%
	≥ 277 cm/s (inspiration) sens 68% spec 93%	≥ 205 cm/s (inspiration) sens 78% spec 84%	≥ 243 cm/s (inspiration) sens 68% spec 71%	≥ 272 cm/s (inspiration) sens 72% spec 77%	≥ 52 cm/s (inspiration) sens 76% spec 93%	≥ 52 cm/s (inspiration) sens 78% spec 93%	≥ 83 cm/s (inspiration) sens 53% spec 81%	≥ 84 cm/s (inspiration) sens 66% spec 81%

SMA = superior mesenteric artery; CA = coeliac artery; PSV = peak systolic velocity; EDV = end-diastolic velocity; sens = sensitivity; spec = specificity.

Recommendation 15	Class	Level of evidence	References
In patients with suspected CMI, DUS of the mesenteric arteries is recommended as the first line examination	I	B	109–112,114,119

CMI = chronic mesenteric ischaemia; DUS = duplex ultrasound.

**3.2.2. Angiography.** DSA has historically been considered to be the gold standard for the diagnosis of mesenteric occlusive disease. It can provide good quality imaging of the mesenteric vasculature and also demonstrates any collat-

recent study comparing the quality of imaging of the mesenteric vessels.<sup>115</sup> Moreover, it has been confirmed that the IMA and peripheral mesenteric vessels can be better visualised using CTA.<sup>123</sup>

Recommendation 16	Class	Level of evidence	References
In patients with a moderate to high suspicion of CMI, CTA is recommended to map the occlusive disease, and to detect or exclude other intra-abdominal pathology	I	C	60,70,115,121–123
<b>Recommendation 17</b>			
MRA may be considered an alternative to CTA for diagnosis of suspected CMI, although there is some evidence that images obtained with MRA are not as accurate or complete as those obtained with CTA	IIb	C	60,70,115,121–123

CMI = chronic mesenteric ischaemia; CTA = computed tomography angiography; MRA = magnetic resonance angiography.

eral circulation. In addition, it has the advantage of allowing endovascular procedures to be performed at the same time as the DSA. On the other hand, DSA is an invasive treatment with potential complications, and it exposes patients to radiation. CTA has replaced DSA as a diagnostic modality and can be used as the diagnostic test for planning endovascular treatment. In some centres, pressure gradient measurement across the lesion with simultaneously placed pressure sensors in the aorta and distal to the occlusive lesion, is an integral part of the endovascular procedure.<sup>95,120</sup> Severe SMA stenosis is defined by a mean arterial pressure gradient across the lesion of 10 mmHg or more (the aim of stenting is to reduce the mean arterial pressure gradient close to 0 mmHg,<sup>95</sup> see below).

**3.2.2.1. Computed tomography angiography.** CTA is now the imaging method of choice in CMI. With 3D reformatting, it can provide excellent reconstructions of the mesenteric arteries and has a sensitivity and specificity of 96% and 94%, respectively, for the diagnosis of occlusions.<sup>70</sup> This imaging technique also allows visualisation of other abdominal organs during the same procedure and therefore helps to exclude other causes of chronic abdominal pain. In addition, CTA allows the identification of calcified plaques. Three-dimensional imaging allows evaluation of the collateral circulation which develops in CMI. The CTA findings of localised narrowing with post-stenotic dilatation and the absence of atherosclerotic plaques can support the diagnosis of MALS.<sup>121</sup>

**3.2.2.2. Magnetic resonance angiography.** Magnetic resonance angiography as a non-invasive test has a potential role in the imaging of CMI. In a small series the sensitivity and specificity were 100% and 95%, respectively, compared with catheter angiography and surgery.<sup>122</sup> The main advantages of MRA are its lack of radiation exposure and the possibility of making flow measurements.<sup>60,122</sup> CTA has been demonstrated to be superior to MRA, however, in a

**3.2.2.3. Proof of ischaemia (functional evaluation).** The presence of vessel stenosis is no proof of actual ischaemia, and the clinical history of CMI has a large overlap with many other disorders including those of the pancreas, gall bladder, stomach, and duodenum, as well as functional disorders. This emphasises the need for a functional test that could actually prove ischaemia and distinguish CMI from other conditions. Most experienced physicians do not hesitate to treat patients with weight loss or severe postprandial complaints in the presence of severe multi-vessel involvement. The far more common patient with single vessel stenosis, however, is a different problem. Most will not have ischaemia, and the numbers of these asymptomatic patients referred will probably increase with the increasing use of imaging for other suspected conditions. The number of reliable diagnostic tests, however, remains very limited.

Proof of actual CMI can be obtained through five types of investigation:

- i) assessment of tissue ischaemia during endoscopy
- ii) measurement of gastrointestinal blood flow
- iii) measurement of decreased tissue PO<sub>2</sub> or increased tissue CO<sub>2</sub>
- iv) measurement of ischaemia specific biomarkers
- v) laparotomy with histopathology.

Upper gastrointestinal endoscopy showed no abnormalities in a cohort of 41 CMI patients.<sup>124</sup> Histopathological examination of gastroduodenal biopsies had no additional value mainly because the abnormalities are minimal and nonspecific.<sup>125</sup>

Measurement of blood flow changes in the mesenteric arteries is not sufficient to prove CMI. The presence or absence of collaterals and variable metabolic demand play a crucial but poorly defined role. It was hypothesised that the cumulative gastrointestinal blood flow, measured in the portal vein (PV) or in the entire hepatic circulation should be diminished after a test meal.<sup>126</sup> One investigation of six patients with severe

multi-vessel CMI suggested that a low basal blood flow, or an increase below 30% after a meal would indicate CMI.<sup>127</sup> Only small case series have been published thereafter, and the technique is rarely used anymore. Measurement of PV blood flow might be a less invasive alternative,<sup>128</sup> but to the GWC's knowledge no subsequent studies have been published.

Measurement of mucosal blood flow combined with oxygen saturation has been used for decades. Recently, an improved technique, visual light spectroscopy, has become available. In the largest published study of 41 CMI patients (diagnosed by a multi-disciplinary team based on evaluation of symptoms, gastrointestinal tonometry, and abdominal CTA or MRA) a sensitivity of 90% and a specificity of 60% were demonstrated.<sup>124</sup> The latter seems insufficiently reliable for patient selection.

Increased luminal PCO<sub>2</sub>, known as tonometry, is indicative of mesenteric ischaemia, irrespective of flow or metabolism. This has been firmly established in various animal models using both occlusive and non-occlusive causes.<sup>129</sup> The luminal PCO<sub>2</sub> can be measured using a nasogastric and nasojejunal catheter attached to a specially designed capnograph (Tonocap<sup>®</sup>) that measures the PCO<sub>2</sub> automatically. This PCO<sub>2</sub> gradient increased only when blood flow was reduced below 50% of the basal flow and then increased sharply.<sup>130,131</sup> The increased CO<sub>2</sub> stems from locally buffered lactic acid in anaerobic metabolism.

Tonometry, either as an exercise test or after standard test meals, has good accuracy for diagnosing CMI.<sup>30,132</sup> The sensitivity and specificity for diagnosing CMI are 76% and 92% for exercise tonometry and 92% and 77% for 24 hours tonometry.<sup>132,133</sup> The drawback of tonometry is that the current technique is complicated, time-consuming, and error-prone. The current manufacturer has stopped production and support of the Tonocap<sup>®</sup>, although catheters are still available, and it is uncertain if other PCO<sub>2</sub> based measurements will become available.

Availability of serological markers for CMI detection could be a major advantage in diagnosis. Most studies of serological markers in mesenteric ischaemia have been performed in AMI or NOMI patients.<sup>49,67,134,135</sup> In a pilot study in 24 CMI patients it was demonstrated that ischaemia was associated with I-FABP increase after meals.<sup>136</sup> No large studies have been published in CMI patients so far, so serology remains an unproven diagnostic tool for the foreseeable future.

Accurate functional testing is urgently required to help diagnose suspected CMI, in particular in one vessel disease. Currently, however, the methodology is not yet

validated and widespread enough to issue any recommendations on its use.

**3.2.3. Treatment.** Revascularisation is indicated in patients who develop symptoms of CMI. There is no role for a conservative approach with long-term chronic parenteral nutrition and non-interventional therapy. In fact, excessive delays in proceeding with definitive revascularisation or use of parenteral nutrition alone have been associated with clinical deterioration, bowel infarction, and risk of sepsis from catheter related complications.<sup>40</sup>

The goals of mesenteric revascularisation include relief of symptoms, improving quality of life, restoration of normal weight, and improving survival by prevention of bowel infarction. Prophylactic revascularisation in patients with asymptomatic disease is controversial and is rarely performed. Based on one report there may be a role for prophylactic revascularisation in patients with severe three vessel disease who have difficult access to medical care or who live in remote or underserved areas.<sup>11</sup> If a conservative approach is taken, these patients need to be closely monitored and counselled regarding symptoms of mesenteric ischaemia. A low threshold is recommended for proceeding with revascularisation if the patient develops any gastrointestinal symptoms such as abdominal bloating, diarrhoea, or atypical pain. Mesenteric revascularisation during other concomitant aortic reconstructions also remains controversial because combined reconstructions have higher morbidity and mortality rates.

The relevance of single vessel mesenteric stenosis is controversial. It has been shown that long-term improvement can be achieved by treatment and therefore the main question is how to select patients who will benefit from treatment. Two reports that have studied this found that clinical history has a low predictive value.<sup>133,137</sup> Comparing the clinical presentation of 109 patients with CMI to 161 patients without ischaemia, only postprandial pain, weight loss, an altered eating pattern, and diarrhoea were of some value. Even when all four symptoms were present, the probability of CMI was only 60%.<sup>137</sup> This emphasises the need for functional tests, especially in patients with single vessel disease.

There is little evidence for either enteral or parenteral feeding of patients with CMI, despite the symptoms of malnutrition and weight loss. Experimentally there is some evidence that enteral nutrition increases intestinal metabolic demand and may contribute to bowel necrosis in cases of impaired mesenteric perfusion.<sup>138</sup> Revascularisation is the mainstay of treatment, following which the patient can resume oral nutrition.

Recommendation 18	Class	Level of evidence	References
In patients with symptomatic CMI caused by multi-vessel occlusive disease, revascularisation is recommended	I	B	11,40,133
<b>Recommendation 19</b>			
In patients with symptomatic single vessel disease, revascularisation may be considered	IIb	B	133,137
<b>Recommendation 20</b>			
In patients with advanced CMI (severe weight loss, diarrhoea, continuous pain), it is not recommended that revascularisation is delayed by attempts to improve the nutritional status	III	C	11,40

CMI = chronic mesenteric ischaemia.

**3.2.4. Treatment strategies.** Revascularisation strategies to treat CMI continue to evolve with rapid development of novel endovascular devices and techniques. During the last decade the number of mesenteric revascularisations has increased tenfold because of increasing recognition and the advent of endovascular therapy, which allows a less invasive treatment alternative.<sup>10</sup> In most centres angioplasty and stenting have become the primary treatment modalities, relegating open surgical bypass to patients who are not candidates or who fail endovascular therapy.<sup>10,139,140</sup> In a recent systematic review endovascular revascularisation

after endovascular revascularisation (OR 0.20, 95% CI 0.17–0.24).<sup>10,142</sup>

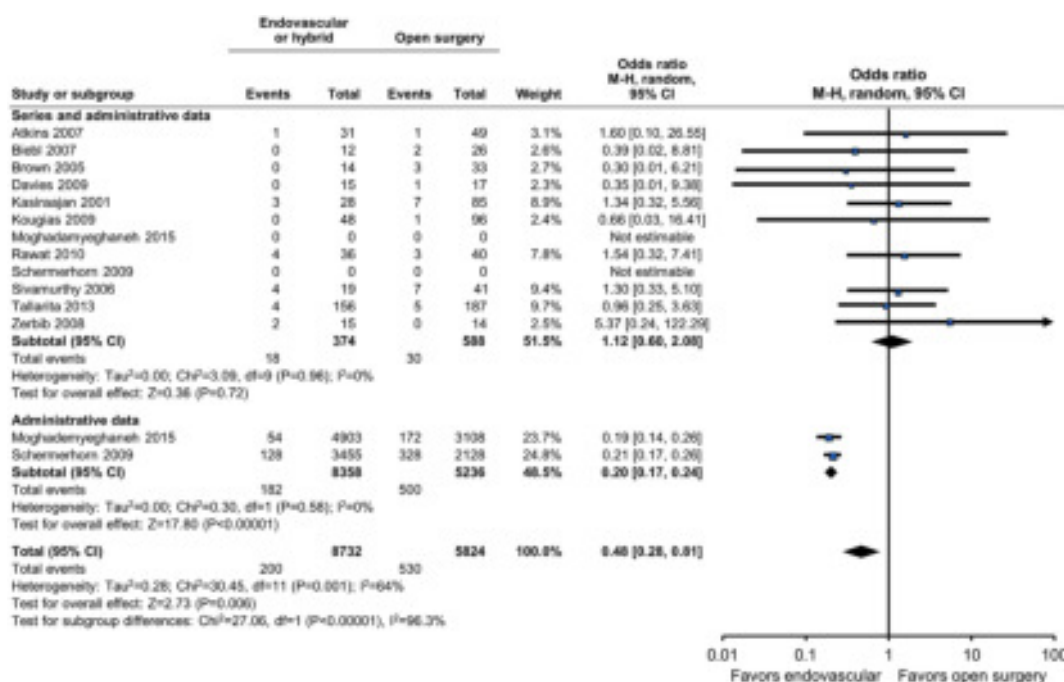
Mesenteric bypass on the other hand, offers improved patency, with lower rates of re-intervention and better freedom from recurrent symptoms. It remains to be proven that endovascular treatment leads to similar long-term patency and clinical improvement.<sup>10,140,141,143–153</sup> Randomised controlled trials (RCTs) are warranted, but are difficult to perform because of small numbers of patients, but if major referral centres could collaborate this would certainly be feasible.

Recommendation 21	Class	Level of evidence	References
In patients with CMI, needing revascularisation, the superior long term results of open surgery must be offset against a possible early benefit of endovascular intervention with regard to peri-procedural mortality and morbidity.	I	B	10,139,141,142

CMI = chronic mesenteric ischaemia.

was demonstrated to have a mortality risk of 6% (range 0–21%).<sup>141</sup> Compared with open surgical bypass, endovascular revascularisation has been associated with decreased morbidity, length of stay, and convalescent time.<sup>139,141</sup> A meta-analysis of mortality following open and endovascular revascularisation has been performed by the GWC (Fig. 5). Although it could be questioned whether an unpublished meta-analysis should be included in a guideline, the GWC thought the issue to be of such great clinical importance that they performed the analysis themselves, using the methodology described in: [www.prisma-statement.org](http://www.prisma-statement.org). In single centre cohorts, from highly specialised centres, no difference in mortality was identified (OR 1.12, 95% CI 0.6–2.08). In administrative data from the Nationwide Inpatient Sample from the USA, however, the mortality was lower

**3.2.5. Endovascular revascularisation.** The SMA is the main primary target for revascularisation, whenever possible. Revascularisation of the CA or IMA has also been performed, particularly when the SMA is chronically occluded and not suitable for recanalisation. The characteristics of the SMA that affect treatment selection include vessel diameter, extent of stenosis or occlusion, presence of tandem lesions, degree of calcification, and the extent of collateralisation.<sup>142–145</sup> Angioplasty and stenting are most effective for relatively short focal SMA stenoses or occlusions with minimal to moderate calcification or thrombus. Endovascular revascularisation also may be possible in patients with longer segment occlusions or excessively calcified vessels.<sup>154,155</sup> For CA lesions, angioplasty and stenting carries a higher rate of restenosis,<sup>156</sup> and should not be performed if



**Figure 5.** Meta-analysis of mortality after open and endovascular revascularisation. (This meta-analysis was performed by the GWC in March 2016, and is only published in this document.)

there is active compression by the median arcuate ligament. CA stenting is an option if the vessel is not compressed or if the median arcuate ligament has been surgically released using a laparoscopic or open technique.

The role of two vessel stenting (of both the CA and the SMA) remains controversial, but most reports indicate that angioplasty and stenting of a single vessel may be sufficient. Two retrospective studies have shown a non-significant trend towards lower recurrence with two vessel stenting,<sup>157,158</sup> and another study showed more frequent long-term success after two vessel repair.<sup>129</sup> On the other hand, another study reported nearly identical recurrence rates at 2 years in patients treated with SMA stents (78%)

occlusions, and long lesions that extend into the mid-segment of the SMA. In these cases, stenting may be possible, but the technical result is not optimal and restenosis or intra-procedural complications can occur.<sup>99,161</sup>

Balloon angioplasty, which was the primary method used in the first reports and in the 1990s, has been largely replaced by primary stenting because of elastic recoil and restenosis, which limits its use for ostial lesions.<sup>151,162–171</sup> Although there are no prospective comparisons between angioplasty alone and primary stenting, most experts agree that routine mesenteric stenting is indicated given that these lesions resemble renal artery stenoses.<sup>101,155–158,172–183</sup> Further data are required on the possible benefits of drug eluting balloons and stents in the mesenteric arteries.

Recommendation 22	Class	Level of evidence	References
In patients requiring revascularisation for CMI, the SMA is the main target vessel using either open or endovascular techniques	I	B	156,171,183
Recommendation 23			
In patients requiring endovascular treatment of CMI, routine mesenteric stenting should be used, as opposed to plain balloon angioplasty	I	C	101,155–158, 172–179,181,182

CMI = chronic mesenteric ischaemia; SMA = superior mesenteric artery.

compared with two vessel stenting of the SMA and CA (60%).<sup>156</sup> Two vessel mesenteric interventions may have a role in selected patients with severe gastric ischaemia who do not have a good collateral network between the CA and SMA. A second intervention adds cost and potential risk of complications, but there are some data indicating that two vessel revascularisation is superior to one vessel revascularisation.<sup>129,145–147</sup> The GWC did not consider the data robust enough, however, to issue a recommendation to support routine two vessel over one vessel revascularisation.

CA intervention may be considered in higher risk patients who have had failed recanalisation of the SMA, or in those in whom an SMA intervention is felt to have a low chance of success because of excessive calcification or long segment

Recanalisation with deliberate sub-intimal angioplasty has also been described,<sup>184</sup> but there are no studies comparing results of this with standard intraluminal angioplasty.

There is some controversy as to whether a bare metal or covered stent should be used to treat SMA stenosis. In a retrospective non-randomised study of 225 patients, covered stents were associated with lower restenosis rates, a lower clinical symptom recurrence rate, and fewer re-interventions when compared with bare metal stents (approximately 10% compared with 50%).<sup>185</sup> An ongoing Dutch multicentre RCT compares bare metal versus covered stents of CA and SMA origin stenosis (NL 46337.078.13). Results are expected in 2017.

Recommendation 24	Class	Level of evidence	References
In patients requiring mesenteric artery stenting, covered stents, as opposed to bare metal stents, may be considered	IIb	C	185

occlusion. In some patients, coeliac stenting may be considered a “bridge” to open bypass or retrograde SMA stenting.<sup>159</sup> Evidence for the efficacy of angioplasty of the IMA is limited, although a case series of four patients with successful results has been reported.<sup>160</sup> The indication for IMA angioplasty remains unclear.

In many centres, an endovascular first approach is used, regardless of the patient’s clinical risk. Anatomical factors that increase the technical difficulty of endovascular procedures include severe eccentric calcification, flush

**3.2.6. Open surgery.** Open surgical bypass has been used primarily in patients who have unfavourable mesenteric lesions, and/or have had a failed percutaneous intervention and/or have recurrent in-stent stenosis/occlusion. A mortality of <3% has been reported for mesenteric bypass performed in large tertiary care centres, although this may be higher in patients who present late with established bowel infarction.<sup>139,145,186</sup> Surgery also may be preferable in patients who have non-atherosclerotic causes such as vasculitis, neurofibromatosis, and mid-aortic syndrome.<sup>187,188</sup>

Recommendation 25	Class	Level of evidence	References
In patients with CMI, open revascularisation should be considered in the following situations: i) In a patient who has failed endovascular therapy or ii) In patients who are not candidates for endovascular intervention because of extensive occlusion and calcification precluding safe angioplasty and stenting or iii) In young patients with complex non-atherosclerotic lesions caused by vasculitis or mid-aortic syndrome	Ila	B	101,151,155–158, 162–181

CMI = chronic mesenteric ischaemia.

### 3.2.6.1. Pre-operative evaluation prior to open surgery.

Pre-operative evaluation should assess surgical risk, nutritional status, and anatomical factors that affect the choice of reconstruction. A comprehensive evaluation of cardiac, pulmonary, and renal function is needed, because these procedures are usually required in patients who have multiple comorbidities. This should not delay treatment in patients requiring urgent revascularisation. Routine cardiac catheterisation is unnecessary and cardiac evaluation and peri-operative management are guided by the recommendations of the European Society of Cardiology for patients undergoing major non-cardiac surgery.<sup>189</sup> Although nutritional status and smoking cessation are important, time is most important, and revascularisation must not be delayed.

**3.2.7. Open surgical techniques.** Planning open surgical reconstruction of the mesenteric arteries involves selection of the type of incision (transperitoneal vs. retroperitoneal), conduit (vein vs. prosthetic), graft configuration (antegrade vs. retrograde), source of inflow (aortic vs. iliac), and the number of vessels to be reconstructed (single vs. multiple). The type of open reconstruction should be tailored to the anatomy and to the patient's clinical risk assessment.<sup>140</sup> Patients with less physiological reserve because of advanced age, cachexia, or severe cardiac, pulmonary, and renal dysfunction are not good candidates for supra-coeliac aortic reconstructions, but may be better suited to extra-anatomical reconstructions based on the infrarenal aorta or iliac artery. Alternatively, the technique of retrograde open mesenteric stenting (ROMS) has been used with surgical exposure of the SMA and introduction of the stent retrogradely via direct puncture.<sup>96,190,191</sup> In the largest series published so far, successful ROMS was reported in 14 of 15 cases, with high secondary patency rates.<sup>97</sup>

**3.2.7.1. Antegrade bypass.** The distal thoracic or supra-coeliac aorta is often selected as the inflow source if it is spared from severe atherosclerotic disease. The graft configuration may offer a potential haemodynamic advantage, while avoiding the potential risk of graft kinking that can occur with retrograde grafts.<sup>192</sup> In most reports, two vessel reconstruction of the CA and the SMA is done using a bifurcated polyethylene terephthalate (e.g. Dacron®) graft.<sup>139,186</sup>

**3.2.7.2. Retrograde bypass.** A retrograde bypass based on the infrarenal aorta, a previous aortic graft, or the iliac arteries may be preferred if the supra-coeliac aorta is diseased or the patient has compromised cardiac or pulmonary function. Most retrograde reconstructions deal with a single vessel, typically the SMA, but reconstruction of the CA or common hepatic artery can also be achieved by tunnelling the graft retroperitoneally or via the transverse mesocolon. The anastomotic site of the graft is determined by the lack of significant calcification. It can be in the distal aorta or the iliac arteries, which has the advantage of avoiding cross-clamping the aorta. As the graft assumes a C-shaped configuration, it is important to avoid graft elongation, angulation, or kinking. It is also important to cover the graft with an omental flap to avoid contact with the intestines. Reports suggest that retrograde grafts perform as well as antegrade grafts.<sup>139,186</sup>

**3.2.7.3. Retrograde open mesenteric stenting.** The ROMS technique uses a hybrid approach via a midline laparotomy to expose the SMA or CA combined with endovascular retrograde stenting.<sup>96,190</sup> ROMS is an alternative if percutaneous stenting via the aorta fails. It avoids the need for extensive dissection, vein harvesting, and use of a prosthetic graft, and may be ideal in patients with extensive aorto-iliac disease and no good inflow source, or in those with bowel gangrene and contamination.

The SMA is dissected out below the pancreas and any jejunal branches are controlled prior to catheter manipulations. Retrograde access is established with a guidewire and sheath. The narrowed or occluded vessel is treated by angioplasty and stenting, most often using a balloon expandable stent. It can sometimes be easier to snare the guidewire in the aorta, and then work from the groin or the arm rather than from the abdomen. The puncture site is closed with interrupted sutures or opened longitudinally and closed with a patch if severely diseased. Re-entry into the aorta can sometimes be difficult with this technique, and there is a risk of causing an aortic dissection.

**3.2.7.4. Endarterectomy.** Trans-aortic endarterectomy is now rarely used, but can be considered in patients that have bacterial contamination or perforated bowel, previous abdominal irradiation, extensive abdominal wall hernias, or other hostile conditions. A recent publication reported an operative mortality of 3.8% among 80 patients treated by trans-aortic endarterectomy.<sup>193</sup> The mean follow-up was 3.8

years (range 0–17 years). The 1- and 5 year survival was 92.2% and 64.5%, respectively. Symptoms requiring re-intervention occurred in nine (11%) patients at a mean of 29 months. Direct mesenteric endarterectomy, with or without stenting of proximal disease, is an alternative in some cases.

revascularisation ( $p=.51$ ). The 10-year secondary patency was 92% for complete and 93% for incomplete revascularisation ( $p=.63$ ). Freedom from gastrointestinal symptoms was influenced by the completeness of revascularisation: 79% for complete versus 65% for incomplete revascularisation at 10 years ( $p=.04$ ).

Recommendation 26	Class	Level of evidence	References
In patients needing mesenteric revascularisation, ROMS should be considered when trans-aortic stenting and open reconstruction are impossible	Ila	C	139,186,194

ROMS = retrograde open mesenteric stenting.

### 3.3. Results and follow-up

Most publications on the treatment of CMI report 30 day and in hospital outcomes. Those studies that report longer follow-up often have incomplete data and therefore the long-term outcome of mesenteric revascularisation is difficult to assess. Some studies report outcomes until 5 years after treatment, but there is little information beyond this time period.

A review<sup>144</sup> of eight studies ( $n=247$ ) comparing open versus endovascular revascularisation for CMI identified a higher technical success rate for open compared with endovascular intervention, but for the latter this improved with time. The rate of early post-operative symptom relief (five studies) was higher for open versus endovascular revascularisation, but significantly higher in only two studies (71% vs. 33%,  $p=.01$  and 100% vs. 79%,  $p=.03$ ). The rate of late symptom relief (seven studies, follow-up 1–3 years) was also higher for open versus endovascular revascularisation, and significantly higher in five studies (range 59–100% for open revascularisation and 22–75% for endovascular revascularisation;  $p=.0004$  to  $p=.02$ ). There was no significant difference in the 30-day mortality rates. Rates of medium-term restenosis (five studies) and re-intervention (four studies) were reported to be significantly lower for open revascularisation. Primary graft patency was higher for open revascularisation at 6 months (one study), 1 year (one study, 90% vs. 58%,  $p<.001$ ), and 2 years (one study). Secondary graft patency was higher for open revascularisation at 2 years (two studies; 87% vs. 69%,  $p=.003$  and 100% vs. 65%,  $p=.006$ ) and 3 years (one study).

In a retrospective study of 86 open revascularisation procedures performed for CMI, primary outcomes were 30 day mortality and morbidity, and secondary outcomes were survival, primary patency (PP), secondary patency, and freedom from digestive symptoms, depending on the completeness of the revascularisation performed.<sup>181</sup> Median follow-up was 6.9 years (range 0.3–20.0). The 30 day mortality and morbidity rates were, respectively, 3.5% and 13.9%. Ten year survival was 88% for complete and 76% for incomplete revascularisation ( $p=.54$ ). The PP was 84% at 10 years for complete and 87% for incomplete

The possible benefits of imaging follow-up after mesenteric revascularisation are unknown. If routine imaging (US/CTA/MRA) is performed it is also unknown what management would be recommended if an asymptomatic restenosis was found. In a study of 157 patients treated for CMI by mesenteric artery angioplasty and stenting, 57 patients (36%) developed a restenosis after a mean follow-up of 29 months.<sup>90</sup> Thirty patients underwent treatment, 24 of whom presented with recurrent symptoms and six had pre-occlusive lesions. Mesenteric re-interventions were associated with a low mortality (3%), a high complication rate (27%) (e.g. access site problems, bowel ischaemia, congestive cardiac failure, and stent thrombosis) and excellent symptom improvement (92%). In another report on 24 patients who underwent SMA stenting for CMI and who were followed with DUS, eight re-interventions were performed.

It follows from examining the data in these and other studies that the main reason to follow patients up after mesenteric revascularisation is to assess restenosis of an angioplasty or stented site or to identify a stenosed or occluded surgical graft. The majority of cases who proceed to treatment in this situation, however, are patients who have recurrent symptoms following previous treatment. There is little evidence therefore to indicate that routine follow-up, either clinically, or with some modality of vascular imaging is of benefit. The European Society of Cardiology guidelines on the treatment of peripheral arterial diseases recommend duplex ultrasound every 6–12 months but again there is no evidence to support this.<sup>195</sup> When deciding on follow-up (clinical and/or with imaging) the value not only for the patient, but also the competence of the multidisciplinary team investigating and treating patients with CMI, must be considered.<sup>196</sup>

In general, there is evidence from patients with atherosclerosis that antiplatelet therapy is beneficial, particularly in preventing cardiac events and stroke. It is unclear currently whether dual antiplatelet therapy confers any additional benefit to prevent restenosis after mesenteric revascularisation, compared with single antiplatelet therapy.

Recommendation 27	Class	Level of evidence	References
In patients after revascularisation for CMI, repeated follow-up by clinical assessment to detect symptomatic restenosis might be considered	IIb	C	99,196
<b>Recommendation 28</b>			
In patients after revascularisation for CMI, repeated long-term follow-up by imaging to detect asymptomatic restenosis might be considered	IIb	C	99,196
<b>Recommendation 29</b>			
In patients after revascularisation for CMI, antiplatelet therapy is recommended	I	A	195
<b>Recommendation 30</b>			
In patients after endovascular revascularisation for CMI, dual antiplatelet therapy might be considered for 3–12 months	IIb	C	183

CMI = chronic mesenteric ischaemia.

CMI is an uncommon condition requiring an integrated team approach. Diagnosis, selecting patients for revascularisation, and being able to offer different treatment options (both open and endovascular surgery) requires a team of dedicated and experienced specialists.<sup>197,198</sup> This background explains the last recommendation of this chapter.

*the mesenteric arteries being patent. It is caused by either mesenteric vasoconstriction secondary to conditions such as heart failure, vasoconstrictive medication, and hypovolaemia or by increased intra-abdominal pressure."*

The subgroup of patients who have an underlying arterial stenosis is an important one, as it affects both diagnosis and

Recommendation 31	Class	Level of evidence	References
Patients with CMI should preferably be investigated and treated at specialised centres that can offer a multidisciplinary assessment, as well as both open and endovascular treatment	I	C	197,198

CMI = chronic mesenteric ischaemia.

## 4. ARTERIAL ISCHAEMIA, NON-OCCLUSIVE MESENTERIC ISCHAEMIA

### 4.1. Background and definition

Acute and chronic arterial occlusions leading to mesenteric ischaemia have been discussed in the previous chapters. Arterial occlusion is not always necessary to produce intestinal gangrene. Ischaemia develops when the oxygen supply to the intestines is insufficient to meet metabolic needs. The term NOMI was first suggested by Ende in 1958.<sup>199</sup> In the critically ill patient, often having a low CO, multiple interventions are performed to save the patient's life.<sup>31</sup> In this situation the intestinal circulation may be compromised, sometimes as a side effect of resuscitation causing vasoconstriction of the mesenteric circulation, or caused by an ACS.<sup>200</sup>

Although the definition may seem rather straightforward, that is there is no occlusion of the mesenteric arteries, it is not easy to define NOMI. The main mechanism underlying NOMI is mesenteric vasoconstriction in response to reduced effective blood volume.<sup>201</sup> NOMI can develop in a patient with asymptomatic mesenteric atherosclerosis, for example when circulatory shock develops in the presence of mesenteric stenosis. This combination may change a previously asymptomatic stenosis of a mesenteric artery into life threatening mesenteric ischaemia if hypotension, hypovolaemia, or ACS develops. It is suggested therefore that NOMI is defined in the following way:

*"NOMI is defined as a hypoperfusion syndrome that occurs when severe ischaemia of the intestines develops, despite*

treatment, to be discussed below. There are a number of clinical scenarios in which NOMI can develop, and the most common are the following:

- The patient with severe cardiac failure, needing massive inotropic support or an intra-aortic balloon pump device to survive. Even compensated patients with cardiac failure have been shown to have mild NOMI.<sup>202</sup>
- In the post-operative period after cardiac surgery.
- Intestinal hypoperfusion following renal replacement therapy or massive burn injury, in both situations associated with hypovolemia.
- Patients with ACS, in particular after massive bleeding, with or without trauma.
- Intestinal hypoperfusion following aortic dissection type A or B.
- Colonic ischaemia following AAA repair.
- Patients with severe sepsis.

According to the recently published *Management of Descending Thoracic Aorta Diseases Clinical Practice Guidelines (of the ESVS)*, the risk of developing visceral ischaemia after type B aortic dissection (TBAD) is approximately 7%.<sup>203</sup> That may develop either as systemic hypoperfusion secondary to compression of the true lumen, or as a specific malperfusion of the mesenteric arteries. According to the International Registry of Aortic Dissection, visceral ischaemia is the third most common cause of death in patients with TBAD (after aortic rupture and tamponade).<sup>204</sup> Given this background, the mentioned guidelines



recommend that patients with acute TBAD who develop new or recurrent abdominal pain and, where there is suspicion of visceral, renal, and/or limb malperfusion, should undergo repeat CTA (Class I, Level C).<sup>203</sup> Those guidelines give general recommendations regarding prevention and treatment of malperfusion, and thus are not included in these mesenteric Guidelines.

Colonic ischaemia is an important complication of AAA repair. The main risk factors are rupture, massive bleeding, and intra-abdominal hypertension or ACS.<sup>31,142,205</sup> Although this complication was not covered by the ESVS AAA clinical practice guidelines published in 2011,<sup>206</sup> it will be covered by the revised AAA guidelines to be published in 2018. No recommendations are issued on this condition in this document.

These Guidelines will not discuss further the NOMI associated with severe sepsis, but refer to guidelines focused on intensive care (there are several). There are multiple case reports on the association between use of cocaine or crack cocaine and intestinal ischaemia, affecting different parts of the gastrointestinal tract. It is unclear, however, if this is an occlusive or non-occlusive mechanism, as thrombosis of the SMA has been observed in some cases.

A special situation occurs if a mesenteric vessel is occluded or stenosed (most often the IMA, but also the SMA or CA) without resulting in any symptoms before the patient develops hypovolaemia and/or hypotension. Is that to be defined as occlusive or non-occlusive disease? This is not crystal clear, and is a grey zone of uncertainty similar to that of acute on chronic mesenteric ischaemia, AMI or CMI?

#### 4.2. Diagnosis

In all the clinical scenarios discussed (a–d above), the key to diagnosis is clinical suspicion and knowledge that these groups of patients are at risk of mesenteric ischaemia. An observational study from 43 ICUs in France, over a period of 5 years aimed to determine risk factors for death in patients with AMI.<sup>194</sup> They confirmed AMI in 780 patients, diagnosed by CTA in 58% and at surgery in 27%. Unfortunately, they did not report separately for AMI and NOMI. The

Another investigation attempted to identify risk factors for developing NOMI after cardiac surgery in a prospective study of 865 patients, among whom 78 (9%) developed NOMI.<sup>207</sup> Diagnosis was verified by angiography in all patients with suspected NOMI. Renal insufficiency and age >70 years were pre-operative risk factors, but the odds ratios were greater for the following post-operative risk factors: intra-aortic balloon pump support and serum lactate >5 mmol/L. They also tested endothelin-1 levels in a case controlled study nested in this cohort, using propensity score analysis to identify the controls.<sup>208</sup> Patients with NOMI had higher levels of endothelin-1, both pre- and post-operatively (the probability of developing NOMI increased with each picogram/mL of endothelin-1: odds ratio pre-operatively 1.29, post-operatively 2.04). Whether or not this is useful as a diagnostic test, and if so, which threshold value gives the optimal sensitivity and specificity, remains to be determined. The proportion of patients developing NOMI after cardiac surgery in this series (9%) was quite high compared with other reports,<sup>208</sup> for example one study reported 23 cases of NOMI in a cohort of 3600 consecutive patients (0.64%).<sup>209</sup> Whether this more than 10 times higher incidence of NOMI reflects a higher diagnostic activity, or a selected patient cohort or both, remains unclear.

As already discussed in chapter 2 on AMI, the only sensitive (but highly nonspecific) biomarker for intestinal ischaemia is D-dimer, which is effective as an exclusion test in this situation.<sup>44–48</sup> After surgery D-dimer is not a useful biomarker for intestinal ischaemia as all patients have elevated D-dimer post surgery. Although Leone et al. showed that high lactate levels are predictive of death after AMI in ICU patients, this does not imply that the test is a reliable diagnostic test.<sup>210</sup> Lactate is very effectively metabolised during its first passage through the liver, resulting in it not serving as an early marker of intestinal ischaemia. In conclusion there are no reliable biomarkers for intestinal ischaemia secondary to NOMI in the aforementioned clinical scenarios, and therefore no recommendations can be made.

Recommendation 32	Class	Level of evidence	References
In patients suspected of having NOMI, clinical suspicion should be considered the mainstay of diagnosis	IIa	C	206–208,210
<b>Recommendation 33</b>			
In patients suspected of having NOMI, use of biomarkers to diagnose or rule out the condition is not recommended	III	C	206–208,210

NOMI = non-occlusive mesenteric ischaemia.

mortality was 58%. Increasing age, having a higher Sequential Organ Failure Assessment severity score, and a plasma lactate concentration >2.7 mmol/L at diagnosis were independent risk factors of ICU mortality. In contrast, having a prior history of peripheral vascular disease or an initial surgical treatment were independent protective factors against ICU mortality. This latter observation is probably explained by a higher grade of suspicion, improving the chance of an earlier diagnosis.

#### 4.3. The role of imaging

Diagnosing intestinal ischaemia with DUS is dependent on verifying a high PSV, which is unlikely during NOMI. Even a significant stenosis where the mesenteric arteries originate from the aorta will not result in a high PSV, because of the low flow situation. Standard CTA or MRA also fail to reliably diagnose NOMI, as they lack the necessary flow dynamics. Multi-detector computed tomography in 38 patients who

underwent laparotomy for suspected NOMI were analysed retrospectively by three independent radiologists.<sup>211</sup> The sensitivity and specificity were 96% and 33–60%, respectively, and the inter-observer agreement was 68%, which are not acceptable figures for a diagnostic test. Another investigation compared the diameter of the SMA with multi-planar reconstruction of CTA images between four cases with NOMI and 13 controls, and found that the diameter of the SMA was significantly smaller among the NOMI patients.<sup>212</sup> Nakamura et al. compared the diameter of the SMA and the SMV, measured on CTA in 11 patients with NOMI and 44 controls.<sup>213</sup> The diameters of both the SMA and the SMV were smaller in NOMI patients, but the difference was greater when the diameters of the SMV were compared. Whether these observations can develop into criteria that can be useful in diagnosing NOMI remains to be seen.

DSA, although invasive, remains the only method available to verify a clinical suspicion of NOMI. To objectively assess the angiographic findings and correlate them with the presence of NOMI, one study analysed images from 63 consecutive patients who underwent DSA for suspected NOMI after previous cardiac or major thoracic vessel surgery.<sup>214</sup> Vessel morphology and reflux of contrast into the aorta correlated with death, and reflux of contrast also correlated with lactate levels, suggesting that extensive bowel gangrene had already developed in these cases. Delayed PV filling did not correlate with death.

In their primary description of mesenteric vasospasm in 1974, Siegelman et al.<sup>215</sup> suggested four radiological signs for the diagnosis of mesenteric vasospasm: 1) Narrowing of the origins of multiple branches of the SMA. 2) Alternate dilatation and narrowing of the intestinal branches (sometimes referred to as “the string of sausages sign”). 3) Spasm of the mesenteric arcades. 4) Impaired filling of intramural vessels.<sup>215</sup> Reflux of contrast into the abdominal aorta has also been regarded as a sign of NOMI.<sup>216</sup>

This is a consequence of IMA either being occluded prior to surgery, or sacrificed during surgery. In a study of 63 patients suffering intestinal ischaemia after open aortic repair, the left colon was affected in 89%.<sup>217</sup>

When colonic infarction occurs as a consequence of classical NOMI, the right colon is more often affected. One study reported 23 patients who developed colonic ischaemia within 3 days of myocardial infarction, representing 0.13% of a larger cohort of 17,500 patients with myocardial infarction.<sup>218</sup> The main risk factor was hypotension. Another investigation identified 58 patients with right sided colonic gangrene and concluded that in this subgroup 54% had some degree of mesenteric atherosclerosis present on radiological examination.<sup>219</sup> In one study focusing on fatal isolated colonic ischaemia identified at autopsy, 53 patients were identified.<sup>220</sup> In this study the left colon was most commonly affected, but the caecum was affected in 25%, and the ascending colon in 26%.

Among patients who develop NOMI during renal replacement therapy (RRT) the right colon is often affected.<sup>221</sup> Hypotensive episodes are always reported, and diabetes, hypertension, and high dose recombinant human erythropoietin therapy also have been reported as risk factors.<sup>221,222</sup> Among patients who develop bowel gangrene after severe thermal injury, NOMI is the main aetiology. In one study of thermal injury, 17 patients developed intestinal infarction, 82% of these had NOMI, and the remainder had an embolic aetiology.<sup>210</sup> The total body surface area burned was 48% in the NOMI group and 20% in the embolic group.<sup>223</sup> Those with emboli were much older and had 100% mortality.

If NOMI is difficult to diagnose in most cases, this is not true for the hypoperfusion situation that develops secondary to intra-abdominal hypertension (IAH) and ACS. The consensus definitions and clinical practice guidelines from the World Society of the Abdominal Compartment Syndrome (WSACS) were updated in 2013, based on a systematic review of the literature.<sup>200</sup> It has been shown in

Recommendation 34	Class	Level of evidence	References
In patients suspected of having NOMI, DSA should be considered the most reliable method to verify the diagnosis	Ila	C	44–47,215,216

NOMI = non-occlusive mesenteric ischaemia; DSA = digital subtraction angiography.

Although laparotomy is useful in diagnosing the extent of bowel injury, it cannot distinguish between occlusive disease and NOMI.

An interesting subgroup of patients are those who develop isolated colonic ischaemia. When colonic ischaemia (often erroneously labelled “ischaemic colitis” because of the inflammation that is secondary to the ischaemia) develops after AAA surgery, the left colon is typically affected.

multiple studies that IAH results in bowel ischaemia,<sup>205,224</sup> and, according to the WSACS guidelines, an intra-abdominal pressure (IAP) above 12 mmHg negatively affects bowel perfusion.<sup>225</sup> NOMI secondary to IAH/ACS can result in multi-organ failure, bowel gangrene, and death.<sup>211</sup> IAP should be measured routinely in patients with risk of developing IAH/ACS, followed by action according to a predefined protocol if IAH develops.

Recommendation 35	Class	Level of evidence	References
In patients with known risk factors for IAH/ACS, a protocol for monitoring of IAP is recommended to prevent NOMI	I	B	200,205,224

IAH = intra-abdominal hypertension; ACS = abdominal compartment syndrome; IAP = intra-abdominal pressure; NOMI = non-occlusive mesenteric ischaemia.

#### 4.4. Treatment

Treatment starts with prevention, and this is supported by studies that have examined NOMI occurring after cardiac surgery. One report analysed 10,409 patients who underwent cardiac surgery, 30 of whom developed NOMI (0.3%) to identify intra-operative factors that predicted this complication.<sup>226</sup> The most powerful association was with

undergone massive resuscitation for shock, heart failure, sepsis, major haemorrhage, etc, as the burden of IAH/ACS is added to the hypoperfusion episode that the patient has already experienced from the underlying condition. In patients with ACS, decompression laparotomy has been shown to effectively reduce IAP, and to improve oxygenation and urinary output.<sup>227</sup>

Recommendation 36	Class	Level of evidence	References
In patients suspected of having NOMI, stenoses of the mesenteric arteries should be identified and treated	I	C	41,214

NOMI = non-occlusive mesenteric ischaemia.

Recommendation 37	Class	Level of evidence	References
Patients with IAP above 12 mmHg should be treated medically to prevent ACS and NOMI	I	B	200,205,219
Recommendation 38			
In patients with ACS (defined as an IAP >20 mmHg and newly developed organ dysfunction or failure), decompression laparotomy should be performed to prevent NOMI	I	B	200,227

IAP = intra-abdominal pressure; ACS = abdominal compartment syndrome; NOMI = non-occlusive mesenteric ischaemia.

intra-operative use of vasopressors, and with the lowest documented intra-operative mean arterial pressure. Whether it was the hypotension per se, or its treatment with vasopressors, or maybe both, that created NOMI is impossible to conclude from this study.

In a population based study on fatal NOMI from Scandinavia the autopsy rate was 87%.<sup>41</sup> They reported an important finding that in 62 patients identified at autopsy with non-occluded vessels, 25 (40%) had a significant narrowing of the SMA that was potentially treatable by stenting. Those with a stenosis were older and more often had a concomitant stenosis of the CA. This observation has an implication for potential treatment. It has also been shown that patients on RRT often have calcification of the mesenteric arteries,<sup>222</sup> making them vulnerable to hypotension. As already discussed, this patient group having a stenosis of one or more of the mesenteric arteries, and suffering from hypotension and/or hypovolaemia, could both be labelled NOMI and acute on chronic mesenteric ischaemia.

If patients have IAH, or have developed an ACS, a proactive approach to reduce IAP with medical treatment, followed by decompression laparotomy when indicated, may be life saving. This is particularly true if the patient has

Of nine patients with NOMI treated with intravenous high dose prostaglandin E1, only one patient died.<sup>228</sup> The diagnostic criteria this group used were different, however, and they may have included patients with other conditions. Traditional therapy consists of intra-arterial administration of vasodilators, such as papaverine, nitroglycerine, prostaglandin E1, or glucagon.<sup>216,229</sup> Usually a bolus dose of papaverine, for example 80 mg, is given intra-arterially (directly into the SMA) followed by a continuous infusion, for example 30–60 mg papaverine/hour, for 24–72 hours. There are no contemporary or comparative studies evaluating different vasodilators, dosages, or regimens, making it impossible to issue precise recommendations in this respect.

Because of the loss of mucosal integrity, most authors suggest antibiotic treatment and animal experiments support that regimen, and other authors suggest anticoagulation, on similar grounds. No controlled studies exist comparing different pharmacological agents. It must be recognised that there is a risk of sudden death because of generalised hypotension when vasodilators are administered into the mesenteric circulation, but there is often no other option to save the patient's life.

Recommendation 39	Class	Level of evidence	References
Patients with life threatening NOMI should be taken to an operating room with the capacity for open and endovascular surgery, where angiography, with stenting in the case of a stenosis, and/or intra-arterial administration of vasodilators and/or laparotomy for bowel resection can be performed	I	C	216,229

NOMI = non-occlusive mesenteric ischaemia.

## 5. VENOUS MESENTERIC ISCHAEMIA

### 5.1. Introduction

Venous disorders are unusual causes of mesenteric ischaemia that can occur with obstruction of the superior and inferior mesenteric veins, the splenic (SV) and portal veins (PV). Recovery following resection of infarcted intestine secondary to mesenteric vein occlusion was first reported by Elliot in 1895,<sup>230</sup> and was then recognised as an entity distinct from mesenteric arterial occlusion by Warren and Eberhard in 1935.<sup>231</sup>

In most cases the venous occlusion creating mesenteric ischaemia is secondary to MVT. The common definition of MVT has been referred to as a single entity as the thrombosis within the SMV *with or without* extension into the PV or SV.<sup>225</sup> The concomitant involvement of more than one venous segment is frequent, the most common veins involved being the portal and superior mesenteric, followed by the splenic and inferior mesenteric veins.<sup>232–235</sup> These will be the focus of these current Guidelines to provide clinicians with approaches to diagnose and manage the disorders for which there are sufficient data to make recommendations. Budd-Chiari Syndrome with or without liver cirrhosis, isolated PV thrombosis, isolated outflow obstruction caused by hepatic veno-occlusive (sinusoidal obstruction) disease, or hepatic disorders associated with congestive heart failure or chemotherapy are not included in these Guidelines.

### 5.2. Diagnosis

Diagnosis of mesenteric ischaemia from venous diseases requires risk factor investigation, clinical assessment, laboratory testing, and imaging. The management of the patient with a truly asymptomatic MVT, where the finding is incidental, is not covered by these Guidelines, and the reader is referred to Guidelines on management of venous thrombosis.

### 5.3. Risk factors

“Mesenteric vein thrombosis” or “portal vein thrombosis” rather than “obstruction” is the term generally adopted. It should be noted, however, that as for any thromboembolic venous disease, there are three possible causes for the condition: pro-thrombotic states, local vessel wall injury, and venous stasis (also known as Virchow’s triad).

Most obstructions in mesenteric veins can be considered as “secondary”,<sup>6,14,225,234–236</sup> because of the presence of one or more predisposing conditions, either local or systemic, favouring venous obstruction as shown in Table 4. A thorough investigation can actually identify one or more systemic pro-thrombotic factors in approximately 60–70% of patients with MVT, and further local triggering factors in as many as 30–40% of cases.<sup>232,234,237</sup> On the other hand, currently available investigations fail to identify a causal factor in about 20% of patients.<sup>232,236</sup> This may suggest the existence of other, still unidentified, pro-thrombotic risk factors. When the underlying aetiology cannot be identified, MVT is labelled “primary” or “idiopathic”. Although

spontaneous, idiopathic thrombosis of the mesenteric veins, not associated with any other disease or aetiological factor, may account for 21–49% of the cases, the rates depend on how well those factors were investigated.<sup>6,13,14,232,235–238</sup>

Vein obstruction may originate in the peripheral or in the major central mesenteric veins. The latter is usually associated with PVT, whereas the former is more likely to present as isolated MVT.<sup>12,236</sup>

Reports on the risk factors associated with mesenteric vein ischaemia were mostly anecdotal until recently, when an autopsy series and a population based study were published.<sup>239,240</sup> The autopsy series showed the presence of abdominal cancer in 22% of cases and liver cirrhosis in 17%.<sup>239</sup> The population based study showed thrombophilia markers in 67%, a local factor (surgery or inflammation) in 25%, cancer in 24%, and use of oral contraceptives in 6% of patients with evidence of intestinal infarction.<sup>240</sup> Of note, these percentages relate to the worst category of patients with venous mesenteric ischaemia (i.e. showing transmural intestinal gangrene). Imaging studies (CTA) in the Swiss Inflammatory Bowel Disease Cohort Study showed a high prevalence (26.8%) of MVT among patients with inflammatory bowel disease.<sup>241</sup> The relative incidence of risk factors vary according to the location of the thrombosis, that is whether the mesenteric, portal, and/or hepatic veins are involved.<sup>234</sup>

Among all risk factors, pro-thrombotic conditions are the most common causes in patients with isolated mesenteric venous obstruction. Specifically, malignancies including myeloproliferative neoplasms are the main form of pro-thrombotic disorders associated with venous mesenteric obstruction.<sup>13,14,233,234,236</sup> In contrast, local causes may be more frequently associated with combined mesenteric and portal venous obstruction. Malignant tumours within the portal venous territory and cirrhosis are the leading local risk factors.<sup>12,236</sup> In isolated SV thrombosis, pancreatic cancer and acute pancreatitis are the most common risk factors (30–40%) followed by splenectomy.<sup>234</sup>

This malignancy associated pro-thrombotic state may play a role in venous thrombosis developing in patients with malignant abdominal tumours in the absence of compression or invasion. Likewise, systemic inflammatory response is a major general risk factor for thrombosis. It is difficult to determine whether inflammation is a cause or consequence of MVT, however.

Inherited or acquired pro-thrombotic conditions have been found in many patients with MVT, whether or not a local risk factor was identified. Inherited thrombophilia has been identified in 36–55%<sup>234,238,239</sup> of patients with MVT. Although Factor V Leiden mutation is a genetic defect, peripheral venous thrombotic manifestations are often delayed until adulthood. In a study from Scandinavia, the prevalence of Factor V Leiden mutation (activated protein C resistance) in patients with MVT was 45%,<sup>225</sup> higher than the prevalence of 7% in the background population.<sup>242</sup>

**Table 4.** Risk factors in mesenteric and portal vein ischaemia in adults.

	Risk factors	Notes <sup>a</sup>
Local factors causing wall injury	Cancer, any abdominal organ: pancreatic (hepatic vein, portal vein) hepatic (portal vein) colonic (superior mesenteric vein)	Prevalence 13–24%
	Abdominal Inflammatory focal lesions: - Pancreatitis - Inflammatory bowel disease - Appendicitis/peritonitis	Prevalence 7–34% Often in the settings of pre-existent thrombophilia
	Post-surgical trauma: - splenectomy, injury of portal vein, cholecystectomy, gastrectomy, surgical portosystemic shunt, transjugular intrahepatic portosystemic shunting, liver transplantation	Prevalence 3–45% Often in the settings of pre-existent thrombophilia
Venous stasis	Abdominal trauma (blunt and penetrating)	Prevalence 1–3%
	Portal hypertension	Preserved liver function with precipitating factors. Or advanced disease in the absence of evident precipitating factors
	Congestive heart failure	
	Cirrhosis of the liver	
	Increased abdominal pressure; abdominal compartment syndrome	
	Hypersplenism	
	Obesity	
Pregnancy		
Acquired thrombophilia	Haematological conditions: Polycythaemia Myelofibrosis Thrombocythaemia	Prevalence in myeloproliferative neoplasms: 17–53%
	JAK2 gene sequence variation	Prevalence 27–100%
	Antiphospholipid antibodies	Prevalence 1–11%
Acquired thrombophilia	Paroxysmal nocturnal haemoglobinuria (PNH)	Prevalence 0–9%. Often in Budd-Chiari syndrome
	Non-haematological conditions: Any malignancy related	
	Oral contraceptive	Prevalence 0–4%
	Post-pregnancy	Prevalence 2–44%
	Hyperhomocysteinemia	Prevalence 9–19%
	Others: Nephrotic syndrome, Cytomegalovirus infection	
Inherited thrombophilia	Prothrombin gene mutation G20210A	Prevalence 2–22%
	Factor V Leiden	Prevalence 3–45%
	Protein C deficiency	Prevalence 1–9%
	Protein S deficiency	Prevalence 0–7%
	Antithrombin deficiency	Prevalence 1–4%
	Increased Factor VIII	Inherited or acquired

<sup>a</sup> According to multiple reviews.<sup>232,233,237,239</sup>

MVT is a common first clinical manifestation of patients with newly diagnosed myeloproliferative disorders such as *polycythemia vera* or essential thrombocytosis, and often occurs before a rise in peripheral blood counts. The JAK2 mutation is diagnostic of myeloproliferative disorders, and appears to be important in the development of MVT, and was found in 21–37% of patients with MVT.<sup>232,237,243–246</sup>

A meta-analysis reported a prevalence of JAK2 mutation of 33% (95% CI 26–36%) in patients with diagnosed MVT, compared with a prevalence of about 1% in patients with venous thromboembolism in other sites, and found a strong association between JAK2 mutation and the

development of MVT (OR 54; 95% CI 13–222). Moreover, 52% (95% CI 38–67%) of patients with MVT and JAK2 mutation were diagnosed with an unknown myeloproliferative disease during the follow-up period, and thereby the MVT was the first finding of the underlying predisposing condition.<sup>246</sup> These results may suggest it is important to screen for JAK2 V617F mutation in patients with MVT without evidence of other major systemic or local risk factors.

In many patients more than one factor shown in Table 4 may account for the MVT. Identification of a local risk factor does not exclude the possibility of systemic risk factors.<sup>247,248</sup>

#### 5.4. Laboratory testing

Laboratory investigation includes a full blood count, differential white cell count, and a peripheral blood smear. Other laboratory testing is usually not helpful in the diagnosis of either venous ischaemia or other types of mesenteric ischaemia. Serum lactate levels often are not associated with intestinal infarction initially; and by the time lactic acidosis is present it is late in the course of the illness and, at that point the mortality rate is already 75%. Leukocytosis and haemoconcentration are common findings,<sup>236</sup> but there are no specific plasma biomarkers of MVT. An elevated D-dimer level may be a sensitive but nonspecific serum marker.<sup>239</sup>

Cohort studies identified a high prevalence of pro-thrombotic factors in patients with MVT including Factor V Leiden and pro-thrombin G20210A gene mutation over-representation,<sup>243,249,250</sup> or deficiencies of antithrombin, protein C, or protein S. The key question is whether these findings influence recurrence rates and/or treatment. It is unclear to what extent these factors have implications for treatment and duration of therapy after mesenteric ischaemia. With this high rate of pro-thrombotic factors present in patients with MVT, however, many experts tend to offer patients with identified risk factors lifelong antithrombotic treatment, despite the lack of an evidence base for such treatment. Consequently, routine screening of genetic and pro-thrombotic factors in patients with MVT may be considered.

Patients with recurrent venous and/or arterial thrombosis or those with recurrent foetal loss may be considered for testing for the antiphospholipid antibody syndrome (APLAS) including lupus anticoagulants, anticardiolipin antibodies, B2glycoprotein, deficiencies of antithrombin, protein C, and protein S.<sup>251</sup> If there is no local cause for the venous thrombosis (e.g. cirrhosis, inflammation, cancer) a myeloproliferative neoplasm should be considered.

acute onset of symptoms within 4 weeks of presentation are classified as having acute venous mesenteric ischaemia. The mean duration of symptoms is often reported to vary from 6 to 14 days, and a 2-week period may be considered an alternative acute time frame.<sup>13</sup> Chronic MVT is used for patients with symptoms lasting longer than 4 weeks, but without bowel infarction, or those without a recent onset of abdominal complaints where MVT was an incidental finding on abdominal imaging. There is no consensus on how to distinguish acute from chronic MVT, but the 4 week criterion is the suggestion of the GWC.

Acute presentation accounts for <20–74% of cases, depending on the vein segment involved, and is more common if thrombosis involves the mesenteric veins.<sup>234,239</sup> Generally speaking, however, even patients with acute MVT tend to present with a more protracted time course compared with those with AMI. After an acute onset, symptoms persist for 2–3 days in more than 75% of the cases before the diagnosis is made, and diffuse abdominal pain may have been present for days or weeks.<sup>12</sup>

SMV involvement, in contrast to isolated PVT, is associated with symptoms in the overwhelming majority (92%) of cases and often results in bowel gangrene (33–45%) if left untreated.<sup>14,233,247–250</sup> Abdominal pain, anorexia, and diarrhoea are the most common presenting symptoms. Unspecific abdominal pain is often present in the early stage of the disease, whereas localised abdominal tenderness develops later. Melaena, haematemesis, or haematochezia occur in only about 15%, but occult blood may be present in 50% of the cases.<sup>12</sup> Fever and peritoneal signs are suggestive of progression of ischaemia to bowel infarction, and hypotension with a systolic blood pressure of less than 90 mmHg along with ascites formation are associated with a poor prognosis.<sup>236</sup> A high, spiking fever with chills, a painful liver, and sometimes shock are clinical fea-

Recommendation 40	Class	Level of evidence	References
In patients with MVT, investigations for abdominal cancer, inflammatory disease, and myeloproliferative neoplasms should be performed	I	B	233,234,237,246
<b>Recommendation 41</b>			
In patients with MVT, investigations for concurrent risk factors for thrombosis should be considered	IIa	B	6,233,234,237,251
<b>Recommendation 42</b>			
In patients with recurrent MVT and/or recurrent foetal loss, investigation for APLAS should be considered	IIa	C	233,234,243,249,251
<b>Recommendation 43</b>			
In patients with MVT, genetic assessment of thrombophilia may be considered	IIb	C	251

MVT = mesenteric venous thrombosis; APLAS = antiphospholipid antibody syndrome.

#### 5.5. Clinical manifestations

From a clinical point of view, MVT may appear in two different entities: *acute* and *chronic*. These represent successive stages of the same disease and share similar causes but differ with respect to their management. Patients with

tures of pylephlebitis, which is the name for an infectious thrombophlebitis of the PV and its branches.<sup>252</sup> Multiple, small liver abscesses are common in this setting. Blood cultures may demonstrate a growth of *Bacteroides*, with or without other enteric species.<sup>232</sup> Acute septic MVT is always

**Table 5.** Diagnostic differentiation of venous versus other types of mesenteric ischaemia.<sup>a</sup>

	Venous	Arterial occlusion	Non-occlusive
Ischaemia	Obstruction of the mesenteric/portal venous vein	Occlusion of the coeliac, superior mesenteric, and/or inferior mesenteric artery, or their branches by an embolus or thrombus	Reduction in cardiac output with reactive mesenteric vessel spasm reaction
Demographics	<50y women=men	<80y women>men	<80y
Risk factors	<ul style="list-style-type: none"> <li>- Virchow's triad (flow, vessel wall and blood) predisposing to venous thrombosis.</li> <li>- Systemic malignancies with thrombophilia</li> <li>- Para-neoplastic phenomenon</li> <li>- Inherited thrombophilia (Factor Leiden, protein S or AT deficiency)</li> <li>- Pancreatic or hepatocellular cancer</li> <li>- History of DVT</li> <li>- Activated protein C resistance</li> <li>- Liver cirrhosis/portal hypertension</li> </ul>	<ul style="list-style-type: none"> <li>- Cardiac arrhythmia particularly atrial fibrillation</li> <li>- Valvular heart disease</li> <li>- Coronary heart disease</li> <li>- Peripheral artery disease</li> <li>- History of stroke</li> </ul>	<ul style="list-style-type: none"> <li>- Congestive heart failure and cardiomyopathy</li> <li>- Low cardiac output</li> <li>- Following prolonged heart surgery with extracorporeal circulation</li> <li>- Long-term haemodialysis</li> </ul>
Typical clinical presentation	<ul style="list-style-type: none"> <li>- Chronic/subacute presentation depending on the involved vein</li> <li>- Insidious onset with less severe abdominal symptoms</li> <li>- Depending on the extension and severity of venous thrombosis</li> <li>- Nonspecific abdominal complaints, for days</li> </ul>	<ul style="list-style-type: none"> <li>- Acute presentation</li> <li>- Sudden onset of abdominal pain</li> <li>- Discrepancy between severe pain and objective findings</li> <li>- Pain-free interval</li> <li>- Late abdominal distension and clinical deterioration</li> </ul>	<ul style="list-style-type: none"> <li>- Increasing abdominal pain in conscious patients</li> <li>- Abdominal distension</li> <li>- Signs of sepsis</li> </ul>
CTA	Diagnostic in >90%	AMI: Diagnostic in >90% CMI: Insufficient for diagnosis	Not diagnostic
Angiography	Diagnostic in 50–60%	Diagnostic	Diagnostic
Bowel infarction	Gradual ischaemia to normal transition	Abrupt ischaemia to normal transition	The entire bowel is partly ischaemic (patchy appearance)
Need for surgery	Rare if anticoagulation started immediately	More likely	More likely

<sup>a</sup> Modified from Hamoud 2014.<sup>236</sup>

associated with an abdominal focus of infection but the primary focus can easily be overlooked and, therefore, is detected only by careful review of the imaging.<sup>247,248</sup>

The risk of developing persistent occlusion and chronic MVT seems to depend on thrombus localisation. In one study thrombosis in smaller peripheral vessels had a higher risk than thrombosis in larger, more proximal vessels.<sup>239</sup>

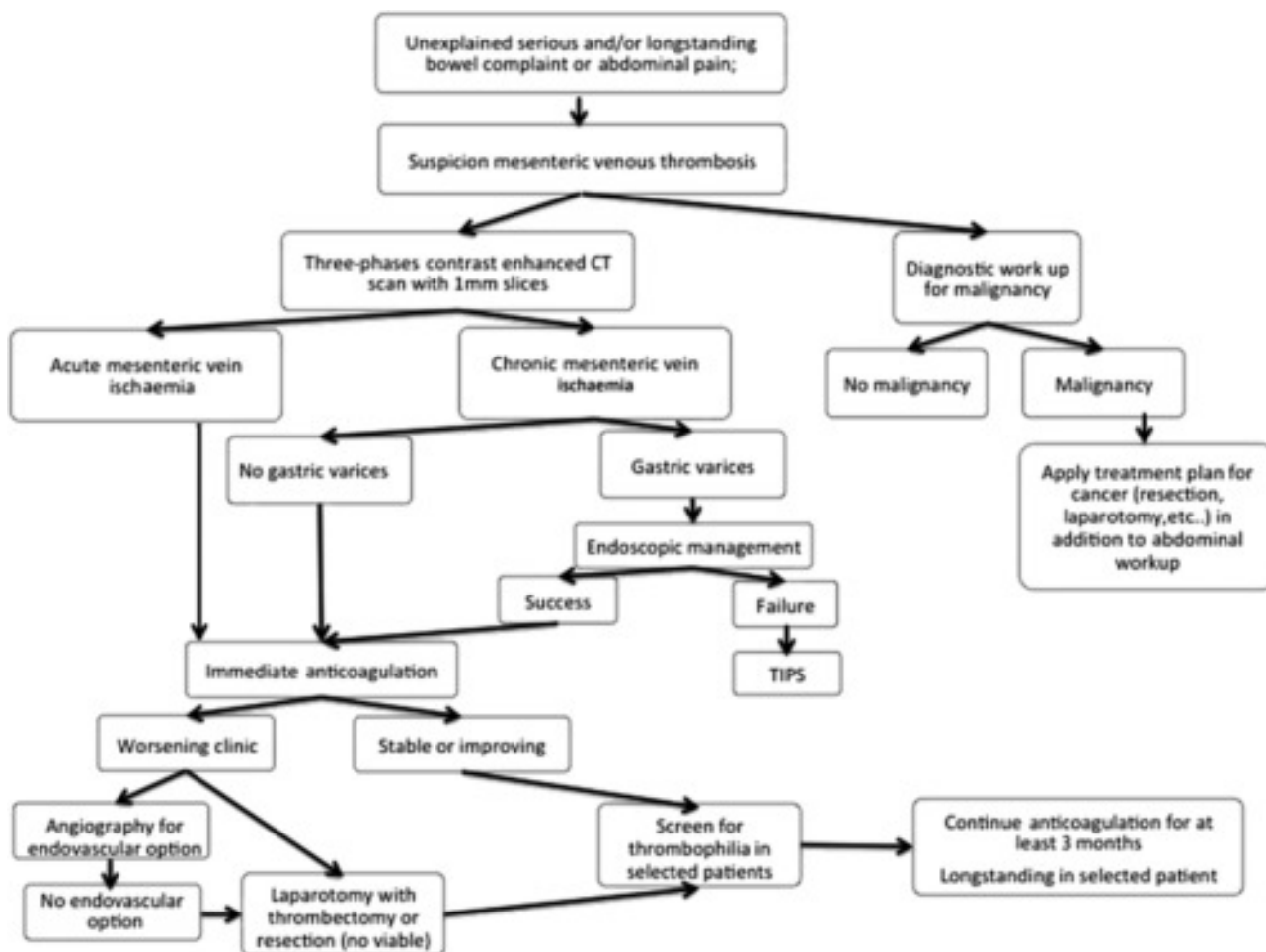
Chronic MVT may also manifest as “portal cavernoma” where the obstructed PV is replaced by a network of collateral veins. Complete occlusion of the PV, or of its two main branches, is virtually always associated with portal hypertension and the development of portosystemic collaterals. Classical presentation of cavernoma with ruptured oesophageal/gastric varices or biliary symptoms related to portal cholangiopathy (jaundice, cholangitis, cholecystitis, or pancreatitis) is rare. The diagnosis is

commonly made after a fortuitous finding of hypersplenism or portal hypertension. When MVT patients develop gastrointestinal bleeding the outcome is better than with other causes of portal hypertension, probably because the patients are usually younger and have normal liver function.<sup>232</sup>

### 5.6. Differential diagnosis

Although there are subtle differences between arterial and venous mesenteric ischaemia, it is possible to differentiate the two conditions clinically when these present acutely as summarised in Table 5.

Acute and particularly chronic venous mesenteric obstruction is a difficult diagnosis among patients presenting with acute or subacute abdominal pain. Awareness of the disease, a careful risk factor evaluation, and positive



**Figure 6.** Flow diagram of suggested management of MVT. This flow diagram was developed by the GWC. CTA = computed tomography angiography; TIPS = transjugular intrahepatic portosystemic shunt; MVT = mesenteric venous thrombosis.

findings at physical examination should lead the clinician through the following care pathway (Fig. 6).

primary diagnostic modality for patients with a high clinical suspicion of mesenteric ischaemia.<sup>253</sup> CTA often demon-

Recommendation 44	Class	Level of evidence	References
In patients with MVT and fever, septic portal vein thrombosis should be considered, whether or not an abdominal source of infection is identified	Ila	C	232,247,252
<b>Recommendation 45</b>			
In patients with newly diagnosed portal hypertension MVT is one of the diagnoses considered	I	C	232

MVT = mesenteric venous thrombosis.

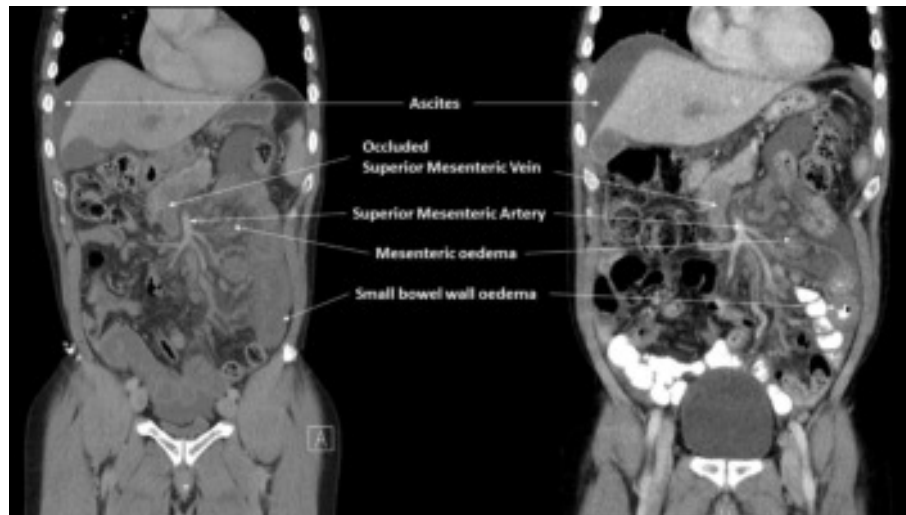
### 5.7. Imaging

In patients with otherwise unexplained, serious, and/or longstanding bowel complaints, a three phase CTA with 1 mm maximum slice thickness is indicated. CTA of the abdomen, with intravenous contrast injection and imaging in the portal venous phase, is the most important and accurate diagnostic tool and the imaging investigation of choice.<sup>60,253–255</sup> If immediately available, contrast enhanced MRA also has been considered as an alternative

strates extensive thrombosis of the porto-mesenteric system, with extension of thrombosis to at least the extra-hepatic PV and SV, and additional, more subtle, intestinal findings (Fig. 7).

A CT scan without contrast can show hyper-attenuating material in the PV. After injection of a contrast agent, the diagnostic vascular findings are lack of luminal enhancement, increased hepatic enhancement in the arterial phase, and decreased hepatic enhancement in the portal phase. The assessment of “non-vascular findings” includes intestinal signs





**Figure 7.** A patient with MVT and bowel ischaemia. CTA of the abdomen showing extensive thrombosis of the superior mesenteric, splenic, extra- and intra-hepatic portal venous system (on the left). Partial recanalisation (extra-hepatic portal vein and a few branches of the superior mesenteric vein) using an endovascular procedure (on the right).

such as bowel wall thickening, bowel dilatation, mesenteric fat stranding, pneumatosis intestinalis, and portal venous gas. Overall, combining the vascular findings and the appearance of the bowel wall results in a specificity of 90–94% with a sensitivity of 96% for the diagnosis of venous mesenteric obstruction.<sup>60,253,255</sup> Given its availability, speed, and diagnostic accuracy, CTA is the gold standard for diagnosis of acute MVT.

The protocol for acute CTA of the abdomen varies with the clinical history provided by the referring physician. Differentiation between arterial and venous mesenteric ischaemia may be difficult on clinical grounds, in which case a combined arterial and porto-venous scan should be considered. For assessment of the venous mesenteric circulation, CTA techniques with protocols optimised to assess porto-mesenteric thrombosis, venous circulation, and intestinal ischaemia should be applied. In detail, CTA data acquisition should be performed at a peak venous enhancement, with the delay between the start of injection and the beginning of the image acquisition tailored for this purpose and with 1 mm slices. Usually a 55–70 s delay following administration of 125–150 mL of intravenous contrast at a rate of 3.5–5 mL/s through a peripheral vein is used. Imaging is completed with reconstruction in coronal and sagittal planes and maximum intensity projection three dimensional reformatting, which provide an entire view of the thrombosed vein in the single image. Furthermore, unenhanced data acquisition before the

portal phase may be useful in detecting mural haemorrhage.<sup>253,255</sup> Thrombus appears as a well-demarcated persistent, partial or complete intraluminal filling defect that may be surrounded by a rim enhancing venous wall.<sup>256</sup> Thrombosis shown on an unenhanced CTA has a low density during the very acute period (within 1 week of the onset of the disease), a high density during the following 1–3 weeks, and a low density again during the entire chronic (>3 weeks) period. Enlargement of the affected veins may be seen: marked venous enlargement is a useful sign to indicate acute thrombosis because in the chronic stages there is a trend towards a reduced vein calibre.

In the presence of chronic MVT, especially when ascites or other signs of portal hypertension are manifest, DUS can show hyperechoic material in the vessel lumen with distension of the PV and its tributaries, and may be the first choice for investigation of the porto-mesenteric veins. DUS can thereby provide real-time flow information of the visceral vessels and also bowel wall thickening and free intraperitoneal fluid. The peripheral circulation may not be accurately visualised, however, and mesenteric veins are more difficult to examine with ultrasound because of a poor acoustic window associated with overlying bowel gas. Confirmatory CTA may, therefore, become necessary for full assessment of vascular and intestinal pathology.

Laparotomy is necessary in some patients, especially those with peritonitis, to assess bowel viability.

Recommendation 46	Class	Level of evidence	References
In patients suspected of having MVT, CTA with imaging in the arterial and portal phases should be performed	I	B	253,255
Recommendation 47			
In patients with MVT, it is recommended that the possibility of intestinal infarction is ruled out until resolution of pain	I	C	232,253

MVT = mesenteric venous thrombosis; CTA = computed tomography angiography.

## 5.8. Treatment

The main goal of treatment of MVT is recanalisation, or at least halting the thrombotic process, to prevent intestinal infarction, portal hypertension, and recurrence of thrombosis. In most patients, anticoagulation is sufficient to tip the balance between coagulation and fibrinolysis. In chronic MVT additional goals are the prevention and treatment of gastrointestinal bleeding and portal cholangiopathy.

The management of MVT has changed over recent decades; there is no agreement on the optimal treatment strategy, because of the rarity of the condition and the absence of RCTs. In hospital, mortality among patients with MVT is lower, around 12–20%, when compared with the other causes of AMI.<sup>234,238,239,257,258</sup> Patients should receive specific medical therapy, endovascular treatment, open surgery, critical care, and nutritional support, as appro-

gangrene or bleeding becomes necessary. It has been shown that anticoagulation started in the early stages results in recanalisation in >80% of patients and complete recanalisation is associated with less extensive disease.<sup>248,261</sup>

The size and extent of venous thrombosis largely affect the outcome, clinical presentation, and probability of bowel infarction. Bowel infarction mostly requires involvement of the venous arcades and vasa recta, which in turn causes complete venous occlusion. Arterial vasospasm and thrombosis also can be a major contributing factor leading to propagation of the ischaemia and bowel infarction. Extensive thrombosis and ascites are predictive factors of poor recanalisation on anticoagulants,<sup>237</sup> and patients with these features at diagnosis could be treated with other, more aggressive therapies.

Recommendation 48	Class	Level of evidence	References
In patients with acute MVT without peritonitis, anticoagulation with heparin is indicated as first line therapy	I	C	248,262

MVT = mesenteric venous thrombosis.

priate. In one study it was suggested that aggressive endovascular treatment, and liberal use of open surgery in patients suspected of bowel infarction, in a multidisciplinary team including gastroenterologists, gastrointestinal and vascular surgeons, interventional radiologists, and coagulation specialists could improve the outcome (mortality 12%, recanalisation >90%).<sup>258</sup> There is general agreement that the main treatment of mesenteric venous ischaemia should be conservative using anticoagulation and supportive treatment.

**5.8.1. Supportive treatment.** Pain control, fluid and electrolyte replacement, and bowel rest should be initiated immediately after diagnosis. Nasogastric aspiration is used in the case of ileus, abdominal distension, and intractable nausea and vomiting. Supportive treatment also includes nutritional support and replacement of fluid and electrolytes and blood transfusion for patients presenting with bleeding. The use of antibiotics has not been shown to be associated with improvement in mortality or hospital stay, but if the patient has perforation, sepsis secondary to bacterial translocation, pylephlebitis or septic thrombophlebitis appropriate antibiotics should be initiated.<sup>259</sup>

**5.8.2. Anticoagulation.** The mainstay for treatment of MVT is anticoagulation. In the absence of major contraindications, anticoagulant therapy is recommended for all patients with acute symptomatic mesenteric venous thrombosis. Systemic anticoagulation should be initiated soon after the diagnosis is made by using unfractionated heparin or low molecular weight heparin (LMWH) followed by VKA or NOACs to reduce the risk of thrombus propagation, recurrence, and overall mortality.<sup>260,261</sup> In the early phase unfractionated heparin has the advantage of being reversible with protamine if laparotomy for bowel

**5.8.3. Endovascular options.** Most patients are treated successfully with medical treatment only, but a small proportion (5%) of patients deteriorate during medical treatment, and in this situation recent clinical practice in some centres has been to initiate endovascular treatment.<sup>239</sup> Patients with persisting symptoms, worsening abdominal pain after initiation of anticoagulation, or development of signs of peritonitis, and who are poor surgical candidates may be considered for endovascular treatment. Recently developed endovascular procedures for the treatment of MVT include TIPS<sup>263–265</sup> with mechanical aspiration thrombectomy, direct thrombolysis,<sup>266</sup> or thrombolysis followed by angioplasty,<sup>258</sup> percutaneous transhepatic mechanical thrombectomy,<sup>267</sup> percutaneous transhepatic thrombolysis,<sup>268,269</sup> and thrombolysis via the SMA.<sup>270</sup> Rapid thrombus removal or dissolution can be achieved through these techniques (Fig. 6); however, all published data on endovascular treatments for MVT are from case reports and small case series.

TIPS has been used for MVT with the rationale of creating a low pressure system which works as a vacuum of clot fragments and improves the effectiveness of thrombolysis in the case of acute thrombosis. The use of TIPS was associated with immediate symptomatic improvement and successful recanalisation in 83% of patients treated in an acute stage.<sup>263</sup> A retrospective study on 20 patients with chronic PVT suggested a high success rate in cases of non-cavernous disease and was effective in prevention of variceal bleeding and recurrent ascites.<sup>264</sup> However, another prospective analysis of nine patients with TIPS reported a complication rate of up to 22% with an 11% mortality.<sup>265</sup> Pulmonary embolism was also a concern.

Catheter directed thrombolysis can be administered by different approaches. The indirect SMA approach (with a

catheter in the SMA) is possible with a lower dose of the thrombolytic agent.<sup>258</sup> With a direct venous approach an even lower dose can be used, reducing the bleeding risk, and improving clot lysis, compared with the SMA approach. Although technically challenging, both transjugular intrahepatic and percutaneous transhepatic approaches provide relatively rapid resolution of thrombus by direct access to mesenteric veins.<sup>258</sup> Endovascular techniques have been successfully reported with respect to favourable survival and patency of the porto-mesenteric veins, low rates of portal hypertension and complications, and prevention of bowel resection in selected patients.<sup>269</sup> In contrast, in a study of 16 MVT patients treated with local thrombolysis, clearance of thrombus was often only partially achieved, and treatment was associated with significant bleeding complications in 60% of patients who often required blood transfusion.<sup>270</sup> In patients with a high risk of bleeding, when thrombolysis is contraindicated, endovascular thrombectomy rapidly removes thrombus and shortens the duration of thrombolytic infusion. A potential drawback of thrombectomy and angioplasty is intimal trauma promoting rethrombosis.

At present, there is no evidence regarding thrombolysis or other endovascular therapies for acute MVT to support any recommendations. Treatment has only been described in several single centre case studies. Studies are needed to assess whether these more invasive treatments are indicated when anticoagulation fails in patients with extensive thrombosis of the mesenteric and/or portal venous systems.

**5.8.4. Open surgery.** Patients with persisting or worsening symptoms and those with frank perforation or signs of peritonitis require open surgical intervention.

The aim of the surgery is to remove irreversibly ischaemic bowel and conserve as much bowel as possible. There are two difficulties in the surgical management of patients with an acute stage of venous mesenteric ischaemia: choosing when to perform a laparotomy and deciding when a segment bowel is irreversibly damaged. The decision to perform prompt surgical exploration and not await the effects of anticoagulation or endovascular treatment is mostly based on the presence of signs of peritoneal irritation at presentation. These signs may not correlate with the severity of bowel ischaemia, however. Repeated physical examination of the abdomen, laboratory testing (C-reactive protein, leukocyte count, and lactate levels), and/or repeated CTA examinations are the basis of clinical decision making.<sup>257</sup>

Surgical resection of the necrotic bowel and anastomosis is the standard procedure. The distinction between irreversibly ischaemic and viable bowel is often more difficult than in arterial mesenteric ischaemia. Although bowel viability can be assessed by various intra-operative methods (DUS, studies with fluorescein, etc), none of these techniques has proven to be superior to clinical judgement. The finding of atonic bowel with serosal bluish discoloration indicates irreversible damage and requires resection. Liberal second- and third-look laparotomies may

be needed to define the viability of the ischaemic bowel. Furthermore, anastomosis is often difficult because of oedema, and is therefore preferably postponed until a later laparotomy.

A damage control approach to mesenteric ischaemia implies immediate laparotomy with eventual resection of infarcted bowel, no attempt to restore gastrointestinal continuity, performing a skin only closure rather than attempting abdominal fascia closure, and returning the patient to the ICU to be stabilised prior to a planned subsequent procedure with second look laparotomy.<sup>258,271</sup> Leaving the abdomen open is an attractive alternative, as second look laparotomy is imperative, and intra-abdominal hypertension is avoided. There are different safety issues involved: open abdomen treatment is safe in experienced hands, but may otherwise pose a threat to the exposed intestines. Closing the abdomen may be safe if intra-abdominal pressure is monitored, otherwise further ischaemic injury to the bowel may occur (please see Chapter 4). The recommendations in Chapter 2, regarding bowel resection, antibiotic treatment, and second look laparotomy, are valid also for venous ischaemia (Recommendations 7–9).

### 5.9. Follow-up

After the acute phase of MVT, anticoagulation should be maintained to prevent progression and recurrence of thrombosis. Oral anticoagulation (VKA or NOAC) can be started after the acute phase of venous mesenteric ischaemia, usually after 2–3 weeks when the phase of acute ischaemic injury has passed. Although no specific trials have been performed of NOAC treatment after MVT, there is no reason to believe that these agents would not be as effective as VKA.

Anticoagulation should be given for at least 3–6 months, or indefinitely if underlying persistent pro-thrombotic factors are identified. The optimal duration of anticoagulant treatment after the acute phase of mesenteric vein ischaemia is a matter for debate, mainly because of the paucity of data, and even conflicting results. In a large cohort of 832 patients with MVT with only a minority of patients receiving secondary prophylaxis with anticoagulants, the incidence of recurrent venous thrombosis after a mean follow-up of 27 months was only 3.5/100 patient years. Only half of the recurrent events involved the mesenteric veins, while the other half involved limb veins or the pulmonary arteries.<sup>234</sup>

Other studies showed a higher risk of recurrence without anticoagulation, however.<sup>261,262,272</sup> Combined data from four retrospective surveys showed that when initiated immediately, 6 months of anticoagulation therapy in patients with MVT was associated with complete recanalisation in 50%, partial recanalisation in 40%, and no recanalisation in 10%.<sup>248</sup> In an historical cohort of patients with MVT, of whom nearly two thirds were treated with anticoagulant drugs, the incidence rate of thrombotic events was 5.5/100 patient years and the absence of anticoagulant therapy was an independent predictor of thrombosis.<sup>261</sup> In another multicentre, retrospective cohort

study on patients with MVT receiving secondary prevention with VKA, the overall recurrence rate was 2.34/100 patient years and increased to 4.59/100 patient years after discontinuation of treatment. The incidence of haemorrhagic complications was low, with only 2.6% of patients experiencing a major bleeding event.<sup>262</sup>

The risk of recurrence may differ depending on the involved vein and the cause of the mesenteric ischaemia.<sup>234,272</sup> A European multicentre study which assessed the outcome of early anticoagulation after acute MVT showed that anticoagulant treatment successfully prevented thrombus extension, and was associated with a favourable 1 year recanalisation rate that was 38% for the PV, 54% for the SV, and 61% for the SMV.<sup>272</sup> In a multicentre prospective registry of 604 patients with MVT, anticoagulation was administered to 465 patients in the entire cohort (77%) with a mean duration of 13.9 months using either parenteral or VKA. Two year data showed that during anticoagulant treatment and after treatment discontinuation, the incidence of thrombotic events was 5.6 per 100 patient years (3.9–8.0) and 10.5 per 100 patient years (6.8–16.3), respectively. The major bleeding rate was 3.9 per 100 patient years (2.6–6.0) and 1.0 per 100 patient years (0.3–4.2), respectively. The highest rates of both thrombotic events and major bleeding during the whole study period were observed in patients with cirrhosis (11.3 per 100 patient years and 10.0 per 100 patient years, respectively); the lowest rates were in patients with MVT secondary to transient risk factors.<sup>273</sup> In a large cohort study patients with thrombosis of the SV showed the highest recurrence free survival at 10 years (97%) and those with MVT the lowest (60%).<sup>234</sup>

When evaluating the risk and benefit of anticoagulant therapy, bleeding is a major concern in patients with MVT. In

NOAC in patients with cancer, as well as for patients with venous thrombosis in the limbs or with pulmonary embolism.<sup>260</sup>

Prolonged anticoagulation more than 3 months after MVT should be considered on an individual basis, after carefully balancing (i) risk factors for bleeding (e.g. the presence of varices, a low platelet count, and previous bleeding episodes); (ii) the risk of recurrence (e.g. persisting risk factors and previous venous thromboembolism); and (iii) the consequences of recurrence or progression (extensive bowel involvement and short bowel syndrome).<sup>274</sup> Patients with the new risk factors for MVT, such as JAK2 mutation with or without myeloproliferative disorders, should be considered for indefinite treatment, given the persistent nature of their risk factors. The advantage of prolonged anticoagulation should be balanced with the risk of major bleeding, including recent major haemorrhage, uncontrolled hypertension, serum creatinine >1.2 mg/dL, anaemia, or age >75.<sup>274</sup>

Other studies have suggested that the optimal duration of anticoagulant treatment should also take into consideration the recanalisation rate of the mesenteric veins, as this may greatly affect mesenteric venous haemodynamics and, consequently, the risk of recurrence. DUS at 1 and 3 and 6 months after an endovascular procedure may allow examination of the portal system and shunting function after TIPS.<sup>275</sup> The value of post-operative CTA for evaluating the extent of thrombosis and the frequency of thrombus recanalisation remains unclear. A repeat CTA after 6 months of anticoagulation therapy may be helpful in determining the duration of treatment, unless it has already been decided to give lifelong anticoagulation.

Recommendation 49	Class	Level of evidence	References
In MVT patients with reversible causes (e.g. trauma, infection, or pancreatitis), anticoagulation for 3–6 months is recommended	I	B	14,251,262,273,274
<b>Recommendation 50</b>			
In MVT patients, lifelong anticoagulation is recommended if there is (i) proven thrombophilia; (ii) recurrent venous thrombosis; (iii) when progression, or recurrence of thrombosis would have severe clinical consequences	I	B	14,251,262,273,274

MVT = mesenteric venous thrombosis.

the abovementioned cohort, major bleeding rates were 6.9/100 patient years, most commonly involving the gastrointestinal tract, and were higher than the rate of recurrent venous thromboembolism. Gastrointestinal varices and warfarin therapy were independently associated with bleeding in multivariate analysis.<sup>234</sup> In another cohort of patients with MVT and ischaemia, the incidence of gastrointestinal bleeding was 12.5/100 patient years.<sup>261</sup> In this and other studies, the presence and size of varices was associated with recurrent bleeding, independently of anticoagulant therapy.<sup>261,272</sup>

The use of anticoagulant drugs in chronic MVT, presenting with variceal bleeding and hypersplenism but without signs of recent occlusion, should not be considered.

Secondary prevention with LMWH in the first 3–6 months may be considered as an alternative to VKA or

## 6. MESENTERIC ARTERIAL ANEURYSMS

### 6.1. Diagnosis

True aneurysms of the mesenteric arteries and its branches are rare, with an estimated prevalence of 0.1–2%.<sup>17–19</sup> These are usually silent but potentially fatal because of the risk of rupture. Pain may occur at the time of rupture or suggest impending rupture. Although rarely reported, thrombosis or embolisation may result in clinical signs of mesenteric ischaemia or solid organ infarction. Post-stenotic dilatation also may be observed, commonly as a consequence of external compression of the CA in MALS.<sup>276</sup> In these cases, symptoms of epigastric or postprandial pain and weight loss may be present. Post-stenotic dilatation may also be present in other locations.<sup>277–279</sup>

The splenic artery (SA) is most commonly affected (60% of cases), followed by the hepatic artery (HA, 20%), but virtually all vessels of the mesenteric circulation may be involved. Concomitant aneurysms are found in up to one third of patients with visceral artery aneurysms.<sup>277,279–282</sup> These include other visceral arteries (4–44%),<sup>20,21,277,281,283–286</sup> the thoraco-abdominal aorta and iliac arteries (3–27%),<sup>277,279,281,286</sup> and intracranial arteries (3–4%).<sup>277,281,286</sup> Abdominal organ transplant recipients may be at increased risk of aneurysmal degeneration of mesenteric arteries.<sup>287</sup>

False aneurysms of the mesenteric arteries may result from acute or chronic local inflammatory or infectious disease, commonly pancreatitis, or may result from trauma (including iatrogenic injuries during hepatobiliary procedures).<sup>279,288,289</sup> In some cases, no causal relationship can be established.

associated with patient characteristics, as well as with type, location, and size of the aneurysm. In a large series of 138 patients with asymptomatic mesenteric aneurysms, observation was selected as the primary approach.<sup>297</sup> In this cohort, 91% of the aneurysms remained stable, whereas 6% needed an intervention within 2 years because of growth. There were no ruptures after a mean of 3 years follow-up. These authors concluded that true aneurysms <25mm in diameter could be safely observed and suggested imaging at 3 year intervals. Similar observations had been reported previously by investigators who suggested repair for SA aneurysms >20 mm.<sup>298</sup> There are no prospective comparisons between observation and intervention for small asymptomatic mesenteric aneurysms.

Recommendation 51	Class	Level of evidence	References
In patients with mesenteric aneurysms, CTA is recommended for diagnosis, anatomical characterisation, and procedural planning	I	C	17–21,277,279–286, 289–296

CTA = computed tomography angiography.

Recommendation 52	Class	Level of evidence	References
In patients with true symptomatic aneurysms of the mesenteric arteries, urgent repair is recommended irrespective of size or location	I	C	17,20,277,279,284, 288,290,293–297
<b>Recommendation 53</b>			
In patients with asymptomatic true aneurysms of the mesenteric arteries, intervention should be considered at a diameter $\geq$ 25 mm	IIa	C	297,298
<b>Recommendation 54</b>			
In patients with asymptomatic true aneurysms of the mesenteric arteries with a diameter <25 mm, imaging at 2–3 year intervals may be considered	IIb	C	293,297

Most commonly, aneurysms of the mesenteric arteries are incidental findings. This may occur when performing abdominal imaging for other reasons, and may be suspected after abdominal X-rays or ultrasound. CTA allows for accurate diagnosis, anatomical characterisation, and interventional planning, and is generally the preferred imaging method. MRA may be a reasonable alternative.

## 6.2. Treatment

Rupture and bleeding are the most relevant clinical manifestations of mesenteric aneurysms. The natural history of mesenteric aneurysms is not well characterised, however, and rupture risk cannot be accurately established. It is

Specific patient subgroups may benefit from repair irrespective of size. Patients with aneurysms of the pancreaticoduodenal and gastroduodenal arcades, as well as of the HAs have been suggested to have a higher risk of rupture, requiring prompt treatment.<sup>17,299</sup> The prevalence of ruptured SA aneurysms in pregnant women is extremely low. There are several case reports of ruptured SA aneurysms during pregnancy, however, and some for other visceral artery aneurysms. Importantly, maternal and foetal mortality is high after rupture (up to 70% and 90%, respectively).<sup>286,297–301,303</sup> Intervention should therefore be considered irrespective of size in women of child-bearing age. Finally, recipients of an abdominal organ transplant are also more likely to benefit from treatment at any diameter.<sup>287,298,302</sup>

Recommendation 55	Class	Level of evidence	References
In patients with true asymptomatic mesenteric aneurysms, intervention irrespective of size may be considered for the following subgroups: aneurysms of the pancreaticoduodenal and gastroduodenal arcade; of the intra-parenchymatous hepatic arteries; in women of child-bearing age; recipients of a liver transplant	IIb	C	17,286,287,298–303

Once intervention is considered necessary, meticulous imaging is required to adequately determine the optimal strategy. Treatment in some cases may be safely performed by primary occlusion of the affected vessel, both by open or laparoscopic and endovascular techniques. The selection of open or endovascular techniques depends on patient and anatomical characteristics, local expertise, and individual preference. There are no randomised trials or prospective studies comparing open and endovascular repairs, and consequently the level of evidence is low. In contemporary literature, the proportion of patients managed with endovascular techniques ranges from 0% to 100%, and studies are very heterogeneous in patient characteristics, presentation, and preferred therapeutic options. Thus, there is no consensus for optimal management at present.

It is generally accepted that pseudoaneurysms have a higher rupture risk, and should be treated promptly. In a series of 48 patients with bleeding aneurysms, 45 (94%) were pseudoaneurysms.<sup>289</sup> Bleeding was a more frequent indication for intervention in pseudoaneurysms in another report (63% vs. 18% for true aneurysms).<sup>17</sup> Others have also published similar observations.<sup>278,304</sup>

Recommendation 56	Class	Level of evidence	References
In patients with asymptomatic pseudoaneurysms of the mesenteric arteries, intervention may be considered irrespective of size	IIb	C	17,278,289,304

In some cases treatment may be performed by occlusion of the affected vessel. Preservation or occlusion of the involved vessel depends on the region of perfusion and presence of collateral pathways. In most cases arterial occlusion may be performed without consequences; however, end organ infarction may result in serious and potentially devastating consequences. Arterial preservation is therefore desirable whenever feasible. Careful individualised evaluation is necessary to determine the need for arterial patency.

Recommendation 57	Class	Level of evidence	References
In patients with mesenteric aneurysms, arterial reconstruction is recommended over occlusion when technically possible, in a patient who is not a high risk surgical candidate	I	C	290,297,298,305

Recommendation 58	Class	Level of evidence	References
In patients with mesenteric aneurysms who are anatomically suitable, endovascular repair should be considered because of lower peri-operative morbidity than open surgery	IIa	C	278–280,288–291, 293–297

Despite the low quality of evidence and the high risk of selection bias of retrospective studies, the following can be observed across retrospective studies: open, laparoscopic and endovascular repair<sup>305</sup> can be offered to elective patients at very low mortality rates (0–3%), but peri-operative morbidity is generally higher with open repair. This is offset by a small but relevant early failure rate and late reperfusion risk, with consequent

need for secondary intervention.<sup>278–280,284,288–291,293–297</sup> Open repair also has the advantage of excluding the aneurysm completely with minimal compromise of the collateral circulation. In cases of rupture the benefit of endovascular repair may be greater, as open repair for rupture is often more complex and results in a higher physiological insult.<sup>279,284,289,291</sup>

Open or laparoscopic repair may involve resection and end to end anastomosis, re-implantation, graft interposition, or simple ligation. In some cases, organ resection may be necessary. Endovascular repair may be performed by implantation of a covered stent,<sup>292</sup> embolisation with coils or glue, and arterial stenting, as well as by inflow and outflow occlusion of the involved vessel. Coil embolisation is the most commonly used technique, because of its wide applicability and high success rate.<sup>279,288,289</sup> Glue embolisation has also been used successfully but is technically more challenging and may have a higher chance of distal embolisation.<sup>279,288,289</sup> Flow diverting stents have been used for complex aneurysms where preservation of side branches or heavy tortuosity precluded the application of conventional endovascular techniques, but there are

insufficient data to support this indication.<sup>306</sup> Percutaneous thrombin injection has been performed, but is associated with high recurrence rates.<sup>21,287,289</sup>

### 6.3. Follow-up after treatment

The follow-up after treatment of aneurysms of the mesenteric arteries is determined by the underlying disease and chosen therapeutic method.

After open repair, most patients will not require routine imaging surveillance unless the underlying mechanism (e.g. pancreatitis) remains. It is generally advisable to confirm successful aneurysm occlusion or thrombosis after endovascular therapy with early CTA or MRA. MRA may be a reasonable alternative<sup>307</sup> because of image artefacts caused by metal coils on CTA. Depending on location, DUS also may be used as an alternative to confirm effective exclusion of

the aneurysm and its reduction in size. Repeated imaging is advised for patients with true aneurysms treated by endovascular repair, because of the risk of late recurrence.<sup>279,284,294–298,304</sup> Imaging at 2 to 3-year intervals may suffice to detect late failures and allow for timely secondary procedures, although this is not supported by data.

Patients with pseudoaneurysms treated effectively with inflow and outflow embolisation do not require routine follow-up imaging, as the chance of recurrence is small. When the underlying cause persists, repeated imaging is recommended as the chance of recurrence is high. Similarly, pseudoaneurysms treated by percutaneous thrombin injection have a higher risk of recurrence and repeated imaging is advised.

The GWC could not identify any data in the literature comparing different medical treatments following surgery or follow-up regimens, and the following recommendations are entirely based on expert opinions. (Level C evidence).

Recommendation 59	Class	Level of evidence	References
In patients with true aneurysms of the mesenteric arteries treated by endovascular repair, imaging at 3-year intervals may be considered	IIb	C	279,284,294–298,304
Recommendation 60			
In patients with successfully excluded pseudoaneurysms of the mesenteric arteries, follow-up may be considered only when the underlying aetiology persists	IIb	C	279,284,294–298,304

## 7. ISOLATED DISSECTIONS OF THE MESENTERIC ARTERIES

### 7.1. Introduction

This chapter is on the diagnosis and management of isolated dissection of the CA or the SMA. Dissections resulting from extension of a primary aortic dissection represent a different entity and are not considered here. Isolated mesenteric artery dissections (IMAD) are rare but are increasingly diagnosed because of the widespread availability of high quality CTA. They can be encountered as an incidental finding on a CTA in asymptomatic patients, or in the evaluation of patients admitted with abdominal pain or suspected of having mesenteric ischaemia. Because of the rarity of the condition and the absence of case control or randomised trials, all the evidence in this chapter stems from 39 case series of at least five patients that were reviewed independently (see [Appendix S1, supplementary material](#)).

### 7.2. Patient characteristics

Most of the experience with IMAD comes from Asian countries in the Far East such as China, Korea, and Japan. However, from a total of 688 cases with isolated mesenteric dissections (37 series with 572 SMA dissections, 17 series with 125 CA dissections) identified in the search, 143 (21%) originated from the USA, 29 from France, 10 from Brazil, and seven from Israel. These papers did not report the ethnicity of the patients. The aetiology of IMAD is as yet unknown but seems to be associated with hypertension (prevalence 39%, 95% CI 36–43%), while the prevalence of diabetes in these patients

**Table 6.** Pooled estimates of risk factors in patients with isolated mesenteric artery dissections supplementary.<sup>1–39</sup>

Variable	Proportion N (%)	95% CI (%)
Male gender	586/688 (85)	82–88
Hypertension	250/633 (39)	36–43
Smoking	174/456 (38)	33–43
Dyslipidaemia	78/397 (20)	16–24
Diabetes mellitus	32/410 (8)	6–11
Cardiac disease, any	27/357 (8)	5–11

is low (8%, 95% CI 6–11%). Affected patients are relatively young (mean age 55 years) and there is a male preponderance (85%) (Table 6). These data are in line with a review of 596 cases<sup>308</sup> and with a review of a Chinese case series of 622 isolated SMA dissections; the mean age of these patients was 55 years and 43% had hypertension and 89% were male.<sup>309</sup>

**7.2.1. Diagnosis.** Most symptomatic patients present with abdominal pain (91%),<sup>309</sup> yet 26% of the patients in the present analysis were asymptomatic. As there are no specific lab tests, the diagnosis of IMAD is established by CTA. Two systems have been proposed to classify the extent of the dissection (Figs. 8 and 9).

The Sakamoto classification describes findings at CTA as type I (entry and re-entry tear visible, patent false lumen), type II (only entry tear visible, patent false lumen), type III (thrombosis of false lumen, and ulcer like projection), and type IV (occlusion of false lumen without ulcer like projection).<sup>310</sup>

Yun classifies the dissection of the visceral artery at CTA as type I (entry and re-entry tear visible, patent false lumen), type IIa (only entry tear visible, patent false lumen), type IIb (thrombosis of false lumen, patent true lumen), and type III (occlusion of true and false lumen).<sup>311</sup>

### 7.3. Treatment

Treatment of patients with IMAD is aimed at prevention of intestinal ischaemia or rupture of the artery. Although most patients present with acute abdominal pain, the majority can be treated without an intervention. In the present dataset 75% of the 688 patients (74% were symptomatic) were managed conservatively with food withdrawal, hydration, analgesia, blood pressure control, and (unfractionated) heparin, antiplatelet agents, VKA, or no anticoagulation at all in a minority. Unfortunately, no recommendation can be given with regard to optimal medical treatment. Some 134 (20%) of the patients ultimately underwent an endovascular

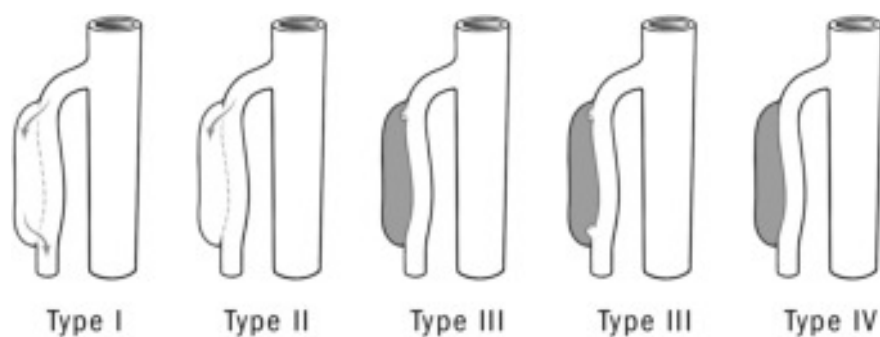


Figure 8. The Sakamoto classification.<sup>310</sup>

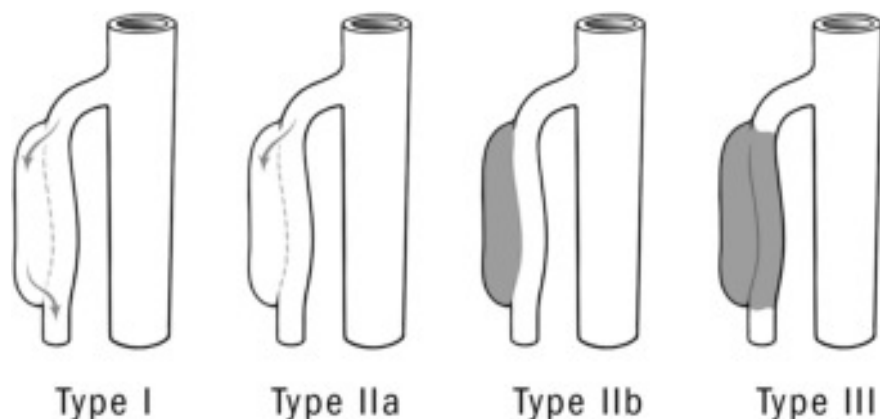


Figure 9. The Yun classification.<sup>311</sup>

intervention, predominantly consisting of stenting of the affected CA or SMA, and in 40 patients (6%) open revascularisation was necessary. Bowel resection was performed in nine (1.3%) patients, and in hospital mortality was 0.6%. A 16% failure rate of medical treatment of symptomatic patients with SMA dissection and 45% failure rate in patients with a dissection in both the CA and SMA were reported.<sup>308</sup> In the Chinese population, management of an isolated SMA dissection was conservative in 254/402 (63%) patients, endovascular in 135/402 (34%), and surgical in 13/402 (3%).<sup>309</sup>

As the clinical presentation and course of patients with an IMAD is heterogeneous, no strict recommendations for treatment can be given. Neither the Sakamoto nor the Yun classification can predict the clinical course.<sup>310,311</sup> Patients with an asymptomatic IMAD do not require immediate

intervention and can be treated medically with antiplatelet therapy and control of hypertension. Patients with symptomatic IMAD can initially be managed medically. It seems appropriate to administer antiplatelet therapy or unfractionated heparin to prevent thrombosis of the affected artery. Close clinical observation is necessary and when there is a suspicion of bowel ischaemia, endovascular intervention will be the treatment of choice. Anatomical considerations define the endovascular strategy, which will most often consist of stenting. Unfortunately, there are no robust data on the long-term patency of endovascular interventions for this indication. If endovascular treatment fails, surgical bypass is the next step, although other procedures such as intemectomy, thrombectomy, or patch angioplasty also can be performed, depending on the local anatomical situation.

Recommendation 61	Class	Level of evidence	References
In patients with asymptomatic IMAD, conservative treatment with antiplatelet therapy and control of hypertension should be considered	IIa	C	308,309
<b>Recommendation 62</b>			
Patients with symptomatic IMAD should be considered for treatment with antiplatelet therapy or LMWH or unfractionated heparin until symptoms resolve	IIa	C	308,309
<b>Recommendation 63</b>			
Patients with a symptomatic IMAD not responding to medical management and with a suspicion of bowel ischaemia should be considered for endovascular revascularisation	IIa	C	308,309

IMAD = Isolated mesenteric artery dissection; LMWH = low-molecular weight heparin.



#### 7.4. Follow-up

Given the weakening of the dissected arterial wall, one might expect aneurysmal degeneration in the years following an IMAD. CTA, DUS, or MRA (depending on local expertise) are suitable modalities for surveillance after discharge. Patients with favourable remodelling and unchanged anatomy over time may be discharged from a surveillance programme. Unfortunately, there are no studies with systematic and sufficiently long follow-up to determine the natural course after IMAD. Among the 35 studies that reported mid-term follow-up (median time of 21 months), only seven endovascular and five open re-interventions were reported in a total of 637 patients, indicating that the need for intervention is uncommon.

disseminated and evaluated in prospective multicentre studies. Portal vein lactate measurement with magnetic spectroscopy has been reported in experimental studies, and could perhaps be developed into a mesenteric ischaemia function test.

Development of methods to measure precise volume blood flow in the mesenteric circulation, for instance with MRA or CTA, would improve the possibilities for evaluating the effect of different interventions.

To better understand, compare, and combine the results of studies reporting on the outcomes of interventions for CMI in meta-analyses, reporting standards are needed that incorporate additional outcome parameters to patency and re-interventions for recurrent symptoms. None of the

Recommendation 64	Class	Level of evidence	References
Follow-up with imaging should be considered after IMAD to detect aneurysm formation, occlusion, or stenosis	Ila	C	308,309

IMAD = isolated mesenteric artery dissections.

## 8. FUTURE RESEARCH

Developing the current Guidelines for the diagnosis and treatment of diseases of the mesenteric arteries and veins has demonstrated that the level of evidence to support the recommendations is low. The low prevalence of these disorders makes it difficult to perform RCTs, which implies that the necessary information to guide clinical decision making has to come from observational studies. Evidence from observational studies can be acceptable, however, as long as inherent biases have been addressed in the design and reporting of such studies. Complete and long-term follow-up is important in such cohorts. The GWC identified several issues that are worth placing on the research agenda for the near future.

### 8.1. Acute and chronic mesenteric ischaemia

When results after different surgical procedures, such as SMA stenting, are reported, it is important to distinguish patients with AMI, CMI, and acute on chronic mesenteric ischaemia. These are different patient cohorts, and it is rather meaningless to compare results, or discuss the possible advantage of different follow-up regimens, if the patient population is mixed.

There is a need to develop a specific biomarker for intestinal ischaemia.

The selection of patients with symptoms of CMI for interventional treatment must be improved. Some 15% of patients who have been treated with a technically successful intervention remain symptomatic. This rate is comparable with patients after a laparoscopic cholecystectomy. It has been outlined that functional testing is of paramount importance in diagnosing CMI, in particular in one vessel disease. Although exercise tonometry has been shown to have a high accuracy for establishing the diagnosis of CMI, it is not widely available. Either a new methodology to select patients for an intervention needs to be developed, or exercise tonometry needs to be

studies comparing endovascular and open surgery for CMI supplied data on more relevant outcomes such as weight gain or the reason for re-interventions. In addition, there were no data available on patient reported outcome measures (PROMs) such as quality of life or simple pain scores before and after an intervention. Development and evaluation of PROMs for this specific group of patients is crucial to improve our understanding of the outcomes of interventions for CMI, and to aid shared decision making.

When better methods have been developed on how to select patients for treatment, and how to compare results, the next step is to compare different interventions. There are multiple issues to be addressed: single or multiple vessel revascularisation, open versus endovascular management, bare versus covered stent deployment, bare versus drug coated technology, post-intervention drug therapy, anticoagulation versus antiplatelet therapy, single versus dual antiplatelet therapy, etc.

Further research is also warranted to determine if routine surveillance and treatment of re-stenoses after treatment for CMI, before they become symptomatic confers any benefit, thus guiding the need for follow-up with imaging after intervention.

Last but not least, the GWC wants to emphasise the need to develop multicentre, preferably international, collaboration in research on mesenteric vascular disease. Although the patient cohort in total is rather large, the number of subgroups of patients with different pathologies and treatments is also great, emphasising the need for collaboration that might then supply physicians and patients with high quality data to support future decision making.

### 8.2. Venous mesenteric ischaemia

Thrombolysis seems to be a promising technique in patients with venous mesenteric ischaemia. Yet the GWC had difficulty in interpreting the results of the small case series

reporting on the role and the different techniques of thrombolysis, mainly because in most papers patient selection was not clear. For this field it would also be desirable to share data from as many centres as possible in a registry because of the low prevalence of the disorder. Registries represent a potential way forward when studying treatment of uncommon and rare diseases. The Vascunet collaboration of registries within Europe, Australia, and New Zealand is a sub-committee of the ESVS, and has recently established a transatlantic collaboration with the Society for Vascular Surgery - Vascular Quality Improvement in North America.

Although several cohort studies have identified a high prevalence of pro-thrombotic factors in patients with venous mesenteric ischaemia indicating Factor V Leiden and pro-thrombin G20210A gene mutations over-representation, the value of routine blood screening of inherited or acquired thrombophilic factors as risk factor estimates and/or as determinants of anticoagulation therapy length or recurrence rates remains to be evaluated.

### 8.3. Mesenteric artery aneurysms

There were hardly any data available on the natural history of mesenteric artery aneurysms, including the risks and benefits of prophylactic treatment. Given the low prevalence it would be desirable to use the existing registries to study these patients. Another alternative is to start a dedicated international registry of such patients, to expand our knowledge. As the risk of rupture seems to be low, a prospective registry of patients managed without operative intervention is warranted. These aneurysms are diagnosed more often as a result of increased imaging, in particular with CT, resulting in an inherent risk of overtreatment.

### 8.4. Isolated dissections of the mesenteric arteries

The role of endovascular treatment as well as the duration and frequency of follow-up examinations need to be defined in rigorous prospective cohort studies. As the disease may behave differently in Asian and European populations, there is a need for multicentre collaboration in Europe, where the disease is less common.

## APPENDIX A. SUPPLEMENTARY DATA

Supplementary data related to this article can be found at <http://dx.doi.org/10.1016/j.ejvs.2017.01.010>.

## REFERENCES

- 1 Cao P, Paola De Rango (1966–2016). A great loss to the vascular community. *Eur J Vasc Endovasc Surg* 2016;**51**:615.
- 2 Wittens C, Davies AH, Baekgaard N, Broholm R, Cavezzi A, Chastanet S, et al. Editor's choice - Management of chronic venous disease: clinical practice guidelines of the European Society for Vascular Surgery (ESVS). *Eur J Vasc Endovasc Surg* 2015;**49**(6):678–737.
- 3 Windecker S, Kolh P, Alfonso F, Collet JP, Cremer J, Falk V, et al. 2014 ESC/EACTS Guidelines on myocardial revascularization: the task force on myocardial revascularization of the European Society of Cardiology (ESC) and the European

- Association for Cardio-Thoracic Surgery (EACTS). Developed with the special contribution of the European Association of Percutaneous Cardiovascular Interventions (EAPCI). *Eur Heart J* 2014;**35**(37):2541–619.
- 4 Klar E, Rahmanian PB, Bucker A, Hauenstein K, Jauch KW, Luther B. Acute mesenteric ischemia: a vascular emergency. *Dtsch Arztebl Int* 2012;**109**(14):249–56.
- 5 Khan A, Hsee L, Mathur S, Civil I. Damage-control laparotomy in nontrauma patients: review of indications and outcomes. *J Trauma Acute Care Surg* 2013;**75**(3):365–8.
- 6 Acosta S. Mesenteric ischemia. *Curr Opin Crit Care* 2015;**21**(2):171–8.
- 7 Acosta S, Ogren M, Sternby NH, Bergqvist D, Bjorck M. Clinical implications for the management of acute thromboembolic occlusion of the superior mesenteric artery: autopsy findings in 213 patients. *Ann Surg* 2005;**241**(3):516–22.
- 8 Karkkainen JM, Lehtimäki TT, Manninen H, Paajanen H. Acute mesenteric ischemia is a more common cause than expected of acute abdomen in the elderly. *J Gastrointest Surg* 2015;**19**(8):1407–14.
- 9 Mitchell EL, Moneta GL. Mesenteric duplex scanning. *Perspect Vasc Surg Endovasc Ther* 2006;**18**(2):175–83.
- 10 Schermerhorn ML, Giles KA, Hamdan AD, Wyers MC, Pomposelli FB. Mesenteric revascularization: management and outcomes in the United States, 1988–2006. *J Vasc Surg* 2009;**50**(2):341–8. e1.
- 11 Thomas JH, Blake K, Pierce GE, Hermreck AS, Seigel E. The clinical course of asymptomatic mesenteric arterial stenosis. *J Vasc Surg* 1998;**27**(5):840–4.
- 12 Kumar S, Sarr MG, Kamath PS. Mesenteric venous thrombosis. *New Engl J Med* 2001;**345**(23):1683–8.
- 13 Singal AK, Kamath PS, Tefferi A. Mesenteric venous thrombosis. *Mayo Clin Proc* 2013;**88**(3):285–94.
- 14 Acosta S. Epidemiology of mesenteric vascular disease: clinical implications. *Semin Vasc Surg* 2010;**23**(1):4–8.
- 15 Ageno W, Squizzato A, Togna A, Magistrali F, Mangini M, Fugazzola C, et al. Incidental diagnosis of a deep vein thrombosis in consecutive patients undergoing a computed tomography scan of the abdomen: a retrospective cohort study. *J Thromb Haemost* 2012;**10**(1):158–60.
- 16 Ogren M, Bergqvist D, Bjorck M, Acosta S, Eriksson H, Sternby NH. Portal vein thrombosis: prevalence, patient characteristics and lifetime risk: a population study based on 23,796 consecutive autopsies. *World J Gastroenterol* 2006;**12**(13):2115–9.
- 17 Fankhauser GT, Stone WM, Naidu SG, Oderich GS, Ricotta JJ, Bjarnason H, et al. The minimally invasive management of visceral artery aneurysms and pseudoaneurysms. *J Vasc Surg* 2011;**53**(4):966–70.
- 18 Pulli R, Fargion A, Pratesi G, Dorigo W, Angiletta D, Pratesi C. Aortic type B dissection with acute expansion of iliac artery aneurysm in previous endovascular repair with iliac branched graft. *J Vasc Surg* 2011;**54**(6):1788–91.
- 19 Saltzberg SS, Maldonado TS, Lamparello PJ, Cayne NS, Nalbandian MM, Rosen RJ, et al. Is endovascular therapy the preferred treatment for all visceral artery aneurysms? *Ann Vasc Surg* 2005;**19**(4):507–15.
- 20 Huang YK, Hsieh HC, Tsai FC, Chang SH, Lu MS, Ko PJ. Visceral artery aneurysm: risk factor analysis and therapeutic opinion. *Eur J Vasc Endovasc Surg* 2007;**33**(3):293–301.
- 21 Lagana D, Carrafiello G, Mangini M, Dionigi G, Caronno R, Castelli P, et al. Multimodal approach to endovascular treatment of visceral artery aneurysms and pseudoaneurysms. *Eur J Radiol* 2006;**59**(1):104–11.

- 22 Debus ES, Muller-Hulsbeck S, Kolbel T, Larena-Avellaneda A. Intestinal ischemia. *Int J Colorectal Dis* 2011;**26**(9):1087–97.
- 23 Douard R, Chevallier JM, Delmas V, Cugnenc PH. Clinical interest of digestive arterial trunk anastomoses. *Surg Radiol Anat* 2006;**28**(3):219–27.
- 24 Parks DA, Jacobson ED. Physiology of the splanchnic circulation. *Arch Int Med* 1985;**145**(7):1278–81.
- 25 Lundgren O. Studies on blood flow distribution and counter-current exchange in the small intestine. *Acta Physiol Scand Suppl* 1967;**303**:1–42.
- 26 Zeller T, Macharzina R. Management of chronic atherosclerotic mesenteric ischemia. *Vasa* 2011;**40**(2):99–107.
- 27 Someya N, Endo MY, Fukuba Y, Hayashi N. Blood flow responses in celiac and superior mesenteric arteries in the initial phase of digestion. *Am J Physiol Regul Integr Comp Physiol* 2008;**294**(6):R1790–6.
- 28 van Bockel JH, Geelkerken RH, Wasser MN. Chronic splanchnic ischaemia. *Best Practice Research Clin Gastroenterol* 2001;**15**(1):99–119.
- 29 Veenstra RP, ter Steege RW, Geelkerken RH, Huisman AB, Kolkman JJ. The cardiovascular risk profile of atherosclerotic gastrointestinal ischemia is different from other vascular beds. *Am J Med* 2012;**125**(4):394–8.
- 30 Mensink PB, van Petersen AS, Geelkerken RH, Otte JA, Huisman AB, Kolkman JJ. Clinical significance of splanchnic artery stenosis. *Br J Surg* 2006;**93**(11):1377–82.
- 31 Björck M, Wanhainen A. Nonocclusive mesenteric hypoperfusion syndromes: recognition and treatment. *Semin Vasc Surg* 2010;**23**(1):54–64.
- 32 Lu M, Weiss C, Fishman EK, Johnson PT, Verde F. Review of visceral aneurysms and pseudoaneurysms. *J Comp Assist Tomogr* 2015;**39**(1):1–6.
- 33 Shanley CJ, Shah NL, Messina LM. Common splanchnic artery aneurysms: splenic, hepatic, and celiac. *Ann Vasc Surg* 1996;**10**(3):315–22.
- 34 Person B, Dorfman T, Bahouth H, Osman A, Assalia A, Kluger Y. Abbreviated emergency laparotomy in the non-trauma setting. *World J Emerg Surg* 2009;**4**:41.
- 35 Roussel A, Castier Y, Nuzzo A, Pellenc Q, Sibert A, Panis Y, et al. Revascularization of acute mesenteric ischemia after creation of a dedicated multidisciplinary center. *J Vasc Surg* 2015;**62**(5):1251–6.
- 36 Acosta S, Björck M. Modern treatment of acute mesenteric ischaemia. *Br J Surg* 2014;**101**(1):e100–8.
- 37 Huisman-de Waal G, Schoonhoven L, Jansen J, Wanten G, van Achterberg T. The impact of home parenteral nutrition on daily life—a review. *Clin Nutr* 2007;**26**(3):275–88.
- 38 Sudan D. The current state of intestine transplantation: indications, techniques, outcomes and challenges. *Am J Transpl* 2014;**14**(9):1976–84.
- 39 Joyce KE, Lord S, Matlock DD, McComb JM, Thomson R. Incorporating the patient perspective: a critical review of clinical practice guidelines for implantable cardioverter defibrillator therapy. *J Interv Card Electrophysiol* 2013;**36**(2):185–97.
- 40 Rheudasil JM, Stewart MT, Schellack JV, Smith 3rd RB, Salam AA, Perdue GD. Surgical treatment of chronic mesenteric arterial insufficiency. *J Vasc Surg* 1988;**8**(4):495–500.
- 41 Acosta S, Ogren M, Sternby NH, Bergqvist D, Björck M. Fatal nonocclusive mesenteric ischaemia: population-based incidence and risk factors. *J Int Med* 2006;**259**(3):305–13.
- 42 Acosta S, Björck M. Acute thrombo-embolic occlusion of the superior mesenteric artery: a prospective study in a well defined population. *Eur J Vasc Endovasc Surg* 2003;**26**(2):179–83.
- 43 Björnsson S, Resch T, Acosta S. Symptomatic mesenteric atherosclerotic disease—lessons learned from the diagnostic workup. *J Gastrointest Surg* 2013;**17**(5):973–80.
- 44 Acosta S, Nilsson TK, Björck M. D-dimer testing in patients with suspected acute thromboembolic occlusion of the superior mesenteric artery. *Br J Surg* 2004;**91**(8):991–4.
- 45 Block TA, Acosta S, Björck M. Endovascular and open surgery for acute occlusion of the superior mesenteric artery. *J Vasc Surg* 2010;**52**(4):959–66.
- 46 Akyildiz H, Akcan A, Ozturk A, Sozuer E, Kucuk C, Karahan I. The correlation of the D-dimer test and biphasic computed tomography with mesenteric computed tomography angiography in the diagnosis of acute mesenteric ischemia. *Am J Surg* 2009;**197**(4):429–33.
- 47 Chiu YH, Huang MK, How CK, Hsu TF, Chen JD, Chern CH, et al. D-dimer in patients with suspected acute mesenteric ischemia. *Am J Emerg Med* 2009;**27**(8):975–9.
- 48 Matsumoto S, Sekine K, Funaoka H, Yamazaki M, Shimizu M, Hayashida K, et al. Diagnostic performance of plasma biomarkers in patients with acute intestinal ischaemia. *Br J Surg* 2014;**101**(3):232–8.
- 49 Thuijls G, van Wijck K, Grootjans J, Derikx JP, van Bijnen AA, Heineman E, et al. Early diagnosis of intestinal ischemia using urinary and plasma fatty acid binding proteins. *Ann Surg* 2011;**253**(2):303–8.
- 50 Gearhart SL, Delaney CP, Senagore AJ, Banbury MK, Remzi FH, Kiran RP, et al. Prospective assessment of the predictive value of alpha-glutathione S-transferase for intestinal ischemia. *Am Surg* 2003;**69**(4):324–9. discussion 9.
- 51 Block T, Nilsson TK, Björck M, Acosta S. Diagnostic accuracy of plasma biomarkers for intestinal ischaemia. *Scand J Clin Lab Invest* 2008;**68**(3):242–8.
- 52 Shi H, Wu B, Wan J, Liu W, Su B. The role of serum intestinal fatty acid binding protein levels and D-lactate levels in the diagnosis of acute intestinal ischemia. *Clin Res Hepatol Gastroenterol* 2015;**39**(3):373–8.
- 53 Acosta S, Block T, Björnsson S, Resch T, Björck M, Nilsson T. Diagnostic pitfalls at admission in patients with acute superior mesenteric artery occlusion. *J Emerg Med* 2012;**42**(6):635–41.
- 54 Park WM, Gloviczki P, Cherry Jr KJ, Hallett Jr JW, Bower TC, Panneton JM, et al. Contemporary management of acute mesenteric ischemia: factors associated with survival. *J Vasc Surg* 2002;**35**(3):445–52.
- 55 Lange H, Jackel R. Usefulness of plasma lactate concentration in the diagnosis of acute abdominal disease. *Eur J Surg* 1994;**160**(6–7):381–4.
- 56 Studer P, Vaucher A, Candinas D, Schnuriger B. The value of serial serum lactate measurements in predicting the extent of ischemic bowel and outcome of patients suffering acute mesenteric ischemia. *J Gastrointest Surg* 2015;**19**(4):751–5.
- 57 Meyer ZC, Schreinemakers JM, Mulder PG, de Waal RA, Ermens AA, van der Laan L. Determining the clinical value of lactate in surgical patients on the intensive care unit. *J Surg Res* 2013;**183**(2):814–20.
- 58 Jakob SM, Merasto-Minkinen M, Tenhunen JJ, Heino A, Alhava E, Takala J. Prevention of systemic hyperlactatemia during splanchnic ischemia. *Shock* 2000;**14**(2):123–7.
- 59 Menke J. Diagnostic accuracy of multidetector CT in acute mesenteric ischemia: systematic review and meta-analysis. *Radiology* 2010;**256**(1):93–101.
- 60 Oliva IB, Davarpanah AH, Rybicki FJ, Desjardins B, Flamm SD, Francois CJ, et al. ACR Appropriateness Criteria (R) imaging of mesenteric ischemia. *Abdom Imaging* 2013;**38**(4):714–9.

- 61 Wadman M, Block T, Ekberg O, Syk I, Elmstahl S, Acosta S. Impact of MDCT with intravenous contrast on the survival in patients with acute superior mesenteric artery occlusion. *Emerg Radiol* 2010;**17**(3):171–8.
- 62 Hunt SJ, Coakley FV, Webb EM, Westphalen AC, Poder L, Yeh BM. Computed tomography of the acute abdomen in patients with atrial fibrillation. *J Comp Assist Tomogr* 2009;**33**(2):280–5.
- 63 Acosta S, Björnsson S, Ekberg O, Resch T. CT angiography followed by endovascular intervention for acute superior mesenteric artery occlusion does not increase risk of contrast-induced renal failure. *Eur J Vasc Endovasc Surg* 2010;**39**(6):726–30.
- 64 Lehtimäki TT, Karkkainen JM, Saari P, Manninen H, Paajanen H, Vanninen R. Detecting acute mesenteric ischemia in CT of the acute abdomen is dependent on clinical suspicion: review of 95 consecutive patients. *Eur J Radiol* 2015;**84**(12):2444–53.
- 65 Firetto MC, Lemos AA, Marini A, Avesani EC, Biondetti PR. Acute bowel ischemia: analysis of diagnostic error by overlooked findings at MDCT angiography. *Emerg Radiol* 2013;**20**(2):139–47.
- 66 Blachar A, Barnes S, Adam SZ, Levy G, Weinstein I, Precel R, et al. Radiologists' performance in the diagnosis of acute intestinal ischemia, using MDCT and specific CT findings, using a variety of CT protocols. *Emerg Radiol* 2011;**18**(5):385–94.
- 67 Cudnik MT, Darbha S, Jones J, Macedo J, Stockton SW, Hiestand BC. The diagnosis of acute mesenteric ischemia: a systematic review and meta-analysis. *Acad Emerg Med* 2013;**20**(11):1087–100.
- 68 Barmase M, Kang M, Wig J, Kochhar R, Gupta R, Khandelwal N. Role of multidetector CT angiography in the evaluation of suspected mesenteric ischemia. *Eur J Radiol* 2011;**80**(3):e582–7.
- 69 Aschoff AJ, Stuber G, Becker BW, Hoffmann MH, Schmitz BL, Schelzig H, et al. Evaluation of acute mesenteric ischemia: accuracy of biphasic mesenteric multi-detector CT angiography. *Abdom Imaging* 2009;**34**(3):345–57.
- 70 Kirkpatrick ID, Kroeker MA, Greenberg HM. Biphasic CT with mesenteric CT angiography in the evaluation of acute mesenteric ischemia: initial experience. *Radiology* 2003;**229**(1):91–8.
- 71 Ofer A, Abadi S, Nitecki S, Karram T, Kogan I, Leiderman M, et al. Multidetector CT angiography in the evaluation of acute mesenteric ischemia. *Emerg Radiol* 2013;**20**:139–47.
- 72 Yikilmaz A, Karahan OI, Senol S, Tuna IS, Akyildiz HY. Value of multislice computed tomography in the diagnosis of acute mesenteric ischemia. *Eur J Radiol* 2011;**80**(2):297–302.
- 73 Ryer EJ, Kalra M, Oderich GS, Duncan AA, Gloviczki P, Cha S, et al. Revascularization for acute mesenteric ischemia. *J Vasc Surg* 2012;**55**(6):1682–9.
- 74 Yun WS, Lee KK, Cho J, Kim HK, Huh S. Treatment outcome in patients with acute superior mesenteric artery embolism. *Ann Vasc Surg* 2013;**27**(5):613–20.
- 75 Bingol H, Zeybek N, Cingoz F, Yilmaz AT, Tatar H, Sen D. Surgical therapy for acute superior mesenteric artery embolism. *Am J Surg* 2004;**188**(1):68–70.
- 76 Duran M, Pohl E, Grabitz K, Schelzig H, Sagban TA, Simon F. The importance of open emergency surgery in the treatment of acute mesenteric ischemia. *World J Emerg Surg* 2015;**10**:45.
- 77 Holdsworth RJ, Raza Z, Naidu S, McCollum PT. Mesenteric revascularisation for acute-on-chronic intestinal ischaemia. *Postgrad Med J* 1997;**73**(864):642–4.
- 78 Arthurs ZM, Titus J, Bannazadeh M, Eagleton MJ, Srivastava S, Sarac TP, et al. A comparison of endovascular revascularization with traditional therapy for the treatment of acute mesenteric ischemia. *J Vasc Surg* 2011;**53**(3):698–704. discussion-5.
- 79 Beaulieu RJ, Arnaoutakis KD, Abularrage CJ, Efron DT, Schneider E, Black 3rd JH. Comparison of open and endovascular treatment of acute mesenteric ischemia. *J Vasc Surg* 2014;**59**(1):159–64.
- 80 Bulkley GB, Zuidema GD, Hamilton SR, O'Mara CS, Klacsmann PG, Horn SD. Intraoperative determination of small intestinal viability following ischemic injury: a prospective, controlled trial of two adjuvant methods (Doppler and fluorescein) compared with standard clinical judgment. *Ann Surg* 1981;**193**(5):628–37.
- 81 Redaelli CA, Schilling MK, Buchler MW. Intraoperative laser Doppler flowmetry: a predictor of ischemic injury in acute mesenteric infarction. *Dig Surg* 1998;**15**(1):55–9.
- 82 Kalra M, Ryer EJ, Oderich GS, Duncan AA, Bower TC, Gloviczki P. Contemporary results of treatment of acute arterial mesenteric thrombosis: has endovascular treatment improved outcomes? *Perspect Vasc Surg Endovasc Ther* 2012;**24**(4):171–6.
- 83 Gonenc M, Dural CA, Kocatas A, Buyukasik S, Karabulut M, Alis H. The impact of early diagnostic laparoscopy on the prognosis of patients with suspected acute mesenteric ischemia. *Eur J Trauma Emerg Surg* 2013;**39**(2):185–9.
- 84 Kougiaris P, Lau D, El Sayed HF, Zhou W, Huynh TT, Lin PH. Determinants of mortality and treatment outcome following surgical interventions for acute mesenteric ischemia. *J Vasc Surg* 2007;**46**(3):467–74.
- 85 Björck M, Acosta S, Lindberg F, Troeng T, Bergqvist D. Revascularization of the superior mesenteric artery after acute thromboembolic occlusion. *Br J Surg* 2002;**89**(7):923–7.
- 86 Wong PF, Gilliam AD, Kumar S, Shenfine J, O'Dair GN, Leaper DJ. Antibiotic regimens for secondary peritonitis of gastrointestinal origin in adults. *The Cochrane Database Syst Rev* 2005;(2):CD004539.
- 87 Rotondo MF, Schwab CW, McGonigal MD, Phillips 3rd GR, Fruchterman TM, Kauder DR, et al. 'Damage control': an approach for improved survival in exsanguinating penetrating abdominal injury. *J Trauma* 1993;**35**(3):375–82. discussion 82–3.
- 88 Acosta S, Sonesson B, Resch T. Endovascular therapeutic approaches for acute superior mesenteric artery occlusion. *Cardiovasc Intervent Radiol* 2009;**32**(5):896–905.
- 89 Heiss P, Loewenhardt B, Manke C, Hellinger A, Dietl KH, Schlitt HJ, et al. Primary percutaneous aspiration and thrombolysis for the treatment of acute embolic superior mesenteric artery occlusion. *Eur Radiol* 2010;**20**(12):2948–58.
- 90 Raupach J, Lojik M, Chovanec V, Renc O, Strycek M, Dvorak P, et al. Endovascular management of acute embolic occlusion of the superior mesenteric artery: a 12-year single-centre experience. *Cardiovasc Intervent Radiol* 2016;**39**(2):195–203.
- 91 Choi KS, Kim JD, Kim HC, Min SI, Min SK, Jae HJ, et al. Percutaneous aspiration embolectomy using guiding catheter for the superior mesenteric artery embolism. *Korean J Radiol* 2015;**16**(4):736–43.
- 92 Kawasaki R, Miyamoto N, Oki H, Yamaguchi M, Okada T, Sugimura K, et al. Aspiration therapy for acute superior mesenteric artery embolism with an angled guiding sheath and guiding catheter. *J Vasc Intervent Radiol* 2014;**25**(4):635–9.

- 93 Björnsson S, Björck M, Block T, Resch T, Acosta S. Thrombolysis for acute occlusion of the superior mesenteric artery. *J Vasc Surg* 2011;**54**(6):1734–42.
- 94 Yanar F, Agcaoglu O, Sarici IS, Sivrikoz E, Ucar A, Yanar H, et al. Local thrombolytic therapy in acute mesenteric ischemia. *World J Emerg Surg* 2013;**8**(1):8.
- 95 Dias NV, Acosta S, Resch T, Sonesson B, Alhadad A, Malina M, et al. Mid-term outcome of endovascular revascularization for chronic mesenteric ischaemia. *Br J Surg* 2010;**97**(2):195–201.
- 96 Wyers MC, Powell RJ, Nolan BW, Cronenwett JL. Retrograde mesenteric stenting during laparotomy for acute occlusive mesenteric ischemia. *J Vasc Surg* 2007;**45**(2):269–75.
- 97 Blauw JT, Meerwaldt R, Brusse-Keizer M, Kolkman JJ, Gerrits D, Geelkerken RH, et al. Retrograde open mesenteric stenting for acute mesenteric ischemia. *J Vasc Surg* 2014;**60**(3):726–34.
- 98 Chen Y, Zhu J, Ma Z, Dai X, Fan H, Feng Z, et al. Hybrid technique to treat superior mesenteric artery occlusion in patients with acute mesenteric ischemia. *Exp Ther Med* 2015;**9**(6):2359–63.
- 99 Tallarita T, Oderich GS, Macedo TA, Gloviczki P, Misra S, Duncan AA, et al. Reinterventions for stent restenosis in patients treated for atherosclerotic mesenteric artery disease. *J Vasc Surg* 2011;**54**(5):1422–9. e1.
- 100 Tallarita T, Oderich GS, Gloviczki P, Duncan AA, Kalra M, Cha S, et al. Patient survival after open and endovascular mesenteric revascularization for chronic mesenteric ischemia. *J Vasc Surg* 2013;**57**(3):747–55. discussion 54–5.
- 101 Sharafuddin MJ, Nicholson RM, Kresowik TF, Amin PB, Hoballah JJ, Sharp WJ. Endovascular recanalization of total occlusions of the mesenteric and celiac arteries. *J Vasc Surg* 2012;**55**(6):1674–81.
- 102 Cholesterol Treatment Trialists' Collaboration, Baigent C, Blackwell L, Emberson J, Holland LE, Reith C, et al. Efficacy and safety of more intensive lowering of LDL cholesterol: a meta-analysis of data from 170,000 participants in 26 randomised trials. *Lancet* 2010;**376**(9753):1670–81.
- 103 Peeters Weem SM, van Haelst ST, den Ruijter HM, Moll FL, de Borst GJ. Lack of evidence for dual antiplatelet therapy after endovascular arterial procedures: a meta-analysis. *Eur J Vasc Endovasc Surg* 2016 Aug;**52**(2):253–62.
- 104 Menke J, Luthje L, Kastrup A, Larsen J. Thromboembolism in atrial fibrillation. *Am J Cardiol* 2010;**105**(4):502–10.
- 105 Sana A, van Noord D, Mensink PB, Kooij S, van Dijk K, Bravenboer B, et al. Patients with chronic gastrointestinal ischemia have a higher cardiovascular disease risk and mortality. *Atherosclerosis* 2012;**224**(1):235–41.
- 106 Hansen KJ, Wilson DB, Craven TE, Pearce JD, English WP, Edwards MS, et al. Mesenteric artery disease in the elderly. *J Vasc Surg* 2004;**40**(1):45–52.
- 107 Wilson DB, Mostafavi K, Craven TE, Ayerdi J, Edwards MS, Hansen KJ. Clinical course of mesenteric artery stenosis in elderly americans. *Arch Int Med* 2006;**166**(19):2095–100.
- 108 van Noord D, Kuipers EJ, Mensink PB. Single vessel abdominal arterial disease. *Best Practice Research Clin Gastroenterol* 2009;**23**(1):49–60.
- 109 Moneta GL, Lee RW, Yeager RA, Taylor Jr LM, Porter JM. Mesenteric duplex scanning: a blinded prospective study. *J Vasc Surg* 1993;**17**(1):79–84. discussion 5–6.
- 110 Zwolak RM, Fillinger MF, Walsh DB, LaBombard FE, Musson A, Darling CE, et al. Mesenteric and celiac duplex scanning: a validation study. *J Vasc Surg* 1998;**27**(6):1078–87. discussion 88.
- 111 van Petersen AS, Meerwaldt R, Kolkman JJ, Huisman AB, van der Palen J, van Bockel JH, et al. The influence of respiration on criteria for transabdominal duplex examination of the splanchnic arteries in patients with suspected chronic splanchnic ischemia. *J Vasc Surg* 2013;**57**(6):1603–11. 11 e1–10.
- 112 van Petersen AS, Kolkman JJ, Meerwaldt R, Huisman AB, van der Palen J, Zeebregts CJ, et al. Mesenteric stenosis, collaterals, and compensatory blood flow. *J Vasc Surg* 2014;**60**(1):111–9. 9 e1–2.
- 113 AbuRahma AF, Stone PA, Srivastava M, Dean LS, Keiffer T, Hass SM, et al. Mesenteric/cealic duplex ultrasound interpretation criteria revisited. *J J Vasc Surg* 2012;**55**(2):428–36. e6; discussion 35–6.
- 114 Oderich GS, Panneton JM, Macedo TA, Noel AA, Bower TC, Lee RA, et al. Intraoperative duplex ultrasound of visceral revascularizations: optimizing technical success and outcome. *J Vasc Surg* 2003;**38**(4):684–91.
- 115 Schaefer PJ, Pfarr J, Trentmann J, Wulff AM, Langer C, Siggelkow M, et al. Comparison of noninvasive imaging modalities for stenosis grading in mesenteric arteries. *RoFo* 2013;**185**(7):628–34.
- 116 Perko MJ, Just S, Schroeder TV. Importance of diastolic velocities in the detection of celiac and mesenteric artery disease by duplex ultrasound. *J Vasc Surg* 1997;**26**(2):288–93.
- 117 Bowersox JC, Zwolak RM, Walsh DB, Schneider JR, Musson A, LaBombard FE, et al. Duplex ultrasonography in the diagnosis of celiac and mesenteric artery occlusive disease. *J Vasc Surg* 1991;**14**(6):780–6. discussion 6–8.
- 118 Hodgkiss-Harlow K. Interpretation of visceral duplex scanning: before and after intervention for chronic mesenteric ischemia. *Semin Vasc Surg* 2013;**26**(2–3):127–32.
- 119 Almansa C, Bertani H, Noh KW, Wallace MB, Woodward TA, Raimondo M. The role of endoscopic ultrasound in the evaluation of chronic mesenteric ischaemia. *Dig Liver Dis* 2011;**43**(6):470–4.
- 120 Landis MS, Rajan DK, Simons ME, Hayeems EB, Kachura JR, Sniderman KW. Percutaneous management of chronic mesenteric ischemia: outcomes after intervention. *J Vasc Intervent Radiol* 2005;**16**(10):1319–25.
- 121 Horton KM, Talamini MA, Fishman EK. Median arcuate ligament syndrome: evaluation with CT angiography. *RadioGraphics* 2005;**25**(5):1177–82.
- 122 Meaney JF, Prince MR, Nostrant TT, Stanley JC. Gadolinium-enhanced MR angiography of visceral arteries in patients with suspected chronic mesenteric ischemia. *J Magn Reson Imaging* 1997;**7**(1):171–6.
- 123 Laissy JP, Trillaud H, Douek P. MR angiography: noninvasive vascular imaging of the abdomen. *Abdom Imaging* 2002;**27**(5):488–506.
- 124 Van Noord D, Sana A, Benaron DA, Pattynama PM, Verhagen HJ, Hansen BE, et al. Endoscopic visible light spectroscopy: a new, minimally invasive technique to diagnose chronic GI ischemia. *Gastrointest Endosc* 2011;**73**(2):291–8.
- 125 Van Noord D, Biermann K, Moons LM, Pattynama PM, Verhagen HJ, Kuipers EJ, et al. Histological changes in patients with chronic upper gastrointestinal ischaemia. *Histopathology* 2010;**57**(4):615–21.
- 126 Zacho HD, Abrahamsen J. Functional versus radiological assessment of chronic intestinal ischaemia. *Clin Physiol Funct Imaging* 2010;**30**(2):116–21.
- 127 Hansen HJ, Engell HC, Ring-Larsen H, Ranek L. Splanchnic blood flow in patients with abdominal angina before and after arterial reconstruction. A proposal for a diagnostic test. *Ann Surg* 1977;**186**(2):216–20.

- 128 Tsukuda T, Ito K, Koike S, Sasaki K, Shimizu A, Fujita T, et al. Pre- and postprandial alterations of portal venous flow: evaluation with single breath-hold three-dimensional half-Fourier fast spin-echo MR imaging and a selective inversion recovery tagging pulse. *J Magn Reson Imaging* 2005;**22**(4):527–33.
- 129 Groeneveld AB, Kolkman JJ. Splanchnic tonometry: a review of physiology, methodology, and clinical applications. *J Crit Care* 1994;**9**(3):198–210.
- 130 Knichwitz G, Rotker J, Mollhoff T, Richter KD, Brussel T. Continuous intramucosal PCO<sub>2</sub> measurement allows the early detection of intestinal malperfusion. *Crit Care Med* 1998;**26**(9):1550–7.
- 131 Otte JA, Oostveen E, Geelkerken RH, Groeneveld AB, Kolkman JJ. Exercise induces gastric ischemia in healthy volunteers: a tonometry study. *J Appl Physiol (1985)* 2001;**91**(2):866–71.
- 132 Otte JA, Geelkerken RH, Oostveen E, Mensink PB, Huisman AB, Kolkman JJ. Clinical impact of gastric exercise tonometry on diagnosis and management of chronic gastrointestinal ischemia. *Clin Gastroenterol Hepatol* 2005;**3**(7):660–6.
- 133 Sana A, Vergouwe Y, van Noord D, Moons LM, Pattynama PM, Verhagen HJ, et al. Radiological imaging and gastrointestinal tonometry add value in diagnosis of chronic gastrointestinal ischemia. *Clin Gastroenterol Hepatol* 2011;**9**(3):234–41.
- 134 Acosta S, Nilsson T. Current status on plasma biomarkers for acute mesenteric ischemia. *J Thromb Thrombolysis* 2012;**33**(4):355–61.
- 135 van Wijck K, Lenaerts K, van Loon LJ, Peters WH, Buurman WA, Dejong CH. Exercise-induced splanchnic hypoperfusion results in gut dysfunction in healthy men. *PLoS One* 2011;**6**(7):e22366.
- 136 Mensink PB, Hol L, Borghuis-Koertshuis N, Geelkerken RH, Huisman AB, Doelman CJ, et al. Transient postprandial ischemia is associated with increased intestinal fatty acid binding protein in patients with chronic gastrointestinal ischemia. *Eur J Gastroenterol Hepatol* 2009;**21**(3):278–82.
- 137 ter Steege RW, Sloterdijk HS, Geelkerken RH, Huisman AB, van der Palen J, Kolkman JJ. Splanchnic artery stenosis and abdominal complaints: clinical history is of limited value in detection of gastrointestinal ischemia. *World J Surg* 2012;**36**(4):793–9.
- 138 Turza KC, Drenitsky J, Sawyer RG. Nutrition issues in gastroenterology, Sept 009: Series #78, Ed: Parrish CR; 11–22.
- 139 Oderich GS, Bower TC, Sullivan TM, Bjarnason H, Cha S, Gloviczki P. Open versus endovascular revascularization for chronic mesenteric ischemia: risk-stratified outcomes. *J Vasc Surg* 2009;**49**(6):1472–9. e3.
- 140 Oderich GS, Gloviczki P, Bower TC. Open surgical treatment for chronic mesenteric ischemia in the endovascular era: when it is necessary and what is the preferred technique? *Semin Vasc Surg* 2010;**23**(1):36–46.
- 141 van Petersen AS, Kolkman JJ, Beuk RJ, Huisman AB, Doelman CJ, Geelkerken RH, et al. Open or percutaneous revascularization for chronic splanchnic syndrome. *J Vasc Surg* 2010;**51**(5):1309–16.
- 142 Moghadamyeghaneh Z, Carmichael JC, Mills SD, Dolich MO, Pigazzi A, Fujitani RM, et al. Early outcome of treatment of chronic mesenteric ischemia. *Am Surg* 2015;**81**(11):1149–56.
- 143 Kasirajan K, O'Hara PJ, Gray BH, Hertzner NR, Clair DG, Greenberg RK, et al. Chronic mesenteric ischemia: open surgery versus percutaneous angioplasty and stenting. *J Vasc Surg* 2001;**33**(1):63–71.
- 144 Assar AN, Abilez OJ, Zarins CK. Outcome of open versus endovascular revascularization for chronic mesenteric ischemia: review of comparative studies. *J Cardiovasc Surg* 2009;**50**(4):509–14.
- 145 Atkins MD, Kwolek CJ, LaMuraglia GM, Brewster DC, Chung TK, Cambria RP. Surgical revascularization versus endovascular therapy for chronic mesenteric ischemia: a comparative experience. *J Vasc Surg* 2007;**45**(6):1162–71.
- 146 Biebl M, Oldenburg WA, Paz-Fumagalli R, McKinney JM, Hakaim AG. Surgical and interventional visceral revascularization for the treatment of chronic mesenteric ischemia—when to prefer which? *World J Surg* 2007;**31**(3):562–8.
- 147 Gupta PK, Horan SM, Turaga KK, Miller WJ, Pipinos II. Chronic mesenteric ischemia: endovascular versus open revascularization. *J Endovasc Ther* 2010;**17**(4):540–9.
- 148 Indes JE, Giacovelli JK, Muhs BE, Sosa JA, Dardik A. Outcomes of endovascular and open treatment for chronic mesenteric ischemia. *J Endovasc Ther* 2009;**16**(5):624–30.
- 149 Oderich GS, Malgor RD, Ricotta 2nd JJ. Open and endovascular revascularization for chronic mesenteric ischemia: tabular review of the literature. *Ann Vasc Surg* 2009;**23**(5):700–12.
- 150 Rawat N, Gibbons CP, Joint Vascular Research Group. Surgical or endovascular treatment for chronic mesenteric ischemia: a multicenter study. *Ann Vasc Surg* 2010;**24**(7):935–45.
- 151 Rose SC, Quigley TM, Raker EJ. Revascularization for chronic mesenteric ischemia: comparison of operative arterial bypass grafting and percutaneous transluminal angioplasty. *J Vasc Intervent Radiol* 1995;**6**(3):339–49.
- 152 Sivamurthy N, Rhodes JM, Lee D, Waldman DL, Green RM, Davies MG. Endovascular versus open mesenteric revascularization: immediate benefits do not equate with short-term functional outcomes. *J Am Coll Surg* 2006;**202**(6):859–67.
- 153 Zerbib P, Lebuffe G, Sergent-Baudson G, Chamatan A, Massouille D, Lions C, et al. Endovascular versus open revascularization for chronic mesenteric ischemia: a comparative study. *Langenbecks Arch Surg* 2008;**393**(6):865–70.
- 154 Manunga JM, Oderich GS. Orbital atherectomy as an adjunct to debulk difficult calcified lesions prior to mesenteric artery stenting. *J Endovasc Ther* 2012;**19**(4):489–94.
- 155 Sarac TP, Altinel O, Kashyap V, Bena J, Lyden S, Srivastava S, et al. Endovascular treatment of stenotic and occluded visceral arteries for chronic mesenteric ischemia. *J Vasc Surg* 2008;**47**(3):485–91.
- 156 Malgor RD, Oderich GS, McKusick MA, Misra S, Kalra M, Duncan AA, et al. Results of single- and two-vessel mesenteric artery stents for chronic mesenteric ischemia. *Ann Vasc Surg* 2010;**24**(8):1094–101.
- 157 Silva JA, White CJ, Collins TJ, Jenkins JS, Andry ME, Reilly JP, et al. Endovascular therapy for chronic mesenteric ischemia. *J Am Coll Cardiol* 2006;**47**(5):944–50.
- 158 Peck MA, Conrad MF, Kwolek CJ, LaMuraglia GM, Paruchuri V, Cambria RP. Intermediate-term outcomes of endovascular treatment for symptomatic chronic mesenteric ischemia. *J Vasc Surg* 2010;**51**(1):140–7. e1–2.
- 159 Biebl M, Oldenburg WA, Paz-Fumagalli R, McKinney JM, Hakaim AG. Endovascular treatment as a bridge to successful surgical revascularization for chronic mesenteric ischemia. *Am Surg* 2004;**70**(11):994–8.
- 160 Wohlaer M, Kobeiter H, Desgranges P, Becquemin JP, Cochennec F. Inferior mesenteric artery stenting as a novel treatment for chronic mesenteric ischaemia in patients with an occluded superior mesenteric artery and celiac trunk. *Eur J Vasc Endovasc Surg* 2014;**27**(3):e21–3.

- 161 Oderich GS, Tallarita T, Gloviczki P, Duncan AA, Kalra M, Misra S, et al. Mesenteric artery complications during angioplasty and stent placement for atherosclerotic chronic mesenteric ischemia. *J Vasc Surg* 2012;**55**(4):1063–71.
- 162 Allen RC, Martin GH, Rees CR, Rivera FJ, Talkington CM, Garrett WV, et al. Mesenteric angioplasty in the treatment of chronic intestinal ischemia. *J Vasc Surg* 1996;**24**(3):415–21. discussion 21–3.
- 163 Hackworth CA, Leef JA. Percutaneous transluminal mesenteric angioplasty. *Surg Clin North Am* 1997;**77**(2):371–80.
- 164 Hallisey MJ, Deschaine J, Illescas FF, Sussman SK, Vine HS, Ohki SK, et al. Angioplasty for the treatment of visceral ischemia. *J Vasc Intervent Radiol* 1995;**6**(5):785–91.
- 165 Levy PJ, Haskell L, Gordon RL. Percutaneous transluminal angioplasty of splanchnic arteries: an alternative method to elective revascularisation in chronic visceral ischaemia. *Eur J Radiol* 1987;**7**(4):239–42.
- 166 Maspes F, Mazzetti di Pietralata G, Gandini R, Innocenzi L, Lupattelli L, Barzi F, et al. Percutaneous transluminal angioplasty in the treatment of chronic mesenteric ischemia: results and 3 years of follow-up in 23 patients. *Abdom Imaging* 1998;**23**(4):358–63.
- 167 Matsumoto AH, Tegtmeier CJ, Fitzcharles EK, Selby Jr JB, Tribble CG, Angle JF, et al. Percutaneous transluminal angioplasty of visceral arterial stenoses: results and long-term clinical follow-up. *J Vasc Intervent Radiol* 1995;**6**(2):165–74.
- 168 McShane MD, Proctor A, Spencer P, Cumberland DC, Welsh CL. Mesenteric angioplasty for chronic intestinal ischaemia. *Eur J Vasc Surg* 1992;**6**(3):333–6.
- 169 Nyman U, Ivancev K, Lindh M, Uher P. Endovascular treatment of chronic mesenteric ischemia: report of five cases. *Cardiovasc Intervent Radiol* 1998;**21**(4):305–13.
- 170 Odurny A, Sniderman KW, Colapinto RF. Intestinal angina: percutaneous transluminal angioplasty of the celiac and superior mesenteric arteries. *Radiology* 1988;**167**(1):59–62.
- 171 Roberts Jr L, Wertman Jr DA, Mills SR, Moore Jr AV, Heaston DK. Transluminal angioplasty of the superior mesenteric artery: an alternative to surgical revascularization. *Am J Roentgenol* 1983;**141**(5):1039–42.
- 172 Aksu C, Demirpolat G, Oran I, Demirpolat G, Parildar M, Memis A. Stent implantation in chronic mesenteric ischemia. *Acta Radiol* 2009;**50**(6):610–6.
- 173 Brown DJ, Schermerhorn ML, Powell RJ, Fillinger MF, Rzcuidlo EM, Walsh DB, et al. Mesenteric stenting for chronic mesenteric ischemia. *J Vasc Surg* 2005;**42**(2):268–74.
- 174 Daliri A, Grunwald C, Jobst B, Szucs-Farkas Z, Diehm NA, Kickuth R, et al. Endovascular treatment for chronic atherosclerotic occlusive mesenteric disease: is stenting superior to balloon angioplasty? *Vasa* 2010;**39**(4):319–24.
- 175 Fioole B, van de Rest HJ, Meijer JR, van Leersum M, van Koeverden S, Moll FL, et al. Percutaneous transluminal angioplasty and stenting as first-choice treatment in patients with chronic mesenteric ischemia. *J Vasc Surg* 2010;**51**(2):386–91.
- 176 Kougiass P, El Sayed HF, Zhou W, Lin PH. Management of chronic mesenteric ischemia. The role of endovascular therapy. *J Endovasc Ther* 2007;**14**(3):395–405.
- 177 Kougiass P, Huynh TT, Lin PH. Clinical outcomes of mesenteric artery stenting versus surgical revascularization in chronic mesenteric ischemia. *Int Angiol* 2009;**28**(2):132–7.
- 178 Matsumoto AH, Angle JF, Spinosa DJ, Hagspiel KD, Cage DL, Leung DA, et al. Percutaneous transluminal angioplasty and stenting in the treatment of chronic mesenteric ischemia: results and longterm followup. *J Am Coll Surg* 2002;**194**(1 Suppl):S22–31.
- 179 Gibbons CP, Roberts DE. Endovascular treatment of chronic arterial mesenteric ischemia: a changing perspective? *Semin Vasc Surg* 2010;**23**(1):47–53.
- 180 Schaefer PJ, Schaefer FK, Hinrichsen H, Jahnke T, Charalambous N, Heller M, et al. Stent placement with the monorail technique for treatment of mesenteric artery stenosis. *J Vasc Intervent Radiol* 2006;**17**(4):637–43.
- 181 Schaefer PJ, Schaefer FK, Mueller-Huelsbeck S, Jahnke T. Chronic mesenteric ischemia: stenting of mesenteric arteries. *Abdom Imaging* 2007;**32**(3):304–9.
- 182 Schoch DM, LeSar CJ, Joels CS, Erdoes LS, Sprouse LR, Fugate MW, et al. Management of chronic mesenteric vascular insufficiency: an endovascular approach. *J Am Coll Surg* 2011;**212**(4):668–75. discussion 75–7.
- 183 Ahanchi SS, Stout CL, Dahl TJ, Carty RL, Messerschmidt CA, Panneton JM. Comparative analysis of celiac versus mesenteric artery outcomes after angioplasty and stenting. *J Vasc Surg* 2013;**57**(4):1062–6.
- 184 Glasby MJ, Bolia A. Treatment of chronic mesenteric ischemia by subintimal angioplasty of an occluded superior mesenteric artery. *Eur J Vasc Endovasc Surg* 2007;**33**(6):676–8.
- 185 Oderich GS, Erdoes LS, Lesar C, Mendes BC, Gloviczki P, Cha S, et al. Comparison of covered stents versus bare metal stents for treatment of chronic atherosclerotic mesenteric arterial disease. *J Vasc Surg* 2013;**58**(5):1316–23.
- 186 Park WM, Cherry Jr KJ, Chua HK, Clark RC, Jenkins G, Harmsen WS, et al. Current results of open revascularization for chronic mesenteric ischemia: a standard for comparison. *J Vasc Surg* 2002;**35**(5):853–9.
- 187 Rits Y, Oderich GS, Bower TC, Miller DV, Cooper L, Ricotta 2nd JJ, et al. Interventions for mesenteric vasculitis. *J Vasc Surg* 2010;**51**(2):392–400. e2.
- 188 Fields CE, Bower TC, Cooper LT, Hoskin T, Noel AA, Panneton JM, et al. Takayasu's arteritis: operative results and influence of disease activity. *J Vasc Surg* 2006;**43**(1):64–71.
- 189 Kristensen SD, Knuuti J, Saraste A, Anker S, Bøtker HE, De Hert S, et al. 2014 ESC/ESA Guidelines on non-cardiac surgery: cardiovascular assessment and management: the Joint Task Force on non-cardiac surgery: cardiovascular assessment and management of the European Society of Cardiology (ESC) and the European Society of Anaesthesiology (ESA). *Eur Heart J* 2014;**35**(35):2383–431.
- 190 Milner R, Woo EY, Carpenter JP. Superior mesenteric artery angioplasty and stenting via a retrograde approach in a patient with bowel ischemia—a case report. *Vasc Endovasc Surg* 2004;**38**(1):89–91.
- 191 Pisimisis GT, Oderich GS. Technique of hybrid retrograde superior mesenteric artery stent placement for acute-on-chronic mesenteric ischemia. *Ann Vasc Surg* 2011;**25**(1):132. e7–11.
- 192 Farber MA, Carlin RE, Marston WA, Owens LV, Burnham SJ, Keagy BA. Distal thoracic aorta as inflow for the treatment of chronic mesenteric ischemia. *J Vasc Surg* 2001;**33**(2):281–7. discussion 7–8.
- 193 Mell MW, Acher CW, Hoch JR, Tefera G, Turnipseed WD. Outcomes after endarterectomy for chronic mesenteric ischemia. *J Vasc Surg* 2008;**48**(5):1132–8.
- 194 Lejay A, Georg Y, Tartaglia E, Creton O, Lucereau B, Thaveau F, et al. Chronic mesenteric ischemia: 20 year experience of open surgical treatment. *Eur J Vasc Endovasc Surg* 2015;**49**(5):587–92.

- 195 European Stroke O, Tendera M, Aboyans V, Bartelink ML, Baumgartner I, Clement D, et al. ESC guidelines on the diagnosis and treatment of peripheral artery diseases: document covering atherosclerotic disease of extracranial carotid and vertebral, mesenteric, renal, upper and lower extremity arteries: the Task Force on the Diagnosis and Treatment of Peripheral Artery Diseases of the European Society of Cardiology (ESC). *Eur Heart J* 2011;**32**(22):2851–906.
- 196 Baker AC, Chew V, Li CS, Lin TC, Dawson DL, Pevac WC, et al. Application of duplex ultrasound imaging in determining in-stent stenosis during surveillance after mesenteric artery revascularization. *J Vasc Surg* 2012;**56**(5):1364–71. discussion 71.
- 197 Lees TA. Improving quality of care by system change. *Br J Surg* 2008;**95**(12):1435–6.
- 198 Vascular Society of Great Britain and Ireland. *The provision of services for patients with vascular disease*. 2015 [https://www.vascularsociety.org.uk/\\_userfiles/pages/files/Resources/POVS%202015%20Final%20version.pdf](https://www.vascularsociety.org.uk/_userfiles/pages/files/Resources/POVS%202015%20Final%20version.pdf).
- 199 Ende N. Infarction of the bowel in cardiac failure. *New Engl J Med* 1958;**258**(18):879–81.
- 200 Kirkpatrick AW, Roberts DJ, De Waele J, Jaeschke R, Malbrain ML, De Keulenaer B, et al. Intra-abdominal hypertension and the abdominal compartment syndrome: updated consensus definitions and clinical practice guidelines from the World Society of the Abdominal Compartment Syndrome. *Intensive Care Med* 2013;**39**(7):1190–206.
- 201 Kolkman JJ, Mensink PB. Non-occlusive mesenteric ischaemia: a common disorder in gastroenterology and intensive care. *Best Practice Research Clin Gastroenterol* 2003;**17**(3):457–73.
- 202 Krack A, Richartz BM, Gastmann A, Greim K, Lotze U, Anker SD, et al. Studies on intragastric PCO<sub>2</sub> at rest and during exercise as a marker of intestinal perfusion in patients with chronic heart failure. *Eur J Heart Fail* 2004;**6**(4):403–7.
- 203 Rimbau V, Böckler D, Brunkwall J, Cao P, Chiesa R, Coppi G, et al. Editor's choice. Management of descending thoracic aorta diseases. Clinical practice guidelines of the European Society for Vascular Surgery. *Eur J Vasc Endovasc Surg* 2017;**53**(1):4–52.
- 204 Hagan PG, Nienaber CA, Isselbacher EM, Bruckman D, Karavite DJ, Russman PL, et al. The International Registry of Acute Aortic Dissection (IRAD): new insights into an old disease. *JAMA* 2000;**283**(7):897–903.
- 205 Djavani K, Wanhainen A, Valtysson J, Bjorck M. Colonic ischaemia and intra-abdominal hypertension following open repair of ruptured abdominal aortic aneurysm. *Br J Surg* 2009;**96**(6):621–7.
- 206 Moll FL, Powell JT, Fraedrich G, Verzini F, Haulon S, Waltham M, et al. Management of abdominal aortic aneurysms clinical practice guidelines of the European society for vascular surgery. *Eur J Vasc Endovasc Surg* 2011;**41**(Suppl 1): S1–58.
- 207 Groesdonk HV, Klingele M, Schlempp S, Bomberg H, Schmied W, Minko P, et al. Risk factors for nonocclusive mesenteric ischemia after elective cardiac surgery. *J Thorac Cardiovasc Surg* 2013;**145**(6):1603–10.
- 208 Groesdonk HV, Raffel M, Speer T, Bomberg H, Schmied W, Klingele M, et al. Elevated endothelin-1 level is a risk factor for nonocclusive mesenteric ischemia. *J Thorac Cardiovasc Surg* 2015;**149**(5):1436–42. e2.
- 209 Huwer H, Winning J, Straub U, Istringhaus H, Kalweit G. Clinically diagnosed nonocclusive mesenteric ischemia after cardiopulmonary bypass: retrospective study. *Vascular* 2004;**12**(2):114–20.
- 210 Leone M, Bechis C, Baumstarck K, Ouattara A, Collange O, Augustin P, et al. Outcome of acute mesenteric ischemia in the intensive care unit: a retrospective, multicenter study of 780 cases. *Intensive Care Med* 2015;**41**(4):667–76.
- 211 Kwok HC, Dirkwager I, Duncan DS, Gillham MJ, Milne DG. The accuracy of multidetector computed tomography in the diagnosis of non-occlusive mesenteric ischaemia in patients after cardiovascular surgery. *Crit Care Resusc* 2014;**16**(2):90–5.
- 212 Woodhams R, Nishimaki H, Fujii K, Kakita S, Hayakawa K. Usefulness of multidetector-row CT (MDCT) for the diagnosis of non-occlusive mesenteric ischemia (NOMI): assessment of morphology and diameter of the superior mesenteric artery (SMA) on multi-planar reconstructed (MPR) images. *Eur J Radiol* 2010;**76**(1):96–102.
- 213 Nakamura Y, Urashima M, Toyota N, Ono C, Iida M, Fukumoto W, et al. Non-occlusive mesenteric ischemia (NOMI): utility of measuring the diameters of the superior mesenteric artery and superior mesenteric vein at multi-detector CT. *Jpn J Radiol* 2013;**31**:737–43.
- 214 Minko P, Stroeder J, Groesdonk HV, Graeber S, Klingele M, Buecker A, et al. A scoring-system for angiographic findings in nonocclusive mesenteric ischemia (NOMI): correlation with clinical risk factors and its predictive value. *Cardiovasc Intervent Radiol* 2014;**37**(3):657–63.
- 215 Siegelman SS, Sprayregen S, Boley SJ. Angiographic diagnosis of mesenteric arterial vasoconstriction. *Radiology* 1974;**112**(3):533–42.
- 216 Trompeter M, Brazda T, Remy CT, Vestring T, Reimer P. Non-occlusive mesenteric ischemia: etiology, diagnosis, and interventional therapy. *Eur Radiol* 2002;**12**(5):1179–87.
- 217 Bjorck M, Bergqvist D, Troeng T. Incidence and clinical presentation of bowel ischaemia after aortoiliac surgery—2930 operations from a population-based registry in Sweden. *Eur J Vasc Endovasc Surg* 1996;**12**(2):139–44.
- 218 Cappell MS, Mahajan D, Kurupath V. Characterization of ischemic colitis associated with myocardial infarction: an analysis of 23 patients. *Am J Med* 2006;**119**(6):527. e1–9.
- 219 Kaser SA, Muller TC, Guggemos A, Nitsche U, Spath C, Maurer CA, et al. Outcome after surgery for acute right-sided colonic ischemia without feasible vascular intervention: a single center experience of 58 patients over 6 years. *BMC Surg* 2015;**15**:31.
- 220 Acosta S, Ogren M, Sternby NH, Bergqvist D, Bjorck M. Fatal colonic ischemia: a population-based study. *Scand J Gastroenterol* 2006;**41**(11):1312–9.
- 221 Quiroga B, Verde E, Abad S, Vega A, Goicoechea M, Reque J, et al. Detection of patients at high risk for non-occlusive mesenteric ischemia in hemodialysis. *J Surg Res* 2013;**180**(1): 51–5.
- 222 Ori Y, Chagnac A, Schwartz A, Herman M, Weinstein T, Zevin D, et al. Non-occlusive mesenteric ischemia in chronically dialyzed patients: a disease with multiple risk factors. *Nephron Clin Pract* 2005;**101**:87–93.
- 223 Muschitz GK, Fochtman A, Keck M, Ihra GC, Mittlbock M, Lang S, et al. Non-occlusive mesenteric ischaemia: the prevalent cause of gastrointestinal infarction in patients with severe burn injuries. *Injury* 2015;**46**(1):124–30.
- 224 Bjorck M, Wanhainen A. Management of abdominal compartment syndrome and the open abdomen. *Eur J Vasc Endovasc Surg* 2014;**47**(3):279–87.
- 225 Acosta S, Bjork M. Mesenteric vascular disease: venous thrombosis. In: Cronenwett J, editor. *Rutherford's vascular surgery*. 8th ed. Saunders; 2014. p. 2414–20 [Chapter 154].



- 226 Sastry P, Hardman G, Page A, Parker R, Goddard M, Large S, et al. Mesenteric ischaemia following cardiac surgery: the influence of intraoperative perfusion parameters. *Interact Cardiovasc Thorac Surg* 2014;**19**(3):419–24.
- 227 De Waele JJ, Kimball E, Malbrain M, Nesbitt I, Cohen J, Kaloiani V, et al. Decompressive laparotomy for abdominal compartment syndrome. *Br J Surg* 2016;**103**:709–15.
- 228 Mitsuyoshi A, Obama K, Shinkura N, Ito T, Zaima M. Survival in nonocclusive mesenteric ischemia: early diagnosis by multi-detector row computed tomography and early treatment with continuous intravenous high-dose prostaglandin E(1). *Ann Surg* 2007;**246**(2):229–35.
- 229 Kozuch PL, Brandt LJ. Review article: diagnosis and management of mesenteric ischaemia with an emphasis on pharmacotherapy. *Aliment Pharmacol Ther* 2005;**21**(3):201–15.
- 230 Elliot JW. II. The operative relief of gangrene of intestine due to occlusion of the mesenteric vessels. *Ann Surg* 1895;**21**(1):9–23.
- 231 Warren S, Eberhardt TP. Mesenteric venous thrombosis. *Surg Gynecol Obstet* 1935;**61**:102–20.
- 232 DeLeve LD, Valla DC, Garcia-Tsao G. American Association for the study liver diseases. Vascular disorders of the liver. *Hepatology* 2009;**49**(5):1729–64.
- 233 De Stefano V, Martinelli I. Abdominal thromboses of splanchnic, renal and ovarian veins. *Best Practice Research Clin Haematol* 2012;**25**(3):253–64.
- 234 Thatipelli MR, McBane RD, Hodge DO, Wysokinski WE. Survival and recurrence in patients with splanchnic vein thromboses. *Clin Gastroenterol Hepatol* 2010;**8**(2):200–5.
- 235 Bobadilla JL. Mesenteric ischemia. *Surg Clin North Am* 2013;**93**(4):925–40. ix.
- 236 Hamoud B, Singal AK, Kamath PS. Mesenteric venous thrombosis. *J Clin Exp Haematol* 2014;**4**(3):257–63.
- 237 Primignani M. Portal vein thrombosis, revisited. *Dig Liver Dis* 2010;**42**(3):163–70.
- 238 Morasch MD, Ebaugh JL, Chiou AC, Matsumura JS, Pearce WH, Yao JS. Mesenteric venous thrombosis: a changing clinical entity. *J Vasc Surg* 2001;**34**(4):680–4.
- 239 Acosta S, Alhadad A, Svensson P, Ekberg O. Epidemiology, risk and prognostic factors in mesenteric venous thrombosis. *Br J Surg* 2008;**95**(10):1245–51.
- 240 Acosta S, Ogren M, Sternby NH, Bergqvist D, Björck M. Mesenteric venous thrombosis with transmural intestinal infarction: a population-based study. *J Vasc Surg* 2005;**41**(1):59–63.
- 241 Violi NV, Schoepfer AM, Fournier N, Guiu B, Bize P, Denys A, et al. Prevalence and clinical importance of mesenteric venous thrombosis in the Swiss inflammatory bowel disease cohort. *Am J Roentgenol* 2014;**203**(1):62–9.
- 242 Svensson PJ, Dahlback B. Resistance to activated protein C as a basis for venous thrombosis. *New Engl J Med* 1994;**330**(8):517–22.
- 243 Colaizzo D, Amitrano L, Tiscia GL, Scenna G, Grandone E, Guardascione MA, et al. The JAK2 V617F mutation frequently occurs in patients with portal and mesenteric venous thrombosis. *J Thromb Haemost* 2007;**5**(1):55–61.
- 244 De Stefano V, Fiorini A, Rossi E, Za T, Farina G, Chiusolo P, et al. Incidence of the JAK2 V617F mutation among patients with splanchnic or cerebral venous thrombosis and without overt chronic myeloproliferative disorders. *J Thromb Haemost* 2007;**5**(4):708–14.
- 245 Kiladjian JJ, Cervantes F, Leebeek FW, Marzac C, Cassinat B, Chevret S, et al. The impact of JAK2 and MPL mutations on diagnosis and prognosis of splanchnic vein thrombosis: a report on 241 cases. *Blood* 2008;**111**(10):4922–9.
- 246 Dentali F, Squizzato A, Brivio L, Appio L, Campiotti L, Crowther M, et al. JAK2V617F mutation for the early diagnosis of Ph- myeloproliferative neoplasms in patients with venous thromboembolism: a meta-analysis. *Blood* 2009;**113**(22):5617–23.
- 247 Dourakis SP, Tsochatzis E, Alexopoulou A, Archimandritis AJ. Pylephlebitis complicating silent diverticulitis. *Lancet* 2006;**368**(9533):422.
- 248 Condat B, Pessione F, Helene Denninger M, Hillaire S, Valla D. Recent portal or mesenteric venous thrombosis: increased recognition and frequent recanalization on anticoagulant therapy. *Hepatology* 2000;**32**(3):466–70.
- 249 Amitrano L, Brancaccio V, Guardascione MA, Margaglione M, Iannaccone L, Dandrea G, et al. High prevalence of thrombophilic genotypes in patients with acute mesenteric vein thrombosis. *Am J Gastroenterol* 2001;**96**(1):146–9.
- 250 Amitrano L, Guardascione MA, Scaglione M, Pezzullo L, Sangiuliano N, Armellino MF, et al. Prognostic factors in noncirrhotic patients with splanchnic vein thromboses. *Am J Gastroenterol* 2007;**102**(11):2464–70.
- 251 Tait C, Baglin T, Watson H, Laffan M, Makris M, Perry D, et al. Guidelines on the investigation and management of venous thrombosis at unusual sites. *Br J Haematol* 2012;**159**(1):28–38.
- 252 Choudhry AJ, Baghdadi YM, Amr MA, Alzghari MJ, Jenkins DH, Zielinski MD. Pylephlebitis: a review of 95 cases. *J Gastrointest Surg* 2016;**20**(3):656–61.
- 253 Rajesh S, Mukund A, Arora A. Imaging diagnosis of splanchnic venous thrombosis. *Gastroenterol Res Pract* 2015;**2015**:101029.
- 254 Wayne E, Ough M, Wu A, Liao J, Andresen KJ, Kuehn D, et al. Management algorithm for pneumatosis intestinalis and portal venous gas: treatment and outcome of 88 consecutive cases. *J Gastrointest Surg* 2010;**14**(3):437–48.
- 255 Acosta S, Alhadad A, Ekberg O. Findings in multi-detector row CT with portal phase enhancement in patients with mesenteric venous thrombosis. *Emerg Radiol* 2009;**16**(6):477–82.
- 256 Virmani V, Ramanathan S, Virmani VS, Kielar A, Sheikh A, Ryan J. Non-neoplastic hepatic vascular diseases: spectrum of CT and MRI appearances. *Clin Radiol* 2014;**69**(5):538–48.
- 257 Brunaud L, Antunes L, Collinet-Adler S, Marchal F, Ayav A, Bresler L, et al. Acute mesenteric venous thrombosis: case for nonoperative management. *J Vasc Surg* 2001;**34**(4):673–9.
- 258 Yang S, Fan X, Ding W, Liu B, Meng J, Xu D, et al. Multidisciplinary stepwise management strategy for acute superior mesenteric venous thrombosis: an intestinal stroke center experience. *Thromb Res* 2015;**135**(1):36–45.
- 259 Grisham A, Lohr J, Guenther JM, Engel AM. Deciphering mesenteric venous thrombosis: imaging and treatment. *Vasc Endovasc Surg* 2005;**39**(6):473–9.
- 260 Kearon C, Akl EA, Comerota AJ, Prandoni P, Bounameaux H, Goldhaber SZ, et al. Antithrombotic therapy for VTE disease: antithrombotic therapy and prevention of thrombosis, 9th ed: American College of chest physicians evidence-based clinical practice guidelines. *Chest* 2012;**141**(2 Suppl):e419S–494.
- 261 Condat B, Pessione F, Hillaire S, Denninger MH, Guillin MC, Poliquin M, et al. Current outcome of portal vein thrombosis in adults: risk and benefit of anticoagulant therapy. *Gastroenterology* 2001;**120**(2):490–7.
- 262 Dentali F, Ageno W, Witt D, Malato A, Clark N, Garcia D, et al. Natural history of mesenteric venous thrombosis in patients treated with vitamin K antagonists: a multi-centre, retrospective cohort study. *Thromb Haemost* 2009;**102**(3):501–4.

- 263 Semiz-Oysu A, Keussen I, Cwikiel W. Interventional radiological management of prehepatic obstruction of [corrected] the splanchnic venous system. *Cardiovasc Intervent Radiol* 2007;**30**(4):688–95.
- 264 Walser EM, McNees SW, DeLa Pena O, Crow WN, Morgan RA, Soloway R, et al. Portal venous thrombosis: percutaneous therapy and outcome. *J Vasc Intervent Radiol* 1998;**9**(1 Pt 1):119–27.
- 265 Ganger DR, Klapman JB, McDonald V, Matalon TA, Kaur S, Rosenblate H, et al. Transjugular intrahepatic portosystemic shunt (TIPS) for Budd-Chiari syndrome or portal vein thrombosis: review of indications and problems. *Am J Gastroenterol* 1999;**94**(3):603–8.
- 266 Wang MQ, Liu FY, Duan F, Wang ZJ, Song P, Fan QS. Acute symptomatic mesenteric venous thrombosis: treatment by catheter-directed thrombolysis with transjugular intrahepatic route. *Abdom Imaging* 2011;**36**(4):390–8.
- 267 Takahashi N, Kuroki K, Yanaga K. Percutaneous transhepatic mechanical thrombectomy for acute mesenteric venous thrombosis. *J Endovasc Ther* 2005;**12**(4):508–11.
- 268 Zhou W, Choi L, Lin PH, Dardik A, Eraso A, Lumsden AB. Percutaneous transhepatic thrombectomy and pharmacologic thrombolysis of mesenteric venous thrombosis. *Vascular* 2007;**15**(1):41–5.
- 269 Di Minno MN, Milone F, Milone M, Iaccarino V, Venetucci P, Lupoli R, et al. Endovascular thrombolysis in acute mesenteric vein thrombosis: a 3-year follow-up with the rate of short and long-term sequelae in 32 patients. *Thromb Res* 2010;**126**(4):295–8.
- 270 Hollingshead M, Burke CT, Mauro MA, Weeks SM, Dixon RG, Jaques PF. Transcatheter thrombolytic therapy for acute mesenteric and portal vein thrombosis. *J Vasc Intervent Radiol* 2005;**16**(5):651–61.
- 271 Freeman AJ, Graham JC. Damage control surgery and angiography in cases of acute mesenteric ischaemia. *ANZ J Surg* 2005;**75**(5):308–14.
- 272 Plessier A, Darwish-Murad S, Hernandez-Guerra M, Consigny Y, Fabris F, Trebicka J, et al. Acute portal vein thrombosis unrelated to cirrhosis: a prospective multicenter follow-up study. *Hepatology* 2010;**51**(1):210–8.
- 273 Ageno W, Riva N, Schulman S, Beyer-Westendorf J, Bang SM, Senzolo M, et al. Long-term clinical outcomes of splanchnic vein thrombosis: results of an international registry. *JAMA Int Med* 2015;**175**(9):1474–80.
- 274 Bauer KA. Duration of anticoagulation: applying the guidelines and beyond. *Hematol Am Soc Hematol Educ Program* 2010;**2010**:210–5.
- 275 Rajani R, Melin T, Bjornsson E, Broome U, Sangfelt P, Danielsson A, et al. Budd-Chiari syndrome in Sweden: epidemiology, clinical characteristics and survival - an 18-year experience. *Liver Int* 2009;**29**(2):253–9.
- 276 Kim EN, Lamb K, Relles D, Moudgill N, DiMuzio PJ, Eisenberg JA. Median arcuate ligament syndrome-review of this rare disease. *JAMA Surg* 2016;**151**(5):471–7.
- 277 Carr SC, Mahvi DM, Hoch JR, Archer CW, Turnipseed WD. Visceral artery aneurysm rupture. *J Vasc Surg* 2001;**33**(4):806–11.
- 278 Gabelmann A, Gorich J, Merkle EM. Endovascular treatment of visceral artery aneurysms. *J Endovasc Ther* 2002;**9**(1):38–47.
- 279 Pitton MB, Dappa E, Jungmann F, Kloeckner R, Schotten S, Wirth GM, et al. Visceral artery aneurysms: incidence, management, and outcome analysis in a tertiary care center over one decade. *Eur Radiol* 2015;**25**(7):2004–14.
- 280 Ghariani MZ, Georg Y, Ramirez C, Lebiad E, Gaudric J, Chiche L, et al. Long-term results of surgical treatment of aneurysms of digestive arteries. *Ann Vasc Surg* 2013;**27**(7):954–8.
- 281 Nanez L, Knowles M, Modrall JG, Valentine RJ. Ruptured splenic artery aneurysms are exceedingly rare in pregnant women. *J Vasc Surg* 2014;**60**(6):1520–3.
- 282 Stone WM, Abbas M, Cherry KJ, Fowl RJ, Gloviczki P. Superior mesenteric artery aneurysms: is presence an indication for intervention. *J Vasc Surg* 2002;**36**(2):234–7. discussion 7.
- 283 Muscari F, Barret A, Chaufour X, Bossavy JP, Bloom E, Pradere B, et al. Management of visceral artery aneurysms. Retrospective study of 23 cases. *Ann Chir* 2002;**127**(4):281–8.
- 284 Pulli R, Dorigo W, Troisi N, Pratesi G, Innocenti AA, Pratesi C. Surgical treatment of visceral artery aneurysms: a 25-year experience. *J Vasc Surg* 2008;**48**(2):334–42.
- 285 Sachdev U, Baril DT, Ellozy SH, Lookstein RA, Silverberg D, Jacobs TS, et al. Management of aneurysms involving branches of the celiac and superior mesenteric arteries: a comparison of surgical and endovascular therapy. *J Vasc Surg* 2006;**44**(4):718–24.
- 286 Sessa C, Tinelli G, Porcu P, Aubert A, Thony F, Magne JL. Treatment of visceral artery aneurysms: description of a retrospective series of 42 aneurysms in 34 patients. *Ann Vasc Surg* 2004;**18**(6):695–703.
- 287 Cron DC, Coleman DM, Sheetz KH, Englesbe MJ, Waits SA. Aneurysms in abdominal organ transplant recipients. *J Vasc Surg* 2014;**59**(3):594–8.
- 288 Madhusudhan KS, Gamanagatti S, Garg P, Shalimar, Dash NR, Pal S, et al. Endovascular embolization of visceral artery pseudoaneurysms using modified injection technique with N-Butyl Cyanoacrylate glue. *J Vasc Intervent Radiol* 2015;**26**(11):1718–25.
- 289 Roberts KJ, McCulloch N, Forde C, Mahon B, Mangat K, Olliff SP, et al. Emergency treatment of haemorrhaging coeliac or mesenteric artery aneurysms and pseudoaneurysms in the era of endovascular management. *Eur J Vasc Endovasc Surg* 2015;**49**(4):382–9.
- 290 Dorigo W, Pulli R, Azas L, Fargion A, Angiletta D, Pratesi G, et al. Early and intermediate results of elective endovascular treatment of true visceral artery aneurysms. *Ann Vasc Surg* 2016;**30**:211–8.
- 291 Grottemeyer D, Duran M, Park EJ, Hoffmann N, Blondin D, Iskandar F, et al. Visceral artery aneurysms—follow-up of 23 patients with 31 aneurysms after surgical or interventional therapy. *Langenbecks Arch Surg* 2009;**394**(6):1093–100.
- 292 Kunzle S, Glenck M, Puipe G, Schadde E, Mayer D, Pfammatter T. Stent-graft repairs of visceral and renal artery aneurysms are effective and result in long-term patency. *J Vasc Intervent Radiol* 2013;**24**(7):989–96.
- 293 Lakin RO, Bena JF, Sarac TP, Shah S, Krajewski LP, Srivastava SD, et al. The contemporary management of splenic artery aneurysms. *J Vasc Surg* 2011;**53**(4):958–64. discussion 65.
- 294 Loffroy R, Rao P, Ota S, De Lin M, Kwak BK, Krause D, et al. Packing technique for endovascular coil embolisation of peripheral arterial pseudoaneurysms with preservation of the parent artery: safety, efficacy and outcomes. *Eur J Vasc Endovasc Surg* 2010;**40**(2):209–15.
- 295 Shukla AJ, Eid R, Fish L, Avgerinos E, Marone L, Makaroun M, et al. Contemporary outcomes of intact and ruptured visceral artery aneurysms. *J Vasc Surg* 2015;**61**(6):1442–7.
- 296 Tulsyan N, Kashyap VS, Greenberg RK, Sarac TP, Clair DG, Pierce G, et al. The endovascular management of visceral artery aneurysms and pseudoaneurysms. *J Vasc Surg* 2007;**45**(2):276–83. discussion 83.

- 297 Corey MR, Ergul EA, Cambria RP, English SJ, Patel VI, Lancaster RT, et al. The natural history of splanchnic artery aneurysms and outcomes after operative intervention. *J Vasc Surg* 2016;**63**(4):949–57.
- 298 Abbas MA, Stone WM, Fowl RJ, Gloviczki P, Oldenburg WA, Pairolero PC, et al. Splenic artery aneurysms: two decades experience at Mayo clinic. *Ann Vasc Surg* 2002;**16**(4):442–9.
- 299 Wagner WH, Allins AD, Treiman RL, Cohen JL, Foran RF, Levin PM, et al. Ruptured visceral artery aneurysms. *Ann Vasc Surg* 1997;**11**(4):342–7.
- 300 Angelakis EJ, Bair WE, Barone JE, Lincer RM. Splenic artery aneurysm rupture during pregnancy. *Obstet Gynecol Surv* 1993;**48**(3):145–8.
- 301 Stanley JC, Wakefield TW, Graham LM, Whitehouse Jr WM, Zelenock GB, Lindenauer SM. Clinical importance and management of splanchnic artery aneurysms. *J Vasc Surg* 1986;**3**(5):836–40.
- 302 Lee PC, Rhee RY, Gordon RY, Fung JJ, Webster MW. Management of splenic artery aneurysms: the significance of portal and essential hypertension. *J Am Coll Surg* 1999;**189**(5):483–90.
- 303 Corey EK, Harvey SA, Sauvage LM, Bohrer JC. A case of ruptured splenic artery aneurysm in pregnancy. *Case Rep Obstet Gynecol* 2014;**2014**:793735.
- 304 Guillon R, Garcier JM, Abergel A, Mofid R, Garcia V, Chahid T, et al. Management of splenic artery aneurysms and false aneurysms with endovascular treatment in 12 patients. *Cardiovasc Intervent Radiol* 2003;**26**(3):256–60.
- 305 Etezadi V, Gandhi RT, Benenati JF, Rochon P, Gordon M, Benenati MJ, et al. Endovascular treatment of visceral and renal artery aneurysms. *J Vasc Intervent Radiol* 2011;**22**(9):1246–53.
- 306 Zhang Y, Lu Q, Zhao Z, Bao J, Feng X, Feng R, et al. Multiple overlapping uncovered stents as an alternative flow-diverting strategy in the management of peripheral and visceral aneurysms. *J Vasc Surg* 2014;**60**(5):1209–17.
- 307 Iryo Y, Ikushima I, Hirai T, Yonenaga K, Yamashita Y. Evaluation of contrast-enhanced MR angiography in the follow-up of visceral arterial aneurysms after coil embolization. *Acta Radiol* 2013;**54**(5):493–7.
- 308 Garrett Jr HE. Options for treatment of spontaneous mesenteric artery dissection. *J Vasc Surg* 2014;**59**(5):1433–9. e1–2.
- 309 Luan JY, Guan X, Li X, Wang CM, Li TR, Zhang L, et al. Isolated superior mesenteric artery dissection in China. *J Vasc Surg* 2016;**63**(2):530–6.
- 310 Sakamoto I, Ogawa Y, Sueyoshi E, Fukui K, Murakami T, Uetani M. Imaging appearances and management of isolated spontaneous dissection of the superior mesenteric artery. *Eur J Radiol* 2007;**64**(1):103–10.
- 311 Yun WS, Kim YW, Park KB, Cho SK, Do YS, Lee KB, et al. Clinical and angiographic follow-up of spontaneous isolated superior mesenteric artery dissection. *Eur J Vasc Endovasc Radiol* 2009;**37**(5):572–7.