

Chapter 12

ENDODONTIC SURGERY

Steven G. Morrow and Richard A. Rubinstein

HISTORICAL PERSPECTIVE

Contrary to what many dentists think, endodontic surgery is not a concept developed in the twentieth century. The first recorded endodontic surgical procedure was the incision and drainage of an acute endodontic abscess performed by Aetius, a Greek physician–dentist, over 1,500 years ago.¹ Since then, endodontic surgery and endodontic surgical procedures have been developed and refined, a result of the valuable contributions of many pioneers in dentistry including Abulcasis, Fauchard, Hüllihan, Martin, Partisch, and Black.²

William Hunter's classic presentation "An Address on the Role of Sepsis and Antisepsis in Medicine," which was delivered to the Faculty of Medicine of McGill University in Montreal in 1910, had a major impact on dentistry and initiated the conflict of "focal infection," whose embers still smolder. As a result, the development of endodontics and endodontic surgery can best be characterized as both progressive and regressive. Tremendous strides were made in the development and application of endodontic surgical techniques, but the concepts involved in endodontic surgery were being severely attacked by the medical profession.²

Although Hunter's presentation initiated a major conflict, it turned out to be a blessing in the development of endodontics and endodontic surgery. The stimulus to form the American Association of Endodontists was in part the result of endodontic pioneers joining in mutual support to develop scientific evidence for their concepts.

The results of scientific investigation and the clinical application of the techniques and concepts developed during the second half of the twentieth century represent the basis of what is known and will be practiced into the twenty-first century. However, endodontic surgery is dynamic, and it is imperative that scientific investigation continue; concepts, techniques, and material used in endodontic surgery must be continually

evaluated and modified, and more emphasis must be placed on the assessment of long-term clinical outcomes.

CURRENT APPLICATION

During the last 20 years, endodontics has seen a dramatic shift in the application of periradicular surgery and the part it plays in the delivery of endodontic services. Previously, periradicular surgery was commonly considered the treatment of choice when nonsurgical treatment had failed or if existing restorative or prosthetic treatment would be endangered by orthograde treatment.³ Grossman et al included in a list of indications for endodontic surgery the presence of large and intruding periapical lesions, overfilled canals, incomplete apical root formation, and destruction of the apical constriction by overinstrumentation.⁴

The dental literature contains an abundance of clinical articles, scientific reports, and textbook chapters that provide extensive lists of indications for periradicular surgery. However, many of the previously accepted indications are no longer valid in light of current concepts of the biologic basis for endodontic treatment (Figure 12-1). Therefore, it must be recognized that periradicular surgery has become very selective in contemporary dental practice (Figures 12-2, 12-3, and 12-4). Moreover, it must be emphasized that the application of surgery must always be in the best interest of the patient and also within the realm of the expertise of the practitioner.

INDICATIONS

Several factors have resulted in a significant impact on the indications for and the application of endodontic surgery. According to the American Association of Endodontists, more than 14 million root canal treatments are done annually in the United States.⁵ Even though the success rate of nonsurgical endodontic

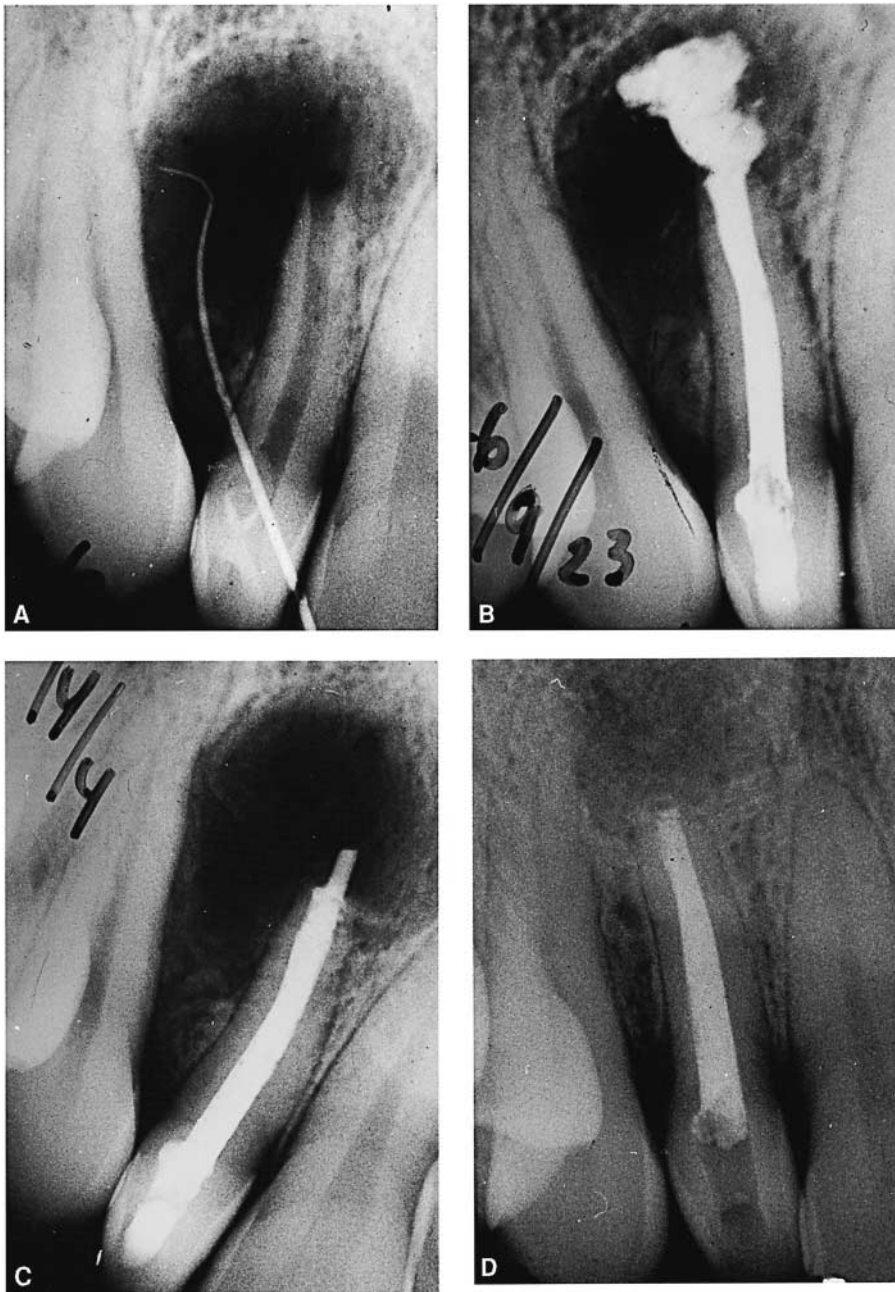


Figure 12-1 A, *Dens invaginatus* (*dens in dente*), with accompanying apical/lateral cyst. Patient is a 16-year-old girl. Gutta-percha sound placed through draining stoma. B, Calcium hydroxide [Ca(OH)₂] and iodoform (for contrast) paste fills débrided canal. C, Drainage ceased and Ca(OH)₂ resorbed away in 8 months. At this appointment, the canal was filled with gutta-percha and AH26 sealer. D, Follow-up radiograph 15 years after obturation. No surgery was done. (Courtesy of Dr. César C. Mexia de Almeida, Lisbon, Portugal.)

treatments is high, failures do occur. Many retrospective studies have established endodontic success rates, ranging from a high of 96% to a low of 53%.⁶⁻¹³ Additionally, in recent years, there has been an increasing interest in endodontic **re-treatment procedures** (see chapter 13). Studies reporting the success rate for **non-surgical re-treatment** indicate successes as low as 62% to as high as 98%.¹⁴⁻¹⁸ This emphasis on nonsurgical re-treatment of endodontic failures has probably had the single greatest impact on the indications for surgical intervention in the treatment of endodontic pathosis.

A classic categorization of specific indications and contraindications was developed by Luebke, Glick, and Ingle and has been modified for this chapter¹⁹ (Table

12-1). Even though these indications describe specific situations, they should not be considered “automatic” indications but should be applied as judgment and circumstances dictate.

CONTRAINDICATIONS

Few absolute contraindications to endodontic surgery exist. Most contraindications are relative, and they are usually limited to three areas: (1) the patient’s medical status, (2) anatomic considerations, and (3) the dentist’s skills and experience.

Advances in medicine have dramatically increased life expectancy and the survival rate from most of today’s diseases. Dentists are, with increasing frequen-

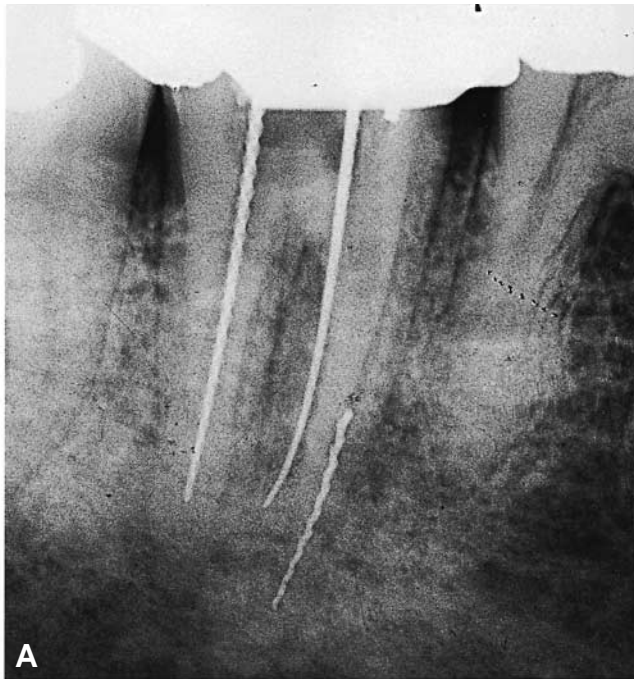
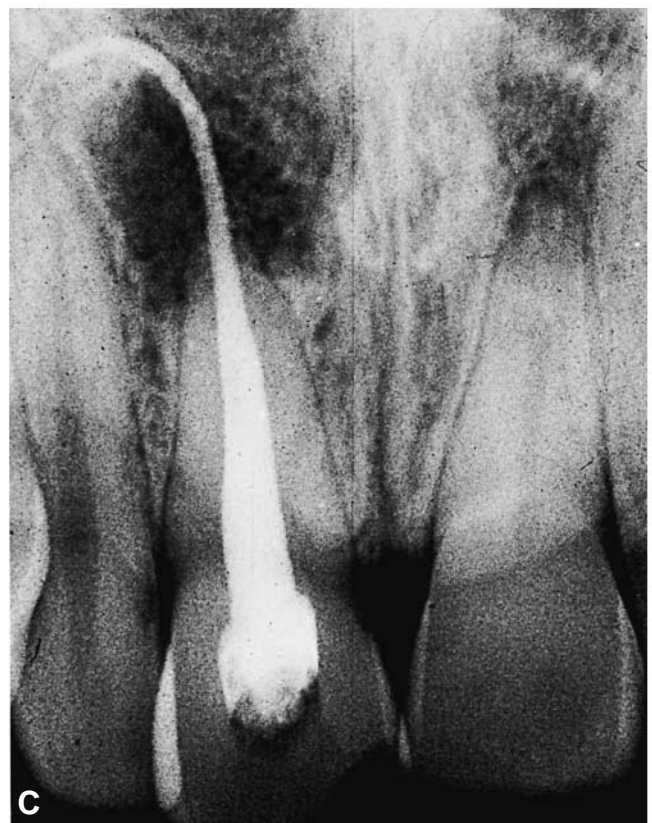
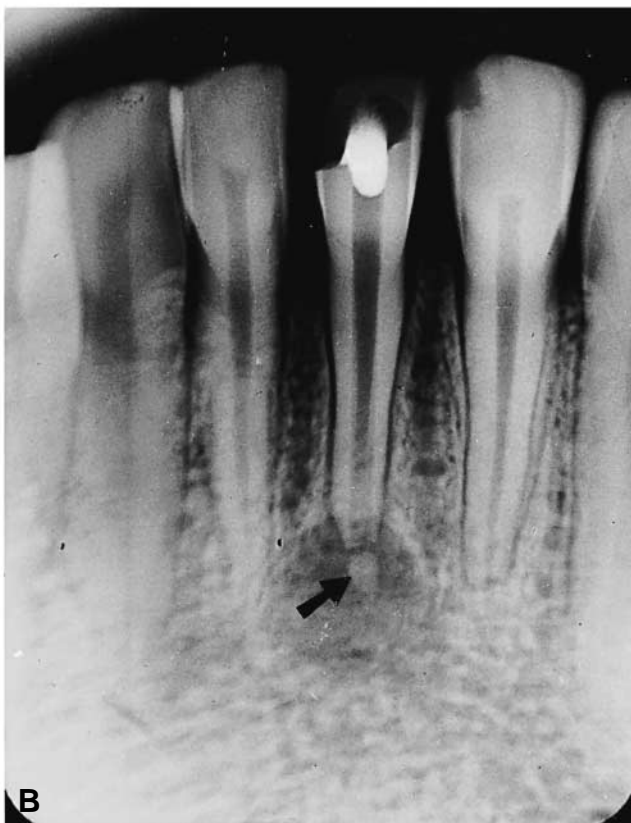
Figure 12-2 A, Fractured instrument protrudes past apical foramen of mesiolingual canal. B, Overinstrumentation has led to apical perforation and fracture of root tip (arrow) that must be removed surgically. C, Overextended gutta-percha filling caused physical irritation with pain and inflammation.



cy, being asked to treat medically compromised patients. When considering performing any surgical procedure on a patient who reports a major systems disorder (cardiovascular, respiratory, digestive, hepatic, renal, immune, or skeletomuscular), a thorough medical history is mandatory. Following the identification

of all potential medical complications and a review of the patient's current drug regimen, a consultation with the primary care physician or specialist may be in order. The dentist should explain to the physician the needed endodontic surgical treatment, including a brief description of the procedure, anesthetic agents

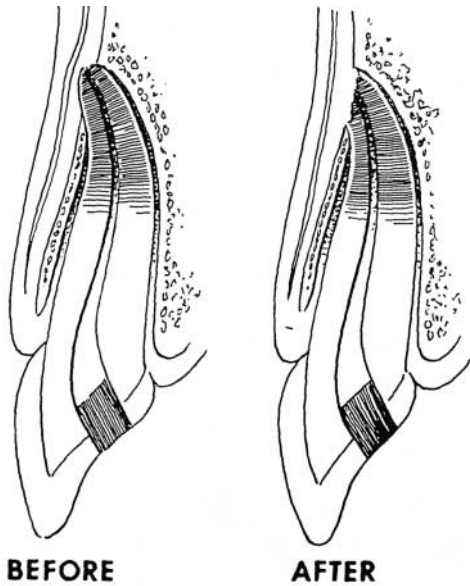


Figure 12-3 Beveling of the root apex to subcortical level relieves facial periradicular tenderness.

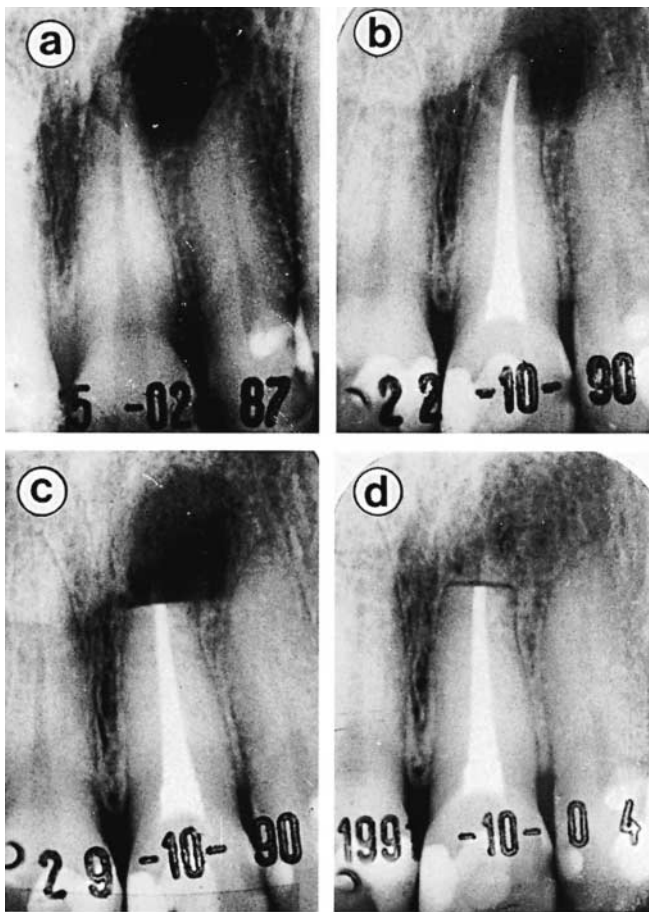


Figure 12-4 Cyst enucleation necessary to achieve healing. Longitudinal radiographs over 4 years and 9 months. a, Pretreatment. b, No healing 44 months after root filling. c, Apicoectomy and cyst enucleation. d, Complete healing 1 year later. Reproduced with permission from Nair PNR et al. Radicular cyst affecting a root-filled human tooth. *Int Endod J* 1993;26:225.

Table 12-1 Indications for Endodontic Surgery

1. Need for surgical drainage
2. Failed nonsurgical endodontic treatment
 1. Irretrievable root canal filling material
 2. Irretrievable intraradicular post
3. Calcific metamorphosis of the pulp space
4. Procedural errors
 1. Instrument fragmentation
 2. Non-negotiable ledging
 3. Root perforation
 4. Symptomatic overfilling
5. Anatomic variations
 - A. Root dilaceration
 - B. Apical root fenestration
6. Biopsy
7. Corrective surgery
 1. Root resorptive defects
 2. Root caries
 3. Root resection
 4. Hemisection
 5. Bicuspidization
8. Replacement surgery
 1. Replacement surgery
 1. Intentional replantation (extraction/replantation)
 2. Post-traumatic
 2. Implant surgery
 1. Endodontic
 2. Osseointegrated

and other drugs to be used, the approximate length of time required for the procedure, and the expected length of recovery. In this way, the physician can more adequately assess the medical risks involved and can assist the dentist in determining appropriate treatment modifications. These modifications may be preoperative (alteration of drug therapy, sedative or hypnotic, systemic antibiotics), intraoperative (nitrous oxide, intravenous sedation), or postoperative (reinstatement of drug therapy, sedatives, and analgesics).

Anatomic considerations are addressed in more detail later in this chapter. However, it should be emphasized that the majority of these anatomic considerations present contraindications that must be addressed for each individual patient. The major anatomic considerations of importance to endodontic surgery involve (1) the nasal floor, (2) the maxillary sinus, (3) the mandibular canal and its neurovascular bundle, (4) the mental foramen and its neurovascular bundle, and (5) anatomic limitations to adequate visual and mechanical access to the surgical site. A skilled

surgeon with the needed armamentarium is usually able to circumvent these anatomic limitations and accomplish successful endodontic surgery.

It is imperative that dental professionals keep in mind that all treatment rendered by them to their patients must be in the patients' best interest and at the highest quality possible. As a professional, one has an obligation to know one's limitations of clinical skills and to confine treatment efforts to be consistent with those limitations. Unless the general practitioner has had extensive surgical training and experience, the majority of endodontic surgical procedures should be done by trained endodontic specialists. When receiving care of a specialized nature, patients need and deserve treatment that meets the standard of care delivered by competent practitioners who are trained as specialists.¹⁹ The standard of care in dentistry is that practiced by the specialist in any given dental discipline.²⁰

CLASSIFICATION OF ENDODONTIC SURGICAL PROCEDURES

Endodontic surgery encompasses surgical procedures performed to remove the causative agents of periradicular pathosis and to restore the periodontium to a state of biologic and functional health. These procedures may be classified as follows:

1. Surgical drainage
 1. Incision and drainage (I & D)
 2. Cortical trephination (fistulative surgery)
2. Periradicular surgery
 1. Curettage
 2. Biopsy
 3. Root-end resection
 4. Root-end preparation and filling
 5. Corrective surgery
 1. Perforation repair
 - a. Mechanical (iatrogenic)
 - b. Resorptive (internal and external)
 2. Root resection
 3. Hemisection
3. Replacement surgery (extraction/replantation)
4. Implant surgery
 1. Endodontic implants
 2. Root-form osseointegrated implants

SURGICAL DRAINAGE

Surgical drainage is indicated when purulent and/or hemorrhagic exudate forms within the soft tissue or the alveolar bone as a result of a symptomatic periradicular abscess. A significant reduction of pain and a

decrease in the length of morbidity will follow the release of pressure and the evacuation of the by-products of inflammation and infection.²¹ Surgical drainage may be accomplished by (1) incision and drainage (I & D) of the soft tissue or (2) trephination of the alveolar cortical plate.

Incision and Drainage

Fluctuant soft-tissue swelling occurs when periradicular inflammatory exudate exits through the medullary bone and the cortical plate. Once through the cortical plate, the exudate spreads into the surrounding soft tissues. When this occurs, an incision should be made through the focal point of the localized swelling to relieve pressure, eliminate exudate and toxins, and stimulate healing. If the swelling is intraoral and localized, the infection may be managed by surgical drainage alone. However, if the swelling is diffuse or has spread into extraoral musculofascial tissues or spaces, surgical drainage should be supplemented with appropriate systemic antibiotic therapy.²² (Figure 12-5) (also see chapter 18, "Pharmacology for Endodontics").

Learning the correct timing for I & D takes experience. The patient often presents with a generalized, diffuse facial swelling that is indurated. Caution should always be exercised with hard swellings of this nature, especially when accompanied by a fever. Such an infection can extend into fascial planes and anatomic spaces and become life threatening. Consultation with, or referral to, an appropriate specialist may be indicated.

Unfortunately, incision into a diffuse or indurated swelling before its localization is often unsuccessful in affording immediate relief or reduction of the swelling. When this situation exists, it has been suggested that the patient be placed on appropriate systemic antibiotic therapy and instructed to use hot salt water "mouth holds" ($\frac{1}{4}$ – $\frac{1}{2}$ tsp of salt in a 10–12-oz glass of hot water) in the swollen area to assist in the localization of the swelling to a more fluctuant state. The clinical situation should be monitored every 24 hours. As soon as the swelling has localized and a fluctuant area has developed, surgical drainage should be performed.³

Incision and Drainage Tray Setup. The tray setup should be simple and uncluttered. The instruments and supplies needed for the procedure should be laid out in the order of their use (Figure 12-6).

Local Anesthesia. Whenever possible, nerve block injection is the preferable method for obtaining local anesthesia. In some cases, block injections must be supplemented with local infiltration to obtain adequate local anesthesia. In other clinical situations, block injections are either impossible or impractical and

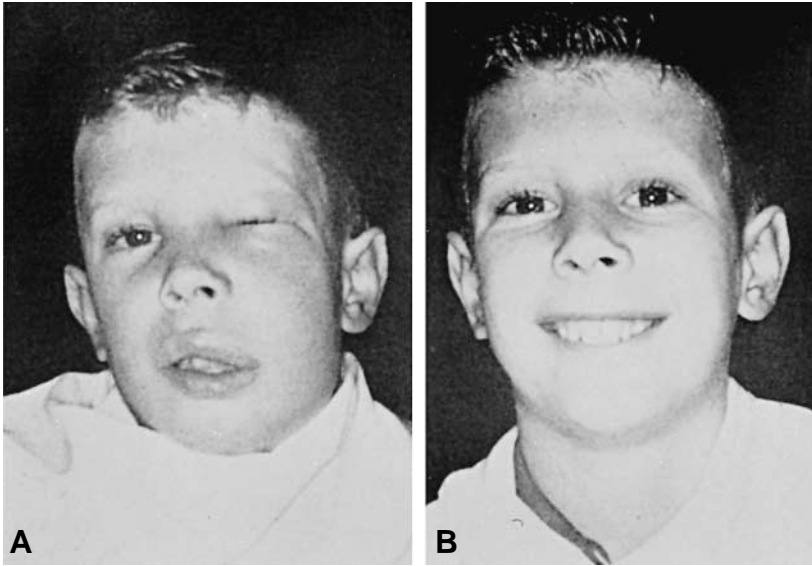


Figure 12-5 Rapid dissolution of massive cellulitis following incision and drainage and antibiotic therapy. **A**, Unilateral facial asymmetry and eye closure indicate severity of inflammatory edema from abscess, apical to maxillary lateral incisor. **B**, Five days later all signs of inflammation have vanished and patient is ready for root canal therapy. (Courtesy of Dr. Bertram L. Wolfshon.)

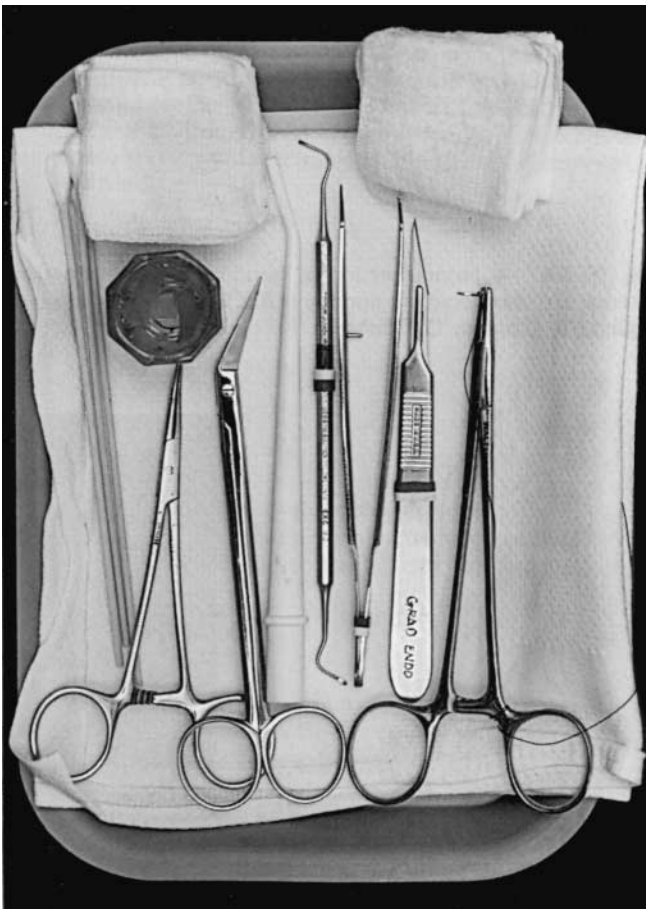

Figure 12-6 A well-organized incision and drainage (“I & D”) kit is essential for efficient accomplishment of drainage procedures. (Courtesy of Graduate Endodontics, Loma Linda University.)

anesthesia will be limited to local infiltration. When local infiltration is used, the oral mucosa in the area to be injected should be dried with 2×2 gauze and a topical anesthetic placed. Local anesthetic should be deposited peripheral to the swollen mucoperiosteal tissues. Injection directly into the swollen tissues should be avoided because it is painful, may cause spread of infection, and does not produce effective anesthesia.²

Inflammation results in the lowering of tissue pH, which effects alteration of the equilibrium of the injected anesthetic and a significant reduction in tissue concentration of the non-ionized form. Local anesthetics with low pKa values, such as mepivacaine, are the most effective in this clinical situation.²³ Patients should be warned that, as a result of the effects of inflammation and infection, local anesthesia may not eliminate all discomfort associated with this procedure. The discomfort, however, is usually minimal and transient in nature. The reduced effectiveness of local anesthetic agents to block pain transmissions in a site of inflammation has been well documented.^{24–26} Najjar has also demonstrated that inflammation in dental tissues can produce neurologic changes at distant sites along the nerve trunk, rendering local anesthetic less effective.²⁷ The use of nitrous oxide analgesia may be useful in reducing patient anxiety and lowering the pain threshold.

Incision. Following the administration of the appropriate block and/or infiltration anesthesia, the surgical area should be isolated with sterile 2×2 gauze sponges. The incision should be horizontal and placed at the dependent base of the fluctuant area. This will allow the greatest release (flow) of exudate. The incision should be made using a scalpel blade that is pointed,

such as a No. 11 or No. 12, rather than a rounded No. 15 blade. The exudate should be aspirated and, if indicated, a sample collected for bacteriologic culturing. Probing with a curette or hemostat into the incisional wound to release exudate entrapped in tissue compartments will facilitate a more effective result² (Figure 12-7).

Placement of a Drain. The use of drains following an I & D procedure is controversial. Frank et al. recommended the use of a rubber dam drain to maintain the patency of the surgical opening.³ McDonald and Hovland have stated that the incision alone will usually provide the needed drainage.²⁸ However, if initial drainage is limited, placement of a drain may be indicated. The drain may be made of either iodoform gauze or rubber dam material cut in an “H” or “Christmas tree” shape. It may be sutured in place for added retention and should be removed after 2 to 3 days. Bellizzi and Loushine recommended the use of a ¼-inch Penrose drain, which should be sutured in place and removed in 24 to 48 hours.²⁹

Gutmann and Harrison stated that the use of drains following I & D procedures has been greatly abused.² Patients with localized or diffuse intraoral swellings, even if mild extraoral swelling is present, do not usually require drains following I & D procedures. Healing will progress much more rapidly without insertion of an artificial barrier in the incisional wound site. The tissues should be allowed to close the incisional wound at their normal wound-healing pace, which is about 24 to 48 hours. When sufficient drainage has occurred, epithelial closure of the incisional wound will follow. The insertion of a drain is only indicated in cases presenting with moderate to severe cellulitis and other positive signs of an aggressive infective process.

Cortical Trephination

Cortical trephination is a procedure involving the perforation of the cortical plate to accomplish the release of pressure from the accumulation of exudate within the alveolar bone. This is a limited-use procedure and is fraught with peril and potential negative complications. Patients who present with moderate to severe pain but with no intraoral or extraoral swelling may require drainage of periradicular exudate to alleviate the acute symptoms. Literature pertaining to this procedure is very limited and consists primarily of case reports, opinions, and clinical experiences.² Two clinical studies have been reported on trephination procedures. However, they were both designed to investigate the efficacy of trephination in avoiding postobturation pain rather than in treating existing acute conditions.^{30,31} The treatment of choice for these patients is

drainage through the root canal system (apical trephination) whenever possible. This may involve the removal of intraradicular posts and/or existing root canal obturation material. Apical trephination involves penetration of the apical foramen with a small endodontic file and enlarging the apical opening to a size No. 20 or No. 25 file to allow drainage from the periradicular lesion into the canal space. The decision about whether to perform apical or cortical trephination is based primarily on clinical judgment regarding the urgency of obtaining drainage.

Cortical trephination involves making an incision through mucoperiosteal tissues and perforating through the cortical plate with a rotary instrument (Figure 12-8). Some practitioners prefer to lay a mucoperiosteal flap to expose the buccal/labial cortical plate before the trephination procedure. The objective is to create a pathway through the cancellous bone to the vicinity of the involved periradicular tissues. It is often difficult to identify the appropriate site for cortical trephination. Good quality diagnostic radiographs and careful clinical examination will aid in determining the appropriate trephination site. The site most often recommended is at or near the root apex.^{3,32-34} Gutmann and Harrison² suggest, however, that the trephination site should be at or about midroot level in the interdental bone, either mesial or distal to the affected tooth. Cortical trephination should always be initiated from a buccal approach, never from the lingual or palatal. Gutmann and Harrison recommend using either a No. 6 or No. 8 round bur in a high-speed handpiece to penetrate the **cortical plate**. A reamer or K-type file is then passed through the **cancellous bone** into the vicinity of the periradicular tissues. It is not necessary to pass the instrument directly to the root apex to achieve effective results.² The clinician must exercise good judgment to avoid anatomic structures such as the maxillary sinus and the neurovascular contents of the mandibular canal and the mental foramen, as well as the tooth itself.

PERIRADICULAR SURGERY

As previously discussed, the indications for, and the application of, periradicular endodontic surgery have undergone dramatic changes in the last two decades. These changes have been especially evident when dealing with the treatment of failed nonsurgical endodontic treatments. A widely held principle of endodontic diagnosis and treatment planning is that the primary modality for endodontic treatment failure should be **nonsurgical endodontic re-treatment** whenever possible^{2,3,28,35-39} (see chapter 13, “Outcome of Endodontic Treatment and Re-treatment”).

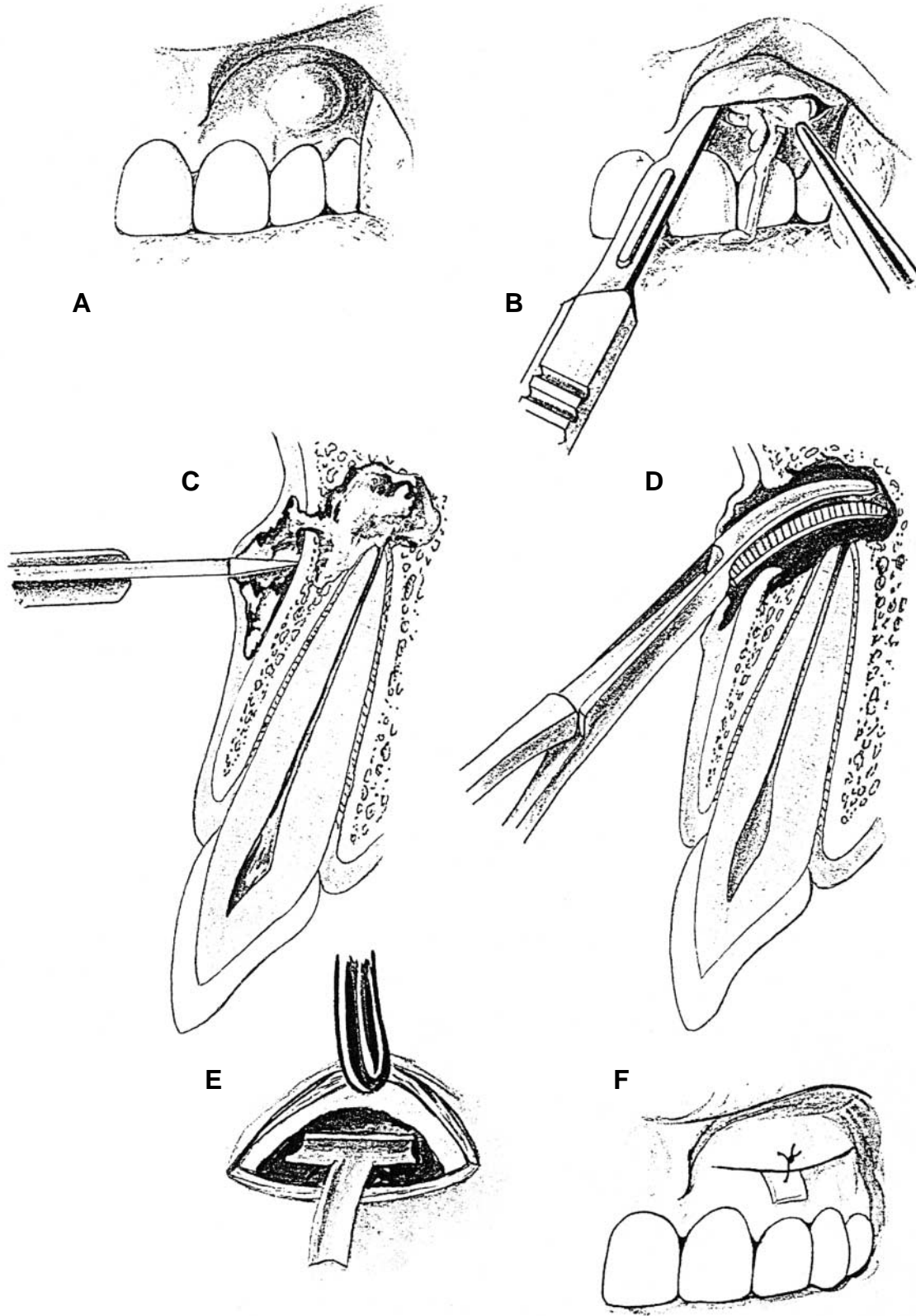


Figure 12-7 Incision and drainage of acute apical abscess. A, Good level of anesthesia is established and region is packed with gauze sponges. B, Sweeping incision is made through core of lesion with No. 11 or 12 scalpel. Drainage is aspirated by assistant. C, Profile view of incision showing scalpel carried through to bone. D, In some cases a small curved hemostat through defect of bony plate into body of infection. By spreading beaks, adequate drainage is established and may be maintained by suturing T-drain through incision. Patient requires antibiotics for bacteremia and analgesics to control discomfort. E, T-drain is positioned to ensure patency of incision until all drainage ceases. F, If drain will not remain in place, it may be sutured.

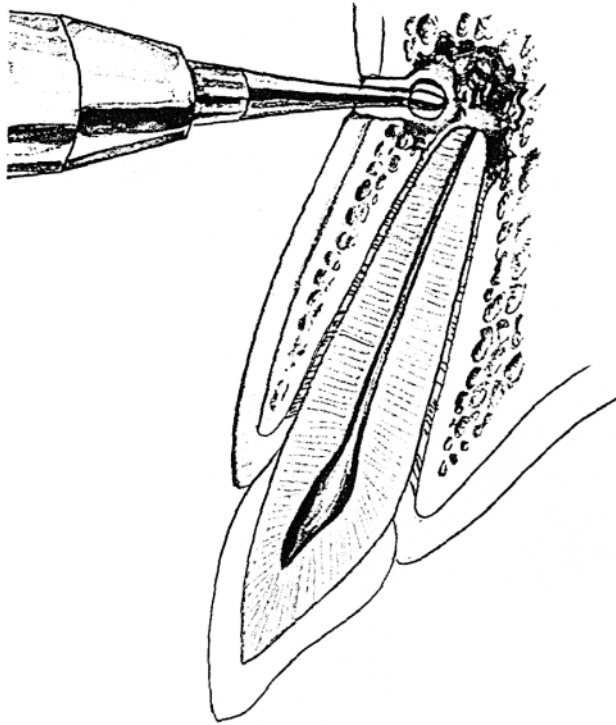


Figure 12-8 Surgical trephination of intact labial cortical plate to relieve liquid and gas pressure of acute apical abscess. Accurate pinpointing of lesion is done by radiography.

The importance of thorough and meticulous presurgical planning cannot be overemphasized. Not only must the dental practitioner and staff be thoroughly trained, but, in addition, all necessary instruments, equipment, and supplies must be readily available in the treatment room (Figure 12-9). This requires that every step of the procedure be carefully planned and analyzed. The potential for possible complications must be anticipated and incorporated into the presurgical planning.

Good patient communication is essential for thorough surgical preparation. It is important that the patient understands the reason surgery is needed as well as other treatment options available. The patient must be informed of the prognosis for a successful outcome and the risks involved in the surgical procedure, in addition to the benefits. It is also important that the patient be informed of the possible short-term effects of the surgery, such as pain, swelling, discoloration, and infection. **Signed** consent forms are advised. It is recommended that patients not be allowed to watch the procedure in a mirror, even if they so request.

A presurgical mouth rinse will improve the surgical environment by decreasing the tissue surface bacterial

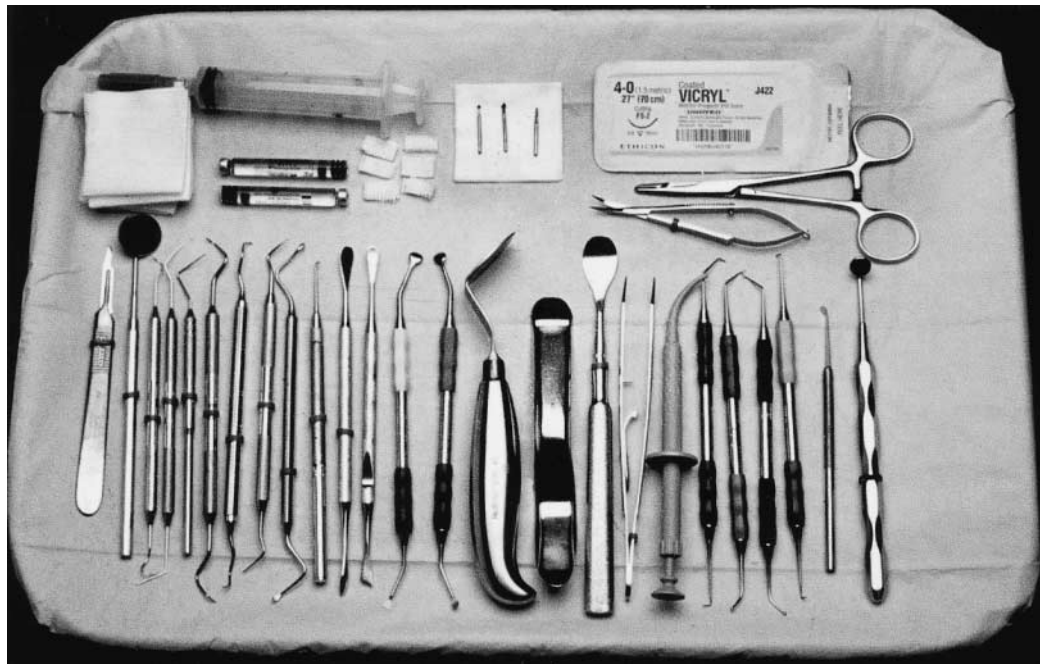


Figure 12-9 Suggested surgical instrument setup. **Top Row:** Extra 2-inch \times 2-inch gauze; irrigating syringe with sterile saline, (Monoject); two extra carpules lidocaine 1/50,000 epinephrine; Teflon gauze cut in small squares; surgical length FG carbide burs No. 6, No. 8, and No. H267 (Brassler); 4-0 Vicryl (Polyglactin 910) suture; needle holder; scissors. **Bottom Row:** Scalpel handle with No. 15C Bard-Parker blade; mouth mirror, front surface No. 4; cow horn DE explorer; No. 16 DE endodontic explorer; periodontal probe; perio curettes; bone curettes; Morse No. 00 scaler (Ransom and Randolph); periosteal elevators; flap retractors; locking cotton pliers; root-end filling material carrier; root-end filling condenser; front surface micro mirrors. Instruments required for endodontic surgery are prearranged on the surgical tray with logical placement in order of their use from left to right. Instruments are sterilized and packaged in readiness for use.

contamination and thereby reducing the inoculation of microorganisms into the surgical wound. Chlorhexidine gluconate (Peridex) has been shown to decrease salivary bacterial counts by 80 to 90% with a return to normal within 48 hours.⁴⁰ Gutmann and Harrison recommend that chlorhexidine gluconate oral rinses should be started the day before surgery, given immediately before surgery, and continued for 4 to 5 days following surgery.² The reduction in numbers of oral bacteria before and during the early postsurgical period and the inhibition of plaque formation produce a markedly improved environment for wound healing.²

Most periradicular surgical procedures, regardless of their indication, share a number of concepts and principles: (1) the need for profound local anesthesia and hemostasis, (2) management of soft tissues, (3) management of hard tissues, (4) surgical access, both visual and operative, (5) access to root structure, (6) periradicular curettage, (7) root-end resection, (8) root-end preparation, (9) root-end filling, (10) soft-tissue repositioning and suturing, and (11) postsurgical care. All of these concepts and principles may not be used in any given surgery. However, an in-depth knowledge and understanding of these principles, and the manner in which they relate to the biology and physiology of the tissues involved, is of major importance. The strict adherence to and application of these principles will greatly influence the success of the surgical treatment and will minimize patient morbidity.

Anesthesia and Hemostasis

The injection of a local anesthetic agent that contains a vasoconstrictor has two equally important objectives: (1) to obtain profound and prolonged anesthesia and (2) to provide good hemostasis both during and after the surgical procedure. To sacrifice one for the other is shortsighted and unnecessary. Failure to obtain profound surgical anesthesia will result in needless pain and anxiety for the patient. Inadequate hemostasis will result in poor visibility of the surgical site, thus prolonging the procedure and resulting in increased patient morbidity. With the proper handling of any medical condition with which the patient may present, and the selection of an appropriate anesthetic agent and vasoconstrictor, it is possible to accomplish both objectives.

Selection of Anesthetic Agent. The selection of an appropriate anesthetic agent should always be based on the medical status of the patient and the desired duration of anesthesia needed (see chapter 9, "Preparation for Endodontic Treatment"). The two major groups of local anesthetic agents are the esters and amides. The important difference between these groups lies not in

their ability to produce profound anesthesia but in the manner in which they are metabolized and the potential for allergic reactions. Esters have a much higher allergic potential than do amides.⁴¹ The only ester local anesthetic available in dental cartridges in the United States is a combination of propoxycaine and procaine (Ravocaine).

The amide group of local anesthetics, which include lidocaine (Xylocaine), mepivacaine (Carbocaine), prilocaine (Citanest), bupivacaine (Marcaine), etidocaine (Duranest), and articaine (Ultracaine), undergo a complex metabolic breakdown in the liver. Patients with a known **liver dysfunction** should be administered amide local anesthetic agents with caution because of the potential for a high systemic blood concentration of the drug. Also, patients with severe **renal impairment** may be unable to remove the anesthetic agent from the blood, which may result in an increased potential for toxicity as a result of elevated blood levels of the drug. Therefore, significant renal dysfunction presents a relative contraindication, and dosage limits should be lowered.^{23,41}

The high clinical success rate in producing profound and prolonged local anesthesia along with its low potential for allergic reactions makes **lidocaine (Xylocaine) the anesthetic agent of choice** for periradicular surgery. Selection of another anesthetic agent is indicated only in the presence of a true documented contraindication. If the use of an amide anesthetic agent (lidocaine) is absolutely contraindicated, the ester agent, procaine-propoxycaine with levonordefrin (Ravocaine with Neocobefrin), is the only choice at present.²

Selection of Vasoconstrictor Agent. The choice of vasoconstrictor in the local anesthetic will have an effect on both the duration of anesthesia and the quality of hemorrhage control at the surgical site.^{23,42-44} Vasopressor agents used in dentistry are direct-acting, sympathomimetic (adrenergic) amines that exert their action by stimulating special receptors (alpha- and beta-adrenergic receptors) on the smooth muscle cells in the microcirculation of various tissues. These agents include **epinephrine (Adrenalin)**, **levonordefrin (Neocobefrin)**, and **levarterenol (Levophed, noradrenaline, norepinephrine)**.^{41,42} For the purpose of **hemostasis**, there is little or **no justification for the use of levarterenol**. The degree of hemostasis required for most periradicular surgical procedures cannot be produced safely by levarterenol.⁴¹

Ahlquist was the first to determine the existence of two types of adrenergic receptors.⁴⁵ He termed them alpha and beta. He documented that each produces different responses when stimulated. Many tissues have both alpha

and beta receptors; however, one will usually predominate. Gage demonstrated that the action of a vasopressor drug on the microvasculature depends on (1) the predominant receptor type and (2) the receptor selectivity of the vasopressor drug.⁴⁶ **Alpha receptors predominate in the oral mucosa and gingival tissues, whereas beta receptors predominate in skeletal muscle.**^{23,47} Epinephrine receptor selectivity is approximately equal for alpha and beta receptors. Levonordefrin receptor selectivity, however, is primarily for alpha-adrenergic receptors.

Stimulation of the **alpha-adrenergic receptors** will result in **contraction** of the smooth muscle cells in the microvasculature with a subsequent reduction of blood flow through the vascular bed. Stimulation of the **beta-adrenergic receptors** will result in a **relaxation** of the smooth muscle cells in the microvasculature with a subsequent **increased blood flow through the vascular bed**. Since epinephrine receptor selectivity is equal for alpha and beta receptors, and beta receptors predominate in skeletal muscle, **it is important not to inject epinephrine into skeletal muscles in the area of endodontic surgery or a vasodilation with increased blood flow will result.**^{23,46}

Epinephrine is the most effective and most widely used vasoconstrictor agent used in dental anesthetics.^{41,48-50} The other vasopressors available are less effective. Even though they are used in higher concentrations in an effort to compensate for their lower effectiveness, the difference in the degree of clinical effect is readily observable. Many studies have been reported measuring the plasma catecholamine levels and the clinical effects of the injection of epinephrine containing local anesthetics for dental treatment.⁵¹⁻⁵⁵ The results of these studies indicate that even though the plasma level of catecholamines increases following the injection, this increase does not generally appear to be associated with any significant cardiovascular effects in healthy patients or those with mild to moderate heart disease. Pallasch stated that the hemodynamic alterations seen with elevated plasma epinephrine are usually quite short in duration, probably because of the very short plasma half-life of epinephrine, usually less than 1 minute. He also stated that the good achieved by the inclusion of vasoconstrictors in dental local anesthetics greatly outweighs any potential deleterious effects of these agents.⁵⁶

Injection Sites and Technique. For periradicular surgery, it is imperative that profound prolonged anesthesia and maximum hemostasis be achieved. In addition to the choice of anesthetic and vasopressor agents, the sites and technique of injection are important factors as well. Nerve block anesthesia involves injection in close proximity to a main nerve trunk that is usually located

some distance from the surgical site. Thus, the vasopressor agent in the anesthetic preparation used in nerve block anesthesia will not significantly affect the blood flow at the surgical site. Profound nerve block anesthesia can be achieved with a local anesthetic containing dilute (1:100,000 or 1:200,000) epinephrine.^{23,24}

Hemostasis, unlike anesthesia, however, cannot be achieved by injecting into distant sites.⁴⁸ Only the small vessels of the microvasculature are affected by the injected vasopressor; larger vascular channels are not. An inferior alveolar nerve block injection effectively blocks pain transmission from the surgical site; however, the vasopressor injected has no effect on the inferior alveolar artery and normal blood flow continues to the peripheral surgical site. Therefore, **additional injections must be administered in the soft tissue in the immediate area of the surgery.** This is accomplished by local infiltration using a higher concentration (1:50,000 epinephrine) of vasopressor in the anesthetic solution. In the maxilla, infiltration anesthesia can simultaneously achieve anesthesia and hemostasis. It is important to note that, whatever technique is used to obtain anesthesia, **infiltration in the surgical site is always required to obtain hemostasis.**^{2,57}

The infiltration sites of injection for periradicular surgery are always multiple and involve deposition of anesthetic throughout the entire surgical field in the alveolar mucosa just superficial to the periosteum at the level of the root apices (Figure 12-10). **Following block anesthesia**, using a 30-gauge needle with the bevel toward bone, a small amount of solution (0.25–0.50 mL) should be slowly deposited. The needle tip is then moved peripherally (mesially and distally) and similar small amounts are slowly injected in adjacent areas.^{2,48}

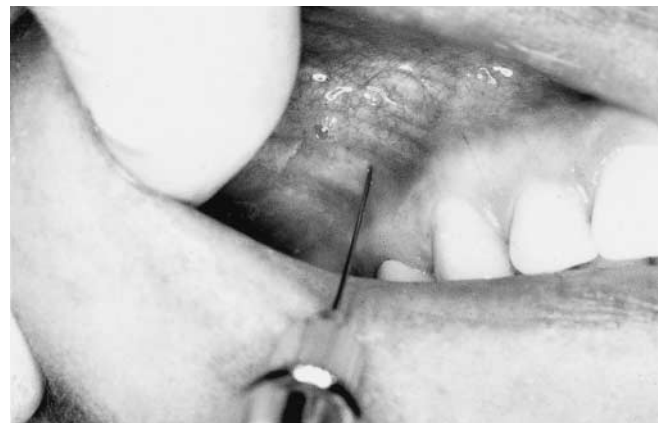

Figure 12-10 Proper placement of needle for infiltration anesthesia to obtain maximum surgical hemostasis is in the alveolar mucosa just superficial to the periosteum at the level of the root apices.

The **rate of injection** in the target sites directly affects the degree of hemostasis.² The recommended injection rate is 1 mL/minute, with a maximum safe rate of 2 mL/minute.^{41,58} Rapid injection produces localized pooling of solution in the injected tissues, resulting in delayed and limited diffusion into adjacent tissues. This results in minimal surface contact with the microvascular bed and less than optimal hemostasis.

The amount of anesthetic solution needed varies and depends on the size of the surgical site. In a small surgical site involving only a few teeth, one cartridge (1.8 cc) of solution containing 1:50,000 epinephrine is usually sufficient to obtain adequate hemostasis. For more extensive surgery involving multiple teeth, it is rarely necessary to inject more than two cartridges (3.6 cc) of anesthetic (1:50,000 epinephrine) to achieve both anesthesia and hemostasis.

Reactive Hyperemia: The Rebound Phenomenon. It is important that the endodontic surgeon be aware of the delayed beta-adrenergic effect that follows the hemostasis produced by the injection of vasopressor amines. A rebound occurs from an alpha (vasoconstriction) to a beta (vasodilation) response and is termed **reactive hyperemia** or the **rebound phenomenon**.⁵⁹

Following the injection of a vasopressor amine, tissue concentration of the vasopressor gradually decreases to a level that no longer produces an alpha-adrenergic vasoconstriction. The restricted blood flow slowly returns to normal but then rapidly increases far beyond normal, as a beta-adrenergic dilatation occurs.^{23,59,60} This rebound phenomenon is not the result of beta receptor activity but results from localized tissue hypoxia and acidosis caused by the prolonged vasoconstriction.^{47,61} Once this reactive hyperemia occurs, it is usually impossible to re-establish hemostasis by additional injections. Therefore, if a long surgical procedure is planned (multiple roots or procedures), **the more complicated** and hemostasis-dependent procedures (root-end resection, root-end preparation and filling) **should be done first**. The less hemostasis-dependent procedures, such as periradicular curettage, biopsy, or root amputation, should be reserved for last.

The rebound phenomenon has another important clinical implication: postsurgical hemorrhage and hematoma. These possible postsurgical sequelae are best minimized by proper soft-tissue repositioning and postsurgical care, described in more detail later in this chapter.

Soft-Tissue Management

The establishment of good surgical access, both visual and operative, is a requirement for all surgical proce-

dures. Visual access enables the endodontic surgeon to see the entire surgical field. Operative access allows the surgeon to perform the needed surgical procedure(s) with the highest quality and in the shortest amount of time. This will result in the least amount of surgical trauma and a reduction in postsurgical morbidity.

All surgical procedures require the **intentional wounding** of specific tissues, and the subsequent **wound healing** depends on the type of tissues wounded and the type of wound inflicted. The surgeon's goal must always be to minimize trauma to both the soft and hard tissues involved in the surgical procedure. Most periradicular surgical procedures require the raising of a mucoperiosteal flap.

Flap Designs and Incisions. Good surgical access is fundamentally dependent on the selection of an appropriate flap design. Numerous flap designs have been proposed for periradicular surgery (Figure 12-11). It must be noted, however, that no one flap design is suitable for all surgical situations. It is necessary to know the advantages and disadvantages of each flap design.

Principles and Guidelines for Flap Design. Regardless of the design of the surgical flap, there are a number of principles and guidelines that apply to the location and extent of incisions. The adherence to these principles and guidelines will ensure that the flapped soft tissues will fit snugly in their original position and will properly cover the osseous wound site and provide an adequate vascular bed for healing:

1. Avoid horizontal and severely angled vertical incisions.

The gingival blood supply is primarily from the same vessels supplying the alveolar mucosa. As these vessels enter into the gingiva, they assume a vertical course parallel to the long axis of the teeth and are positioned in the reticular layer superficial to the periosteum. They are known as the suprapariosteal vessels.^{62,63}

They are arterioles with a diameter of about 100 μm and are the terminal branches of the buccal, lingual, greater palatine, inferior alveolar, and superior alveolar arteries.⁶⁴

The collagen fibers of the gingiva and alveolar mucosa provide structural strength to these tissues. Collectively, these fibers are termed the gingival ligament. This ligament consists of a number of fiber groups that form attachments from crestal bone and supracrestal cementum to the gingiva and the periosteum on the buccal and lingual radicular bone. The collagen fibers that attach to the periosteum course over the crestal radicular bone in a direction parallel to the long axis of the teeth.⁶⁵

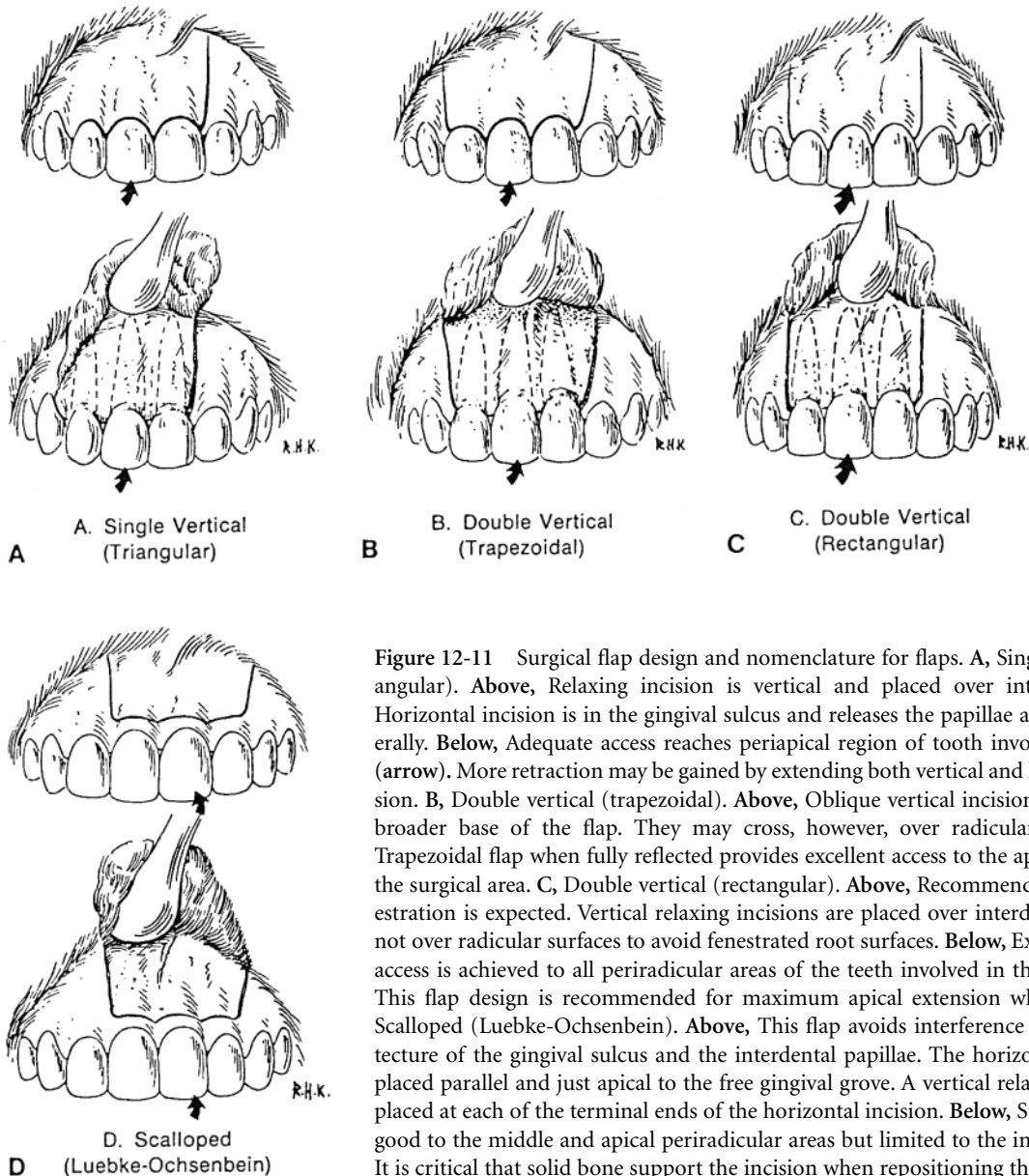


Figure 12-11 Surgical flap design and nomenclature for flaps. **A**, Single vertical (triangular). **Above**, Relaxing incision is vertical and placed over interdental bone. Horizontal incision is in the gingival sulcus and releases the papillae as it extends laterally. **Below**, Adequate access reaches periapical region of tooth involved in surgery (arrow). More retraction may be gained by extending both vertical and horizontal incision. **B**, Double vertical (trapezoidal). **Above**, Oblique vertical incisions provide for a broader base of the flap. They may cross, however, over radicular bone. **Below**, Trapezoidal flap when fully reflected provides excellent access to the apices of teeth in the surgical area. **C**, Double vertical (rectangular). **Above**, Recommended if bony fenestration is expected. Vertical relaxing incisions are placed over interdental bone and not over radicular surfaces to avoid fenestrated root surfaces. **Below**, Excellent surgical access is achieved to all periradicular areas of the teeth involved in the surgical area. This flap design is recommended for maximum apical extension when needed. **D**, Scalloped (Luebke-Ochsenbein). **Above**, This flap avoids interference with the architecture of the gingival sulcus and the interdental papillae. The horizontal incision is placed parallel and just apical to the free gingival groove. A vertical relaxing incision is placed at each of the terminal ends of the horizontal incision. **Below**, Surgical access is good to the middle and apical periradicular areas but limited to the incisal one-third. It is critical that solid bone support the incision when repositioning the flap.

Horizontal and severely angled incisions, such as used in semilunar flaps and in broad-based rectangular flaps, shrink excessively during surgery as a result of contraction of the cut collagen fibers that run perpendicular to the line of incision. As a result of this shrinkage, it is often difficult to return the flap edges to their original position without placing excessive tension on the soft tissues. This often results in tearing out of the sutures and subsequent scar formation from healing by secondary intention (Figure 12-12). Horizontal or severely angled incisions may also result in interference of the blood supply to the unflapped gingival tissues because of

severance of the gingival blood vessels that run perpendicular to the line of incision.

2. Avoid incisions over radicular eminences.

Radicular eminences, such as the canine, maxillary first premolar, and first molar mesiobuccal root prominences, often fenestrate through the cortical bone or are covered by very thin bone with a poor blood supply. These bony defects may lead to soft-tissue fenestrations if incisions are made over them. Vertical (releasing) incisions should be made parallel to the long axis of the teeth and placed between the adjacent teeth over solid interdental bone, never over radicular bone (Figure 12-13).

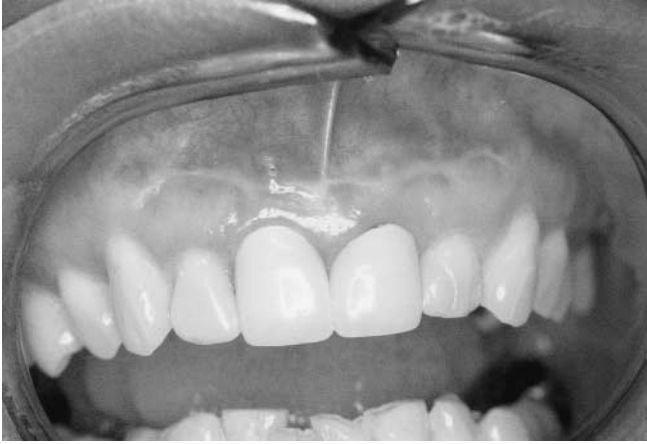

Figure 12-12 Shrinkage of the gingival tissue resulting from cut collagen fibers may result in postsurgical scarring as a result of healing by secondary intention.

3. Incisions should be placed and flaps repositioned over solid bone.

Incisions should never be placed over areas of periodontal bone loss or periradicular lesions. Without good solid bone to support the repositioned edges of the mucoperiosteal flap, inadequate blood supply results in necrosis and sloughing of the soft tissue. The endodontic surgeon must take into consideration the extent of osseous bone removal necessary to accomplish the intended periradicular surgery when designing the flap so that the repositioned flap margins will be supported by solid bone. Hooley and Whitacre suggest that a minimum of 5 mm of bone should exist between the edge of a bony defect and the incision line.⁶⁶

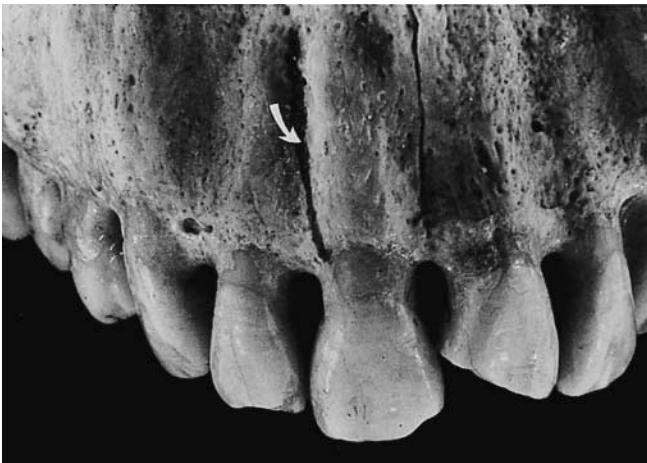

Figure 12-13 Vertical incisions should be made over the thick bone that lies in the “trough” (arrow) between the radicular eminences.

4. Avoid incisions across major muscle attachments.

Incisions across major muscle attachments (frena) make repositioning of the flap and subsequent healing much more difficult. Healing and scar tissue formation by secondary intention healing often results. This can be circumvented by laterally extending the horizontal incision so that the vertical incision bypasses the muscle attachment and it is included within the flap.

5. Tissue retractor should rest on solid bone.

The extension of the vertical incision should be sufficient to allow the tissue retractor to seat on solid bone, thereby leaving the root apex well exposed (Figure 12-14). If the vertical incisions are not adequately extended, there will be a tendency for the retractor to traumatize the mucosal tissue in the fold at the base of the flap. This may affect the blood supply to these tissues and will result in increased postsurgical morbidity.

6. Extent of the horizontal incision should be adequate to provide visual and operative access with minimal soft-tissue trauma.

In general, the horizontal incision for mucoperiosteal flaps in periradicular surgery should extend at least one to two teeth lateral to the tooth to be treated (Figure 12-15). This will allow for adequate surgical access and minimize tension and stretching of the soft tissue. A time-tested axiom regarding the length of an incision is that more trauma results from too short an incision rather than too long, and incisions heal from side to side, not from end to end.

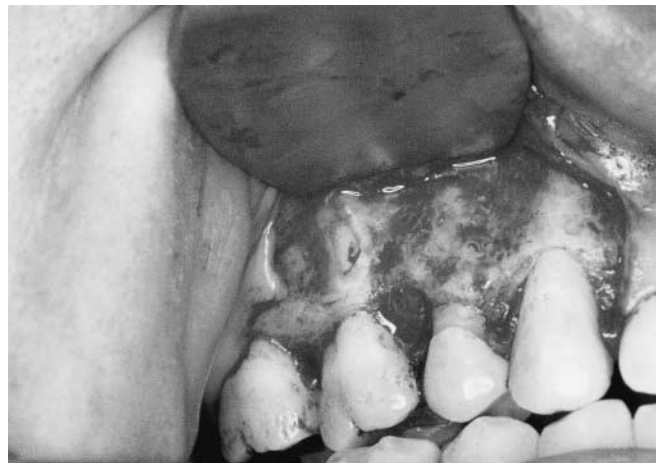

Figure 12-14 The flap retractor should be broad enough to provide visual access to the surgical site and also rest on solid bone without impinging soft tissue.

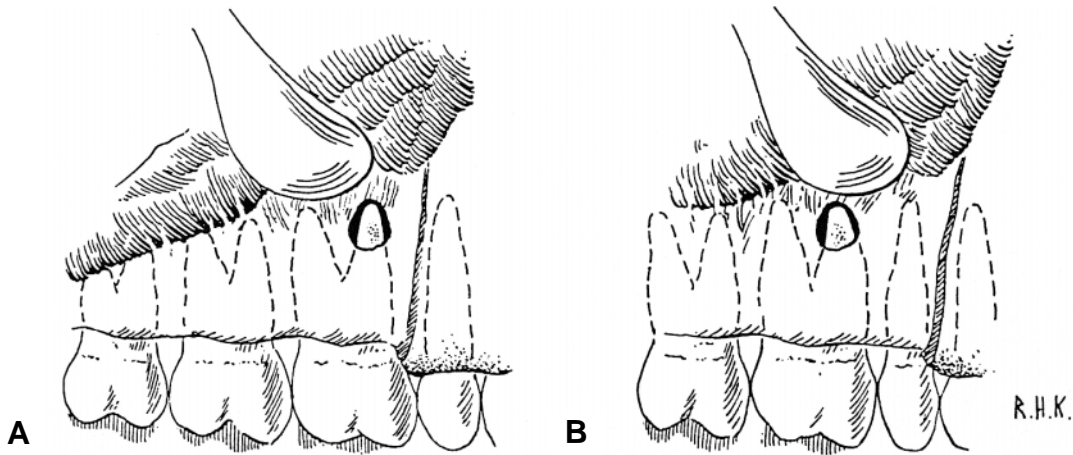


Figure 12-15 An incision should be no closer than 5 mm to a bony defect. A, Vertical incision is too close to bony defect. B, Incision placed one tooth mesially allows for better visual access and solid bony support for the incision.

7. The junction of the horizontal sulcular and vertical incisions should either include or exclude the involved interdental papilla.

Vertical releasing incisions should be made parallel to the long axis of the teeth and placed between the adjacent teeth over solid interdental bone, **never over radicular bone**. The vertical incision should intersect the horizontal incision and terminate in the intrasulcular area at the mesial or distal line angle of the tooth. The involved interdental papilla should never be split by the vertical incision or intersect the horizontal incision in the midroot area (Figure 12-16).

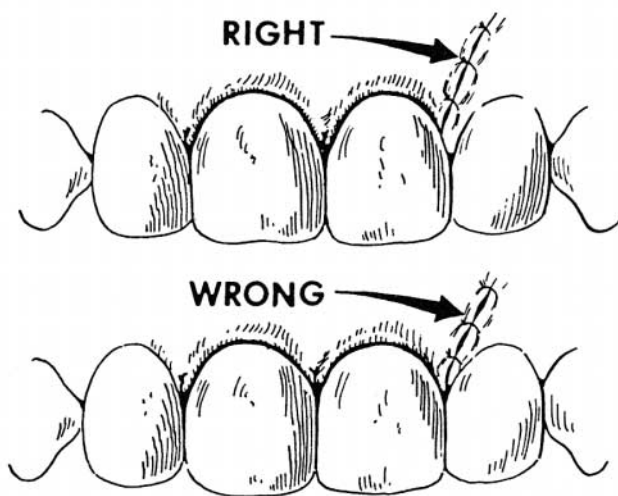


Figure 12-16 Incisions that split the papillae do not heal as well and may leave a periodontal defect following suture removal.

8. The flap should include the complete mucoperiosteum (full thickness).

The flap should include the entire mucoperiosteum (marginal, interdental and attached gingiva, alveolar mucosa, and periosteum). Full-thickness flaps result in less surgical trauma to the soft tissues and better surgical hemostasis than do split-thickness flaps. The major advantages of full-thickness flaps are derived from the maintenance of the suprapariosteal blood vessels that supply these tissues.

According to Gutmann and Harrison, the two major categories of periradicular surgical flaps are the **full mucoperiosteal flaps** and the **limited mucoperiosteal flaps**.² The location of the horizontal component of the incision is the distinguishing characteristic between the two categories of surgical flaps. All **full mucoperiosteal flaps** involve an intrasulcular horizontal incision with reflection of the marginal and interdental (papillary) gingival tissues as part of the flap. **Limited mucoperiosteal flaps** have a submarginal (subsulcular) horizontal or horizontally oriented incision, and the flap does not include the marginal or interdental tissues.² The addition of plane geometric terms to describe flap designs, as suggested by Luebke and Ingle, provides for an easily identifiable classification of periradicular surgical flap designs.⁶⁷ The classification of periradicular surgical flaps is found in Table 12-2, and a description of these flaps and their application in endodontic surgery follows.

Full Mucoperiosteal Flaps. *Triangular Flap.* The triangular flap is formed by a horizontal, intrasulcular incision and one vertical releasing incision (Figure 12-11, A). The primary advantages of this flap design are

Table 12-2 Classification of Surgical Flaps

1. Full mucoperiosteal flaps
(a) Triangular (one vertical releasing incision)
(b) Rectangular (two vertical releasing incisions)
(c) Trapezoidal (broad-based rectangular)
(d) Horizontal (no vertical releasing incision)
2. Limited mucoperiosteal flaps
(a) Submarginal curved (semilunar)
(b) Submarginal scalloped rectangular (Luebke-Ochsenbein)

that it affords good wound healing, which is a result of a minimal disruption of the vascular supply to the flapped tissue, and ease of flap reapproximation, with a minimal number of sutures required. The major disadvantage of this flap design is the somewhat limited surgical access it provides because of the single vertical releasing incision. This limited surgical access often makes it difficult to expose the root apices of long teeth (eg, maxillary cuspids) and mandibular anterior teeth.

In posterior surgery, both maxillary and mandibular, the vertical releasing incision is always placed at the **mesial extent** of the horizontal incision, never the distal. This affords the surgeon maximum visual and operative access with minimum soft-tissue trauma. For **anterior surgery**, the vertical releasing incision should be placed at the extent of the horizontal incision that is closest to the surgeon and is therefore **dependent on the surgeon's position** to the right or left of the patient.

After reflecting a triangular flap, sometimes the surgeon may find it necessary to obtain additional access. This can be easily obtained by placement of a **distal relaxing incision**. A relaxing incision is a short vertical incision placed in the marginal and attached gingiva and located at the extent of the horizontal incision opposite the vertical releasing incision. This incision is also good for relieving flap retraction tension while achieving adequate surgical access.

As a result of the excellent wound-healing potential of this flap design and the generally favorable surgical access it provides, use of the triangular mucoperiosteal flap is recommended whenever possible. It is recommended for **maxillary incisors and posterior teeth**. It is the only recommended flap design for **mandibular posterior teeth** because of anatomic structures contraindicating other flap designs.²

Rectangular Flap. The rectangular flap is formed by an intrasulcular, horizontal incision and two vertical releasing incisions (see Figure 12-11, C). The major advantage of this flap design is increased surgical access to the root apex. This flap design is especially useful for **mandibular anterior teeth**, multiple teeth, and teeth with long roots, such as **maxillary canines**.

The major disadvantage of the rectangular flap design is the difficulty in reapproximation of the flap margins and wound closure. Postsurgical stabilization is also more difficult with this design than with the triangular flap. This is primarily due to the fact that the flapped tissues are held in position solely by the sutures. This results in a greater potential for postsurgical flap dislodgment. This flap design is not recommended for posterior teeth.

Trapezoidal Flap. The trapezoidal flap is similar to the rectangular flap with the exception that the two vertical releasing incisions intersect the horizontal, intrasulcular incision at an obtuse angle (see Figure 12-11, B). The angled vertical releasing incisions are designed to create a broad-based flap with the vestibular portion being wider than the sulcular portion. The desirability of this flap design is predicated on the assumption that it will provide a better blood supply to the flapped tissues. Although this concept is valid in other tissues, such as the skin, its application is unfounded in periradicular surgery.⁶⁸

Since the blood vessels and collagen fibers in the mucoperiosteal tissues are oriented in a vertical direction, the angled vertical releasing incisions will sever more of these vital structures. This will result in more bleeding, a disruption of the vascular supply to the unflapped tissues, and shrinkage of the flapped tissues. **The trapezoidal flap is contraindicated in periradicular surgery.**^{32,68}

Horizontal Flap. The horizontal, or envelope, flap is created by a horizontal, intrasulcular incision with no vertical releasing incision(s). This flap design has very limited application in periradicular surgery because of the limited surgical access it provides. Its major applications in endodontic surgery are limited to repair of cervical defects (root perforations, resorption, caries, etc) and hemisections and root amputations.

Limited Mucoperiosteal Flaps. Submarginal Curved (Semilunar) Flap. The submarginal or semilunar flap is formed by a curved incision in the alveolar mucosa and the attached gingiva (see Figure 12-11, E). The incision begins in the alveolar mucosa extending into the attached gingiva and then curves back into the alveolar mucosa. There are no advantages to this flap design and its disadvantages are many, including poor surgical access and poor wound healing, which results in scarring. **This flap design is not recommended for periradicular surgery.**

Submarginal Scalloped Rectangular (Luebke-Ochsenbein) Flap. The submarginal scalloped rectangular flap is a modification of the rectangular flap in that the horizontal incision is not placed in the gingival

sulcus but in the buccal or labial attached gingiva. The horizontal incision is scalloped and follows the contour of the marginal gingiva **above the free gingival groove** (Figure 12-11, D). The major advantages of this flap design are that it does not involve the marginal or interdental gingiva and the crestal bone is not exposed. The primary disadvantages are that the vertically oriented blood vessels and collagen fibers are severed, resulting in more bleeding and a greater potential for flap shrinkage, delayed healing, and scar formation.

When considering the use of this flap design, the endodontic surgeon must keep in mind that the horizontal, scalloped incision must be placed and the flap repositioned over solid bone. Careful evaluation of any buccal or labial periodontal pockets must also be made to minimize the possibility of leaving unflapped gingival tissue without bony support.

The importance of properly angled diagnostic radiographs cannot be overemphasized when considering the use of this flap design. The size and position of any periradicular inflammatory bone loss must also be considered when placing the horizontal incision to ensure that the margins of the flap, when reapproximated, will be adequately supported by solid bone.

Proponents of this flap design stress the importance of not involving the marginal gingiva and the gingival sulcus in the horizontal incision, which may result in an alteration of the soft-tissue attachment and crestal bone levels. It has been reported, however, that, with proper reapproximation of the reflected tissues and good soft-tissue management, the gingival attachment level is minimally altered or unchanged when full mucoperiosteal flaps are used.

The key element in preventing loss of the soft-tissue attachment level is ensuring that the root-attached tissues are not damaged or removed during surgery.⁶⁸⁻⁷⁰ It has also been reported that crestal bone loss is minimal (about 0.5 mm) when full mucoperiosteal flaps are used in periodontic surgery. These procedures may involve apical positioning of flaps, excision of marginal gingiva, and root planing that must rely on new attachment of soft tissue to cementum. Unlike periodontal surgery, endodontic surgery can accomplish reattachment that results in little or no crestal bone loss.⁷¹ Harrison and Jurosky reported that crestal bone showed complete osseous repair of resorptive defects and no alteration of crestal height following periradicular surgery using a triangular (full mucoperiosteal) flap.⁷⁰ In the absence of periodontal disease, a complete return to anatomic and functional normalcy can be expected, following periradicular surgery using triangular or rectangular flap designs.²

Flap Design for Palatal Surgery. Periradicular surgery from a palatal approach is difficult due to the surgeon's limited visual and operative access to this area. The only flap designs indicated for palatal approach surgery are the horizontal (envelope) and the triangular, with the latter being preferred. The palatal surgical approach should be limited to the posterior teeth. Anterior teeth should be approached from the labial aspect, except when radicular pathosis dictates a palatal approach, for example, curettement of a cyst located toward the palate.

The **horizontal intrasulcular incision** for the triangular flap should extend anteriorly to the mesial side of the first premolar or, for the horizontal (envelope) flap, to the midline. It should extend distally as far as needed to afford access to the involved palatal root. A distal relaxing incision extending a few millimeters from the marginal gingiva toward the midline or over the tuberosity area can be added to achieve better access and to relieve tension on the distal extent of the flap.

The **vertical releasing incision** for the triangular flap should extend from a point near the midline and join the anterior extent of the horizontal incision mesial to the first premolar. There is no validity to concerns regarding a potential hemorrhage problem with vertical incisions in the palatal mucosa in the premolar area. The greater palatine artery branches rapidly as it courses anteriorly and an incision in the premolar area results in a minimal disruption to the vascular supply.

The palatal mucosa is tough and fibrous, and flap reflection and retraction can be difficult in this area. Placement of a sling suture in the flapped tissue attached to a tooth or a bite block on the opposite side of the maxillary arch may aid the surgeon in improving visual and operative access by eliminating the need to manually retract the flap while performing this potentially difficult surgical procedure (Figure 12-17).

Incisions. Following the selection of the flap design, it is important to select the proper scalpel blade to accomplish the delicate task of making smooth, clean, atraumatic incisions. Incisions for the majority of mucoperiosteal flaps for periradicular surgery can be accomplished by using one or more of four scalpel blades: No. 11, No. 12, No. 15, and No. 15C (Figure 12-18). The horizontal incision should be made first, followed by the vertical releasing incisions to complete the perimeters of the flap design.

The horizontal incision for a **full mucoperiosteal flap** begins in the gingival sulcus and should extend through the fibers of the gingival attachment to the crestal bone. Care should be exercised to ensure that the interdental papilla be incised through the **midcol area**,

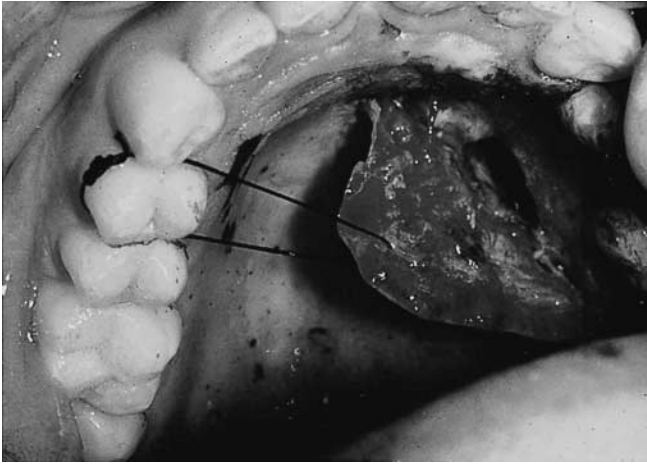


Figure 12-17 Single sling suture retracts palatal flap, giving surgical access and freeing hands of surgeon to hold mouth mirror and handpiece. (Courtesy of Dr. Donald D. Antrim.)

separating the buccal and lingual papilla and incising the fibers of the epithelial attachment to crestal bone. Because these tissues are extremely delicate and space is very limited, this important incision is best made with a small scalpel blade, such as No. 11 or No. 15C (Figure 12-19). By holding the scalpel handle in a pen grasp and using finger rests on the teeth, the surgeon can achieve maximum control and stability when performing these delicate incision strokes. An attempt should be made to accomplish the horizontal incision using as few incision strokes as necessary to minimize trauma to the marginal gingiva.



Figure 12-18 Scalpel blades for surgical incisions. From top: Microsurgical blade, No. 15C, No. 15, No. 12, No. 11.

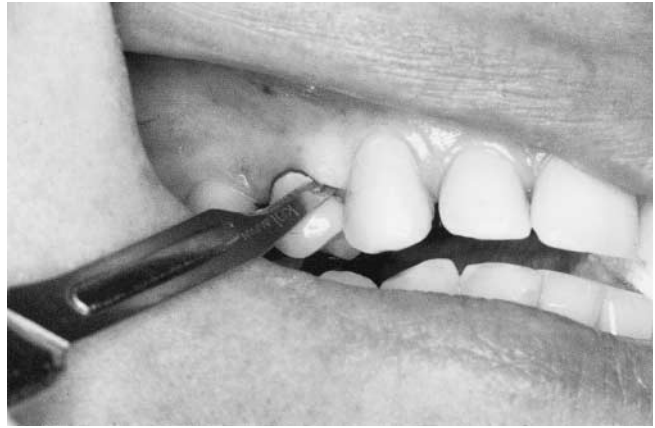

Figure 12-19 No. 15C scalpel blade placed in the gingival sulcus for horizontal incision.

The horizontal incision for a **limited mucoperiosteal flap** should begin in the attached gingiva and be placed about 2 mm coronal to the mucogingival junction (Figure 12-20). The incision should be **scalloped** following the contour of the marginal gingiva. It is important that the horizontal incision **never be placed** coronal to the depth of the gingival sulcus. The depth of the gingival sulcus must be measured before placement of this flap design. The No. 15 or No. 15C scalpel blade is recommended for this incision. An attempt should be made to incise through the gingiva and periosteum to the cortical bone using firm pressure and a single, smooth stroke. Multiple incision strokes will result in increased trauma to the gingival tissue, which, in turn, may contribute to retarded healing and scar formation.

Vertical releasing incisions, whether for full or limited mucoperiosteal flaps, should always be vertical and placed between adjacent teeth over interdental bone. **They should never be placed over radicular bone.** The incision should penetrate through the periosteum so that it can be included in the flap. The incision stroke should begin in the alveolar mucosa and proceed in a coronal direction until it intersects the horizontal incision (Figure 12-21). Contrary to a well-ingrained surgical axiom, it is not necessary to accomplish this incision in a single stroke.² It is often difficult to accomplish penetration completely through the gingiva, mucosa, submucosa, and periosteum in a single stroke of the scalpel. An initial incision stroke that penetrates the mucosa and gingiva can be followed by a second that penetrates through the periosteum to the surface of the cortical bone. More accurate placement of the vertical releasing incision will often result from this two-stroke

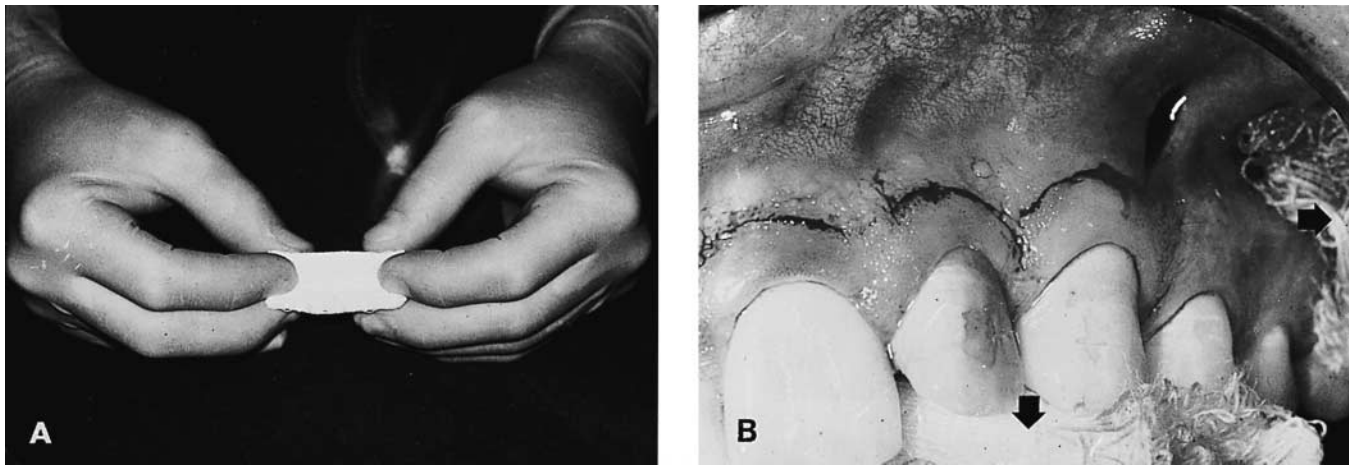


Figure 12-20 Horizontal incision for submarginal scalloped rectangular flap is placed in the attached gingiva just apical to the free gingival groove and follows the contour of the marginal gingiva. Patient biting on gauze can swallow more easily and prevents seepage of hemorrhage. (Courtesy of Dr. Donald D. Antrim.)

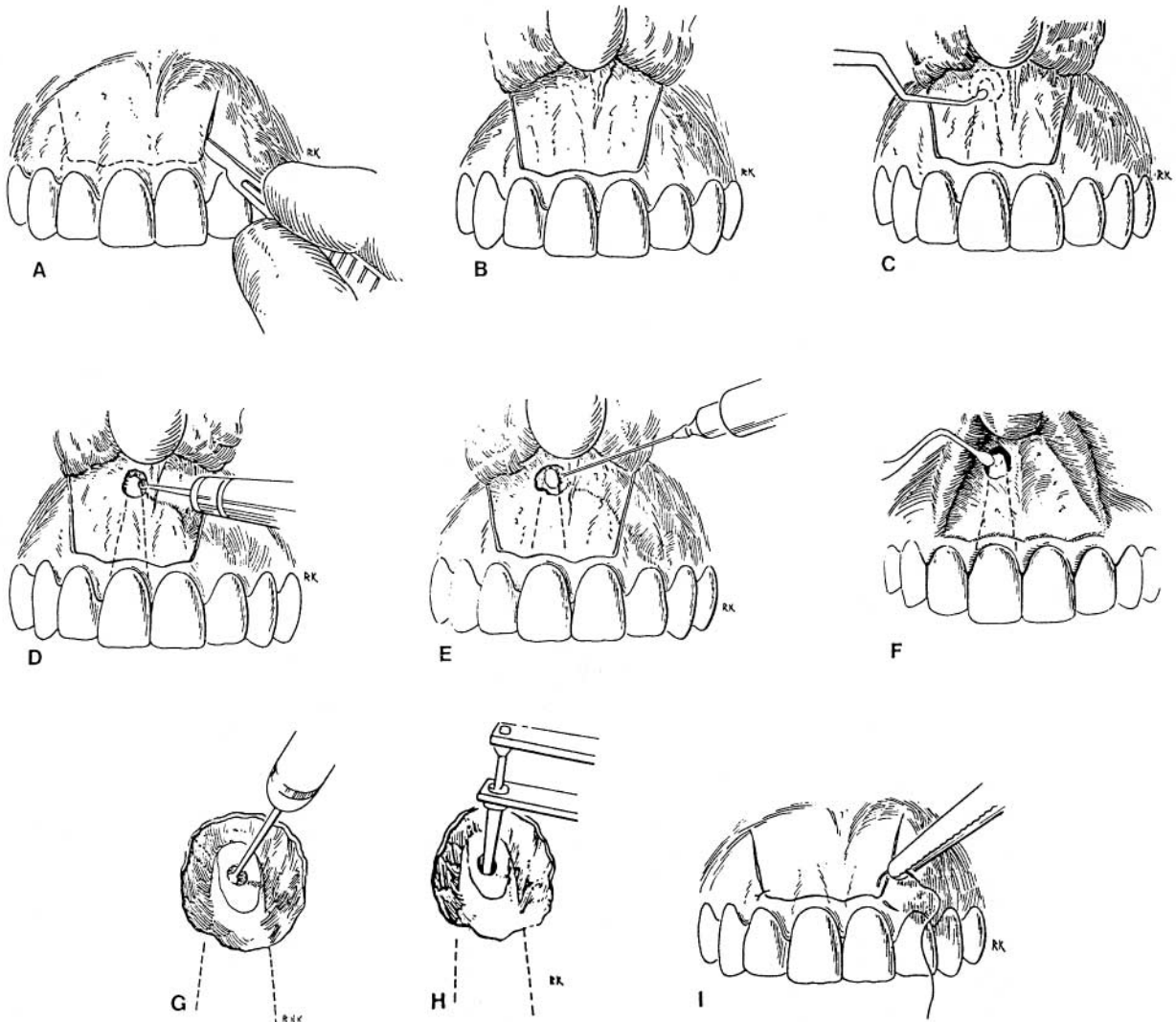


Figure 12-21 Vertical releasing incision should begin in the alveolar mucosa and proceed in a coronal direction until it intersects the horizontal incision.

incision technique because less pressure is required on the initial stroke, affording the surgeon more control over the direction of the scalpel blade. It may be necessary to replace the scalpel blade with a fresh, sharp blade to produce clean, sharp incision lines.

Flap Reflection. Reflection of soft tissues for full or limited mucoperiosteal flaps is a very critical process in the effort to reduce surgical trauma and postsurgical morbidity. Marginal gingiva is very delicate and easily injured. It is, therefore, not appropriate to begin the reflective process in the horizontal incision for full mucoperiosteal flaps. The supracrestal root-attachment fibers are of even greater clinical significance than is the marginal gingiva. These root-attachment fibers are easily damaged or destroyed by direct reflective forces. Damage to these tissues may result in the loss of their viability, allowing for apical epithelial down-growth along the root surface. This epithelial down-growth will result in increased sulcular depth and loss of soft-tissue attachment level.^{2,72} Maintenance of the viability of these root-attachment fibers will likely result in the soft-tissue attachment levels being unaltered following surgery.^{69,72}

Initiating the flap reflective process in the horizontal incision for submarginal flaps is not as injurious to the soft tissues as in the full-flap design since the horizontal incision for the former is placed in attached gingiva. This will, however, result in damaging forces being applied to a critical wound edge and should be avoided whenever possible. The horizontal incision is more subject to delayed wound healing than are the vertical incisions in this flap design. Additional trauma to the attached gingival tissues during flap reflection may result in tissue shrinkage and healing by secondary intention, which will result in increased scar-tissue formation. The reflective procedure for the limited mucoperiosteal flap should begin in the attached gingiva of the vertical incision whenever possible.

Flap reflection is the process of separating the soft tissues (gingiva, mucosa, and periosteum) from the surface of the alveolar bone. This process should begin in the **vertical incision** a few millimeters apical to the junction of the horizontal and vertical incisions (Figure 12-22). A number of periosteal elevators and curettes are available for mucoperiosteal flap elevation (Figure 12-23). The periosteal elevator of choice should be used to gently elevate the periosteum and its superficial tissues from the cortical plate.

Once these tissues have been lifted from the cortical plate and the periosteal elevator can be inserted between them and the bone, the elevator is then directed coronally. This allows the marginal and interdental

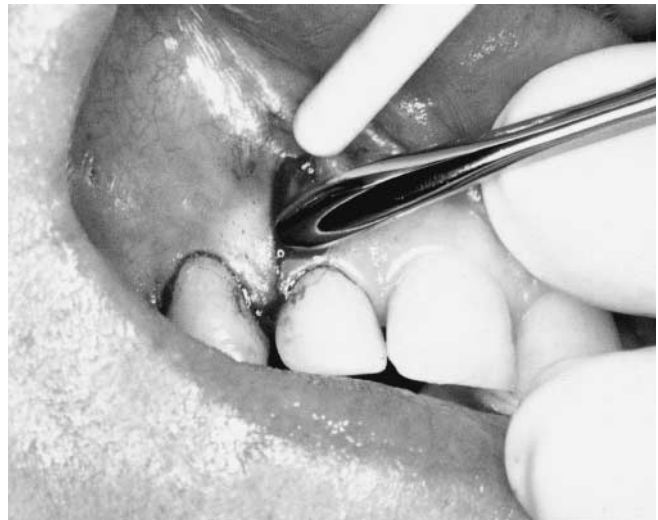

Figure 12-22 Flap reflection begins with the periosteal elevator placed in the attached gingiva a few millimeters apical to the junction of the vertical and horizontal incisions.

gingiva to be separated from the underlying bone and the opposing incisional wound edge without direct application of dissectional forces. This technique allows for all of the direct reflective forces to be applied to the periosteum and the bone. This approach to flap reflection is referred to as “**undermining elevation.**”⁶³

This “undermining elevation” should continue until the attached gingival tissues (marginal and interdental) have been lifted from the underlying bone to the full extent of the horizontal incision. After reflection of these tissues, soft-tissue elevation is continued in an apical direction, lifting the alveolar mucosa, along with **the underlying periosteum**, from the cortical bone until adequate surgical access to the intended surgical area has been achieved (Figure 12-24).

After the flap has been fully reflected, small bleeding tissue tags will be noted on the exposed surface of the

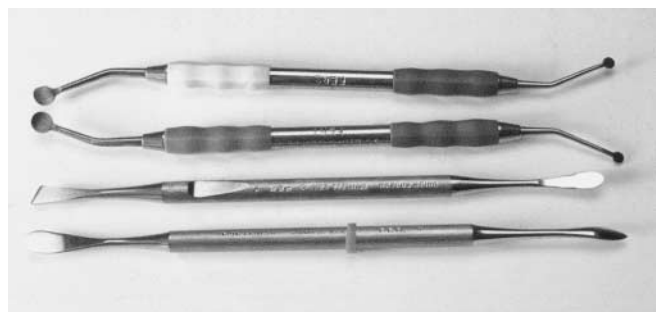

Figure 12-23 Periosteal elevators for flap reflection. From top: No. 1 and No. 2 (Thompson Dental Mfg. Co.); No. 2 (Union Broach Co.); No. 9 (Union Broach Co.).

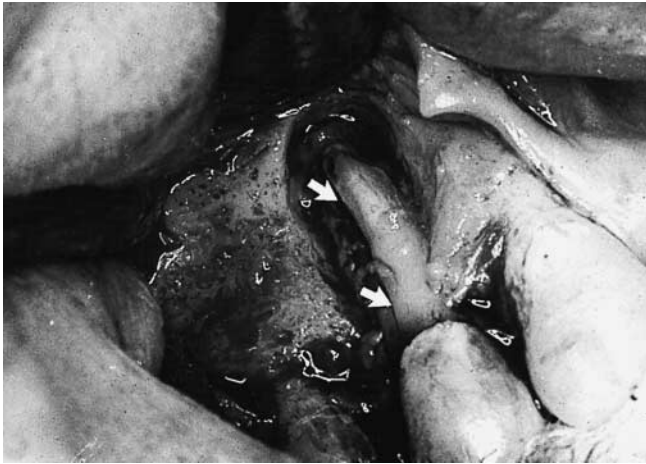

Figure 12-24 Flap fully reflected achieves visual and surgical access to all periradicular surfaces. Arrows indicate vertical root fracture.

cortical bone, especially in the interradicular depressed areas. Bleeding from these tissue tags will stop in a few minutes and they should not be damaged or removed. Research evidence strongly suggests that **these bleeding tissue tags are cortical retained periosteal tissues** and may play an important role in healing and reattachment of the flap to the cortical bone.^{70,73}

In **posterior mandibular surgery**, it is important to be aware of the presence of the **mental foramen** and its associated neurovascular bundle. The most common location of the mental foramen is directly inferior to the crown of the second premolar and mesial to and inferior to its root apex (Figure 12-25). The mental

foramen is visible approximately 75% of the time on periapical radiographs. When it is not visible on the radiograph, it is usually below the border of the film.^{74,75} During flap reflection in the mandibular premolar area, the surgeon must be alert to subtle changes in the resistance of the periosteum to separation from the cortical bone. The resistance of Sharpey's fibers, which attach the periosteum to the bone, to separation results in a thin, white band at the junction of the flapped soft tissues and the cortical bone. Since there are no Sharpey's fibers attaching the periosteum to the border of the mental foramen, this thin, white band will disappear when the border of the mental foramen has been reached. Further reflection of the soft tissues in this area will result in the identification of the neurovascular bundle as it exits from the foramen. Maximum protection to the neurovascular bundle will be best achieved by its early identification during the flap reflective process. This will allow the surgeon to avoid injury to these important anatomic structures during the remainder of the surgical procedure.

Flap Retraction. Flap retraction is the process of holding in position the reflected soft tissues. Proper retraction depends on adequate extension of the flap incisions and proper reflection of the mucoperiosteum. It is necessary to provide both visual and operative access to the periradicular and radicular tissues. The tissue retractor must always rest on **solid cortical bone** with light but firm pressure. In this way, it acts as a passive mechanical barrier to the reflected soft tissues. If the retractor inadvertently rests on the soft tissue at the

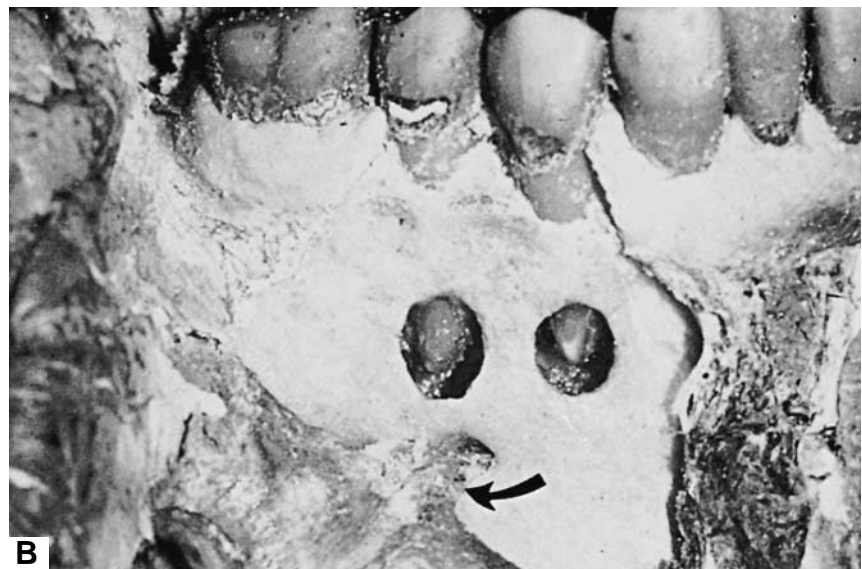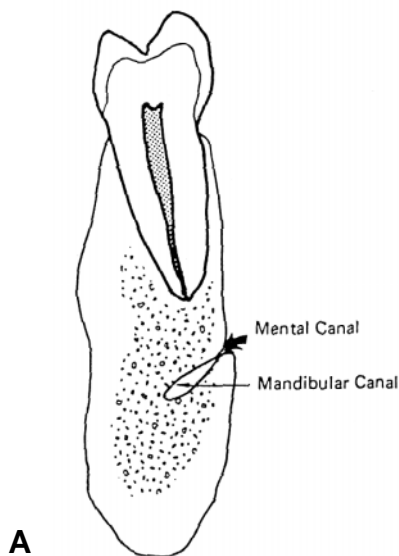


Figure 12-25 Neurovascular bundle is seen in cadaver dissection exiting through the mental foramen (arrow). Notice its relationship to the apices of both mandibular premolars.

base of the flap, mechanical trauma to the alveolar mucosa may result in delayed healing and increased postsurgical morbidity.

There are a number of tissue retractors available for use in endodontic surgery (Figure 12-26). Selection of the proper size and shape of the retractor is important in minimizing soft-tissue trauma. If the retractor is too large, it may traumatize the surrounding tissue. If the retractor is too small, flapped tissue falls over the retractor and impairs the surgeon's access. This results not only in increased soft-tissue trauma but also in extending the length of the surgical procedure. An axiomatic principle of endodontic surgery is that the longer the flap is retracted, the greater the postsurgical morbidity. This is a logical conclusion based on the probability that blood flow to the flapped tissues is impeded during flap retraction. In time, this will result in hypoxia and acidosis with a resulting delay in wound healing.^{2,23,59}

Regardless of whether the retraction time is short or long, the periosteal surface of the flap should be irrigated frequently with physiologic saline (0.9% sodium chloride) solution. Saline should be used rather than water because the latter is hypotonic to tissue fluids. It is not necessary to irrigate the superficial surface of the flap because the stratified squamous epithelium prevents dehydration from this surface. Limited mucoperiosteal flaps are more susceptible to dehydration and may require more frequent irrigation than would full mucoperiosteal flaps.²

Hard-Tissue Management

Following reflection and retraction of the mucoperiosteal flap, surgical access must be made through the cortical bone to the roots of the teeth. Where cortical bone is thin, as in the maxilla, a large periradicular

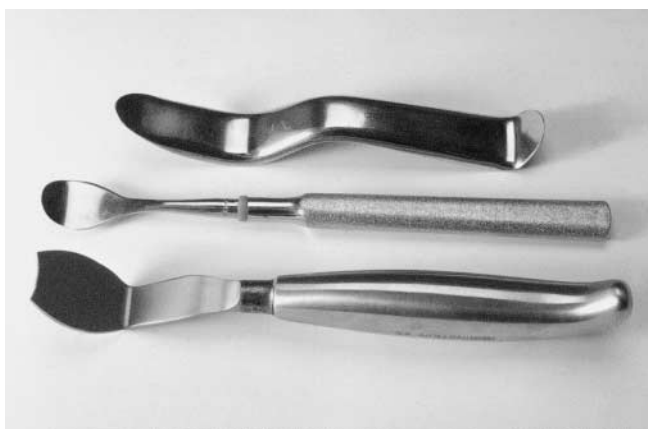

Figure 12-26 Flap retractors. **Top:** No. G3 (Hu-Friedy); **Middle:** No. 3 (Hu-Friedy); **Bottom:** Rubinstein (JedMed Co., St. Louis, MO).

lesion may result in the loss of buccal or labial cortical plate, or if a natural root fenestration is present, the tooth root may be visible through the cortical plate. In other cases, the cortical bone may be very thin, and probing with a small sharp curette will allow penetration of the cortical plate.

The most difficult and challenging situation for the endodontic surgeon occurs when several millimeters of cortical and cancellous bone must be removed to gain access to the tooth root, especially when no periradicular radiolucent lesion is present. A number of factors should be considered to determine the location of the bony window in this clinical situation. The angle of the crown of the tooth to the root should be assessed. Often the long axis of the crown and its root are not the same, especially when a prosthetic crown has been placed. When a root prominence or eminence in the cortical plate is present, the root angulation and position are more easily determined. Measurement of the entire tooth length can be obtained from a well-angled radiograph and transferred to the surgical site by the use of a sterile millimeter ruler. After a small defect has been created on the surface of the cortical plate, a radiopaque marker, such as a small piece of lead foil from a radiographic film packet or a small piece of gutta percha, can be placed in the bony defect and a direct (not angled) radiograph exposed. The radiopaque object will provide guidance for the position of the root apex.⁷⁶⁻⁷⁹

When the cortical plate is intact, another method to locate the root apex is to first locate the body of the root substantially coronal to the apex where the bone covering the root is thinner. Once the root has been located and identified, the bone covering the root is slowly and carefully removed with light brush strokes, working in an apical direction until the root apex is identified (Figure 12-27). Barnes identified four ways in which the root surface can be distinguished from the surrounding osseous tissue: (1) root structure generally has a yellowish color, (2) roots do not bleed when probed, (3) root texture is smooth and hard as opposed to the granular and porous nature of bone, and (4) the root is surrounded by the periodontal ligament.⁸⁰

Under some clinical conditions, however, the root may be very difficult to distinguish from the surrounding osseous tissue. Some authors advocate the use of methylene blue dye to aid in the identification of the periodontal ligament. A small amount of the dye is painted on the area in question and left for 1 to 2 minutes. When the dye is washed off with saline, the periodontal ligament will be stained with the dye, making it easier to identify the location of the root.^{32,77,81,82}

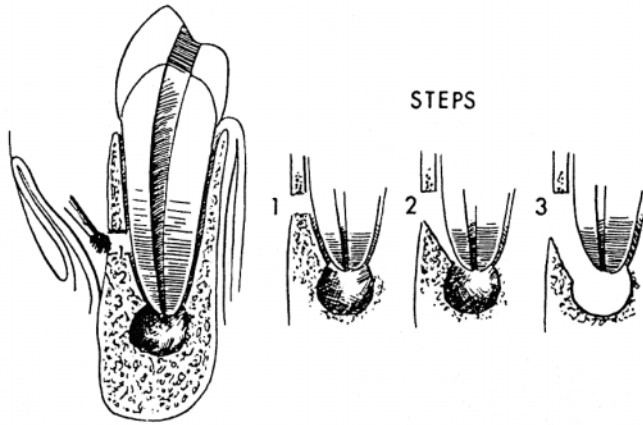


Figure 12-27 Stepwise removal of bone to the apex, after the root has been identified, prevents gouging adjacent roots or structures. (Courtesy of Dr. Merrill E. Schmidt.)

Osseous tissue response to surgical removal is complicated and depends on a number of variables. One important factor is that bone in the surgical site has a temporary decrease in vascular supply because of the local anesthetic vasoconstrictor. This results in the osseous tissue being more heat sensitive and less resistant to injury. Of major importance in osseous tissue removal by burs is the generation of heat. Variables, such as bur sharpness, rotary speed, flute design, and pressure applied, will all have a direct influence on heat generation.

The use of a liquid coolant is indispensable in controlling temperature increase during bone removal by dissipating the heat generated and by keeping the cutting flutes of the instruments free of debris. Osseous temperatures higher than 100°C have been recorded during bone removal with burs even when a liquid coolant was used.⁸³ Animal studies have shown that vascular changes occur in bone when temperatures exceed 40°C. Heating bone tissue in excess of 60°C results in inactivation of alkaline phosphatase, interruption of blood flow, and tissue necrosis.^{84–87} For the coolant to be effective, it must be directed on the head of the bur enough to prevent tissue debris from clogging the flutes.

The shape of the bur used for bone removal and the design of its flutes play a significant role in postsurgical healing. Cutting of osseous tissue with a No. 6 or No. 8 round bur produces less inflammation and results in a smoother cut surface and a shorter healing time than when a fissure or diamond bur is used.^{88–90} Burs with the ability to cut sharply and cleanly, with the largest space between cutting flutes, regardless of the speed of rotation, leave defects that heal in the shortest postsurgical time.⁹¹

The amount of pressure applied to the bone by burs during osseous tissue removal will have a direct effect on the frictional heat generated during the cutting process. Light “brush strokes” with short, multiple periods of osseous cutting will maximize cutting efficiency and minimize the generation of frictional heat.

Several authors have stated that because of a potential for contamination from high-speed turbines, insufficient coolant directed at the bur head and problems of obstructed vision at the surgical site, a low-speed surgical handpiece should be used for osseous removal rather than a high-speed handpiece.^{32,78,92} No studies presently exist that support a biologic basis for the use of a low-speed handpiece rather than the proper use of a high-speed handpiece for bone removal.² In most areas of the mouth, visual access is adequate while using a high-speed handpiece and surgical-length burs. In areas of restricted visibility, the use of a high-speed handpiece with a 45-degree angled head significantly increases visibility.

The Impact Air 45-degree high-speed handpiece offers the added advantage that the air is exhausted to the rear of the turbine rather than toward the bur and the surgical site (Figure 12-28). Several case reports have been published of surgical emphysema resulting in subcutaneous emphysema of the face, intrathoracic complications including pneumomediastinum, fatal descending necrotizing mediastinitis, and Lemierre syndrome from the use of a high-speed dental handpiece.^{93–95} Clinicians should be aware of the spectrum of this potential problem and, specifically, of the potential hazards of pressurized nonsterile air blown into open surgical sites by the dental drill.⁹⁶

When performing periradicular surgery, inexperienced endodontic surgeons, in their attempt to be conservative in the removal of osseous tissue, often create too small a window through the cortical plate to expose the tooth root. As a result, both visual and operative access is impaired for the most delicate and critical part



Figure 12-28 Impact Air 45-degree handpiece. Air is exhausted to the rear of the turbine rather than toward the surgical site.

of the surgery: root-end resection and root-end filling. Although it is advisable to limit osseous tissue removal to no more than is necessary, failure to achieve sufficient visual and operative access results in extending the time required for the surgical procedure, increasing the stress level of the surgeon, trauma to adjacent tissues, and postsurgical patient morbidity.

Periradicular Curettage

Once the root and the root apex have been identified and the surgical window through the cortical and medullary bone has been properly established, any diseased tissue should be removed from the periradicular bony lesion. This removal of periradicular inflammatory tissue is best accomplished by using the various sizes and shapes of sharp surgical bone curettes and angled periodontal curettes (Figure 12-29). Several instrument manufacturers provide a wide assortment of curettes that can be used for débridement of the soft tissue located adjacent to the root. The choice of specific curettes is very subjective, and endodontic surgeons will develop a preference for curettes that work best for them. It is advisable, however, to have a wide assortment of curettes available in the sterile surgery pack to use should the need arise.

Before proceeding with periradicular curettage, it is advisable to inject a local anesthetic solution containing a vasoconstrictor into the soft-tissue mass. This will reduce the possibility of discomfort to the patient during the débridement process and will also serve as hemorrhage control at the surgical site. Additional injections of local anesthetic solution may be necessary if the amount of soft tissue needing to be removed is extensive and hemorrhage control is a problem.

Curettement of the inflammatory soft tissue will be facilitated if the tissue mass can be removed in one piece. Penetration of the soft-tissue mass with a curette will



Figure 12-29 Assorted curettes for removing periradicular inflammatory soft tissue.

result in increased hemorrhage and shredding the tissue will result in more difficult removal. To accomplish removal of the entire tissue mass, the largest bone curette, consistent with the size of the lesion, is placed between the soft-tissue mass and the lateral wall of the bony crypt with the **concave surface** of the curette facing the bone. Pressure should be applied against the bone as the curette is inserted between the soft-tissue mass and the bone around the lateral margins of the lesion. Once the soft tissue has been freed along the periphery of the lesion, the bone curette should be turned with the **concave portion toward the soft tissue** and used in a scraping fashion to free the tissue from the deep walls of the bony crypt. Again, care should be taken not to penetrate the soft-tissue mass with the curette.

Once the tissue has been detached from the walls of the crypt, its removal can be facilitated by grasping it with a pair of tissue forceps. The tissue should be immediately placed in a bottle containing 10% buffered formalin solution for transportation to the pathology laboratory. Although the majority of periradicular lesions of pulpal origin are granulomas, radicular cysts, or abscesses, a multitude of benign and neoplastic lesions have been recovered from periradicular areas.⁹⁷ All soft tissue removed during periradicular curettage should be sent for histopathologic examination to ensure that no potentially serious pathologic condition exists.⁹⁸

When the periradicular inflammatory soft tissue cannot be removed as a total mass, débridement is much more difficult and time consuming. As demonstrated by Fish, there is a considerable amount of reparative tissue in periradicular lesions.⁹⁹ Although it has been advocated for many years that all the soft tissue adjacent to the root be removed during periradicular surgery, in theory and practice this may not be necessary. This is especially true in cases where the lesion invades critical anatomic areas and structures such as the maxillary sinus, nasal cavity, mandibular canal, or adjacent vital teeth. Curettement of soft tissue in these and other critical anatomic areas should be avoided.²

Root-End Resection

Root-end resection is a common yet controversial component of endodontic surgery. Historically, many authors have advocated periradicular curettage as the definitive treatment in endodontic surgery **without root-end resection**. Their rationale for this approach centered primarily around the perceived need to maintain a cemental covering on the root surface and to maintain as much root length as possible for tooth stability.^{100–102} According to Gutmann and Harrison, no

studies are available to support either of these concerns. The rationale for periradicular curettage as a terminal procedure to protect root length and to ensure the presence of cementum is, therefore, highly questionable, especially if the source of periradicular irritant is still within the root canal system.² Other authors have stated that periradicular curettage per se, without root-end resection and root-end filling, should never be considered a terminal treatment in periradicular surgery unless it is associated with concurrent orthograde root canal treatment.^{103,104}

Indications. There are many stated indications in the literature for **root-end resection** as part of endodontic periradicular surgery. These indications may be classified as either biologic or technical. el-Swiah and Walker reported on a retrospective study that evaluated the clinical factors involved in deciding to perform root-end resections on 517 teeth from 392 patients. They reported that biologic factors constituted 60% of the total, whereas technical factors constituted 40%. The most common biologic factors were persistent symptoms and continued presence of a periradicular lesion. The most common technical factors contributing to the need for root-end resections were interradicular posts, crowned teeth without posts, irretrievable root canal filling materials, and procedural accidents.¹⁰⁵

There are three important factors for the endodontic surgeon to consider before performing a root-end resection: (1) instrumentation, (2) extent of the root-end resection, and (3) angle of the resection.

Instrumentation. The choice of bur type and the use of either a low- or high-speed handpiece for root-end resection deserve some consideration (Figure 12-30). Ingle et al. recommended that root-end resection is best accomplished by use of a No. 702 tapered fissure bur or a No. 6 or No. 8 round bur in a low-speed straight handpiece. They stated that a large round bur was excellent for this procedure because it was easily controlled and prevented gouging and the formation of sharp line angles.¹⁰⁶ Gutmann and Harrison, however, have stated that the use of a low-speed handpiece for root-end resection can be very difficult to control unless a good finger rest is obtained and a sharp bur is used. They have suggested the use of a high-speed handpiece and a surgical-length plain fissure bur.^{2,104} Gutmann and Pitt Ford stated that, even though various types of burs have been recommended for root-end resections, there is no evidence to support an advantage of one type of bur over another with regard to tissue-healing response. For years, however, clinical practice has favored a smooth, flat, resected root surface.¹⁰³




Figure 12-30 Burs for hard tissue removal. **A**, FG No. 6, No. 8, No. H267 (Brassler). **B**, SHP No. 6, No. 8, cross-cut fissure bur, plain fissure bur. Burs with larger spaces between cutting flutes result in less clogging of the bur with debris, thus reducing development of frictional heat.

Nedderman et al. used the scanning electron microscope (SEM) to evaluate the resected root face and gutta-percha fillings following root-end resection with various types of burs using both high- and low-speed handpieces. They reported that the use of round burs at both speeds resulted in scooping or ditching of the root surface. Cross-cut fissure burs at both speeds produced the roughest resected root surfaces with the gutta-percha being smeared across the root face. **Plain fissure burs**, both high- and low speed, produced the **smoothest** resected root surface, with plain fissure burs and a low-speed handpiece resulting in the **least gutta-percha distortion**.¹⁰⁷

Morgan and Marshall reported on a study that compared the topography of resected root surfaces using No. 57, Lindeman, or Multi-purpose burs. Further comparisons were made after refinements with either a multi-fluted carbide or an ultra-fine diamond finishing bur. The resected root surfaces were examined by light microscopy at 20× magnification for smoothness and irregularities. Their results indicated that the **Multi-purpose bur** produced a smoother and more uniplanar surface than did the No. 57 bur and caused less damage to

the root than either the No. 57 or the Lindeman bur. The multifluted carbide finishing bur tended to improve the smoothness of the resected root face, whereas the ultra-fine diamond tended to roughen the surface.¹⁰⁸

Since Theodore H. Maiman produced light amplification by stimulated emission of radiation (LASER) in 1960, lasers have found application in many areas of industry and medicine. Laser technology has been developed very rapidly and is now being used in various fields of dentistry. Most lasers used in dentistry operate either in the infrared or visible regions of the electromagnetic spectrum. These lasers act by producing a thermal effect. This means that the laser beam, when absorbed, has the capability to coagulate, vaporize, or carbonize the target tissue. It is important to note that different types of lasers may have different effects on the same tissue and the same laser may have different effects on different tissues.

Recently, many investigators have studied and reported on the *in vitro* and *in vivo* effects of the application of laser energy for root-end resections in endodontic periradicular surgery. A team of investigators from the Tokyo Medical and Dental University in Japan reported on an *in vitro* study using the Er:YAG laser for root-end resections. They reported that there was no smear layer or debris left on the resected root surfaces prepared by the use of the Er:YAG laser. Smear layer and debris, however, were left on the root surfaces prepared with a fissure bur.¹⁰⁹

Komori and associates reported on an *in vitro* study evaluating the use of the Er:YAG laser and the Ho:YAG laser for root-end resections. They reported that the Er:YAG laser produced smooth, clean, resected root surfaces free of any signs of thermal damage. The Ho:YAG laser, however, produced signs of thermal damage and large voids between the gutta-percha root canal fillings and the root canal walls.¹¹⁰

Moritz and associates reported on an *in vitro* study evaluating the use of the carbon-dioxide (CO₂) laser as an aid in performing root-end resections. They chose the laser because it had previously been shown to have a sealing effect on the dentinal tubules. Their results indicated that the use of the CO₂ laser as an adjunct following root-end resection with a fissure bur resulted in decreased dentin permeability, as measured by dye penetration and sealing of dentinal tubules determined by SEM examination. Their conclusion was that CO₂ laser treatment optimally prepares the resected root-end surface to receive a root-end filling because it seals the dentinal tubules, eliminates niches for bacterial growth, and sterilizes the root surface.¹¹¹

Maillet and associates evaluated the connective-tissue response to healing adjacent to the surface of dentin cut by a Nd:YAG laser versus dentin cut by a fissure bur. Disks of human roots 3.5 mm thick were implanted in the dorsal subcutaneous tissue of rats for 90 days. The disks were then recovered, with the surrounding tissue, at various times. The tissue against the cut dentin surfaces was assessed for extent of inflammation and fibrous capsule thickness by light microscopy. Their results showed a statistically significant increase in inflammation and fibrous capsule thickness adjacent to the dentin surfaces cut with the Nd:YAG laser compared with the bur-cut surfaces.¹¹²

Miserendino submitted a case report in which the CO₂ laser was used to perform a root-end resection and to sterilize the unfilled apical portion of the root canal space. He stated that the rationale for laser use in endodontic periradicular surgery includes (1) improved hemostasis and concurrent visualization of the operative field, (2) potential sterilization of the contaminated root apex, (3) potential reduction in permeability of root-surface dentin, (4) reduction of post-operative pain, and (5) reduced risk of contamination of the surgical site through elimination of the use of aerosol-producing air turbine handpieces. He concluded that the initial results of the clinical use of the CO₂ laser for endodontic periradicular surgery confirms the previous *in vitro* laboratory findings and indicates that further study of the application of lasers for microsurgical procedures in endodontics is in order.¹¹³

Komori and associates recently reported on eight patients (13 teeth) in whom the Er:YAG laser was used for root-end resections in periradicular endodontic surgery. They reported that all procedures were performed without the use of a high- or low-speed dental handpiece. Although the cutting speed of the laser was slightly slower than with the use of burs, the advantages of the laser included the absence of discomfort and vibrations, less chance for contamination of the surgical site, and reduced risk of trauma to adjacent tissue¹¹⁴ (Figure 12-31).

Extent of the Root-End Resection. William Hunter's classic presentation on the role of sepsis and antisepsis in medicine had an impact that lasted for many years on the extent of root-end resections in periradicular surgery. Historically, it was believed that failure to remove all foci of infection could result in a persistence of the disease process. Since the portion of the root that extended into the diseased tissue was "infected," and the cementum was "necrotic," it was necessary to resect the root to the level of healthy bone. Andreasen and Rud, in 1972, were unable to demon-

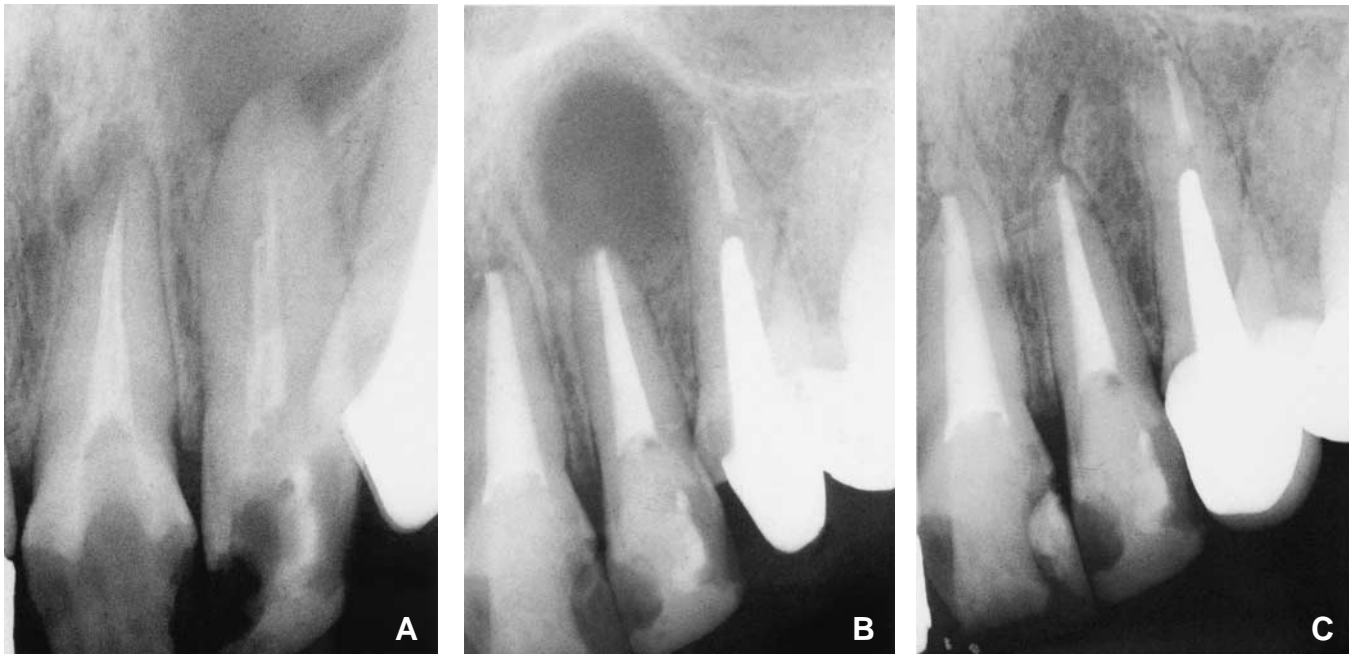

Figure 12-31 Root-end resection using LASER energy. A, Pretreatment radiograph revealing failing endodontic treatments with periradicular inflammatory lesions. B, Radiograph following endodontic retreatment and root-end resection of teeth No. 9 and No. 10 using Er:YAG laser. C, Twenty-six-month postsurgical radiograph revealing good periradicular healing. (Courtesy of Dr. Silvia Cecchini.)

strate the validity of this concept. Their findings indicated that there was no correlation between the presence of microorganisms in the dentinal tubules and the degree of periradicular inflammation.¹¹⁵

The extent of root-end resection will be determined by a number of variable factors that a dental surgeon must evaluate on an individual, case-by-case basis. It is not clinically applicable to set a predetermined amount of root-end removal that will be appropriate for all clinical situations. The following factors should be considered when determining the appropriate extent of root-end resection in periradicular surgery:

1. Visual and operative access to the surgical site (example: resection of buccal root of maxillary first premolar to gain access to the lingual root).
2. Anatomy of the root (shape, length, curvature).
3. Number of canals and their position in the root (example: mesial buccal root of maxillary molars, mesial roots of mandibular molars, two canal mandibular incisors).
4. Need to place a root-end filling surrounded by solid dentin (because most roots are conical shaped, as the extent of root-end resection increases, the surface area of the resected root face increases).
5. Presence and location of procedural error (example: perforation, ledge, separated instrument, apical extent of orthograde root canal filling).

6. Presence and extent of periodontal defects.
7. Level of remaining crestal bone.

The endodontic surgeon must constantly be aware that conservation of tooth structure during root-end resection is desirable; however, root conservation should not compromise the goals of the surgical procedure (Figure 12-32).

Angle of Root-End Resection. Historically, endodontic textbooks and other literature have recommended that the angle of root-end resections, when used in periradicular surgery, should be 30 degrees to 45 degrees from the long axis of the root facing toward the buccal or facial aspect of the root. The purpose for the angled root-end resections was to provide enhanced visibility to the resected root end and operative access to enable the surgeon to accomplish a root-end preparation with a bur in a low-speed handpiece.^{2,3,29,32,63,76-78,103}

More recently, several authors have presented evidence indicating that beveling of the root end results in opening of dentinal tubules on the resected root surface that may communicate with the root canal space and result in apical leakage, even when a root end filling has been placed. Ichescu and associates, using a spectrophotometric analysis of dye penetration, concluded that the resected root end of an endodontically treated tooth exhibited more apical leakage than one

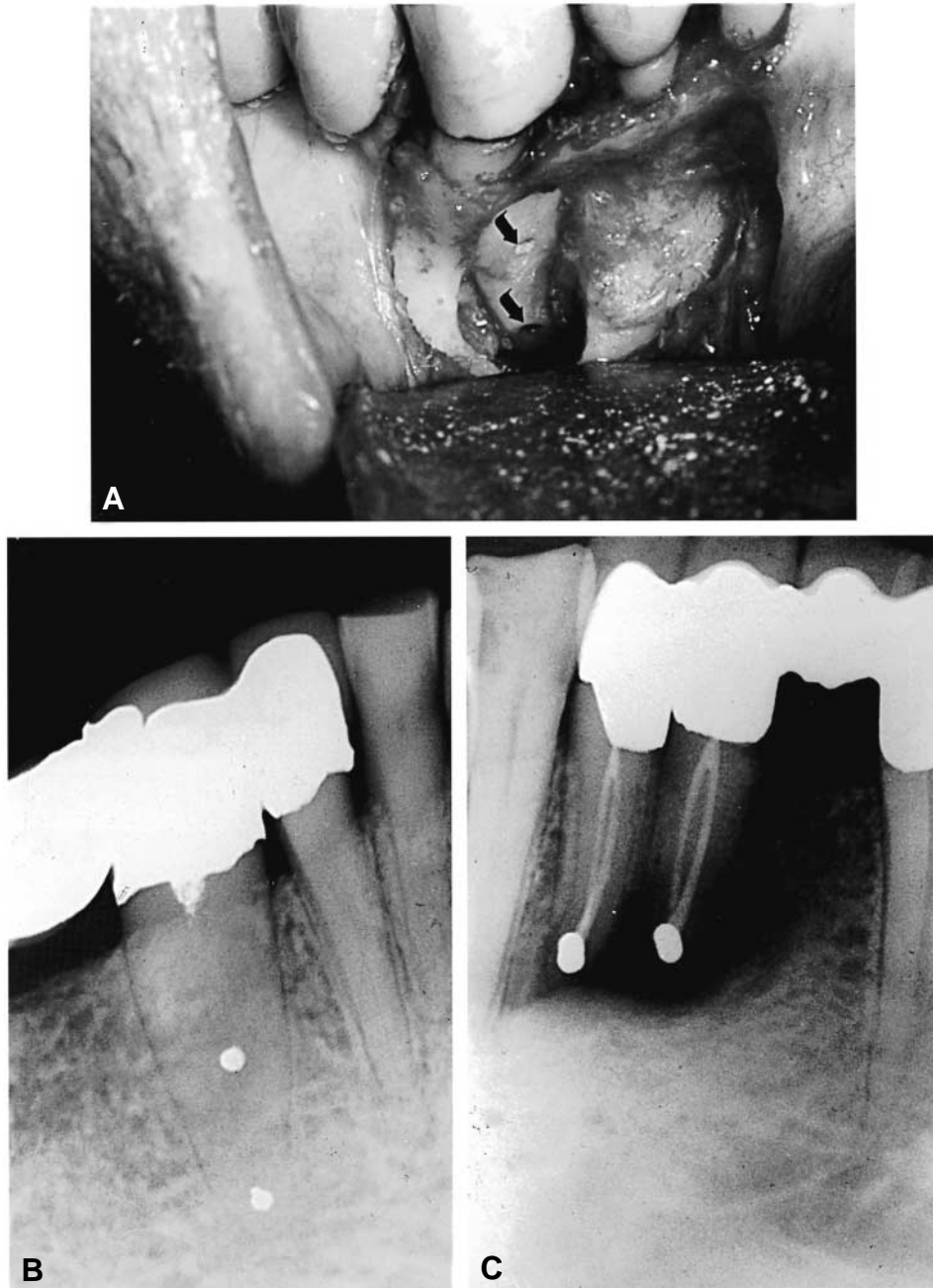


Figure 12-32 A, Mandibular canine abutment found to have two canals (arrows) on surgical exposure. B, One-year recall of A, with complete healing. C, Two-canal mandibular incisors serving as double abutments. Larger retrofillings obturate two foramina to rescue case. (Courtesy of Dr. L. Stephen Buchanan.)

without root-end resection.¹¹⁶ Beatty, using a similar method of dye penetration analysis, examined apical leakage at different root-end resection angles and reported that significantly more leakage occurred in those roots where the root-end filling did not extend to the height of the bevel.¹¹⁷ Vertucci and Beatty proposed that exposed dentinal tubules may constitute a potential pathway for apical leakage.¹¹⁸

Tidmarsh and Arrowsmith examined the cut root surface following root-end resections at angles between 45 degrees and 60 degrees approximately 3 mm from the root apex. Using scanning electron microscopy, they reported the presence of an average of 27,000 dentinal tubules per mm^2 on the face of the root-end resection midway between the root canal and the dentine-cementum junction.¹¹⁹

Gagliani and associates assessed the apical leakage measured by dye penetration in extracted teeth with root-end resections at 45-degree and 90-degree angles from the long axis of the root. Their findings indicated a statistically significant increase in leakage extending to the root canal space through dentinal tubules in those teeth with 45-degree angled root-end resections. They concluded that, by increasing the angle of the root-end resection from the long axis of the root, the number of exposed dentinal tubules increases. If infection persists within the root canal system coronal to the root-end filling, the likelihood of bacteria and/or bacterial by-products spreading outside of the root canal is high.¹²⁰

Regardless of the angle or the extent of the root-end resection, it is extremely important that the resection be complete and that no segment of root is left unresected. The potential for incomplete root-end resection is especially high in cases where the root is broad in its labial–lingual dimension and where surgical access and visibility are impaired. Carr and Bentkover stated that failure to cut completely through the root in a buccal–lingual direction is one of the most common errors in periradicular surgery.⁸² Once the desired extent and bevel of root-end resection have been achieved, the face of the resected root surface should be carefully examined to verify that complete circumferential resection has been accomplished. This can be accomplished by using a fine, sharp explorer or the tip of a Morse scaler guided around the periphery of the resected root surface. If complete resection is in doubt, a small amount of methylene blue dye can be applied to the root surface for 5 to 10 seconds. After the area has been irrigated with sterile saline, the periodontal ligament will appear dark blue, thereby highlighting the root outline.

Root-End Preparation

The purpose of a root-end preparation in periradicular surgery is to create a cavity to receive a root-end filling. Historically, root-end preparations have been performed by the use of small round or inverted cone burs in a miniature or straight low-speed handpiece. One major objective of a root-end preparation is that it be placed parallel to the long axis of the root. It is rare that sufficient access is present to allow a bur in a contra angle or straight handpiece to be inserted down the **long axis** of the root. These preparations are almost always placed obliquely into the root with a high risk of perforation to the lingual.

It is important for proper root-end preparation that the endodontic surgeon have a thorough knowledge of the root canal morphology of the tooth being treated. Incisor teeth with single roots and single canals most

often have a straightforward, uncomplicated root canal system, except for lateral or accessory canals, usually located in the apical one-third of the root.

Roots with multiple canals, however, have the potential to have more complicated root canal systems. An isthmus or anastomosis may exist between two root canals in the same root.¹²¹ This isthmus connection, when it occurs, becomes an important factor in the ability to thoroughly clean and débride these root canal systems (Figure 12-33). They also become a significant factor in the design and placement of the root-end preparation. If an isthmus exists and is not included in the root-end preparation, the remaining necrotic pulp tissue and debris may be a nidus for recurrent infection and subsequent treatment failure. The use of methylene blue dye placed on the resected root surface can also aid in the detection of an existing root canal isthmus.

Several authors have reported on studies investigating the actual incidence of an isthmus being present between two root canals in the same root. These reports indicate that the mesial root of the mandibular first molar has the highest incidence, at 89%, followed by the mesiobuccal root of the maxillary first molar, at 52%.^{122–127} In the past, the existence of a canal isthmus was often overlooked, and when identified, it was difficult to prepare with the traditional bur preparation. The recognition and proper management of a canal isthmus is an important factor that may affect the success of periradicular surgery involving roots with two or more canals.

Importance of Surgical Hemostasis. Good visualization of the surgical field and of the resected root surface is essential in determining the optimum placement of the root-end preparation. The ability to visualize the fine detail of the anatomy on the resected root surface depends on excellent surgical hemostasis to provide a clean, dry, surgical site. Presurgical hemostasis was discussed earlier in this chapter and its importance cannot be overemphasized. Frequently, however, the need for additional hemostasis at the surgical site becomes evident. This surgical hemostasis is best achieved by the use of various topical or local hemostatic agents. Ideally, these hemostatic agents should be placed subsequent to the root-end resection and before the root-end preparation and filling.² These topical and local hemostatic agents have been broadly classified by their mechanism of action¹²⁸ (see Table 12-3).

Bone Wax. The recommended use of bone wax dates back more than 100 years.¹²⁸ In 1972, Selden reported bone wax to be an effective hemostatic agent in periradicular surgery.¹²⁹ Bone wax contains mostly highly purified beeswax with the addition of small




Figure 12-33 Cause of two endodontic failures revealed under dental operating microscope following root-end amputation. A, Nondébrided unfilled isthmus connecting mesiobuccal and mesiolingual canals. B, Low-power magnification reveals nondébrided unfilled portion of otherwise well-filled canal. C, Higher magnification of box area in B. (Courtesy of Dr. Gary Carr and Pacific Endodontic Research Foundation.)

Table 12-3 Classification of Topical Hemostatic Agents

1. Mechanical agents (Nonresorbable)
 - a. Bone wax (Ethicon, Somerville, NJ)
2. Chemical agents
 - a. Vasoconstrictors: epinephrine (Racellets, Epidri, Radri) (Pascal Co, Bellevue, WA)
 - b. Ferric sulfate: Stasis (Cut-Trol, Mobile, AL); Viscostat; Astringent (Ultradent Products, Inc, UT)
3. Biologic agents
 - a. Thrombin USP: Thrombostat (Parke-Davis, Morris Plains, NJ); Thrombogen (Johnson & Johnson Medical, New Brunswick, NJ)
4. Absorbable hemostatic agents
 - a. Mechanical agents
 - i. Calcium sulfate USP
 - b. Intrinsic action agents
 - i. Gelatin: Gelfoam (Upjohn Co, Kalamazoo, MI); Spongostan (Ferrostan, Copenhagen, Denmark)
 - ii. Absorbable collagen: Collatape (Colla-tec Inc, Plainsboro, NJ); Actifoam (Med-Chem Products Inc, Boston, MA)
 - iii. Microfibrillar collagen hemostats: Avitene (Johnson & Johnson, New Brunswick, NJ)
 - c. Extrinsic action agents
 - i. Surgicel (Johnson & Johnson, New Brunswick, NJ)

USP = United States Pharmacopeia.

amounts of softening and conditioning agents. Its hemostatic mechanism of action is purely mechanical in that the wax, when placed under moderate pressure, plugs the vascular openings. **It has no effect on the blood-clotting mechanism.**

When using bone wax for surgical hemostasis, it should first be packed firmly into the entire bony cavity. The excess should then be carefully removed with a curette until only the root apex is exposed. When the root-end surgical procedure is completed, **all remaining bone wax should be thoroughly removed before surgical closure.** Numerous authors, however, have reported the presence of persistent inflammation, foreign-body giant cell reactions, and delayed healing at the surgical site following the use of bone wax.^{130–133} With the availability of more biocompatible and biodegradable products for local hemostasis, **bone wax can no longer be recommended for use in periradicular surgery.**^{2,134}

Vasoconstrictors. Vasoconstrictors, such as epinephrine, phenylephrine, and nordefrin, have been recommended as topical agents for hemorrhage control during periradicular surgery. Of these agents, epinephrine has been shown to be the most effective and the most often recommended.^{2,128,135,136} Cotton pellets containing racemic epinephrine in varying amounts (Epidri, Racellete, Radri) are available (Figure 12-34). For example, each Epidri pellet contains 1.9 mg of

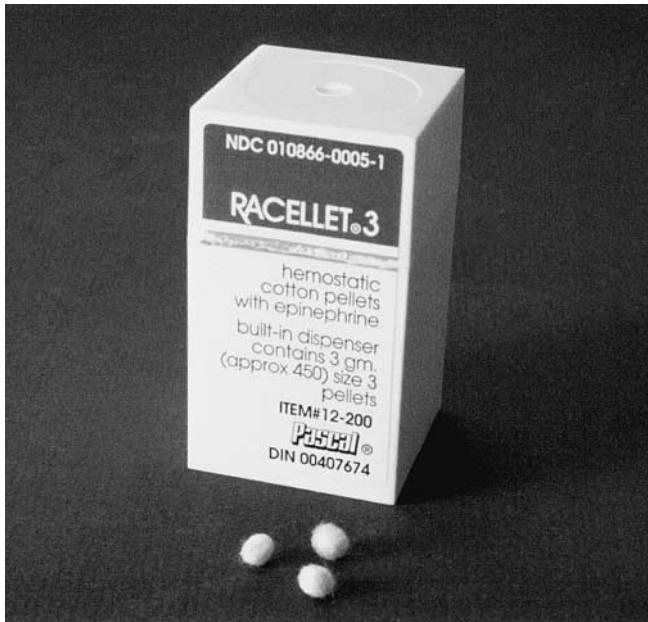

Figure 12-34 Racellet Pellets (Pascal Co, Bellevue, WA). Each pellet contains 0.55 mg of racemic epinephrine. Epidri pellets (Pascal Co) contain 1.9 mg racemic epinephrine.

racemic epinephrine. Each Racellete No. 2 pellet contains 1.15 mg and each Racellete No. 3 pellet contains 0.55 mg of epinephrine. Radri pellets contain a combination of vasoconstrictor and astringent. Each Radri pellet contains 0.45 mg of epinephrine and 1.85 mg of zinc phenolsulfonate.

Two areas of concern when using cotton pellets containing epinephrine need to be addressed. The first is the potential for leaving cotton fibers in the surgical site and the second is the possible hemodynamic effect of epinephrine on the vascular system. Gutmann and Harrison stated that cotton fibers that are left at the surgical site may impair the actual root-end seal by being trapped along the margins of the root-end filling material.² They also stated that cotton fibers may serve as foreign bodies in the surgical site and result in impaired wound healing. Cotton pellets and gauze products containing cotton should, therefore, be considered the least desirable materials to be used for root-end isolation or hemostasis. Sterile Telfa pads (Kendall Co., Mansfield, Mass.) are useful adjuncts as they contain no cotton fibers. They can be cut into small squares that are easily adapted to the surgical site (Figure 12-35).

Weine and Gerstein and Selden have cautioned against the use of vasoconstrictors as topical agents for hemostasis during periradicular surgery because their use may result in systemic vascular change.^{76,129} Besner, however, has shown that when a Racellete No. 2 pellet containing 1.15 mg of epinephrine was used during




Figure 12-35 Telfa pads contain no cotton fibers and can be cut into small squares that are easily adapted to the surgical site.

periradicular surgery, the pulse rate of the patient did not change.¹³⁷ Pallasch has stated that, although the use of vasoconstrictors in topical hemostatic agents and gingival retraction cord remains controversial, data exist from which to formulate reasonable guidelines. Elevated blood levels of epinephrine can occur with their use but do not generally appear to be associated with any significant cardiovascular effects in healthy patients or those with mild to moderate heart disease. In patients with more severe heart disease, epinephrine-impregnated cotton pellets or gauze, or gingival retraction cord, should be used with caution or avoided.¹³⁸ Kim and Rethnam, however, have stated that, because epinephrine used topically causes immediate local vasoconstriction, there is little absorption into the systemic circulation and thus a reduced chance of a systemic effect.¹²⁸

Ferric Sulfate. Ferric sulfate is a chemical agent that has been used as a hemostatic agent for over 100 years. It was first introduced as Monsel's solution (20% ferric sulfate) in 1857. Its mechanism of action results from the agglutination of blood proteins and the acidic pH (0.21) of the solution. In contrast to vasoconstrictors, ferric sulfate effects hemostasis through a chemical reaction with the blood rather than an alpha-adrenergic effect.¹²⁸

Ferric sulfate is easy to apply, requires no application of pressure, and hemostasis is achieved almost immediately (Figure 12-36). Ferric sulfate, however, is

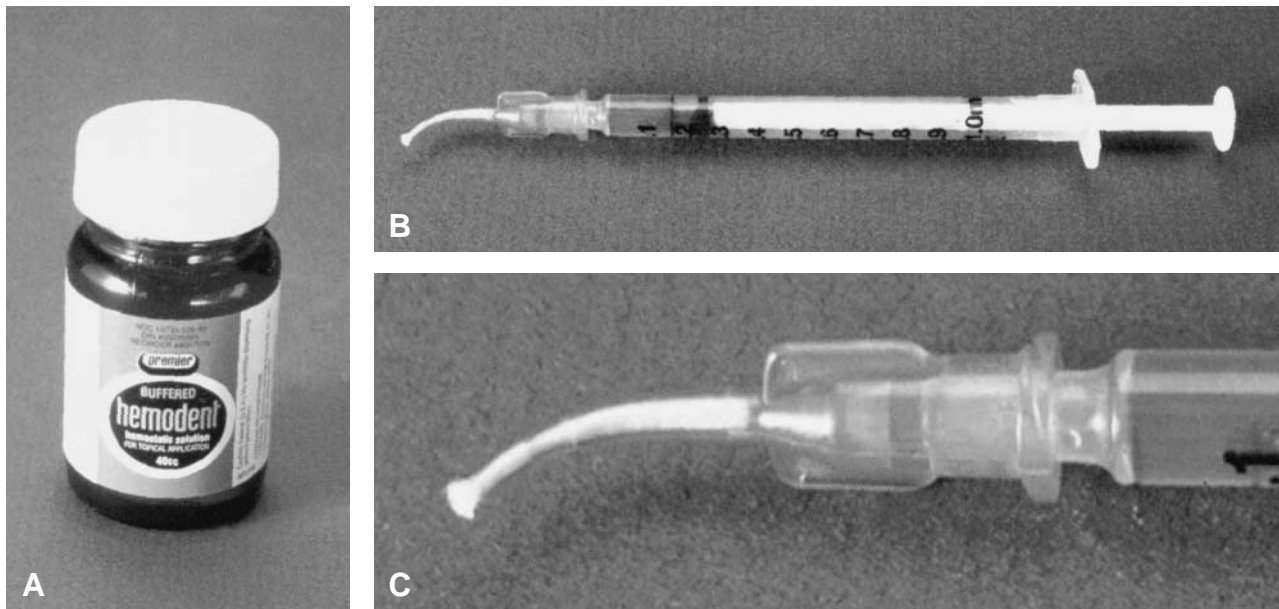


Figure 12-36 Hemodent (Premier Dental; King of Prussia, Pa.). A, Ferric sulfate achieves hemostasis as a result of agglutination of blood proteins rather than from an alpha-adrenergic effect like epinephrine. B, An Infusion Tip (Ultradent Products Inc., Utah) placed on a 1.0 cc syringe (Monoject) containing a small amount of ferric sulfate solution. The infusion tip allows for controlled placement of the hemostatic agent. C, Close-up of infusion tip.

known to be cytotoxic and may cause tissue **necrosis and tattooing**. Systemic absorption is unlikely because the agglutinated protein plugs that occlude the blood-vessel orifices isolate it from the vascular supply.¹²⁸ Lemon and associates, using rabbit mandibles, reported a significant adverse effect on osseous healing when ferric sulfate was left in the surgical site following creation of experimental surgical bony defects.¹³⁹ Jeansonne and associates, however, using a similar rabbit model, reported that when ferric sulfate was placed only until hemostasis was obtained and the surgical site was thoroughly curetted and irrigated with sterile saline 5 minutes later, there was no significant difference in osseous repair, as compared with the untreated controls.¹⁴⁰ Ferric sulfate appears to be a safe hemostatic agent when used in limited quantities and care is taken to **thoroughly curette and irrigate** the agglutinated protein material before surgical closure.¹²⁸

Thrombin. Topical thrombin has been developed for hemostasis wherever wounds are oozing blood from small capillaries and venules. Thrombin acts to initiate the extrinsic and intrinsic clotting pathways. It is designed for topical application only and may be life threatening if injected. Topical thrombin has been investigated as a hemostatic agent in abating bleeding in cancellous bone. Although there was less bleeding than in the control, thrombin was **not** as

effective as other available topical hemostatic agents.¹³⁴ In a report of a study by Codben and associates, no impedance of bone healing was evident 3 months following the use of topical thrombin.¹⁴¹ Topical thrombin has been used successfully in neurosurgery, cardiovascular surgery, and burn surgery; however, its use in periradicular surgery has not been adequately investigated at this time. The main disadvantages of topical thrombin are its difficulty of handling and high cost.

Calcium Sulfate. Calcium sulfate (plaster of Paris) is a resorbable material used in surgery for over 100 years. It has gained popularity, in recent years, as a barrier material in guided tissue-regeneration procedures.^{142,143} Calcium sulfate can also be used as a hemostatic agent during periradicular surgery. It consists of a powder and liquid component that can be mixed into a thick putty-like consistency and placed in the bony crypt using wet cotton pellets to press it against the walls. The hemostatic mechanism of calcium sulfate is similar to bone wax in that it acts as a mechanical barrier, plugging the vascular channels. In contrast to bone wax however, calcium sulfate is biocompatible, resorbs completely in 2 to 4 weeks, and does not cause an increase in inflammation. It is porous, which allows for fluid exchange so that flap necrosis does not occur when left in place following surgery. Calcium sulfate also has the advantage of being relatively inexpensive.¹²⁸

Gelfoam and Spongostan. Gelfoam and Spongostan are hard, gelatin-based sponges that are water insoluble and resorbable. They are made of animal-skin gelatin and become soft on contact with blood. Gelatin sponges are thought to act intrinsically by promoting the disintegration of platelets, causing a subsequent release of thromboplastin. This, in turn, stimulates the formation of thrombin in the interstices of the sponge.¹²⁸

The main indication for the use of gelatin-based sponges is to control bleeding in surgical sites by leaving it in situ, such as in extraction sockets, where hemostasis cannot be achieved by the application of pressure. During periradicular surgery, hemostasis is needed for improved visualization to accomplish the delicate task of root-end resection and filling. Once the gelatin sponge contacts blood, it swells and forms a soft, gelatinous mass. This swollen, soft, gelatinous mass tends to visually obscure the surgical site. Because it is soft, pressure cannot be applied to the severed microvasculature without dislodging the gelatin sponge, which will result in a continuation of bleeding. The major use for gelatin-based sponges in periradicular surgery is placement in the bony crypt, after root-end resection and root-end filling have been completed just before wound closure. Because gelatin-based sponges promote disintegration of platelets, release of thromboplastin, and the formation of thrombin, they may be beneficial in reducing postsurgical bleeding from the "rebound phenomenon."

The initial reaction to gelatin-based sponge material in the surgical site is a **reduction in the rate of osseous healing**. Boyes-Varley and associates examined early healing in the extraction sockets of monkeys. Histologically, the sockets containing gelatin-based sponge material displayed a greater inflammatory cell infiltrate, marked reduction in bone in-growth, and a foreign-body reaction at 8 days.¹⁴⁴ Olson and associates, however, reported that there was no distinguishable difference in healing rate or inflammatory cell infiltrate between extraction sockets in which Gelfoam was placed and the controls after 90 days.¹⁴⁵

Collagen. Collagen-based products have been used extensively as surgical hemostatic agents. It is believed that four principal mechanisms of action are involved in hemostasis enhanced by collagen-based products: (1) stimulation of platelet adhesion, aggregation, and release reaction¹⁴⁶; (2) activation of Factor VIII (Hageman Factor)¹⁴⁷; (3) mechanical tamponade action¹⁴⁸; and (4) the release of serotonin.¹⁴⁹ The collagen used for surgical hemostasis is obtained from bovine sources and is supplied in sheets (Collatape) and sponge pads (Actifoam). Both forms are applied

dry, directly to the bleeding site, while using pressure. Hemostasis is usually achieved in 2 to 5 minutes.¹²⁸

Microfibrillar Collagen Hemostat. Avitene and Instat are two popular forms of microfibrillar collagen. It is derived from purified bovine dermal collagen, shredded into fibrils, and converted into an insoluble partial hydrochloric acid salt. It functions through topical hemostasis, providing a collagen framework for platelet adhesion. This initiates the process of platelet aggregation and adhesion and formation of a platelet plug.¹⁵⁰ Avitene has been recommended as a viable means of controlling hemorrhage in periodontal surgery, resulting in a minimal interference in the osseous wound-healing process.^{151,152} Haasch and associates have demonstrated its potential use in periradicular surgery.¹⁵³ In a study designed to examine osseous regeneration in the presence of Avitene, Finn and associates found that bone formation proceeded uneventfully without a foreign-body reaction.¹⁵⁴

The application of microfibrillar collagen products may be difficult and tedious, at times, because of their affinity for wet surfaces, such as instruments and gloves. To overcome these problems, it has been recommended that they be applied to the surgical site by use of a spray technique. This allows direct application of the hemostatic agent to the bleeding points.¹⁵⁵ Other disadvantages of microfibrillar collagen products: they are inactivated by autoclaving, their use in contaminated wounds may enhance infection, and they are expensive compared with other topical hemostatic agents.¹²⁸

Surgicel. Surgicel is a chemically sterilized substance resembling surgical gauze and is prepared by the oxidation of regenerated cellulose (oxycellulose), which is spun into threads, then woven into a gauze that is sterilized with formaldehyde. Its mode of action is principally physical since it does not affect the clotting cascade through aggregation or adhesion of platelets, such as the collagen-based products. Surgicel initially acts as a barrier to blood and then as a sticky mass that acts as an artificial coagulum or plug.¹³⁴

Surgicel left in bone following surgery has been shown to markedly **reduce the rate of repair and increase inflammation**. Difficulty in completely removing Surgicel from bony wounds has been described, with even minimally retained fragments resulting in inflammation and a foreign-body reaction.¹³⁰ The manufacturer, Johnson and Johnson, **does not recommend implantation of Surgicel** in bony defects.¹⁵⁶

Instrumentation. Root-end preparation techniques have historically involved a recommendation that the endodontic surgeon, following the root-end resection, examine the root canal filling to determine

the quality of the seal. Adequately evaluating the quality of seal of a root canal filling requires measurements in the area of microns, and we currently do not possess these capabilities at a clinical level. SEM studies have shown that the act of **root-end resection disturbs the gutta-percha seal.**^{157,158} The preparation for, and the placement of, a **root-end filling is therefore recommended** whenever root-end resection has been performed.⁸²

Root-end preparations should accept filling materials that predictably seal off the root canal system from the periradicular tissues. Carr and Bentkover have defined an ideal root-end preparation as a class I preparation at least 3.0 mm into root dentin with walls parallel to and coincident with the anatomic outline of the pulp space.⁸² They also identified five requirements that a root-end preparation must fulfill:

1. The apical 3 mm of the root canal must be freshly cleaned and shaped.
2. The preparation must be parallel to and coincident with the anatomic outline of the pulp space.
3. Adequate retention form must be created.
4. All isthmus tissue, when present, must be removed.
5. Remaining dentin walls must not be weakened.

For successful root-end preparations, the endodontic surgeon must be well versed in both root morphology and root canal system anatomy. The teeth that

require periradicular surgery are often those in which the anatomy is unusual or complex.⁸²

Bur Preparation. The traditional root-end cavity preparation technique involved the use of either a miniature contra angle or straight handpiece and a small round or inverted cone bur. The objective was to prepare a class I cavity preparation down the long axis of the root within the confines of the root canal. The recommended depth of the preparation ranged from 1 to 5 mm, with 2 to 3 mm being the most commonly advocated.^{76,78,104}

The ability of the endodontic surgeon to prepare a class I cavity parallel to the long axis of the root with a miniature contra angle handpiece may be difficult and depends on the physical access available around the root apex. According to Arens et al., this requires a minimum of 10 mm above or below the point of entry.³² Accomplishing this with a straight handpiece is virtually impossible. These preparations are most often placed obliquely into the root, resulting in a risk of perforation and/or weakening of the dentin walls, and predisposing to a possible root fracture (Figure 12-37, A).

Ultrasonic Root-End Preparation. Ultrasonic root-end preparation techniques have been developed in an attempt to solve the major inadequacies and shortcomings of the traditional bur-type preparation. The use of ultrasonic instrumentation during periradicular surgery was first reported by Richman in 1957 when he used an ultrasonic chisel to remove bone and




Figure 12-37 Comparison between bur and ultrasonic root-end preparations. A, Bur preparation shows large cavity prepared obliquely to the canal with a No. 33½ inverted cone bur. B, Ultrasonic preparation shows clean preparation parallel to the canal. Scanning electron micrograph. (Courtesy of Dr. Gary Wuchenich and Dr. Debra Meadows.)

root apices.¹⁵⁹ This concept was further developed by Bertrand and colleagues in 1957 when they reported on the use of modified ultrasonic periodontal scaling tips for root-end preparations in periradicular surgery.¹⁶⁰ Recently, specially designed ultrasonic root-end preparation instruments have been developed and are available from a number of instrument manufacturers (Figure 12-38). Their use has become very popular and they appear to have many advantages over the traditional bur-type preparation, such as smaller preparation size, less need for root-end beveling, a deeper preparation, and more parallel walls for better retention of the root-end filling material (Figure 12-37, B).

After the root-end resection has been completed, all soft tissue that needs to be removed has been curetted from the lesion, and proper hemostasis achieved, the resected root face should be thoroughly examined. The use of **magnification** and staining with methylene blue dye will aid in the identification of additional portals of exit, aberrant anatomy, and/or isthmuses not readily apparent. An appropriate cavity design should be planned and its outline identified by lightly etching it on the dentin of the resected root face with the sharp point of a CT-5 ultrasonic tip without irrigation to enhance vision.

After the outline of the root-end preparation has been established, the preparation should be deepened with an appropriately sized and angled ultrasonic tip, with irrigation, on the lowest power setting possible to accomplish dentin and root canal filling material removal. A light touch with a brush-type motion should be used, which will facilitate the maximum cutting efficiency and reduce pressure against the root surface. Special attention and care should be taken regarding removal of all root canal filling material on the lateral walls of the root-end cavity preparation, **especially the labial or facial wall**. This is a vulnerable area in which root canal filling material or debris is often left, resulting in a compromised root-end seal.

At the completion of the root-end preparation, it should be thoroughly irrigated with sterile saline, dried, and examined, preferably with **magnification**, for quality and cleanliness. Small, front-surface micro-mirrors are a beneficial adjunct to this examination process (Figure 12-39). Properly performed, ultrasonic root-end cavity instrumentation produces conservative, smooth, nearly parallel walled preparations (Figure 12-40). In a study involving SEM examination, root-end preparations using ultrasonic instrumentation have been reported to be contaminated with less debris and smear layer than those prepared using a bur. Ultrasonic instrumentation also resulted in root-end

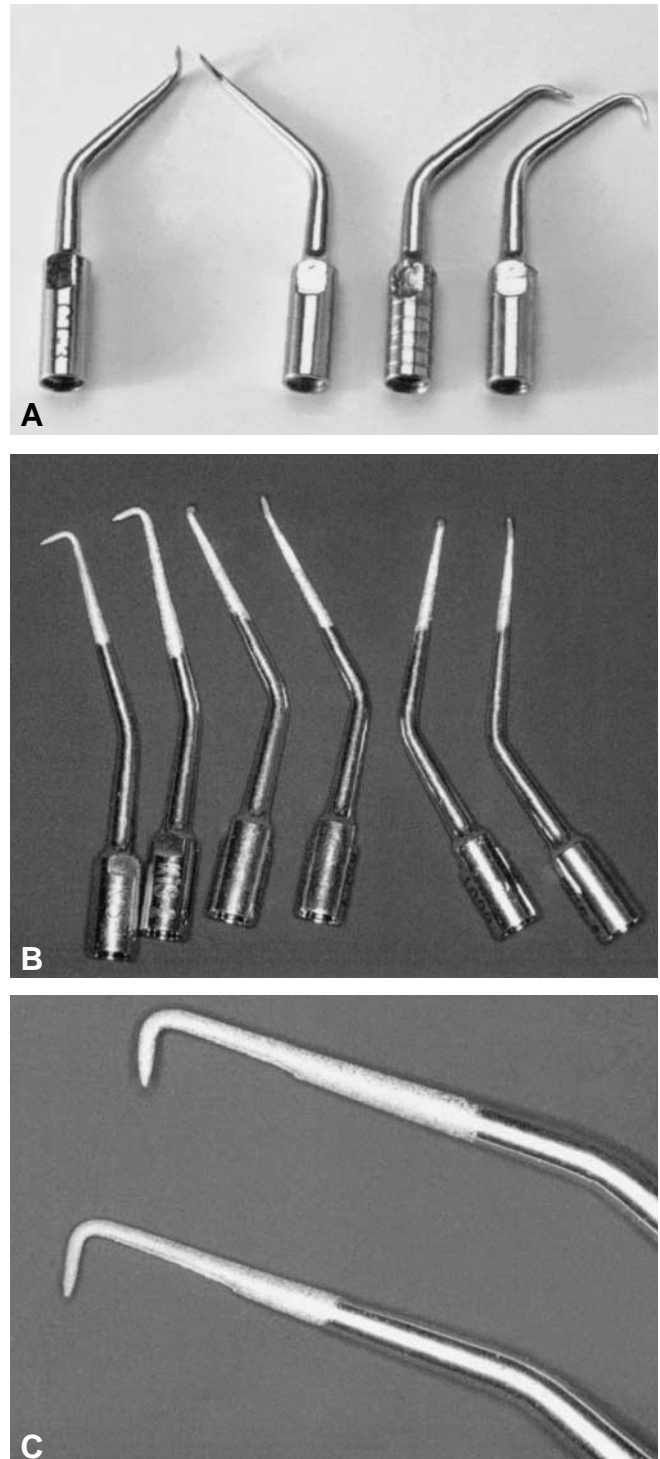


Figure 12-38 Ultrasonic tips. **A**, Ultrasonic tips developed by Dr. Gary Carr (Excellence in Endodontics, San Diego, CA). Available with plain or diamond-coated tips. **B**, KiS Microsurgical Ultrasonic Instruments (Obtura Spartan, Fenton, MO). The tips are coated with zirconium nitride for faster dentin cutting with less ultrasonic energy. **C**, Close-up of KiS Microsurgical Ultrasonic Instruments.




Figure 12-39 Variety of small front surface micro-mirrors for viewing root-end resection and root-end preparation through the microscope.

cavities that followed the direction of the root canal more closely than those prepared with a bur^{161,162} (see Figure 12-37, B).

A recent controversy has developed regarding the potential for ultrasonic energy in root-end cavity preparation to result in the **formation of cracks** in the dentin surrounding the root-end preparation. Some authors have reported that the use of ultrasonic instrumentation resulted in an increased number and extent of dentin crack formation.^{163,164} Others have reported no difference in the incidence of dentin crack formation between bur and ultrasonic root-end cavity preparation in extracted teeth.^{165,166}

Layton and associates reported an *in vitro* study evaluating the integrity of the resected root-end surfaces, following root-end resection and after root-end preparation, with ultrasonic instrumentation at low and high frequencies. The results indicated that root-end resection alone may result in dentin crack formation regardless of the type of root-end preparation.

Their data also indicated that **more dentin cracks** occurred when the ultrasonic tip was used on the **high-frequency setting** than on the low-frequency setting and that more cracks resulted following ultrasonic root-end cavity preparation, regardless of the frequency setting, than after root-end resection alone.¹⁶⁷

Calzonetti and associates used a polyvinylsiloxane replication technique to study cracking after root-end resection and ultrasonic root-end preparation in cadavers' teeth. They found **no cracks** in 52 prepared root-ends examined under scanning electron microscopy.¹⁶⁸ Their results indicate that there is a possibility that the **intact periodontal ligament** adds a protective function by **absorbing the shock** of ultrasonic vibrations to prevent cracking in the clinical setting, a possibility that was not observed in extracted human teeth studies.

Morgan and Marshall reported on an *in vivo* study using electron microscopy to examine resin casts made from polyvinylsiloxane impressions taken following

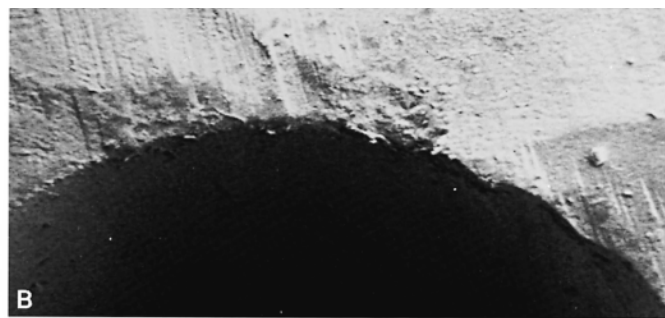



Figure 12-40 A, Eight-power dental operating microscope view of root-end preparation using Carr ultrasonic tips. Preparation is 0.5 mm in diameter. B, Higher magnification shows smoothness of walls. (Courtesy of Dr. Gary Carr.)

root-end resection and root-end preparation with ultrasonic instrumentation at **low power setting**. Their results revealed that **no cracks were evident** on any of the roots following root-end resection alone and **only one small, shallow, incomplete crack** was detected from **25 roots following ultrasonic root-end preparation**.¹⁶⁹

Sumi and associates reported on a human clinical outcomes assessment study that evaluated the success/failure rate of periradicular surgeries performed on 157 teeth involving root-end cavity preparations using ultrasonic instrumentation. Observation periods ranged from 6 months to 3 years. Outcome assessment was based on clinical and radiographic findings. A success rate of 92.4% was reported. It was concluded that ultrasonic root-end preparation provides excellent clinical results.¹⁷⁰ **Available evidence indicates that root-end cavity preparation using ultrasonic instrumentation provides a convenient, effective, and clinically acceptable method for preparing the resected root end to receive a root-end filling.**

Root-End Filling

The purpose of a root-end filling is to establish a seal between the root canal space and the periapical tissues. According to Gartner and Dorn, a suitable root-end filling material should be (1) able to prevent leakage of bacteria and their by-products into the periradicular tissues, (2) nontoxic, (3) noncarcinogenic, (4) biocompatible with the host tissues, (5) insoluble in tissue fluids, (6) dimensionally stable, (7) unaffected by moisture during setting, (8) easy to use, and (9) radiopaque.¹⁷¹ One might add, it should not stain tissue (tattoo).

Root-End Filling Materials. Numerous materials have been suggested for use as root-end fillings, including gutta-percha, amalgam, Cavit, intermediate restorative material (IRM), Super EBA, glass ionomers, composite resins, carboxylate cements, zinc phosphate cements, zinc oxide-eugenol cements, and mineral trioxide aggregate (MTA). The suitability of these various materials has been tested by evaluating their microleakage (dye, radioisotope, bacterial penetration, fluid filtration), marginal adaptation, and cytotoxicity and clinically testing them in experimental animals and humans.

A large number of *in vitro* studies dealing with the marginal adaptation and sealing ability (leakage) of various root-end filling material have been published. The results of these studies have often been inconsistent, contradictory, and confusing and have been questioned as to their clinical relevance. Factors such as the choice of storage solutions and the molecular size of the dye particles, and many other variables, can crucially influence the outcome of these *in vitro* studies.¹⁷²

In vitro cytotoxicity and biocompatibility studies using cell cultures have also been published. Owadally and associates reported on an *in vitro* antibacterial and cytotoxicity study comparing IRM and amalgam. Their results indicated that IRM was significantly more antibacterial than amalgam at all time periods of exposure, and amalgam was significantly more cytotoxic than IRM.¹⁷³ Makkawy and associates evaluated the cytotoxicity of resin-reinforced glass ionomer cements compared with amalgam using human periodontal ligament cells. Their results indicated that, at 24 hours, amalgam significantly inhibited cell viability compared with resin-reinforced glass ionomer cement and the controls. At 48 and 72 hours, however, all materials tested exhibited a similar slightly inhibitory effect on cell viability.¹⁷⁴

Chong and associates compared the cytotoxicity of a glass ionomer cement (Vitrebond; 3M Dental; St Paul, Minn.), Kalzinol, IRM and EBA cements, and amalgam. Their results indicated that fresh IRM cement exhibited the most pronounced cytotoxic effect of all materials tested. Aged Kalzinol was the second most cytotoxic material, with no significant difference being reported between Vitrebond EBA cement and amalgam.¹⁷⁵

Zhu, Safavi, and Spangberg evaluated the cytotoxicity of amalgam, IRM cement, and Super-EBA cement in cultures of human periodontal ligament cells and human osteoblast-like cells. Their results indicated that amalgam was the most cytotoxic of the materials tested and showed a reduction in total cell numbers for both cell types. IRM and Super-EBA, however, were significantly less cytotoxic than amalgam and demonstrated no reduction in total cell numbers for both periodontal ligament and osteoblast-like cells.¹⁷⁶

Several authors have published results of *in vivo* tissue compatibility studies of various root-end filling materials using an experimental animal model. Harrison and Johnson reported on a study designed to determine the excisional wound-healing responses of the periradicular tissues to IRM, amalgam, and gutta-percha using a dog model. Healing responses were evaluated microscopically and radiographically at 10 and 45 days postsurgically. They reported **no evidence of inhibition** of dentoalveolar or osseous wound healing associated with amalgam, gutta-percha, or IRM. Statistical analysis showed no difference in wound healing among the three materials tested.¹⁷⁷

Pitt Ford and associates examined the effects of IRM, Super-EBA, and amalgam as root-end filling materials in the roots of mandibular molars of monkeys. They reported that the tissue response to IRM and Super-EBA was less severe than that to amalgam. No

inflammation was evident in the bone marrow spaces adjacent to root-end fillings of IRM and Super-EBA. In contrast, however, inflammation was present in the alveolar bone marrow spaces with every root end filled with amalgam.^{178,179}

A research group at Kyushu University in Japan reported the results of a histologic study comparing the effects of various root-end filling materials, including a 4-META-TBB resin (C&B Metabond, Parkell, Farmingdale, N.Y.), using a rat model. The materials tested were amalgam, light-cured glass ionomer cement, IRM, a 4-META-TBB resin, and light-cured composite resin. The 4-META-TBB resin and light-cured composite resin root-end fillings showed the most favorable histologic response among the materials tested. These materials did not provoke inflammation and did not appear to inhibit new bone formation, as seen with the other materials.¹⁸⁰

Torabinejad and associates reported on a study designed to examine and compare the tissue reaction to several commonly used root-end filling material and a newly developed material, MTA (ProRoot, Tulsa Dental/Dentsply International; Tulsa, Okla.). Their study involved the implantation of amalgam, IRM, Super-EBA, and MTA in the tibias and mandibles of guinea pigs. The presence of inflammation, predominant cell type, and thickness of fibrous connective tissue adjacent to each implanted material was evaluated. The tissue reaction to implanted MTA was the most favorable observed at both implantation sites; in every specimen, it was free of inflammation. Mineral trioxide aggregate was also the material most often observed with direct bone apposition.¹⁸¹

Mineral trioxide aggregate was developed by Torabinejad and his associates at Loma Linda University. The main molecules present in MTA are calcium and phosphorous ions, derived primarily from tricalcium silicate, tricalcium aluminate, tricalcium oxide, and silicate oxide. Its pH, when set, is 12.5 and its setting time is 2 hours and 45 minutes. The compressive strength of MTA is reported to be 40 MPa immediately after setting and increases to 70 MPa after 21 days. The result of solubility testing of MTA (ADA specification #30) indicated an insignificant weight loss following testing.¹⁸²

Mineral trioxide aggregate has been extensively evaluated for microleakage (dye penetration, fluid filtration, bacterial leakage), marginal adaptation (SEM), and biocompatibility (cytotoxicity, tissue implantation, and in vivo animal histology). The sealing ability of MTA has been shown to be superior to that of Super-EBA and was not adversely affected by blood contamination. Its marginal adaptation was shown to be better than amalgam, IRM, or Super-EBA. Mineral trioxide aggregate

has also been shown to be less cytotoxic than amalgam, IRM, or Super-EBA. Animal usage tests in which MTA and other commonly used root-end filling material were compared have resulted in less observed inflammation and better healing with MTA. In addition, with MTA, new cementum was observed being deposited on the surface of the material¹⁸³⁻¹⁹⁴ (Figure 12-41).

Many prospective and retrospective human clinical usage studies have been reported that assess the outcome of periradicular surgery involving the placement of various root-end filling materials. It is difficult to compare the results of these studies because the authors have used differing evaluation criteria and observations periods. It is important, however, to consider some of the more significant of these clinical usage reports.

Oynick and Oynick, in 1978, reported on the clinical use of a resin and silicone-reinforced zinc oxide and eugenol cement (Stailine, Staines, England) as a root-end filling material in 200 cases over a period of 14 years. Radiographic evaluations following periradicular surgical procedures using Stailine indicated favorable healing. Histologic and SEM evaluations of the root apex and adjacent periradicular bone, taken by block section, revealed newly formed bone in areas of previous resorption and collagen fibers growing into the filling material.¹⁹⁵

Dorn and Gartner reported on a retrospective study of 488 periradicular surgical treatments in which three different root-end filling materials were used, IRM, Super-EBA, and amalgam. The evaluation period was from 6 months to 10 years. Outcome assessment was conducted by evaluation of the most recent recall radi-

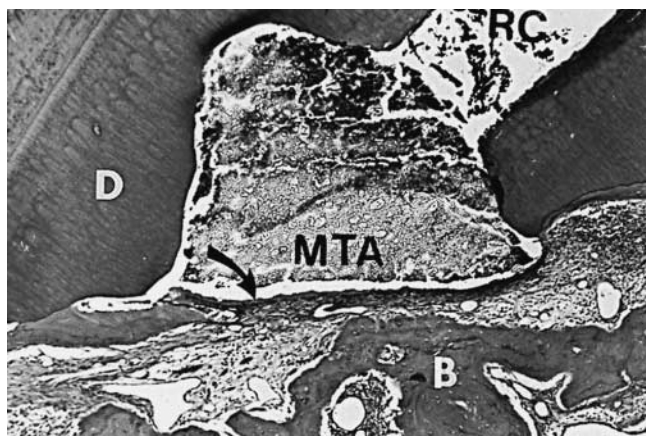


Figure 12-41 Mineral trioxide aggregate (MTA) retrofilling. Cementum (arrow) formed subjacent to the filling material (separated from the material during slide preparation). B = bone; D = dentin; RC = root canal. (Courtesy of Dr. M. Torabinejad.)

ograph as compared with the immediate postsurgical radiograph. Analysis of the data indicated there was no significant difference in the outcome of healing rates between IRM and Super-EBA. There was a significant difference, however, in the outcome between IRM, Super-EBA, and amalgam, the latter being the worst.¹⁹⁶ Pantshev and associates, however, reported on a prospective clinical study that evaluated the outcome of periradicular surgical procedures using either EBA cement or amalgam. The minimum evaluation period was 3 years and healing was based on clinical and radiographic analysis. Their data indicated no significant difference in the outcome between the two materials evaluated.¹⁹⁷

Rud and associates have reported on several prospective and retrospective human usage studies in an attempt to evaluate the acceptability of a composite resin, combined with a **dentin bonding agent**, as a root-end filling material. The placement is different from other root-end fillings in that no root-end preparation, other than root-end resection, is made. The material covers the entire resected root-end surface. They have shown that the creation of a leak-resistant seal is possible with this material; however, **the process is very technique sensitive** as a result of the need for **strict moisture control**. They have reported complete bone healing in 80 to 92% of cases using this technique. Their observation periods ranged from 1 to 9 years.^{198–202}

Smear Layer Removal. Instrumentation of dentin results in the accumulation of a smear layer covering the dentinal surface and occluding the dentinal tubules. It has been shown that bacteria may colonize in the smear layer and penetrate the dentinal tubules.²⁰³ **Removal of this smear layer** seems desirable in the situation of root-end fillings that are placed in a bacterially contaminated root apex. Irrigation with tetracycline has been shown to remove the smear layer.²⁰⁴ Smear layer removal from resected root ends and dentin demineralization by citric acid has been shown to be associated with more rapid healing and deposition of cementum on the resected root-end.²⁰⁵

Tetracyclines have a number of properties of interest to endodontists; they are antimicrobial agents, effective against periodontal pathogens; they bind strongly to dentin; and when released they are still biologically active.²⁰⁶ Root surfaces exposed to anaerobic bacteria accumulate endotoxin and exhibit collagen loss, which may suppress fibroblast migration and proliferation, thus interfering with healing.²⁰⁷ Root surface conditioning with acidic agents, such as **tetracycline**, not only **removes the smear layer**, it also **removes endotoxin** from contaminated root surfaces.²⁰⁸

Barkhordar and Russel reported on an in vitro study that examined the effect of irrigation with doxycycline hydrochloride, a hydroxy derivative of tetracycline, on the sealing ability of IRM and amalgam, when used as root-end fillings. Their results indicated significantly less microleakage following irrigation with doxycycline involving both IRM and amalgam, compared with the control irrigation with saline. They also suggested that, because of the long-lasting sustentative of **doxycycline** on root surfaces and its slow release in a biologically active state, their results support **its use for dentin conditioning** before placement of a root-end filling in periradicular surgery.²⁰⁹

Based on a review of the currently available literature, there does not appear to be an “ideal” root-end filling material. Intermediate restorative material, Super-EBA, and MTA appear to be the currently available materials that most closely meet the requirements, both physical and biologic, for a root-end filling material. MTA is a relatively new material, compared with IRM and Super-EBA, and long-term human usage studies are as yet not available for any of these materials. Final judgment on their use will need to be reserved until such clinical usage studies are available.

Placement and Finishing of Root-end Fillings. The method for placement of the root-end filling material will vary depending on the type of filling material used. Amalgam may be carried to the root-end preparation with a small K-G carrier that is sized for root-end preparations. Deeper lying apices may be more easily reached by using a Messing gun (Figure 12-42). Zinc oxide–eugenol cements (IRM and Super-EBA) are best mixed to a thick clay-like consistency, shaped into a small cone, and attached to the back side of a spoon excavator or the tip of a plastic instrument or Hollenback carver and placed into the root-end preparation.

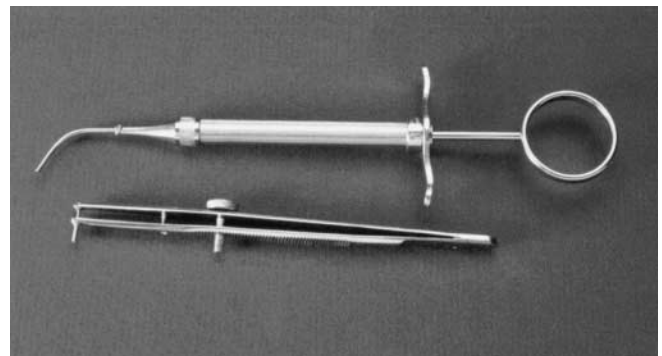


Figure 12-42 Root-end filling material carriers. Top, Messing gun with a curved tip. Bottom, Small K-G carrier.

Mineral trioxide aggregate is a unique root-end filling material with physical properties much different from other materials. It is a very fine, gray-colored powder that is mixed with a sterile liquid, such as saline or local anesthetic solution, on a sterile glass slab. It cannot be mixed to a clay-like consistency as can IRM or Super-EBA because as more powder is added to the liquid, the mix becomes dry and crumbly. If the mix is too wet, it is runny and very difficult to handle because of its lack of form. The surgical area must be kept very dry during its placement, and care must be taken not to wash out the filling material by irrigation before closure of the soft tissue. The setting time of MTA is 2.5 to 3 hours. Properly mixed, MTA should be free of excess moisture, **firm, but not crumbly**. It can be delivered to the root-end preparation by placing a small amount on the back side of a small spoon excavator or by using a small amalgam-type carrier (Figure 12-43).

Root-end preparations using ultrasonic tips tend to be smaller in diameter and extend deeper into the root canal than those prepared with a bur. As a result, the need for specially designed **root-end filling condensers** has resulted in their availability from many different manufacturers in various styles and shapes (Figure 12-44). It is important that the endodontic surgeon become familiar with the different shapes and styles of condensers to enable the surgeon to properly condense the root-end filling material to the full extent of the root-end preparation. The condenser should be small enough in diameter that it does not bind on the walls

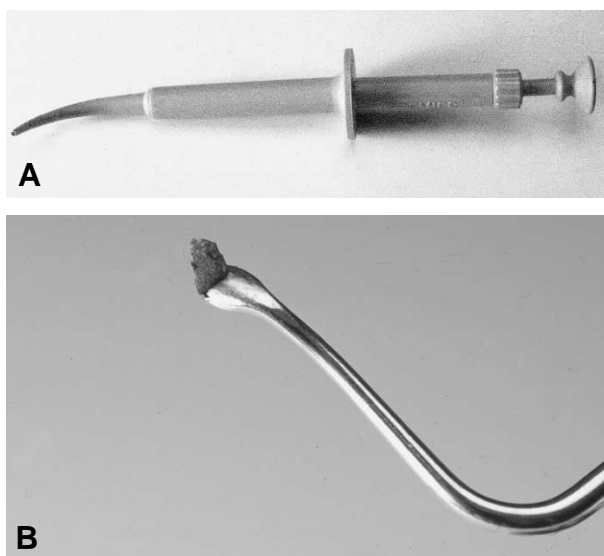


Figure 12-43 Carriers for mineral trioxide aggregate (MTA). A, Small plastic amalgam-type carrier (Premier Dental, King of Prussia, Pa.). B, A small amount of MTA can be carried and placed into the root-end preparation on the back side of a spoon excavator.




Figure 12-44 Small condensers for placing root-end filling material into ultrasonic preparations (Thompson Dental Mfg. Co).

of the root-end preparation during condensation, thus resulting in the possibility of root-end fractures. It is also important that the condenser is long enough to properly condense the filling material into the deepest part of the root-end preparation.

Various techniques have been advocated for finishing root-end fillings in periradicular surgery. Fitzpatrick and Steiman reported on an *in vitro* study designed to evaluate the marginal interfaces between the dentin and root-end fillings of IRM and Super-EBA. Following placement of the root-end fillings, they were finished by burnishing with a ball burnisher, a moistened cotton pellet, or with a carbide finishing bur in a high-speed handpiece with air/water spray. Their results indicated that **root-end fillings finished with a finishing bur displayed significantly better marginal adaptation**, with little evidence of flash, when compared with the other methods. There was no significant difference between the other finishing techniques or between the materials tested.²¹⁰

Forte and associates reported on an *in vitro* study designed to compare microleakage, by the fluid filtration method, of root-end fillings of Super-EBA either unfinished or finished with a 30-flute high-speed finishing bur. Their results indicated **no significant difference** in microleakage, after 180 days, between root-end fillings of Super-EBA, finished or unfinished.²¹¹

Soft-Tissue Repositioning and Suturing

After final inspection of the root-end filling and removal of all visible excess filling material and surgical packing, a radiograph should be taken to evaluate the placement of the root-end filling and to check for the presence of any root fragments or excess root-end filling material (Figure 12-45). If ferric sulfate was used as a hemostatic

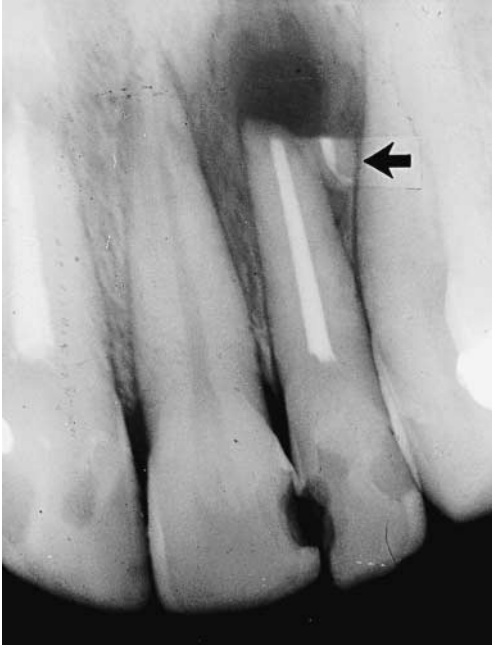

Figure 12-45 Radiograph taken after suturing and developed after patient left the office. The patient had to return for removal of root tip.

agent during surgery, the coagulated protein material should be thoroughly curetted and hemorrhage induced so that healing is not impaired.¹²⁸ Thorough examination of the underside of the flap, in the depth of the fold between the mucoperiosteum and the alveolar bone, should be done before repositioning the flap to remove any debris or foreign material that may be present. The final steps in the periradicular surgical procedure are wound closure and soft-tissue stabilization.

Repositioning and Compression. The elevated mucoperiosteal tissue should be gently replaced to its original position with the incision lines approximated as closely as possible. The type of flap design will affect the ease of repositioning, with full mucoperiosteal flaps generally providing less resistance to repositioning than would limited mucoperiosteal flaps. Using a surgical gauze, slightly moistened with sterile saline, gentle but firm pressure should be applied to the flapped tissue for 2 to 3 minutes (5 minutes for palatal tissue) before suturing. **Tissue compression**, both before and after suturing, not only enhances intravascular clotting in the severed blood vessels but also approximates the wound edges, especially the dissectional wound. This reduces the possibility of a blood clot forming between the flap and the alveolar bone.²

Suturing. It is important to stabilize the reflected tissue to prevent dislodgment until initial wound healing has taken place. Several authors have reported on studies in animals and humans designed to evaluate the effec-

tiveness of medical grade adhesives, such as cyanoacrylate, for surgical wound closure and to compare them with sutures. Results of these studies have been mixed, and, at this time, their use has not replaced that of sutures for wound closure in endodontic surgery.²¹²⁻²¹⁸

The purpose of suturing is to approximate the incised tissues and stabilize the flapped mucoperiosteum until reattachment occurs. The placement of sutures in oral tissues, however, creates unique problems. It is evident that incisional wounds in oral tissues heal more rapidly than in skin. However, sutures are better tolerated and interfere less with postsurgical healing in the skin. "The major problem in oral tissues is the constant bathing of the suture material and suture tract with saliva containing a high concentration of microorganisms, that may gain entrance to underlying tissues."²

Sutures are available in many different materials, the most common being synthetic fibers (nylon, polyester, polyglactin, and polyglycolic acid), collagen, gut, and silk (Figure 12-46). Sutures are classified by absorbency (absorbable or nonabsorbable), by size according to the manufacturer's minimum diameter, and by physical design as monofilament, multifilament, twisted, or braided. The classification of suture size is complicated by the existence of two standards, the United States Pharmacopeia (USP) and the European Pharmacopeia (EP). The USP size is designated by two Arabic numbers, one a 0, separated by a hyphen (3-0, 4-0, 5-0, etc). **The higher the first number, the smaller the diameter** of the suture material. The EP system is a number that represents the manufacturer's minimum diameter tolerance of the suture in millimeters (1 = 0.10 mm, 1.5 = 0.15 mm, etc).

Silk. Silk sutures are made of protein fibers (fibroin) bound together with a biologic glue (sericin), similar to fibronectin, produced by silkworms. Silk sutures are nonabsorbable, multifilamentous, and braided. They have a high capillary action effect that enhances the movement of fluids between the fibers ("wicking" action), resulting in severe oral tissue reactions.²¹⁹⁻²²¹ This tissue reaction results from the accumulation of plaque on the fibers that occurs within a few hours following insertion into the tissues.²²² Silk's advantage is limited to its ease of manipulation. Because of the severe tissue reaction to silk, it is not the suture material of choice for endodontic surgery today.² If silk sutures are used, however, the patient should rinse postoperatively with chlorhexidine.

Gut. Collagen is the basic component of plain gut suture material and is derived from sheep or bovine intestines. The collagen is treated with diluted

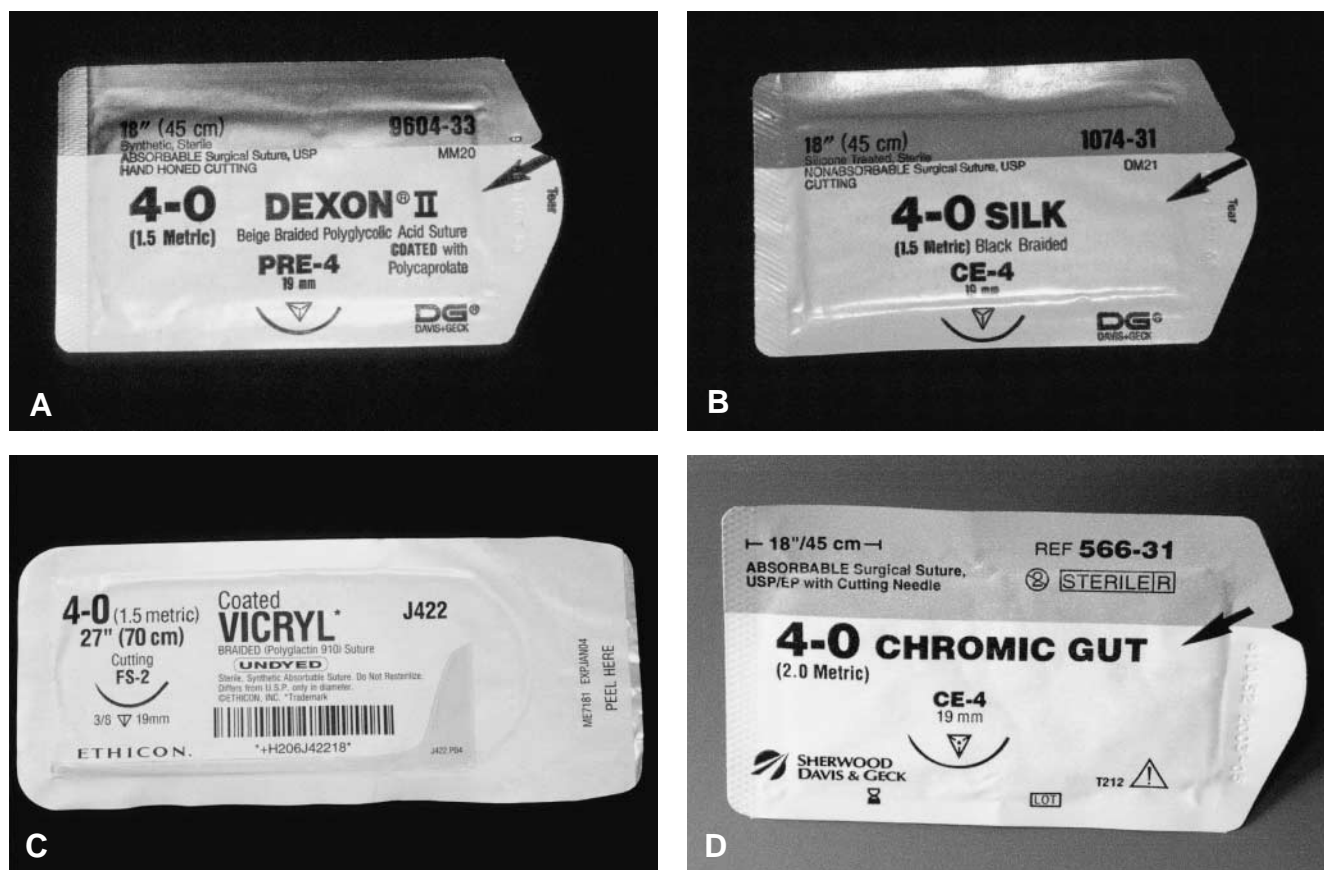

Figure 12-46 Various suture materials. A, Dexon II (braided absorbable polyglycolic acid) suture. B, Silk (braided nonabsorbable) suture. C, Vicryl (braided absorbable polyglactin 910) suture. D, API (absorbable chromic gut) suture.

formaldehyde to increase its strength and is then shaped into the appropriate monofilament size. Gut sutures are absorbable; however, the absorption rate is variable and can take up to 10 days. Because of the unpredictability of gut suture absorption in oral tissues, a scheduled suture removal appointment should be made.

Chromic gut sutures consist of plain gut that has been treated with chromium trioxide. This results in a delay in the absorption rate. Because retention of sutures beyond a few days is not recommended in endodontic surgery, the use of chromic gut sutures offers no advantage. Also, evidence indicates that plain gut is more biocompatible with oral soft tissues than is chromic gut.^{2,219–221}

Gut suture material is marketed in sterile packets containing isopropyl alcohol. When removed from the packet, the suture is hard and nonpliable because of its dehydration. Before using, gut sutures should be hydrated by placing them into sterile, distilled water for 3 to 5 minutes. After hydration, the gut suture material will be smooth and pliable with manipulative properties similar to silk.²²³

Collagen. Reconstituted collagen sutures are made from bovine tendon after it has been treated with cyanoacetic acid and then coagulated with acetone and dried. Collagen sutures offer no advantage over gut for endodontic surgery since their absorption rate and tissue response are similar. They are available only in small sizes and used almost exclusively in microsurgery.

Polyglycolic Acid (PGA). Suture material made from fibers of polymerized glycolic acid is absorbable in mammalian tissue. The rate of absorption is about 16 to 20 days. Polyglycolic acid sutures consist of multiple filaments that are braided and share handling characteristics similar to silk. Polyglycolic acid was the first synthetic absorbable suture and it is manufactured as Dexon.

Polyglactin (PG). In 1975, Craig and coworkers reported the development of a copolymer of lactic acid and glycolic acid called polyglactin 910 (90 parts glycolic acid and 10 parts lactic acid).²²⁴ Sutures of polyglactin are absorbable and consist of braided multiple filaments. Their absorption rate is similar to that of polyglycolic acid. They are commercially available as Vicryl.

Many studies have been reported evaluating the response of the oral soft tissues to gut, collagen,

polyglycolic acid, and polyglactin sutures, with conflicting results. As a result, there is insufficient evidence, at this time, to make a strong recommendation among these materials. The important factor to remember about sutures, regardless of what material is used, is that they should be removed as early as the clinical situation will permit.

Needle Selection. Surgical needles are designed to carry the suture material through the tissues with minimal trauma. For that reason, a needle with a reverse cutting edge (the cutting edge is on the outside of the curve) is preferable. The arc of the surgical needle selected should match the optimum curvature needed to penetrate the tissues in and out on both sides of the incision, 2 to 3 mm from the wound margins. Suture needles are available in arcs of one-fourth, three-eighths, one-half, and five-eighths of a circle, with the most useful being the three-eighths and one-half circle. The radius of the arch of the needle is also an important consideration. The smaller the radius of the arch, the more conducive the needle is to quick turnout. For vertical incision lines and anterior embrasure suturing, a relatively tight arc is necessary to allow for quick needle turnout. Suturing in posterior areas, however, requires less curvature and a longer needle to reach through the embrasure (Figure 12-47). The final selection of an appropriate surgical needle is based on a combination of factors, including the location of the incision, the size and shape of the interdental embrasure, the flap design, and the suture technique planned.

Suture Techniques. There is a wide variety of suture techniques designed to accomplish the goals of closure and stabilization of flaps involving oral mucoperiosteal tissues. All suturing techniques should be evaluated on the basis of their ability to accomplish these goals.² Several authors have compared the effects of continuous and interrupted suture techniques. Their findings indicate that the **interrupted suturing** technique provides for **better flap adaptation** than does the continuous technique and, therefore, is the recommended technique, and the most commonly used, for endodontic surgery.^{225,226} Sutures are holding mechanisms and should not pull or stretch the tissue as a tear in the flap margin may result. Sutures that close an incision too tightly compromise circulation and increase chances for the sutures to tear loose on swelling. Before placing sutures, bleeding should be controlled to prevent the formation of a hematoma under the flap. This will prevent the direct apposition of the flap to the bone and can act as a culture medium for bacterial growth. The suturing techniques that are most conducive to rapid surgical wound healing are the

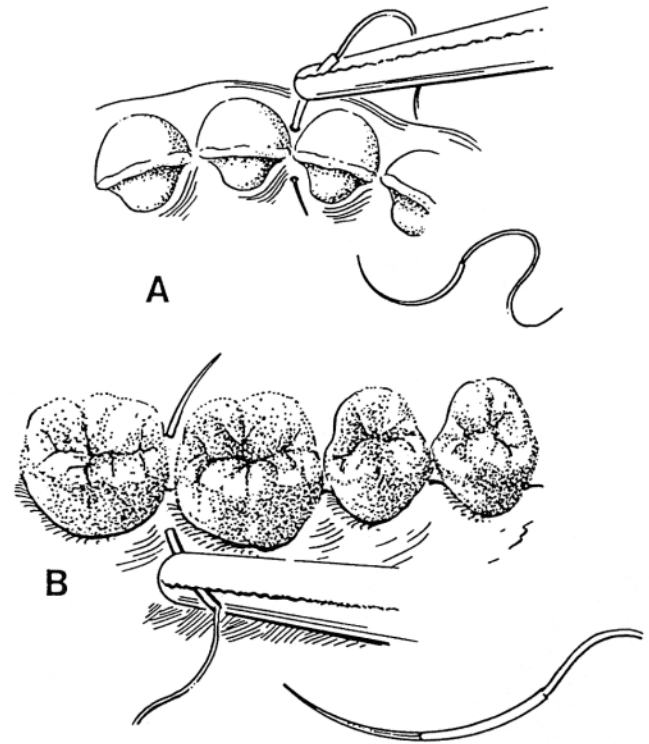


Figure 12-47 A, More tightly curved needle such as a half-circle is best for suturing incision lines and anterior embrasures. B, Straighter and longer curved needle is necessary for suturing in areas such as posterior embrasures.

single interrupted suture, the interrupted loop (interdental) suture, the vertical mattress suture, and the single sling suture.

Single Interrupted Suture. The single interrupted suture is used primarily for closure and stabilization of vertical releasing and relaxing incisions in full mucoperiosteal flaps and horizontal incisions in limited mucoperiosteal flap designs (Figure 12-48). The initial needle penetration should be through the independent (movable) tissue. The point of needle entry should be from the buccal or facial side and 2 to 3 mm from the incision margin to provide sufficient tissue to minimize suture tear-out. The needle should then enter the **under surface** of the mucoperiosteum of the dependent (immovable) tissue and penetrate through the mucoperiosteum at a point 2 to 3 mm from the incision margin. To accomplish this, it is often necessary to **elevate** the attached mucoperiosteum from the underlying bone for a distance of a few millimeters at the point of needle insertion. It is important that the periosteum is included with the tissue bite—otherwise the suture will most likely tear out of the fragile attached gingiva.

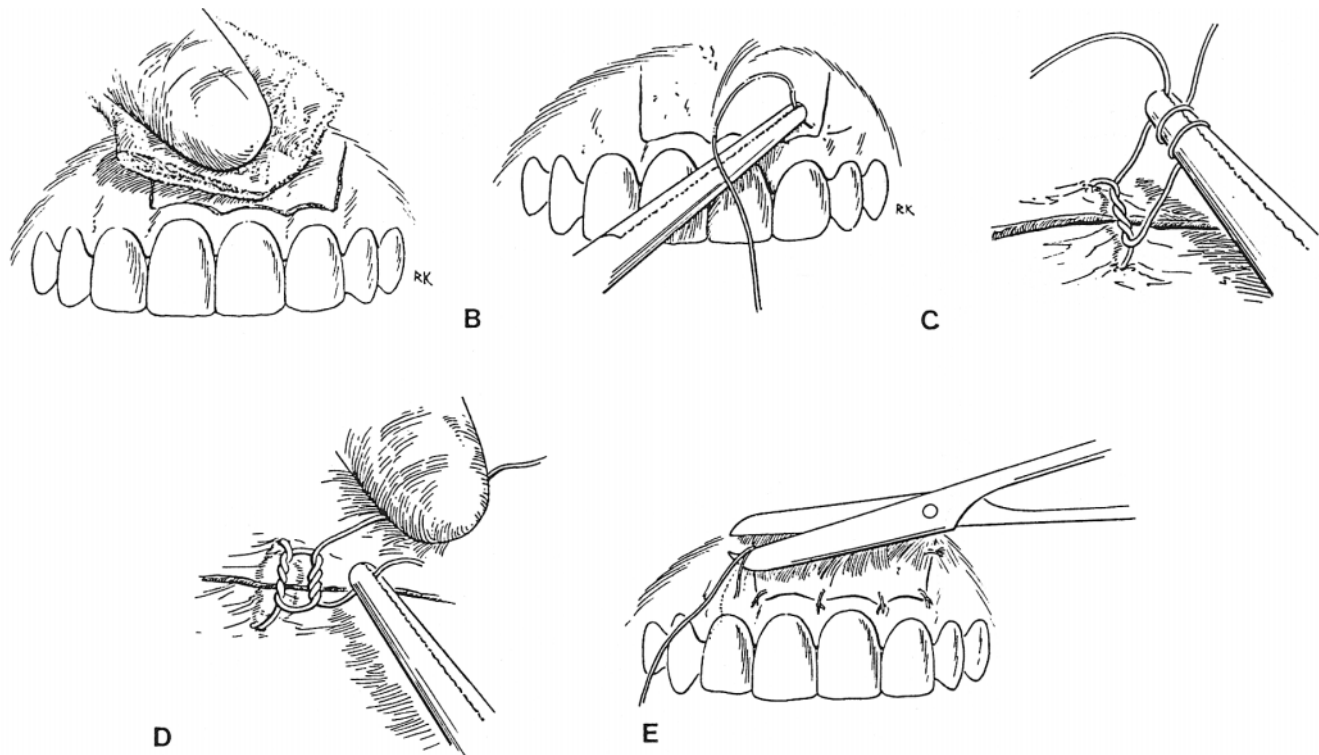


Figure 12-48 Suturing technique. A, Damp 2-inch \times 2-inch gauze is used to smooth tissue flap into place. B, Most unattached portion of the flap is sutured to attached tissue. Two- to three-millimeter margin should be present between puncture points and incision lines. C, Wound edges are approximated with the first tie. D, Surgeon's knot is used to tie suture in place. E, Interrupted sutures are used to secure remainder of flap.

After the suture needle has been passed through the mucoperiosteum on both sides of the incision, the suture material should be drawn through the tissue until the end opposite the needle is approximately 1 to 2 inches from the tissue. The suture should be tied with a secure knot. A surgical knot is the most effective and least likely to slip. The surgeon's knot is best tied by wrapping double loops or throws of the long end (the end with the needle attached) of the suture around the needle holder. By then grasping the short end of the suture with the needle holder and slipping the throws off, the first half of the surgical knot is tied. After adjusting the tissue tension, the second half of the knot is tied by repeating the same process, except wrapping the loops of suture around the needle holder in the **opposite direction** from the first tie, like a square knot. Suture knots should be placed to the side of the incision. Suture knots collect food, plaque, and bacteria, thus resulting in localized infection and a delay in healing when placed directly over the incision (Figure 12-48, C and D).

Interrupted Loop (Interdental) Suture. The interrupted loop, or interdental suture, is used primarily to

secure and stabilize the horizontal component of full mucoperiosteal flaps. The surgical needle is inserted through the buccal or facial interdental papillae, then through the lingual interdental papillae, and then back through the interdental embrasure. It is tied on the buccal or facial surface of the attached gingiva (Figure 12-49, A). This suture technique highly predisposes the fragile interdental tissue and col to inflammation and retarded healing, resulting in a loss of the outer gingival epithelium, with possible blunting or formation of a double papillae.

A modification of this interrupted loop suture is described as follows. After the surgical needle has been passed through the buccal and lingual papillary gingiva, the suture is passed over the interdental contact and secured with a surgeon's knot. This modification eliminates the presence of suture material in the interdental embrasure, thus reducing postsurgical inflammation to this delicate tissue. In clinical situations in which the horizontal component of a full mucoperiosteal flap involves a tooth or teeth with full-coverage crowns, this modification allows for a slight incisal or occlusal repositioning of the mucoperiosteal flap. This can be

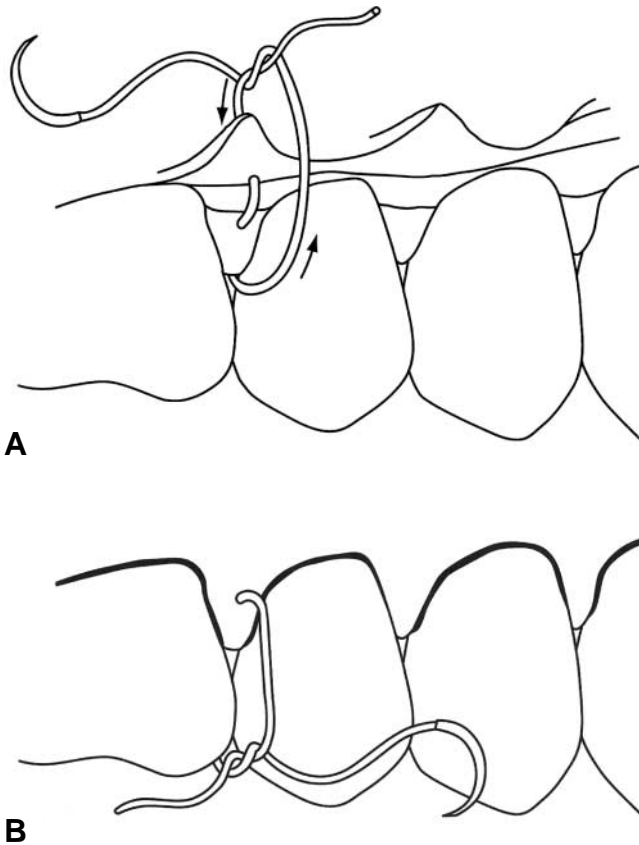


Figure 12-49 A, Interrupted loop suture. Suture is passed gingival to the interproximal contact. B, Modified interrupted loop suture. Suture is passed incisal to the interproximal contact.

accomplished by placing slight tension on the suture over the interdental contact and may compensate for a loss of gingival height resulting from the sulcular incision (Figure 12-49, B).

Vertical Mattress Suture. The vertical mattress suture has the advantage of not requiring needle penetration or suture material being passed through tissue involved in the incisional wound. The surgical needle enters and exits the flapped mucoperiosteum some distance apical from the incision line. The suture is then passed through the **interdental embrasure**, directed to the lingual gingiva of the adjacent tooth and passed back through the opposite interdental embrasure. The needle then enters and exits the flapped mucoperiosteum again, is passed through the embrasure, and, again, lingual to the tooth and through the opposite interdental embrasure to be tied on the buccal surface with a surgeon's knot (Figure 12-50). This suture technique also provides for the opportunity to return the flapped tissue to a slightly incisal or occlusal position from its original to compensate for a loss of gingival height.

Single Sling Suture. The single sling suture is similar to the vertical mattress suture. The surgical needle is passed through the attached gingiva of the flap, through the interdental embrasure, but not through the lingual soft tissue. It is then directed lingual to the tooth and passed through the opposite interdental embrasure and over the incisal or occlusal margin of the flap. The needle is then passed through the attached gingiva of the flap, from the buccal or facial side, back through the embrasure, passed lingual to the tooth, through the opposite embrasure, passed over the flap margin, and tied with a surgeon's knot (Figure 12-51). This suture technique is particularly effective for achieving the maximum incisal or occlusal level when repositioning the flap. Because the lingual anchor is the lingual surface of the tooth and not of the fragile lingual tissue, tension can be placed on the flapped tissue to adjust the height of the flap margin.

Postsurgical Care

Postsurgical management of the patient is equally as important as the surgical procedure itself. An important component of postsurgical care is a genuine expression of concern and reassurance to the patient regarding both their physical and emotional experience. It is well known that the emotional state of a patient has a direct relationship on the level of morbidity following a surgical procedure. The patient's **awareness that the surgeon cares and is readily available**, should the patient have a problem, is a priceless adjunct to healing. A telephone call to the patient, the evening following or the morning after endodontic surgery, is very reassuring and helps to build a strong doctor-patient relationship. This also allows any patient anxieties to be dealt with before they become major concerns.

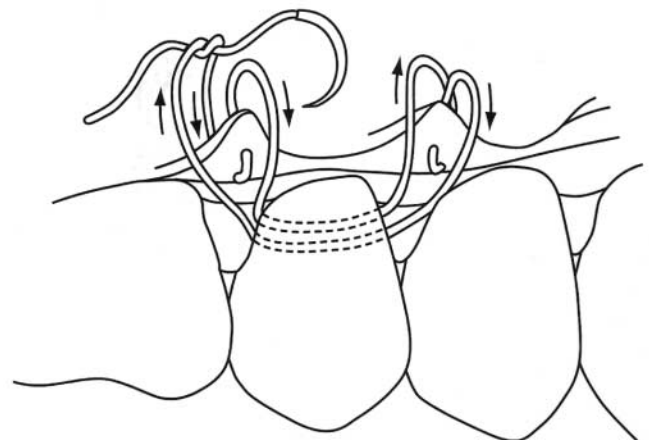


Figure 12-50 Vertical mattress suture.

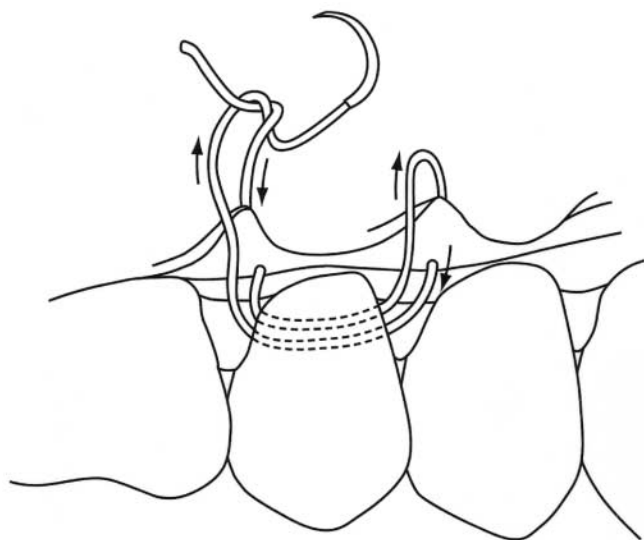


Figure 12-51 Single sling suture.

Another important component of postsurgical care is good patient communication. It is the endodontic surgeon's responsibility to properly communicate to the patient the expected and normal postsurgical sequelae as well as detailed home care instructions. These instructions are best conveyed both verbally and in writing. Alexander stated that without written reinforcement, the understanding and retention of verbal instructions cannot be ensured. He also advised that written materials should be presented after oral instructions have been given rather than the other way around. Since up to 20% of Americans are functionally illiterate, written instructions should use simple words (preferably 1 to 2 syllables) and short sentences of no more than 10 words.²²⁷ Normal postsurgical sequelae include the possibility of slight bleeding from the surgical area for a few hours, pain that may persist for a few days, and swelling and soft-tissue discoloration (ecchymosis) in the surgical area that may be evident for as many as 8 to 10 days. An example of written postsurgical instructions, which should be reviewed verbally with the patient before he is dismissed, is provided in Table 12-4.

Bleeding, swelling, discoloration, pain, and infection are the most likely untoward sequelae following endodontic surgery. These should be thoroughly discussed with the patient during the presurgical consultation and should be reinforced at the time of surgery, before dismissal of the patient.

Bleeding and Swelling. Slight oozing of blood from severed microvessels may be evident for several

Table 12-4 Instructions for Postoperative Care Following Endodontic Surgery. (May Be Copied)

1. Do not do any difficult activity for the rest of the day. Easy activity is okay, but be careful and do not bump your face where the surgery was done. You should not drink any alcohol or use any tobacco (smoke or chew) for the next 3 days.
2. It is important that you have a good diet and drink lots of liquids for the first few days after surgery. Juices, soups, and other soft foods such as yogurt and puddings are suggested. Liquid meals, such as Segoe, Slender, and Carnation Instant Breakfast, can be used. You can buy these at most food stores.
3. Do not lift up your lip or pull back your cheek to look at where the surgery was done. This may pull the stitches loose and cause bleeding.
4. A little bleeding from where the surgery was done is normal. This should only last for a few hours. You may also have a little swelling and bruising of your face. This should only last for a few days.
5. You may place an ice bag (cold) on your face where the surgery was done. You should leave it on for 20 minutes and take it off for 20 minutes. You can do this for 6 to 8 hours. **After 8 hours, the ice bag (cold) should not be used.** The next day after surgery, you can put a soft, wet, hot towel on your face where the surgery was done. Do this as often as you can for the next 2 to 3 days.
6. Discomfort after the surgery should not be bad, but the area will be sore. You should use the pain medicine you were given, or recommended to you, as needed.
7. Rinse your mouth with 1 tablespoon of the chlorhexidine mouthwash (Peridex) you were given or prescribed. This should be done two times a day (once in the morning and once at night before going to bed). You should do this for 5 days.
8. The stitches that were placed need to be taken out in a few days. You will be told when to return. **It is important that you come in to have this done!!**
9. You will be coming back to the office several times during the next few months so that we can evaluate how you are healing. These are very important visits and you should come in even if everything feels okay.
10. If you have any problems or if you have any questions, you should call the office. The office phone number is xxx-xxxx. If you call after regular office hours or on the weekend, you will be given instructions on how to page the doctor on call.

hours following surgery. When a little blood is mixed with saliva, it often appears to the patient as a lot of blood. If the patient is forewarned of this possibility, it goes a long way to reducing their anxiety. Slight swelling of the intraoral and extraoral tissues is a nor-

mal consequence of surgical trauma and leakage of blood from the severed microvessels. Proper compression of the surgical flap, both before and after suturing, greatly reduces postoperative bleeding and swelling.

Additional supportive therapy is the application of an ice pack, with firm pressure, to the facial area over the surgical site. Pressure and reduction of temperature slow the flow of blood and help to counteract the rebound phenomenon, which occurs following the use of a vasoconstrictor in the local anesthetic. Application of cold also acts as an effective analgesic as a result of its reduction in sensitivity of the peripheral nerve endings. The ice pack should be applied in a 20 minutes on and 20 minutes off cycle. This regimen should be repeated for 6 to 8 hours and should preferably be started in the surgeon's office with the use of a disposable instant chemical cold pack (Figure 12-52). Continuous application of cold should be avoided. This will initiate a physiologic mechanism that will result in an increase in blood flow to the site of cold application.²²⁸

If minor bleeding should persist for more than 12 hours following surgery, it can usually be managed by the patient with proper home care. At the time of surgery, the patient should be given several 2-inch \times 2-inch gauze pads in a sterile pack (Figure 12-53). The patient should be instructed to slightly moisten one of the sterile gauze pads and to place it over the bleeding site while applying firm pressure. Pressure should be applied to the area for 10 to 15 minutes. Should the bleeding problem persist, the patient should be instructed to place a moist tea bag, or one of the gauze pads soaked in tea, over the bleeding area and to apply pressure in the same manner as before. Tannic acid, contained in tea, is known to be an effective hemostatic agent. If home treatment fails, the patient should be seen in the dental office, where the



Figure 12-52 Col-Press (instant chemical cold pack), Hospital Marketing Service Co. Inc.




Figure 12-53 Several 2-inch \times 2-inch sterile gauze pads sealed in plastic.

dentist can inject a local anesthetic agent containing 1:50,000 epinephrine and apply tissue compression to the bleeding area. Unless there is an undisclosed or undiagnosed bleeding disorder, this should resolve the problem.² The patient should be warned **not to take aspirin** for pain before surgery or afterward, but rather to take acetaminophen or ibuprofen.

Application of moist heat over the surgical site is recommended; **however, it should not begin until 24 hours following the surgery.** Heat promotes blood flow and enhances the inflammatory and healing processes. The application of moist heat is best accomplished by the use of a small cotton towel that has been moistened with hot tap water. The hot, moist towel should be applied to the surface of the face over the surgical area for about 30 minutes. The towel should be reheated with hot tap water every 5 to 10 minutes to maintain the temperature.

Discoloration. Discoloration of the mucoperiosteal and/or facial tissues following surgery is the result of the breakdown of blood that has leaked into the surrounding tissues. Again, patients should be made aware of the potential for postsurgical discoloration at the presurgical consultation visit and the information should be reinforced at the time of surgery (Figure 12-54). This ecchymosis can last for up to 2 weeks and is observed more in the elderly and in fair-complexioned patients. This is an esthetic problem only and requires no special treatment. In patients with ecchymosis, applications of moist heat may be beneficial for up to 2 weeks following surgery. Heat promotes fluid exchange and speeds resorption of discoloring agents from the tissues.²

Pain. In the majority of patients, pain following periradicular surgery is surprisingly minimal. Postsurgical pain is usually of short duration and most

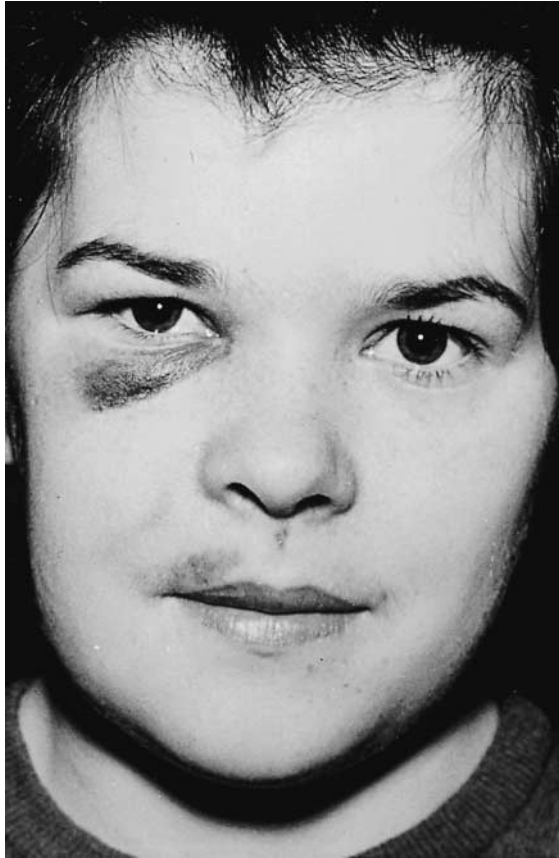

Figure 12-54 “Black eye” ecchymosis following periradicular surgery. Also note discoloration of upper lip.

often reaches its maximum intensity about 6 to 8 hours following surgery. A significant reduction in pain can usually be expected on the first postoperative day followed by a steady decrease in discomfort each day following surgery. It is unusual for a patient to experience pain that cannot be managed by mild to moderate analgesics.²²⁹

Another method of postsurgical pain control is the use of long-acting local anesthetic agents, such as bupivacaine (Marcaine) or etidocaine (Duranest), which provide 6 to 8 hours of local anesthesia and up to 10 hours of local analgesia.^{230,231} Since these long-acting anesthetic agents contain a low concentration of vasoconstrictor (1:200,000), they are not suitable to be used alone in periradicular surgery. They can either be used before surgery, in conjunction with lidocaine 1:50,000 epinephrine, or at the conclusion of the surgical procedure before dismissal of the patient. The return of sensation is more gradual with the long-acting anesthetics than with the short-acting anesthetics; therefore, the onset of discomfort is less sudden.

Infection. Although endodontic surgery is performed in an area that is heavily populated with bacteria, postsurgical infections are rare. For this reason, peritreatment systemic antibiotic therapy is seldom required and is not considered part of routine postsurgical care in healthy patients. The most common causes of postsurgical infections following periradicular surgery are the result of inadequate aseptic techniques and improper soft-tissue reapproximation and stabilization. These factors are under the direct control of the endodontic surgeon.²

The clinical signs and symptoms of a postsurgical infection are usually evident 36 to 48 hours after surgery. The most common indications are progressively increasing pain and swelling. Suppuration, elevated temperature, and lymphadenopathy may or may not be present. Systemic antibiotic therapy should be initiated promptly, when indicated. The antibiotic of choice is penicillin V and the recommended dosage is 1.0 g as an initial dose, followed by a maintenance dose of 500 mg. The dosing interval should be every 3 to 4 hours, preferably without food. In patients allergic to penicillin, the antibiotic of choice is clindamycin with an initial dose of 600 mg, followed by a maintenance dose of 150 to 300 mg, depending on the age and weight of the patient. The dosing interval should be every 8 hours, preferably without food. The patient should be monitored every 24 hours and antibiotic therapy withdrawn as soon as the clinical condition indicates that the patient's host defenses have regained control of the infection and that the infection is resolving or has resolved. (For additional information see Chapter 18, “Pharmacology for Endodontics.”)

Oral Hygiene. Oral hygiene often presents a postsurgical problem for many patients. A toothbrush should not be used as an aid to oral hygiene in the area of surgery until the day following surgery, and then only on the occlusal or incisal surfaces of the teeth. Use of a toothbrush in the surgical area may dislodge the mucoperiosteal flap and lead to serious postsurgical complications. A cotton swab soaked with chlorhexidine oral rinse (Peridex) or 3% hydrogen peroxide may be used to gently remove oral debris from the surgical area. A regimen of twice daily (morning and evening) rinsing with chlorhexidine oral rinse will provide an effective means for reduction of debris, decreasing the population of the oral microbial flora and inhibiting plaque formation. Chlorhexidine oral rinses should continue for 4 to 6 days following surgery (2 to 3 days following suture removal).

Suture Removal. According to Gutmann and Harrison, the key to preventing sutures from having a negative effect on wound healing following surgery is

their early removal.² The primary purpose for placing sutures following endodontic surgery is to approximate the edges of the incisional wound and to provide stabilization until the epithelium and myofibroblast-fibronectin network provides a sufficient barrier to dislodgment of the flapped tissues. This usually occurs within 48 hours following surgery. It has been recommended that sutures should not be allowed to remain longer than 96 hours.

A suture removal kit should contain a cotton swab, 2-inch × 2-inch gauze sponges, suture scissors, cotton pliers, and a mouth mirror (Figure 12-55). The sutures and surrounding mucosa should be cleaned with a cotton swab containing a mild disinfectant followed by hydrogen peroxide. This helps to destroy bacteria and remove plaque and debris that have accumulated on the sutures, thus reducing the inoculation of bacteria into the underlying tissues as the suture is pulled through. A topical anesthetic should also be applied with a swab at the surgical site. This greatly reduces the

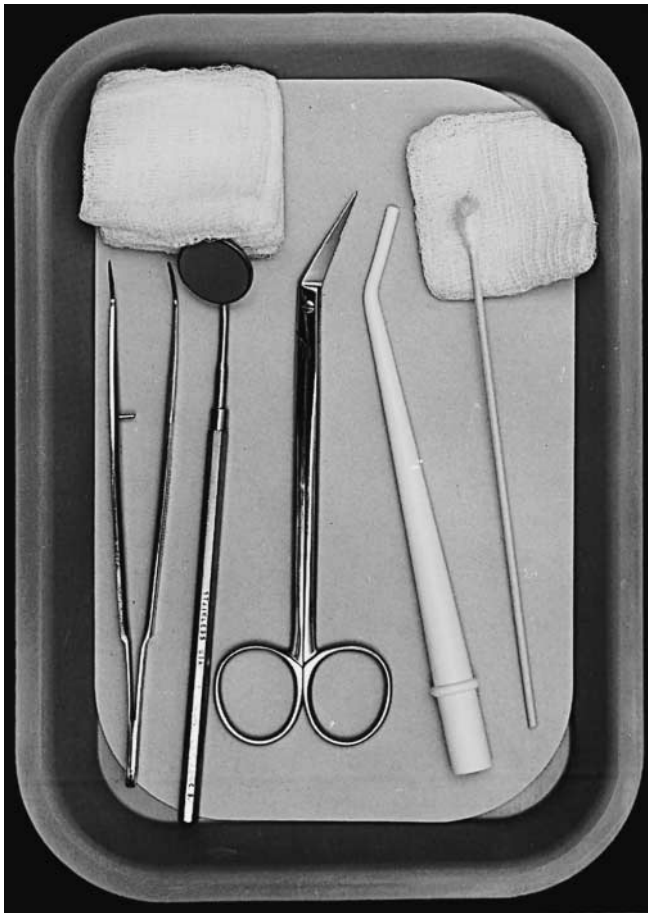

Figure 12-55 Suture removal kit should be presterilized and packaged, and it should contain all necessary instruments and auxiliary supplies needed for the procedure.

discomfort associated with the placement of the scissors blade under the suture, a procedure that is particularly painful in areas of persistent swelling and edema, commonly seen in the mucobuccal fold.

Sharp-pointed scissors are used to cut the suture material, followed by grasping the knotted portion with cotton pliers and removing the suture. Various designs of scissors are available and can be selected according to specific access needs in different areas of the mouth. It has been suggested that a No. 12 scalpel blade be used to sever the suture. The advantages are stated to be a predictably sharp cutting edge and less “tug” on the suture.²³²

Corrective Surgery

Corrective surgery is categorized as surgery involving the correction of defects in the body of the root other than the apex. When the coronal and middle thirds of the root are involved, it is imperative to physically observe, diagnose, and repair the defect. A full sulcular mucoperiosteal flap, such as the triangular or rectangular design, must be used to gain adequate visual and surgical access. Corrective surgical procedures may be necessary as a result of procedural accidents, resorption (internal or external), root caries, root fracture, and periodontal disease. Corrective surgery may involve periradicular surgery, root resection (removal of an entire root from a multirrooted tooth leaving the clinical crown intact), hemisection (the separation of a multirrooted tooth and the removal of a root and the associated portion of the clinical crown), or intentional replantation (extraction and replantation of the tooth into its alveolus after the corrective procedure has been done). Reparative defects of the root and associated procedures are classified as follows:

- I. Perforation repair
 - A. Mechanical
 - B. Resorptive/caries
- II. Periodontal repair
 - A. Guided tissue regeneration
 - B. Root resection/hemisection
 - C. Surgical correction of the radicular lingual groove

Perforation Repair. *Mechanical.* Perforations are procedural accidents that can occur during root canal or postspace preparation. High potential areas for perforations are the pulp chamber floor of molars and the distal aspect of the mesial root of mandibular molars and the mesial buccal root of maxillary molars (strip perforations). When a perforation has occurred, the initial

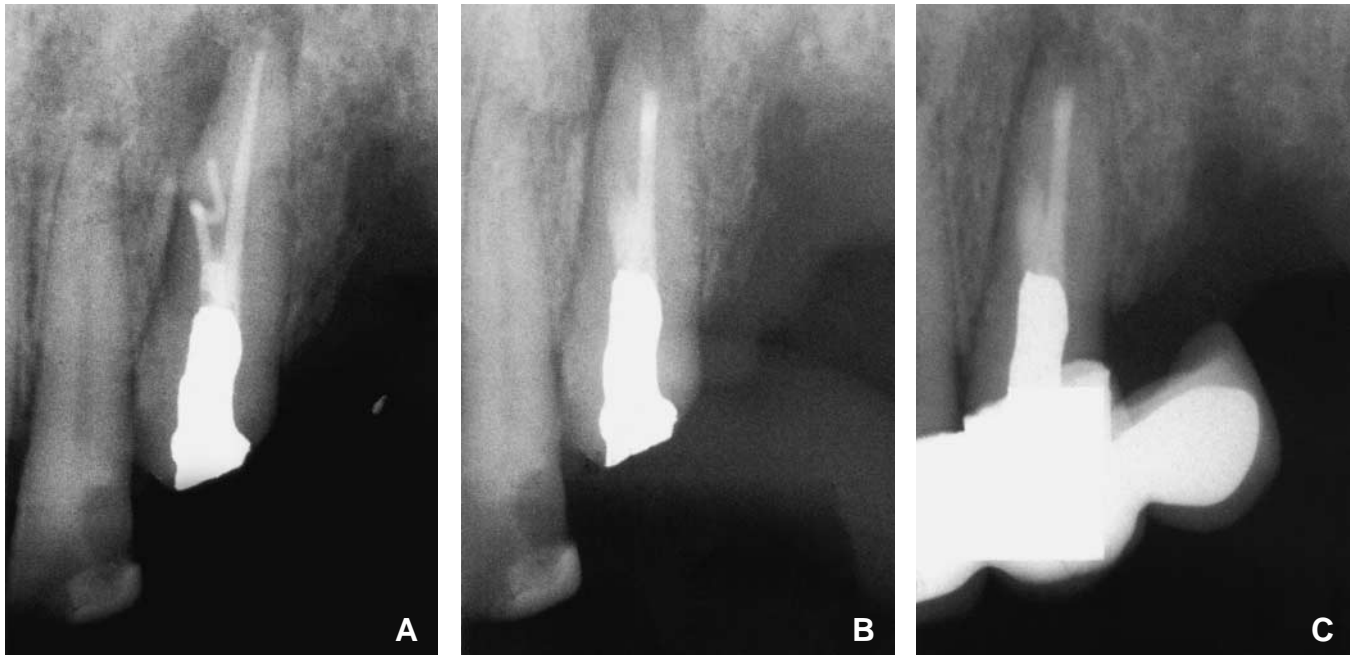


Figure 12-56 A, Lateral midroot perforation with extruded filling material. B, Radiograph following surgical removal of extruded filling material, root-end resection, root-end fill, and repair of perforation defect with mineral trioxide aggregate (MTA). C, Radiograph 2 years following surgery.

attempt at correction should be an internal repair (see chapter 14, “Endodontic Mishaps: Their Detection, Correction, and Prevention”). Corrective surgery should be reserved for those teeth when internal repair is not a treatment option or when internal repair has failed.

“Strip perforations” that occur on the distal aspect of the mesial roots of maxillary and mandibular molars are usually inaccessible and extremely difficult to repair surgically. Visual and surgical access is limited, and bone removal necessary to obtain access to the site of the perforation usually results in a major periodontal defect. This type of clinical situation may be better

managed by intentional replantation, root resection, or hemisection.

Midroot perforations, such as those resulting from postspace preparations, should be immediately sealed internally, if possible, or calcium hydroxide should be placed as an intracanal dressing and sealed at a subsequent appointment. If the perforation is excessively large or long-standing, a full mucoperiosteal flap should be reflected, the perforation site identified, and the repair made with an appropriate repair material (Figure 12-56). If the perforation is located in the apical third of the root, a root-end resection, extending to

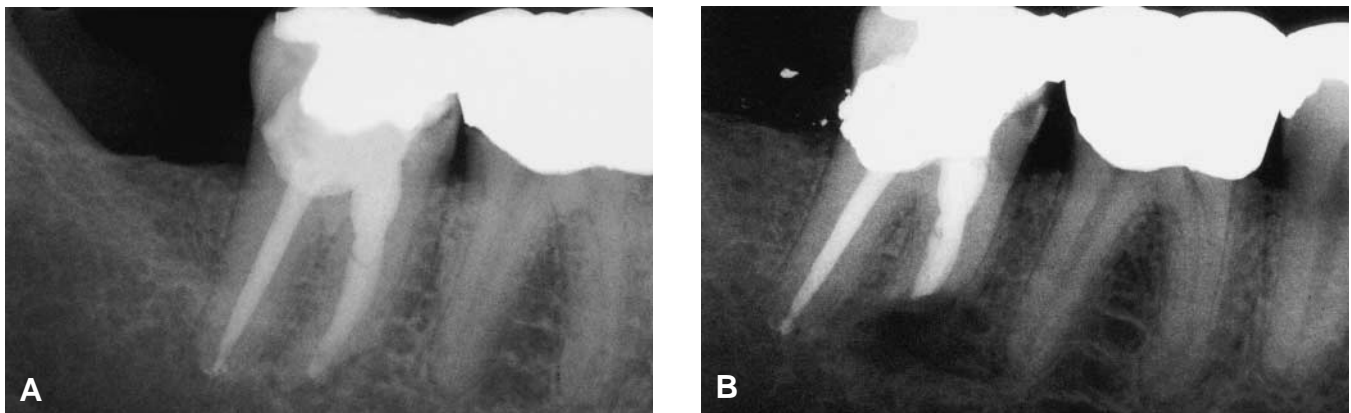


Figure 12-57 A, Lateral perforation of the apical one-third of the mesial root of tooth No. 31. B, Root-end resection of mesial root. Root canal was obturated with mineral trioxide aggregate (MTA).

the point of the perforation, and a root-end filling should be considered as a more effective and efficient way of handling this clinical situation (Figure 12-57).

Resorption (External or Internal) and Root Caries. Repair of a defect on the root surface, from either internal or external resorption, depends to a large extent on whether there is communication between the resorptive defect and the oral cavity and/or the pulp space. When communication between the defect and the oral cavity exists, a corrective surgical procedure is usually necessary. When the resorptive defect has also communicated with the pulp space, excessive and persistent hemorrhage into the pulp space is usually evident during root canal instrumentation. This makes cleaning, shaping, and obturation of the pulp space very difficult, unless surgical repair of the resorptive defect is done first. If the decision is made to repair the root defect before filling the pulp space, after the pulp tissue has been removed, a **temporary, easily removable filling** should be placed in the root canal space. A large gutta-percha point may be used for this purpose; no sealer is used. This will serve as an internal matrix to prevent the repair material from obstructing the root canal. Depending on the setting time of the repair material used, the pulp space may be prepared and obturated at the same appointment. Otherwise, an intracanal dressing of calcium hydroxide should be placed, the access cavity sealed from oral contamination, and the pulp space prepared and obturated at a subsequent appointment (Figure 12-58).

In the case of a resorptive defect that opens into the gingival sulcus, the approach depends to a great extent on the location and the extent of the defect. If it is approachable from the buccal or facial side, a full mucoperiosteal flap should be raised, and the extent of the defect established. If the resorptive defect **has not extended into the pulp space**, it should be restored with a suitable material, such as amalgam, composite resin, or glass ionomer cement. If the **defect has extended into the pulp space**, the flap should be repositioned and stabilized with a suture. A rubber dam should be placed and a conventional coronal access preparation followed by removal of the pulp tissue and placement of a **temporary internal matrix** should be done. Following this, the rubber dam should be removed, the flap elevated, the resorptive defect repaired, and the flap repositioned and stabilized with sutures. The temporary internal canal matrix should be removed and the root canal preparation and obturation completed or a calcium hydroxide intracanal dressing placed and the endodontic treatment completed at a subsequent appointment.

If the resorptive defect opens into the gingival sulcus on the lingual or palatal surface of the tooth, surgical and visual access are much more difficult. A sulcular lingual or palatal flap can be raised to explore the extent of the defect. **Vertical incisions on the lingual side of the mandible should be avoided whenever possible** because of the fragile nature of this tissue. If the resorptive defect is surgically accessible, treatment can proceed as described earlier. If it is not accessible, then intentional replantation or extraction should be considered.

Some cases of resorption or root caries are so extensive that nothing can be done to save the entire tooth. Extraction may be the solution for some cases, or total root amputation or hemisection may apply to others. A case in point calling for hemisection is illustrated in Figure 12-59. Internal-external resorption has destroyed virtually one half of a lower first molar, a terminal tooth in the arch, with opposing occlusion. Probing with a cowhorn explorer and viewing the radiograph reveals the massive lesion and defect (Figure 12-59, A and B). The crown of the tooth is sectioned buccolingually with a high-speed fissure bur (Figure 12-59, C-E). The mesial crown and root are then extracted, and immediate root canal therapy is completed in the remaining distal root (Figure 12-59, F and G). A premolar rubber dam clamp may be used on the remaining "bicuspidized" distal root of the molar. The remaining tooth structure and edentulous space should be restored with a fixed partial denture as soon as possible to prevent mesial drift of the distal root (Figure 12-59, H). This provides for function against the maxillary opponent(s), thereby preventing continual eruption.

Periodontal Repair. Guided Tissue (Bone) Regeneration. In the past, extensive periodontal defects required extraction or root amputation. Today, with techniques of guided bone regeneration and demineralized freeze-dried bone allografts, many teeth that were previously untreatable can be saved. Several authors have published reports on the effectiveness of the use calcium sulfate, alone and as a composite with an allograft material, and resorbable and nonresorbable barrier membranes, with and without allografts, on the quality and quantity of alveolar bone regeneration in endodontic and periodontic defects. Many of these case reports have had mixed results.²³³⁻²³⁸

Few controlled clinical studies comparing the results of the use of guided bone regeneration techniques have been reported. Santamaria and associates reported on a controlled clinical study to determine the degree of bone regeneration following radicular cyst enucleation. Thirty patients were involved in the study. The control group consisted of enucleation of the cyst only and the

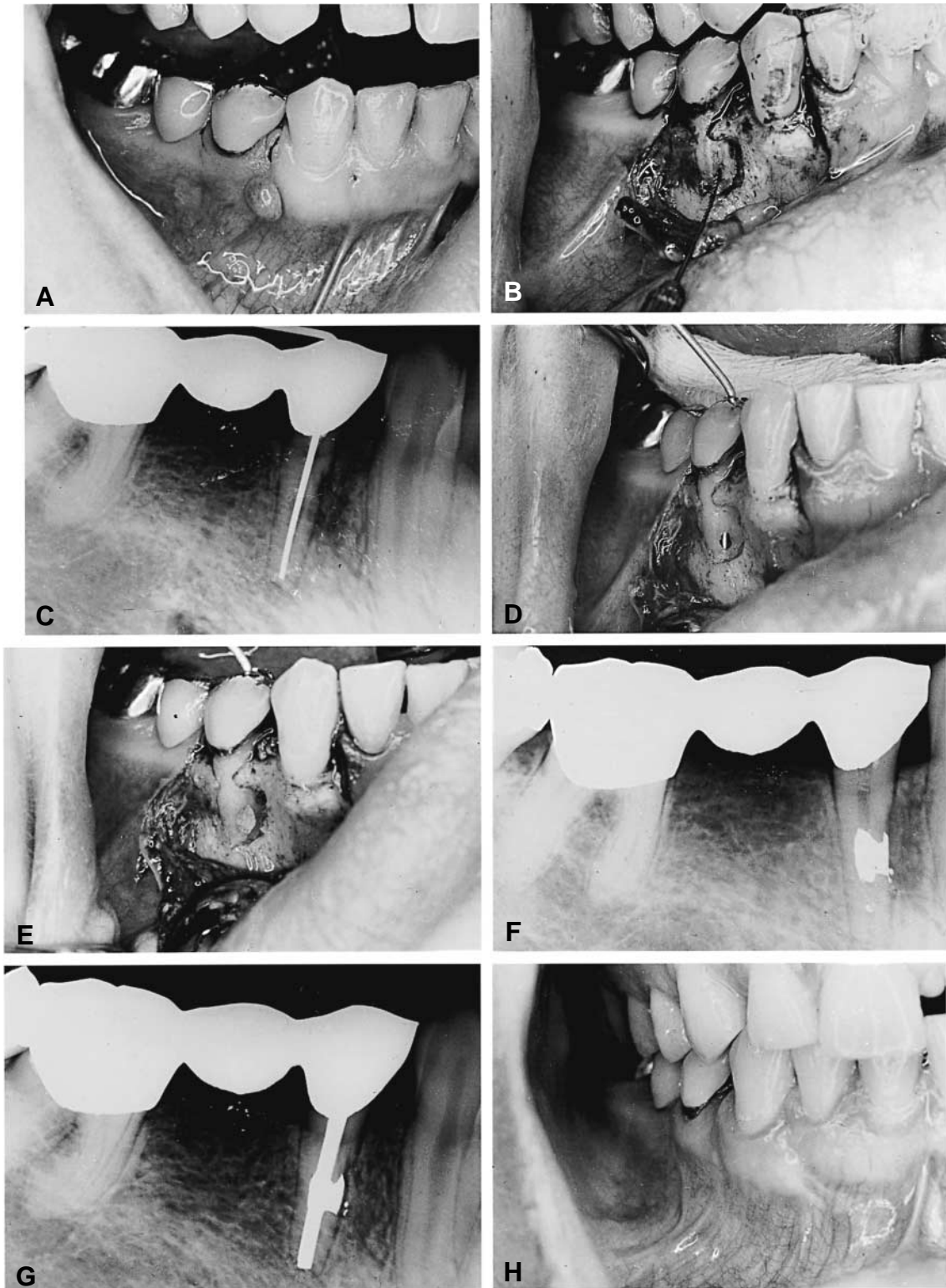


Figure 12-58 Corrective surgical repair of root-resorptive defect. A, Constant drainage mesial to first premolar bridge abutment. Internal and external resorption revealed in radiograph. B, Elevating rectangular flap uncovers huge dehiscence and resorptive defect. Instrument placed into defect proves connection with pulp lesion. C, Conventional occlusal endodontic cavity is prepared and pulpectomy is performed. Internal matrix of endodontic silver point is placed. D, Internal matrix in place and hemorrhage controlled. E, Amalgam filling inserted into external resorptive defect. Non-zinc alloy is used. F, Silver point is immediately removed and flap repositioned and sutured. Because of time constraints in this particular case, canal enlargement and obliteration are completed at subsequent appointment. G, Radiograph 9 months following therapy. Repair of bone is apparent. H, Photograph 9 months following therapy. Note complete repair of draining stoma and incisions. (Courtesy of Dr. David Yankowitz.)

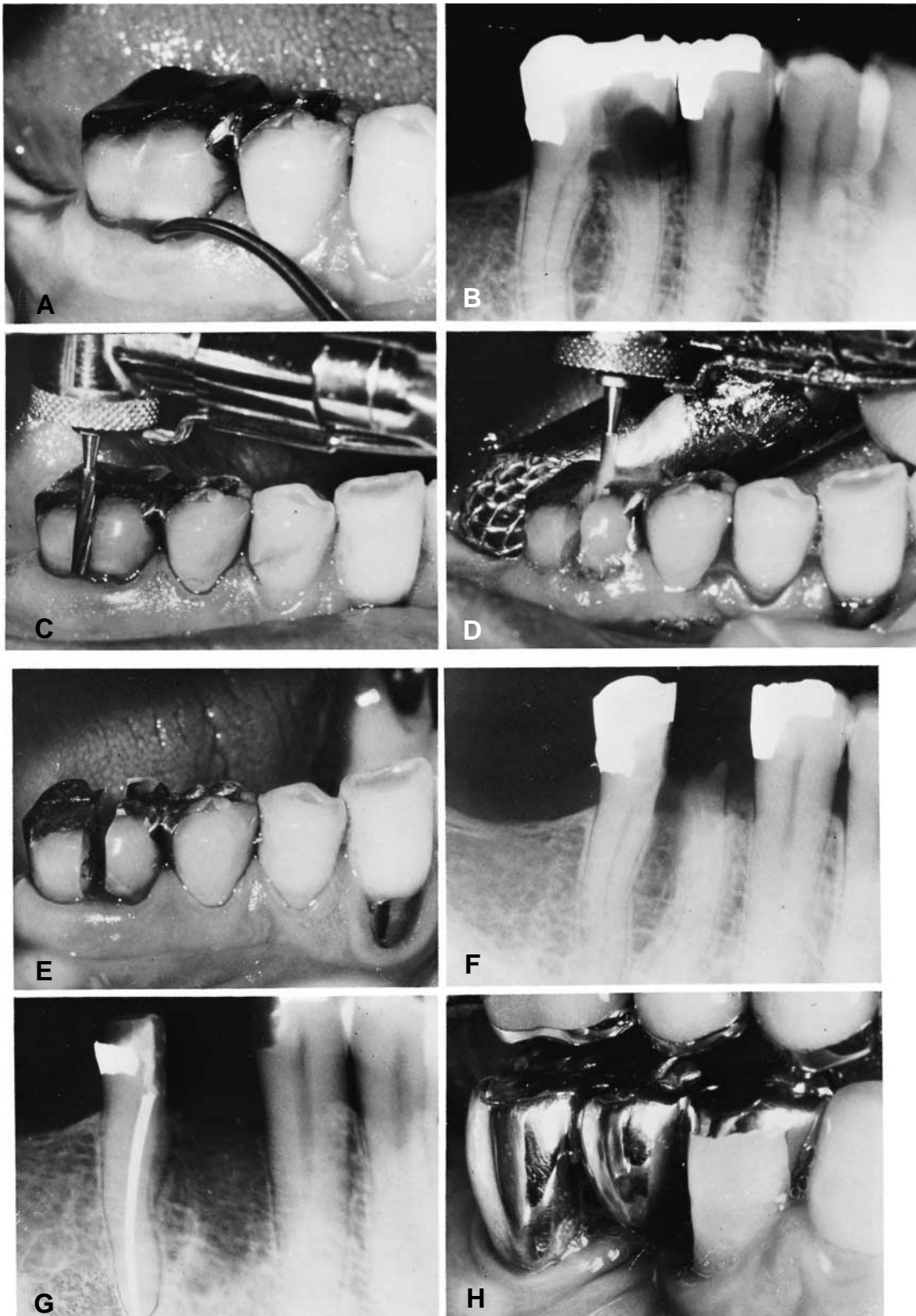


Figure 12-59 Technique for hemisecting and restoring mandibular molar. **A**, Using cowhorn explorer, resorptive lesion and relation to crest of alveolar process are established. **B**, Huge area of internal resorption involving mesial half of molar. **C**, Extra long #559-XL fissure bur has length or reach necessary to cut entirely through crown to furca. **D**, Tooth is sectioned from buccal to lingual with copious water and aspiration. **E**, Sectioning completed. Base of cut must terminate at alveolar crest. **F**, Hemisected mandibular molar. Pathologic mesial half is ready for extraction. Accuracy of sectioning is shown by radiograph. **G**, Care must be exercised not to gouge remaining distal portion. Root canal therapy is completed at same dental appointment. Teeth are ready for immediate restoration. **H**, Importance of restoration for contact with opposite arch is here demonstrated. (Restoration by Dr. Milan V. Starks.)

experimental groups involved enucleation of the cyst plus the use of either a resorbable or nonresorbable membrane. The residual volume and density of the newly formed tissue were measured by computer-assisted tomography and computer-assisted digital image analysis before and after enucleation. No statistically significant difference was noted in the volume or density of the newly formed tissue between the three treatment groups 6 months postsurgically. The results suggested that guided bone regeneration using membranes does not contribute to increased quality or quantity of bone regeneration in this clinical situation.²³⁹

Pecora and associates reported on a controlled clinical study involving 20 patients with large endodontic bony lesions that failed to respond to nonsurgical endodontic treatment. Following curettement of the lesions, 10 sites were covered with Gortex membranes before repositioning the flap, and 10 were left uncovered. The investigators reported that radiographic analysis of the lesions 12 months postsurgically revealed that the quality and quantity of the regenerated bone were superior when the **Gortex membranes** were used.²⁴⁰

Root Amputation. Root amputation procedures are a logical way to eliminate a weak, diseased root to allow the stronger root(s) to survive when, if retained together, they would collectively fail. Selected root removal allows improved access for home care and plaque control with resultant bone formation and reduced pocket depth. The incorporation of one half or two-thirds of a tooth can be instrumental in obviating the need for a long-span fixed partial or a removable partial denture. Quite often, amputation of a hopelessly involved root of an abutment tooth saves an entire fixed prosthesis, even one that is full arch in extent.

As always, case selection is an important factor in success. Proper diagnosis, treatment planning, case presentation, and good restorative procedures are all critical factors equally important to the resective procedure itself. The strategic value of the tooth involved must be convincing.

Evaluation of the involved tooth requires thorough periodontal evaluation of the root or roots to be retained. Remaining structures need continuing periodontal care, and this should be pointed out to the patient. Bony support, the crown–root ratio, occlusal relations, and restorability of the remaining segment all determine the case outcome.

INDICATIONS FOR ROOT AMPUTATION:

1. Existence of periodontal bone loss to the extent that periodontal therapy and patient maintenance do not sufficiently improve the condition.

2. Destruction of a root through resorptive processes, caries, or mechanical perforations.
3. Surgically inoperable roots that are calcified, contain separated instruments, or are grossly curved.
4. The fracture of one root that does not involve the other.
5. Conditions that indicate the surgery will be technically feasible to perform and the prognosis is reasonable.

CONTRAINDICATIONS FOR ROOT AMPUTATIONS:

1. Lack of necessary osseous support for the remaining root or roots.
2. Fused roots or roots in unfavorable proximity to each other.
3. Remaining root or roots endodontically inoperable.
4. Lack of patient motivation to properly perform home-care procedures.

MORPHOLOGIC FACTORS: The length, width, and contour of the roots are important factors in determining where the resective cut is made and the strength of the remaining tooth structure. It is important to be aware of the normal and varied anatomy that may be encountered as these factors will materially affect the procedures of root separation and removal. A careful check of the radiograph and probing of periodontal pockets will help to reveal tooth-to-tooth and root-to-root proximities, as well as morphologic characteristics, such as root size and curvature, furcal location, and fused roots (Figure 12-60).

Two different approaches to resection are available. One approach is to amputate horizontally or obliquely the involved root at the point where it joins the crown, a process termed **root amputation** (Figure 12-61). The other approach is to cut vertically the entire tooth in half—from mesial to distal of the crown in the maxillary molars, and from buccal to lingual of the crown in the mandibular molars—removing in either case the pathologic root and its associated portion of the crown. This procedure is termed **hemisection** (Figure 12-62).

Bisection or “**bicuspidization**” refers to a division of the crown that leaves the two halves and their respective roots. This bisection is designed to form a more favorable position for the remaining segments that leaves them easier to clean and maintain (Figure 12-63). If the remaining roots are too close to each other, minor orthodontic movement may be necessary to properly align them. The careful preparation and restoration of the remaining portions of the tooth to minimize food entrapment and plaque accumulation are critical to the long-term success in this situation.

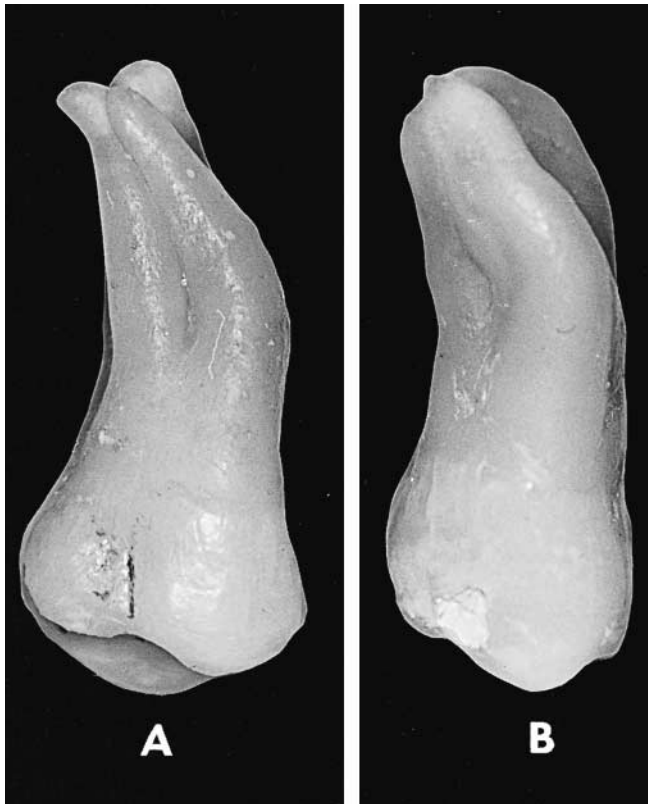

Figure 12-60 A, Roots in close proximity. B, Fused roots are very difficult to resect. Extraction must be considered.

PROCEDURAL SEQUENCE: Following diagnosis and treatment planning, but before resection, endodontic therapy should be done on the roots to be retained. The occlusion should be adjusted to eliminate the trauma of lateral excursions. After the canals of the roots to be retained have been filled, a post (or posts) should be placed when indicated and/or a core should be placed in the pulp chamber and the access cavity. Following the set of the core material, the resection procedure may be done.

AMPUTATION TECHNIQUE FOR MAXILLARY MOLARS: Maxillary molars typically have mesiobuccal roots that are relatively broad buccolingually, narrow mesiodistally, and extend about two-thirds of the distance to the palatal root. Distobuccal roots, however, are much more conical in shape and extend about one half the distance to the palatal root. The length of the palatal root and its considerable thickness impart great stability to this tooth. If occlusal alignment and periodontal factors are favorable, the palatal root can be restored successfully on its own.

The amputation procedure itself is best performed with a surgical-length smooth fissure bur. Length of the cutting portion of the fissure bur is important and especially critical in mesiobuccal roots of maxillary molars

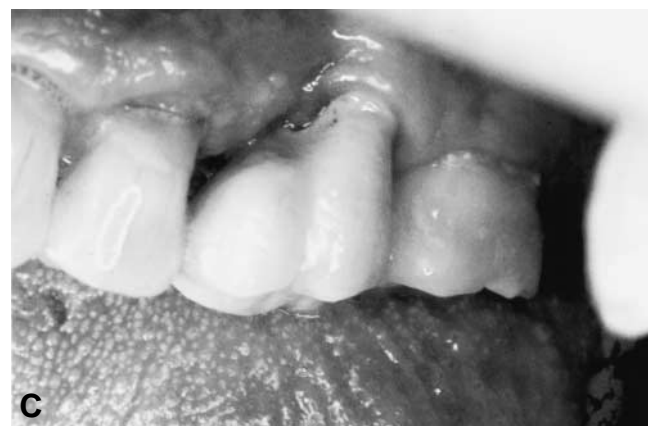
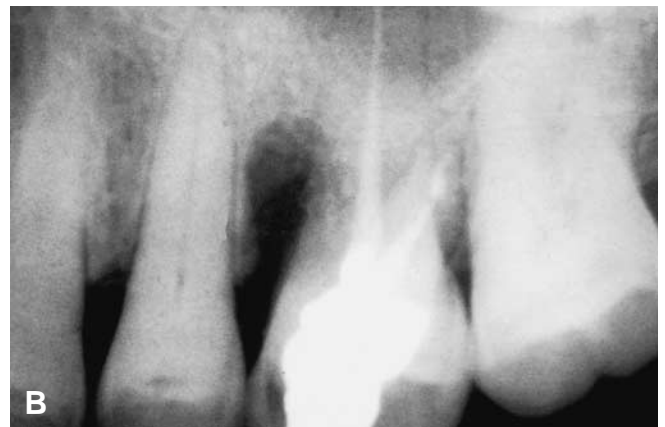
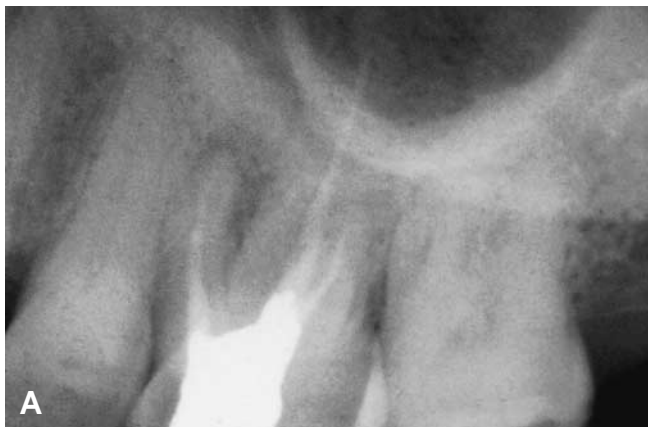Figure 12-61 A, Periradicular lesion consistent with possible vertical root fracture. B, Mesiobuccal root amputation due to vertical root fracture. C, Clinical crown restored with porcelain-fused-to-metal prosthetic crown.

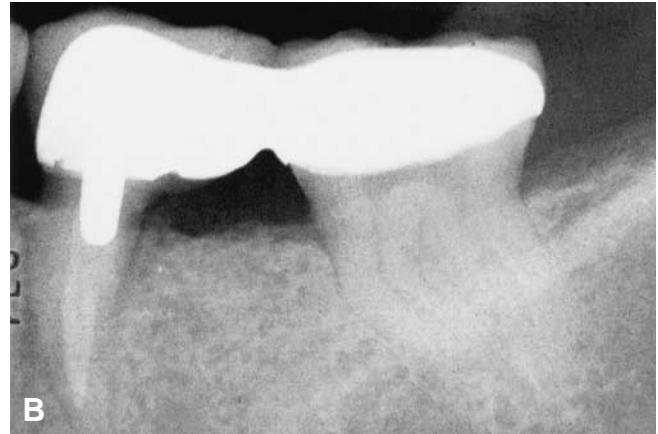
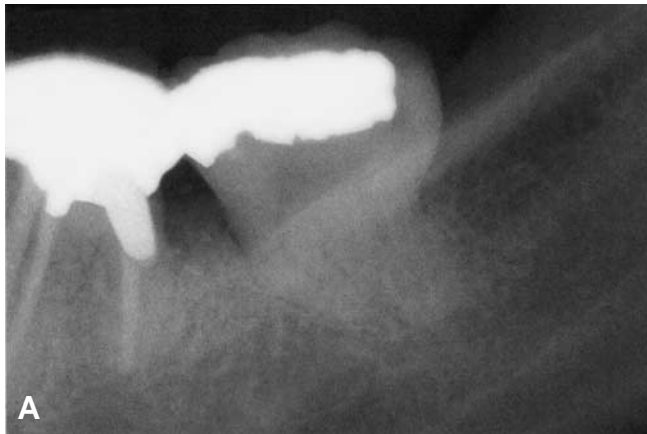
Figure 12-62 A, Postspace perforation on distal aspect of mandibular first molar resulting in a periodontal defect. B, Hemisection and distal root amputation. Note the molars have been splinted together.

and vertical resections through the crown and the furcation. Kirchoff and Gerstein suggested reshaping the crown with a bur so that the crown structure over the root to be removed is resected along with the root. This simplifies the task by making the root-furcation junction more visible for separation and extraction.²⁴¹

To resect a root involving a tooth that is an abutment for a fixed partial denture or has previously been crowned and a new restoration has not been planned, the endodontic surgeon must do the resection horizontally or at an oblique angle. The more vertical the resective cut, the greater the ease of maintaining cleanliness.

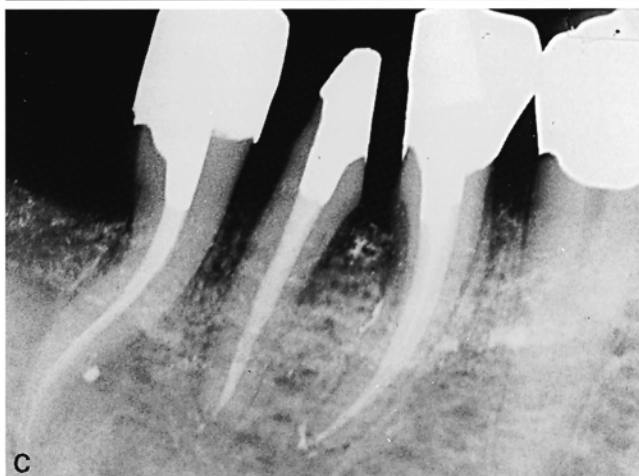
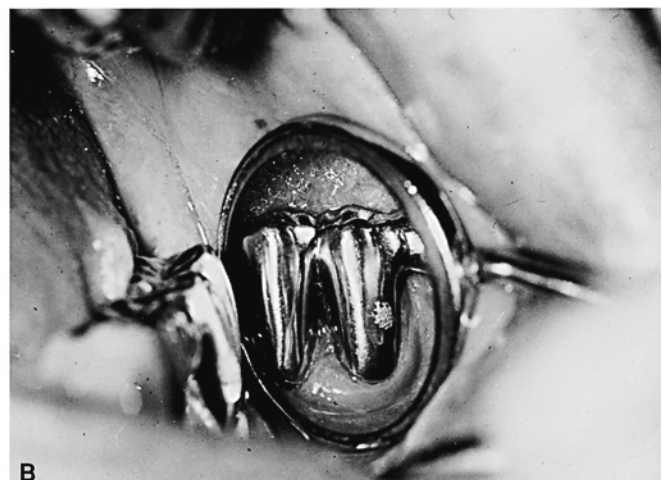
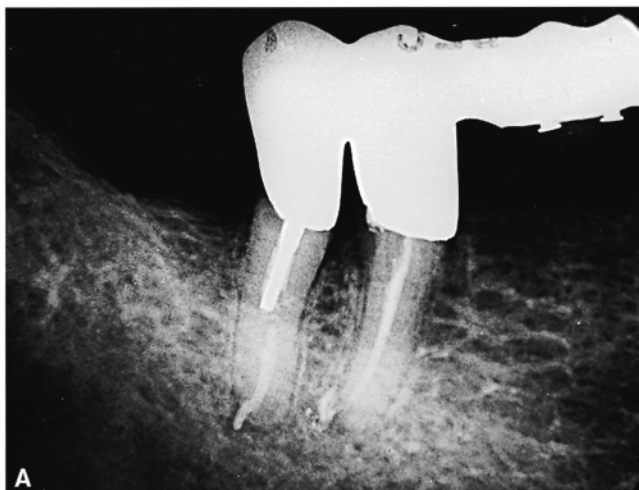Figure 12-63 Terminal molar with periodontal disease involving furca, to be used as bridge abutment. A, Canals obturated with softened gutta-percha and tooth bisected. B, Mirror view of buccal shows how tissue may now be maintained as interdental papilla. C, Different case; hemisection of second molar and bisection of first molar provides three sturdy abutments for terminal bridge. (A and B courtesy of Dr. James D. Zidell; C courtesy of Dr. L. Stephen Buchanan.)

Care must be exercised in maintaining the correct angulation of the bur to avoid gouging the remaining root or crown.

When the root to be removed has been completely resected, there may be enough loss of periradicular bone to permit it to be lifted or elevated from the socket (Figure 12-64). It is possible, however, that sufficient periradicular bone and cortical plate remain such that reflecting a mucoperiosteal flap is necessary so that sufficient bone can be removed to facilitate root removal. Elevation of a flap also allows for osseous recontouring.

Recontouring of the crown at the point of resection is very important. Plain fissure burs and tapered diamond stones are ideal for this reshaping process. The junction of the crown with the furcation should be smooth, with a gradual taper toward the interdental embrasure. There should not be any semblance of a stump left, and enough clearance between the under-surface of the crown and the tissue should be established to facilitate good oral hygiene. Following root amputation, oral hygiene can be enhanced by the use of

a small round brush (Figure 12-65). The patient should be instructed in its use and monitored postsurgically for proper effectiveness.

AMPUTATION TECHNIQUE FOR MANDIBULAR MOLARS: Treatment planning is critical when evaluating mandibular molars for root amputation. If the tooth is not a terminal tooth in the arch or an abutment for a fixed partial denture, extraction and replacement may be a preferred treatment. Some outstanding successes, however, are seen involving hemisection and placement of a three-unit fixed partial denture (see Figure 12-68).

The most common method of root amputation involving **mandibular molar teeth** is a **hemisection**. A terminal second mandibular molar is ideally suited for hemisection, provided there is opposing occlusion and adequate bone support for the remaining root (Figure 12-66). The remaining root and crown structure is restored as a premolar.

The root to be retained undergoes endodontic therapy. A post is placed in the retained root, if indicated, or a coronal-radicular core is placed. Following set of

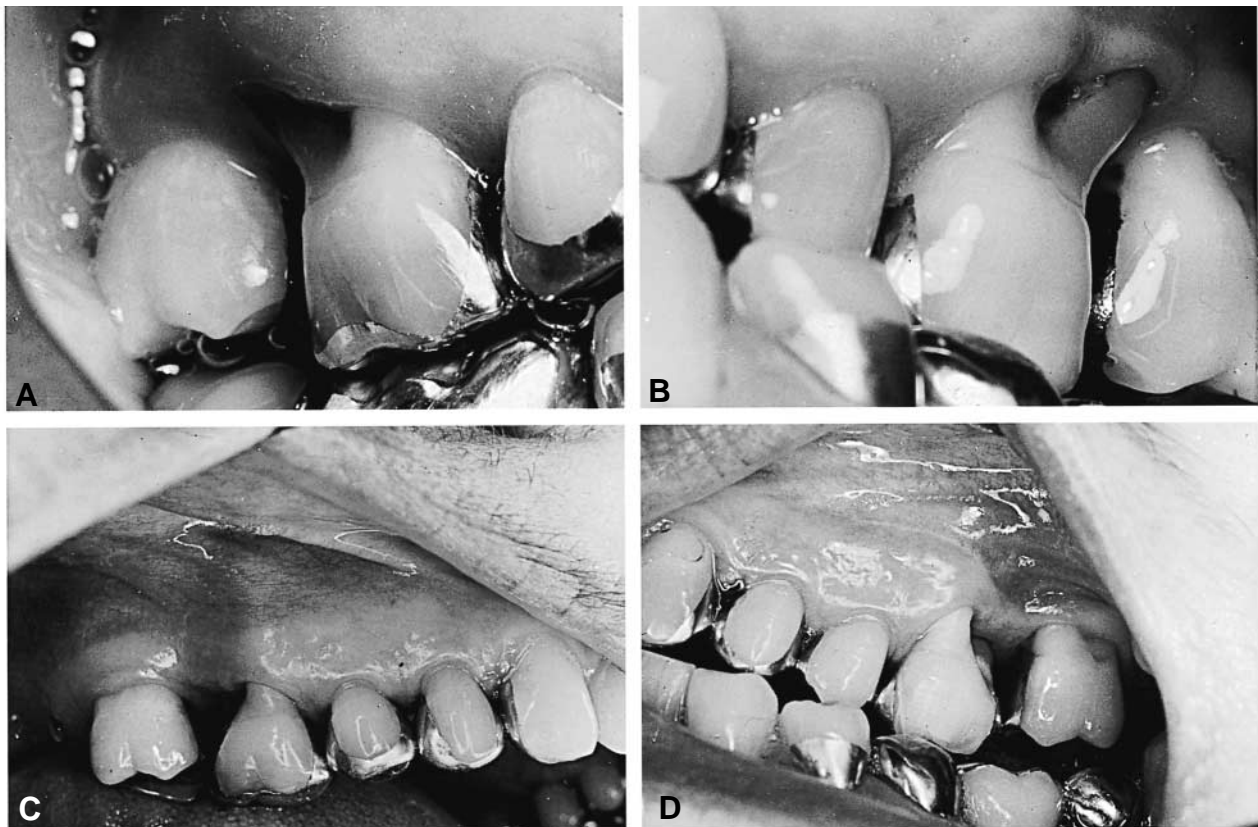


Figure 12-64 Excellent example of bilateral oblique root amputation on the same patient. A, Right maxillary first molar before root canal therapy and root amputation. Distobuccal root has lost its entire bony support. Because furca is exposed, flap need not be raised to amputate this root. B, Result 6 years after amputation. Occlusal table has been narrowed considerably. C, Left maxillary first molar in same patient with bony housing of distobuccal root completely destroyed. D, Result 6 years following root canal therapy and amputation; patient is meticulous in home care.

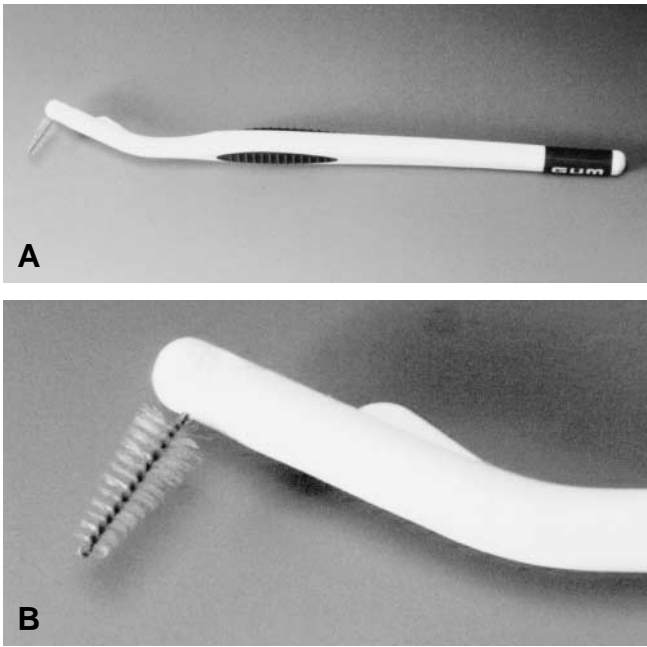
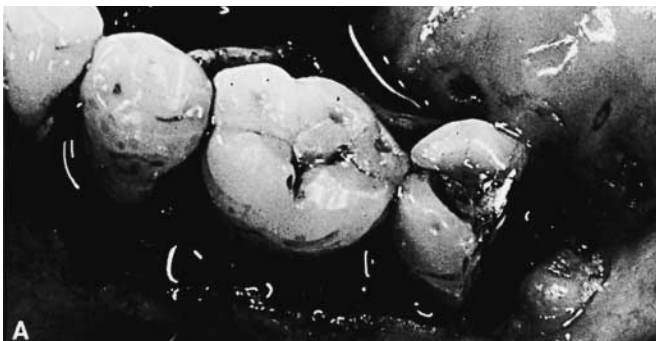

Figure 12-65 A, Cleaning aids such as the Butler Proxabrush (John O. Butler Co., Chicago, Ill.) are important to good maintenance care. B, Close-up of Proxabrush head.

the core material, a sharp cowhorn explorer is used to identify the location of the buccal and lingual furcations (see Figure 12-59, A). Depending on the degree of periodontal bone loss and the thickness of the trunk of the tooth, a mucoperiosteal flap may or may not need to be raised. The coronal sectioning should be done with a fissure bur or a small tapered diamond stone in a high-speed handpiece. The cut should be initiated on the buccal surface and should section the tooth at the expense of the portion of the crown that is scheduled to be removed. Sufficient proximal furcal floor should be left on the portion of the tooth to be retained to establish a restorative finish line as well as sufficient crown for retention.



An elevator should be placed between the two halves of the crown and gently rotated to determine if the separation is complete. Once this has been verified, the pathologic root is gently removed with forceps or eased out with an elevator. Sterile gauze should be packed into the socket while the final contouring of the remaining coronal tooth structure is completed. This will prevent particles of tooth and restorative material from gaining entrance into the open socket. After all coronal contouring is completed, the gauze packing should be removed and, if a flap was elevated, it should be repositioned and stabilized with sutures.

Bisection or “bicuspidization” should be considered in mandibular molars in which periodontal disease has invaded the bifurcation and when repair of internal furcation perforations has been unsuccessful. The type of coronal section is similar to that used for hemisection except the location of the cut is centered in the furcation so as to evenly divide the crown. The furca is then turned into an interproximal space where the tissue is more manageable by the patient (see Figure 12-63).

Single root amputation of mandibular molar teeth (leaving the crown intact) may, on occasion, be indicated where a splint or fixed partial denture is in place. For the most part, however, an uneven exertion of occlusal forces tends to exert an unnatural force on the remaining root, thereby resulting in root fracture. Some teeth are treated successfully by single root amputation, but the length of tooth retention is unpredictable (Figure 12-67).

A tooth that is hopelessly involved, yet is a nonterminal member of a fixed partial denture, may be converted into a pontic by total amputation of its root or roots. Premolars are the most commonly involved teeth in this situation. Following pulpectomy, the canal orifice(s) are prepared with a round bur to a level below the gingival margin. The entire access cavity is filled with amalgam or composite resin following dentin

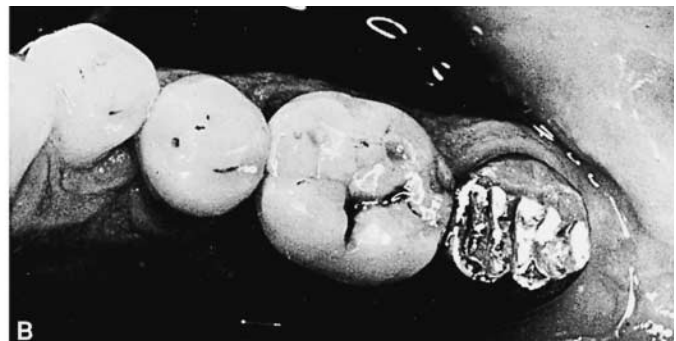

Figure 12-66 Terminal molar, hemisected and bicuspidized. A, Distal half of tooth removed. B, Final full crown restoration contacts both adjacent and opposing molars.

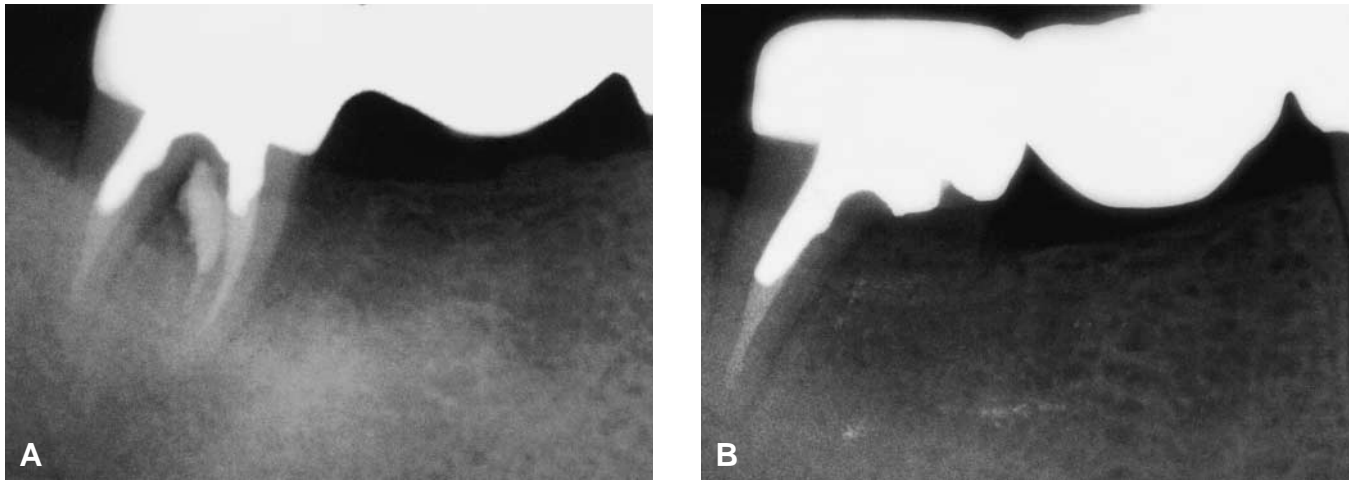


Figure 12-67 Mesial root amputation of a mandibular molar involving the distal abutment of a fixed partial denture. A, Root perforation with root canal filling material and bone loss in the furcation. B, Radiograph taken 5 years following mesial root amputation.

bonding. A buccal/facial marginal mucoperiosteal flap is raised, and the entire root is resected at a level well below the gingival margin. The remaining tooth structure should be contoured in a convex shape to resemble a pontic. The severed root should be removed to the buccal side of the alveolar bone and the flap repositioned and stabilized with appropriate sutures.

Several studies have evaluated the long-term success of root-resected and hemisected teeth. The results range from a success rate of 62 to 100% occurring over times ranging from 1 to 23 years. Combining the data from these studies indicates an overall success rate of 88% for the time periods followed.^{242–251} Long-term prognosis of teeth with roots totally amputated or hemisected depends on the quality of the original surgery and recontouring of the remaining tooth structure, on the quality of the root canal treatment in the remaining root or roots, on the quality of the final restoration, on the quality and quantity of the remaining supporting bone, and on the status of periodontal care. Any one, or combination, of these factors may cause failure of the case. When all of these elements are well executed, a superb and long-lasting result may be achieved (Figure 12-68).

Surgical Correction of the Radicular Lingual Groove. Another serious periodontal defect that can sometimes be corrected surgically is the radicular lingual groove (palatogingival groove). Found almost exclusively in maxillary lateral and central incisors, this developmental defect in root formation precludes the deposition of cementum in the groove; hence it prevents periodontal ligament (PDL) attachment. The groove then causes a narrow periodontal pocket, a bacterial pathway, often to the root apex, that can lead to reinfection of the pulp.⁹²

Prevalence of these grooves may be higher than previously suspected. After examining 921 maxillary incisors, Pecora and his associates in Sao Paulo reported a 2% incidence in central incisors and a 2.6% incidence in lateral incisors. Most of the central incisor grooves, however, were found on the facial surface.²⁵² Goon and his associates at the University of the Pacific in San Francisco reported on an unusual facial radicular groove in a maxillary lateral incisor.²⁵³

Robinson and Cooley have suggested a surgical intervention that may, in a number of cases, correct the defect and allow healing.²⁵⁴ Following a palatal surgical exposure of the defect, the groove is eliminated by grinding it away with round burs or diamond points. Shallow grooves are handled differently from deep grooves (Figure 12-69). If the lingual groove, however, is so deep that it communicates with the pulp space, the case is hopeless and extraction of the tooth is indicated.⁹²

REPLACEMENT SURGERY (EXTRACTION/REPLANTATION)

Grossman, in 1982, defined intentional replantation as “the act of deliberately removing a tooth and—following examination, diagnosis, endodontic manipulation, and repair—returning the tooth to its original socket.”²⁵⁵ Extraction/replantation is by no means a recently developed procedure. Abulcasis, an Arabian physician practicing in the eleventh century, is the first credited with recording the principle of extraction/replantation.²⁵⁶ Over the years since then, many authors have published reports of studies and case reports dealing with the technique and results of extraction/replantation.^{257–261}

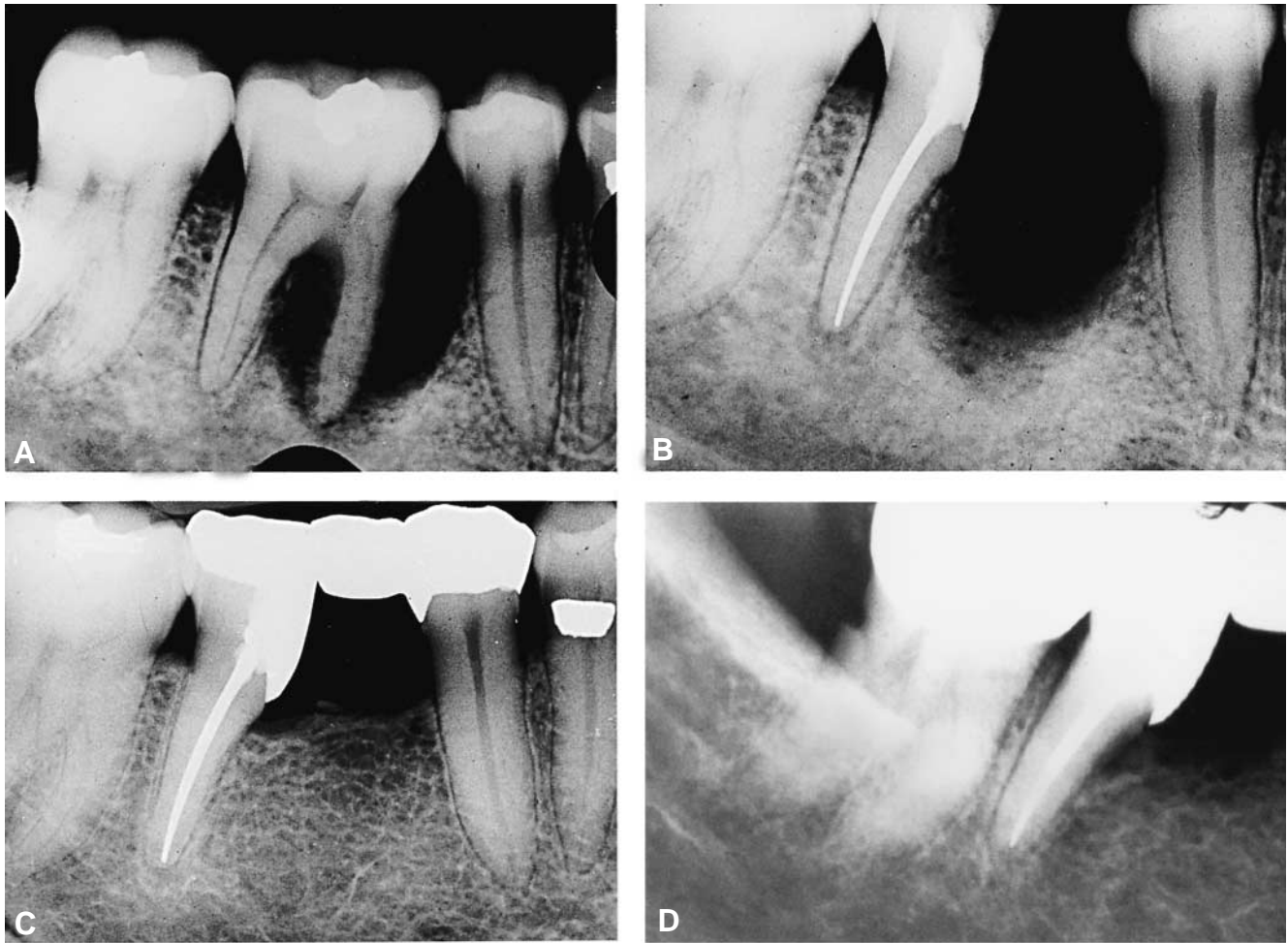


Figure 12-68 Hemisection of mandibular molar. A, Decision to hemisect molar and restore space relates to open contacts and future drifting. B, Tooth is hemisected through furca, and pathologic root removed. Root canal filling of remaining distal root is done at the same appointment through exposed pulp chamber. C, Final restoration of space converts first molar into a premolar. D, Forty-seven-year recall film attests to the meticulous therapy and long-range efficacy of this case. (Endodontic therapy by Dr. Dudley Glick and restoration by Dr. James McPherson.)

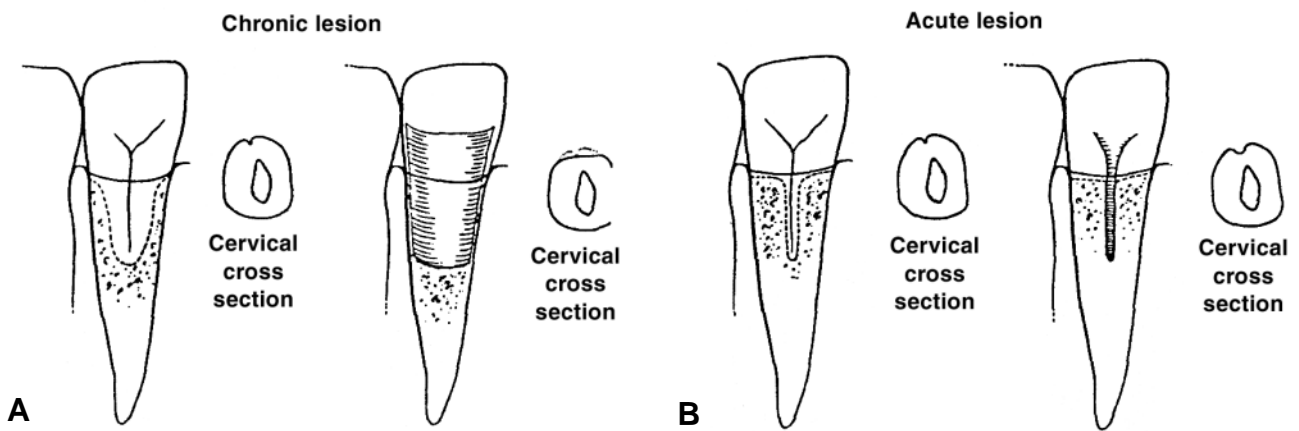


Figure 12-69 Surgical exposure of palatogingival groove allows “saucerization” with diamond stones or burs to remove pathologic groove. A, Illustration of the chronic lesion (left) and saucerization to eliminate the lingual groove (right). The cross-section shows the contour of the lingual surface with the groove (left) and after it has been removed. B, An acute lesion may result in less bone loss than a chronic lesion. In this situation, it may be possible to eliminate the groove without flattening the entire lingual surface. The cross-section illustrates the contour of the lingual surface as it might appear with the groove (left) and its contour after removal (right). Reproduced with permission from Robison SF, Cooley RL. *Gen Dent* 1988;36:340.

Indications

It is generally accepted that extraction/replantation is an acceptable treatment alternative when nonsurgical endodontic treatment is either impossible or has not been successful and periradicular surgery is inadvisable because of poor visual and/or surgical access or the danger of surgical damage to adjacent anatomic structures (mandibular canal, mental foramen). Dryden and Arens have stated that extraction/replantation should not be suggested as a routine treatment but should be considered only as a treatment of last resort. They also suggested the following as **indications for extraction/replantation**²⁶²:

1. Inadequate interocclusal space to perform nonsurgical endodontic treatment caused by the patient's limited range of motion of the temporomandibular joint and associated muscles.
2. Nonsurgical treatment and/or re-treatment are not feasible because of canal obstructions (ie, calcification of the pulp space, posts, separated instruments, impassable ledges).
3. Surgical approach for periradicular surgery is not practical because of limiting anatomic factors (ie, risk of paresthesia because of proximity of root apices to the mandibular canal or mental foramen).
4. Nonsurgical and surgical treatment have failed and symptoms and/or pathosis persist.
5. Visual access is inadequate to perform root-end resection and root-end filling.
6. Root defects (resorption, perforation) exist in areas that are not accessible through a periradicular surgical approach without excessive alveolar bone loss.
7. To thoroughly examine the root or roots on all surfaces to identify or rule out the presence of a root defect, such as a crack or root perforation.

Rationale and Outcome

The replantation of traumatically (accidentally) avulsed teeth is universally accepted as the treatment of choice whenever possible (see Chapter 15, "Endodontic Considerations in Dental Trauma"). If replantation has become the standard of care for teeth that have been traumatically avulsed, why would it not be justifiable to **intentionally "avulse"** a tooth under the controlled trauma of extraction and replant the tooth under aseptic conditions? Dryden and Arens state that, in a personal communication, Andreasen claims 90% success when avulsed teeth are replanted within 30 minutes.²⁶²

There are three factors that directly affect the outcome of extraction/replantation procedures:

1. Keeping the out-of-socket time as short as possible.
2. Keeping the periodontal ligament cells on the root surface moist with saline or Hanks Balanced Salt Solution during the time the tooth is out of the socket.
3. Minimizing damage to the cementum and periodontal ligament cells by gentle elevation and extraction of the tooth. The forcep beaks should not touch the cementum if at all possible.

It is obvious that success depends on the ability to remove the involved tooth without fracture of the root or roots. The patient should always be advised that fracture of the tooth is possible and if this occurs, the tooth must be removed and discarded.

Kingsbury and Wiesenbaugh reported on 151 mandibular premolar and molar teeth that were extracted, treated, and replanted. They evaluated these teeth over a 3-year period and reported a success rate of 95%.²⁶³ Koenig and associates reported on a study involving 192 extracted and replanted teeth. Following an evaluation period of between 6 and 51 months, they reported a success rate of 82%.²⁶⁴ More recently, Bender and Rossman reported on 31 cases of extraction/replantation. They reported a success rate of 80.6% with an observation period of up to 22 years.²⁶⁵ Raghoobar and Vissink reported on 29 cases involving extraction/replantation of mandibular molar teeth. One (3%) had to be removed 4 weeks postsurgically because of pain and mobility, 3 (11%) had to be removed during the first year because of periodontal problems, 4 (14%) showed periodontal problems or root resorption but continued to be functional, and 21 (72%) were considered successful after a 5-year observation period.²⁶⁶ Kratchman stated, "With increased understanding of the periodontium and improved techniques, intentional replantation should no longer be viewed as a treatment of last resort, but rather a successful treatment alternative."²⁶⁷

Steps in Extraction/Replantation

Once extraction/replantation has been determined and accepted as the treatment of choice, orthograde endodontic treatment should be completed to the best degree possible, and the pulp chamber and coronal access restored to help stabilize and reinforce the coronal tooth structure:

1. Following incision of the periodontal fibers with a No. 15 scalpel blade, the tooth to be extracted should be slowly and gently elevated with an appropriate size and style of surgical elevator until a class III

mobility is achieved. This is a very crucial step in the extraction process as it helps to accomplish extraction with the least chance of root fracture.

2. The appropriate forceps are chosen and preferably the beaks are wrapped with a sterile gauze sponge that is saturated with normal saline or Hanks Balanced Salt Solution. Every attempt should be made to minimize damage to the cementum during the extraction process.
3. Following extraction, the tooth should be held with the forceps, protected by saturated gauze or by hand at the coronal portion using a saturated gauze. The roots of the tooth should be thoroughly examined with fiber-optic illumination and magnification to evaluate for the presence of root fractures or radicular defects, such as perforations or resorptions. The application of methylene blue dye to the root surfaces may enhance visualization of otherwise nonvisible root defects. It is extremely important that the root surfaces be constantly bathed with either normal saline or Hanks Balanced Salt Solution during the time the tooth is out of its socket. Intentional replantation is best done as a team effort with each member of the team trained and skilled in their specific function.
4. If no root fractures are evident and the prognosis for replantation appears positive, any root defects should be repaired with an appropriate material. If root end resection is indicated, it should be done with a plain fissure bur in a high-speed handpiece under constant irrigation. Two to three millimeters of root-end should be resected. A small class I root-end preparation should be done with either a bur or an ultrasonic tip extending at least 3 mm into the root and an appropriate root-end filling placed.
5. Following repair of any root defects and/or root-end resection and root-end filling, the extraction socket should be irrigated with normal saline and gently suctioned to remove any blood clot that may have formed. The tooth is then carefully returned to its socket. Reinsertion of the tooth into the socket may be difficult at times, especially if there is a critical path of insertion. Care must also be taken that the tooth is returned to the socket in its proper orientation.
6. After the tooth has been inserted into the socket, a rolled gauze sponge should be placed on the occlusal aspect of the tooth and the patient instructed to bite down so that the interocclusal force will seat the tooth into its socket. The patient should be instructed to maintain interocclusal pressure for approximately 5 minutes.
7. In most cases, posterior teeth are well retained in their sockets and stabilization is usually not

required. If excessive mobility is evident, splinting is suggested. The recommended splinting type and length of time are the same as those for replantation following traumatic avulsion and are discussed in chapter 15, "Endodontic Considerations in Dental Trauma." In the case of a posterior tooth, stabilization may be achieved by placing a figure-8 suture over the occlusal surface of the tooth. The suture may be secured on the occlusal surface of the tooth by placing a shallow groove on the buccal-lingual aspect of the crown (Figure 12-70). Stabilization may also be achieved by the use of a flexible wire with acid etching and bonding with composite resin to an adjacent tooth (Figure 12-71).

8. The patient should be seen 7 to 14 days following intentional replantation surgery to remove any stabilization that was placed and to evaluate tooth mobility. Postsurgical evaluation is recommended at 2, 6, and 12 months following surgery (Figure 12-72).

Intentional replantation is not a completely predictable procedure. Under favorable conditions, however, some authors have reported success rates in excess of 20 years.²⁶²⁻²⁶⁸

IMPLANT SURGERY

Two types of endosteal implants fall under the purview of endodontics: **endodontic implants and osseointegrated implants**, also called endosseous implants.⁹² This is not to say that every dentist, or endodontist for that matter, should be placing endosteal implants, especially when the supporting alveolar bone is compromised. Only those who are specially trained and have extensive experience in periradicular and periodontal surgery should be involved in implant place-

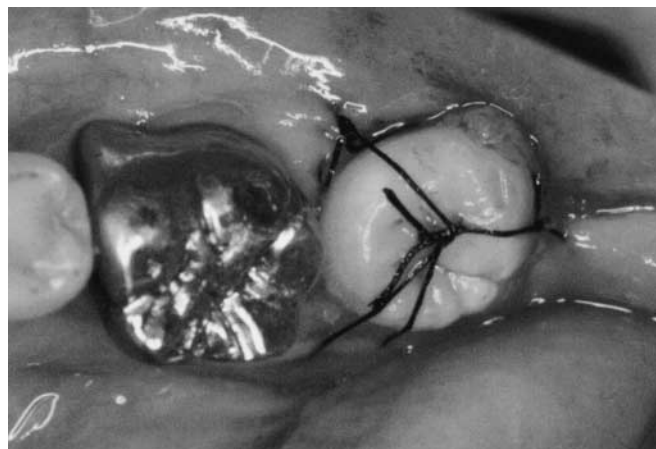


Figure 12-70 Stabilization of the replanted tooth has been achieved by placing a suture over the occlusal surface.

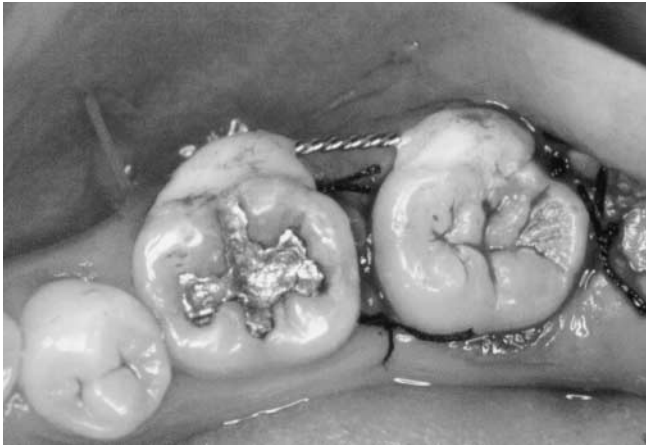

Figure 12-71 Stabilization of the replanted tooth has been achieved by bonding a flexible wire to the adjacent tooth with composite resin.

ment. Jansen has stated that many practitioners have found implant procedures to be too difficult, the learning curve long, and office support staff unsure of their role in the procedure. Restorative dentists who place implants do so only on the average of two to three a year. This is insufficient to acquire the necessary diagnostic and treatment skills to perform successful implant procedures.²⁶⁹

Endodontic Implants

It makes great sense that, if a rigid implant can safely extend beyond the apex of the tooth into sound bone, and by so doing stabilize a tooth with weakened support, the patient is well served and perhaps has avoided replacement for some time. Such is the reasoning behind the concept of the endodontic implant, many of

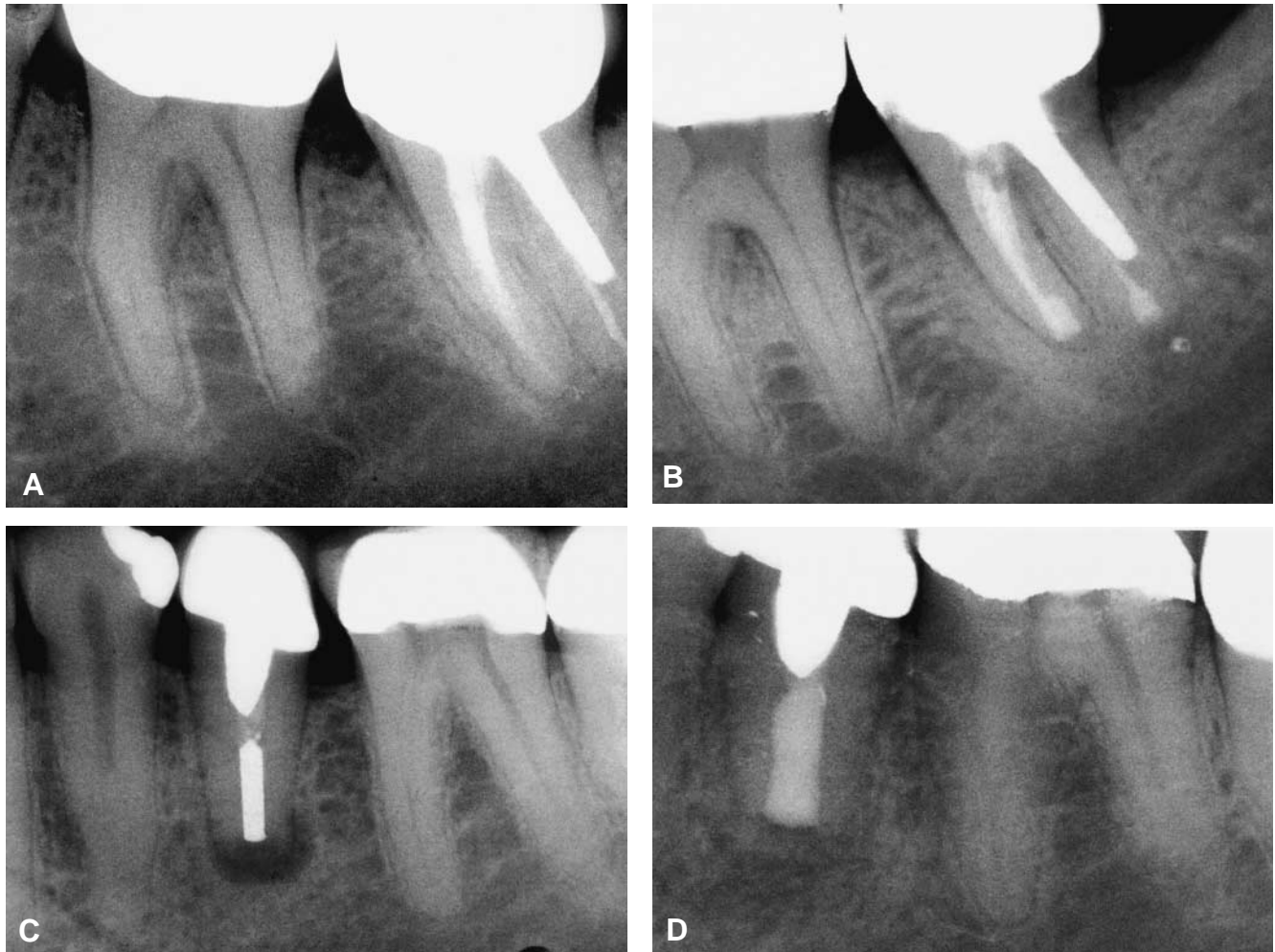


Figure 12-72 A, Patient reported pain to pressure 1 year following root canal therapy, post and crown. Extraction/replantation chosen due to proximity of mandibular canal. B, Radiograph 4 years following extraction/replantation procedure with intermediate restorative material (IRM) for root-end fillings. Patient is asymptomatic. C, Patient presented with pain and localized intraoral swelling, root canal therapy and crown 20 years. D, Three years following extraction/replantation procedure. Silver point removed and root canal space filled with gutta percha and sealer through retrograde approach.

which have proven quite successful (Figure 12-73). On the other hand, when too high a failure rate of endodontic implants developed, the profession backed off from their use. Weine and Frank, however, retrospectively “revisited” their endodontic implant cases placed over a 10-year period. While admitting to “many which did fail,” they “noted some remarkable long-term successes with the technique.”²⁷⁰ Their recommendation was that endodontic implants not be discarded totally but used only in carefully selected cases.

Orlay may have been among the first to use and advocate endodontic implants.²⁷¹ Frank is credited, however, with standardizing the technique, developing the proper instruments, and matching implants.^{272, 273} Frank and Abrams were also able to show that a properly placed endodontic implant was accepted by the periradicular tissue and that a narrow “collar” of healthy fibrous connective tissue, much like a circular periodontal ligament,

surrounded the metal implant and separated it from the alveolar bone²⁷⁴ (Figure 12-74).

Placing endodontic implants is a technique-sensitive procedure. A **perfectly round preparation** must be reamed through the root apex and into the alveolar bone. Failure to accomplish this task results in leakage around the implant–dentin interface and eventual failure of the implant (Figure 12-75). Another critical area is structural weakening of the walls of the root as a result of dentin removal in an attempt to create a round apical orifice. This structural weakness may result in root fracture either at the time of implant placement or as a result of functional stresses on the tooth. It is also important that the periodontal condition that has led to the periradicular bone loss has been stabilized before endodontic implant placement. If not, the case will fail as a result of continued progression of the periodontal disease.

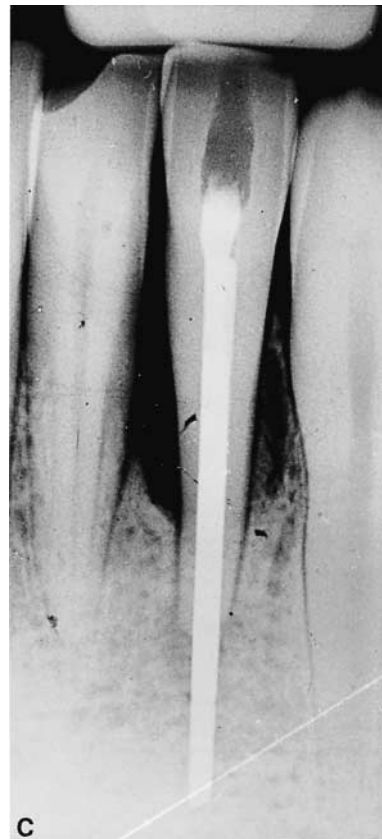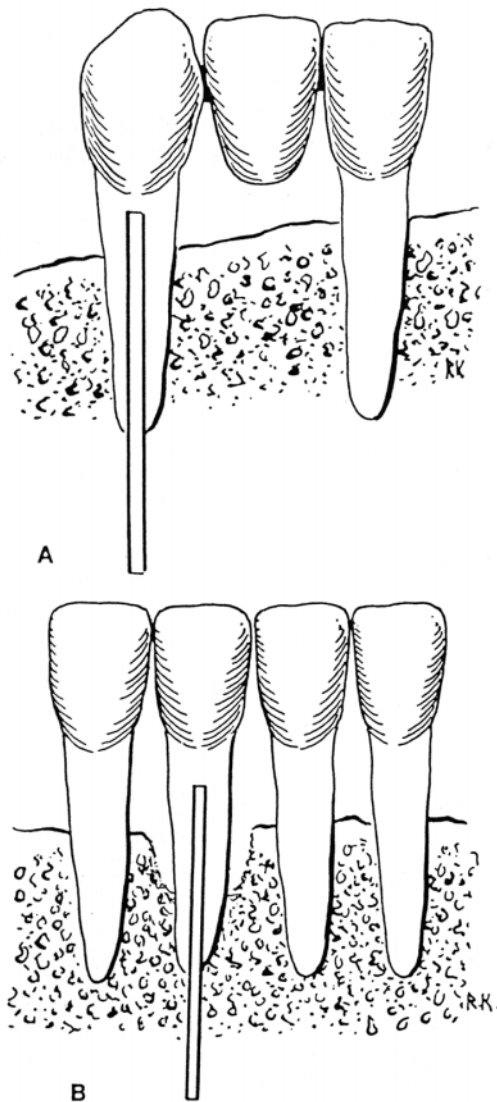


Figure 12-73 Indications for endodontic implants. A, Stabilizing periodontally weakened bridge abutment. B, Considerable restorative effort to replace tooth, and adjacent teeth would be poor abutments. C, Implant in hard-to-restore incisor. Periodontal condition must be treated and controlled. Reproduced with permission from Frank AL. *Dent Clin North Am* 1967;Nov:675.

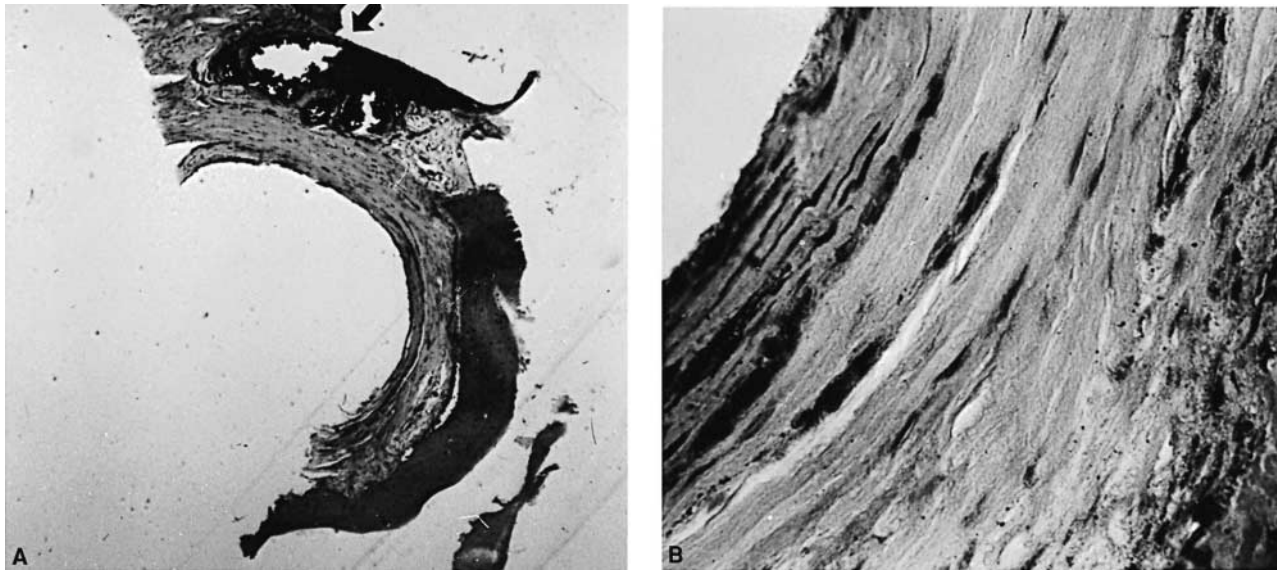


Figure 12-74 A, Low-power photomicrograph of transverse section through subapical region of endodontic implant. Dark material at top (arrow) is excess sealer. B, Higher power reveals connective tissue circular “ligament” configuration, without inflammation. Dark specks are excess sealer being scavenged and resorbed. Reproduced with permission from Frank AL. *J Am Dent Assoc* 1969;78:520.

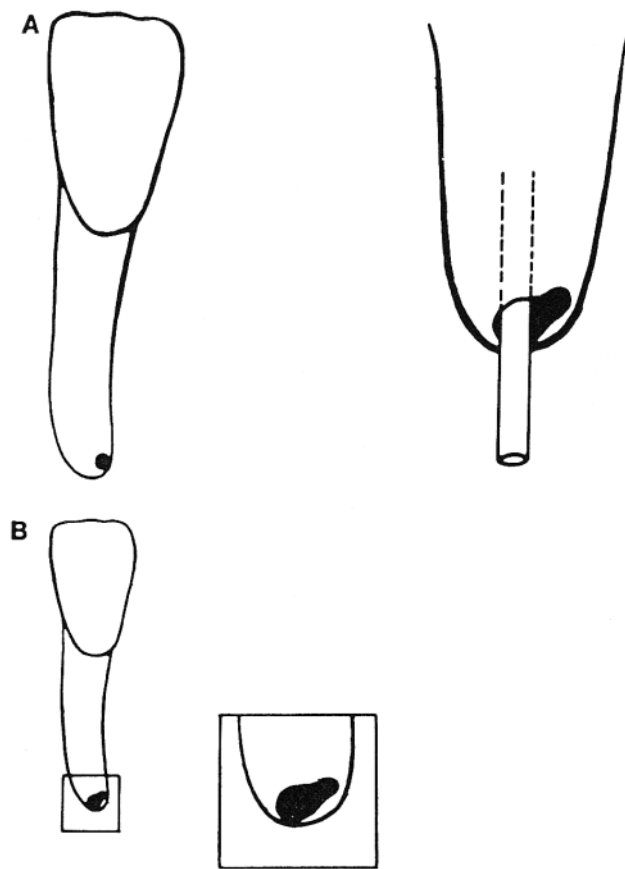


Figure 12-75 A, Portal of exit at a site not exactly at tip of root. B, Pear-shaped preparation is developed by large, stiff instruments. Endodontic implant only partially seals apical preparation leading to microleakage and failure. Reproduced with permission from Weine FS and Frank AL.²⁷⁰

Root-Form Osseointegrated Implants

Osseointegration is defined as “the direct structural and functional connection between ordered, living bone and the surface of a load-carrying implant.”²⁷⁵ Biomechanical as well as bacterial factors have long been recognized to play a substantial role in osseointegration maintenance.^{276,277} Since Brånemark first introduced osseointegration, many alterations and enhancements of his original protocol have been published. In the earlier years, most attention was directed toward successful surgical placement of an implant body, with minimal regard to the implant restoration. **Preexisting bone volume was allowed to direct and guide implant position.** This treatment philosophy resulted in restorative difficulties and created biomechanical concerns as well as hygienic compromise.

Prosthetically directed implant placement involves preplanning the implant restoration before implant placement. This concept emphasizes the importance of a team approach in the overall care of the dental implant patient. This shift from site-directed to prosthetically directed implant placement has been facilitated by the success of current bone regenerative techniques using bone-grafting materials and guided tissue membranes.

Immediate Implant Placement. Of the recent advancements in implant surgery, the most applicable to the practice of endodontics is **immediate implant placement** (Figure 12-76). Implant placement immediately following tooth extraction offers several advantages over

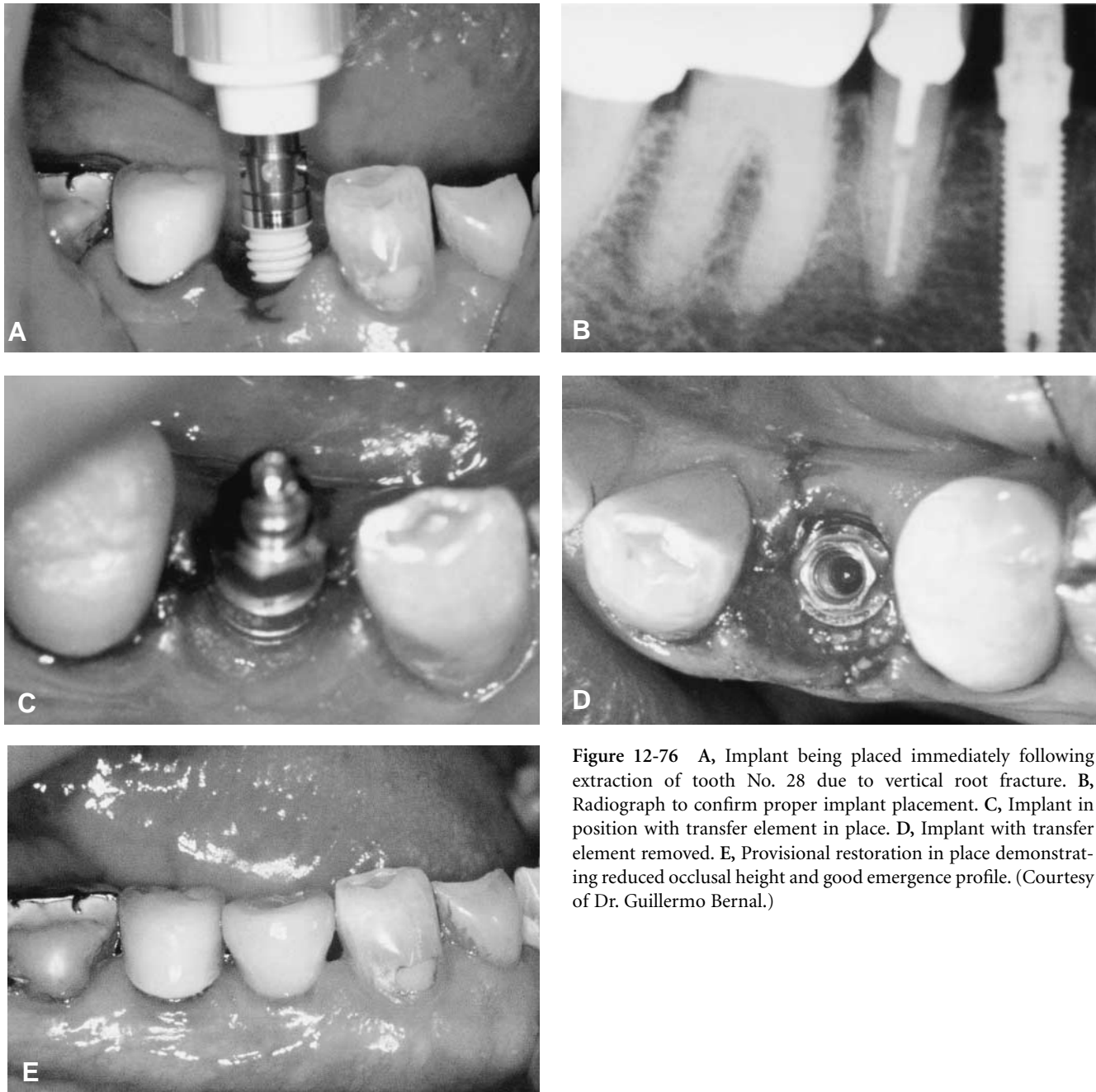


Figure 12-76 A, Implant being placed immediately following extraction of tooth No. 28 due to vertical root fracture. B, Radiograph to confirm proper implant placement. C, Implant in position with transfer element in place. D, Implant with transfer element removed. E, Provisional restoration in place demonstrating reduced occlusal height and good emergence profile. (Courtesy of Dr. Guillermo Bernal.)

the conventional protocol: (1) the incorporation of two procedures into one appointment, (2) the expediency of total treatment time, and (3) the minimization of osseous collapse as well as resorption and maintenance of soft-tissue architecture. Immediate implant placement, however, is not a universally applicable procedure. The presenting clinical situations may vary significantly. According to Gelb, the variables that may affect the regenerative protocol include the following:

1. Severity of the initial infection
2. Location of the root relative to the alveolus
3. Residual bone buccolingually and coronal apically
4. Vascularity of residual bone
5. Density of residual bone
6. Quality of cancellous marrow spaces
7. Availability of bony walls to contain the bone-graft material
8. Volume of bone regeneration necessary

9. Soft tissue available for closure
10. Experience of the operator²⁷⁸

Gelb also stated, "Despite these challenges, immediate implant surgery has been reported to have high predictability, which compares favorably to outcome reported in intact sites."²⁷⁸ In a study by Rosenquist and associates, 109 titanium threaded implants were placed **immediately following extraction** in 51 patients and evaluated over a mean observation time of 30 months. They reported a 92% survival rate for implants that replaced teeth extracted for periodontal reasons and a 96% survival rate for implants that replaced teeth that were extracted for other reasons including endodontic treatment failure, root fracture, and extensive caries.²⁷⁹

Appropriate clinical situations for immediate implant placement should have adequate bone apical to the extraction socket and/or adequate bone buccolingually to secure initial stability of the implant. The apical dimension of bone should be a minimum of 3 to 4 mm in height and the buccolingual bone must be evaluated on the basis of both quality and quantity. The presence of a localized infection does not generally preclude immediate implant placement. Tooth removal and débridement of the area is usually sufficient to control the infection. Immediate implant placement is contraindicated in the posterior mandible when insufficient buccolingual bone exists for initial implant stability and apical extension of the implant beyond the floor of the socket will result in damage to the mandibular nerve.²⁷⁸

Extraction and Curettage Procedure. The tooth should be extracted with as little trauma as possible. It is extremely important to retain the cortical bone buccal and lingual to the extraction socket. In the case of multirrooted teeth, it may be advantageous to section the crown and roots so that the roots may be individually extracted. This may save trauma to a thin cortical plate. All soft tissue should be removed from the bony crypt with curettes until a solid bone foundation is achieved.

Implant Placement. After tooth extraction and thorough débridement of the area, the major considerations for implant placement should be the specific functional and esthetic needs of the case. The drilling sequence may be altered from that of implant placement in an intact site as tapping and countersinking may not be necessary. The implant apex should be stabilized in at least 3 to 4 mm of bone and the implant head should be positioned to conform to either the central fossa, in posterior teeth, or the cingulum, in

anterior teeth, for screw-retained prosthesis. For cement-retained anterior prostheses, the implant head should be placed in line with the incisal edges of the adjacent teeth. For cement-retained posterior prostheses, the implant head should be placed slightly buccal to the central fossa of the planned restoration. Placement of the implant approximately 3 mm apical to the cemento-enamel junction of the adjacent teeth will ensure the maximum flexibility in the emergence profile of the restoration.²⁷⁸

Bone Graft and Membrane Placement. Preserving and/or regenerating buccal or labial bone are important to support soft-tissue dimensions and to give the appearance of a root eminence. The use of bone-grafting materials and membranes, resorbable and nonresorbable, may be used to promote bone growth around the implant and to preserve or restore labial dimensions. Demineralized freeze-dried bone allograft is a commonly used bone-graft material for this purpose.²⁷⁸

The bone-graft material is hydrated with sterile saline and packed into the void. Bone-graft material and a membrane are both used when there is a significant defect or when narrowing of the labial dimension is of major concern. When the bony walls of the defect are well defined and both cortical and cancellous anatomy are good, placement of bone-graft material alone is usually sufficient.²⁷⁸

Soft-Tissue Closure and Supportive Therapy. **Primary closure** is the closure of choice whenever possible. Care should be taken to maintain and preserve the soft tissue during incision and tooth extraction. The soft tissue should be repositioned as close as possible to its original position. When primary closure is not possible, the site should be covered with a nonresorbable membrane. Nonresorbable membranes serve as a scaffold for soft-tissue growth and migration resulting in closure over time. An alternative to placement of a nonresorbable membrane when primary closure is not possible is the use of a connective-tissue graft.²⁷⁸

Supportive therapy following immediate implant placement should include a bactericidal broad-spectrum antibiotic such as amoxicillin, cephalexin (Keflex), or clindamycin for a period of 7 to 14 days. Nonsteroidal anti-inflammatory drugs have been shown to be effective in promoting healing following implant placement.²⁷⁸ Chlorhexidine oral rinses should be used routinely following implant-placement surgery. When primary closure is not possible and a connective-tissue graft is not done, débridement of the surgical area should be done with a cotton swab soaked in chlorhexidine. The patient should be instructed to continue this regimen twice daily until closure has been

achieved. Gelb recommends that the sutures remain in place for 2 weeks and those cases that contain a membrane be monitored every 2 weeks until the membrane is removed.²⁷⁸

It is important to emphasize that, although implant surgery is within the scope of endodontics, it is a very technique-sensitive procedure that requires a relatively long learning curve. It is recommended that the dental practitioner participate in advanced training programs and gain considerable knowledge and experience in diagnosis, treatment planning, and placement of osseointegrated implants before implementing their use in clinical practice.

MICROSURGERY

For years, many dental practitioners have benefited from the use of vision-enhancement devices, such as loupes, surgical telescopes, and head-mounted surgical fiber-optic lamps (Figure 12-77). It is generally accepted that the better the visual access to the operating field, the higher the quality of treatment that can be accomplished.

Perhaps one of the most important recent developments in surgical endodontics has been the introduction of the surgical operating microscope (Figure 12-78). Otologists were the first medical specialists to introduce the operating microscope in the early 1940s. Slowly, the use of the operating microscope was introduced to the fields of ophthalmology, neurosurgery, urology, and other medical fields. Pioneers in the use of the operating microscope in surgical endodontics have been Buchanan,²⁸⁰ Carr,^{281,282} Rubinstein,^{283,284} Pecora and Adreana,²⁸⁵

Ruddle,²⁸⁶ Selden,²⁸⁷ Bellizzi and Loushine,²⁸⁸ Reuben and Apotheker,²⁸⁹ and others.

Surgical telescopes usually magnify in the range of $\times 2.5$ to $\times 6.0$, whereas the surgical operating microscope has a range of magnification of up to $\times 40$. The obvious question is "How much magnification is enough?" As the level of magnification increases, the field of vision and the depth of field (focal depth) decrease, as does the aperture of the microscope, therefore limiting the amount of light that reaches the surgeon's eyes. This makes use of **magnification in excess of $\times 30$ very impractical**. The slightest movement of the patient or of the operating microscope will result in the loss of visual field or focus. This can be very frustrating and result in the time-consuming need to readjust the microscope.

Magnifications in the range of $\times 2.5$ to $\times 8.0$ are recommended for orientation to the surgical field and to provide a wide field of view and a good depth of field. Midrange magnifications in the $\times 10$ to $\times 16$ are best for performing procedures such as root-end resections and root-end preparations. Higher range magnification in the area of $\times 18$ to $\times 30$ should be reserved for observing and evaluating fine detail.

Rubinstein has identified several advantages of the surgical operating microscope.²⁹⁰ They include

1. Visualizing the surgical field.
2. Evaluating the surgical technique.
3. Reducing the number of radiographs needed.
4. Expanding patient education through video use.

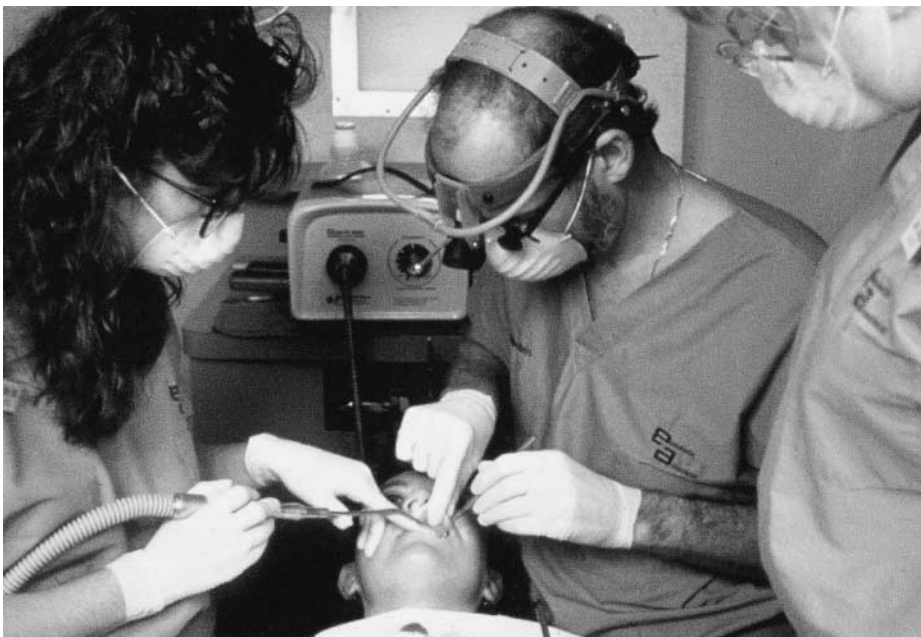


Figure 12-77 Operator using a fiber-optic headlamp system and $\times 2.5$ surgical telescopes.

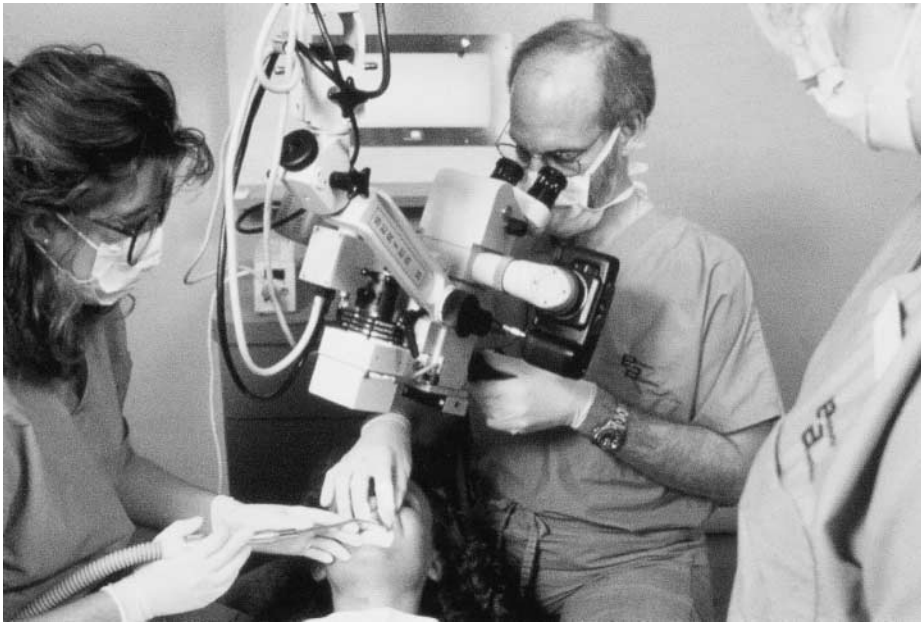


Figure 12-78 Operator using a surgical operating microscope with a 35 mm camera attached.

5. Providing reports to referring dentists and insurance companies.
6. Creating documentation for legal purposes.

The most significant of these advantages is the enhanced ability to visualize the surgical field and to evaluate the surgical technique (Figures 12-79 to 12-82). Incomplete root-end resection and failure to identify and properly include an interconnecting isthmus between multiple canals in a single root during root-end preparation have been stated as among the major causes of failure in endodontic surgery^{82,121} (Figure 12-83; also see Figure 12-33). The use of good illumination and magnification will aid the surgeon in reducing these factors and should result in an increased success rate for endodontic surgery. It must be pointed out that the use of the surgical operating microscope requires a relatively long learning curve and, therefore, it is recommended that the endodontic surgeon participate in advanced training programs and gain considerable experience in surgical microscopy before implementing its use in clinical practice.

An important question that must be addressed is “Does the use of a surgical operating microscope really make a difference in the long-term outcome of endodontic surgery?” A recent report of a prospective study involving endodontic surgery performed under the surgical operating microscope and using ultrasonic root-end preparation techniques with Super EBA as the root-end filling material showed an overall success rate of 96.8%.²⁹¹ This report consisted of 94 root-end surgery

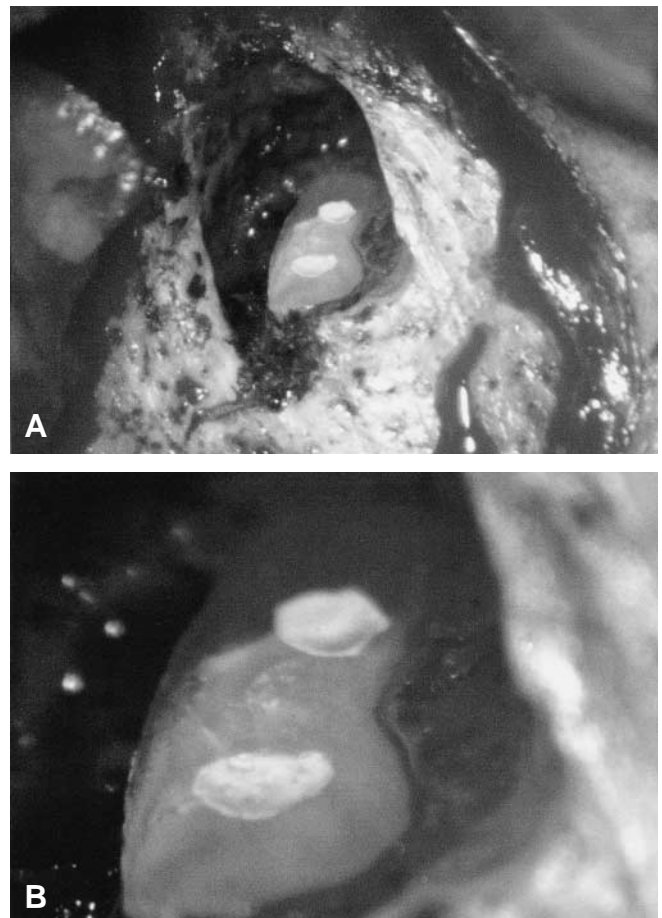


Figure 12-79 Final root-end fillings with Super EBA. A, $\times 8$ original magnification. B, $\times 26$ original magnification.

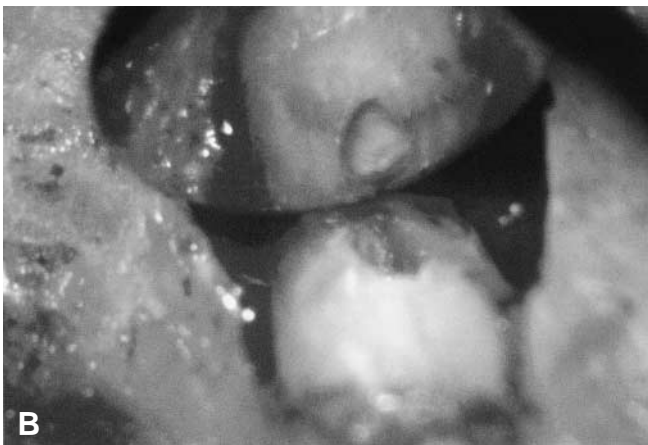
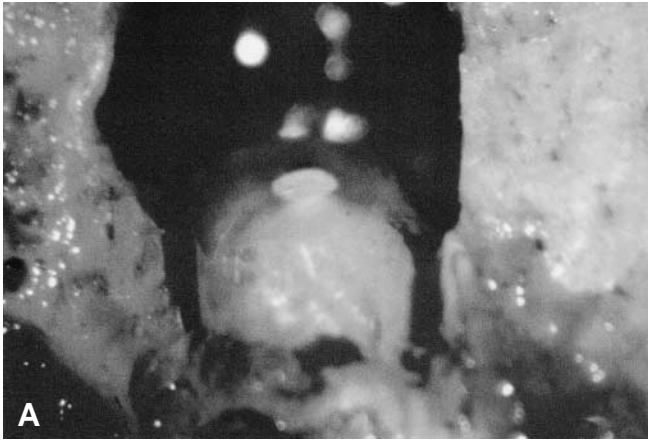


Figure 12-80 A, Beveled surface of the root of a maxillary lateral incisor following root-end resection ($\times 16$ original magnification). B, Root-end preparation following use of ultrasonic tips. Note use of microsurgical mirror ($\times 16$ original magnification).

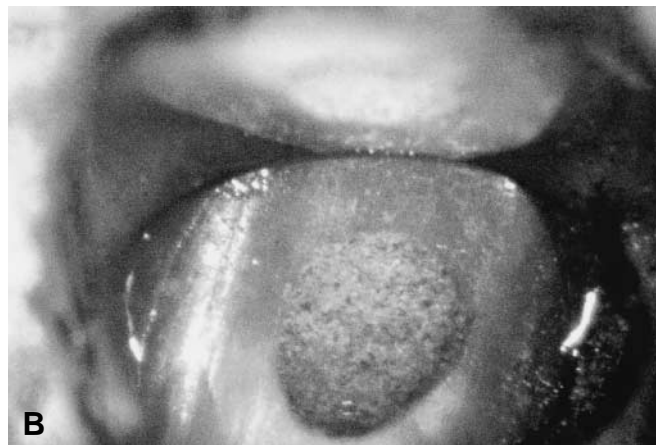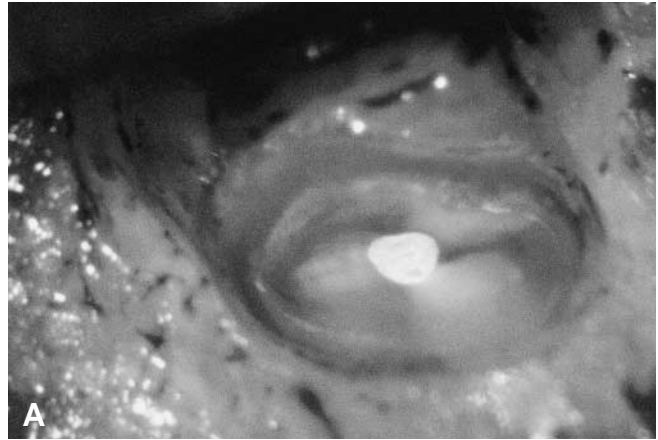


Figure 12-81 A, Finished root-end filling of a maxillary canine after use of a 30 fluted finishing bur ($\times 16$ original magnification). B, Mineral trioxide aggregate (MTA) root filling ($\times 26$ original magnification).

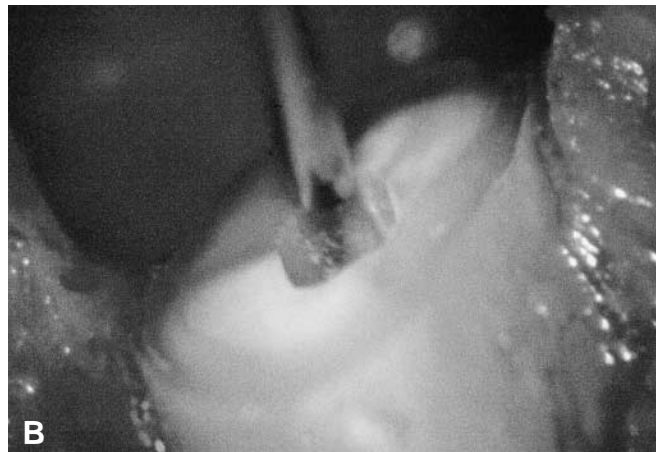


Figure 12-82 A, One-half millimeter blunt Blue Micro Tip mounted in a Stropko Irrigator on a triflow syringe. B, Blue Micro Tip drying the root-end preparation of a maxillary lateral incisor ($\times 20$ original magnification).

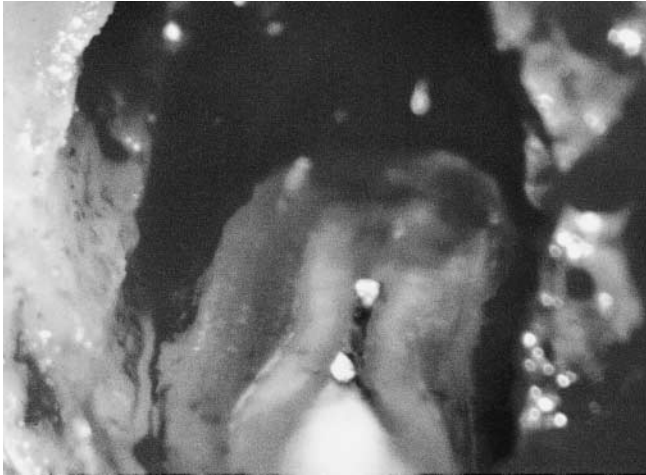


Figure 12-83 Isthmus evident connecting two canals of the mesiobuccal root of a maxillary first molar following root-end resection ($\times 16$ original magnification).

cases (31 molars, 31 premolars, 32 anterior teeth) treated by a single clinician. The evaluation period was 14 months. A case was considered successful when the lamina dura was restored or the case had healed by scar formation. Very strict case-selection criteria were used when selecting cases to be included in this study. **It also must be emphasized that this study had no control group.** The authors attribute the healing success primarily to the use of microsurgical techniques. They do state, however, that because of the short postsurgical evaluation time, their optimism regarding the outcomes of this study is tempered by the realization that cases sometimes fail following a preliminary healing phase. At the present time, there are no long-term (> 5 years) studies evaluating the outcomes of endodontic microsurgery procedures. **Time will be the judge!**

REFERENCES

- Guerini V. A history of dentistry. Philadelphia: Lea & Febiger; 1909. p. 117.
- Gutmann J, Harrison J. Surgical endodontics. St. Louis (MO): Ishiyaku EuroAmerica; 1994.
- Frank A, Simon J, Abou-Rass M, Glick D. Clinical and surgical endodontics: concepts in practice. Philadelphia: JB Lippincott; 1983.
- Grossman L, Oliet S, Del Rio C. Endodontic practice. 11th ed. Philadelphia: Lea & Febiger; 1988.
- American Association of Endodontists Web page. For the patient. www.aae.org (accessed July 1999).
- Sjögren U, Hagglund B, Sundquist G, Wing K. Factors affecting the long-term results of endodontic treatment. *J Endod* 1990;16:498.
- Stabholtz A, Walton R. In: Principles and practice of endodontics. 2nd ed. Philadelphia: WB Saunders; 1996.
- Eriksen H. Endodontology—epidemiologic considerations. *Endod Dent Traumatol* 1991;7:189.
- Pekruhn RB. The incidence of failure following single-visit endodontic therapy. *J Endod* 1986;12:68.
- Jokinen MA, Kotilainen R, Pockkeus P. Clinical and radiographic study of pulpectomy and root canal therapy. *Scand J Dent Res* 1978;86:366.
- Odesjo B, Hellden L, Salonen L, Langeland K. Prevalence of previous endodontic treatment, technical standard and occurrence of periapical lesions in a randomly selected adult, general population. *Endod Dent Traumatol* 1990;6:265.
- Murphy WK, Kaugars GE, Collett WK, Dodds RN. Healing of periapical radiolucencies after nonsurgical endodontic therapy. *Oral Surg* 19091;71:620.
- Jaoui L, Machtou P, Ouhayoun JP. Long-term evaluation of endodontic and periodontal treatment. *Int Endod J* 1995;28:249.
- Friedman S. Retreatment of failures. In: Principles and practice of endodontics. 2nd ed. Philadelphia: WB Saunders; 1996.
- Bergenholtz G, Lekholm U, Milthorpe R. Retreatment of endodontic fillings. *Scand J Dent Res* 1979;87:217.
- Allen RK, Newton CW, Brown CE. A statistical analysis of surgical and nonsurgical retreatment cases. *J Endod* 1989; 15:261.
- Van Nieuwenhuysen JP, Aouar M, D'Hoore W. Retreatment or radiographic monitoring in endodontics. *Int Endod J* 1994;27:75.
- Hepworth MJ, Friedman S. Treatment outcome of surgical and nonsurgical management of endodontic failures. *J Can Dent Assoc* 1997;63:364.
- Luebke RG, Glick DH, Ingle JJ. Indications and contraindications for endodontic surgery. *Oral Surg* 1964;18:97.
- American Association of Endodontists. Appropriateness of care and quality assurance guidelines. 3rd ed. Chicago: American Association of Endodontists; 1998.
- Cohen S, Schwartz S. *J Calif Dent Assoc* 1985;13:97.
- AAE Endodontics, Colleagues for Excellence. Chicago, Spring/Summer, 1999.
- Milam SB, Giovannitti JA. Local anesthetics in dental practice. *Dent Clin North Am* 1984;28:493.
- Holroyd SV, Requa-Clark B. Local anesthetics. In: Holroyd SV, Wynn RL, Requa-Clark B, editors. Clinical pharmacology in dental practice. 4th ed. St. Louis (MO): Mosby; 1988.
- Ritchie JM, Ritchie B, Greengard P. The active structure of local anesthetics. *J Pharmacol Exp Ther* 1965;150:152.
- Wallace JA, Mechanowicz AE, Mundell RD, Wilson EG. A pilot study of the clinical problem of regionally anesthetizing the pulp of an acutely inflamed mandibular molar. *Oral Surg* 1985;59:517.
- Najjar TA. Why can't you achieve adequate regional anesthesia in the presence of infection? *Oral Surg* 1977;4:7.
- McDonald NJ, Hovland EJ. Surgical endodontics. In: Walton R, Torabinejad M, editors. Principles and practice of endodontics. 2nd ed. Philadelphia: W. B. Saunders; 1996.
- Bellizzi R, Loushine R. A clinical atlas of endodontic surgery. Quintessence Publishing; 1991.
- Peters DD. Evaluation of prophylactic alveolar trephination to avoid pain. *J Endod* 1980;6:518.
- Elliott JA, Holcomb JB. Evaluation of a minimally traumatic alveolar trephination procedure to avoid pain. *J Endod* 1988;14:405.
- Arens DE, Adams WR, DeCastro RA, editors. Endodontic surgery. Philadelphia: Harper and Row; 1981.

33. Morse DR. Clinical endodontology. Springfield (IL): Charles C. Thomas; 1974.
34. Bence R. Trepination technique. *J Endod* 1980;6:657.
35. Lovdahl PE. Endodontic retreatment. *Dent Clin North Am* 1992;36:473.
36. Van Nieuwenhuysen JP, Aaouar M, D'Hoore W. Retreatment of radiographic monitoring in endodontics. *Int Endod J* 1994;27:75.
37. Weine FS. Nonsurgical retreatment of endodontic failures. *Compend Contin Educ Dent* 1995;16:324.
38. Cheung GS. Endodontic failures—changing the approach. *Int Dent J* 1996;46:131.
39. Moiseiwitsch JR, Trope M. Nonsurgical root canal therapy with apparent indications for root-end surgery. *Oral Surg* 1998;3:335.
40. Schiott CR, Loe H, Borglum-Jensen S, et al. The effects of chlorhexidine mouth rinses on the human oral flora. *J Periodontal Res* 1970;5:84.
41. Malamed SF. Handbook of local anesthetics. 2nd ed. St. Louis (MO): Mosby; 1986.
42. Jastak JT, Yagiela JA. Regional anesthesia of the oral cavity. St. Louis (MO): Mosby; 1981.
43. Simard-Savoie S. New method for comparing the activity of local anesthetics used in dentistry. *J Dent Res* 1975;54:978.
44. Sisk AL. Vasoconstrictors in local anesthesia for dentistry. *Anesth Prog* 1993;39:187.
45. Ahlquist RP. A study of the adrenotropic receptors. *Am J Physiol* 1948;153:586.
46. Gage TW. Pharmacology of the autonomic nervous system. In: Holroyd SV, Wynn RL, Requa-Clark B. Clinical pharmacology in dental practice. 4th ed. St. Louis (MO): Mosby; 1988.
47. Weiner N. Norepinephrine, epinephrine, and the sympathomimetic amines. In: Gilman AF, Goodman LS, Gilman A, editors. Goodman and Gilman's the pharmacologic basis of therapeutics. 6th ed. New York: Macmillan Publishing; 1980.
48. Bennett CR. Monheim's local anesthesia and pain control in dental practice. 7th ed. St. Louis (MO): Mosby; 1984.
49. Council on Dental Therapeutics of the American Dental Association. Accepted dental therapeutics. 40th ed. Chicago: American Dental Association; 1984.
50. Neidle EA. Introduction to autonomic nervous system drugs. In: Neidle EA, Kroeger DC, Yagiela JA, editors. Pharmacology and therapeutics for dentistry. 2nd ed. St. Louis (MO): Mosby; 1985.
51. Tolas AG, Pflug AD, Halter JB. Arterial plasma epinephrine concentrations and hemodynamic response after dental injection of local anesthetic with epinephrine. *J Am Dent Assoc* 1982;104:41.
52. Chernow B, Balestrieri F, Ferguson DD, et al. Local anesthesia with epinephrine: minimal effects on the sympathetic nervous system or on hemodynamic variables. *Arch Intern Med* 1983;143:2141.
53. Davenport RE, Porcelli RJ, Iacono VJ, et al. Effects of anesthetics containing epinephrine on catecholamine levels during periodontal surgery. *J Periodontol* 1990;61:553.
54. Lipp M, Dick W, Daublander M, et al. Exogenous and endogenous plasma levels of epinephrine during dental treatment under local anesthesia. *Reg Anesth* 1993;18:6.
55. Replogle K, Reader A, Nist R, et al. Cardiovascular effects of intraosseous injections of 2 percent lidocaine with 1:100,000 epinephrine and 3 percent mepivacaine. *J Am Dent Assoc* 1999;130:649.
56. Pallasch TJ. Vasoconstrictors and the heart. *Calif Dent Assoc J* 1998;
57. Hecht A, App GR. Blood volume loss during gingivectomy using two different anesthetic techniques. *J Periodontol* 1974;45:9.
58. Roberts DH, Sowray JH. Local anesthesia in dentistry. 2nd ed. Bristol: John Wright & Sons; 1987.
59. Lindorf HH. Investigation of the vascular effects of newer local anesthetics and vasoconstrictors. *Oral Surg* 1979;48:292.
60. Allen GD. Dental anesthesia and analgesia. 3rd ed. Baltimore (MD): Williams and Wilkins; 1984. p. 64.
61. Yagiela JA. Local anesthetics. In: Neidle EA, Kroeger DC, Yagiela JA, editors. Pharmacology and therapeutics for dentistry 2nd ed. St. Louis (MO): Mosby; 1985; p. 256.
62. Cutright DE, Hansuck EE. Microcirculation of the perioral regions of the *Macaca rhesus*. *Oral Surg* 1970;29:776.
63. Gutmann JL, Harrison JW. Posterior endodontic surgery: anatomical considerations and clinical techniques. *Int Endod J* 1985;18:8.
64. Castelli WA, Huelke DF. The arterial system of the head and neck of the rhesus monkey with emphasis on the external carotid system. *Am J Anat* 1965;116:149.
65. Davis WL. Oral histology: cell structure and function. Philadelphia: WB Saunders; 1986; p. 154.
66. Hooley JR, Whitacre RJ. A self-instructional guide to oral surgery in general dentistry. 2nd ed. Seattle: Stoma Press; 1980.
67. Luebke RG, Ingle JL. Geometric nomenclature for mucoperiosteal flaps. *Periodontics* 1964;2:301.
68. Macphee R, Cowley G. Essentials of periodontology and periodontics. 3rd ed. Oxford: Blackwell Scientific Publications; 1981.
69. Harrison JW, Jurosky KA. Wound healing in the tissues of the periodontium following periradicular surgery. 1. The incisional wound. *J Endod* 1991;17:425.
70. Harrison JE, Jurosky KA. Wound healing in the tissues of the periodontium following periradicular surgery. 2. The dissectional wound. *J Endod* 1991;17:544.
71. Kohler CA, Ramfjord SP. Healing in gingival mucoperiosteal flaps. *Oral Surg* 1960;13:89.
72. Levine LH. Periodontal flap surgery with gingival fiber retention. *J Periodontol* 1972;43:91.
73. Ruben MP, Smukler H, Schulman SM, et al. Healing of periodontal surgical wounds. In: Goldman HM, Cohen DW, editors. Periodontal therapy. 6th ed. St. Louis (MO): Mosby; 1980.
74. Phillips JL, Weller RN, Kulild JC. The mental foramen. 1. Size, orientation, and positional relationship to the mandibular second premolar. *J Endod* 1990;16:221.
75. Phillips JL, Weller RN, Kulild JC. The mental foramen. 2. Radiographic position in relation to the mandibular second premolar. *J Endod* 1992;19:271.
76. Weine FS, Gerstein H. Periapical surgery. In: Weine FS, editor. Endodontic therapy. 4th ed. St. Louis (MO): Mosby; 1982.
77. Arens DE. Surgical endodontics. In: Cohen S, Burns R, editors. Pathways of the pulp. 4th ed. St. Louis (MO): Mosby; 1987.
78. Gerstein H. Surgical endodontics. In: Laskin DN, editor. Oral and maxillofacial surgery. Vol 2. St. Louis (MO): Mosby; 1985.
79. Gutmann JL. Principles of endodontic surgery for the general practitioner. *Dent Clin North Am* 1984;28:895.
80. Barnes IE. Surgical endodontics. A colour manual. Littleton (MA): PSG Publishing; 1984.

81. Cambruzzi JV, Marshall FJ. Molar endodontic surgery. *J Can Dent Assoc* 1983;49:61.
82. Carr GB, Bentkover SK. Surgical endodontics. In: Cohen S, Burnes R, editors. *Pathways of the pulp*. 7th ed. St. Louis (MO): Mosby; 1997; p. 619.
83. Tetsch P. Development of raised temperatures after osteotomies. *J Maxillofac Surg* 1974;21:141.
84. Eriksson AR, Albrektsson T. Heat induced bone tissue injury. *Swed Dent J* 1982;6:262.
85. Eriksson AR, Albrektsson T, Grane B, McQueen D. Thermal injury to bone. A vital-microscopic description of heat effects. *Int J Oral Surg* 1982;11:115.
86. Eriksson AR, Albrektsson T. Temperature threshold levels for heat-induced bone tissue injury: a vital-microscopic study in the rabbit. *J Prosthet Dent* 1984;50:101.
87. Eriksson AR, Albrektsson T. The effect of heat on bone regeneration: an experimental study in the rabbit. *J Oral Maxillofac Surg* 1984;42:705.
88. Boyne P. Histologic response of bone to sectioning by high-speed rotary instruments. *J Dent Res* 1966;45:270.
89. Moss R. Histopathologic reaction of bone to surgical cutting. *Oral Surg* 1964;17:405.
90. Argen E, Arwill T. High-speed or conventional dental equipment for the removal of bone in oral surgery. III: A histologic and micro radiographic study on bone repair in the rabbit. *Acta Odontol Scand* 1968;26:223.
91. Calderwood RG, Hera SS, Davis JR, Waite DE. A comparison of the cutting effect on bone after the production of defects by various rotary instruments. *J Dent Res* 1964;43:207.
92. Ingle JI, Cummings RR, Frank AL, et al. Endodontic surgery. In: Ingle JI, Bakland LK, editors. *Endodontics*. 4th ed. Philadelphia: Lea & Febiger; 1994.
93. Falomo OO. Surgical emphysema following root canal therapy: report of a case. *Oral Surg* 1984;58:101.
94. Ely EW, Stump TE, Hudspeth AS, Haponik EF. Thoracic complications of dental surgical procedures: hazards of the dental drill. *Am J Med* 1993;95:456.
95. Bekiroglu F, Rout PG. Surgical emphysema following dental treatment: two cases. *Dent Update* 1997;24:412.
96. Battrum DE, Gutmann JL. Implications, prevention and management of subcutaneous emphysema during endodontic treatment. *Endod Dent Traumatol* 1995;11:109.
97. Stockdale CR, Chandler NP. The nature of the periapical lesion—a review of 1108 cases. *J Dent* 1988;16:123.
98. McDonald NJ, Hovland ER. Surgical endodontics. In: Walton R, Torabinejad M, editors. *Principles and practice of endodontics*. 2nd ed. Philadelphia: WB Saunders; 1996.
99. Fish EW. Bone infection. *J Am Dent Assoc* 1939;26:691.
100. Barron SL, Gottlieb B, Crook JH. Periapical curettage or apicoectomy. *Texas Dent J* 1947;65:37.
101. Pearson HH. Curette or resect? *J Can Dent Assoc* 1949;14:508.
102. Wakely JW, Simon WJ. Apical curettage or apicoectomy? *Dent Assist* 1977;46:29.
103. Gutmann JL, Pitt Ford TR. Management of the resected root end: a clinical review. *Int Endod J* 1993;26:273.
104. Gutmann JL, Harrison JW. Posterior endodontic surgery: anatomical considerations and clinical techniques. *Int Endod J* 1985;18:8.
105. el-Swiah JM, Walker RT. Reasons for apicectomies: a retrospective study. *Endod Dent Traumatol* 1996;12:185.
106. Ingle JI, Cummings RR, Frank AL, et al. Endodontic surgery. In: Ingle JI, Bakland LK, editors. *Endodontics*. 4th ed. Baltimore: Williams and Wilkins; 1994. p. 723.
107. Nedderman TA, Hartwell GR, Portell FR. A comparison of root surfaces following apical root resection with various burs: scanning electron microscopic evaluation. *J Endod* 1988;14:423.
108. Morgan LA, Marshall JG. The topography of root ends resected with fissure burs and refined with two types of finishing burs. *Oral Surg* 1998;85:585.
109. Ebihara A, Wadachi R, Sekine Y, et al. Application of Er:YAG laser to apicoectomy. 6th International Congress on Lasers in Dentistry; 1998.
110. Komori T, Yokoyama K, Matsumoto Y, Matsumoto K. Erbium:YAG and holmium:YAG laser root resection of extracted human teeth. *J Clin Laser Med Surg* 1997;15:9.
111. Moritz A, Gutknecht N, Goharkhay K, et al. The carbon dioxide laser as an aid in apicoectomy: an in vitro study. *J Clin Laser Med Surg* 1997;15:185.
112. Maillet WA, Torneck CD, Friedman S. Connective tissue response to root surfaces resected with Nd:YAG laser or burs. *Oral Surg* 1996;82:681.
113. Miserendino LJ. The laser apicoectomy: endodontic application of the CO₂ laser for periapical surgery. *Oral Surg* 1988;66:615.
114. Komori T, Yokoyama K, Takato T, Matsumoto K. Clinical application of the erbium:YAG laser for apicoectomy. *J Endod* 1997;23:748.
115. Andreasen JO, Rud J. A histological study of dental and periapical structures after endodontic surgery. *Int J Oral Surg* 1972;1:272.
116. Ichesco WR, Ellison RL, Corcoran JR, Krause DC. A spectrophotometric analysis of dentinal leakage in the resected root [abstract]. *J Endod* 1986;12:129.
117. Beatty R. The effect of reverse filling preparation design on apical leakage [abstract]. *J Dent Res* 1986;65:259.
118. Vertucci RJ, Beatty RG. Apical leakage associated with retrofillings techniques: a dye study. *J Endod* 1986;12:331.
119. Tidmarsh BG, Arrowsmith MG. Dentinal tubules at the root ends of apicected teeth: a scanning electron microscopic study. *Int Endod J* 1989;22:184.
120. Gagliani M, Tusker S, Molinari R. Ultrasonic root-end preparation: influence of cutting angle on the apical seal. *J Endod* 1998;24:726.
121. Hu Young-Yi, Kim S. The resected root surface. *Dent Clin North Am* 1997;41:529.
122. Skidmore AE, Bjornal AM. Root morphology of the human mandibular first molar. *Oral Surg* 1971;33:778.
123. Pineda F, Kuttler Y. Mesiodistal and buccolingual roentgenographic investigation of 7,275 root canals. *Oral Surg* 1972;33:101.
124. Green D. Double canals in single roots. *Oral Surg* 1973;35:698.
125. Cambruzzi JV, Marshall FJ. Molar endodontic surgery. *J Can Dent Assoc* 1983;1:61.
126. Vertucci FJ. Root canal anatomy of the human permanent teeth. *Oral Surg* 1984;58:589.
127. Weller RN, Niemczyk SP, Kim S. Incidence and position of the canal isthmus. Part I. Mesio Buccal root of the maxillary first molar. *J Endod* 1995;21:380.
128. Kim S, Rethnam S. Hemostasis in endodontic microsurgery. *Dent Clin North Am* 1997;41:499.
129. Selden HS. Bone wax as an effective hemostat in periapical surgery. *Oral Surg* 1970;29:262.
130. Ibarrola JL, Bjorenson JE, Austin BP, Gerstein H. Osseous reactions to three hemostatic agents. *J Endod* 1985;11:75.

131. Aurelio J, Chenail B, Gerstein H. Foreign-body reaction to bone wax. *Oral Surg* 1984;58:98.
132. Finn MD, Schow SR, Schneiderman ED. Osseous regeneration in the presence of four hemostatic agents. *J Oral Maxillofac Surg* 1992;50:608.
133. Solheim E, Pinholt EM, Bang G, Sudmann E. Effect of local hemostatics on bone induction in rats: a comparative study of bone wax, fibrin-collagen paste and bioerodible polyorthoester with and without gentamicin. *J Biomed Mater Res* 1992;26:791.
134. Witherspoon DE, Gutmann JL. Haemostasis in periradicular surgery. *Int Endod J* 1996;29:135.
135. Grossman LI. *Endodontic practice*. 7th ed. Philadelphia: Lea & Febiger; 1970.
136. Sommer R, Ostrander R, Crowley M. *Clinical endodontics*. 2nd ed., Philadelphia: WB Saunders; 1962.
137. Besner E. Systemic effects of racemic epinephrine when applied to the bony cavity during periapical surgery. *Va Dent J* 1972;49:9.
138. Pallasch TJ. Vasoconstrictors and the heart. *J Calif Dent Assoc* 1998;26:668.
139. Lemon RR, Steele PJ, Jeansonne BG. Ferric sulfate hemostasis: effect on osseous wound healing left in situ for maximum exposure. *J Endod* 1933;19:170.
140. Jeansonne BG, Boggs WS, Lemon RR. Ferric sulfate hemostasis: effect on osseous wound healing. II. With curettage and irrigation. *J Endod* 1993;19:174.
141. Codben RH, Thrasher EL, Harris WH. Topical hemostatic agents to reduce bleeding from cancellous bone. *J Bone Joint Surg* 1976;58(A):70.
142. Sottosanti J. Calcium sulfate: a biodegradable and biocompatible barrier for guided tissue regeneration. *Compend Contin Educ Dent* 1992;13:226.
143. Pecora G, Adreana S, Margarone JE, et al. Bone regeneration with a calcium sulfate barrier. *Oral Surg* 1997;84:424.
144. Boyes-Varley JG, Cleaton-Jones PE, Lownie JR. Effects of a topical drug combination on the early healing of extraction sockets in the vervet monkey. *Int J Oral Maxillofac Surg* 1988;17:138.
145. Olson RAJ, Roberts DL, Osbon DB. A comparative study of polylactic acid, Gelfoam, and Surgicel in healing extraction sites. *Oral Surg* 1982;53:441.
146. Caen JP, Legrand Y, Sultan Y. Platelets: collagen interactions. *Thromb Haemost* 1970;40:181.
147. Mason RG, Read MS. Some effects of microcrystalline collagen preparations on blood. *Haemostasis* 1974;3:31.
148. Mattsson T, Anneroth G, Kondell PA, Nordenram A. ACP and Surgicel in bone hemostasis. *Swed Dent J* 1990;14:57.
149. Swan N. Textured collagen, a hemostatic agent. *Oral Surg* 1991;72:642.
150. Mason R. Hemostatic mechanisms of microfibrillar collagen. In: *Proceedings of a symposium on Avitene (Microfibrillar Collagen Hemostat)*. Ft Worth (TX): Alcon Laboratories; 1975. p. 32.
151. Kramer GM, Pollack R. Clinical application and histological evaluation of microfibrillar collagen hemostat (Avitene) in periodontal surgery. *Int J Periodontics Restorative Dent* 1982;2:8.
152. Baumhammers A. Control of excessive bleeding following periodontal surgery. *Gen Dent* 1983;31:384.
153. Haasch GC, Gerstein H, Austin BP. Effect of two hemostatic agents on osseous healing. *J Endod* 1989;15:310.
154. Finn MD, Schow SR, Schneiderman ED. Osseous regeneration in the presence of four common hemostatic agents. *J Oral Maxillofac Surg* 1992;50:608.
155. Takeuchi H, Konaga E, Kashitani M. The usefulness of Avitene for the control of oozing in laparoscopic cholecystectomy. *Surg Gynecol Obstet* 1993;176:495.
156. Johnson and Johnson. *Surgicel product information*. New Brunswick, NJ: 1989.
157. Tanzilli JP, Raphael D, Moodnik RM. A comparison of the marginal adaptation of retrograde techniques: a scanning electron microscope study. *Oral Surg* 1980;50:74.
158. Nedderman TA, Hartwell GR, Portell FR. A comparison of root surfaces following apical root resection with various burs: scanning electron microscopic evaluation. *J Endod* 1988;14:423.
159. Richman MJ. The use of ultrasonics in root canal therapy and root resection. *J Dent Med* 1957;12:12.
160. Bertrand G, Festal F, Barailly R. Use of ultrasound in apicoectomy. *Quintessence Int* 1976;7:9.
161. Wuchenich G, Meadows D, Torabinejad M. A comparison between two root-end preparation techniques in human cadavers. *J Endod* 1994;20:279.
162. Gutmann JL, Saunders WP, Nguyen L, et al. Ultrasonic root-end preparation. Part 1. SEM analysis. *Int Endod J* 1994;27:318.
163. Abedi HR, Van Mierlo BL, Wilder-Smith P, Torabinejad M. Effects of ultrasonic root-end cavity preparation on the root apex. *Oral Surg* 1995;80:207.
164. Min MM, Brown CE Jr, Legan JJ, Kafrawy AH. In vitro evaluation of the effects of ultrasonic root-end preparation on resected root surfaces. *J Endod* 1997;23:624.
165. Beling KL, Marshall JG, Morgan LA, Baumgartner JC. Evaluation of cracks associated with ultrasonic root-end preparation of gutta-percha filled canals. *J Endod* 1997;23: May.
166. Waplington M, Lumley P, Walmsley AD. Incidence of root face alteration after ultrasonic retrograde cavity preparation. *Oral Surg* 1997;83:387.
167. Layton CA, Marshall JG, Morgan LA, Baumgartner JC. Evaluation of cracks associated with ultrasonic root-end preparation. *J Endod* 1996;22:157.
168. Calzonetti KJ, Iwanowski T, Komorowski R, Friedman S. Ultrasonic root-end cavity preparation assessed by an in situ impression technique. *Oral Surg* 1998;85:210.
169. Morgan LA, Marshall JG. A scanning electron microscopic study of in vivo ultrasonic root-end preparations. *J Endod* 1999;25:567.
170. Sumi Y, Hattori H, Hayashi K, Ueda M. Ultrasonic root-end preparation: clinical and radiographic results. *J Oral Maxillofac Surg* 1996;54:590.
171. Gartner AH, Dorn SO. Advances in endodontic surgery. *Dent Clin North Am* 1992;36:357.
172. Jou YT, Pertl C. Is there a best retrograde filling material. *Dent Clin North Am* 1997;41:555.
173. Owadally ID, Chong BS, Pitt Ford TR, Wilson RF. Biological properties of IRM with the addition of hydroxyapatite as a retrograde root filling material. *Endod Dent Traumatol* 1994;10:228.
174. Makkawy HM, Koka S, Lavin MT, Ewoldsen NO. Cytotoxicity of root perforation materials. *J Endod* 1998;24:477.
175. Chong BS, Owadally ID, Pitt Ford TR, Wilson RF. Cytotoxicity of potential retrograde root-filling materials. *Endod Dent Traumatol* 1994;10:129.

176. Zhu Q, Safavi E, Spangberg LSW. Cytotoxic evaluation of root-end filling materials in cultures of human osteoblast-like cells and periodontal ligament cells. *J Endod* 1999;25:410.
177. Harrison JW, Johnson SA. Excisional wound healing following the use of IRM as a root-end filling material. *J Endod* 1997;23:19.
178. Pitt Ford TR, Andreasen JO, Dorn SO, Kariyawasam SP. Effect of IRM root-end fillings on healing after replantation. *J Endod* 1994;20:381.
179. Pitt Ford TR, Andreasen JO, Dorn SO, Kariyawasam SP. Effect of Super-EBA as a root-end filling on healing after replantation. *J Endod* 1995;21:13.
180. Maeda H, Hashiguchi I, Nakamuta H, et al. Histological study of periapical tissue healing in the rat molar after retrofillings with various materials. *J Endod* 1999;25:38.
181. Torabinejad M, Pitt Ford TR, Abedi HR, et al. Tissue reaction to implanted root-end filling materials. *J Endod* 1998;24:468.
182. Torabinejad M, Hong CU, McDonald F, Pitt Ford T. Physical and chemical properties of a new root-end filling material. *J Endod* 1995;21:349.
183. Torabinejad M, Watson TF, Pitt Ford TR. Sealing ability of a mineral trioxide aggregate when used as a root-end filling material. *J Endod* 1993;19:591.
184. Torabinejad M, Higa RK, McKendry DJ, Pitt Ford TR. Dye leakage of four root-end filling materials: effects of blood contamination. *J Endod* 1994;20:159.
185. Bates CF, Carnes DL, del Rio CE. Longitudinal sealing ability of mineral trioxide aggregate as a root-end filling material. *J Endod* 1996;22:575.
186. Fischer EJ, Arens DE, Miller CH. Bacterial leakage of mineral trioxide aggregate as compared with zinc-free amalgam, intermediate restorative material, and Super-EBA as a root-end filling material. *J Endod* 1998;24:176.
187. Torabinejad M, Rastegar AF, Kettering JD, Pitt Ford TR. Bacterial leakage of mineral trioxide aggregate as a root-end filling material. *J Endod* 1995;21:109.
188. Torabinejad M, Smith PW, Kettering JD, Pitt Ford TR. Comparative investigation of marginal adaptation of mineral trioxide aggregate and other commonly used root-end filling materials. *J Endod* 1995;21:295.
189. Koh ET, McDonald R, Pitt Ford TR, Torabinejad M. Cellular response to mineral trioxide aggregate. *J Endod* 1998;24.
190. Torabinejad M, Hong CU, Pitt Ford TR, Kettering JD. Cytotoxicity of four root end filling material. *J Endod* 1995;21:489.
191. Kettering JD, Torabinejad M. Investigation of mutagenicity of mineral trioxide aggregate and other commonly used root end filling materials. *J Endod* 1995;21:537.
192. Torabinejad M, Hong CU, Pitt Ford TR. Tissue reaction to implanted Super-EBA and mineral trioxide aggregate in the mandibles of guinea pigs: a preliminary report. *J Endod* 1995;21:569.
193. Torabinejad M, Hong CU, Lee SJ, et al. Investigation of mineral trioxide aggregate for root end filling in dogs. *J Endod* 1995;21:603.
194. Torabinejad M, Pitt Ford TR, McKendry DJ, et al. Histologic assessment of mineral trioxide aggregate as a root-end filling in monkeys. *J Endod* 1997;23:225.
195. Oynick J, Oynick T. A study of a new material for retrograde fillings. *J Endod* 1978;4:203.
196. Dorn SO, Gartner AH. Retrograde filling materials: a retrospective success-failure study of amalgam, EBA, and IRM. *J Endod* 1990;16:391.
197. Pantschev A, Carlsson AP, Andersson L. Retrograde root filling with EBA cement or amalgam. A comparative clinical study. *Oral Surg* 1994;78:101.
198. Rud J, Munksgaard EC, Andreasen JO, et al. Retrograde root fillings with composite and a dentin-bonding agent. *Endod Dent Traumatol* 1991;7(Pt 1):118.
199. Rud J, Munksgaard EC, Andreasen JO, Rud V. Retrograde root fillings with composite and a dentin-bonding agent. *Endod Dent Traumatol* 1991;7:126.
200. Rud J, Rud V, Munksgaard EC. Long-term evaluation of retrograde root fillings with dentin-bonded resin composite. *J Endod* 1996;22:90.
201. Rud J, Rud V, Munksgaard EC. Retrograde root filling with dentin-bonded modified resin composite. *J Endod* 1996;22:477.
202. Rud J, Rud V, Munksgaard EC. Effect of root canal contents on healing of teeth with dentin-bonded resin composite retrograde seal. *J Endod* 1997;23:535.
203. Michelich VJ, Schuster GS, Pashley DH. Bacterial penetration of human dentin in-vivo. *J Dent Res* 1980;59:1398.
204. Barkhordar RA, Watanabe LG, Marshall GW, Hussain MZ. Removal of intracanal smear layer by Doxycycline in vitro. *Oral Surg* 1997;84:420.
205. Craig KR, Harrison JW. Wound healing following demineralization of resected root ends in periradicular surgery. *J Endod* 1993;19:339.
206. Rifkin BR, Vernillo AT, Golub LM. Blocking periodontal disease progression by inhibiting tissue-destructive enzymes: a potential therapeutic role for tetracyclines and their chemically-modified analogs. *J Periodontol* 1993;64:819.
207. Aleo JJ, De Renzis FA, Farbet PA. In vitro attachment of human fibroblasts to root surfaces. *J Periodontol* 1975;46:639.
208. Minabe M, Takeuchi K, Kumada H, Umemoto T. The effect of root conditioning with minocycline HCl in removing endotoxin from the roots of periodontally involved teeth. *J Periodontol* 1994;65:387.
209. Barkhordar RA, Russel T. Effect of Doxycycline on the apical seal of retrograde filling materials. *J Calif Dent Assoc* 1998.
210. Fitzpatrick EL, Steiman HR. Scanning electron microscopic evaluation of finishing techniques on IRM and EBA retrofillings. *J Endod* 1997;23:423.
211. Forte SG, Hauser MJ, Hahn C, Hartwell GR. Microleakage of Super-EBA with and without finishing as determined by the fluid filtration method. *J Endod* 1998;24: 799.
212. Eriksson L. Cyanoacrylate for closure of wounds in the oral mucosa in dogs. *Odontol Revy* 1976;27:19.
213. Javelet J, Torabinejad M, Danforth R. Isobutyl cyanoacrylate: a clinical and histological comparison with sutures in closing mucosal incisions in monkeys. *Oral Surg* 1985;59:91.
214. Vanholder R, Misotten A, Roels H, Matton G. Cyanoacrylate tissue adhesive for closing skin wounds: a double blind randomized comparison with sutures. *Biomaterials* 1993;14:737.
215. Simon HK, McLario KJ, Bruns TB, et al. Long-term appearance of lacerations repaired using a tissue adhesive. *Pediatrics* 1997;99:193.
216. Samuel PR, Roberts AC, Nigam A. The use of Indermil (n-butyl cyanoacrylate) in otorhinolaryngology and head and neck surgery. A preliminary report on the first 33 patients. *J Laryngol Otol* 1997;111:536.

217. Giray CB, Atasever A, Durgun B, Araz K. Clinical and electron microscopic comparison of silk sutures and n-butyl-2-cyanoacrylate in human mucosa. *Aust Dent J* 1997;42:255.
218. Grisdale J. The use of cyanoacrylate in periodontal therapy. *J Can Dent Assoc* 1998;64:632.
219. Lilly GE, Armstrong JH, Salem JE, Cutcher JL. Reaction of oral tissues to suture materials. *Oral Surg* 1968;26(Pt 2):592.
220. Lilly GE, Armstrong JH, Cutcher JL. Reaction of oral tissues to suture materials. *Oral Surg* 26(Pt 3):432.
221. Lilly GE, Cutcher JL, Nones TC, Armstrong JH. Reaction of oral tissues to suture materials. *Oral Surg* 1972;33:152.
222. Ebert JR. Method for scanning electron microscopic study of plaque on periodontal suture material. *J Dent Res* 1974;53:1298.
223. Rakusin H, Harrison JW, Marker VA. Alteration of the manipulative properties of plain gut suture material by hydration. *J Endod* 1988;14:121.
224. Craig PH, Williams JA, Davis KW. A biologic comparison of polyglactin 910 and polyglycolic acid synthetic sutures. *Surg Gynecol Obstet* 1975;141:1.
225. Nelson EH, Junakoshi E, O'Leary TJ. A comparison of the continuous and interrupted suturing technique. *J Periodontol* 1977;48:273.
226. Ramfjord SP, Nissle RR. The modified Widman flap. *J Periodontol* 1974;45:601.
227. Alexander RE. Patient understanding of postsurgical instruction forms. *Oral Surg* 1999;87:153.
228. Guyton AC. *Textbook of medical physiology*. 7th ed. St Louis (MO): Mosby; 1986. p. 860.
229. Seymour RA, Meedhan JG, Blair GS. Postoperative pain after apicoectomy. *Int Endod J* 1986;19:242.
230. Davis W, Oakley J, Smith E. Comparison of the effectiveness of etidocaine and lidocaine as local anesthetic agents during oral surgery. *Anesth Prog* 1984;31:159.
231. Dunsky J, Moore P. Long-acting local anesthetics: a comparison of bupivacaine and etidocaine in endodontics. *J Endod* 1984;10:6.
232. Weisman MI. Comfortable suture removal. *J Endod* 1981;7:186.
233. Anson D. Calcium sulfate: a 4-year observation of its use as a resorbable barrier in guided tissue regeneration of periodontal defects. *Compend Contin Educ Dent* 1996;17:895.
234. Pecora G, Baek SH, Rethman S, Kim S. Barrier membrane techniques in endodontic microsurgery. *Dent Clin North Am* 1997;41:585.
235. Bier SJ, Sininsky MC. The versatility of calcium sulfate: resolving periodontal challenges. *Compend Contin Educ Dent* 1999;20:655.
236. Kellert M, Chalfin H, Solomon C. Guided tissue regeneration: an adjunct to endodontic surgery. *J Am Dent Assoc* 1994;125:1229.
237. Uchin RA. Use of a bioresorbable guided tissue membranes as an adjunct to bony regeneration in cases requiring endodontic surgical intervention. *J Endod* 1996;22:94.
238. Tseng CC, Harn WM, Chen YH, et al. A new approach to the treatment of true-combined endodontic-periodontic lesions by the guided tissue regeneration technique. *J Endod* 1996;22:693.
239. Santamaria J, Garcia AM, de Vincente JC, et al. Bone regeneration after radicular cyst removal with and without guided bone regeneration. *Int J Oral Maxillofac Surg* 1998;27:118.
240. Pecora G, Kim S, Celletti R, Davarpanah M. The guided tissue regeneration principle in endodontic surgery: one-year postoperative results of large periapical lesions. *Int Endod J* 1995;28:41.
241. Kirchoff DA, Gerstein H. Presurgical crown contouring for root amputation procedures. *Oral Surg* 1969;27:379.
242. Bergenholtz A. Radectomy of multirrooted teeth. *J Am Dent Assoc* 1972;85:870.
243. Klanan B. Clinical observations following root amputation in maxillary molar teeth. *J Periodontol* 1975;46:1.
244. Hamp SE, Nyman S, Lindhe J. Periodontal treatment of multirrooted teeth. Results after 5 years. *J Clin Periodontol* 1975;2:126.
245. Langer B, Stein SD, Wagenberg B. An evaluation of root resections. A ten-year study. *J Periodontol* 1981;52:719.
246. Erpenstein H. A 3-year study of hemisected molars. *J Clin Periodontol* 1983;10:1.
247. Buhler H. Evaluation of root-resected teeth. Results after 10 years. *J Periodontol* 1988;59:805.
248. Carnevale G, Febo GD, Tonelli MP, et al. A retrospective analysis of the periodontal-prosthetic treatment of molars with interraderic lesions. *Int J Periodontics Restorative Dent* 1991;11:189.
249. Basten CHJ, Ammons WF Jr, Persson R. Long-term evaluation of root-resected molars. A retrospective study. *Int J Periodontics Restorative Dent* 1996;16:207.
250. Blomlof L, Jansson L, Appelgren R, et al. Prognosis and mortality of root-resected molars. *Int J Periodontics Restorative Dent* 1997;17:191.
251. Carnevale G, Pontoriero R, di Fego G. Long-term effects of root-resective therapy in furcation-involved molars. A 10-year longitudinal study. *J Clin Periodontol* 1998;25:209.
252. Pecora JD, et al. In vitro study of the incidence of radicular grooves in maxillary incisors. *Braz Dent J* 1991;2:69.
253. Goon WWY, et al. Complex facial radicular groove in a maxillary lateral incisor. *J Endod* 1991;17:244.
254. Robinson SF, Cooley RL. Palatogingival groove lesions: recognition and treatment. *Gen Dent* 1988;36:340.
255. Grossman L. Intentional replantation of teeth. *J Am Dent Assoc* 1982;104:633.
256. Weinberger B. Introduction to the history of dentistry. Vol. 1. St. Louis (MO): Mosby; 1948. p. 105.
257. Fauchard P. *Le Chirurgien Dentiste Ou Traite des Dents*. Paris: Chez Pierre-Jean Mariette; 1746. p. 375.
258. Berdmore T. *A treatise on the disorders and deformities of the teeth and gums*. London: White, Dodsley, Beckett, and deHondt; 1768. p. 96.
259. Hammer H. Replantation and implantation of teeth. *Int Dent J* 1955;5:439.
260. Deeb E, Prietto P, McKenna R. Reimplantation of luxated teeth in humans. *J South Calif State Dent Assoc* 1965;33:194.
261. Grossman L, Chacker F. Clinical evaluation and histologic study of intentionally replanted teeth. In: Grossman L, editor. *Transactions of the Fourth International Conference on Endodontics*. Philadelphia: University of Pennsylvania; 1968. p. 127.
262. Dryden JA, Arens DE. Intentional replantation: A viable alternative for selected cases. *Dent Clin North Am* 1994;38:325.
263. Kingsbury B, Weisenbaugh J. Intentional replantation of mandibular premolars and molars. *J Am Dent Assoc* 1971;83:1053.

264. Koenig K, Nguyen N, Barkholder. Intentional replantation: a report of 192 cases. *Gen Dent* 1988;36:327.
265. Bender IB, Rossman LE. Intentional replantation of endodontically treated teeth. *Oral Surg* 1993;76:623.
266. Raghoebar GM, Vissink A. Results of intentional replantation of molars. *J Oral Maxillofac Surg* 1999;57:240.
267. Kratchman S. Intentional replantation. *Dent Clin North Am* 1997;41:603.
268. Nosonowitz D, Stanley H. Intentional replantation to prevent predictable endodontic failures. *Oral Surg* 1984;57:423.
269. Jansen CE. Implant procedures 101. *J Calif Dent Assoc* 2000;28:277.
270. Weine FS, Frank AL. Survival of the endodontic endosseous implant. *J Endod* 1993;19:524.
271. Orlay JG. Endodontic splinting treatment in periodontal disease. *Br Dent J* 1960;108:118.
272. Frank AL. Improvement in the crown:root ratio by endodontic endosseous implants. *J Am Dent Assoc* 1967;74:451.
273. Frank AL. Endodontic endosseous implants and treatment of the wide-open apex. *Dent Clin North Am* 1967;Nov:675.
274. Frank AL, Abrams AM. Histologic evaluation of endodontic implants. *J Am Dent Assoc* 1969;78:520.
275. Branemark PI, Zarb GA, Albrektsson T. *Tissue-integrated prosthesis*. Chicago: Quintessence Publishing; 1985. p. 11.
276. Brunski JB, Moccaia FF, et al. The influence of functional use of endosseous dental implants on the tissue-implant interface. I. Histological aspects. *J Dent Res* 1979;58:1953.
277. Mombelli A, Van Ossten MAC, et al. The microbiota associated with successful or failing osseointegrated titanium implants. *Oral Microbiol Immunonol* 1987;2:145.
278. Gelb DA. Immediate implant surgery: ten-year clinical overview. *Compend Contin Educ Dent* 1999;20:1185.
279. Rosenquist B, Grenthe B, et al. Immediate placement of implants into extraction sockets. *Int J Oral Maxillofac Implants* 1996;11:205.
280. Buchanan LS. The art of endodontics: a rationale for treatment. *DentToday* 1993;12:30.
281. Carr GB. Advanced techniques and visual enhancement for endodontic surgery. *Endod Rep* 1992;7:6.
282. Carr GB. Microscopes in endodontics. *Calif Dent Assoc J* 1992;20:55.
283. Rubinstein R. Horizons in endodontic surgery. Part I: The operating microscope. *Oak County (MI) Review* 1991;30:7.
284. Rubinstein R. Horizons in endodontic surgery. Part II: The operating microscope. *Oak County (MI) Review* 1992;30:9.
285. Pecora G, Andreana S. Use of dental operating microscope in endodontic surgery. *Oral Surg* 1993;75:751.
286. Ruddle CJ. Surgical endodontic retreatment. *Calif Dent Assoc J* 1991;19:61.
287. Selden HS. The role of the dental operating microscope in endodontics. *Pa Dent J* 1986;55:36.
288. Bellizzi R, Loushine R. Adjuncts to posterior endodontic surgery. *J Endod* 1990;16:604.
289. Reuben HL, Apotheke H. Apical surgery with the dental microscope. *Oral Surg* 1984;57:433.
290. Rubinstein R. Endodontic microsurgery and the surgical operating microscope. *Compend Contin Educ Dent* 1997;18:659.
291. Rubinstein RA, Kim S. Short-term observation of the results of endodontic surgery with the use of a surgical operating microscope and Super-EBA as root-end filling material. *J Endod* 1999;25:43.

