

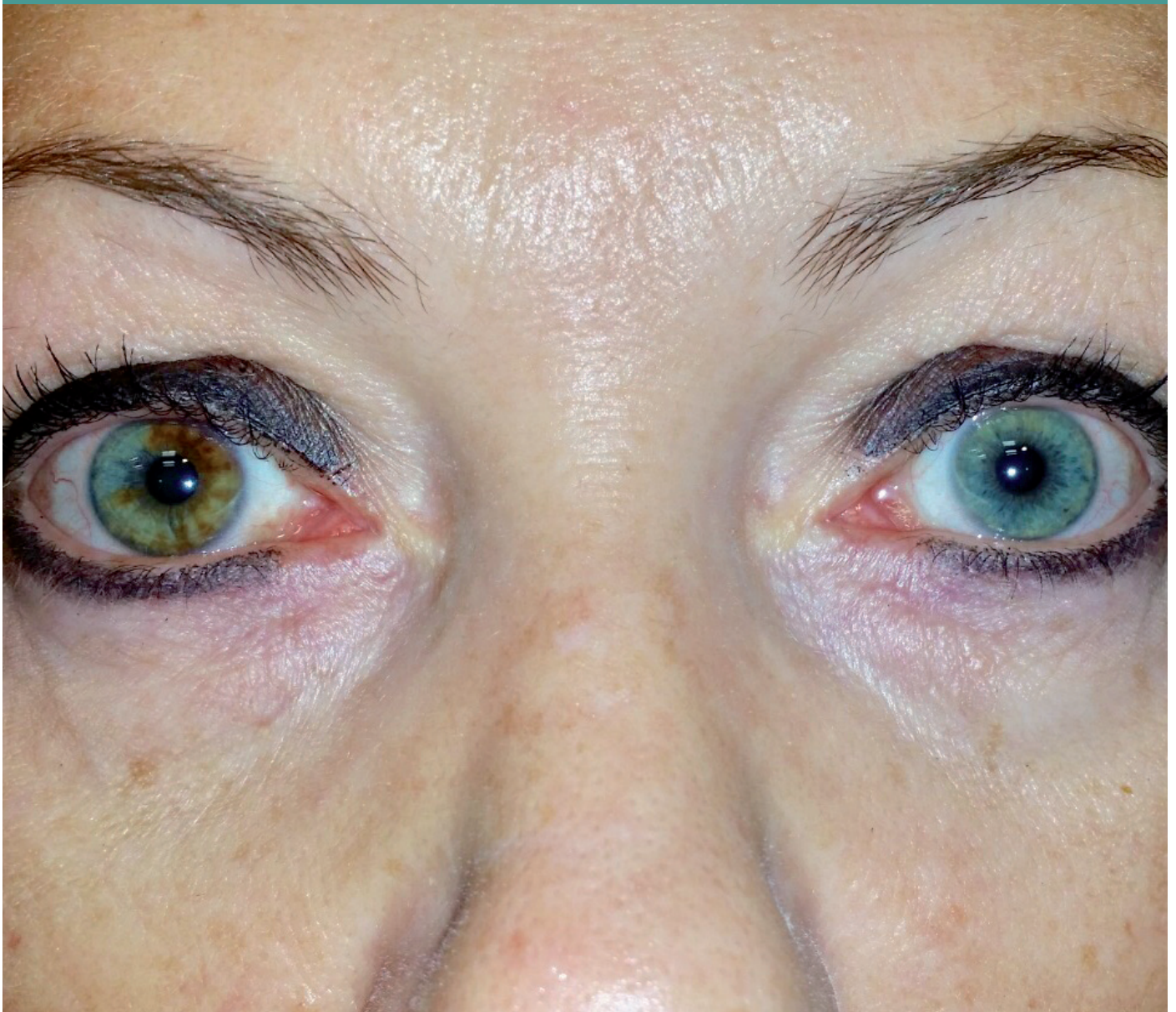

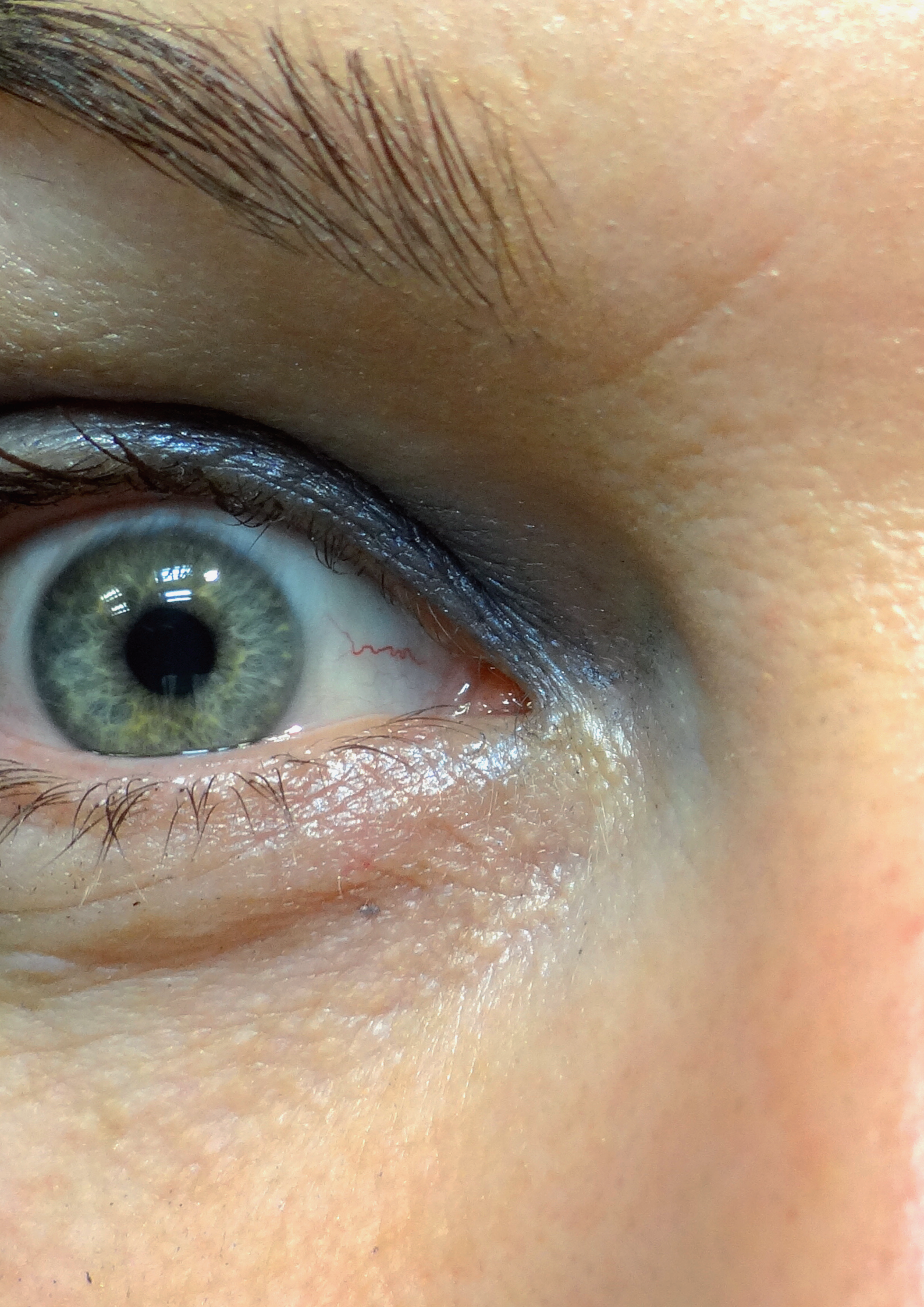
CORPORATION
EUROPA - AMÉRICA

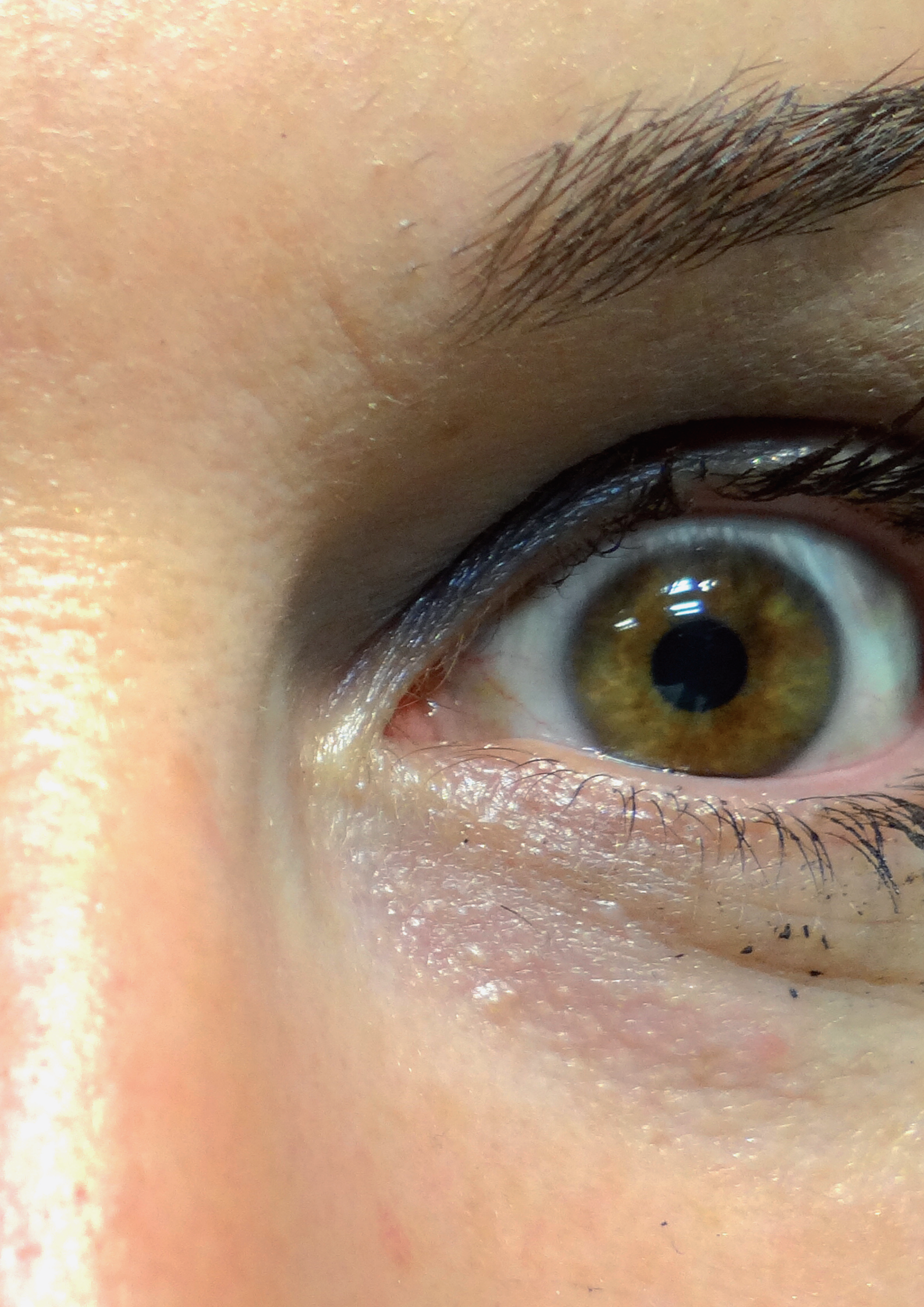NEW
EYES
LASER
BY EYECOS

HETEROCHROMIA

Laser Iridoplasty

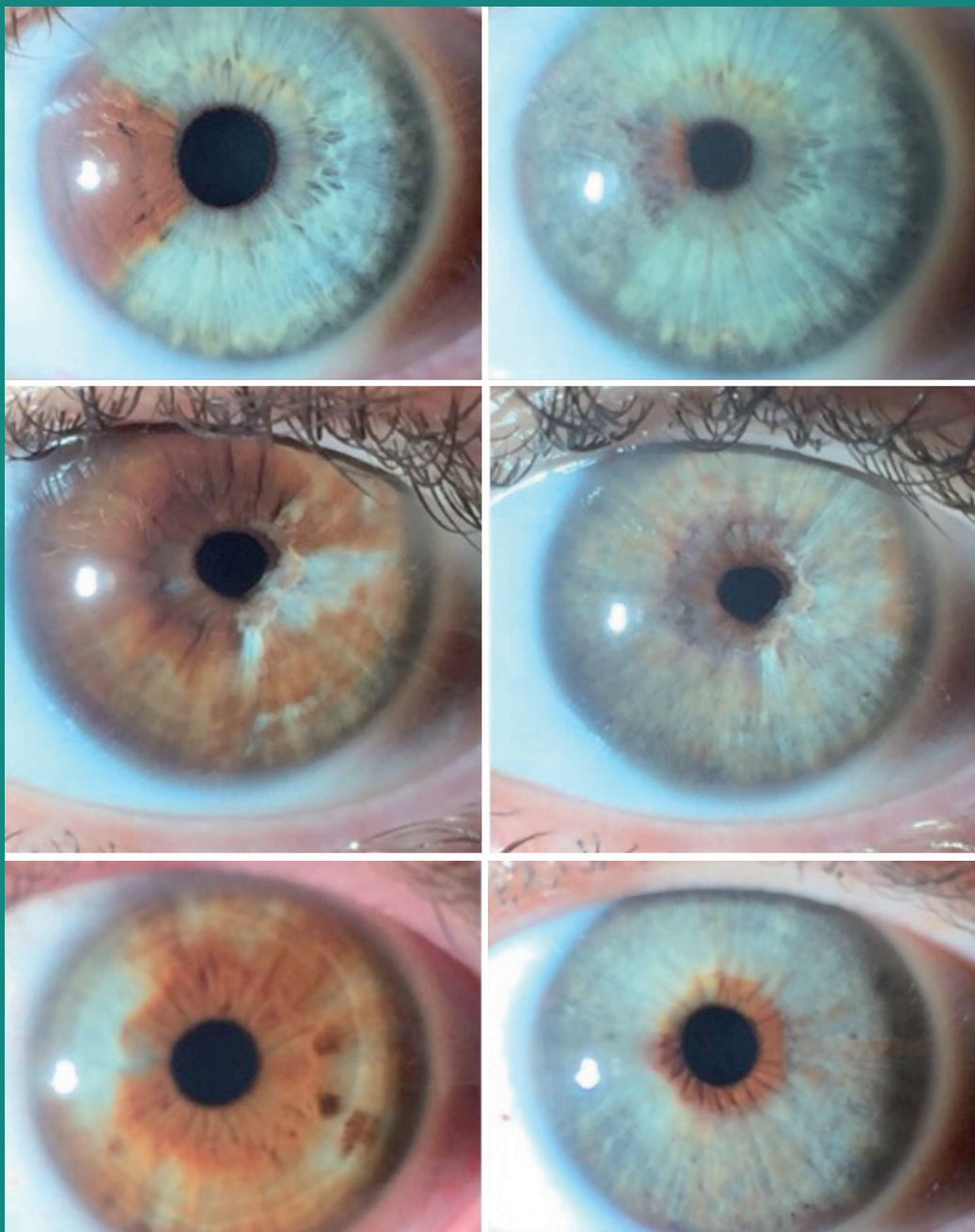






heterochromia - laser iridoplasty

SUMMARY



Introduction.....	06
Material and Methods.....	10
Histological and anatomopathological studies.....	11
Phenotype and genotype studies.....	17
Pharmacological studies.....	21
Technique: Laser cosmetic iridoplasty.....	24
Clinical definition.....	25
Technical definition.....	25
IRÎZ Laser Workstation = Apps + Iris Scanner + Neweyes Laser Mobile apps.....	26
IRÎZ Software Summary.....	32
Iris Scanner with OCT and HD photography.....	34
New laser versions 3G, 4G, 5G.....	36
Planner Program.....	38
Rigid admission criteria:.....	40
General.....	41
Ocular.....	41
Clinical Cases.....	42
A case of partial unilateral congenital heterochromia or Iridis.....	48
A case of a large unilateral congenital single nevus.....	52
A case of bilateral congenital multiple nevus.....	56
Two cases of unilateral heterochromia secondary to complicated cataract surgery...	59
A secondary case to the abuse of aesthetic prostaglandins.....	64
References.....	68

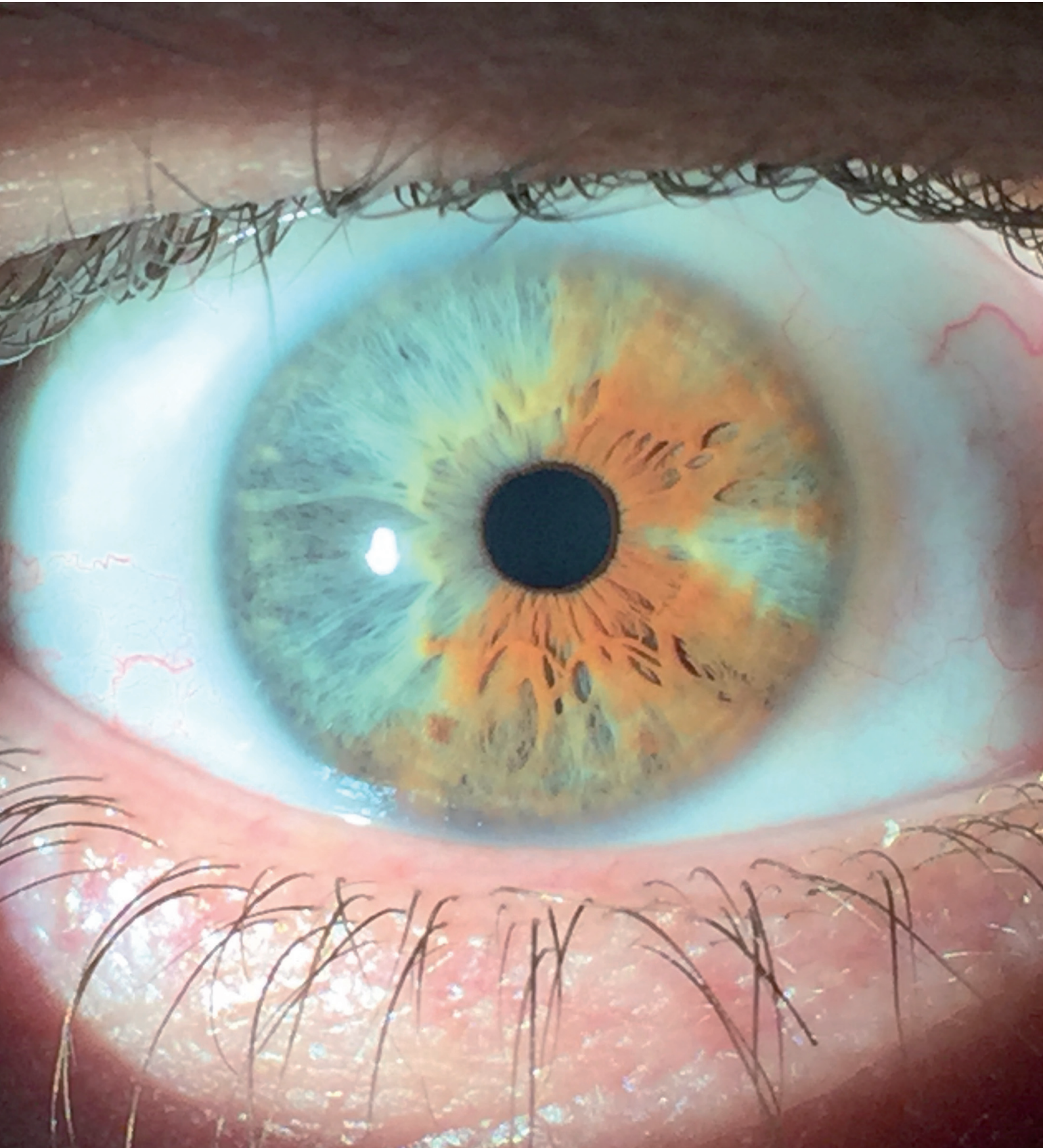
PEDRO GRIMALDOS, MD

- Bachelor of Medicine and Surgery at University of Valencia School of Medicine 1979-1985
- Outstanding Doctoral Thesis
- Specialist in Ophthalmology at Clinical Hospital of the University of Valencia 1985-1990
- Doctoral Thesis Cum Laude
- Stay at Bascom Palmer Eye Institute of University of Florida
- Stay at the Doheny Eye Institute of the University of Southern California
- Organization of numerous Eye Surgery Meetings
- Presentation of numerous clinical research studies
- Invention of Presbylaser to correct Presbyopia by laser (2000)
- Invention of Cosmetic Laser Iridoplasty – Laser Neweyes (2012)
- Development of laser devices, diagnostics tools, applications and ophthalmology software
- Development of the Neweyes Laser Workstation with Apps, Scanner, Analyzer, Planner and 5G Laser
- Currently developing numerous R & D projects



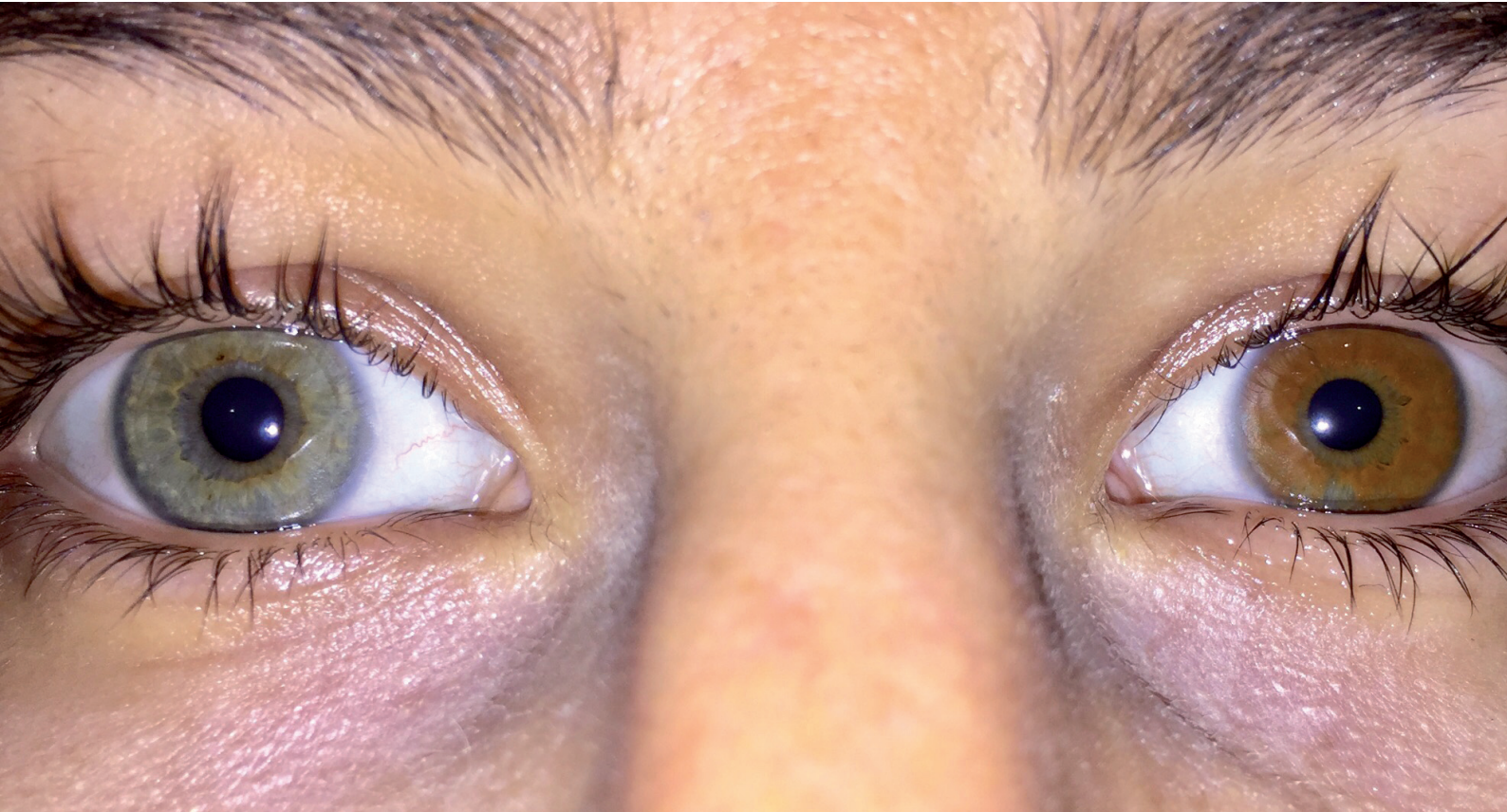
heterochromia - laser iridoplasty

INTRODUCTION



WHAT DEFINES THE COLOR OF THE IRIS?

In a normal healthy eye, the color of the iris is defined by genetic inheritance. In children, initially the color is gray or light blue and it is between 6 and 10 months of age when the final color is fixed. This will depend on the amount and color of the melanocytes (cells that contain the pigment melanin). In this way, if the melanocytes are concentrated on the posterior surface of the iris, the eye will be blue, while if it is distributed throughout the thickness of the iris, the eye will be brown.



TYPES OF IRIS HETEROCHROMIA

Specifically, different types of heterochromia are established in the iris, since it can be both total and partial. Iridium or complete heterochromia. So it is called when the iris of the eyes differ from each other. Iridis or partial heterochromia. The person has two different tonalities within the iris of the same eye. The latter case is much more frequent in humans.

MOMENT OF APPEARANCE

If it appears from the moment the eye acquires its final coloration we are talking about congenital heterochromia and may be of genetic origin or be associated with other diseases such as neurofibromatosis. It can also appear throughout life as a result of injuries or other underlying diseases. In these cases it is known as acquired heterochromia.



CAUSES FOR HETEROCHROMIA

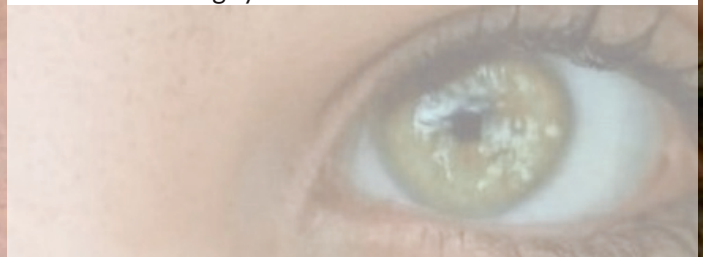
The causes that originate these situations can be very diverse, although in most of the occasions it is an essential disorder, that is, the patient is born therewith and it is not important since it does not suppose any alteration of the vision. In these cases the difference in color between the two eyes or inside one eye does not progress and the ocular function is normal, being something purely anecdotal. However, in cases of acquired heterochromia, if there are changes in coloration previously not present or abnormal ocular function, it is necessary to visit the ophthalmologist to assess a possible underlying disease.

ACQUIRED FACTORS THAT CAN CAUSE HETEROCHROMIA



Siderosis or Hemosiderosis. These are deposits of iron on the iris that alter their normal color. It usually occurs as a result of trauma or eye surgery.

- Fuch heterochromatic cyclitis. It is an inflammation of the anterior chamber of the eye and is one of the causes that most frequently causes of iris heterochromia.
- Glaucoma or certain medications for treatment. The same pathology and even a large number of eye drops among which some are found to treat glaucoma can alter the color of the iris.
- Melanomas. Ocular tumors as a result of the proliferation of cells responsible for synthesizing melanin.
- Ocular inflammation (Uveitis).
- Neurofibromatosis.
- Waardenburg syndrome.



Ocular cosmetic alterations have been treated conservatively so far with contact lenses and aesthetic prostheses, and through different types of surgical interventions. Deformities, irregularities, defects (colobomas) or total absences of the iris (aniridia) have been treated with intraocular implants (Ophtec, Morcher or Dr Schmidt). In order to solve the cases of congenital or acquired tattoos of the cornea, contact lenses and prostheses or surgical keratopigmentation have been used. Regarding pigmentary disorders of the iris, such as heterochromias, uni or bilateral, partial or complete, and nevus, single or multiple, there has been no safe and effective permanent solution other than cosmetic contact lenses. Given that the safety and effectiveness of contact lenses is very high, any surgical solution that puts visual health at risk should be evaluated with great care. Up to now, the surgical techniques proposed to treat iridian pigmentary problems have been mainly two: the cosmetic intraocular lenses (Newiris, Brightocular) and (Neoris, Corneal Eye Tattoo). According to our point of view these two techniques should not be indicated for safety reasons and aesthetic results. Regarding intraocular lenses, they provoke a clear conflict of space in the anterior chamber, which causes glaucoma, uveitis and irreversible endothelial damage [1-10]. Due to these serious complications, implants must be removed after a few months [11-13]. In relation to surgical keratopigmentation, cases of corneal complications have also been described, but cosmetic problems are more evident. The biological dye introduced into the cornea progressively disappears by diffusion over time, so the color fades, and on the other hand, the best result obtained never improves the result of cosmetic contact lenses, so its realization is meaningless. In both cases, the effect is always artificial, "robot eye", with fixed pupils that do not react to light, synthetic and weird colors, and functional limitations of the visual field, together with photophobia and glare.

HISTORY OF TREATMENT OF IRIS HETEROCHROMIA

heterochromia - laser iridoplasty

MATERIAL AND METHODS



HISTOLOGICAL AND ANATOMOPATHOLOGICAL STUDIES

We performed a series of studies with specialized anatomopathologists of corpse eyes with different degrees of pigmentation. The main conclusions we reached were the following (Figures 1, 2 & 3):

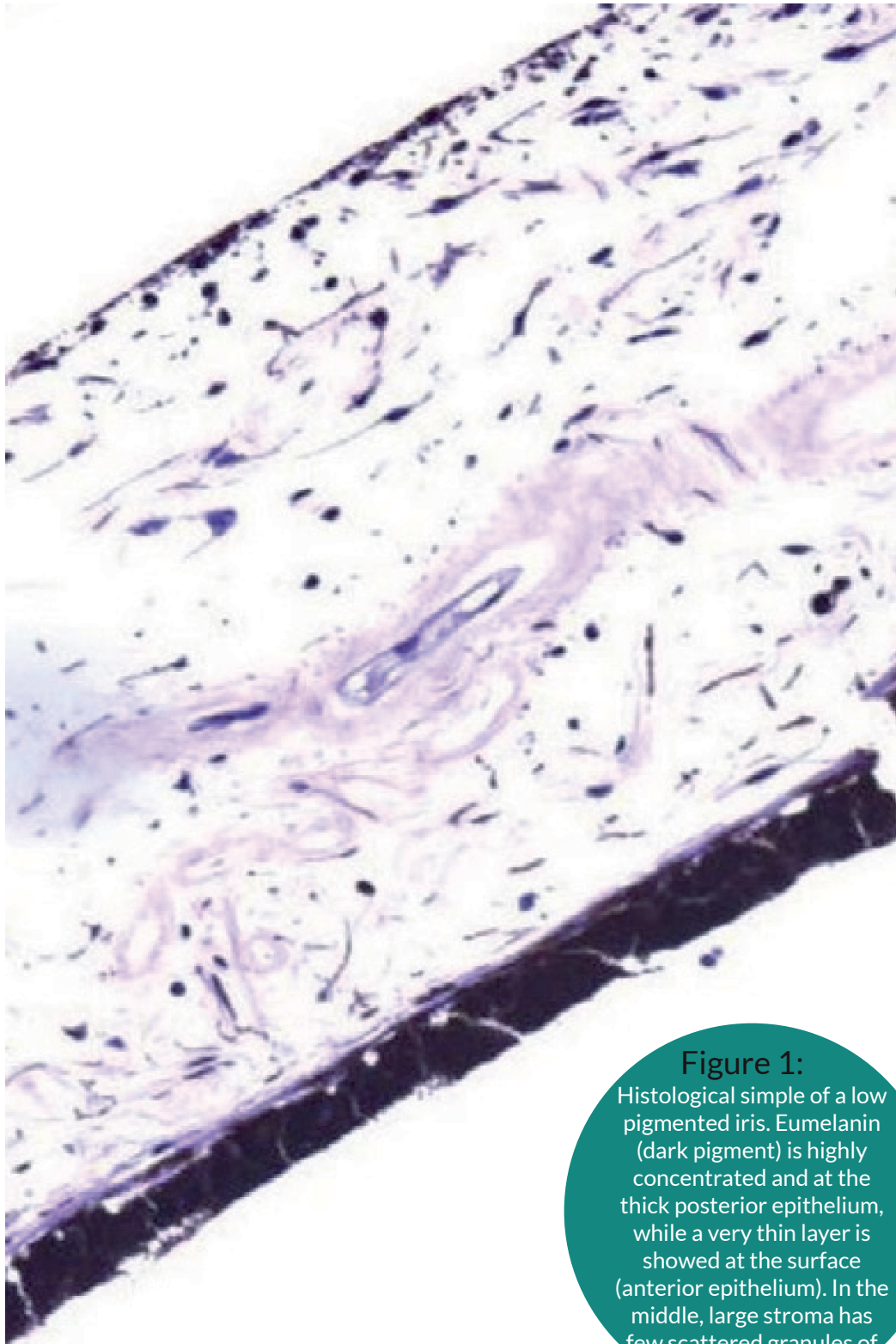
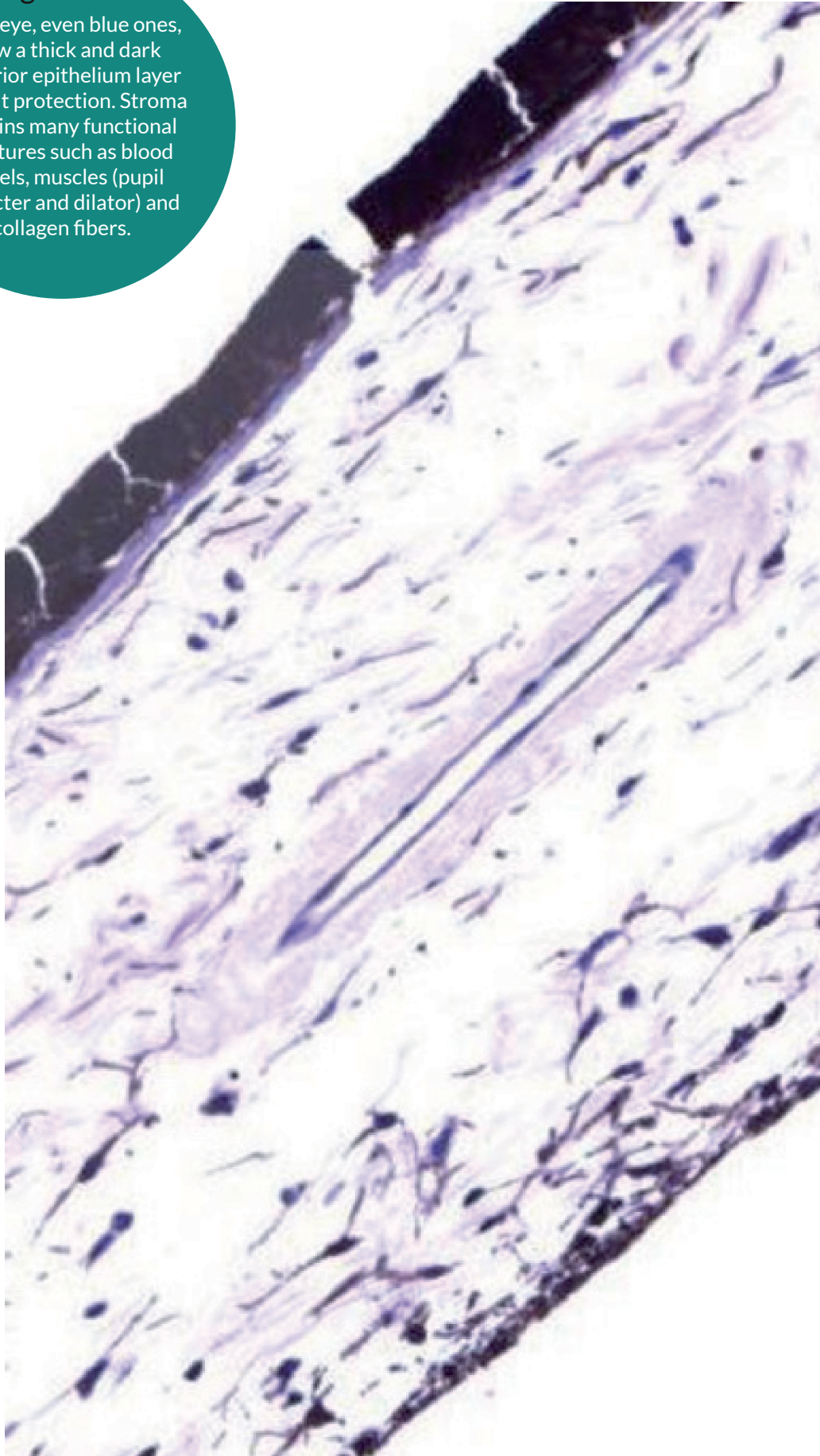


Figure 1:

Histological simple of a low pigmented iris. Eumelanin (dark pigment) is highly concentrated and at the thick posterior epithelium, while a very thin layer is showed at the surface (anterior epithelium). In the middle, large stroma has few scattered granules of melanin.

Figure 2:

Every eye, even blue ones, show a thick and dark posterior epithelium layer for light protection. Stroma contains many functional structures such as blood vessels, muscles (pupil sphincter and dilator) and collagen fibers.



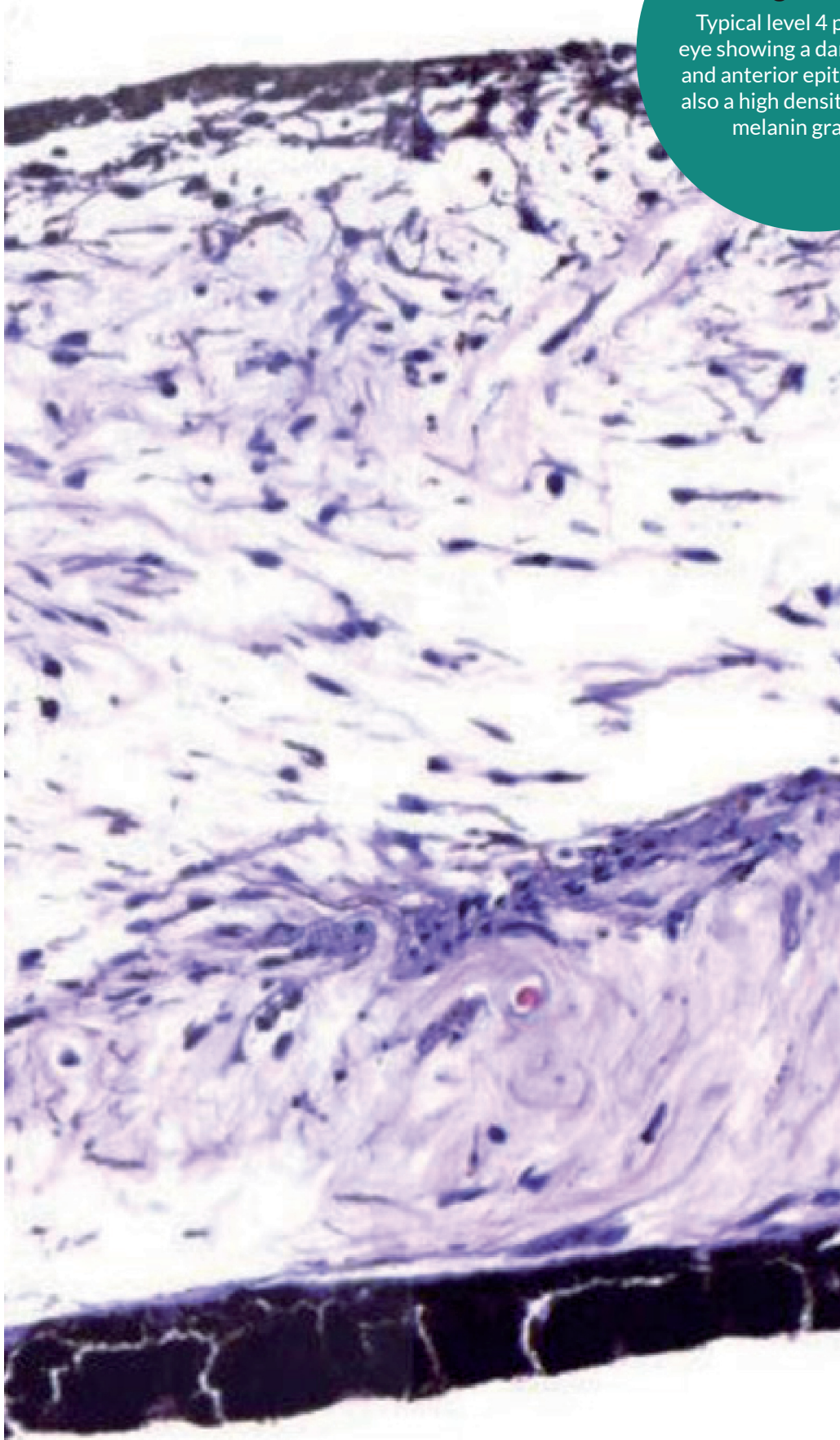
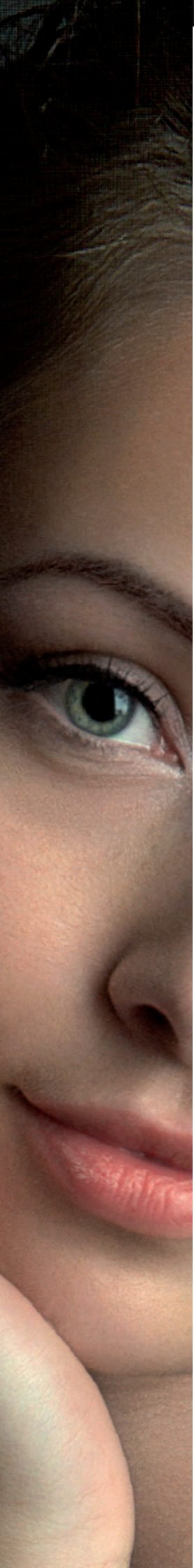

Figure 3:

Typical level 4 pigmented eye showing a dark posterior and anterior epithelium, and also a high density of stroma melanin granules.



1 Eumelanin is brown and pheomelanin is yellow. Eumelanin is concentrated in the posterior epithelium and is scattered in both the stroma and the anterior epithelium.

2 There is a maximum concentration of melanin in the peripupillary area and upper quadrant.

3 The 65.9% of iris cells are melanocytes, and their percentage is the same in blue, green and brown eyes.

4 The difference in color is due to the type of melanin and the thickness of the granules.

5 A more extensive classification of the Grimaldos clinic classification could be divided histologically into 9 grades:

- 1-Light blue
- 2-Dark blue
- 3-Blue with brown ring
- 4-Green
- 5-Green with brown ring
- 6-Brown central with peripheral green
- 7-Brown with some green
- 8-Full light brown
- 9-Full dark brown.

6 Prostaglandins increase the thickness of melanin granules in the anterior epithelium.

The second histological study we conducted was to analyze the effects on the iris of corpse eyes of four different laser wavelengths. We tried to find out what kind of laser could avoid the pernicious effect of repigmentation, safeguarding the integrity of the anatomical and functional structure of the iris.

Thanks to these works we introduced the 2G version of the Neweyes laser, which we used for a time in combination with the 1G. With the 2G laser, the possibility of reactive scar mechanisms after laser application was eliminated (Figure 4 & 5).

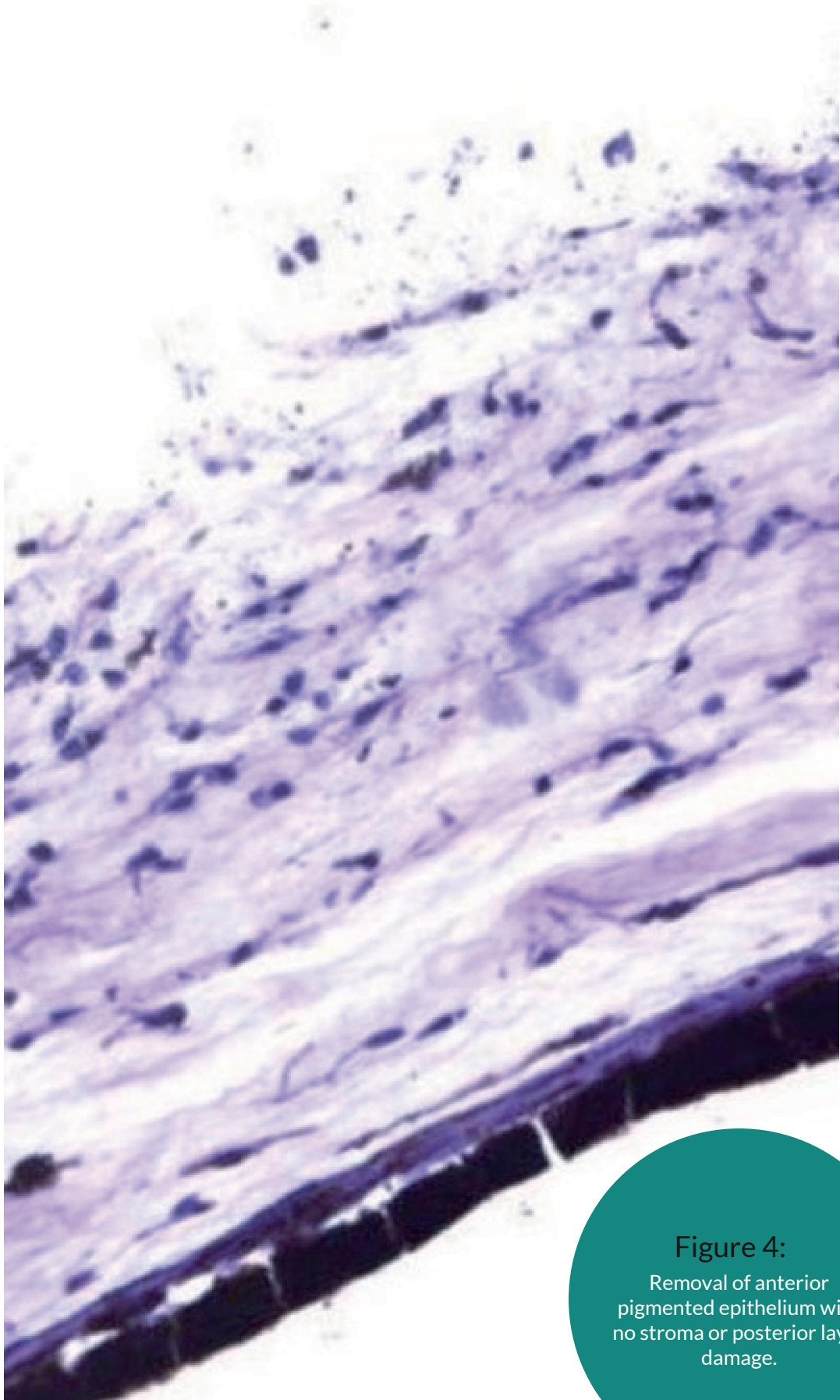


Figure 4:
Removal of anterior pigmented epithelium with no stroma or posterior layer damage.

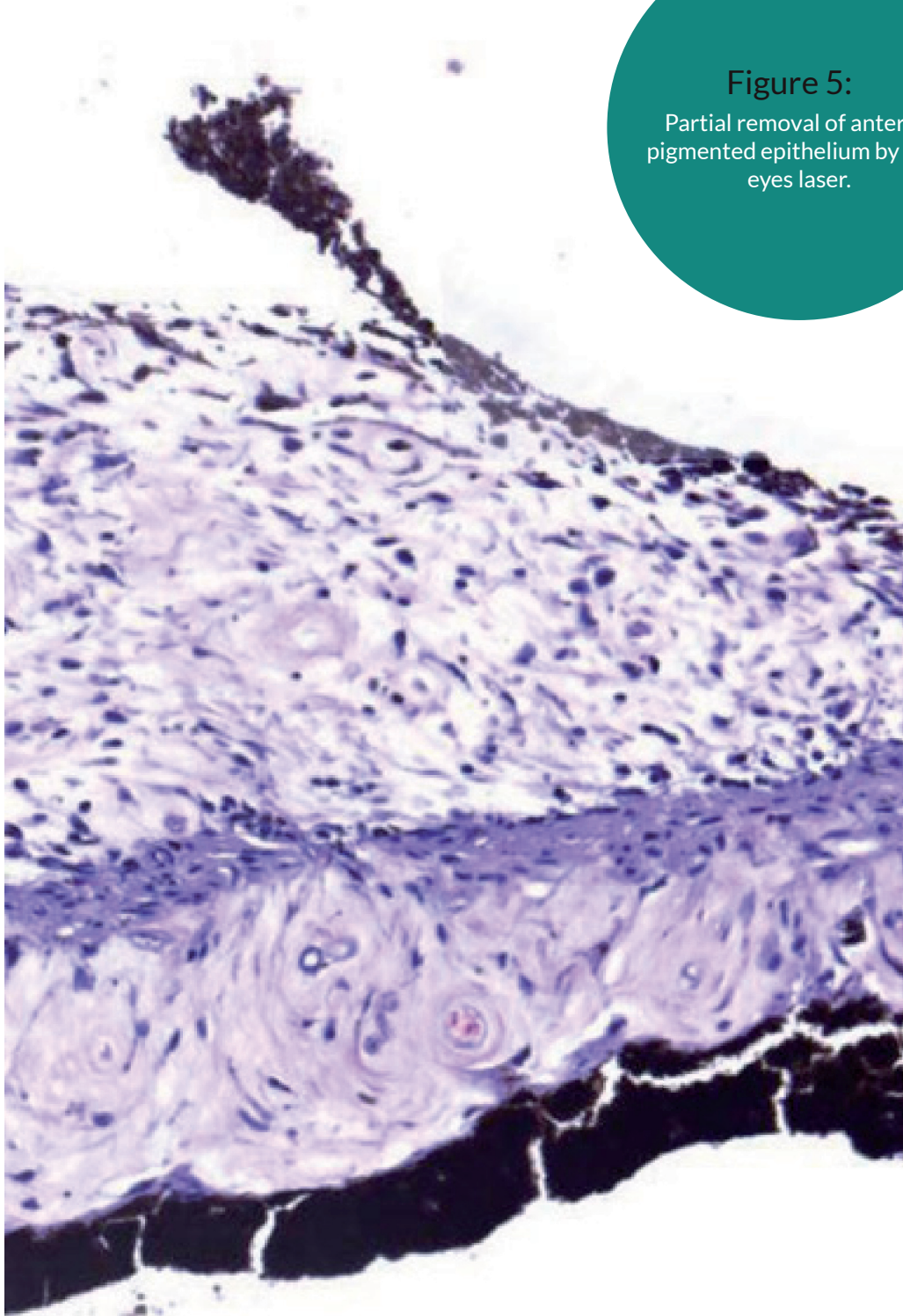


Figure 5:
Partial removal of anterior pigmented epithelium by New eyes laser.

PHENOTYPE AND GENOTYPE STUDIES

To address the challenge of achieving good predictability of laser iridoplasty, we first had to clarify the scientific bases that determine the color of the eyes. The fundamental law is genetic and it is the Theory of the two genes, green and blue (Figure 6). The first thing to notice about this table is that when there is a B, the eyes turn brown. So B is dominant over G and b. In addition to that, when there is a G (but not B), the eyes turn green. Then, G is dominant over b. Some of these details must seem a bit strange. First, there are two distinct genes, but B of one gene is dominant over G of the other gene. The other strange thing is that the recessive form of both genes is blue. These two things are related. The eye color corresponds to the amount of melanin pigment in the eye. Not anywhere in the eye, but in a special place, the stroma of the iris. A lot of melanin in this part of the eye results in brown eyes and less melanin results in green eyes. Little melanin or the absence of melanin in the stroma of the iris results in blue eyes. For this reason the brown color is dominant over the green color. Version B of OCA2 tells the eyes to produce a lot of melanin. The G version of the gey gene tells the eye to produce some melanin. What happens if both genes are present? A lot of melanin is produced and this results in brown eyes. The fact that the recessive form of both genes is blue makes sense. The recessive form of both genes does not work and that thus it is recessive. An OCA2 gene without function is equal to a gene without function (melanin does not occur in the stroma). The absence of melanin in the stroma results in blue eyes. Now we can understand why brown is dominant over green. And why blue is recessive to both.

<i>BB bb</i>	<i>Brown</i>
<i>BB Gb</i>	<i>Brown</i>
<i>BB GG</i>	<i>Brown</i>
<i>Bb bb</i>	<i>Brown</i>
<i>Bb Gb</i>	<i>Brown</i>
<i>Bb GG</i>	<i>Brown</i>
<i>bb GG</i>	<i>Green</i>
<i>bb Gb</i>	<i>Green</i>
<i>bb bb</i>	<i>Blue</i>

Figure 6:
Theory of the two genes for eye color. Allele combination chart. B: Brown, G: Green, b: Blue.

EYCL1 gene is responsible for the green and blue color of the eyes on chromosome 19. On chromosome 15 the responsible for the brown color is EYCL2 gene. Also in chromosome 15 it is EYCL3 gene that causes pigmentation of skin and hair, and whose mutations cause different forms of albinism.

Based on the two genes Theory , we first developed a software and then a mobile application to calculate the result of laser iridoplasty, taking into account the personal characteristics together with those of the parents: color of eyes, skin and hair (Figure 7).

However, we found cases of ignorance of the ancestors, in which the use of the Predictor program was not reliable. So we carried out research with prestigious geneticists who developed a special probe that located the genes responsible for eye color and their different melanin production capacities.

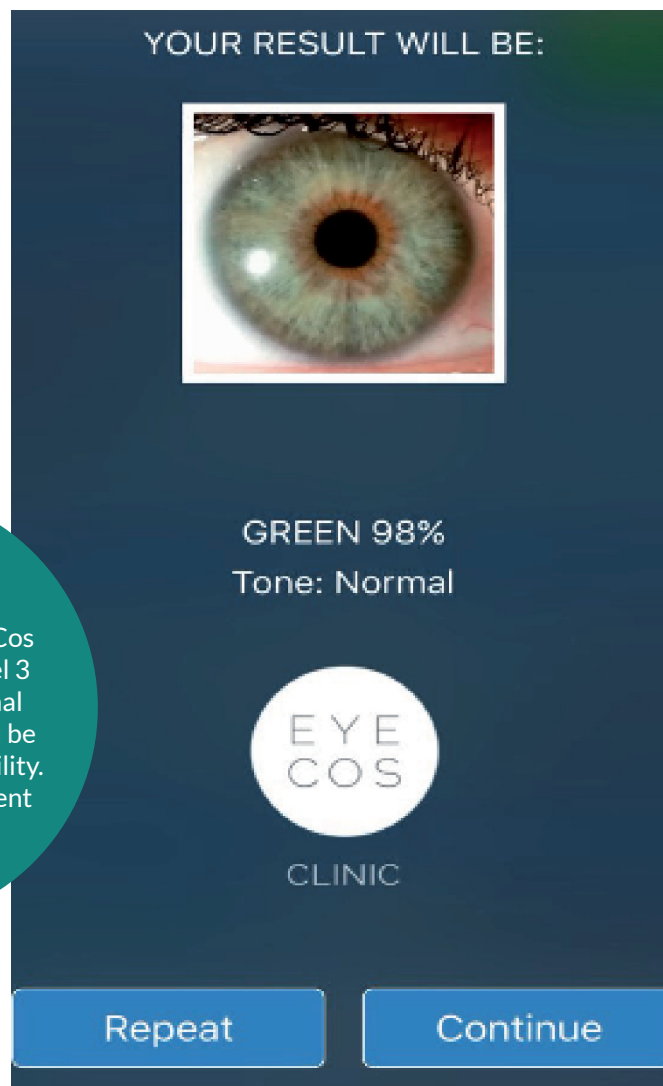


Figure 7:

Scientific result by Eye Cos App Predictor for a level 3 pigmented eye. A normal tone green outcome will be expected at 98% probability. Photo shows a real patient example.

The biochip test is a non-invasive method that is performed from a sample obtained by buccal swabbing and that increases reliability in the prediction based on objective data (DNA analysis) and not only based on statistical predictions, as it is usually done usually (Figure 8).

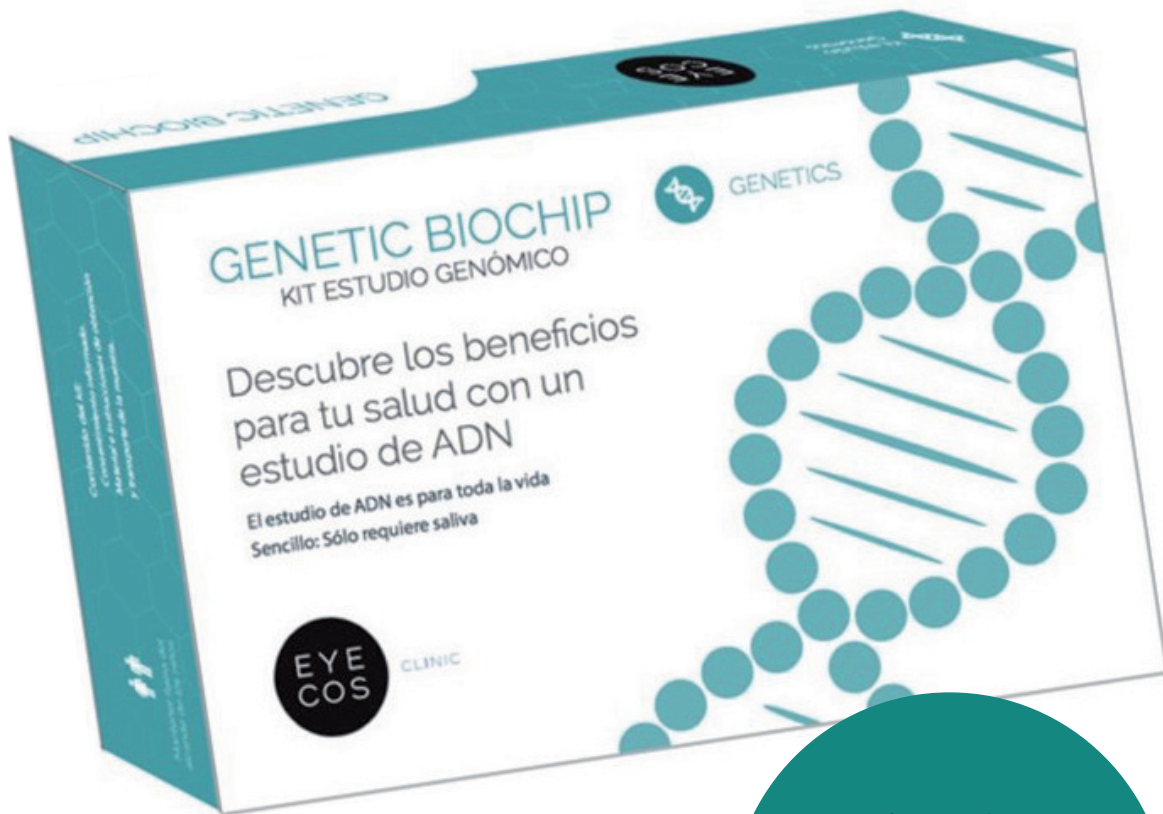

Figure 8:
Genetic biochip box to ensure prediction based on DNA analysis. In this test only a sample of saliva obtained by mouth scraping needs to be processed..

The genes studied were HERC2, TYR, OCA2 and SLC24A4, closely related to the pigment levels of the retina. HERC2 is a neighboring gene of OCA2 that regulates the expression of the latter and determines to a large extent the pigmentation levels of the human iris. Certain variants in these genes determine for example the blue color of the eye. TYR is the gene that codes for tyrosinase, one of the enzymes that regulate melanin levels. Finally, SLC24A4 gene is involved in the specific metabolic mechanisms of the retina.

For the analysis of these 5 genes, the DNA of the buccal samples is purified. The fragments of interest located within the genes mentioned above are amplified by PCR and are subsequently studied by direct sequencing or analysis of fragments with the technology established for this purpose. As a result, specific genotypes are obtained for each person in the five genes studied, allowing the prediction of levels of iris pigmentation in each individual (Figures 9).

INFORME:**DETERMINACIÓN GENÉTICA DEL NIVEL DE PIGMENTACIÓN DEL IRIS****CÓDIGO DE MUESTRA:** GR11**FECHA DE ANÁLISIS:** 02. – 16.6.2016

MÉTODO DE ANÁLISIS: A partir de la muestra de células bucales obtenida mediante raspado con hisopo, se obtiene el material genético (ADN) para análisis mediante PCR. Posteriormente se analiza cada uno de los fragmentos obtenidos mediante las técnicas de secuenciación directa y/o restricción.

El análisis cubre los siguientes polimorfismos genéticos (SNPs) en 4 genes relacionados con el nivel de pigmentación y el color del iris:

HERC2	SLC24A2	HERC2	OCA2	OCA2	TYR
rs12913832	rs12896399	rs1129038	rs1800407	rs1800401	rs1126809
AG	GG	AG	AG	CC	GG

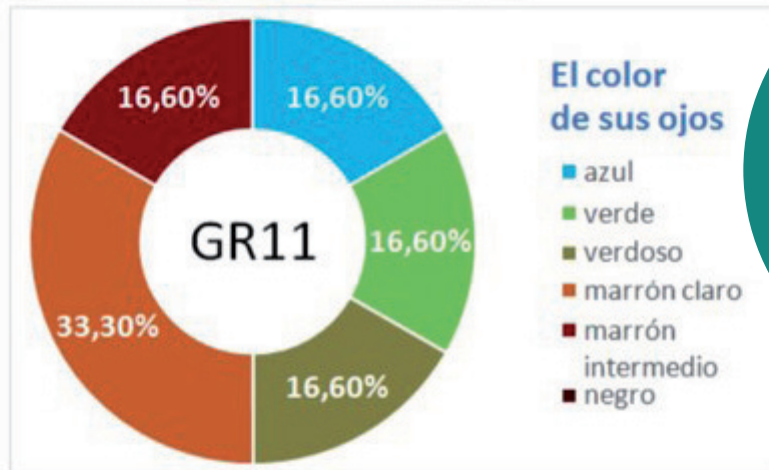
CONCENTRACIÓN DE PIGMENTO: MEDIA-BAJA

Figure 9:
Typical genetic report for a patient. Main eye color genes are studied to offer most accurate prediction

Los genes analizados dan información sobre 6 tonalidades de color del iris.

El gráfico representa la distribución genética y la probabilidad de correspondencia con las diferentes tonalidades que permiten predecir su color de ojos.

CAPACIDAD REGENERATIVA DEL PIGMENTO: probablemente MEDIA-BAJA**CONSIDERACIONES SOBRE LA TÉCNICA**

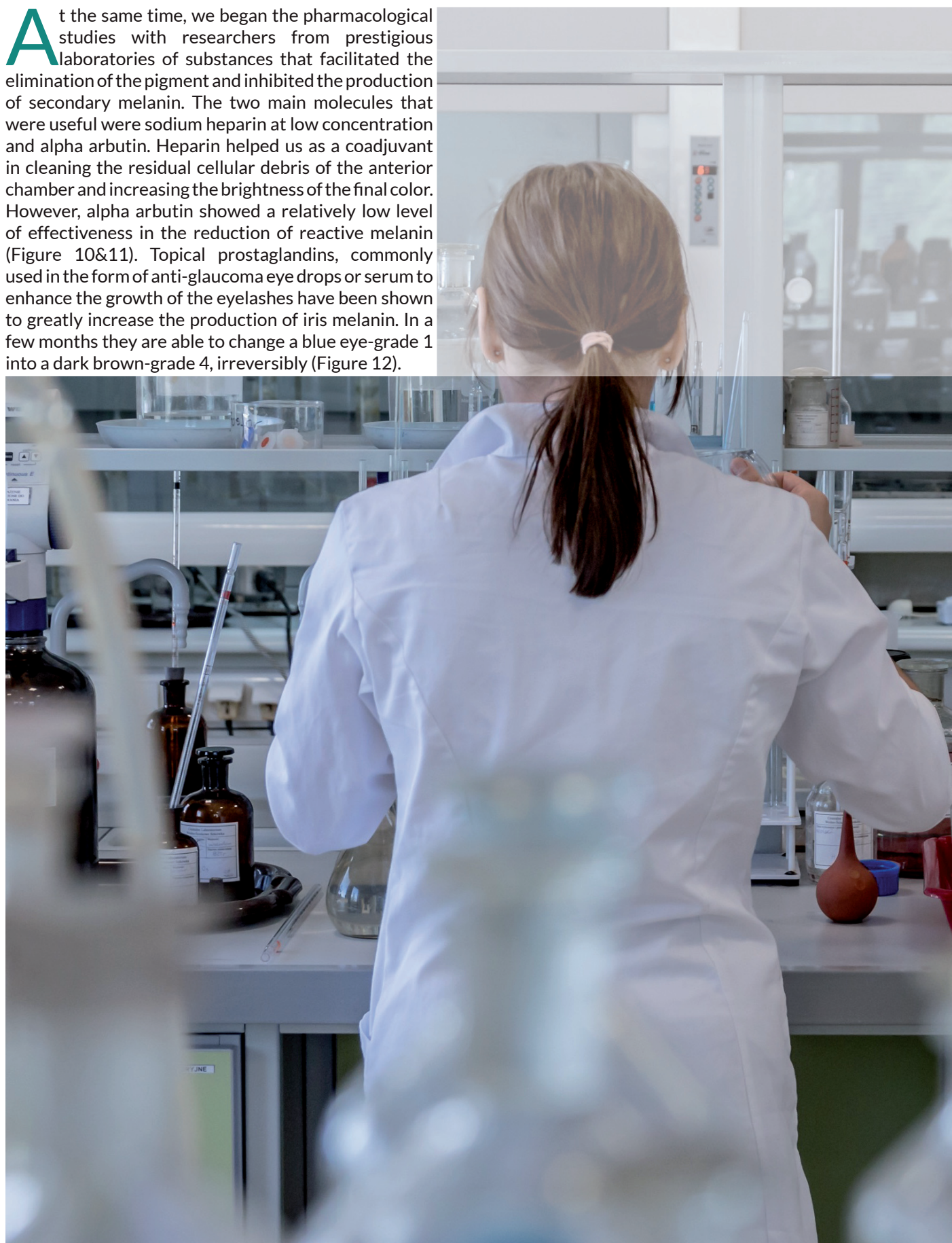- La coloración del iris sigue un patrón multifactorial, por tanto, existen múltiples genes, unos conocidos y otros no, para su determinación. Por tanto, todo test diseñado para determinar la concentración del pigmento del iris, incluyendo el presente, sólo tendría un valor relativo y de probabilidad.
- El color de los ojos está determinado por la cantidad y distribución de la melanina en el iris. Los ojos marrones contienen más melanina que los ojos verdes, mientras que los ojos azules tienen muy poca.
- Este test analiza 4 genes que han sido vinculados con la determinación de la concentración del pigmento del iris que, si bien no son todos los que participan en este proceso, sí son algunos de los más representativos en población caucásica. En este sentido, su valor predictivo es relativo, siendo más certero en la identificación del color marrón versus no marrón (fiabilidad >95% en este sentido).

Fecha: 27.6.2016

Fdo. Dr. J.I.Lao (COMB 41722)

PHARMACOLOGICAL STUDIES

At the same time, we began the pharmacological studies with researchers from prestigious laboratories of substances that facilitated the elimination of the pigment and inhibited the production of secondary melanin. The two main molecules that were useful were sodium heparin at low concentration and alpha arbutin. Heparin helped us as a coadjuvant in cleaning the residual cellular debris of the anterior chamber and increasing the brightness of the final color. However, alpha arbutin showed a relatively low level of effectiveness in the reduction of reactive melanin (Figure 10&11). Topical prostaglandins, commonly used in the form of anti-glaucoma eye drops or serum to enhance the growth of the eyelashes have been shown to greatly increase the production of iris melanin. In a few months they are able to change a blue eye-grade 1 into a dark brown-grade 4, irreversibly (Figure 12).



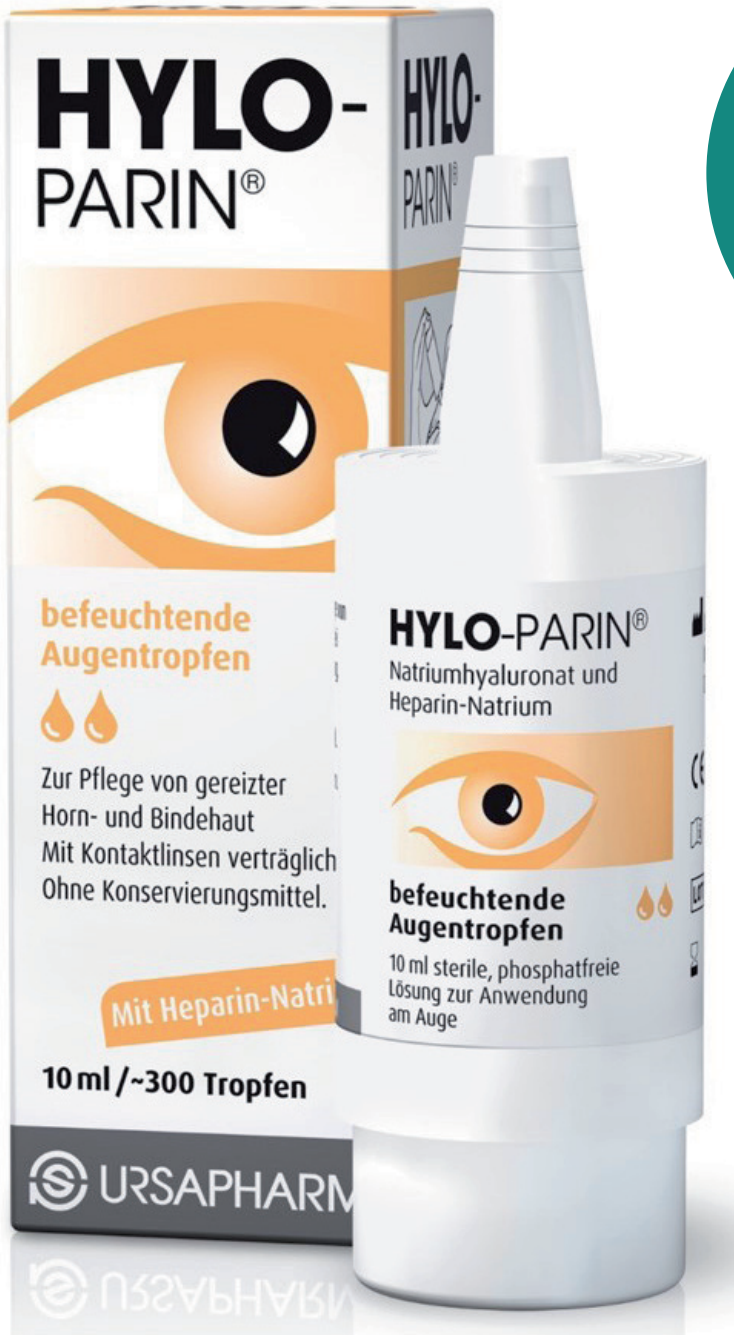

Figure 10:
Low concentrated heparine eyedrop (Hyloparin®) used to facilitate clearance pigment debris out of the eye.



Figure 11:
Low concentrated Alpha Arbutin eye drop was used to reduce melanin production after laser application, but its effect was minimal with time.

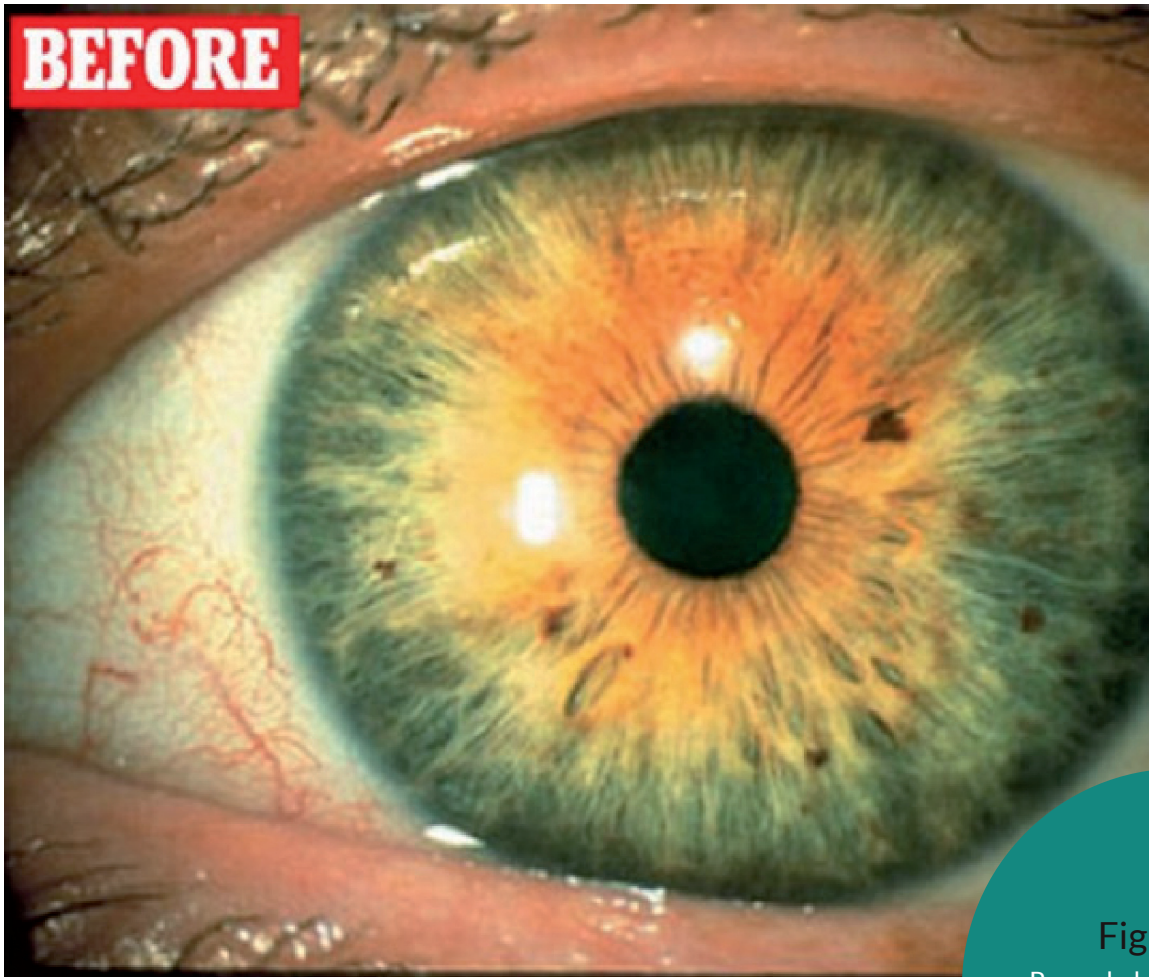
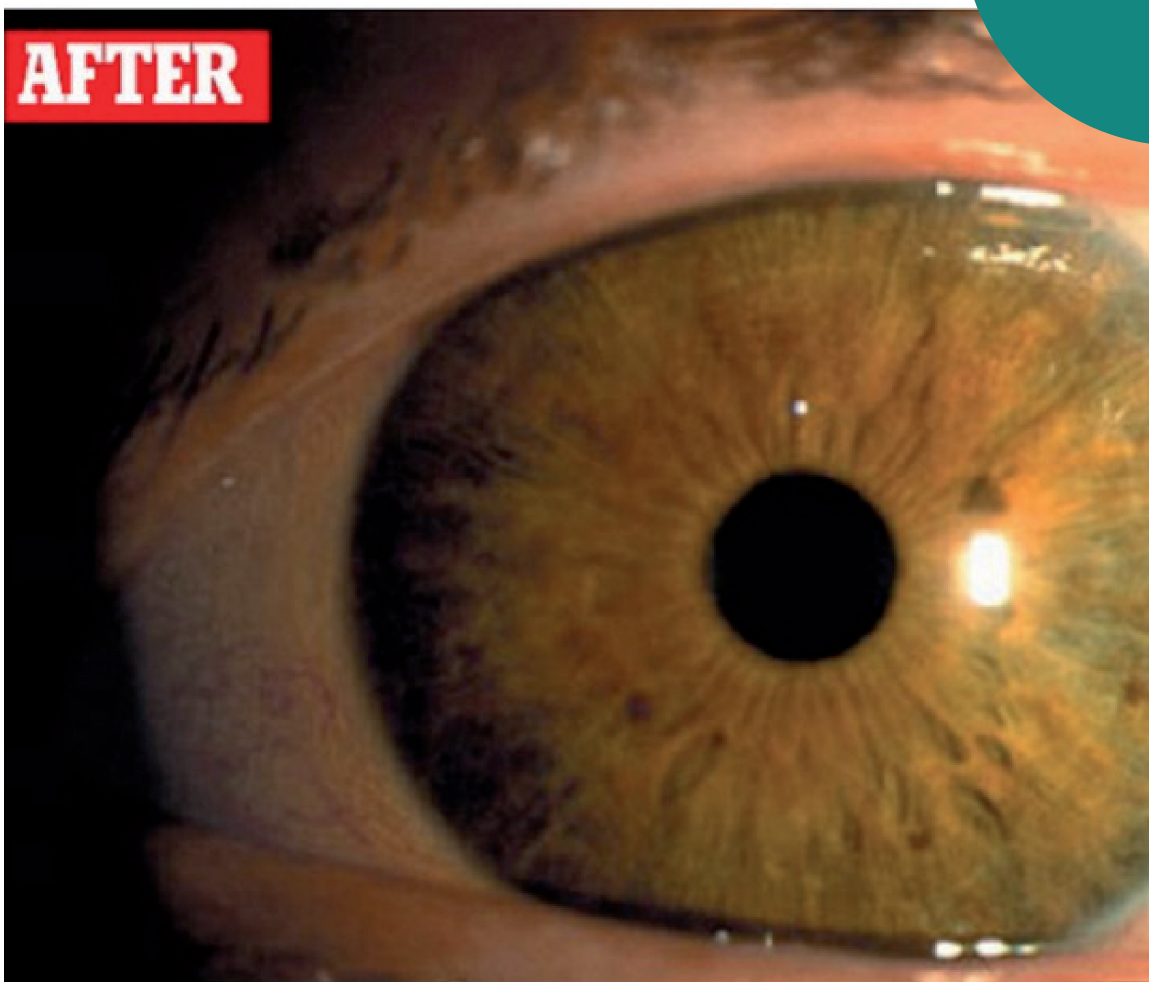
Figure 12:
Remarkable iris darkening
after few months using
prostaglandins drops.



TECHNIQUE: LASER COSMETIC IRIDOPLASTY

After a few years of basic research and evaluation of possible alternatives, in 2012 we began the technological development and the clinical studies of the solution with laser application [14]. A priori offered two clear advantages over the previous possibilities, greater security because it is not a surgical intervention, and naturalness of the result, by obtaining biological textures of the patient and by not altering the functionality of the pupil, which continues to react to light and darkness in a normal way [15]. For this reason, visual aberrations and limitations of the peripheral visual field are not caused. The premises of the project were defined but should be demonstrated over the following years. Several phases were planned:

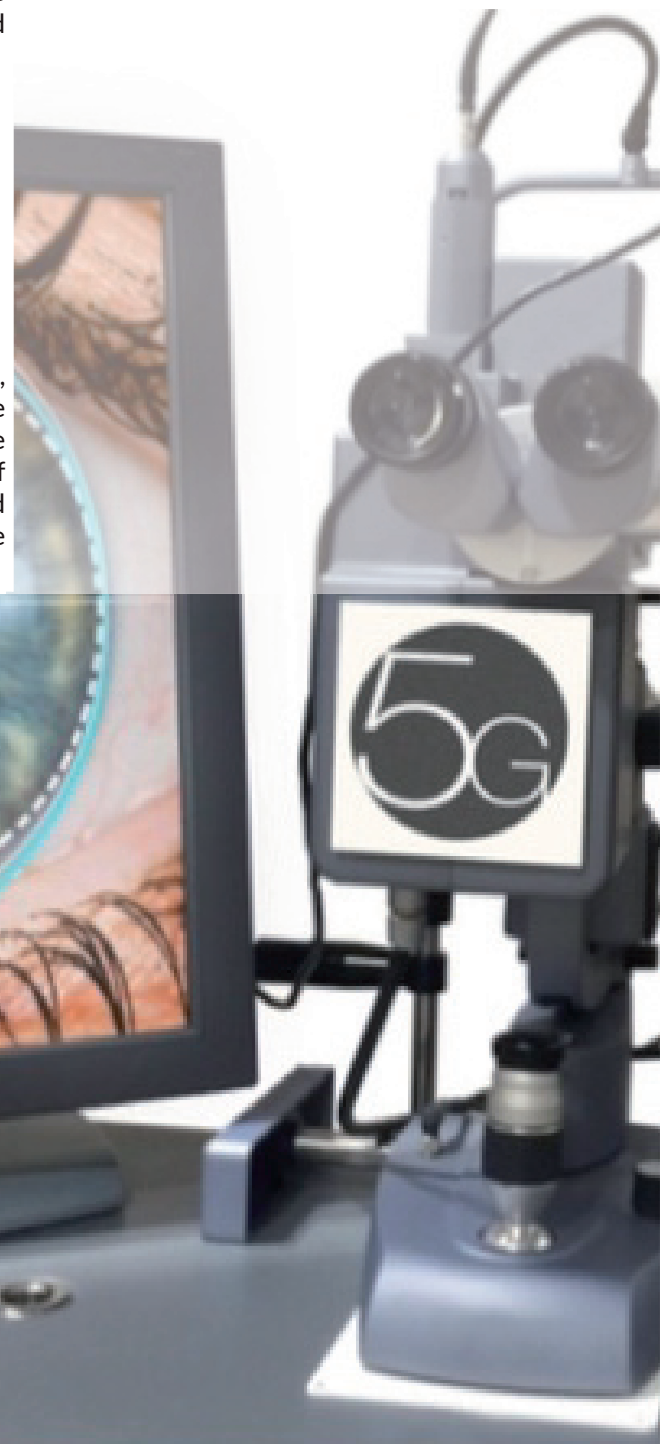First security phase: 2012-2014

Second phase of effectiveness and predictability: 2014-2016

Third phase of technological improvement: 2017-2018

Fourth phase of technical sophistication: 2019-2020

Fortunately, our premises were confirmed over time and, not without effort, we were able to solve the problems we encountered on the road and achieve a state close to the excellence of the original technique. After 7 hard years of research and development we can affirm that we have achieved the challenges that we set ourselves in 2012 and we can enunciate the following definitions:



CLINICAL DEFINITION

“Laser cosmetic iridoplasty is a non-contact, step by step, painless, blade-free, at the office & outpatient procedure”.



TECHNICAL DEFINITION

“An integrated multiple laser system, with non-sterile requirement, scanner patterns, eye tracker & OCT module to perform Custom Treatments”.

Clinica NewEyes

FULL EYE CARE



IRIZ LASER WORKSTATION = APPS + IRIS SCANNER + NEW EYES LASER MOBILE APPS

First, Eye Selfie has made it possible for the first time that a patient can take pictures of their eyes without the help of anyone and with high image quality, good focus, perfect focusing and adequate lighting (Figures 13 & 14). The Eye Selfie App has finally made it possible to carry out a remote diagnosis and effective follow-up (Figure 15). And second, the 3D Simulator App is capable of generating 3D models of the patient's original eyes and three-dimensional simulations of the results predicted by the App Predictor (Figure 16). Sim 3D can also simulate the effect of ambient lighting on the appearance of eye color. With low light the black pupil dilates and the intensity of color decreases proportionally (Figure 17). Finally Sim 3D can simulate the effect of the observation distance on the appearance of the eyes (Figure 18).





EyeCos EYE Selfie

Fotos perfectas de tus...

ABRIR

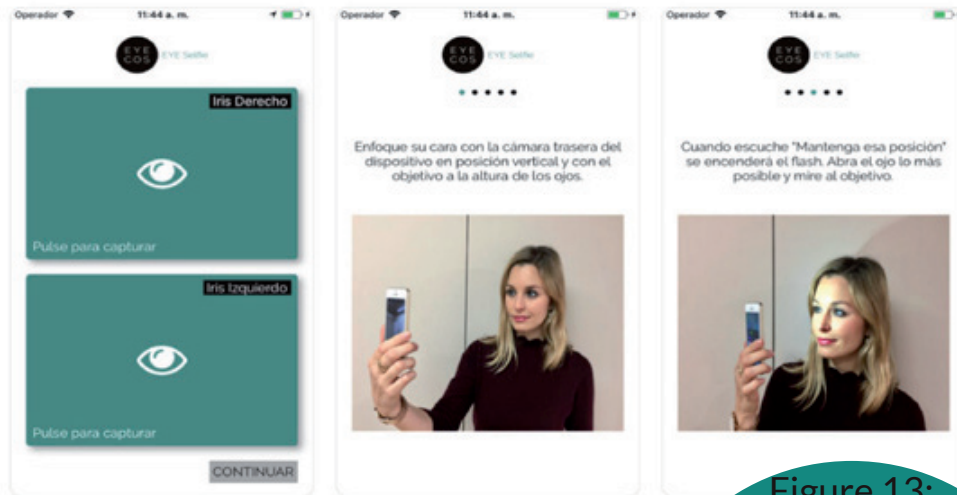


Figure 13:
Eye Cos Eye Selfie App.
Amazing way to take by yourself and automatically perfect HQ eye photos (good focus, centered and adequate lighting). Both eyes are registered and saved on the smart phone. In order to check up, these two pictures can be easily submitted to the doctor by email and a quick medical report is received by email too.


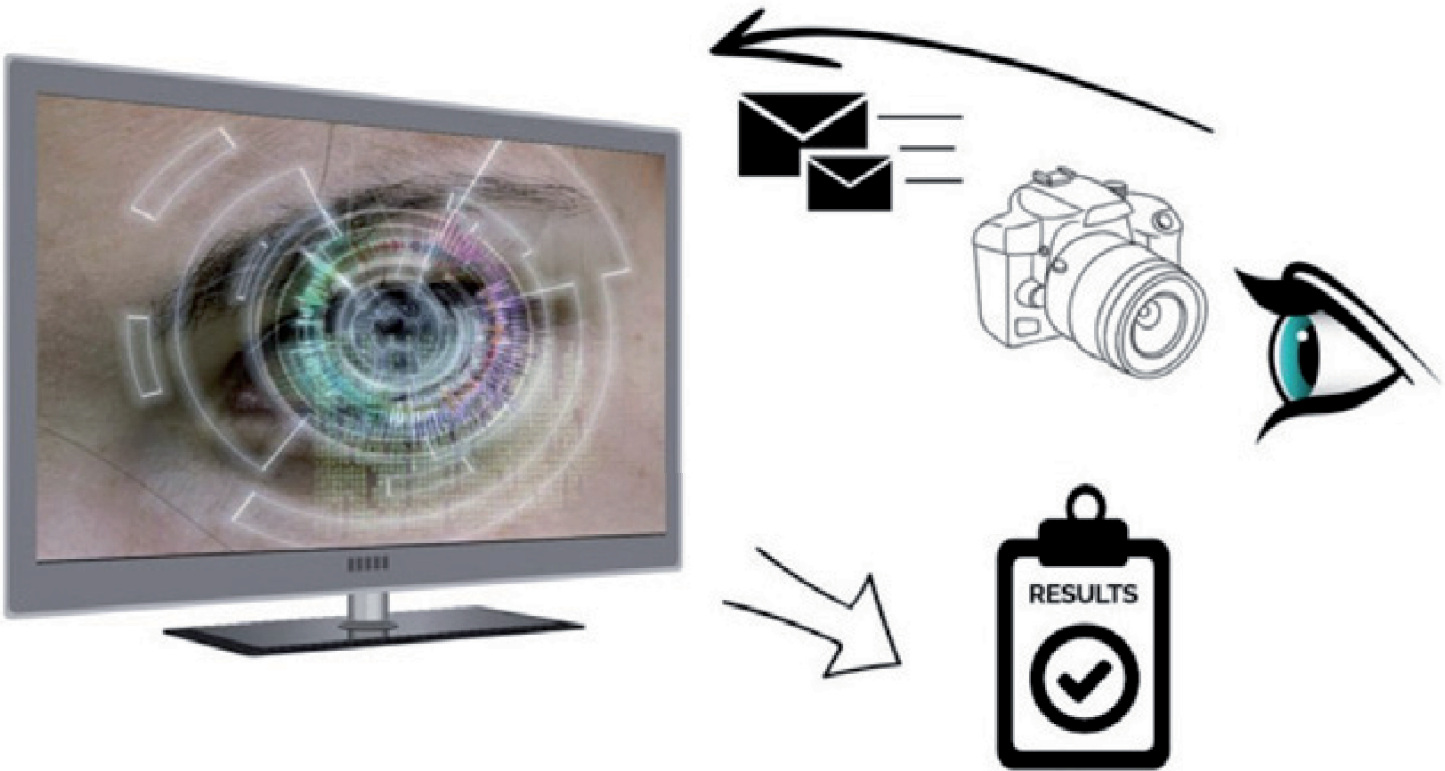


Figure 14:

Automatic mode to take perfect eye photos by Eye Cos Eye Selfie App.

Figure 15:
Both eyes pictures are sent to the doctor. After a detailed study by Grimaldos Iris Software, a quick medical report is received by email (remote check up and follow up).





NewEyes 3D Simul...

Medicina

ABRIR

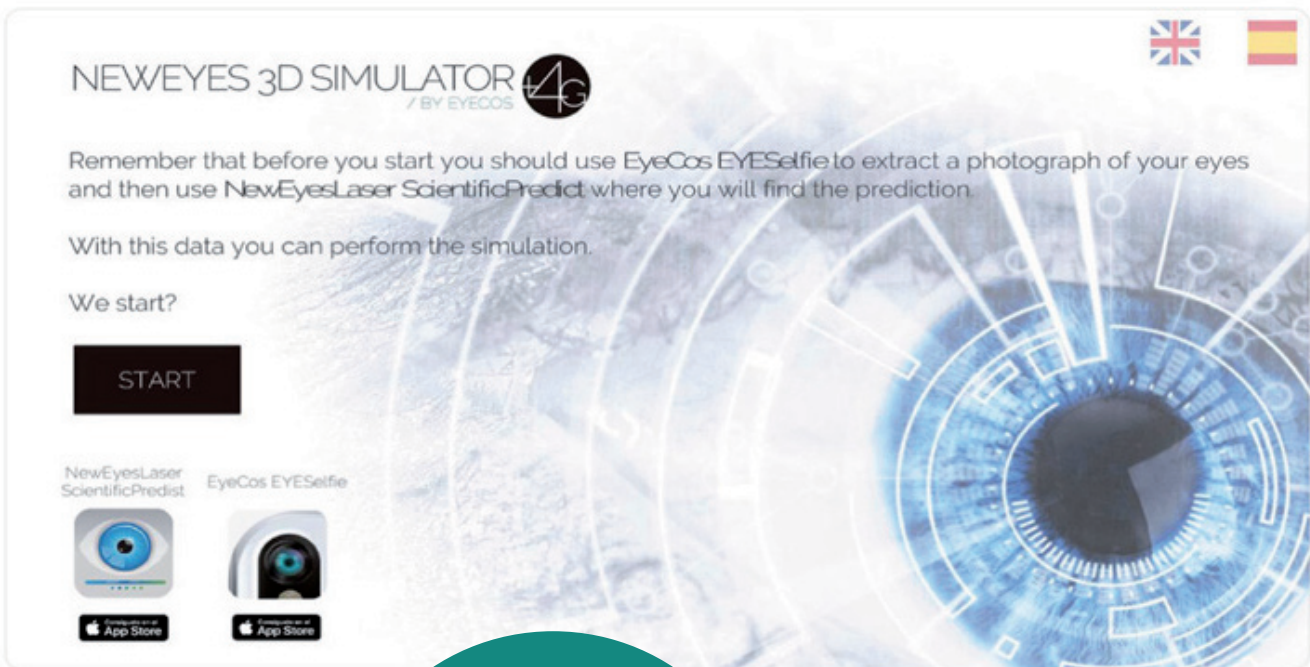


Figure 16:

Eye Cos 3D Simulator App generates automatically three dimension eye models to see the final outcome. Once the App Predictor calculation has been done, the patient can compare laser cosmetic effect, before and after the procedure.

60	45	16	15
59	44	17	14
58	43	18	13
57	42	19	12
56	41	20	11
55	40	21	10
54	39	22	9
53	38	23	8
52	37	24	7
51	36	25	6
50	35	26	5
49	34	27	4
48	33	28	3
47	32	29	2
46	31	30	1




Figure 17:
Eye Cos 3D Simulator offers a dynamic simulation to understand how the pupil size changes with different light levels.

NEW EYES 3D SIMULATOR / BY EYECOS 

- NUEVO
- OJO ORIGINAL
- VER OJO SIN CARA
- COLORES





Figure 18:
Sim 3D App has also a tool to check the distance effect on the eye color. A proportional relationship between far-near observation and brightness has revealed evident.

NEW EYES 3D SIMULATOR / BY EYECOS 

IRÎZ SOFTWARE SUMMARY

The iris analysis software, Grimaldos Summary, calculates maps and parameter quantification thanks to new colorimetric, pachymetric, densitometric and topographic scales (Figure 19 & 20). Using them it has been possible to standardize the explorations, an essential milestone for the scientific advance of the technique. In addition, the second version of the IRÎZ Summary has made dynamic pupilometry, the follow up and partial comparative studies of halves and quadrants possible.



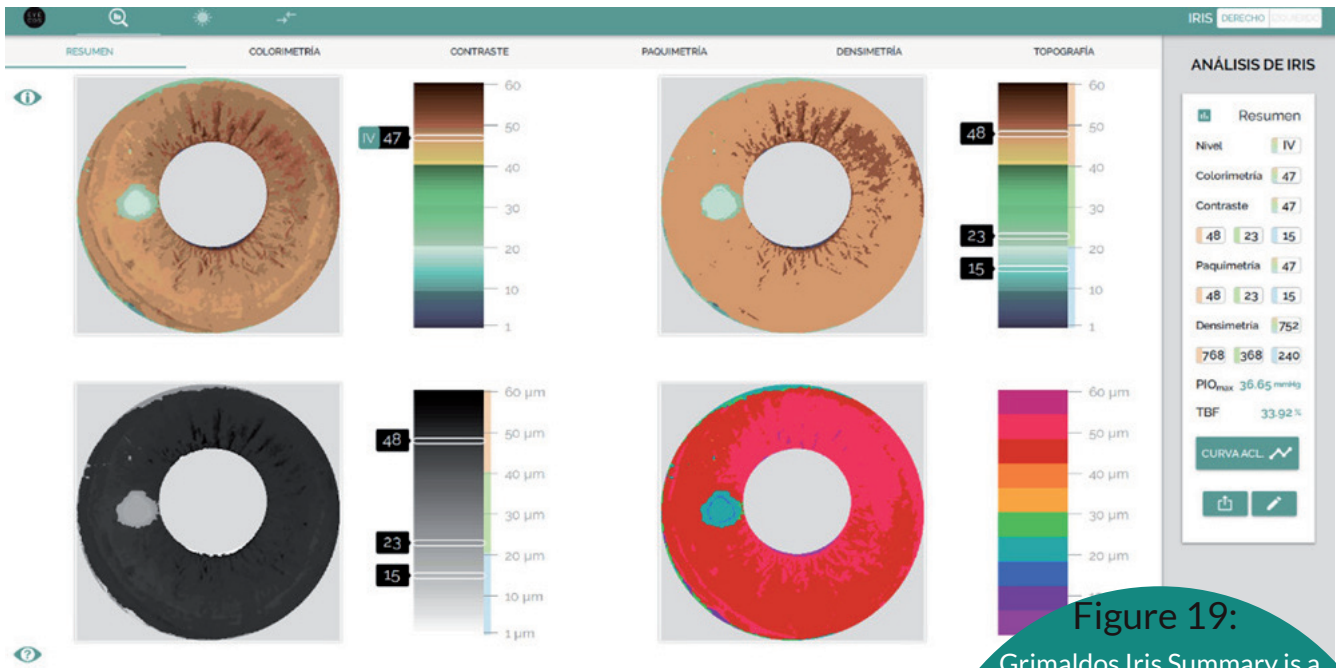


Figure 19: Grimaldos Iris Summary is a reference standard about a quantitative iris study. This advanced software offers graphic maps of colorimetry, color contrast, pachymetry, densitometry and 3D topography. Dynamic fluids parameters are also calculated in order to warrant safety levels. Finally, dynamic pupillometry, follow up and partial evaluations, even between different patients, are available.

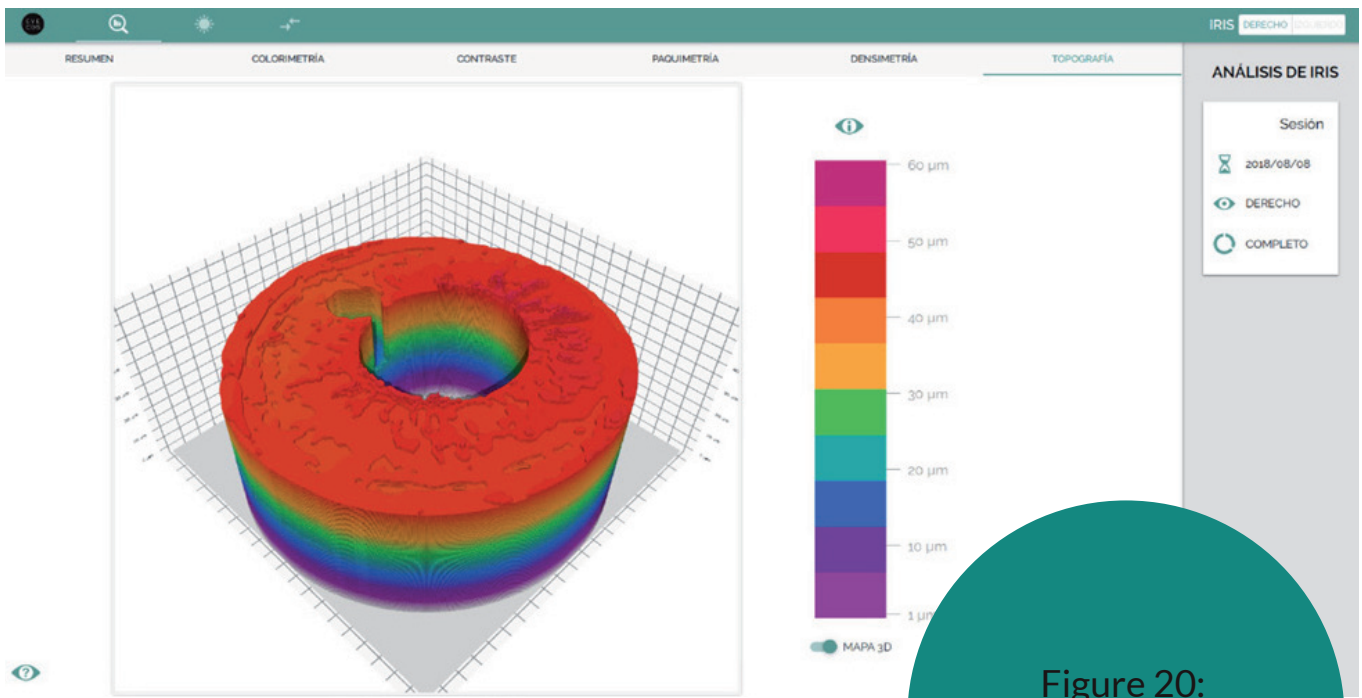
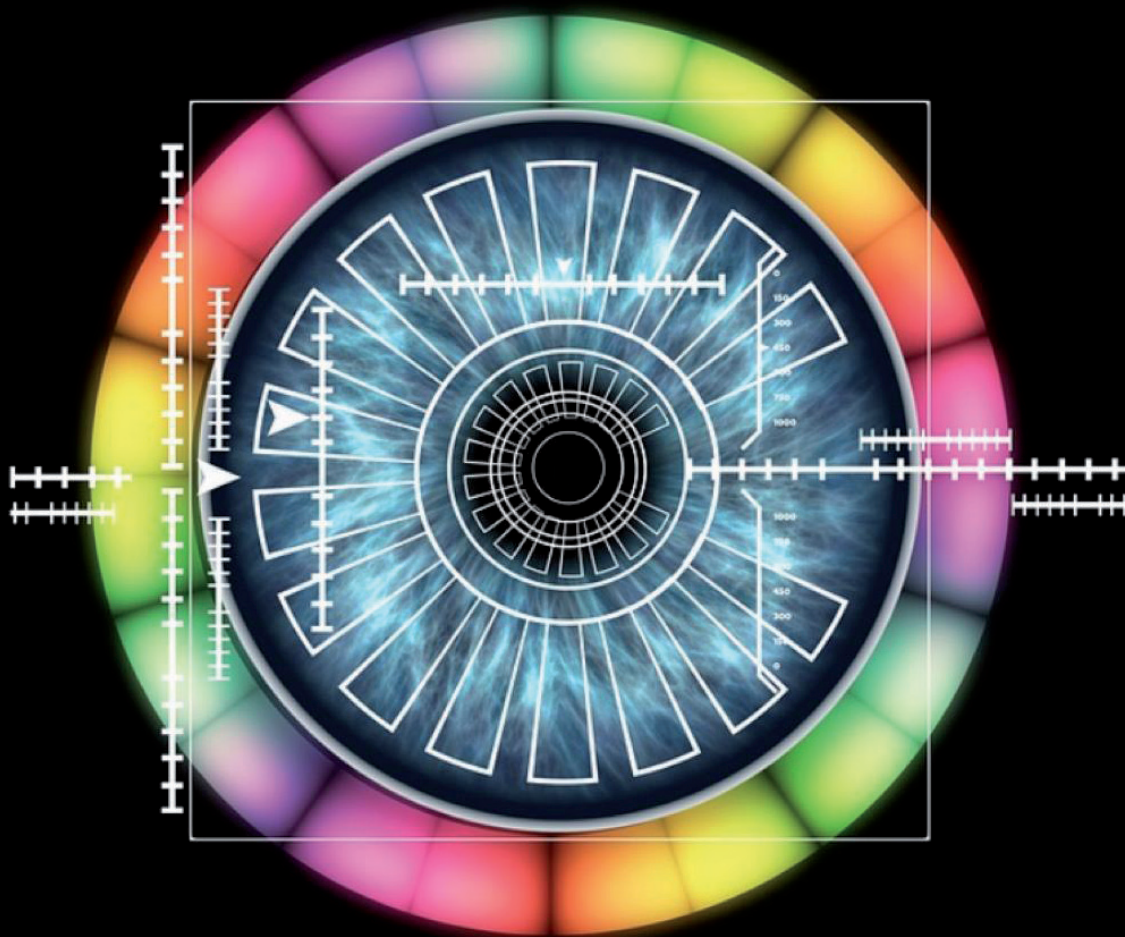


Figure 20: Three dimensional topography.

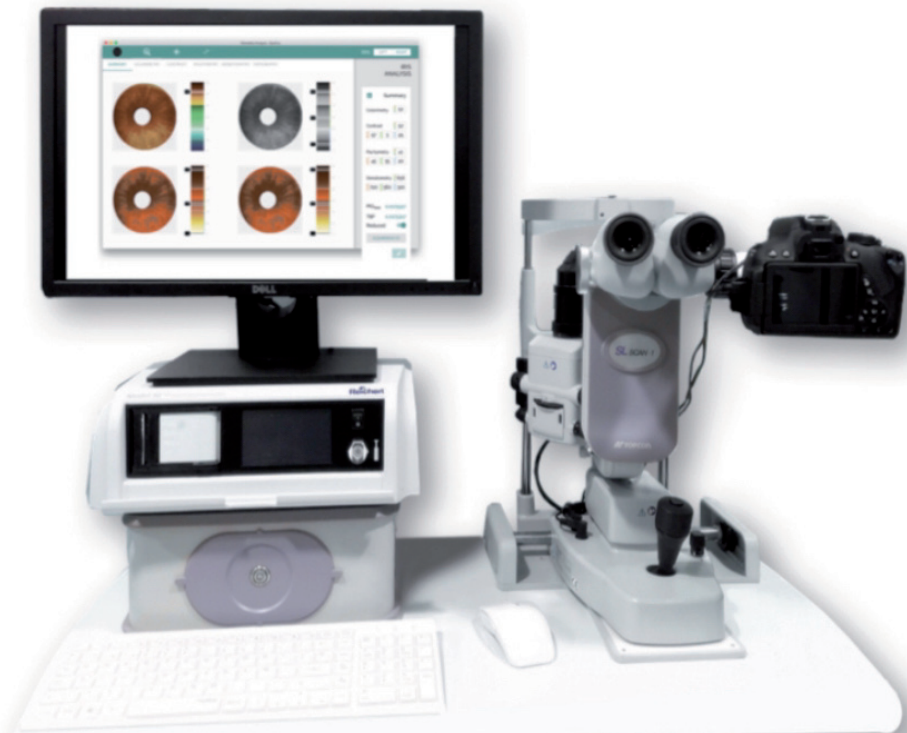
IRIS SCANNER WITH OCT AND HD PHOTOGRAPHY

The IRIZ Scanner incorporates great advantages, such as a high quality image capture system and its processing with the Grimaldos Summary software, a wide field coherence optical tomography (OCT) module and a high precision pneumatic tonometer and topographer (Figure 21).



IRÎZ Scan Analyzer

by EYECOS



Grimaldos IRÎZ Summary

- Colorimetry map
- Contrast map
- Pachymetry map
- Topography 3D map
- Pupillometry dynamic
- Physiodynamics

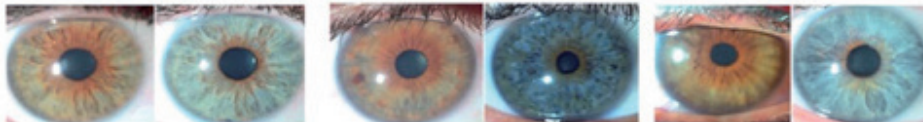Comparative study

- Preop & Postop
- Evolutive Follow up
- Binocular study
- Patients comparative
- Segmentation study

60	45	16	15
59	44	17	14
58	43	18	13
57	42	19	12
56	41	20	11
55	40	21	10
54	39	22	9
53	38	23	8
52	37	24	7
51	36	25	6
50	35	26	5
49	34	27	4
48	33	28	3
47	32	29	2
46	31	30	1

Planner Program

- Eye level classification
- Sessions plan
- Step by step program
- One step program
- Treatment Simulator
- Segmentation plan




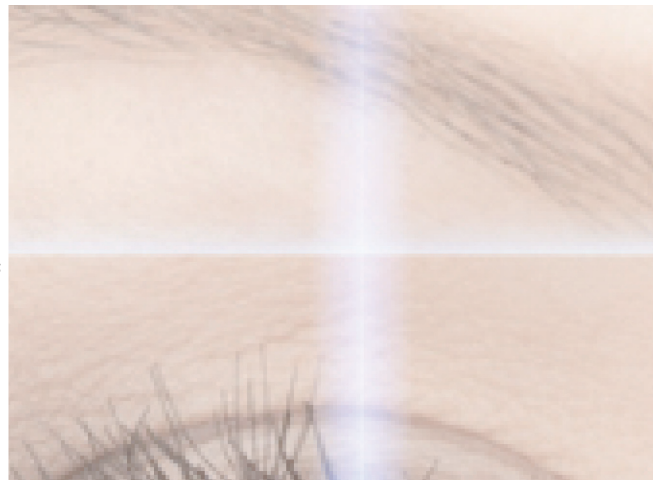
IRÎZ Laser Workstation. Eyecos Corp www.eyecos.eu. Barcelona, Spain

Figure 21:

New IRÎZ Scanner version, with an improved capture system of HQ images, a pneumatictonometer and tonographer and an OCT module.

NEW LASER VERSIONS 3G, 4G, 5G, 6G, & GO ON

The special collaboration with a team of laser engineers has enabled the incorporation of three new generations of Neweyes laser, 3G, 4G and 5G. The 3G is the natural evolution of 2G but with different wavelength, which makes it minimally aggressive and selective of the iridian tissue. The 3G laser has made possible the unique sessions of the entire iris without acute complications. The 4G laser is a device that combines the effects of the original 1G with those of 3G. This mechanism of double action produces a direct cleaning of the melanin and at the same time avoids late repigmentation by definitive destruction of the melanocytes (Figure 22). The 5G version of the Neweyes laser refers to an integral system consisting of 3 or even 4 different lasers. It also incorporates multiple scanner patterns and a passive eye tracker with visible light (not infrared) (Figure 23).



IRIZ Ultimate 5G Laser

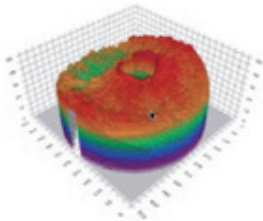
by EYECOS

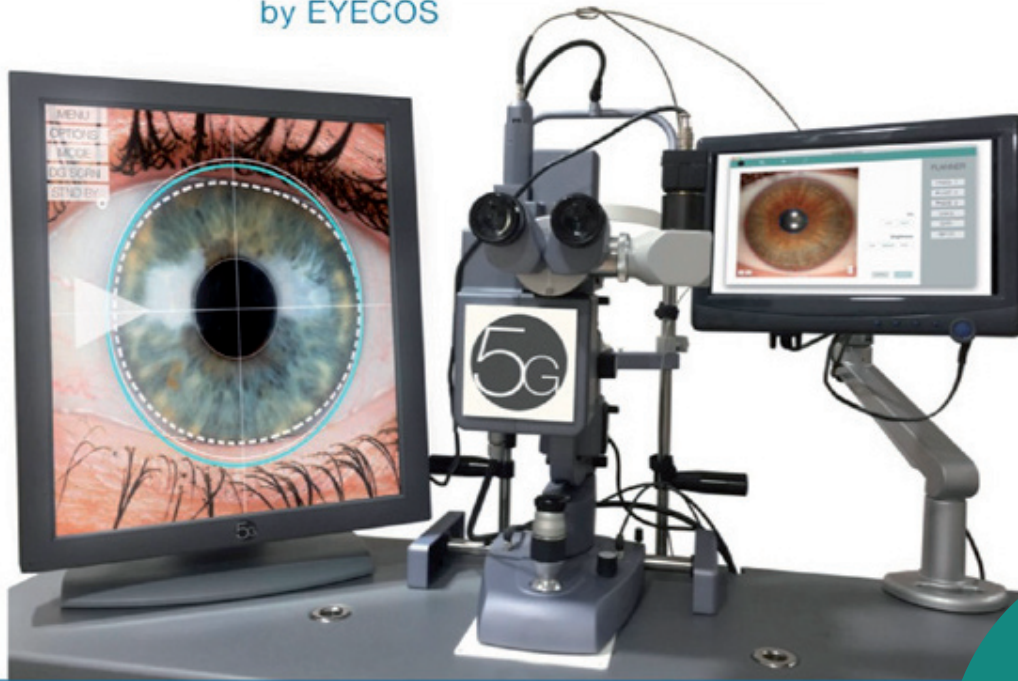

Figure 22:
New 5G New eyes laser version. An integral multiple laser system. Other remarkable improvements have been updated, as a big color screen, scanner patterns, planner program screen and eye tracker.

Accurate performance

3D iAnalyzer & Chart Summary
OCT Guided Custom ablations
IR EyeTracker-full comfort
Fast Scanner mode (<1minute)
Painless Multi 4-Dye Laser
Eye Selfie & Predictor & Sim 3D
Instant & Steps mode



Advanced technology

A four wavelengths integrated laser system, with non sterile requirements, scanner pattern, white and IR eye tracker mode and OCT module, to perform customized treatments based on preop analysis

A safe clinical procedure

A non contact, step by step, painless, blade-free, at the office, outpatient procedure to treat any iris pigmented and cosmetic and color-change indication

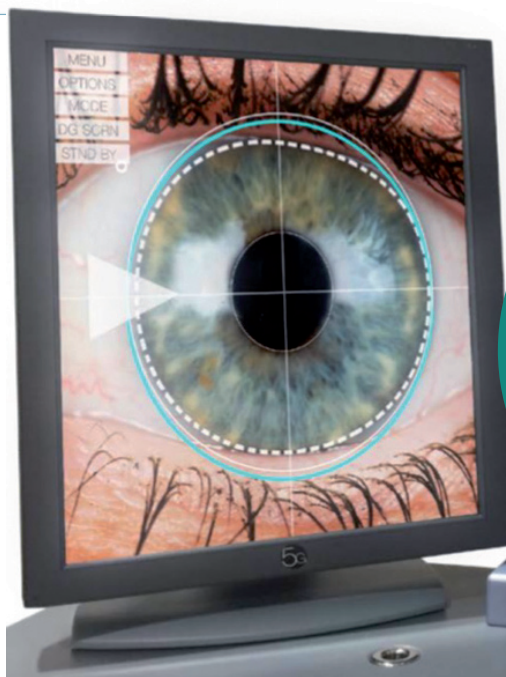
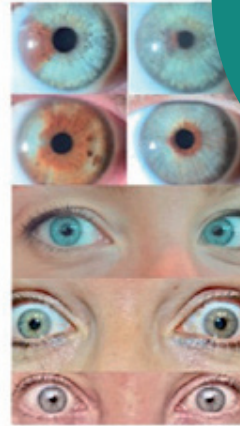
Figure 23:
Large color screen to check iris treatment and manage any sudden movement by eye tracking.

PLANNER PROGRAM

The purpose of the IRIZ Workstation is the routine realization of customized laser iridoplasties. As there are no two identical irises, personalized treatments are mandatory. The differences are in the degree of pigmentation, type of melanin, thickness, topographic irregularity, pupillary function and healing capacity. On the other hand, heterochromias must be accurately mapped in order to eliminate them accurately. After obtaining a meticulous analysis of the iris with the IRIZ Scanner and the Grimaldos Summary software, we introduce these data in the Planner program to generate the specific treatment guideline, with number of sessions and specific parameters to be used in each case (laser type, energy, etc) (Figure 24).



Current financial situation
Putting your strategy into action is how you
through networking, advertising etc

Investment
Fin

Stocks
30%
50%

Trading Graph

Information to focus resources on the greatest opportunities to increase sales and achieve the advantage over other competitors. The strategy's goal is to increase sales and achieve the advantage over other competitors.

It is a process to achieve the company's objectives.

It includes short term and long term activities of marketing that has to do with the analysis of a company's situation and contribute to its objectives. The objectives will be based on how you gain sales by acquiring and keeping customers. The strategy helps convey effective messages with the right twist of marketing approaches that will maximize your marketing activities.

12,357	20,775	24,766	45,556
3,541	354	1,876	190
	133	134	

Issue 764
Monday, Jun 14, 2016
Citydailynews

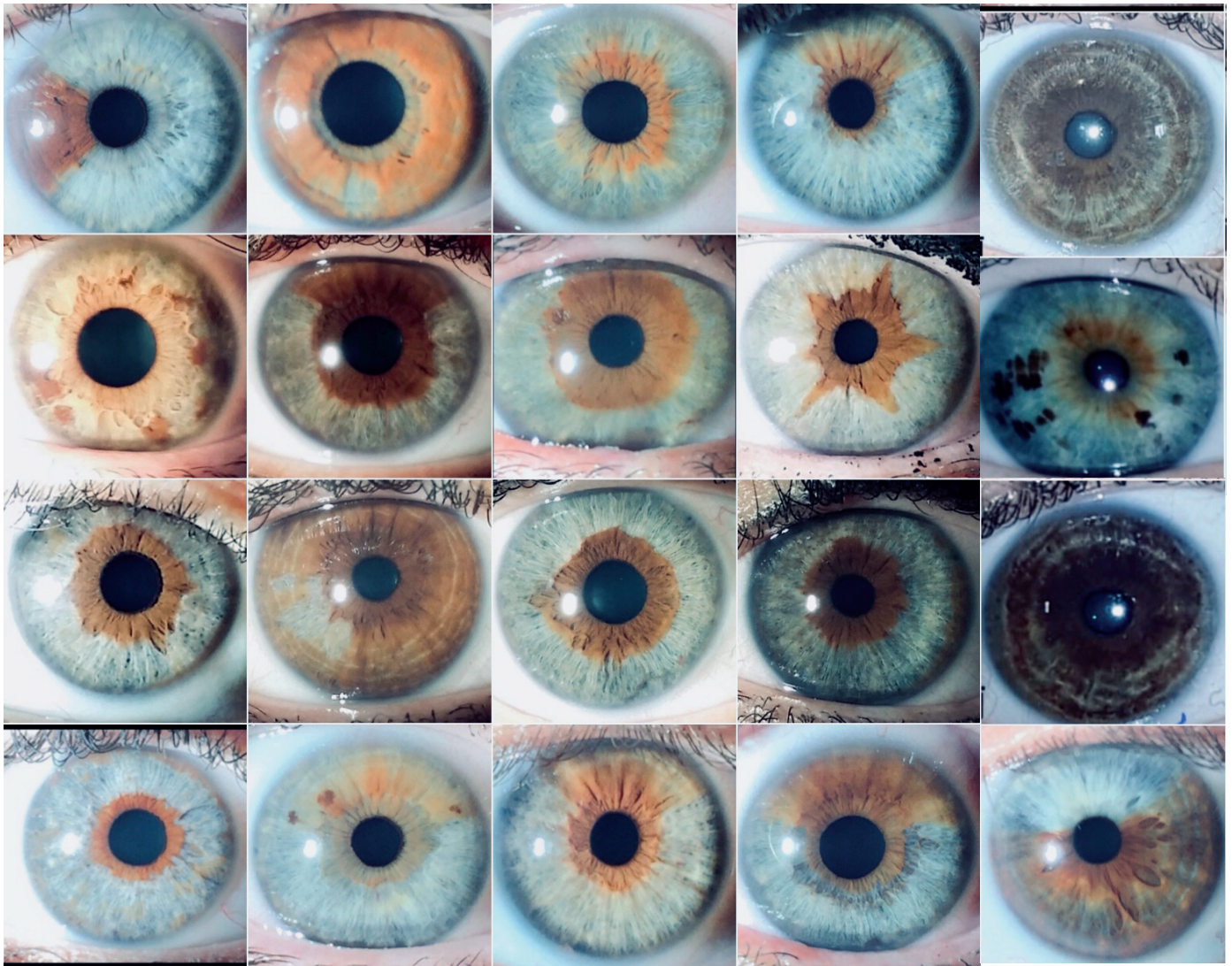
y of the n Union

Are you innovative or are you the experienced type? or do you offer a high-cost, high-quality product, or low-cost, high-value products? It's impossible to be both. You should consider on thinking what your customers need you to be. Your logo is the main foundation of your brand. All the promotional materials should be connected with your brand. All should communicate with your logo. Having a good brand strategy allows you to have a large advantage in gaining competitive edge. Your brand tells your customers what they can have or expect from the products and services you offer. The branding strategy as it should be consistent as it leads to a strong brand equity. The branding strategy you have should be consistent. [more on p.57](#)

	M	T	W	T	F	S	S
	2	3	4	5			
	9	10	11	12			
	16	17	18	19			
	23	24	25	26	27	28	29
	30	31					



Figure 24:
Accessory screen to manage
PlannerProgram.



heterochromia - laser iridoplasty

RIGID ADMISSION CRITERIA:



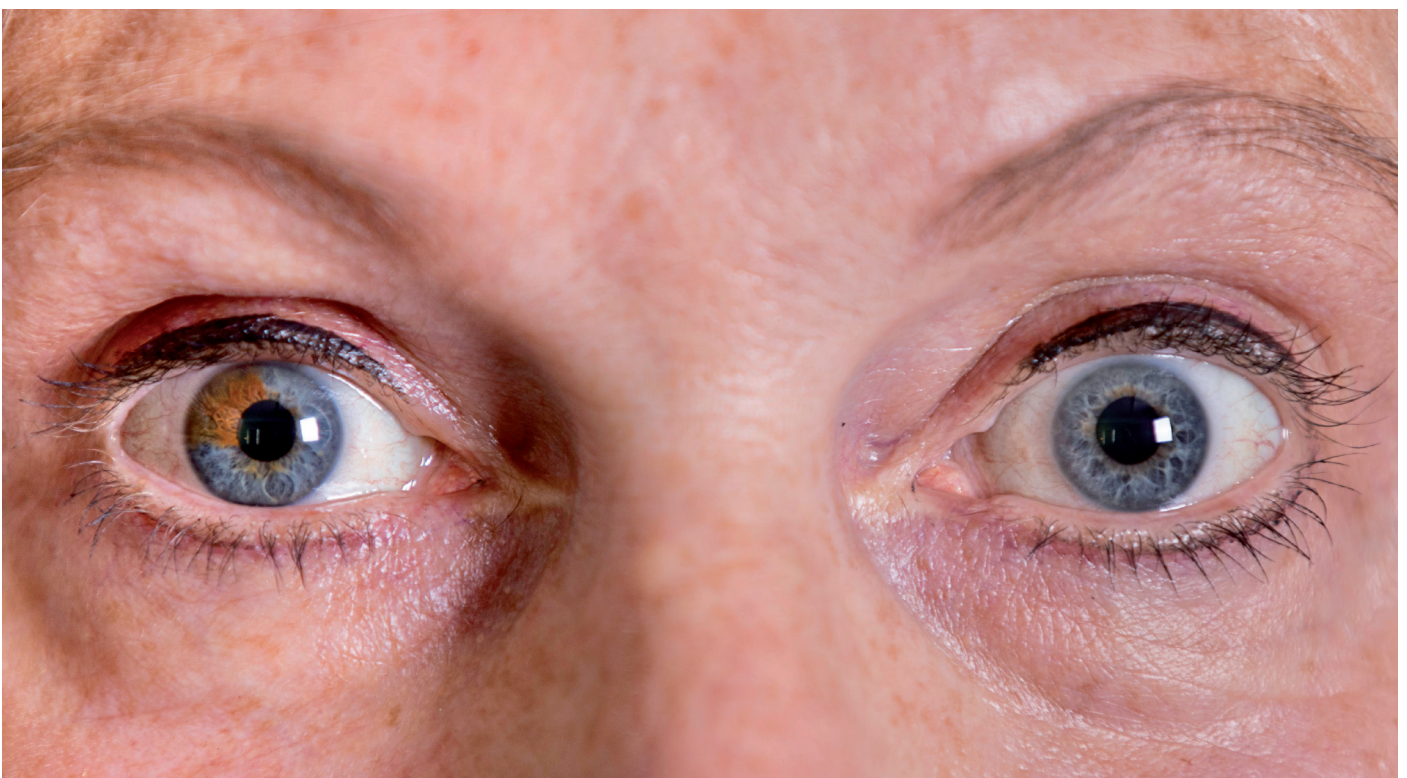GENERAL

- Over 18 years old and healthy
- No psychiatry history
- No drugs or hormones addiction
- No self-immune diseases



OCULAR

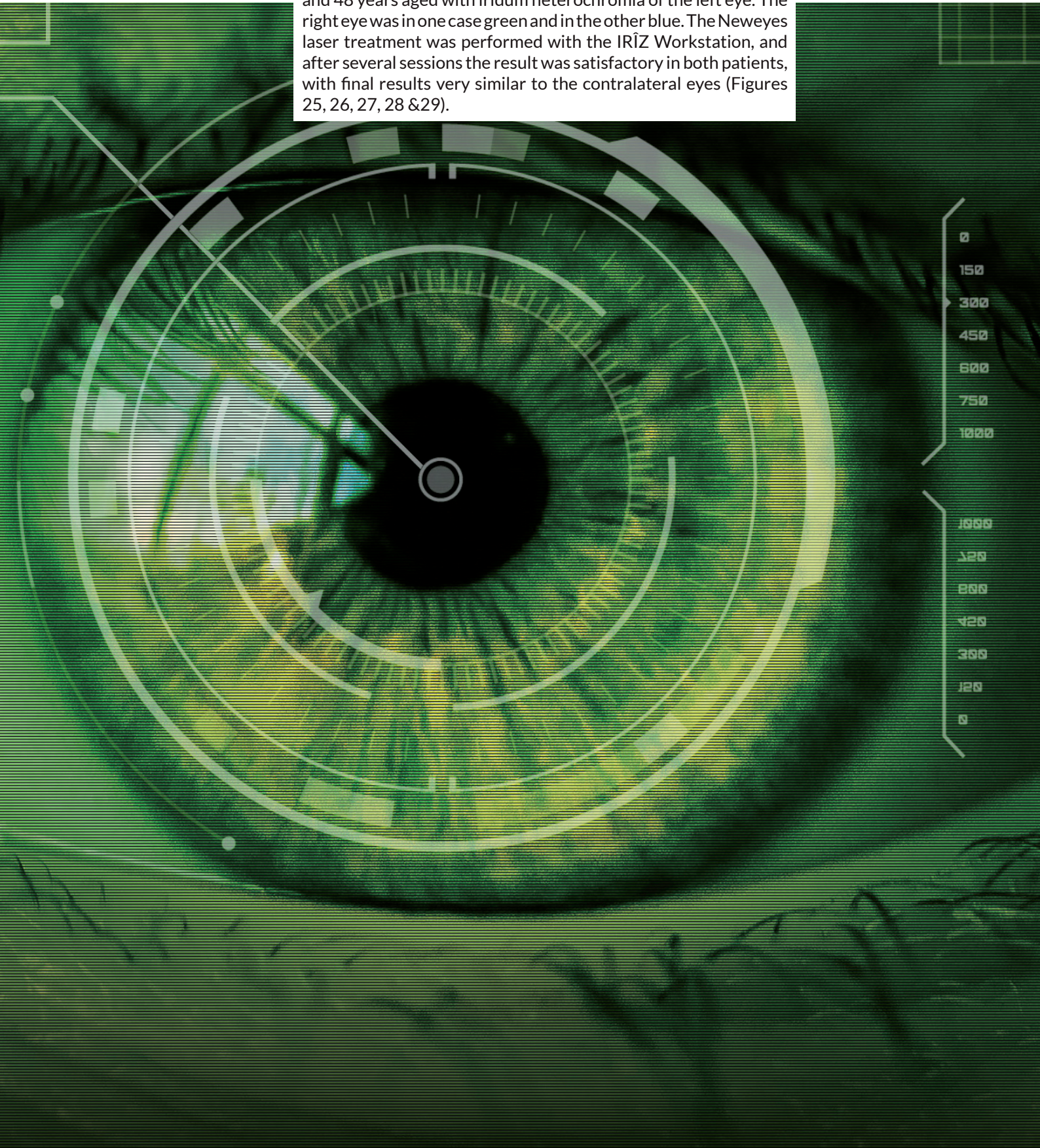
- No glaucoma history
- Eye pressure under 15mmHg
- No uveitis history
- No high refractive errors
- Not levels IV. Better pigment levels: I, II and III.



CLINICAL CASES

Two cases of complete unilateral congenital heterochromia or Iridum

The first two clinical cases correspond to two women of 30 and 48 years aged with iridium heterochromia of the left eye. The right eye was in one case green and in the other blue. The Neweyes laser treatment was performed with the IRIZ Workstation, and after several sessions the result was satisfactory in both patients, with final results very similar to the contralateral eyes (Figures 25, 26, 27, 28 & 29).



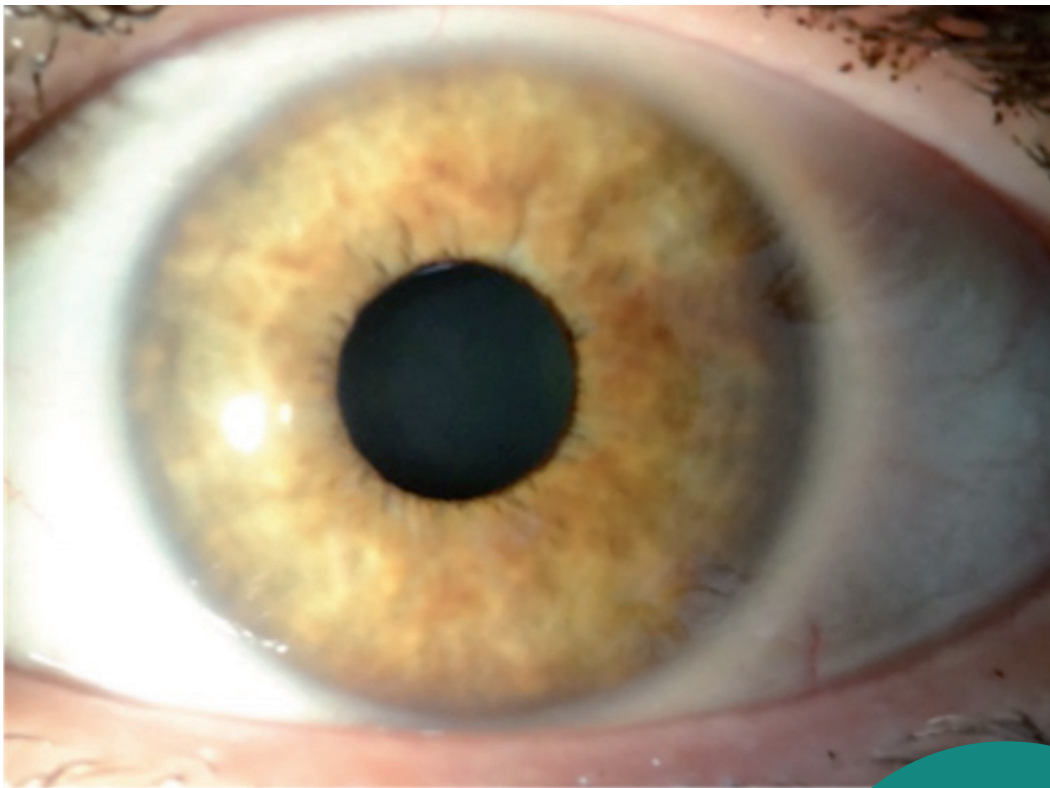


Figure 25:
Congenital heterochromia
iridum on left eye.

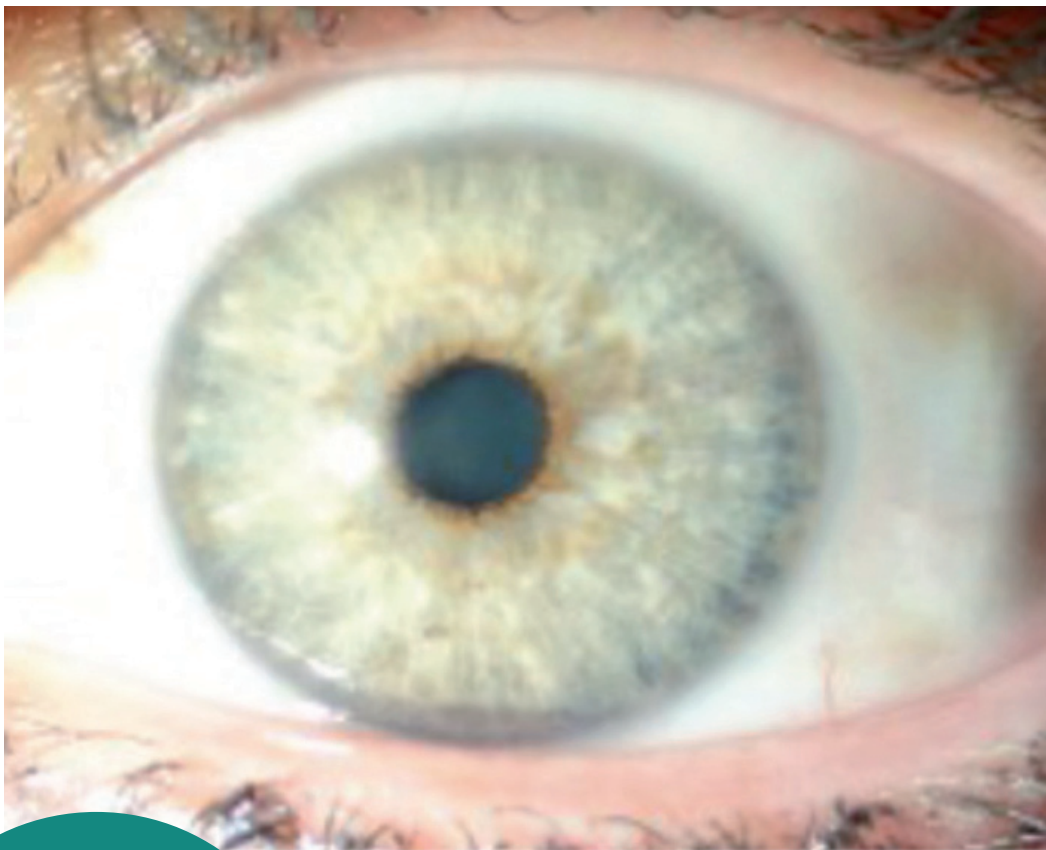

Figure 26:
Same eye of Figure 25
already treated by laser.
Light blue result

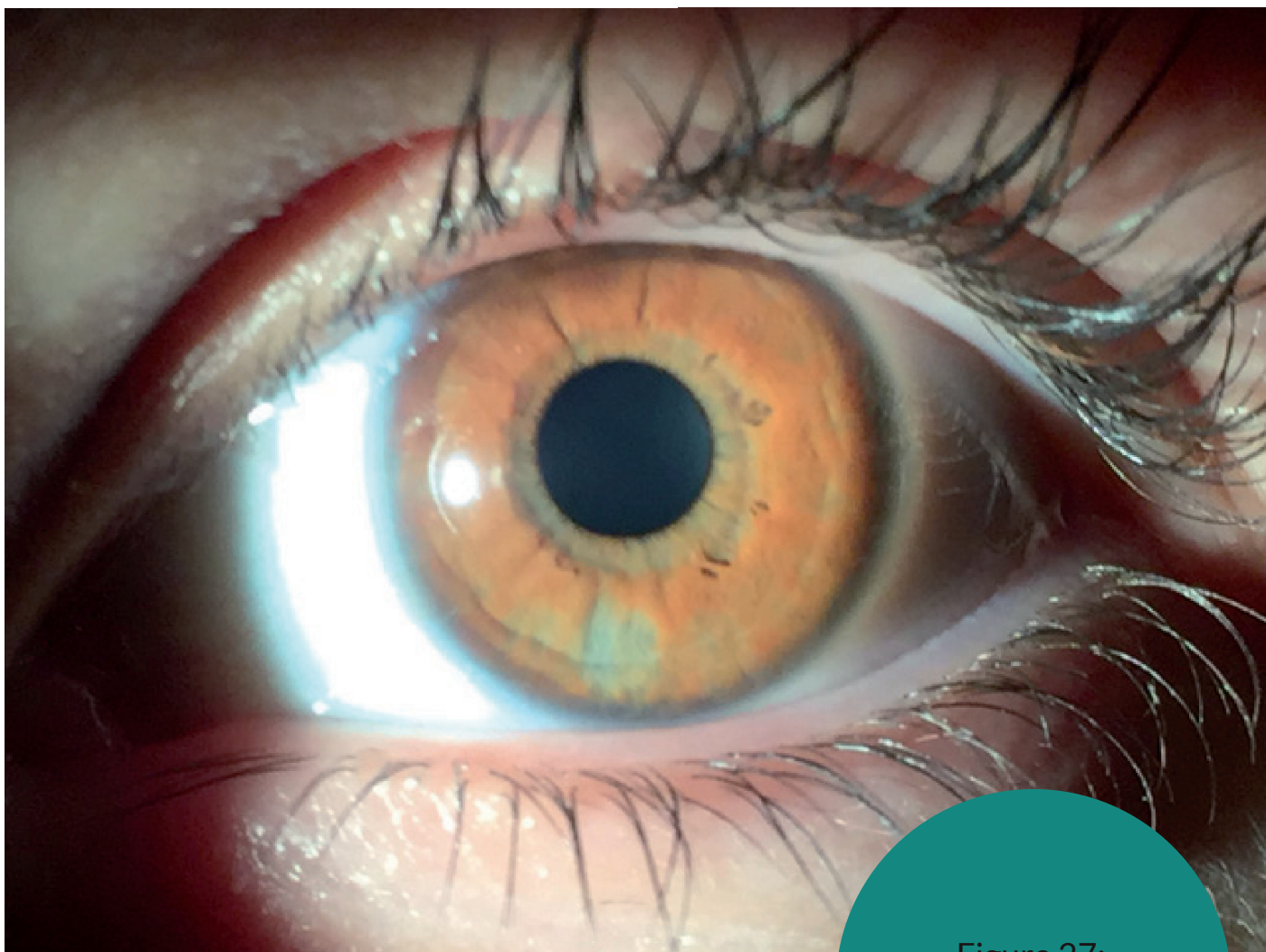


Figure 27:
Congenital heterochromia
iridum on left eye.

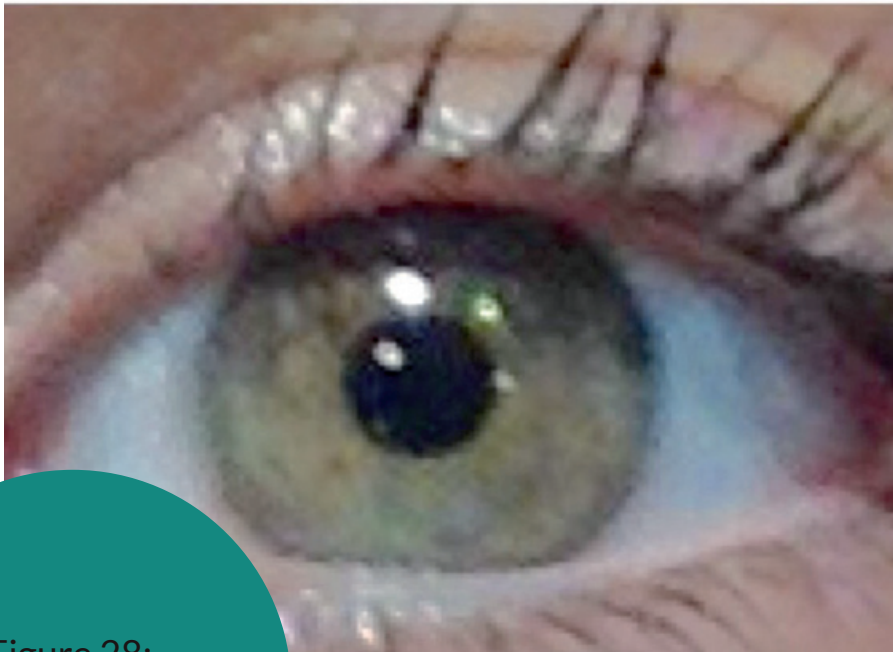
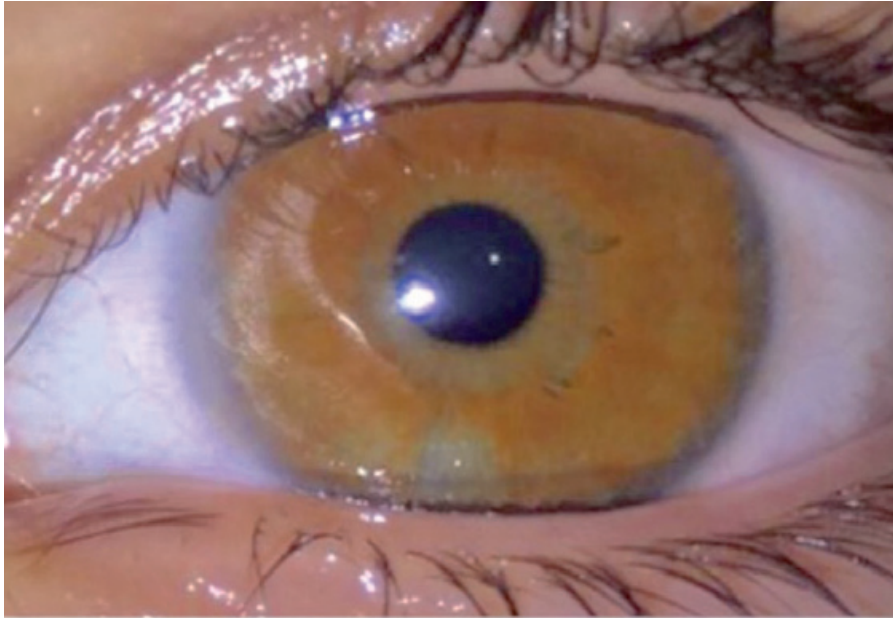


Figure 28:
Before and after laser
treatment (Figure 27)

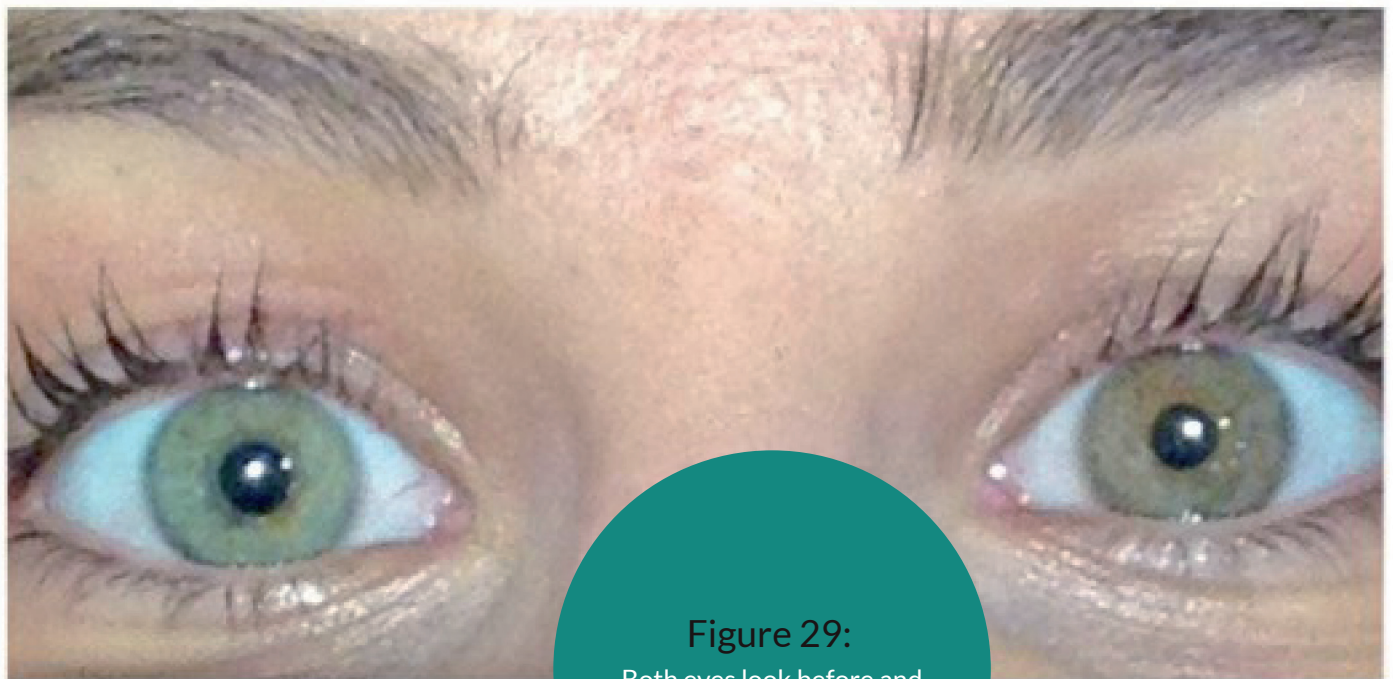
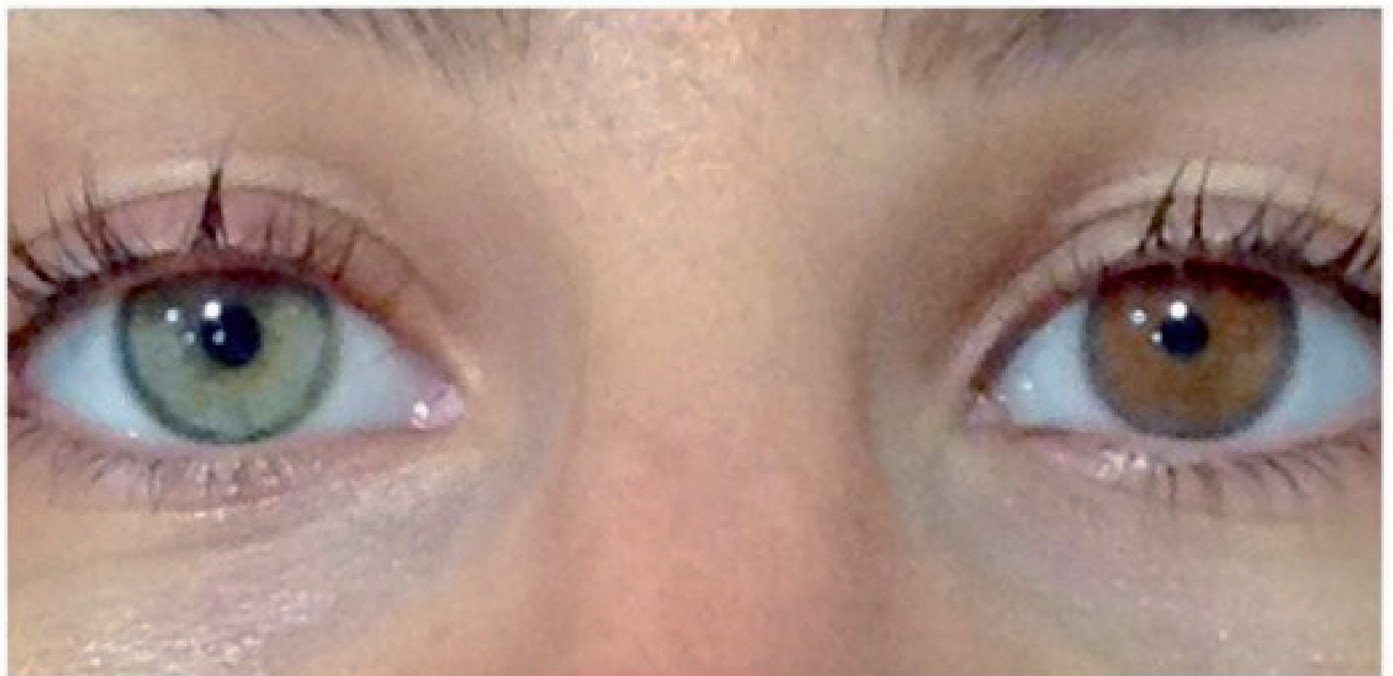
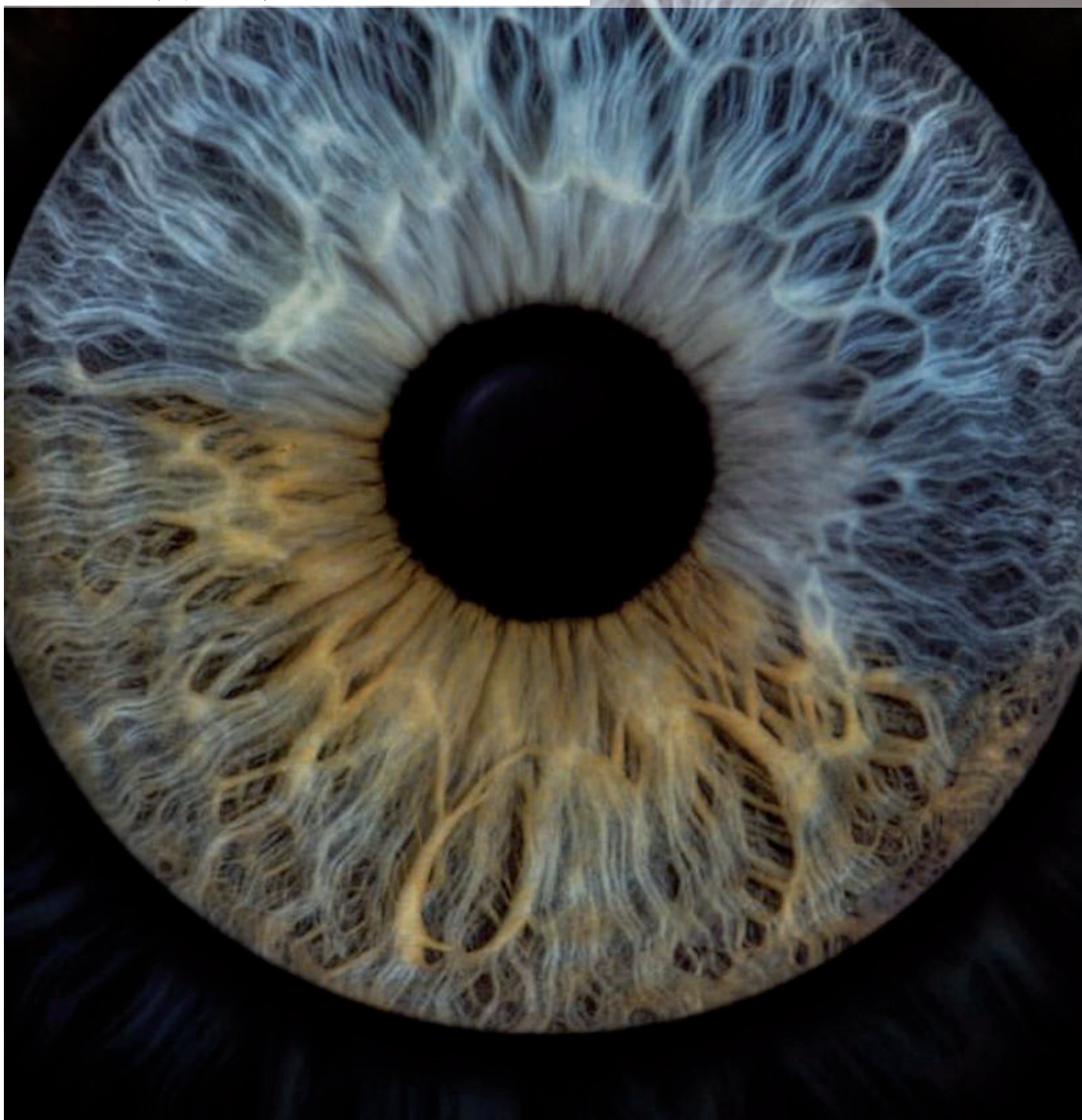
Figure 29:

Both eyes look before and after laser (Figure 27 and 28).

A CASE OF PARTIAL UNILATERAL CONGENITAL HETEROCHROMIA OR IRIDIS

The case was a 51-year-old male with partial heterochromia larger than the lower half of the left iris. The patient had a light blue right eye and the left heterochromic stain was dark brown, so the individual had spent his entire life wearing dark brown contact lenses so that no color difference was noticed between both eyes. After several laser sessions we were able to obtain an almost complete elimination of the left iridial heterochromia and finally the patient didn't need anymore cosmetic lenses (30, 31 & 32).



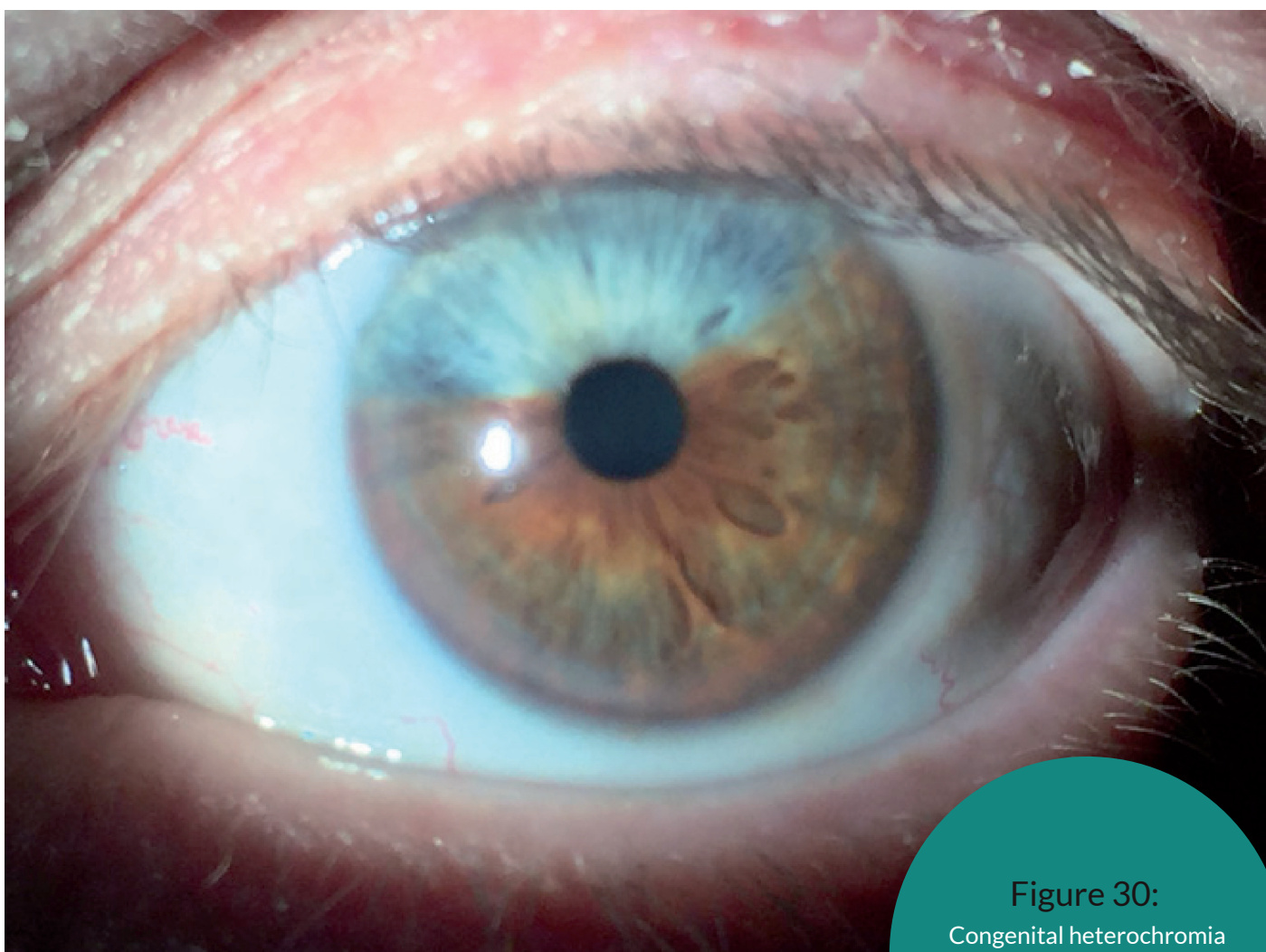


Figure 30:
Congenital heterochromia iridis is on the left eye. Stain is larger than half iris and really dark brown.

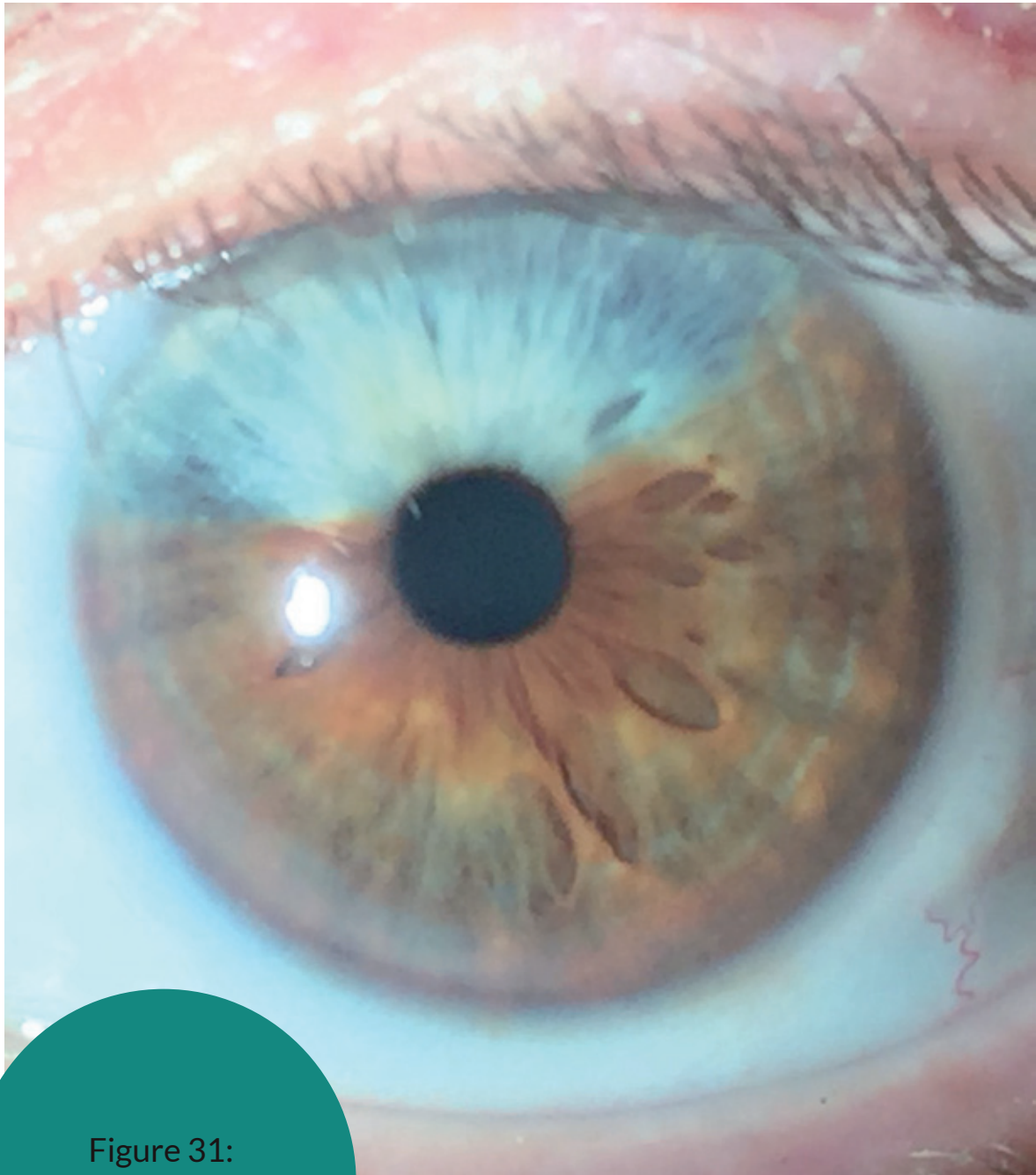

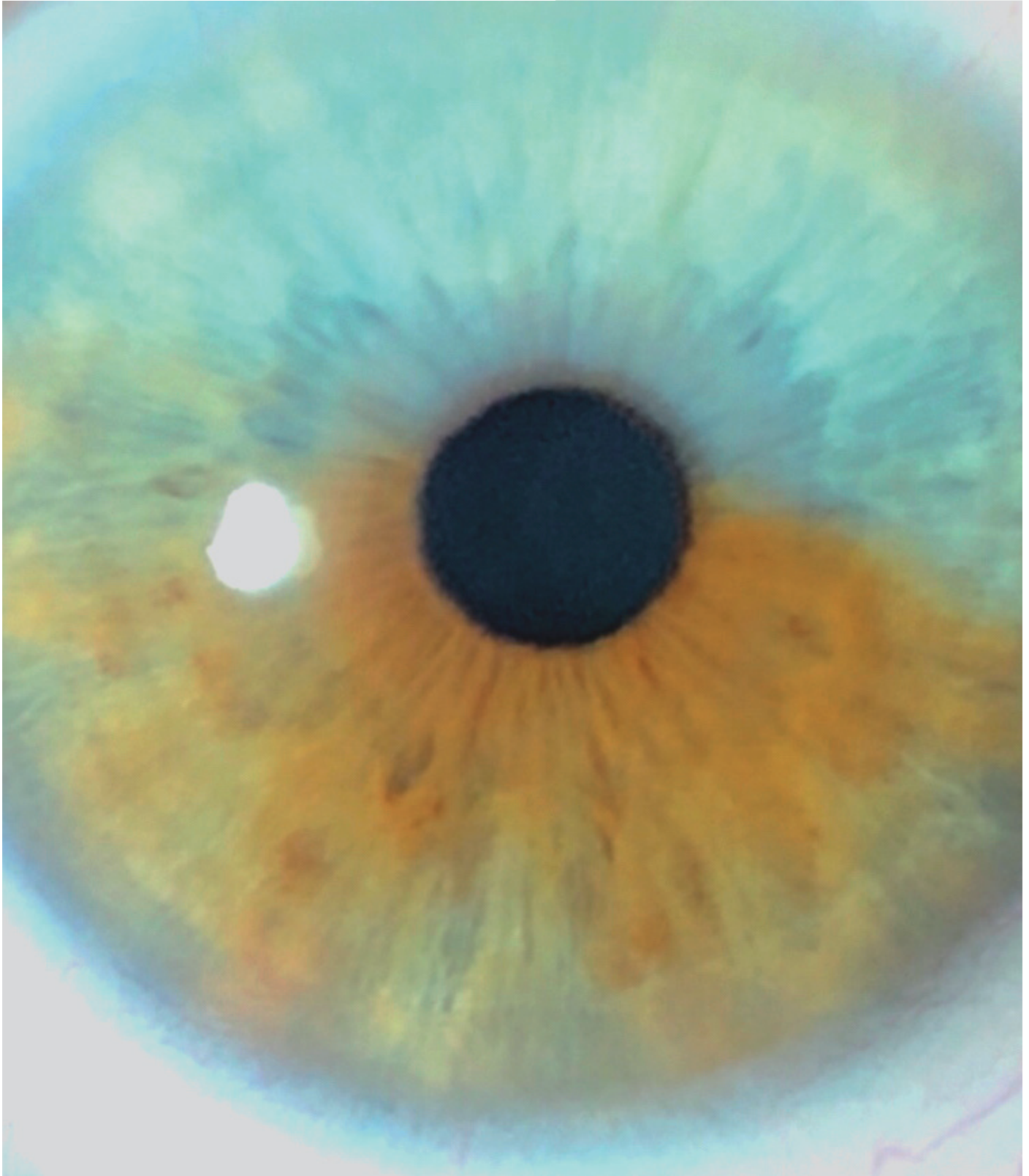
Figure 31:
Same Figure 30 but
magnified.

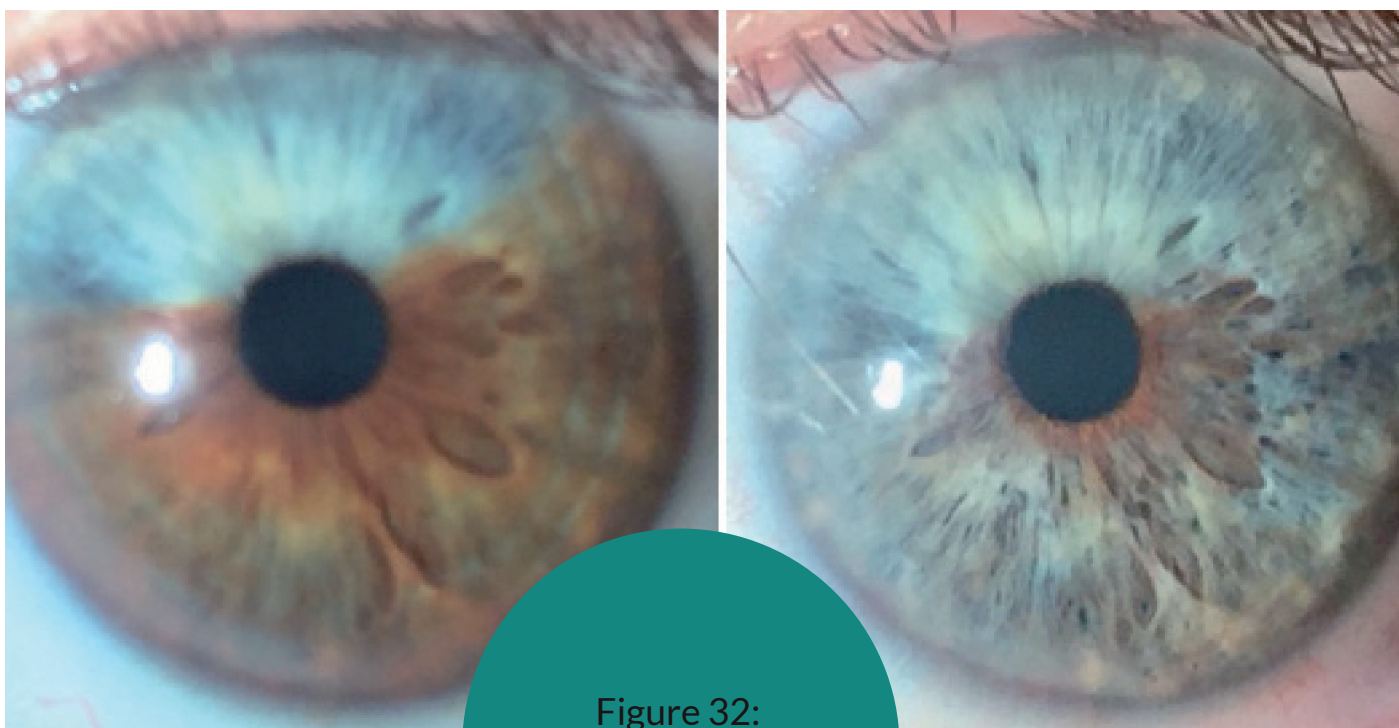

Figure 32:
Before and after change of
Figure 30 patient.

A CASE OF A LARGE UNILATERAL CONGENITAL SINGLE NEVUS

It was a 45-year-old lady with a unilateral nevus of large dimensions and medium brown color. The remaining of both eyes was light blue. Neweyes laser was applied in several sessions trying to eliminate the maximum of pigmentary tissue near the pupillary edge, which we finally achieved (Figures 33, 34 & 35).



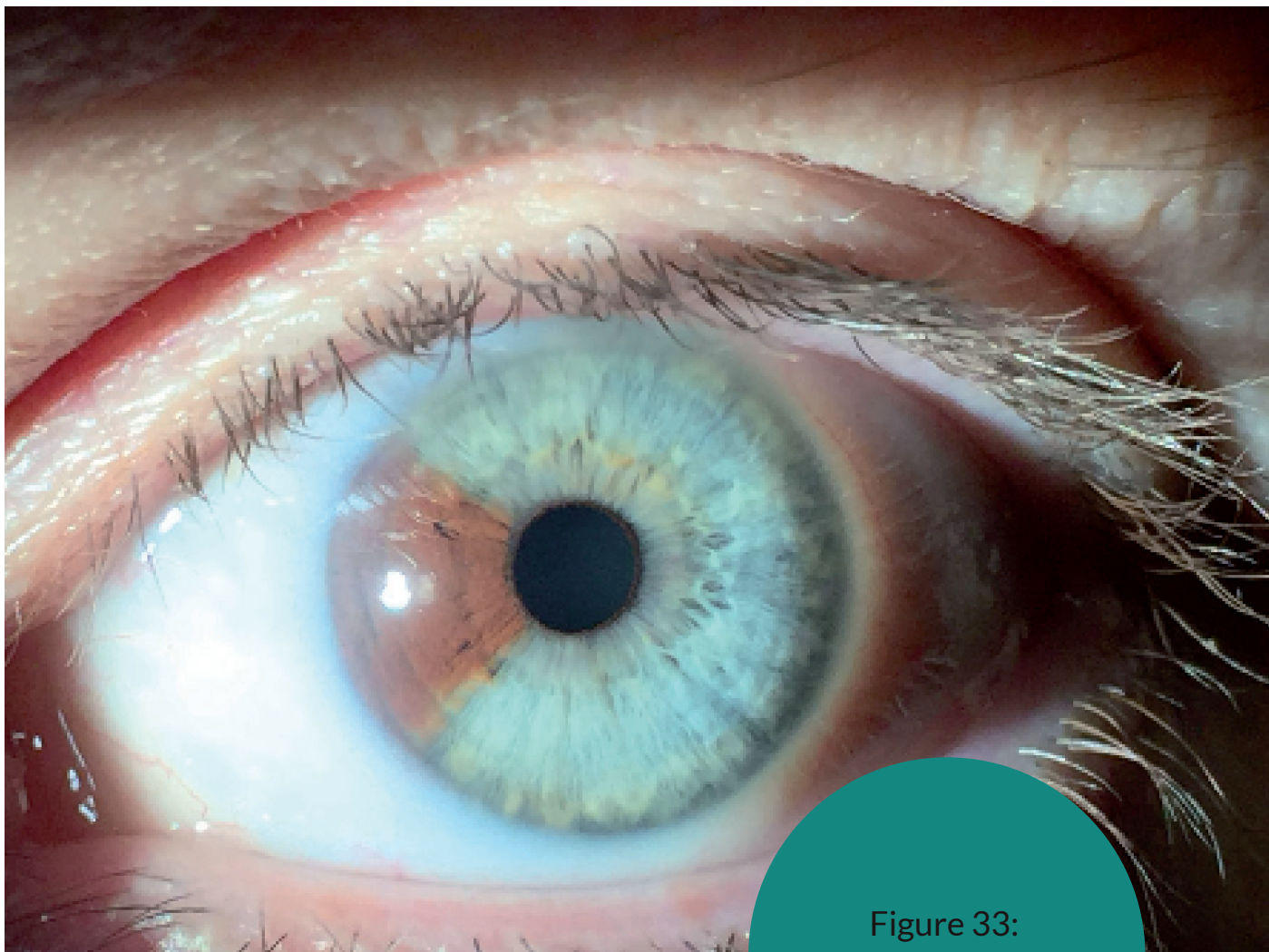


Figure 33:
Big single congenital nevus.

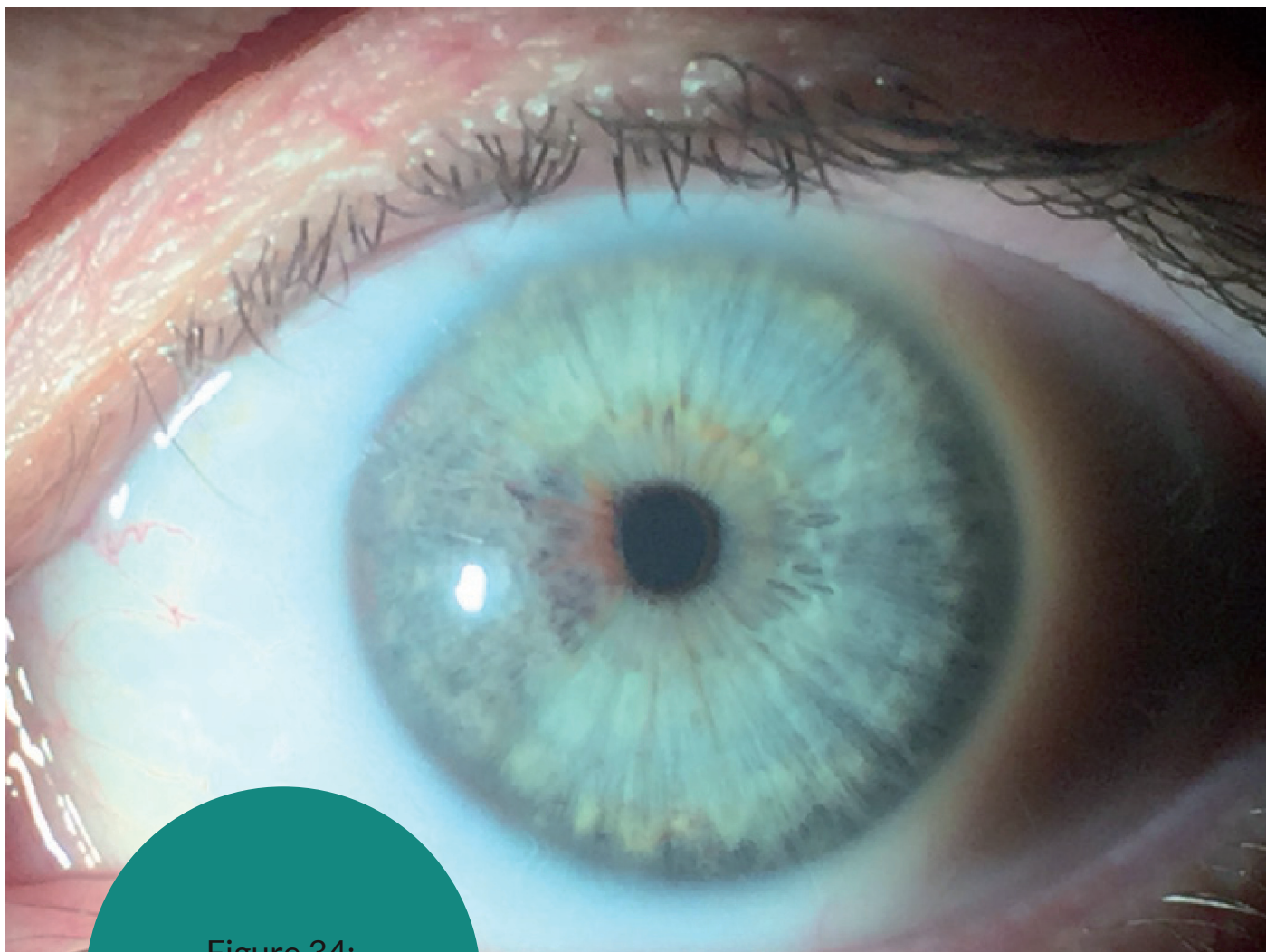


Figure 34:
Already treated nevus of
Figure 33.

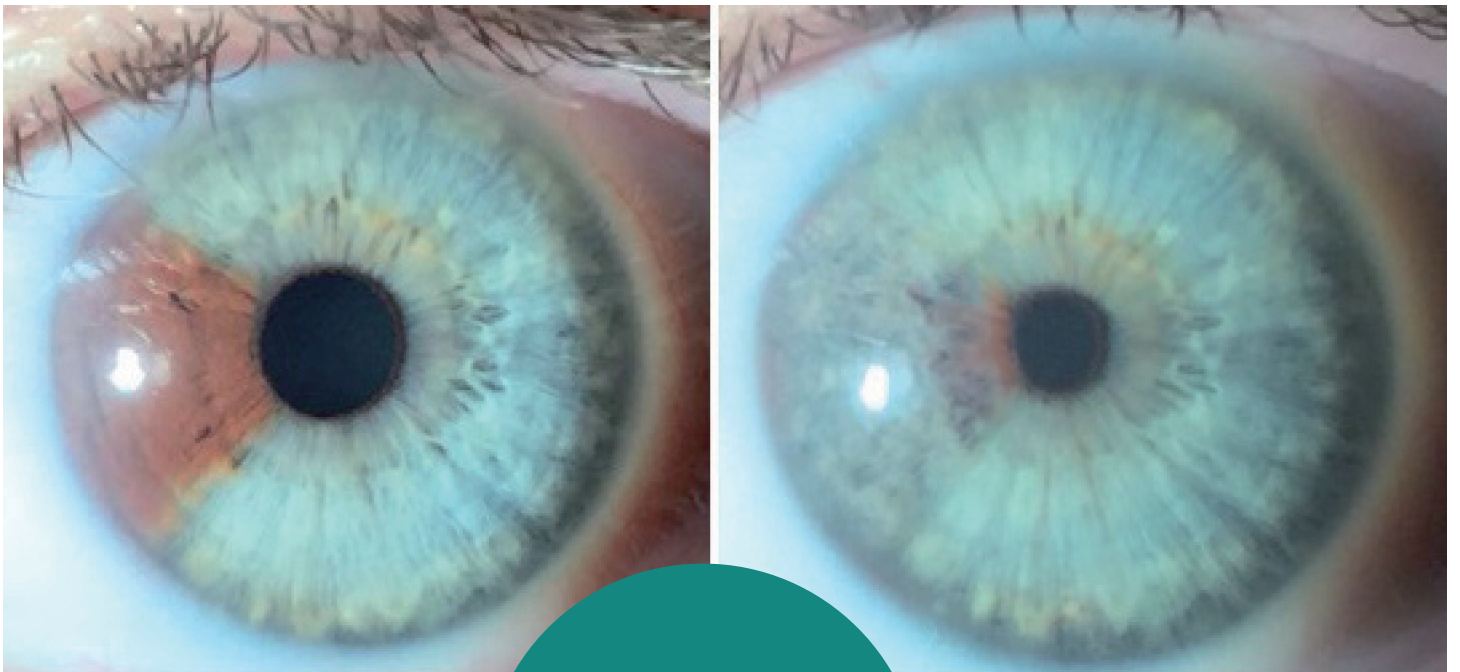
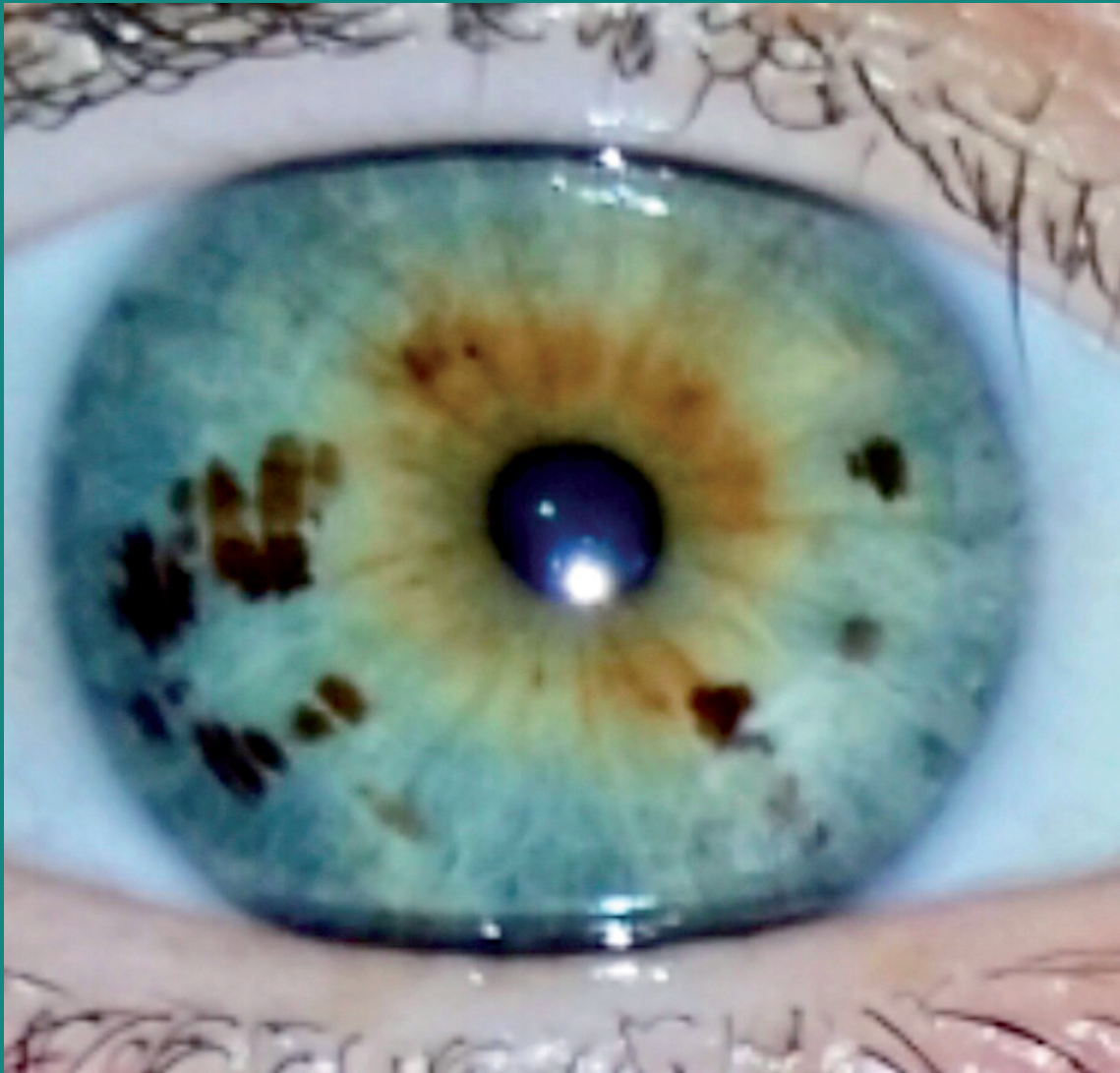


Figure 35:
Before and after laser effect
of bigcongenital nevus.

A CASE OF BILATERAL CONGENITAL MULTIPLE NEVUS

The patient was 25 years old and had multiple nevus of small size and intensity in both eyes with a green background color. All the stains were treated in 3 sessions, achieving the complete elimination of all of them (Figures 36 & 37).



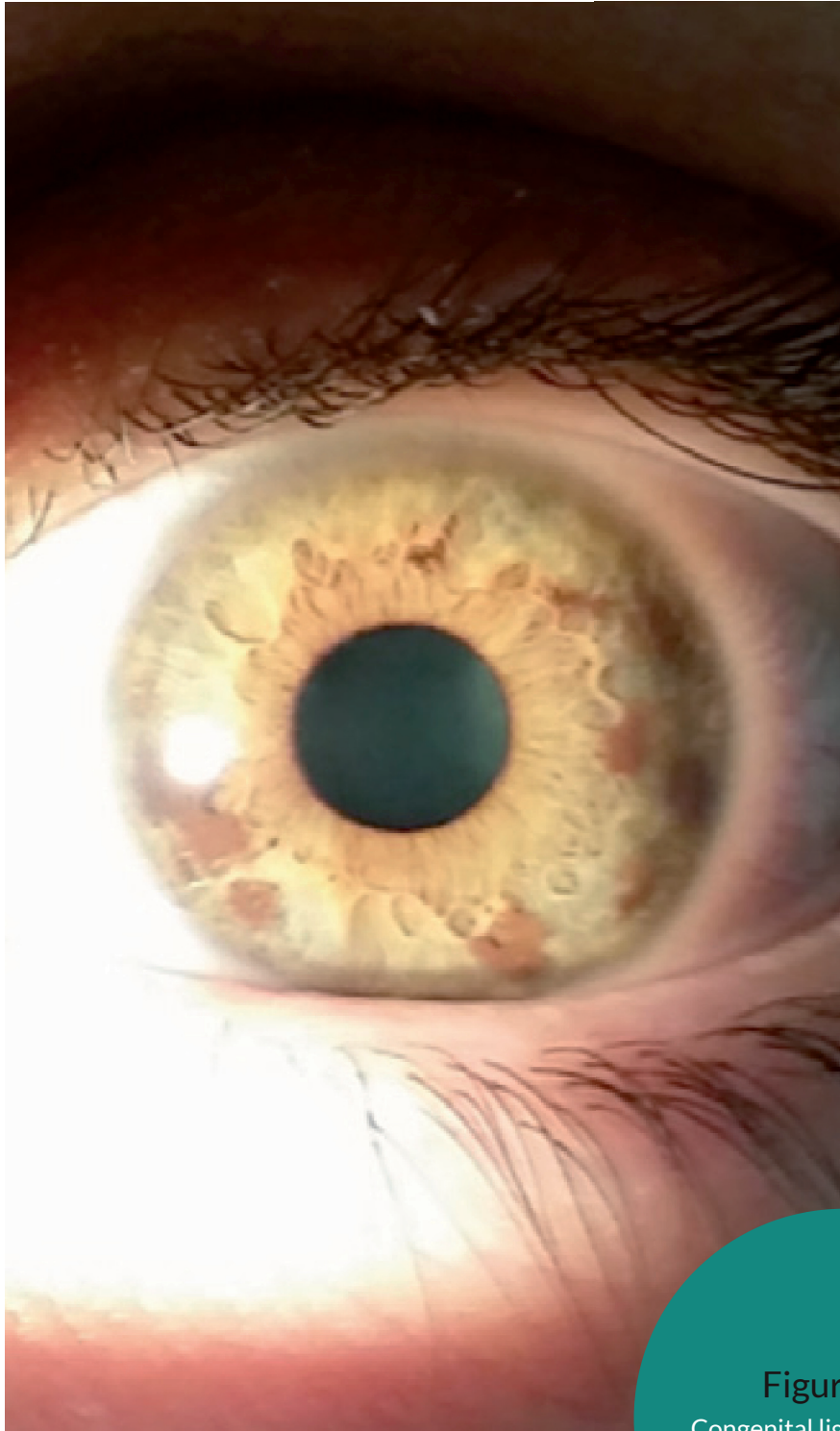


Figure 36:
Congenital light multinevus
on both eyes.

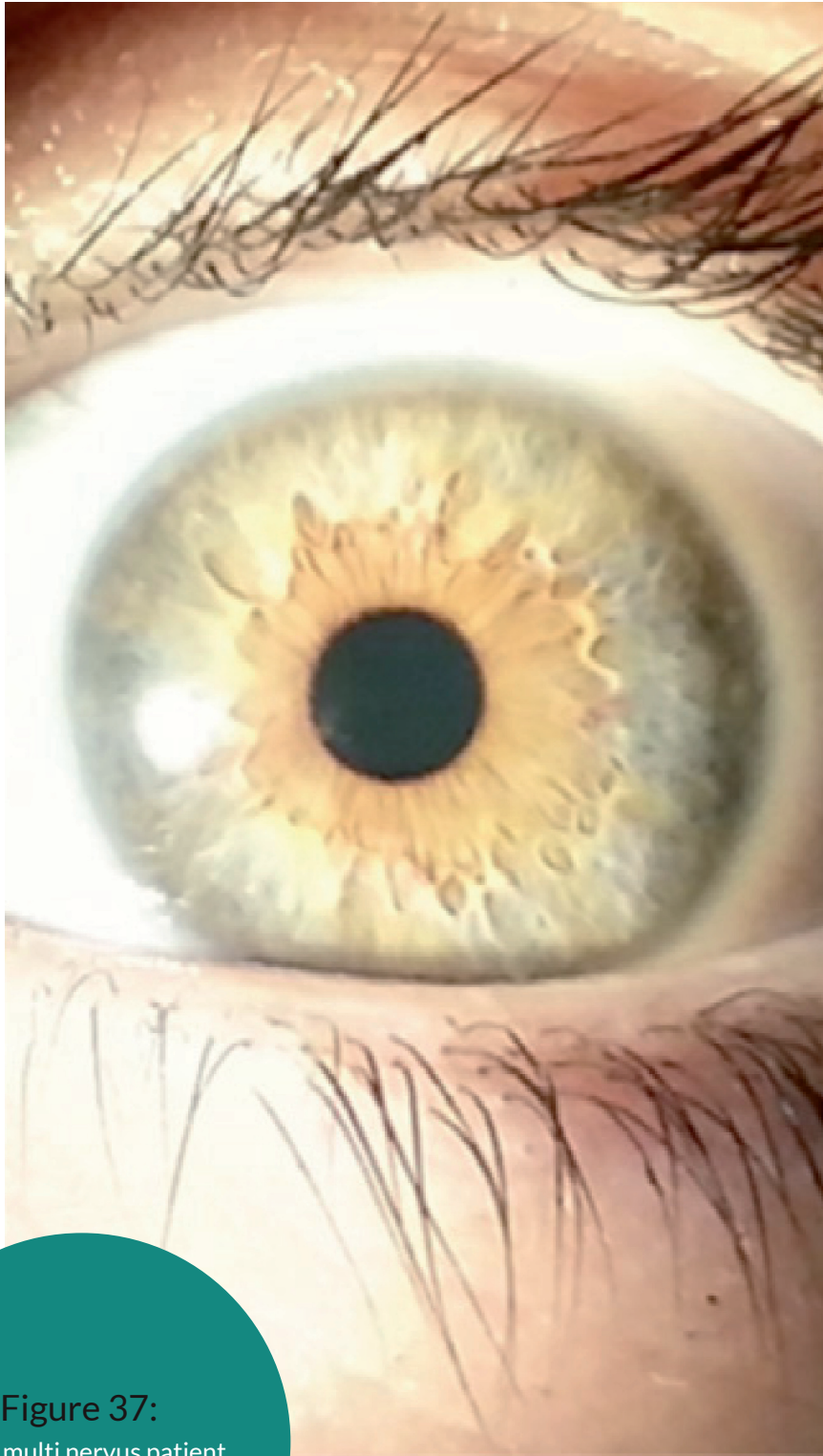

Figure 37:
Same multi nervus patient
already treated.

TWO CASES OF UNILATERAL HETEROCHROMIA SECONDARY TO COMPLICATED CATARACT SURGERY

Two cases of unilateral heterochromia secondary to complicated cataract surgery

Two cases, a 65-year-old woman and a 70-year-old man who had undergone both intracapsular congenital cataract procedures during childhood. Secondly, both suffered from unilateral complete heterochromia with the consequent aesthetic disorder. The only solution they had found useful was cosmetic contact lenses to match the coloration of both eyes. In the case of the 65-year-old lady, the total depigmentation of the operated eye could be achieved, which went from dark brown to a light blue tone (Figures 38&39). After performing the laser treatment in the 70-year-old man, the result was also satisfactory, achieving a very evident rinsing of a very dense and dark brown pigmentation (Figures 40 & 41).

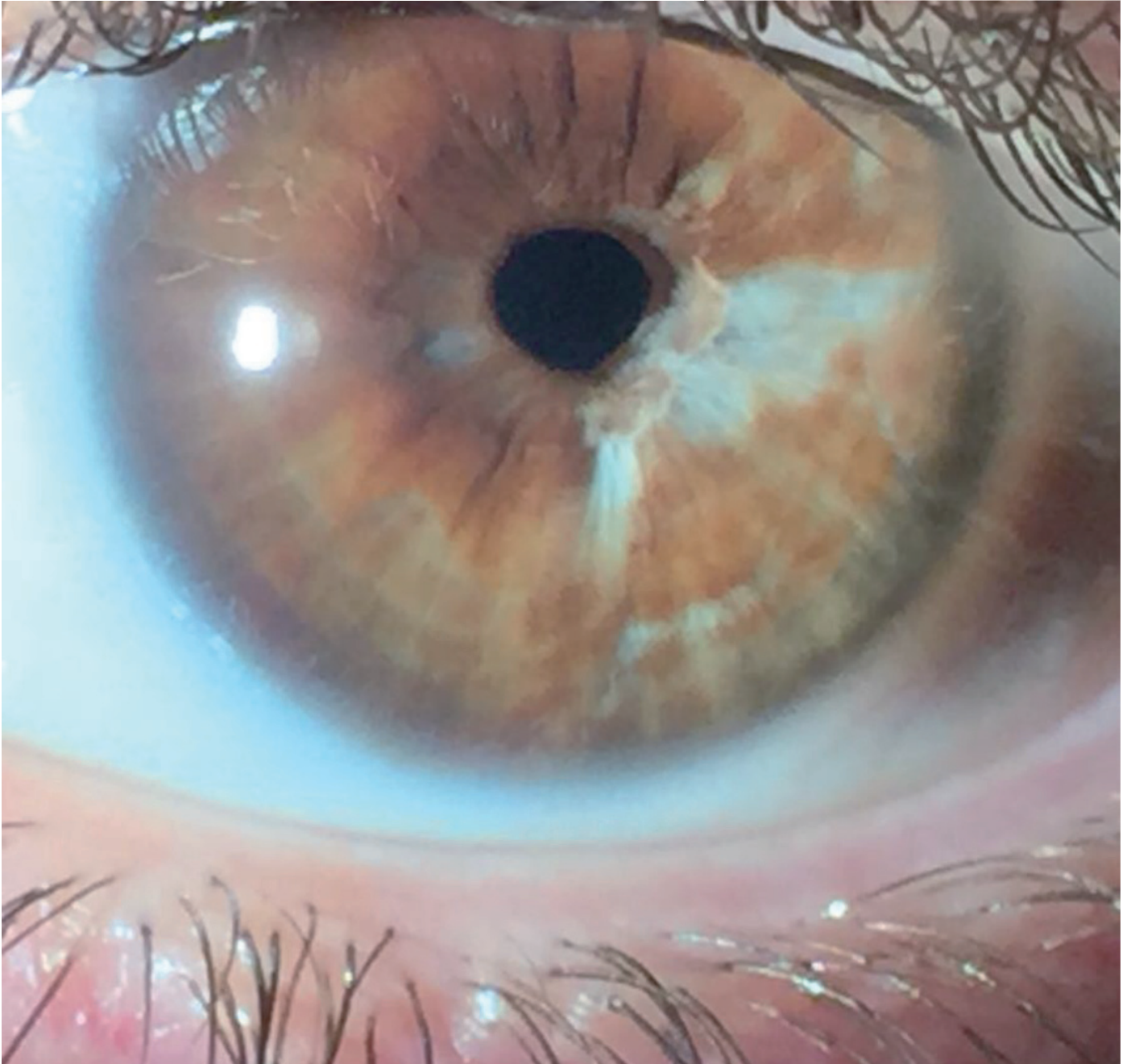

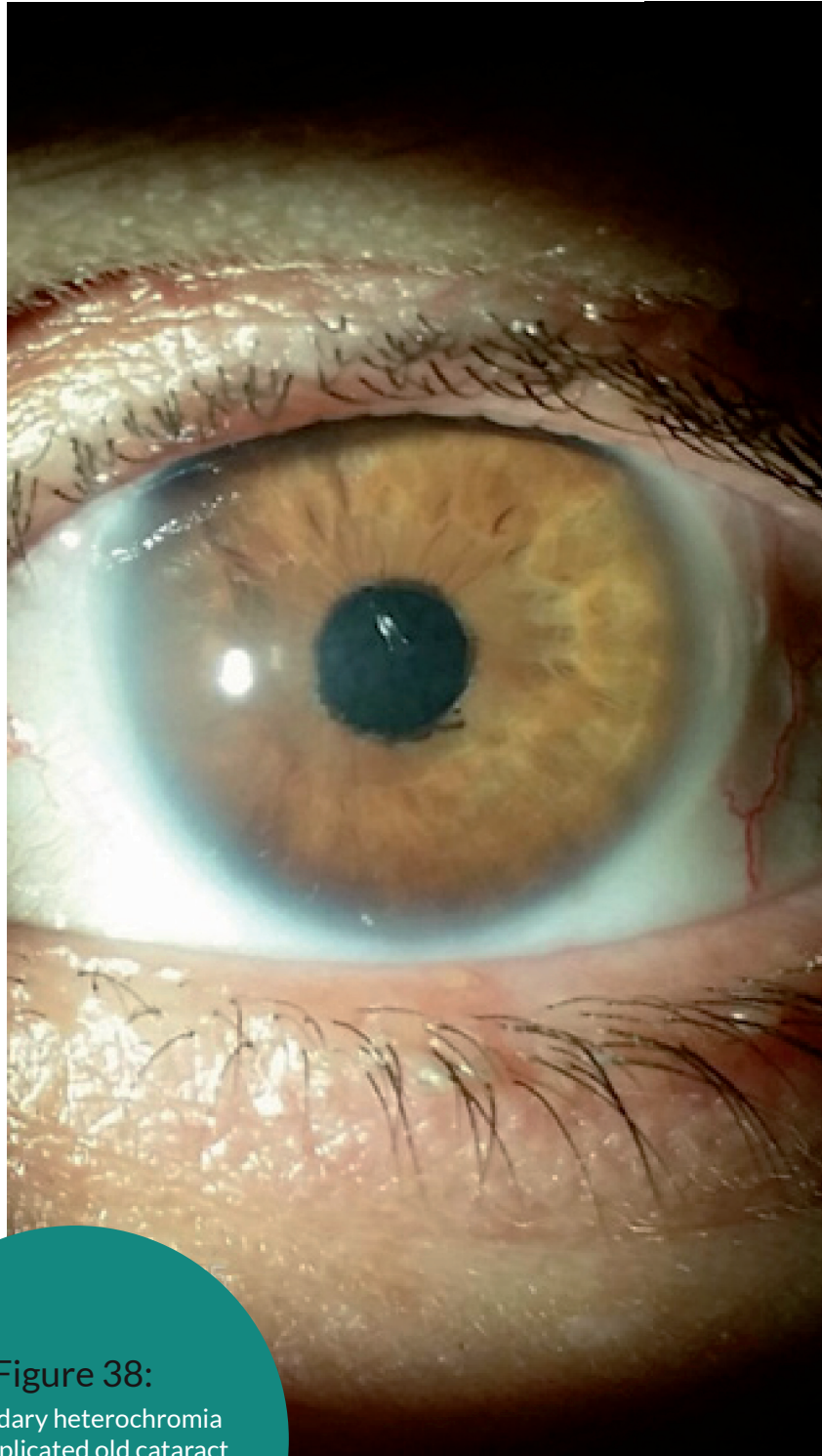


Figure 38:
Secondary heterochromia
to complicated old cataract
surgery. Really dark
pigmented iris.

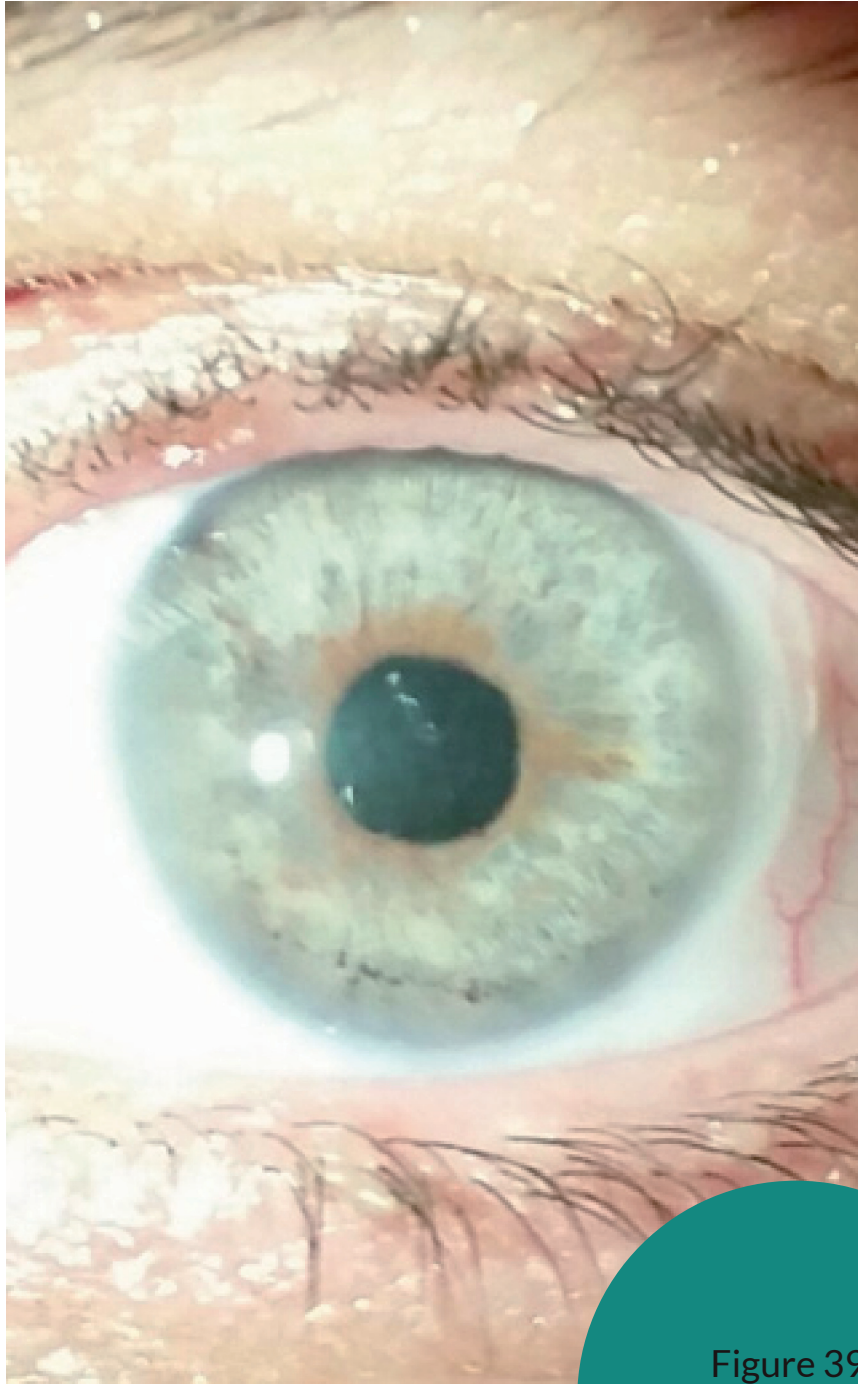

Figure 39:

Light blue outcome after
treatment of Figure 38 patient.

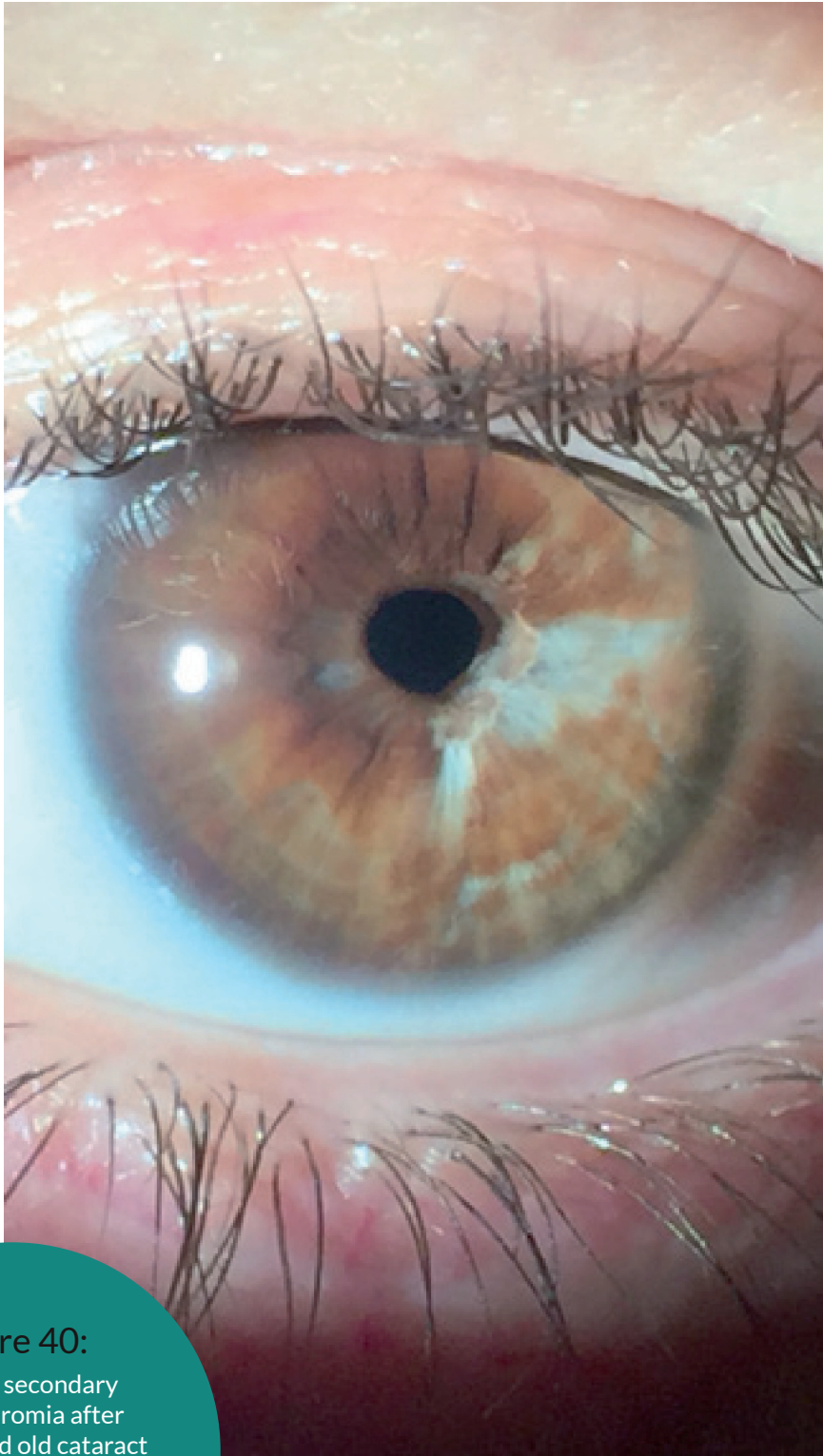


Figure 40:

Another secondary heterochromia after complicated old cataract surgery. Really dark pigmented iris too and evident tissue damage close to the pupil.

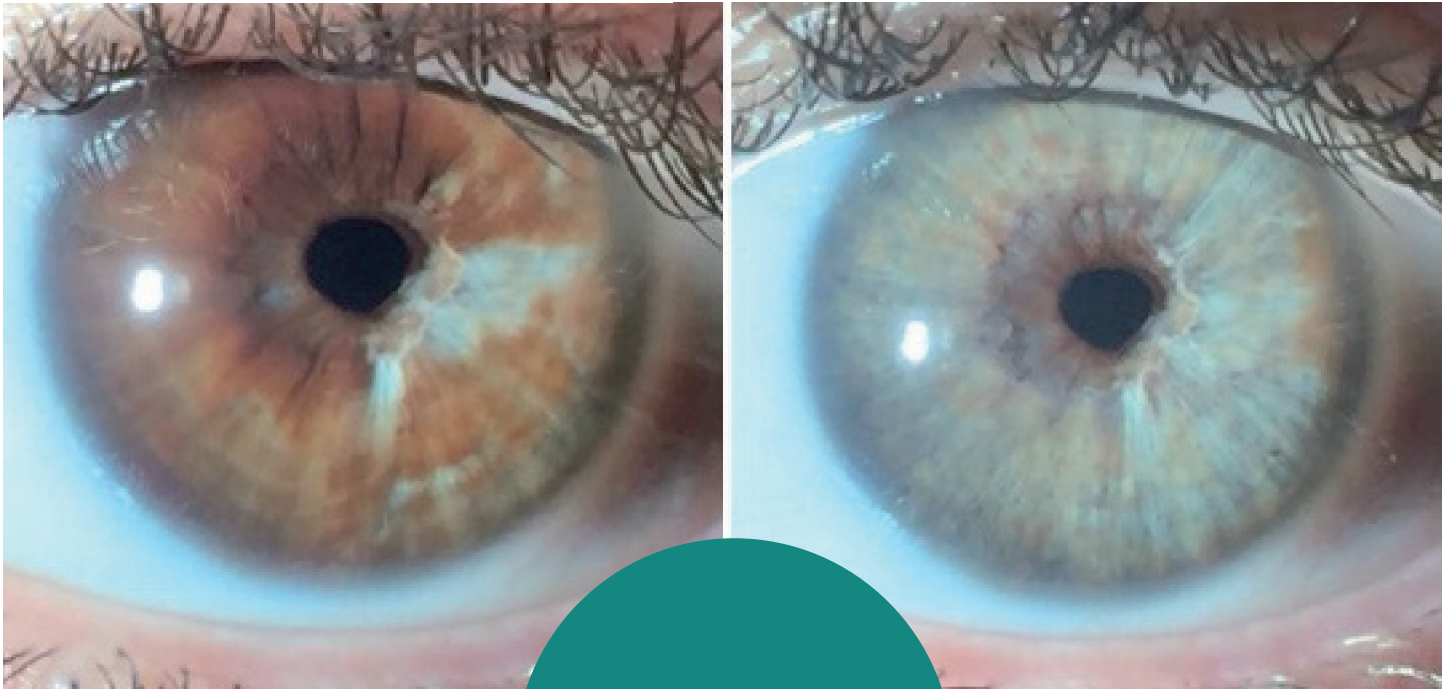
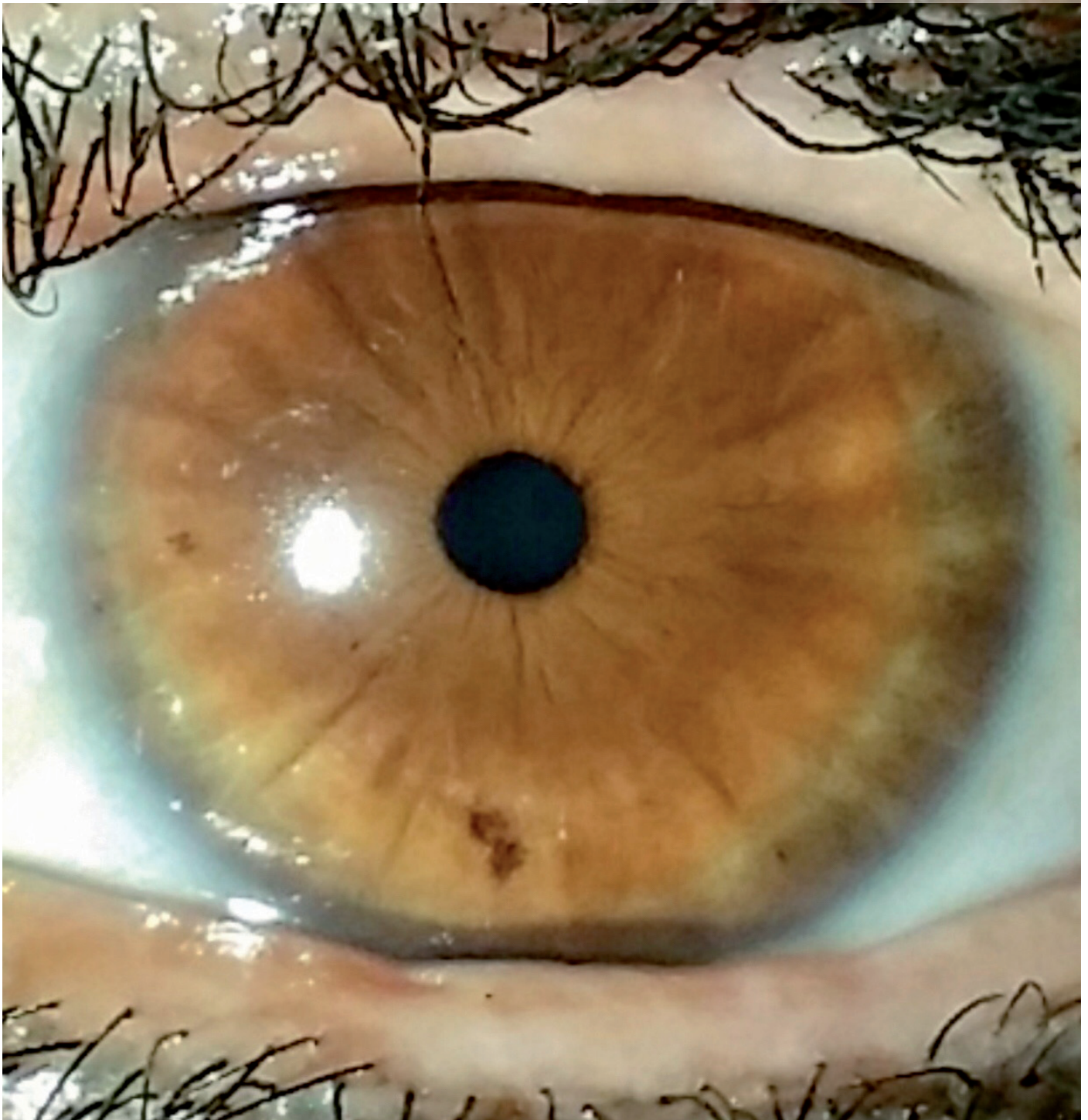
Figure 41:
Before and after laser of
Figure 40 patient.

A SECONDARY CASE TO THE ABUSE OF AESTHETIC PROSTAGLANDINS

It was a 29-year-old girl who had used drops for years to achieve a lengthening of the lashes (Latisse®). This type of serum contains prostaglandins that produce an artificial growth of the eyelashes together with their hyperpigmentation. The undesirable effect is that, when the liquid spreads to the eye, after a few months it also produces a hyperpigmentation of the iris, which can turn from light green or light blue to dark brown (Figures 42, 43 & 44).



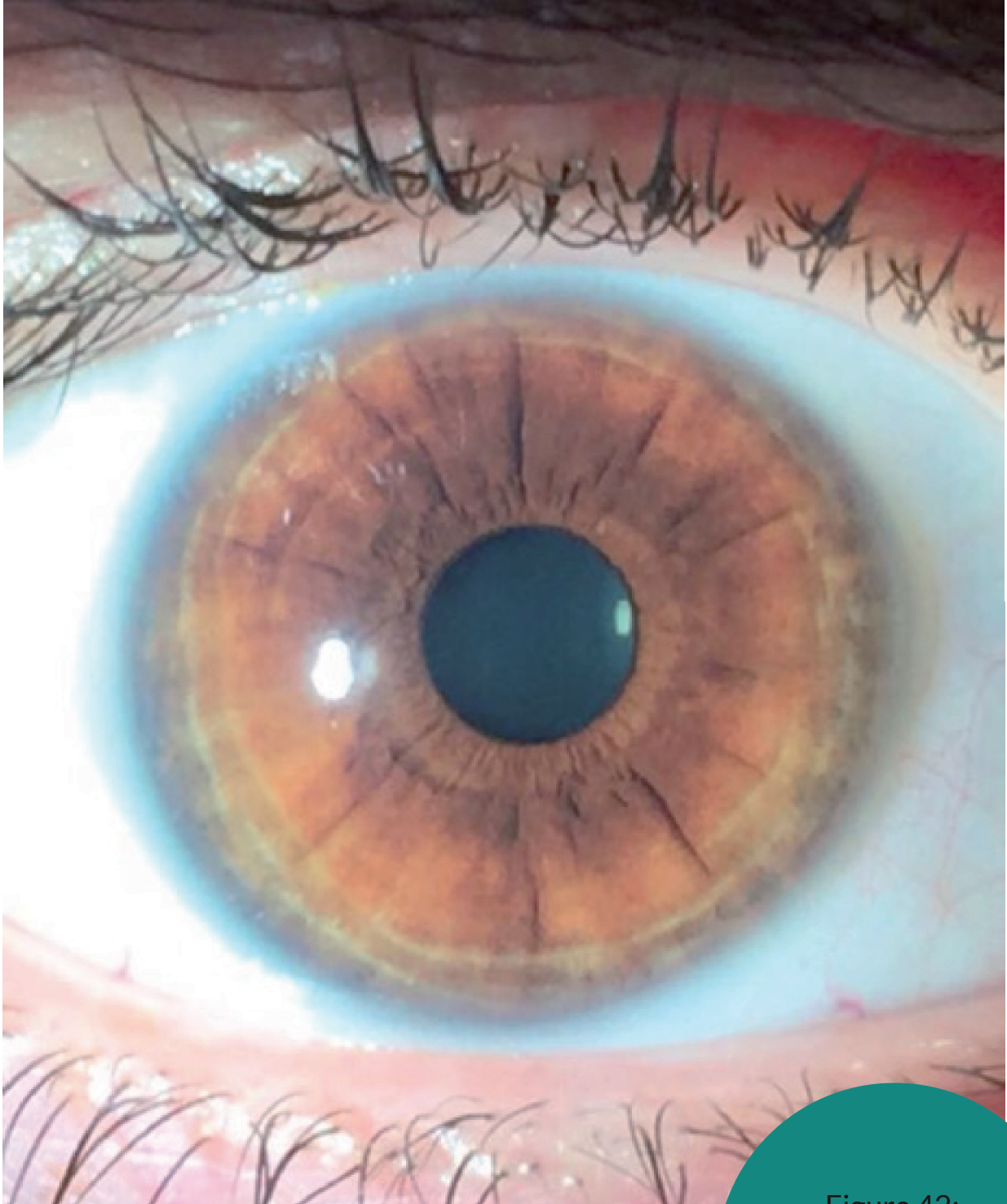

Figure 42:
Dark heterochromia
secondary to prostaglandins
abuse during some years in a
young girl.

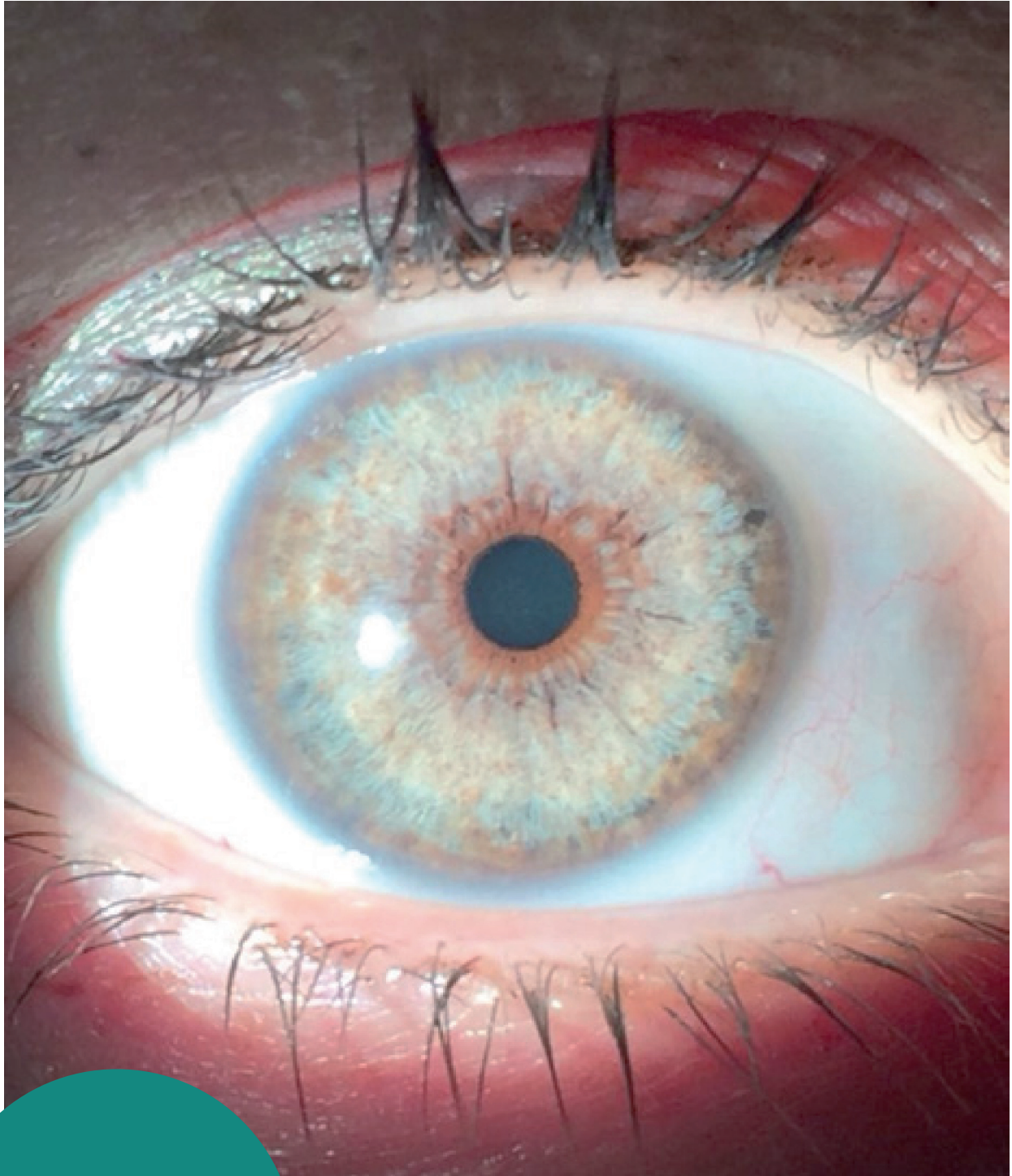


Figure 43:
Final result of
Figure 42 patient.

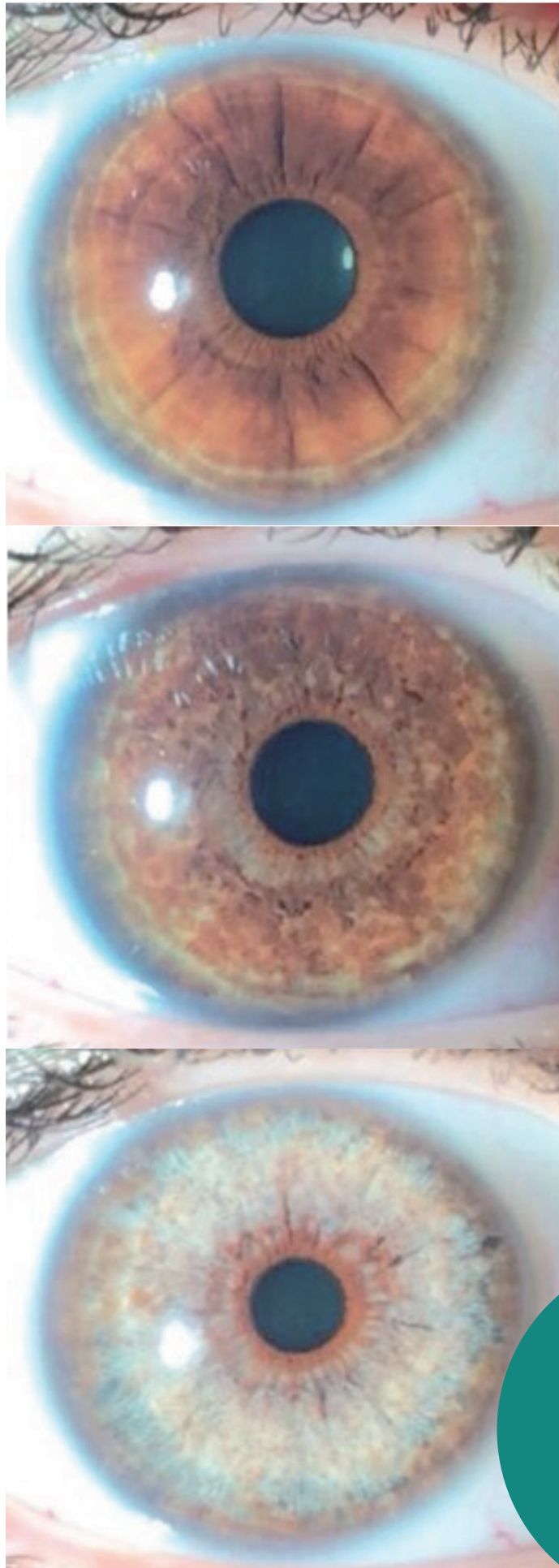


Figure 44:
Treatment follow up of
Figure 42 patient.

REFERENCES



- ❶ Steinemann TL1, Pinninti U, Szczotka LB, Eiferman RA, Price FW, et al. (2003) Ocular complications associated with the use of cosmetic contact lenses from unlicensed vendors. *Eye Contact Lens* 29: 196-200.
- ❷ Mamalis N (2012) Cosmetic iris implants. *J Cataract Refract Surg* 38: 383.
- ❸ Hoguet A, Ritterband D, Koplin R, Wu E, Raviv T, et al. (2012) Serious ocular complications of cosmetic iris implants in 14 eyes. *J Cataract Refract Surg*. 38: 387-393.
- ❹ Galvis V, Tello A, Corrales M (2016) Postoperative results of cosmetic iris implants. *Jcataract Refract Surg* 42: 1518-1526.
- ❺ Shah R, Randleman J (2012) New color iris implants. *Ophthalmology* 119: 1495-1495.
- ❻ Sikder S, Davis S, Holz H, Moshirfar M (2011) Complications of New Color Iris Implantation in phakic eyes: a review. *Clin Ophthalmol* 5: 435-438.
- ❼ George M, Tsai J, Loewen N (2011) Bilateral irreversible severe vision loss from cosmetic iris implants. *Am J Ophthalmol* 151: 872-875.
- ❽ Arthur SN, Wright MM, Kramarevsky N, Kaufman SC, Grajewski AL, et al. (2009) Uveitis-glaucoma-hyphema syndrome and corneal decompensation in association with cosmetic iris implants. *Am J Ophthalmol* 148: 790-793.
- ❾ Thiagalingam S1, Tarongoy P, Hamrah P, Lobo AM, Nagao K, et al. (2008) Complications of cosmetic iris implants. *J Cataract Refract Surg* 34: 1222-1224.
- ❿ Garcia-Pous M, Udaondo P, Garcia Delpech S (2011) Acute endothelial failure after cosmetic iris implants (NewIris). *Clin Ophthalmol* 5: 721-723.
- ⓫ Malik S, Ghauri A, Al-Mousa R (2014) Removal of artificial iris implants due to bilateral angle closure glaucoma and corneal decompensation. Presented at the XXXII Congress of the European Society of Cataract and Refractive Surgeons. London, UK. September.
- ⓬ Mansour AM, Ahmed II, Eadie B, Chelala E, Saade JS, et al. (2016) Iritis, glaucoma and corneal decompensation associated with Bright Ocular cosmetic iris implant. *Br J Ophthalmol* 100: 1098-1101.
- ⓭ Anderson J, Grippo T, Sbeity Z, Ritch R (2010) Serious complications of cosmetic New Color Iris implantation. *Acta Ophthalmol*. 88: 700-704.
- ⓮ Yildirim Y, Duzgun E, Kar T, Sonmez M, Kucukodaci Z, et al. (2016) Evaluation of color-changing effect and complications after Nd: YAG laser application on iris surface. *Med Sci Monit* 22: 107-114.
- ⓯ Basoglu A, Çelik U (2017) The effect of SLT laser application on iris to treat sectorial heterochromia: A promising technique. *Eye Contact Lens* 1: S352-S354.



CORPORATION
EUROPA - AMÉRICA

www.eyecos.eu
www.eyecosamerica.com
Emails:
info@eyecos.eu
info@eyecosamerica.com

NEW
EYES
LASER
BY EYECOS

EyeCos Clinic in Barcelona has the only safe laser for changing eye color with amazing outcomes. La Clínica Eyecos de Barcelona dispone del único láser seguro para el cambio del color de los ojos con unos resultados increíbles.