

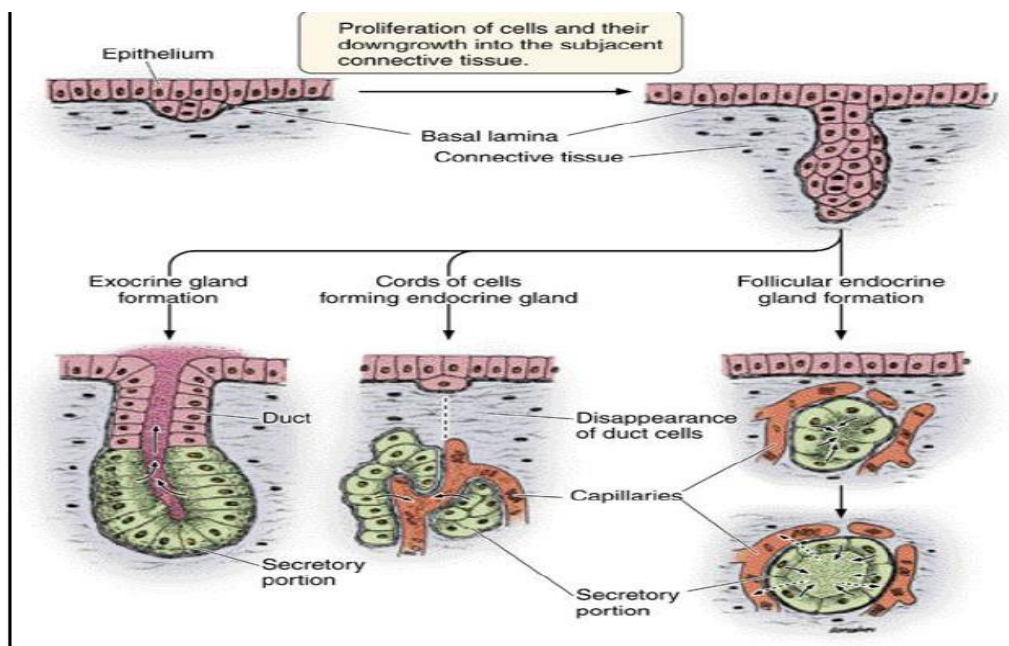
## Glandular Tissue

Epithelial glands are structures derived from epithelial cells that specialize in producing secretion, they usually develop as invagination / in growths into the underlying connective tissue.

Glands are organized arrangement of secretory cells, the molecules to be secreted are generally stored in the cells in small membrane – bound vesicles' called secretory granule. Glandular cells obtain substances needed from blood and transform them (chemically) into a product that's discharged from the cell.

### Types of glands:

During fetal development epithelial cells proliferate and penetrate the underlying connective tissue, they may or may not maintain connection with surface epithelium. When the connection is maintained, exocrine glands are formed, with the connection lost endocrine glands are formed, so the glands classified into three major groups on the basic of method of distribution of their secretory products:



## **1-Exocrine glands:**

Are derived from specialized epithelial cells have secretory portion and ducts that transport the product to the exterior of the glands. The duct may be made of squamous to stratified columnar cells, while the secretory portion may be shaped like test tube (tubular) or as a flask (acina) which is a small ball of secretory epithelial cells containing a tiny central lumen.

Every exocrine secretory cell has some portion of its plasma membrane exposed to external surface, communicating with the outside of the body by system of ducts. Exocrine glands secrete their substances through a ductal system such as salivary glands, sweat glands and glands within gastrointestinal tract.

### **Function of Exocrine Glands**

There are many functions of exocrine glands including regulate body temperature, lubricate, nurture newborns (lactation), aid in digestion, and aid in reproduction.

## **2-Endocrine glands:**

Also derived from specialized epithelial cells but the connection to the exterior duct has disappeared.

Endocrine cells are typically aggregate as cords which passes their secretion into blood vesicles such as ( adrenal gland) ,or follicle which is epithelial cells called follicular cells surround a cavity or vesicle fill with non cellular material called( hormone ) which used to control most major body functions from simple needs like hunger to complex system like metabolism, excretion, stress, growth and development, reproduction , digestion, so endocrine glands control the hormone production where the hormones stay in the gland until the body calls on them.

The major glands of the endocrine system include the pineal gland, pituitary gland, ovaries, testes, thyroid gland, parathyroid gland and adrenal gland.

### **3- Mixed glands:**

In this glands group of cells secrete into duct and another group of cell secrete into blood stream e.g. (pancreas, liver, ovary).

Pancreas which has exocrine function in digestion of food and endocrine function in regulate blood sugar.

### **Classification of exocrine glands**

Exocrine glands can be classified into different types of glands according to various criteria:

#### **A-The glands are classified according to the number of the cells into**

##### **1-Unicellular glands:**

Isolated secretory cells made of only one glandular epithelium cell; called intraepithelial cells located in anon secretory epithelium, e.g., goblet cells among absorption cells in intestinal epithelium.

##### **2-Multicellular gland:**

Multiple cells make up one gland; called extra epithelial cells, it is composed of cluster or groups of cells highly specialized for secretion. This gland is surrounded by capsule of c.t., and from capsule, septa of c.t., extend into the gland to dividing it into lobes. Each lobe is subdivided by finer c.t. into lobules .Blood vessels and lymphatic vessels and nerves of glands have distribution similar to that of c.t.

#### **The glands are classified according to the structure of duct system and the secretory portion (units):**

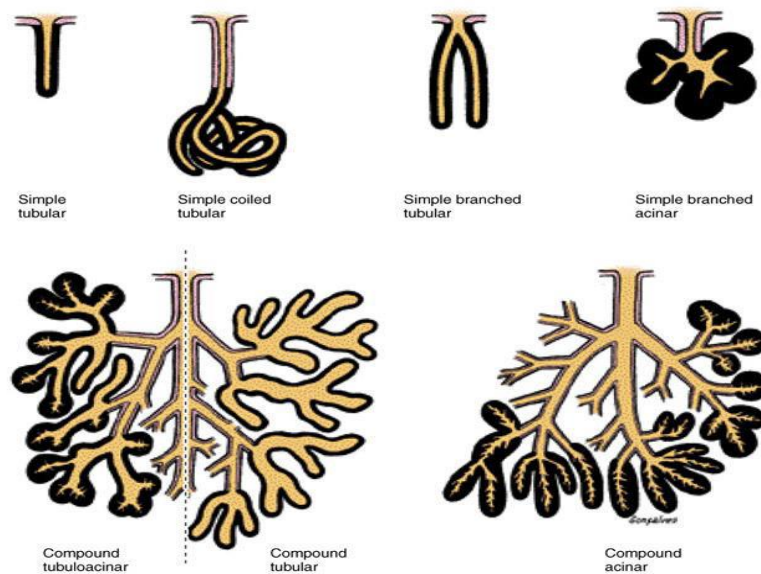
##### **a- simple gland**

Duct portion is unbranched (the secretory portion attached to the duct may be branched), the duct may be short or long and coiled.

The secretory portion can vary from straight tubular (intestine), coiled tubular (sweat), branched tubular (uterus) and branched acinar (sebaceous).

b-compound glands:

Have duct that branch repeatedly, the secretory portion can be tubular (pyloric stomach) acinar (pancreas) or tubuloacinar (salivary and prostate).



**B- The glands are classified according to the type of secretion:**

**1-Mucous glands:**

Cells which are specialized to secrete mucous called mucous cells .e.g. esophageal glands and goblet cells, the cells are typically organized into tubular secretory units .Under L.M. mucous glands are distinguished by empty appearing (pale staining ) apical cytoplasm and densely stained basal nuclei.

Goblet cells take their name from their characteristic shape, with a broad opening at the apical end and a narrow (pinched) base. Cells with this goblet shape are also characteristic of the respiratory tract and the female reproductive tract.

## 2-Serous glands:

Product watery solution of enzymes like serum or else glycoprotein mixture.

Under L.M. serous cells are distinguished by basophilic basal cytoplasm, a spherical, near to the base –located nucleus and variously – staining secretory vesicles in apical cytoplasm

E.g. salivary gland and exocrine cells of the pancreas.

## 3-Mixed glands:

Containing both mucous and serous cells, each with a characteristic appearance. e.g. salivary gland which contain both types of cells.

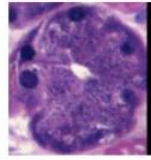
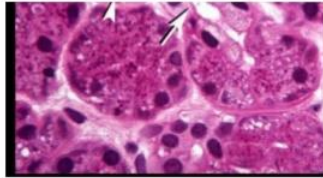
### Mixed glands

- Contain both serous & mucous secretory units.
- Sometimes serous cells form crescentic caps on mucous acini called as **serous demilunes**.

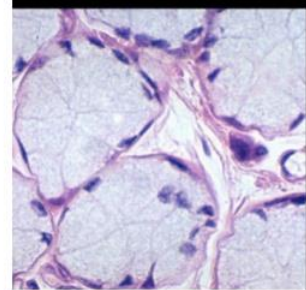
The diagram illustrates a mixed gland with a central duct and surrounding acini. A serous demilune is shown as a crescent-shaped cap of serous cells on a mucous acinus. The histological image shows a similar structure with labels: Interlobular duct, Serous acini, Mucous acini, Serous demilunes, Intralobular duct, and Excretory duct.

## Types of Acini in Salivary Glands

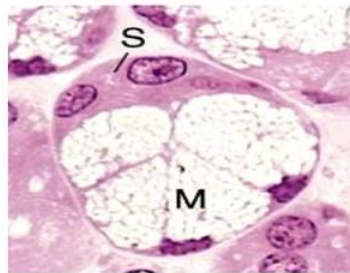### 1) Serous



### 2) Mucous



### 3) Mucoserous



### Serous demilune Crescent of Gianuzzi

## **What is the difference between Serous and Mucus?**

1-Mucous cells in the mucous glands secrete mucus, while serous cells in the serous glands secrete serous.

2-Clusters of serous cells are called serous acini, while the clusters of mucous cells are called mucous acini.

3- Serous acini have narrow lumen while mucous acini have wider lumen.

4- In H and E- stain, mucous cells appear pale blue, unlike the serous cells.

5-Nucleus of serous cell is spherical and is placed in the basal of the cell, while the nucleus of the mucous cell is flattened and situated near to the base.

6- Mucous acini are composed of larger cells than serous acini which are composed of smaller cells.

7-Mucus is thick and viscous fluid, whereas serous is more watery and less thick.

8-Serous contains amylase enzyme, whereas mucus contains little or no enzymes.

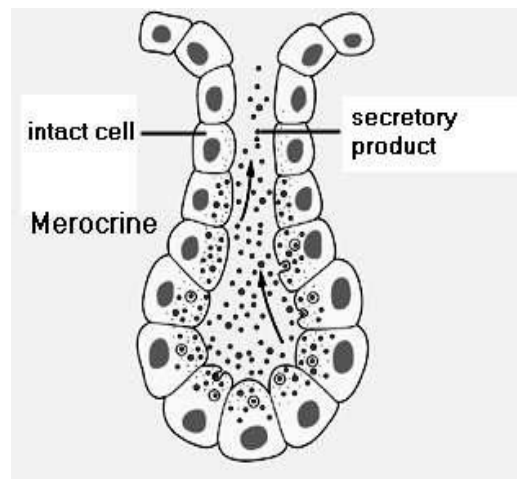
9-Serous helps to digest starch, while mucus mainly serves as lubricant and protection layer.

Exocrine glandular epithelium can also secrete lipids material e.g. sebaceous glands.

### **C -Classification according to mode of secretion:**

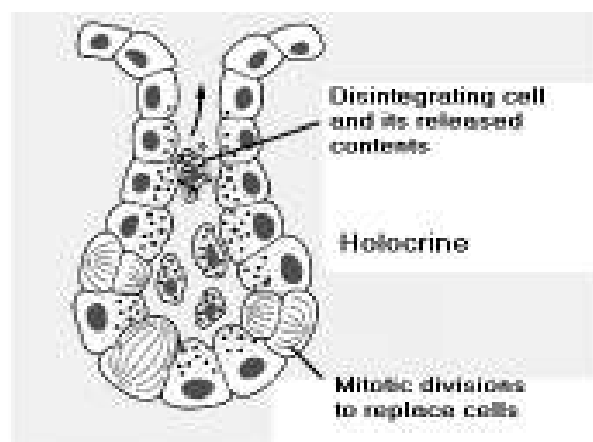
#### **1-Merocrine (eccrine):**

Most exocrine glands are merocrine, the secretory granules (usually protein) leave the cells by exocytosis at the apical end of secretory cells with no loss of other cellular material.



## 2- Holocrine:

Holocrine glands accumulate their secretions in each cell's cytoplasm and release the whole cell into the duct. This destroys the cell, which is replaced by a new growth cell, e.g. sebaceous gland which released its product of secretion (sebum) with remnants of dead cells.

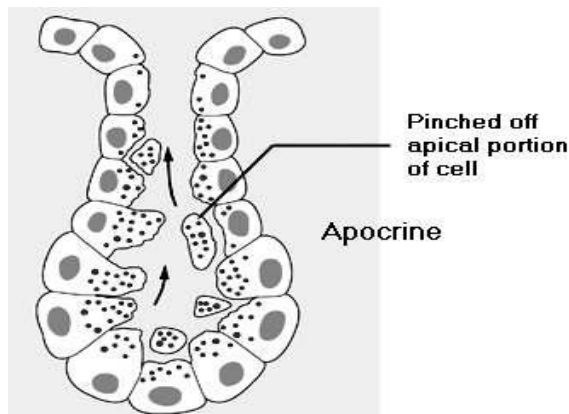


## 3-Apocrine:

The secretory material is released along with a part of apical cytoplasm in the form of (blebs). The rest of the cells is intact and continues to function.

Apocrine secretion is less damaging to the gland than holocrine secretion (which destroys a cell) but more damaging than merocrine secretion (exocytosis). An example of true apocrine glands is the mammary glands which are responsible for secreting breast milk and sweat glands which are responsible for secreting sweat.





There are two types of sweat glands present in skin layer ,apocrine sweat glands which secrete fluid into the sac of hair follicle and then outside of the body( indirectly) ,and eccrine sweat glands which secrete directly through a duct .

The apocrine sweat glands, associated with the presence of hair in human beings (as on the scalp, the armpit, and the genital region), continuously secrete a concentrated fatty sweat into the gland tube. Emotional stress stimulates contraction of the gland, moving its contents. Skin bacteria break down the fats into unsaturated fatty acids that possess a pungent smell.

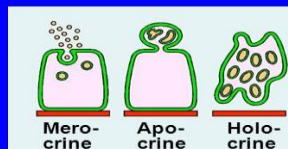
Holocrine secretion is the most damaging (to the cell itself and not to the host which begot the cell) type of secretion, with merocrine secretion being the least damaging and apocrine secretion falling in between.

## GLANDS (Glandular Epithelium)

### Classification:

#### 3- According to mode of secretion:

- a. **Merocrine:** No part of the cell is lost with the secretion, e.g. salivary glands.
- b. **Apocrine:** The top of the cell is lost with the secretion, e.g. mammary gland.
- c. **Holocrine:** The whole cell detaches with the secretion, e.g. sebaceous glands.



### **Myoepithelial cells:**

Many exocrine glands have specialized type of epithelial cells embedded in basement membrane, around the secretory acini and surrounding the ducts, these cells are located between the basal portions of the secretory

cell and the basal lamina, and its cytoplasm contain numerous actin filaments as well as myosin. These cells can contract and expel the secretions of exocrine glands and may aid secretion of acinus glands.

They are found in the sweat glands, mammary glands, and salivary glands.

