



**FOGSI FOR ALL, ALWAYS**

**DHEERA**

**STOP VIOLENCE AGAINST WOMEN**

# FOGSI FOCUS

## *Vaginal Surgeries*



Editor in Chief

**Prof. Dr. S. Shantha Kumari**

Persident FOGSI  
2021 - 2022

Editor

**Dr. Kawita Bapat**

Vice-Persident FOGSI  
2021 - 2022

Co-Editor

**Dr. Krishna Kumari**

**Dr. Anil Sakhare**



## Team FOGSI 2021-2022



**Prof. Dr. S. Shantha Kumari**  
President



**Dr. Hrishikesh D. Pai**  
President Elect



**Dr. Alpesh Gandhi**  
Immediate Past President



**Dr. Archana Verma**  
Vice President



**Dr. Basab Mukherjee**  
Vice President



**Dr. Bipin Pandit**  
Vice President



**Dr. Fessy Louis**  
Vice President



**Dr. Kavitha Bapat**  
Vice President



**Dr. Madhuri Patel**  
Secretary General



**Dr. Suvarna Khadilkar**  
Dy. Secretary General



**Dr. Parikshit Tank**  
Treasurer



**Dr. Niranjana Chavan**  
Joint Treasurer



**Dr. Aruna Suman**  
Joint Secretary

## Team ICOG 2021-2022



**Dr. S. Shantha Kumari**  
President



**Dr. Udaythanawala**  
Chairperson



**Dr. Parag Biniwale**  
Vice Chairperson



**Dr. Ashok Kumar**  
Secretary

## Team JOGI 2021-2022



**Dr. Geetha Balsarkar**  
Editor-In-Chief



**Dr. Pradnya Chagede**  
Secretary & Manager



# FOGSI FOUCS Vaginal Surgeries



Editor - in - Chief  
**Prof. Dr. S. Shantha Kumari**



Editor  
**Dr. Kawita Bapat**



Co-Editor  
**Dr. Krishna Kumari**



Co-Editor  
**Dr. Anil Sakhare**



Foreword  
**Dr. Shirish Seth**



Foreword  
**Dr. Sudhir Shah**



## CONTRIBUTING AUTHORS

**Dr. Anjali Chitnis** (M.D..D.G.O..D.F.P..F.I.C.O.G.)

HOD Sahakar Rugnalay and Chitnis Nursing Home. Ex-Asso.Prof.V.M GOVT MEDICAL COLLEGE SOLAPUR Maha.Trustee AMOGS. Ex-President AMOGS

---

**Dr. Anil Sakhare** (DNB, D.G.O., D.F.P., F.I.C.O.G.)

Ex. Assistant Professor, Dr.S.C.Govt. Medical College, Nanded  
Consultant OBGY, Rayat Hospital, Nanded, Maharashtra

---

**Dr. Kawita Bapat** ( MBBS, MS, FICOG )

Vice President FOGSI Director of One Centre for Gynaecological Excellence,  
Bapat Hospital Bapat Chouraha Sukhliya Indore Madhya Pradesh

---

**Dr. Manik Gurram** (MD DICOG)

Ankur, Gurram Nursing Home, 1895 New Paccha Peth Solapur  
Markandeya Solapur Sahakari Rugnalaya

---

**Dr. Mukesh Rathi** (MBBS MD DNB DGO FCPS)

Laxminarayan Memorial Hospital, Akola

---

**Dr. S. S. Mehendale** (MD(OBGY))

Professor Emeritus, Bharti Vidyapeeth tobe Deemed University Medical College, Pune

---

**Dr. S. P. Kakatkar** (Consultant OBGY Pune)

---

**Prof. Dr. Mrs. T. Srikala Prasad** (M.D.(OBG), D.G.O., M.Ch.(Urology))

Professor and Head of the Department of Urology, Chengalpattu medical College. Chengalpattu, Tamilnadu.  
Past Secretary OGSSI (Obstetrics and Gynecology Society of Southern India)  
Secretary, Tamilnadu Chapter of SOVSI (Society of Vaginal Surgeons of India)  
Nominated Indian Member of the Urogynecology Committee of AOFOG

---

**Dr. Vyomesh Shah** M.B.DG.O, F.I.C.A. F.I.C.M.C.H. Ph.D. (USA) F.M.R.S.H. (lon.), Dip in Endo (USA),  
Vaginal Surgeon & Endoscopist, Avani Hospital, Patan GUJARAT

---



# Message



**Prof. Dr. S. Shantha Kumari**  
FOGSI President 2021-2022

### **FOREWORD FROM THE PRESIDENT'S DESK**

Dear FOGSIANS

Greetings from FOGSI 2021 -2022, I hope that your family and patients are safe in these difficult pandemic times. Wish you the best of health and please take care.

I have been very lucky to take over as President of our prestigious organization FOGSI with all your support. Vaginal surgery is an art that remains ever interesting and loved by all obstetricians and gynecologists. It gives me great pleasure to write a few lines on a subject so very close to my heart for the first FOGSI FOCUS released in my tenure as the 60th President of FOGSI.

India is famous for vaginal surgeons who have excelled in this art. I still remember my first years after joining as postgraduate and to date I am in awe of the great legendary surgeons and I think most agree with me. But unfortunately the generation next who will be taking care of the health of future generations are not showing much interest in this surgical sphere which needs only skill and perseverance and not elaborate expensive instruments. This book is a homage to all our great vaginal surgeons. We have made an honest effort to carry this legacy forward and I hope that this FOGSI Focus of ours will revive the interest in young Obgyns.



These “niche surgeries” often follow the correct approach supported by evidences, and we should do more of them. Why don't we? Vaginal surgery procedures require tactile skill, muscle memory and precise knowledge of anatomical landmarks. Learning correct techniques, practice and repetition are the only methods of perfecting this form of surgery.

I thank the authors for sharing their knowledge and experience and congratulations for the whole team of editors for bringing it together. The chapters have been contributed by experts in their field and I hope that this issue of FOGSI FOCUS on ‘VAGINAL SURGERY’ will update gynaecologists and postgraduate students with the best techniques and latest developments in vaginal surgery.



**FOGSI FOR ALL, ALWAYS**

**DHEERA**  
STOP VIOLENCE AGAINST WOMEN

**Prof. Dr. S. Shantha Kumari**

MD DNB FICOG FRCPI (IRELAND) FRCOG (UK)

FOGSI President 2021

Professor OBGYN

Chairperson ICOG 2018

Consultant Yashoda Hospitals hyd

ICOG secretary (2015-2017)

Member FIGO Working group on VAW

Vice President 2013

IAGE Managing committee Member


National Corresponding Editor for JOGI

Chairperson FOGSI MNNRRC 2008

Mob: 9848031857



# Message



**Dr. Kawita Bapat**  
Vice-President FOGSI  
2021 - 2022

### FROM EDITOR DESK

Dear FOGSIANS

Vaginal hysterectomy in non-prolapsed uteruses is in real means is : "no scar hysterectomy"

The use of institutional guidelines for determining the hysterectomy route and a standardised VH technique resulted in an increased number of performed VHs. This provided an essential opportunity for residents to acquire, improve and maintain the skills required to safely perform VH. Recent data suggest that outpatient vaginal hysterectomy can be a safe procedure and is well-accepted by selected patients.

I usually do vaginal hysterectomy as a day care surgery at my hospital. As minimally advancing technology continues to be developed and refined, surgeons must choose the safest and best cost-effective surgical approach for the patient; and this necessitates the need for resurgence of NDVH.

I hope this fogsi focus will help the surgeons to know more about vaginal surgeries. I must thank all the contributors for their efforts.

**Dr. Kawita Bapat**

MS FICOG

Director

One Center for Gynecological Excellence  
Bapat Hospital Indore, Madhya Pradesh. India



# Foreward



### FOGSI-FOCUS ON VAGINAL SURGERIES

The way to a woman's uterus for Gynecologists has always been through the vagina to examine her and/or do the surgery. However, for many Surgeons, Physicians, etc. it is abdomen and limits them with it. Gynecological, abdominal access for surgery is only when the vaginal route is contraindicated or operator's inefficiency. For hysterectomy, beyond shadow of doubt WHO mentions that vaginal route is the best for a woman/patient and ideal when compared with alternative via abdominal route including laparoscopy. Vaginal is the least invasive with minimal access. Unfortunately, global statistics analysed by WHO are dissuading to give very high rate of abdominal hysterectomies performed and low use or access of vaginal route for hysterectomy. I write with humility of having successfully performed scientifically more than 10,000 hysterectomies vaginally.

Numerous noted international colleagues have strongly propagated hysterectomy via vaginal route. If hysterectomy vaginally was marketed as 'scar less or no visible incision surgery' it would have been the most popular procedure.

Every Gynecologist must remember that "Man learns as he lives and experience is the greatest teacher in the world" ... Swami Vivekananda.

**Dr. Shirish S. Sheth**

President, FIGO (2000-2003)

Consultant Gynecologist

at Breach Candy and Saifee Hospitals, Mumbai, India





# *Foreward*



To decide to publish the FOGSI FOCUS on Vaginal surgeries by our FOGSI President Dr. Shanthakumari Shekharan and Vice-President Dr. Kawita Bapat - is a dream come true decision not only ME, but for thousands of Fogsians as since long they were demanding expert teaching by experienced and senior Vaginal Surgeons of our own country - INDIA. So, at the outset I would like to congratulate our entire FOGSI TEAM to take this welcome decision for the members who want to know a lot for NDVH and Vaginal Surgeries.

India is a country of Villages, Towns and Cities. Approximately 70 percent of the public stays in Villages and Towns where 40 percent of Gynecologists are available to them. Gynecologists working in such remote areas may not have facilities of sophisticated instruments and infrastructures, continuous medical education and help of a good team and Anesthetists. This - quick - easy - cost effective and single handedly managed VAGINAL surgeries are more suitable to Gynecologists practicing at all levels including Cities and Metros to Villages. Open Abdominal Surgeries have played a long innings but with increased exposure, learning and watching the Vaginal route to remove the Uterus, Non Descent Vaginal Hysterectomy has become more popular for the Gynecologists working at all levels in India, including cities and Metros. Gynecologists have started to believe that Every Uterus can be and should be removed VAGINALLY unless the route is contraindicated. Vaginal Hysterectomy is preferred to other routes as it is performed through a natural entrance, direct approach to cervix and uterus, indications are increasing and many contraindications of past years have now been in the list of possible. More and More gynecologists are adopting this route as it is simple, quick, cost effective, needs less instruments and staffs, can be performed under spinal anesthesia, recovery is fast, least intra and post operative problems, least blood loss and pa-



tients can be discharged after 24 hours. NDVH is easy if the selection of patient is proper, Surgeons having perfect knowledge of Pelvic anatomy, surgical steps, energy sources and have experienced assistants. The present FOGSI FOCUS will enlighten the seniors, Juniors and Post Graduates to learn a lot about NDVH and so will certainly increase the confidence to adopt this route for the removal of Non Descent Uterus of normal to large sizes, fibroids, adenomyosis or previous CS cases. All the authors here are seniors and experienced in this surgeries.

Apart from NDVH -different kinds of other vaginal surgeries are described here with full details to enrich the knowledge of all generations Gynecologist.

Remember we are Gynecologists and our route of entry for surgery is through Vaginal orifice. Surgeons removes the Tonsils through oral cavities and not by cutting the skin over the Neck. Likewise we can remove the Uterus or do many Gynecologic surgeries through this route. This FOGSI FOCUS has the aim to create interest and enlighten the knowledge regarding Vaginal surgeries. This will shorten the learning curve and will make you a skillful surgeon.

Once again I congratulate President FOGSI - Dr.Shanthakumari Shekharan , Vice-President Dr.Kawita Bapat and entire FOGSI TEAM to bring out this FOGSI FOCUS on a very important part of our subjects.

**Dr.Sudhir R.Shah**

Senior Gynecologist -  
MANAN HOSPITAL, Rajkot



# C O N T E N T S

1.	"EVOLUTION OF NDVH ".... As I witnessed and experienced <b>Dr. Anjali Chitnis</b>	11
2.	NDVH IN SPECIAL SITUATIONS... <b>Dr. Anil Sakhare</b>	13
3.	TRAINING AND LEARNING CURVE IN VH... <b>Dr. Kawita Bapat</b>	21
4.	HOW TO LEARN NDVH AT OWN HOSPITAL AND GET MASTERY <b>Dr.Manik Gurram</b>	25
5.	VAGINAL HYSTERECTOMY IN CASES WITH PREVIOUS CESAREAN SECTIONS <b>Dr .Mukesh Rathi</b>	28
6.	PELVIC ANATOMY IN THE CONTEXT OF VAGINAL SURGERIES ... <b>Dr. S. S. Mehendale, Dr. S. P. Kakatkar</b>	32
7.	TIPS & TRICKS IN SAFELY OPENING ANTERIOR & POSTERIOR POUCHES... <b>Prof. Dr. Mrs. T. Srikala Prasad,</b>	41
8.	NDVH FOR BIG UTERUS WITH PREVIOUS MULTIPLE C - SECTION <b>Dr. Vyomesh Shah</b>	49



## "EVOLUTION OF NDVH " ... As I witnessed and experienced

I devote this article to my esteem teacher and mentor Dr. B. N. Purandare from whom I learnt the Art, Science and Craft of performing the original non descent vaginal hysterectomy in Nawrosjee Wadia Hospital, Mumbai now called as NDVH.

Since then I believe that the Gynecologist must expand and master the procedure of NDVH and then they will be recognized in terms of the level of expertise.

The evolution in NDVH is a gradual process of change in development over period of time so as to come to today's modern and made easy techniques for simple as well as difficult cases.

AD 120 Hippocrates by Soranus of Ephesus city in Greece amputated uterus vaginally, From 11th to 16th centuries it was mainly for prolapse and inversion of the uterus performed by midwives, surgeons, professor of anatomy and patient herself.

In 18th Century, Langente performed first ever vaginal hysterectomy for Uterine Cancer. They progressed then by identifying and ligating the broad ligament vessels and other liga-

ments. Vaginal hysterectomy was performed by Charles Clay in 1843. This was done well before the procedure of abdominal hysterectomy.

Opening of the Cul-de-sac, pulling of the fundus, peritonisation, anchoring of the stumps to vaginal wall was performed by Schroeder in 1880. Interesting fact is that Doderlein used approach through anterior colpotomy. In 1894

technique of vertical and oblique morcellation of the uterus was used to reduce the size of the uterus.

In 19th century, thus Gynecology was recognized as a separate specialty. In this era, technique of Non Descent Vaginal Hysterectomy was systematically studied and developed by Professor. Sims, Wertheim, Schauta,

Kelley, Bonney, Mayo, Meige and thus we witnessed " The Evolution of non descent vaginal hysterectomy ".

Improvement in understanding the physiology, pathology of the female reproductive organs and its diseases lead to application of different surgical techniques. Safeblood transfusions, effective antibiotics, modern anesthesia added to the improved outcome of operations.

### **Dr. Anjali Chitnis**

Ex. Prof. DR. V. M.  
Govt. Medical College, Solapur  
Head of the Department O & G  
Markandeya Rugnalaya, Solapur  
Consultant Obstetrician  
and Gynecologist,  
Chitnis Nursing Home, Solapur



Specifically designed and modified instruments added to ease of operations. Indications and contraindications to the vaginal route were fairly understood. Psychosocial Impact of vaginal operations was studied. It was researched and concluded that certainly vaginal hysterectomy reduced mortality and morbidity of the patients.

Indian contribution is noteworthy in this field of non descent vaginal hysterectomy. India was not lagging behind in contribution to the field of NDVH. Stalwarts like Dr. B.N. Purandare, Dr. V.N. Shirodkar, Dr. Mitra, Dr. Roy Chawdhari, Dr. V. N. Purandare contributed enormously.

Dr. B. N. Purandare - student of Professor Victor Bonney, his vaginal hysterectomy was called a "Physiological " operation, bloodless, no clamps, no tissue damage. Movements of his fingers, feel of the tissue, knowledge of anatomy and his confidence was unique and outstanding.

Meticulous methodology of applying clamps, infiltration with saline in the tissues, removal of adnexa, extended and radical vaginal procedures were added and made popular by Dr. V.N. Purandare, Dr V N Shirodkar , DR. Subodh Mitra and DR. Choudhari .

DR. Shirish Sheth from K.E.M. Hospital Mumbai made it popular as "NDVH". He used this technique for enlarged uterus i.e. for fibroid uterus and adenomyosis. He used vaginal route for those with previous LSCS, with adnexal

pathology, and even in nulliparous patients. Further other operations like myomectomy, morecellation, intramyometrial coring, removal of adnexa were added by many young and enthusiastic gynecologists.

Use of energy sources in vaginal surgery was a novel concept to achieve haemostasis and avoid using clamps. This was another milestone. Use of electrodiathermy, bipolar energy, harmonic scalpels; replaced clamps and ligatures. The Robotic Surgery was introduced in 2005 which may not replace but can enhance the performance of the surgeon.

Laparoscopic assisted vaginal hysterectomy, Laparoscopic hysterectomy, abdominal and vaginal hysterectomy were studied well and finally NDVH was said the favorable, easy and least morbid surgery.

In Summary, the success of NDVH depends on selecting the right operation for the patient, right patient for the operation. understanding the anatomy and pathology, the clinical manifestations of the disease as assessed by modern diagnostic scans. The well learnt operative technique for NDVH and postoperative care is fundamental.

One must be familiar to all the techniques and different routes. One cannot replace the other. NDVH is a relatively easy operation to perform. Movements of fingers, feel of the tissue, knowledge of anatomy and the surgeon's confidence - is the secret of success. Mastering the art of NDVH is an art itself.





## NDVH IN SPECIAL SITUATIONS.

Hysterectomy is one of the most frequently performed surgical procedure worldwide.<sup>1</sup> Hysterectomy may be performed abdominally, vaginally, laparoscopically or with robotic assistance with the route depending upon physician's choice. Factors to be considered in choosing the route of hysterectomy should include safety, cost effectiveness and medical need of patient. Preferably surgical approach of hysterectomy should be decided by the woman in discussion with surgeon and it is moral responsibility of the surgeon to provide evidence based unbiased opinion.<sup>2</sup>

Most of the literature support that vaginal hysterectomy when feasible is the safest and cost effective procedure for removal of uterus and should be the approach of choice whenever feasible. Evidences demonstrate that it is associated with better outcomes when compared with other approaches to hysterectomy.<sup>3,4 & 5</sup>

Younger trainees are seeing less vaginal procedures being done and having less confidence to carry out the procedure the surgeons are steering away from vaginal approach because laparoscopic and robotic approaches are much more appealing and considered to be glamor-

ous.<sup>6,7</sup>

There are very few contraindications for vaginal hysterectomy. However there are some factors that may influence the surgeon's choice of a route for hysterectomy like surgeons training, accessibility of uterus, size and shape of uterus, extent of extra uterine disease, need of concurrent procedure like oophorectomy and salpingectomy and the cases with previous caesarean section.

As a gynec surgeon I visualize four situation for which each gynaecologist should master the skills of

vaginal hysterectomy. Situation 1 is where because of associated some type of pelvic organ prolapse, vaginal approach is best suited. The situation 2, there are indications of hysterectomy where all three approaches are suitable but ( Non-descent vaginal hysterectomy) NDVH is affordable to everybody. The situation 3, it is scar less surgery in low socio-economic settings. The situation 4, these are the cases where performing NDVH is difficult situation. These are big uterus, irregular uterus, nulliparous uterus, pelvic adhesions, concomitant oophorectomy or salpingectomy, benign adnexal masses, obesity and cases with previ-

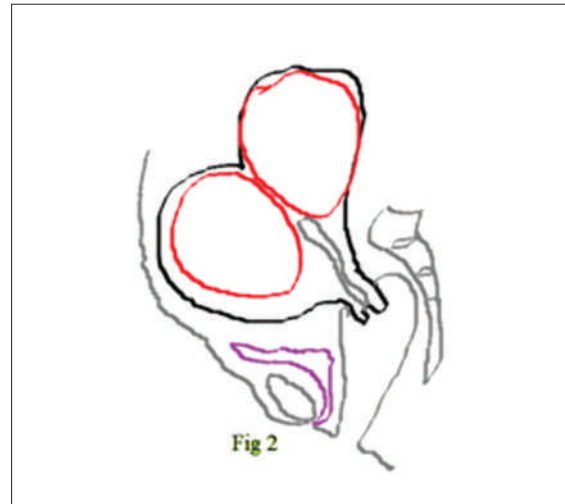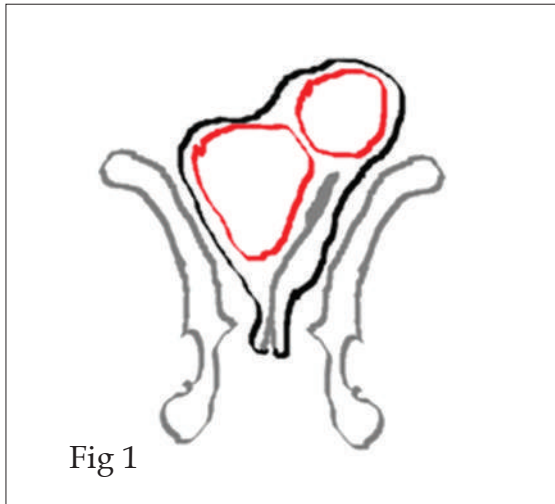
**Dr. Anil Sakhare,**

Consultant, OBS & Gyne,  
Nanded.

ous caesarean section. Earlier few of these conditions were said to be relative contraindications for NDVH. But with expertise and experience, these cases can be easily done by NDVH.

Cases of fibroids, adenomyosis, and irregular uterus more than 12 weeks size can be easily done vaginally by expertise (Fig 1& 2).

Fig 1 & 2. Irregular uterus more than 12 weeks size.

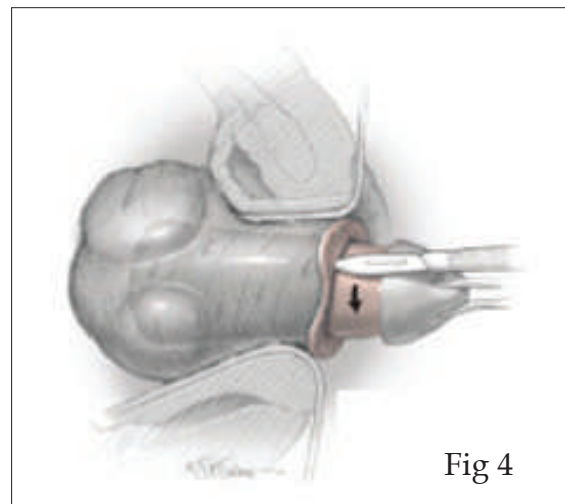
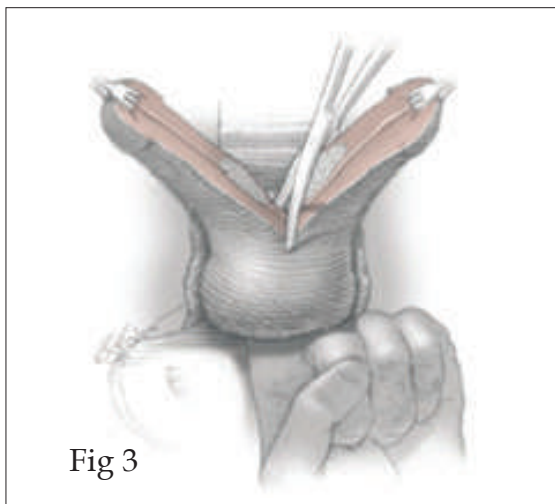


BISECTION, CORING, MORCELLATION and ENUCLEATION are the debulking techniques and proved to be gold standard. 200-

700 gm of uterus has been successfully removed (Fig 3 & 4, Source: Williams Gynecology Ed 3, Vaginal hysterectomy).

Fig 3. Bisection.,

Fig 4. Coring.



Peloci reported 2003 gm uterus removed vaginally. The golden rule of all debulking technique is that they have to be performed after

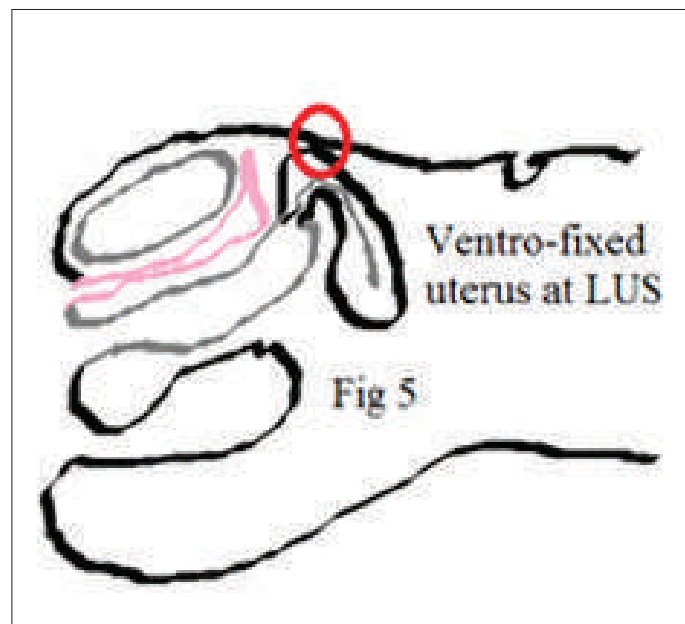
ligation of uterine vessels. Intramyometrial coring was introduced by Lash in 1941 and reintroduced in 1986 for re-

removal of large uteri. In this technique myometrium can be circumferentially incised with scalpel placed parallel to uterine axis of uterus beneath the serosal covering of uterus. This removes the core inside the uterus without violating the integrity of endometrial cavity, to facilitate the coring strong traction on uterus is necessary. It reduces the width of uterus thereby increasing the length; the effect of coring is- it converts spherical structure into rod like structure. When the uterine width is smaller, bisection or morcellation is preferred over coring.

As the number of caesarean section are in-

creasing, in coming days there will be more number of patients undergoing hysterectomy to have caesarean section scar. NDVH can be performed in cases with previous one or more caesarean section. One study found that in 93% cases it was performed successfully without any complications. Only cases with previous caesarean scar having ventrofixed uterus adherent to anterior abdominal wall, are true contraindications for NDVH. These cases can easily diagnosed clinically by vaginally pulling down the cervix and demonstrating the visible abdominal wall retraction (Fig 5).

Fig 5. Post cesarean section ventro-fixed uterus.

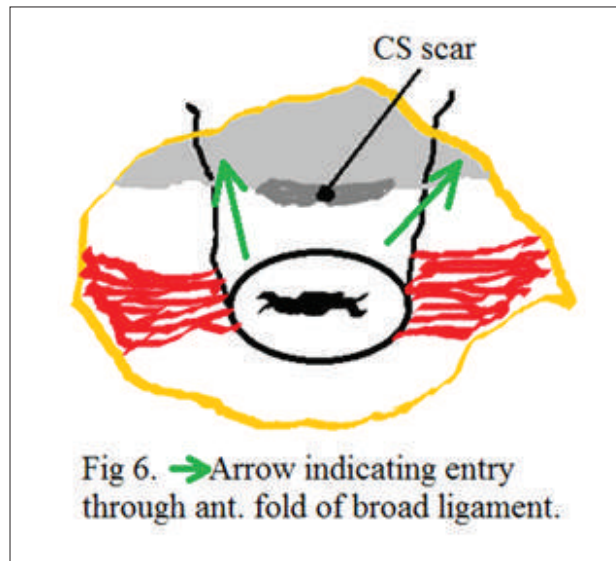


A LSCS scar distorts the anatomy by reducing vesicouterine space between the scar and the urinary bladder. Controlled dissection of caesarean section scar is easier and more directly visible in vagina than from abdomen. Bladder can be dissected and anterior pouch can

be approached by various methods. One method suggested by Dr. Shirish Seth is lateral approach which is going lateral to the LSCS scar on both the side through anterior fold of broad ligament (Fig 6).

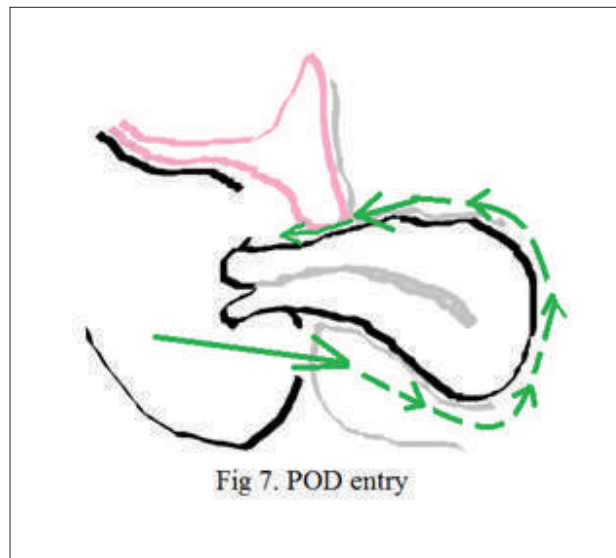


Fig 6. Dr Shirish Seth's lateral approach



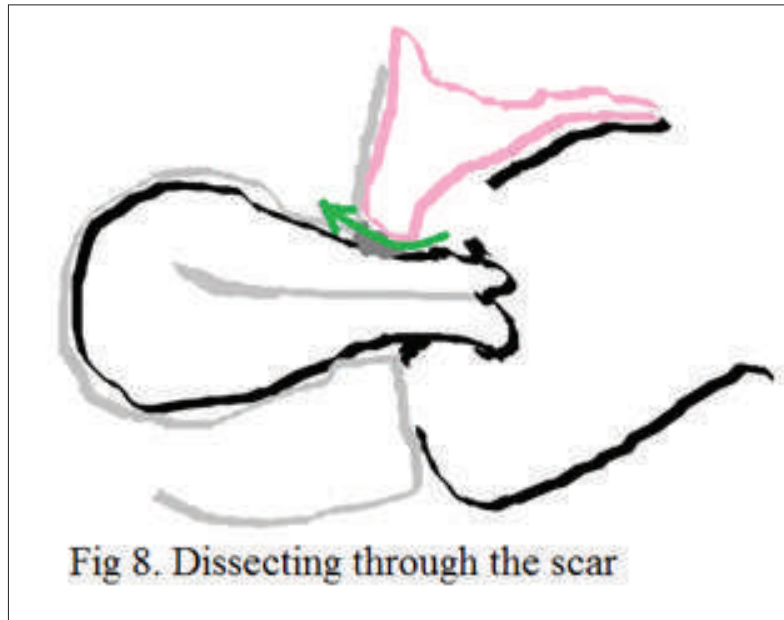
Another method is going around the uterus method is easy when uterus is of normal size after opening of posterior pouch. But this and mobile (Fig- 7).

Fig 7. Pouch of Douglas first approach



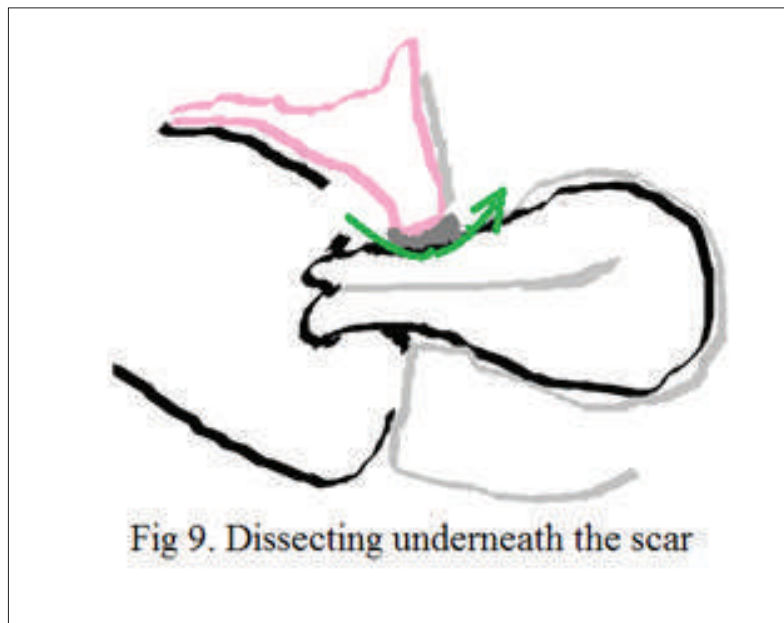
The other method is dissection above the bladder and the peritoneum as independent scar, performed by identifying the scar, the structure (Fig- 8).

Fig 8. Dissecting above the scar or through the scar.



On occasions it is possible to dissect under the scar from the urinary bladder (Fig- 9). the scar which keeps dissection further away

Fig 9. Dissecting beneath the scar through perimetrium.



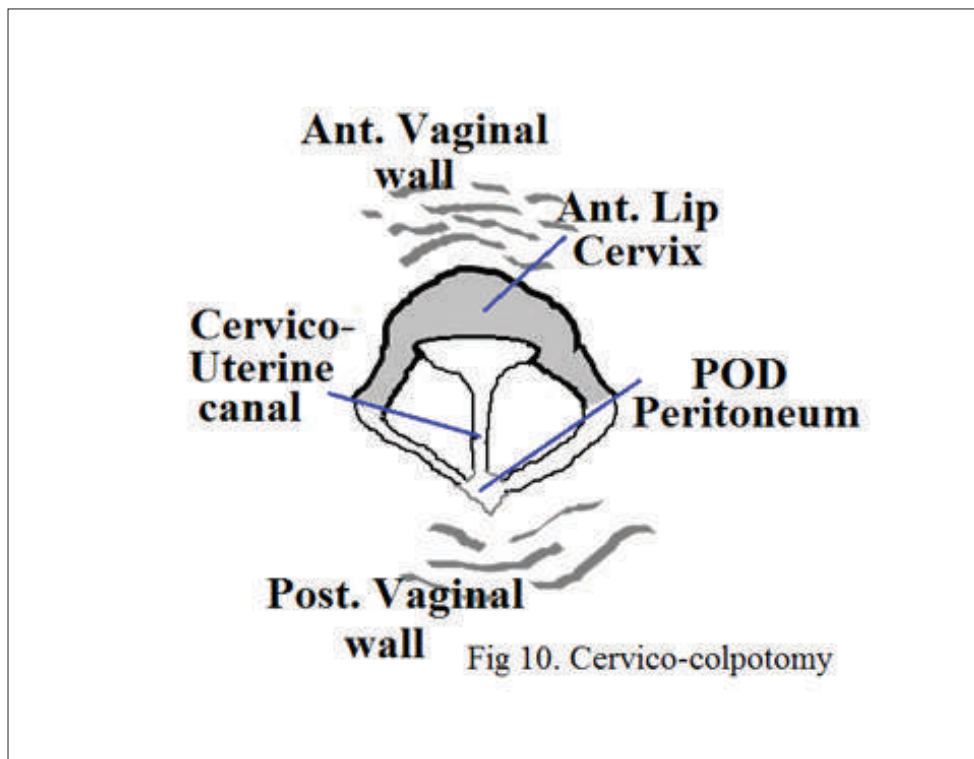
The evidence says that the risk of bladder injury during vaginal hysterectomy does not

seem to be increased in women with previous caesarean section.

Other special situation where NDVH is said to be risky for fear of injury to large or small bowel, is adhesions in pouch of Douglas. Adhesions in POD can be easily diagnosed clinically. Puckered or obliterated POD on per

speculum examination may give indication for possible adhesions. To avoid injury to bowel posterior lip of cervix and vagina can be cut in vertical direction that exposes peritoneum at higher level at its junction with visceral peritoneum, so that it can be recognized and entered directly. This is cervicocolpotomy (Fig- 10).

Fig 10. Cervico-colpotomy.

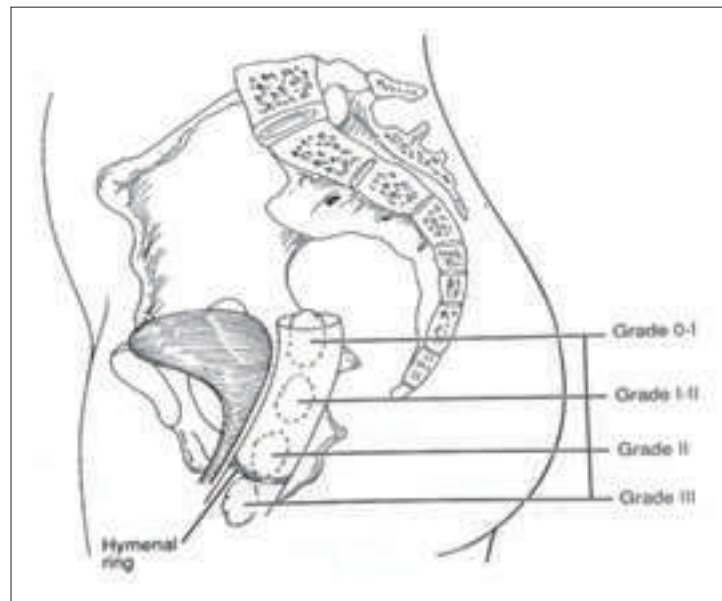


Another special situation is where one has to perform concomitant oophorectomy and / or salpingectomy along with hysterectomy. Inexperienced or untrained gynec surgeon is reluctant to perform NDVH in such a situation. It appears that the surgeon thinks the vaginal hysterectomy is more challenging and cumbersome when it needs to be completed with concomitant adnexectomy/salpingectomy. There appears some reluctance to combine vaginal hysterectomy with oophorectomy because vaginal

oophorectomy is thought to be risky and difficult procedure.

Baden and walker described degrees of ovarian descent 93%. Patient had ovarian mobility up to grade 2 that is up to midportion of vagina, in 4.6 percent ovaries can be pulled up to hymeneal ring. Only 2.5 % patients had little ovarian mobility and 0.1 percent had grade 0 mobility (Fig- 11, Source: Telinde's Text Book of Operative Gynecology Ed 10, Vaginal hysterectomy).

Fig 11. Baden and walker 's classification of degree of ovarian descent.



Oophorectomy by vaginal route can be easily performed by a technique described by Zimmerman. This technique mimics same manoeuvres that are used to remove the adnexa abdominally. Round ligament is clamped

and cut separately, and an extension of incision into the broad ligament is done to create the window in the infra-tubal area. Clamp is then placed through the infra-tubal window to the ovario-pelvic ligament close to the ovary (Fig- 12).

Fig 12. Zimmerman technique of oophorectomy.

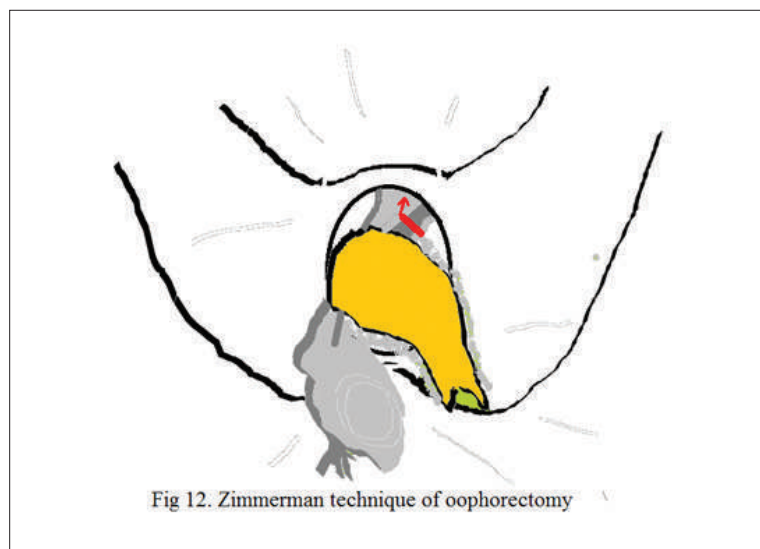


Fig 12. Zimmerman technique of oophorectomy



Salpingectomy during hysterectomy are frequently performed for cancer prevention during TLH or AH. But these are not routinely removed during vaginal hysterectomy with the perception of increased morbidity or difficulty or inadequate training. Salpingectomy should be routinely performed during VH because trade off with cancer prevention is highly favourable.

Benign mobile adnexal masses can be easily removed in 95% cases by vaginal route. Skill augmentation for vaginal surgery can avoid need of costly endoscopic surgeries. With increasing confidence and skills that comes from experience, there are very few patients with indications for hysterectomy in whom the procedure cannot be performed vaginally. Vaginal hysterectomy can be performed easily in cases of previous caesarean section and the cases which need oophorectomy and salpingectomy. Because of little more intraoperative complication rate such special situations should be undertaken after good experience.

### References:

1. Choosing the route of hysterectomy for benign disease. Committee Opinion No. 701. American College of Obstetricians and Gynecologists. *Obstet Gynecol* 2017;129:e155-9.
2. Ray A, Pant L, Magon N. Deciding the Route for Hysterectomy: Indian Triage System. *J Obstet Gynaecol India*. 2015; 65(1):39-44.
3. Tohic AL, Dhainaut C, Yazbeck C, Hallais C, Levin I, Madelenat P. Hysterectomy for benign uterine pathology among women without previous vaginal delivery. *Obstet Gynecol* 2008;111:829-37.
4. Doucette RC, Sharp HT, Alder SC. Challenging generally accepted contraindications to vaginal hysterectomy. *Am J Obstet Gynecol* 2001;184:1386-9; discussion 1390-1.
5. Kovac SR, Barhan S, Lister M, Tucker L, Bishop M, Das A. Guidelines for the selection of the route of hysterectomy: application in a resident clinic population. *Am J Obstet Gynecol* 2002;187:1521-7.
6. Moen, M.D., Richter, H.E. Vaginal hysterectomy: past, present, and future. *Int Urogynecol J* 25, 1161-1165 (2014). <https://doi.org/10.1007/s00192-014-2459-x>.
7. Melendez, J. Vaginal hysterectomy and training. *Int Urogynecol J* 26, 621 (2015). <https://doi.org/10.1007/s00192-014-2611-7>.





### TRAINING AND LEARNING CURVE IN VH...

In the last two decades, surgery carried out in outpatient settings has grown much more strongly than inpatient operations. Day surgery is generally defined as a non emergency procedure undertaken during the period of a normal working day (not exceeding 24 hours) in hospitals or other facilities set up for this purpose.

The concept does not account for minor surgery under local anaesthesia usually conducted in physicians' offices. The increase of day surgery was driven by innovations in surgical and anesthetic techniques, together with financial incentives and patient expectations. For many procedures, day surgery appears as an effective and efficient approach, offering several advantages to patients as well as surgeons and hospital managers. While cost savings have been the primary incentive to day surgery development, the benefits in term of enhanced social and emotional recovery are important. Less nosocomial infections, quicker return to mobility, and high satisfaction in centers where the outpatient procedure has become standard practice. Minimal invasive vaginal hysterectomy is latest and innovative proce-

dure.

It is basically non descent vaginal hysterectomy with minimal invasion.

Vaginal hysterectomy for total vaginal prolapse used to be done so it is surgery of past but becoming surgery of future. Technological change is like an axe in the hands of pathological criminal (Albert Einstein). Thus all the newer

changes in procedures are always welcome for the benefit of patients.

Hysterectomy is the surgery which is significantly costing the health care system. More than half million hysterectomies occur in a year. By the age of 61, out of ten, three women undergo.

Hysterectomy and majority for benign indications like fibroids, bleeding, endometriosis and pelvic pain.

Hysterectomy as a surgery, revolutionized in last 50 years. At first when started total abdominal hysterectomy used to be performed. Then the era of vaginal hysterectomy came. Vaginal hysterectomy was done only for prolapse of uterus. Than with advents of laparoscope era of laparoscopic surgery had come. The first was laparoscopic assisted vaginal hyster-

#### **Dr. Kawita Bapat**

Vice President FOGSI 2021-2022  
Director of One Centre for  
Gynaecological Excellence,  
Bapat Hospital Bapat Chouraha  
Sukhliya Indore Madhya Pradesh



ectomy. Laparoscopically Assisted Vaginal Hysterectomy (LAVH) is a procedure using laparoscopic surgical techniques and instruments to remove the uterus and/or tubes and ovaries through the vagina (birth canal).

Its greatest benefit is the potential to convert what would have been an abdominal hysterectomy into a vaginal hysterectomy. An abdominal hysterectomy requires both a vaginal incision and a four to six inch long incision in the abdomen, which is associated with greater post-operative discomfort and a longer recovery period than for a vaginal procedure.

Another advantage of the LAVH may be the removal of the tubes and ovaries which on occasion may not be easily removed with a vaginal hysterectomy.

This does not mean that all hysterectomies could or should be done by LAVH. There are certain conditions that will necessitate abdominal or vaginal hysterectomy. In fact a vaginal hysterectomy by itself, if indicated, is less time consuming, less expensive, and can be less dangerous. When LAVH is performed, several small abdominal incisions are made. A camera attached to the laparoscope provides a continuous image that is magnified and projected onto a television screen. It provides the view by which the surgeon operates.

The uterus is detached from the ligaments that attach it to other pelvic structures using laparoscopic tools, electro-coagulation or a laser. Adhesions may have to be freed and, if the tubes and ovaries are to be removed, they are detached from their ligaments and blood supply. They then can be removed with the uterus through an incision made in the vagina. Since the incisions are small, the scarring and pain from LAVH is often less than that associated with abdominal hysterectomy.

LAVH advances in laparoscopic supracervical hysterectomy, than most modern but diffi-

cult one total laparoscopic hysterectomy & now minimal invasive vaginal hysterectomy.

Whatever the root of hysterectomy in few questions to be answered :

- Q.1 What should be new selection criteria?
- Q.2 What are the challenges?
- Q.3 What is the technique?
- Q.4 What are the new instrumentation?
- Q.5 What is the fun?

### CHALLENGES :

Challenges in doing hysterectomy are exposure-

- 1) The important challenge is vaginal outlet is small but it is a challenge to deliver uterus out.
- 2) To maintain homeostasis.
- 3) Entry into culde-sac. How to enter into it and large uterus is also a great challenge, as there are chances of internal injury.

### CRITERIA IN DETERMINING ROUTE FOR HYSTERECTOMY :

- Level of suspicion for malignancy.
- Presence of adnexal mass
- Vaginal access
- Assessment of the mobility of the uterus
- What the size of the uterus
- Previous cesarean section.

### MINIMAL INVASIVE VAGINAL HYSTERECTOMY (MIVH)

As vaginal surgeons trained in vaginal surgery. With the advance of evolution in electro surgical units. Vaginal surgeon then become easier and popular. Previously there used to be monopolar instrumentation, conventionally now bipolar instrumentation. There is very much improvement in bipolar instrumentation. It has vessels sealing capacity, bipolar cutting ability and tissue impedance feedback on computerized cauteries. In term, there is a improved outcome.



The general principles of doing MIVH are classical steps of

conventional surgery + three new principles.

1. Only two other instruments
2. Application of clamps close to uterus
3. No traction

Sequence of operation-

1. Vaginal circumferential cut around the cervix .
2. Haemostasis around cervix.
3. Haemostasis and additional amputation of uterine vessels.
4. Amputation of uterus at adnexa
5. Adnexectomy with clamp
6. Occulsion of vaginal vault.
7. Technical challenges to the vaginal approach.

### EXPOSURE

Haemostasis

Entry into the cul-de-sac.

Large uterus.

Ureteral injury

High adnexa

### TECHNIQUE

- Entry into the cul-de-sac
- Stay within the uterus
- Do not abort (if u cannot enter anteriorly or even posteriorly) at some point, uterus will come down and present itself. SO delay entry until u you have good dissensus and visualization.
- IN case of large uterus -
- Bifurcation of uterus
- Amputation of cervix
- Make uterus pear shape to apple shape
- Apply morcellation technique.
- To avoid ureteral injury, mobilized bladder pillars superiorly and laterally.
- Perform cystoscopy

- Present inadvertent
- Occult kinking of the ureter and bladder injury.

### THERMAL HAEMOSTASIS-

#### Need three steps

1. Positioning of clamp
2. Removal of clamp
3. Cutting with scissors

### PREVENTION OF ACCIDENTS

1. Burns of skin and mucosa (prevention through
- 2- Positioning of clamp
- 3- Suctioning of surgical smoke
- 4- Thermal necrosis at the ureter
- 5- Thermal wounds of digestive tract
- 6- Bleeding -immediate and secondary

### LIGATURE VESSEL SEALING SYSTEM

- 1- Low voltage
- 2- High current
- 3- Impedance feedback
- 4- Optimal pressure

Vessel sealing technology ensures reliable, consistent, isolate vessel, thermal spread, predictable, less energy delivery, the pedicles are smaller and therefore the steam effects are much less lateral to the instrument.

No sticking, charring, reliable seals. Bipolar vessel sealing systems decreased blood loss by an average of 48 ml and operative duration by an average of 17 min compared with suturing. Sealing system causes

### OCCULSION OF VESSELS

Mechanical -

Flattening

Compression

Thermal -

Dehydration of tissues

Destruction of proteins

Hardening of the collagen





### **BENEFITS OF TISSUE FUSION SYSTEM**

1. Consistent control of energy delivers
2. Zones are more flexible and stronger
3. Greater reduction of thermal spread
4. Less charring and sticking.
5. Reduction of pain.
6. Good psychological preparation.
7. Multimodal anesthesia.
8. Non aggressive operative technique.
9. No forcible pulling of pedicle & ligaments.
10. Ensuring haemostasis through thermo fusion.

### **IMPACT ON PAIN**

Thermal haemostasias reduces inflammatory and painful events.

Absence of necrotic tissue & foreign bodies.

**MIVH PROCEDURE IS** - Fast, Latest, Reliable, Painless, Suture less, Convenient, Needs no CO<sub>2</sub>, bloodless, less OT time. It is cost effective, early recovery; it needs less duration of anesthesia, Less duration of stay. It is Expertise technique which has Worldwide acceptance and internationally acclaimed in MIVH we Need not to go through seven layers of abdomen.

**CONCLUSION:** MIVH is Good procedure, we should develop new criteria for selecting patients, New technology and instrumentation should be used cautiously and after training and as vaginal surgeons MIVH is only future.





## HOW TO LEARN NDVH AT OWN HOSPITAL AND GET MASTERY

Abdominal hysterectomy is a surgery.

Laparoscopic hysterectomy is a technological surgery.

But vaginal hysterectomy is an art surgery.

Vaginal hysterectomies were already being performed since the 19th century. The first one was done by Langenbeck. Since then many modifications and variations have been reported. Most methods in use today like the Porges, Falk, von Theobald, Heaney, Joel-Cohen and the Chicago methods are carried out with defined sequences. These sequences result from personal interpretations of the pelvic anatomy and the individual experience of the authors. When hysterectomy is indicated, because of the quick recovery, the lack of abdominal scar and the short hospital stay vaginal route should always be considered.

In order to find out whether vaginal hysterectomies can still be optimized and simplified re-evaluation of the six mentioned methods was done by Michael Stark Sandro Gerli Gian Carlo, Di Renzoy. Steps common to all these methods were defined and analysed. Then the steps were re-assessed and excluded if considered unnecessary. Thereafter, the ways of performing the

essential steps were critically compared. As a result, only the re-evaluated and absolutely irreplaceable steps remained, some times with modifications. Finally, their logical sequence was defined and described.

The result is the so-called 'Ten-Step Vaginal Hysterectomy'. This method is logical, easy to learn, to perform and to teach. These are -

**Dr. Manik Gurram**  
Consultant, OBGY Solapur

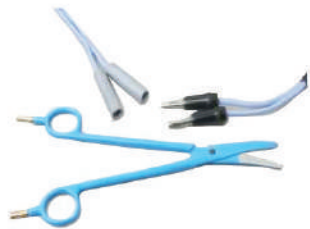1. INCISION OF THE VAGINAL WALL
2. DETACHING BLADDER FROM THE UTERUS
3. OPENING POSTERIOR PERITONEUM
4. DISSECTION OF THE LOWER PART OF THE UTERUS
5. CUTTING AND LIGATING THE UTERINE ARTERIES
6. OPENING THE ANTERIOR PERITONEUM
7. DISSECTION OF THE UPPER PART OF THE UTERUS
8. THE 'NON-STAGE' - LEAVING THE PERITONEUM OPEN
9. RECONSTRUCTION OF THE PELVIC FLOOR IF REQUIRED
10. CLOSING THE VAGINAL WALL

There are various ways to perform vaginal hysterectomy.

1. Vaginal hysterectomy with use of clamps & ligation of pedicles.
2. Clampless vaginal hysterectomy with ligation of pedicles.
3. Vaginal hysterectomy with use of energy sources.

Advantages of use of energy sources :

Bipolar coagulation is a simplest, easily available and affordable source of energy.



Bipolar Scissors



Bipolar Shearer

Bipolar electrocautery was confirmed to be safe and useful even for open surgery by reducing the operating time and blood loss without increasing postoperative morbidity.

Thus its use would lower the cost of surgery.

This beneficial effect was found to be more pronounced in difficult NDVH procedures.

Simple bipolar energy source is available at any small nursing home.

Bipolar & Step Ladder Technique NDVH easy for any one and can be done anywhere at affordable cost to patients. These are our day to day used cautery machines. Not very high end machines. Time required for bipolar electrocauterization is less as compared to ligation method. More number of ligatures are required for the routine method.

Postoperative pain is very less in bipolar cauterization. Blood loss is less with bipolar method as compared to ligation method.

Tying the pedicles with ligatures makes ischemic pedicles with nerve endings are open. Suture material produces foreign body reaction.

Prolonged compression over bladder & rectum is avoided as less time required for bipolar hysterectomy.

If we combine ten steps vaginal hysterectomy with bipolar coagulation, NDVH is very easy. Even difficult NDVH cases can be approached by step ladder type hysterectomy. Pedicles are easily accessible. If required oozing can be controlled by bipolar immediately.

### ADVANTAGES OF BIPOLAR COAGULATION IN VAGINAL HYSTERECTOMY ARE

Good visibility because retrograde bleeding from the uterus is avoided, shorter operating time, rapid convalescence and early mobilization for the patient, avoids ligatures, no subsequent tissue necrosis, therefore less pain.

Highly economical, Bi Clamp is reusable, the procedure saves time and suture material.

Combination of TEN STEP HYSTERECTOMY AND BIPOAR COAGULATION has beneficial effect and it was found to be more pronounced in difficult procedures and it lowers the cost of surgery for doctors and patients.

There are many Gynaecologists performing NDVH ny bipolar coagulation. If you want to try just follow few steps.

Begin with NORMAL SIZE UTERUS for Vaginal hysterectomy.

All steps are same for any other vaginal procedures.

Keep cautery ready, hold cervix.

With bipolar cautery coagulate cervical lip so that you can judge cautery setting (most of times keep it between 40 to 45 watt).

Our aim should be make that area white not black.

Open Douglas pouch, and push bladder up-



ward.

Instead of clamp or ligatures hold the pedicle with bi-clamp and cauterize till it become white and bubbles stop coming out.

Always stay near to uterus.

Start cauterization and cut the pedicle with scissors.

See for haemostasis if any ooze recauterize.

Step by step move upward by cauterizing and cutting pedicles.

Even uterine pedicles can be cauterized before opening peritoneal spaces.

At the last pedicle of ovarian and cornual structures don't give extra traction.

Remove uterus .

Inspect for haemostasis. If any ooze, use bi-clamp to stop it.

Vagina suturing as usual.

**BUT NOW ONE QUESTION REMAINS. WHY THIS BIPOLAR NDVH NOT POPULAR?**

Most of the gynaecologist are not accustomed with electrocautery even during post graduate days. Using cautery for vaginal procedures is difficult for many of us. Many of

us use bipolar for laparoscopic surgery but not for vaginal surgery. Most important thing is economics of NDVH.

A bipolar clamp is reusable, energy source and Bi-clamp are the only two instrument required for bipolar NDVH.

We all know how many instruments are required for TLH or LAVH. I am sure if you ask any company, it prefers TLH or LAVH over NDVH. Its because of only economics.

But if look in to this "bipolar NDVH" from patient and doctor point of view anaesthesia requirements, cost to patient, running cost of surgery for doctors, no requirement of suture, time of surgery, man power in operation theatre, skilled assistance in surgery, post operative pain and recovery, complications rate NDVH by bipolar scores far better than TLH and LAVH.

Even at remote places, in small operation theatre, under spinal anaesthesia with help of non skilled assistants, with routine bipolar energy source (of 150000 Rs) and a reusable clamp of Rs 10,000 one can complete NDVH and can go for bigger size uterus with step ladder technique after gaining experience.





### Vaginal Hysterectomy In Cases With Previous Cesarean Sections

**The** vaginal route for hysterectomy in the present times is being pushed to background amidst the glitz and glamour of laparoscopic route, consequently the new generation of gynecologists find their experience limited because of the inadequate training. Over and above that, the vaginal route for hysterectomy in cases with previous scars on the uterus is looked upon with apprehension of not being able to find the correct planes, accidental bladder injury or bleeding. But with a better determination and a little careful approach, the gynecological surgeon can offer the patient all the advantages of the natural orifice surgery.

#### **Advantages of the vaginal route in cases of previously scarred uterus :**

Scarring and adhesion formation are the consequences of practically all the surgeries. In cases of previous LSCS, the adhesions between the bladder and uterine surface, uterus and the parietal surface of anterior abdominal wall and at times the uterus and the bowel or omentum are the ones which are found most commonly. These can be dense, covering the entire uterus, altering the entire pelvic anatomy, but are the

well settled and asymptomatic adhesions most of the times. By the vaginal route, one doesn't have to disturb these adhesions, and uterus is removed from underneath these curtains of adhesions, thus eliminating the risk of injury to the viscera while separating these adhesions before reaching the uterus, by the abdominal or laparoscopic route. One just has to dissect the bladder away from the uterine surface or excise the fibrous band from the uterus to the parietal wall. Of course one has to take the help of a laparoscope in a few cases where the approach is difficult by the vaginal route.

#### **Preoperative evaluation before planning the surgery.**

**A) History :** Detailed history of why, how and where the cesarean sections were done and complications if any.

#### **B ) Clinical examination :**

**Per Abdomen :** Nature of the scar, whether uterus is palpable or not

#### **Per speculum :**

1) A stretched up posterior wall of the vagina, the cervix that is difficult to visualize and grasp with the vulsellum and the puckering of

**Dr. Mukesh Rathi**  
Consultant, OBS & Gyne, Akola

the anterior abdominal wall on pulling down the cervix (Sheth's sign), strongly suggest parietal adhesions or a band.

2) Have to mobility of the uterus.

**Per vaginal:** Size, mobility and how high the uterus is, along with the evaluation of adnexal pathology if any.

Investigations.

A good sonography for the size, number and localization. A dynamic sonography to look for the signs of suspected adhesions like a pulled up and elongated cervix, not being able to see the full bladder between the fundus of the uterus and anterior abdominal wall and markedly upwardly displaced uterus is of great help.

**Contraindications to the Vaginal route:**

- 1) Absence of uterine mobility, difficult to visualize and grasp the cervix
- 2) Positive cervico-fundal Sheth's sign
- 3) Associated big fibroids, adnexal masses, malignancy
- 4) Previous complex surgeries of the uterus like rupture
- 5) Big size uterus (depends upon individual surgeons experience)
- 6) Narrow subpubic angle or a narrow fibrosis vagina

In such cases one can take the help of laparoscope or adopt a laparoscopic or abdominal route, though with experience one can deal with some of these cases by the vaginal route.

**Examination Under Anaesthesia (EUA)**

The decision on the final route of surgery should always be taken after EUA as under relaxation, the descent and mobility tend to change. Secondly a detailed confirmation of the clinical findings, helps in making a judgement.

**Surgical approach:** Key steps and precautions.

1) Approaching the lateral window: After taking the semilunar incision on the cervix, the

two lateral corners of the anterior vaginal wall are held up, a closed scissor or a finger opens up a space medial to the uterocervical border of the incision. Bladder is dissected up to clear the cervical surface and take the uterosacral ligament. (image 1)

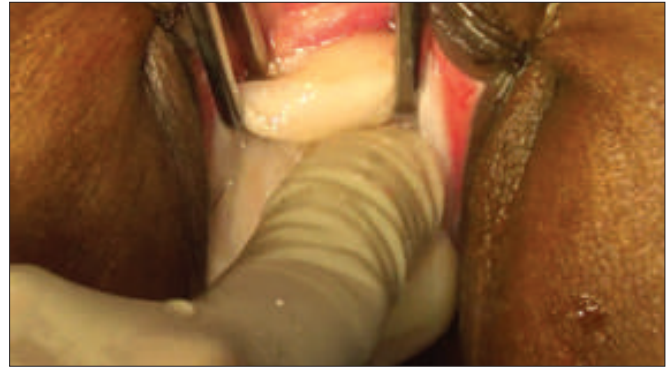

Image 1

**2) Entering the lateral window:**

Adhesions of the bladder and the uterus are mainly in the central 3/5 area of the uterocervical surface. Remaining area on the either side, is devoid of any adhesions. This surgical window (Sheth's space) just lateral to the uterocervical border and underneath the lateral most border of the overlying bladder, between the two leaves of the broad ligament is a safe space to begin the dissection from. (image 2a). The peritoneal fold just over the uterine arteries is held up, incised, and the space widened by opening up the scissor or by finger dissection over the cervicouterine surface to dissect the bladder away. This will lead to the space between the bladder and the uterovesical fold of peritoneum. Similar procedure is carried out on the other side. So now the bladder is adherent only in the centre. A right angle retractor secures the bladder underneath it on the lateral side. Under the guidance of the finger, the central part of the bladder is dissected away, close and flush to the uterus. (Image 2b)

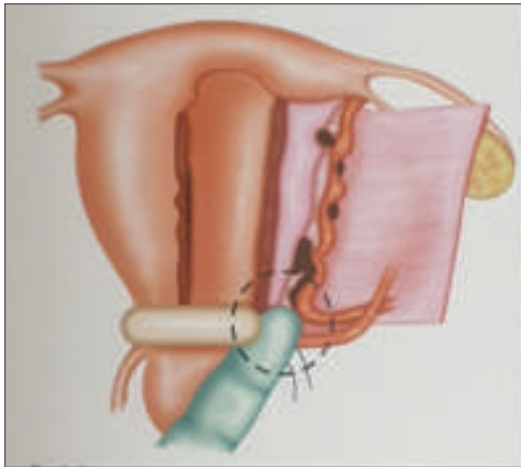


Image 2 a

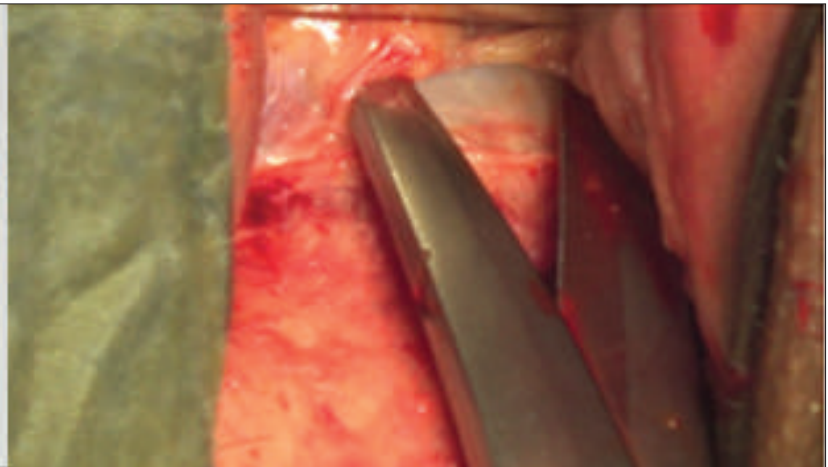


Image 2b

3) Uterine artery –cardinal ligament complex is secured , the uterovesical fold of peritoneum identified and opened, to open up the anterior pouch (Image 3)

If the UV fold cannot be opened this way then some alternative methods like retrograde opening of the pouch after delivering out the fundus through the posterior pouch or bisecting the cervix causing the thin cervical layer of the fascia to separate from the overlying bladder , thus providing the space to dissect the bladder away and open the anterior pouch .

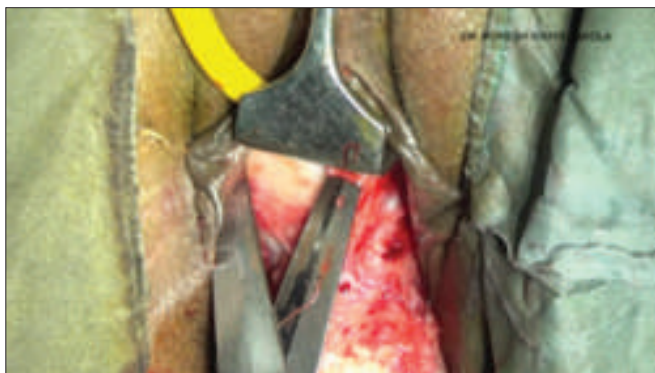

Image 3

4) From here on the routine steps of the vaginal hysterectomy are taken and the uterus de-

livered out. Flimsy omental or paraovarian adhesions can be snipped off.

5) If the thick fibrous band of adhesion is encountered, then if feasible they can be clamped and cut ( very often they are avascular) or coagulated and cut .In case the band of adhesion cannot be tackled from below, then one needs to take the help of laparoscope in certain rare circumstances.

6) After securing the pedicles and hemostasis, one must always rule out the accidental injury to the bladder. The reddish tinge or a hemorrhagic urine along with the field of surgery getting filled with watery fluid, should invariably lead to ruling out accidental cystotomy. Identifying the rent in the bladder is the next step. Filling up the bladder with 100-150 ml of normal saline with methylene blue or giving 20 mg frusemide would help in identifying the location of the rent. The anterior and the posterior margins of the rent along with the angles are identified, and depending upon the location , one must ascertain that the ureteric orifice is not close to the suture line. Bladder is then closed in 2 layers with 3-0 delayed absorbable sutures. Omental graft can be placed over the suture line if feasible or the rent is big . Sub-



sequently the vault is sutured and the bladder catheter (no 16 or 18) kept 5-20 days depending upon the extent of injury .

Non feasibility of the vaginal route for the scarred uterus is a thought barrier. With a proper knowledge of the anatomy and the surgical principles superseded by the zest to do it, the majority of such uteri can be removed by the vaginal route .

“ It is really difficult to say what is impossible for us “

### REFERENCES

- 1 ) American College of Obstetricians and Gynaecologists (ACOG ) . Vaginal hysterectomy often a better option than abdominal .ACOG Today.Washington DC, USA, American College of Obstetricians and Gynaecologists. 2009, Nov/
- 2) Surgical approach to hysterectomy for benign gynecological diseases. Cochrane Database Syst Rev. 2015 Aug 12;(8):CD003677. doi: 10.1002/14651858.CD003677.pub5.
- 3) Sheth SS.: Vaginal hysterectomy or abdominal hysterectomy. In: Sheth SS, Sutton C, eds Menorrhagia. Oxford: Isis Medical Media, 1999: pp. 21330
- 4) Sheth SS, Hajari AR, Lulla CP, Kshirsagar D.: Sonographic evaluation of uterine volume and its clinical importance. J of Obstet & Gynecol Research. 2017; 43: 185-189.
- 5) Sheth SS.: An approach to Vesicouterine Peritoneum through a New Surgical Space. J Gynecol Surg. 1996; 12: 135-140.
- 6) G. D. Maiti<sup>1\*</sup>, Ashok Pillai<sup>2</sup> : Non-descent vaginal hysterectomy in women with previous caesarean section scar: our experience : International Journal of Reproduction, Contraception, Obstetrics and Gynecology 2018 Jun;7(6):2404-2409
- 7) ShethSS .: Vaginal hysterectomy in women with a history of 2 or more cesarean deliveries ; Int. journ of Gynaecology and Obstetrics , 122(2013) 70-74
- 8) Ozdemir E, Ozturk U, Celen S, Sucak A, Gunel M, Guney G, et al. Urinary complications of gynecologic surgery: iatrogenic urinary tract system injuries in obstetrics and gynecology operations. Clin Exp Obstet Gynecol. 2011;38:217-20
- 9) Mamik M.M. Antosh D. Risk factors for lower urinary tract injury at the time of hysterectomy for benign reasons. IntUrogynecol J Pelvic Floor Dysfunct. 2014; 25: 1031-1036





## PELVIC ANATOMY in the context of VAGINAL SURGERIES

### Introduction :

Vaginal surgery requires comprehensive knowledge of pelvic floor. For safely attain access. Maximum exposure. Ensure hemostasis. Avoid injury to bladder blood vessels & bowel.

### What is Pelvic Floor?

Dome shaped muscular sheet which provides primary dynamic support to pelvic viscera along with connective tissue and ligaments that keep the viscera in position.

It consists of pelvic diaphragm, superior perineal membrane, deep perineal pouch and perineal body.

Maintains the continence of urine, faeces.

Allow voiding of urine, defecation, sexual activity and child birth.

It consists of pelvic diaphragm formed by levator ani and endo pelvic fascia.

Which in turned is formed by

1. Pubo coccygeus which is comprised of two parts pubo vaginalis and pubo rectalis.

Pubo coccygeus muscle is inserted into coccyx. Medial most fibers of right and left belly meets in the center and forms a thick plate called as ano coccygeal Raphae or levator plate.

2. Illio coccygeus Arises from arcus tendenus below the arcuate line, goes downwards and backwards and get inserted into coccyx and

last piece of sacrum and give support to pubo coccygeus.

3. Coccygeus muscle. It arises from last part of arcus tendenus at ischial spine and inserted into coccyx.

Arcus tendenus is formed by thickened fascia covering obturator internus muscle also called as white line. White line extends from posterior surface of pubic symphysis to 0.5 cm below illepectineal line & ends at ischial spine.

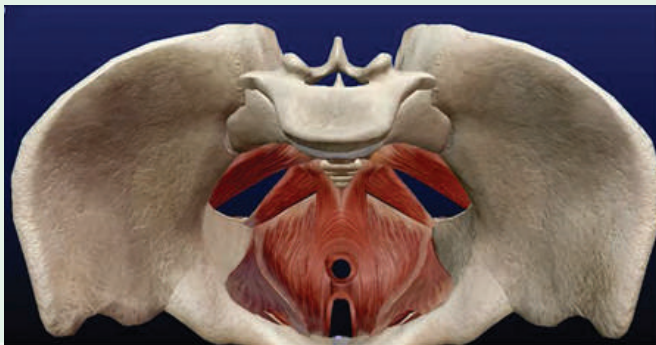### Authors

**Dr. S. S. Mehendale**

Prof. Emeritus, Bharati Vidyapith,  
Pune

**Dr. S. P. Kakatkar**

Consultant Gynecologist, Pune



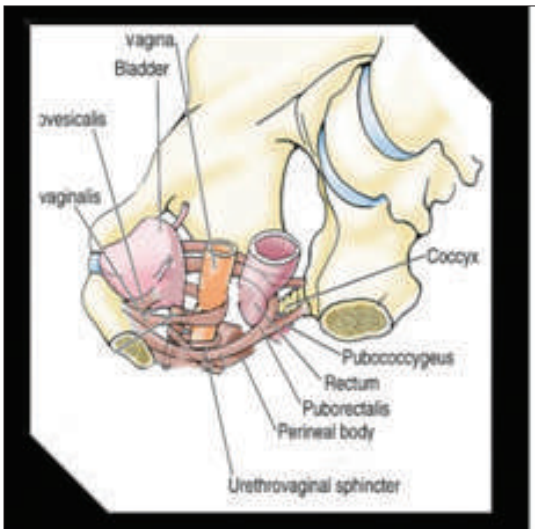
Basic tone of levator ani is due to 70% slow twitch fibers and 30% fast twitch fibers which are situated at peri urethral site and anorectal junction.

**Function:**

With increase intra abdominal pressure the

fast twitch fibers are activated so that both the hiatus get compressed prevents sagging levator ani and prevents incontinence too.

There are two openings in levator ani, Anterior is hiatus urogenitalis which is surrounded by pubo vaginalis.



**Pubo Vaginalis & Pubo Rectalis Sling**

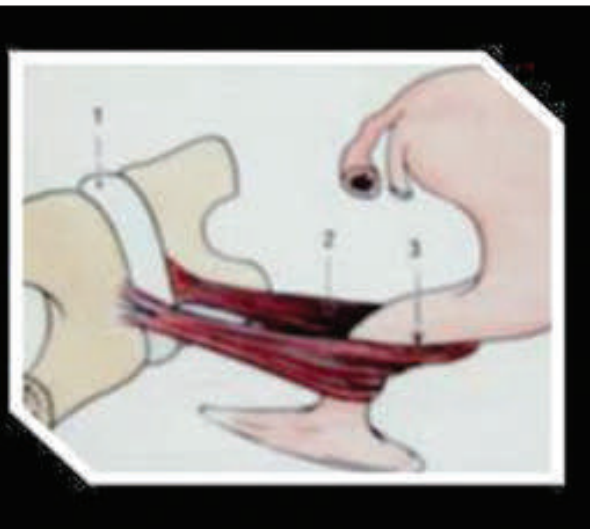
Pubo vaginalis forms sling at junction of middle and lower one third of vagina when intra abdominal pressure is raised the junction is pulled anteriorly and compresses vagina. As result upper two third becomes horizontal. So it prevents prolapse.

Posterior opening is hiatus rectalis which is surrounded by pubo rectalis. Pubo rectalis forms sling at ano rectal junction. When intra abdominal pressure is raised anorectal junction is compressed and pulled anteriorly and anorectal angle becomes acute.

In turn prevents incontinence.

Pubo vaginalis forms sling at junction of middle and lower one third of vagina when intra abdominal pressure is raised the junction is pulled anteriorly and compresses vagina. As result upper two third becomes horizontal. So it prevents prolapse.

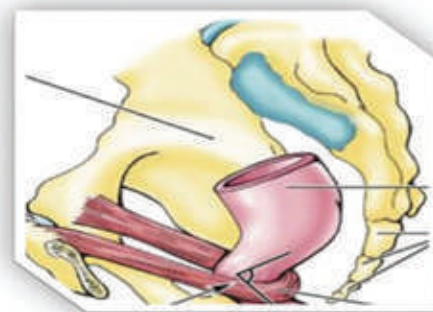
Posterior opening is hiatus rectalis which is



**Pubo Vaginalis Sling**

surrounded by pubo rectalis. Pubo rectalis forms sling at ano rectal junction. When intra abdominal pressure is raised anorectal junction is compressed and pulled anteriorly and anorectal angle becomes acute.

In turn prevents incontinence.



**Pubo Rectalis**

Fibers of pubo rectalis forms the external anal sphincter .

### Endopelvic Fascia and Ligaments

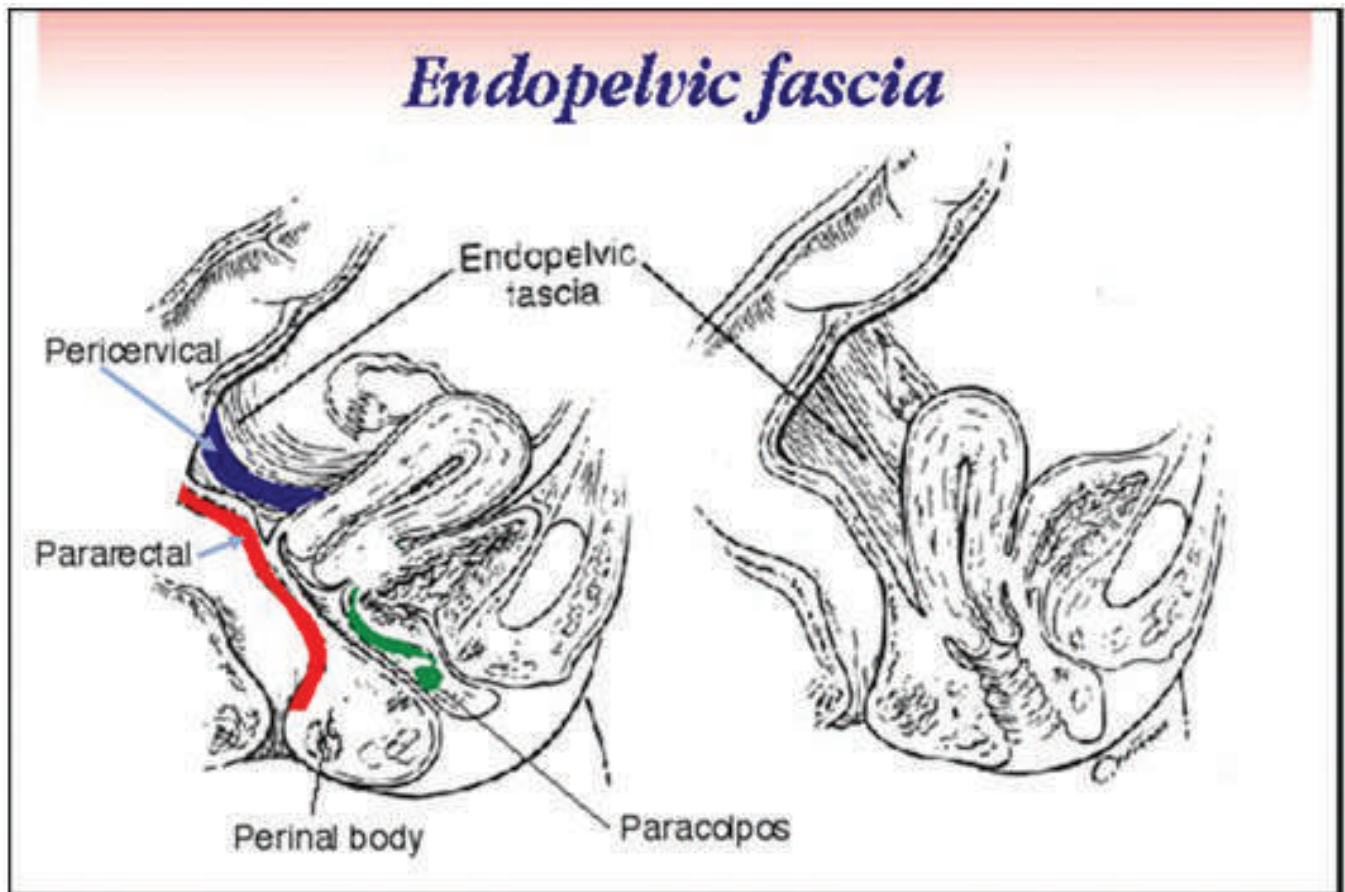
It is mesh like group of collagen fibers interlaced. with elastine smooth cells and fibroblasts. It is parietal and visceral. Parietal fascia is dense and thick. It covers levator ani muscle on superior and inferior aspect, is attached laterally to arcus tendineus.

Visceral fascia covers bladder, uterus cervix and vagina and anterior wall of rectum posteriorly. Endopelvic fascia covering the bladder and anterior vaginal wall is thin as compared

to recto vaginal septum. Endopelvic fascia covering upper two third posterior vaginal wall and anterior surface of rectum forms a thick plate called as rectovaginal fascia or Denon Villiers fascia.

At hiatus urogenitalis and rectalis parietal fascia merges with visceral fascia and forms thick ring at hiatus and prevents prolapse as well as incontinence.

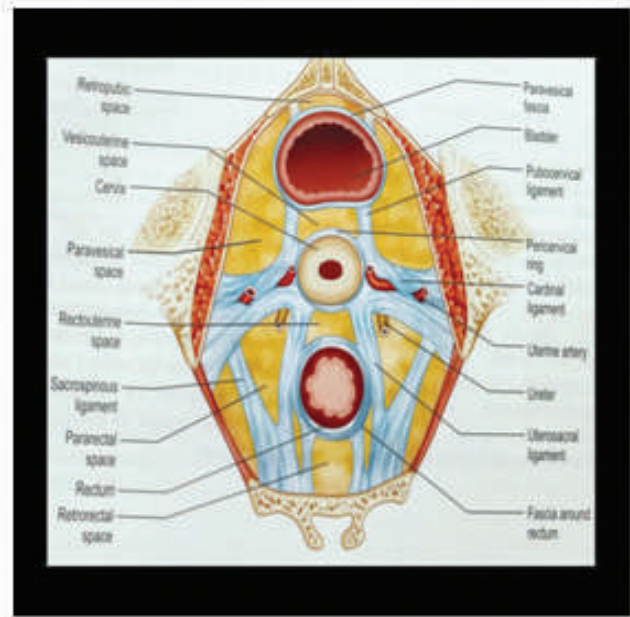
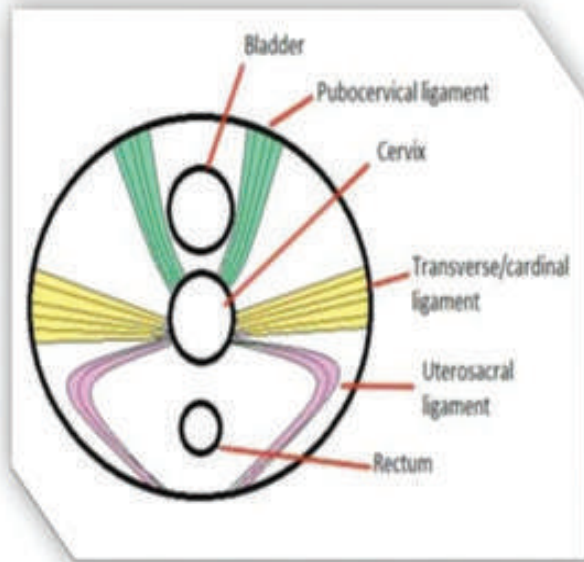
Visceral fascia covers bladder, uterus, cervix, vagina and anterior and lateral wall of rectum.



Ligaments

This is thickened endopelvic fascia with

smooth muscle. It forms a ring around supra vaginal part of cervix.



These are pubo cervical, transverse cardinal or Mackenrodt ligament, uterosacral ligaments.

Important avascular spaces are present between ligaments are para vesicle, vesico cervical, recto vaginal, recto sacral and para rectal spaces.

Blood vessels pass through the ligaments and not through the space.

Ureteric tunnel is situated in Mackenrodt ligament. In the tunnel, ureter lies 1.5 cm lateral to the cervix at internal os. At this point there is crossing of uterine artery and ureter. Uterine artery is on the roof of tunnel and then ascends close to uterus. At the crossing point it gives descending cervical and circular artery.

Vagina is supplied by different branches of internal illiac. They form azygous vessels.

### Relation of Ureter with Ligaments

Mean distance of ureter in ureteric tunnel from the cervix is 1.5 cm.

Mean distance from uterosacral liga-

ments closed to cervix at insertion  $0.9 \pm 0.4$  cm

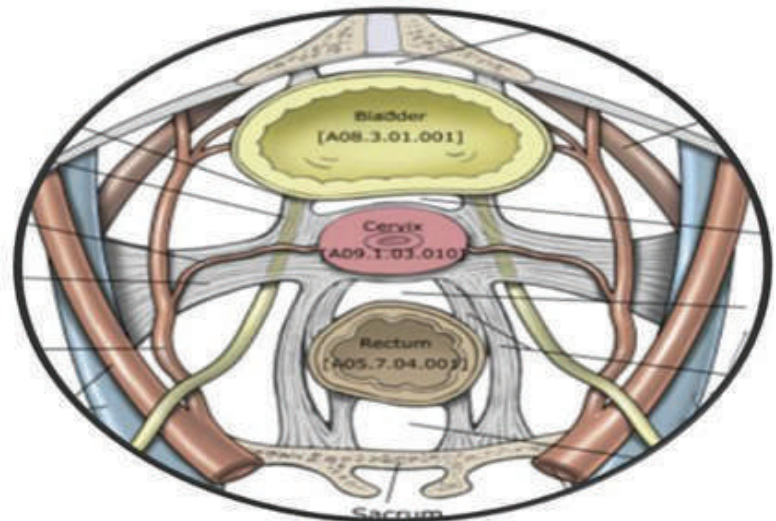
Middle part is  $2.3 \pm 0.9$  cm

At sacral region it  $4.1 \pm 0.6$  cm

It is approximately 1.2 cm from the lateral fornx.

### Perineal Pouches

Mean distance of ureter in ureteric tunnel



from the cervix is 1.5 cm.

Mean distance from uterosacral ligaments closed to cervix at insertion 0.9 +/- 0.4 cm

Middle part is 2.3 +/- 0.9 cm

At sacral region it 4.1 +/- 0.6 cm

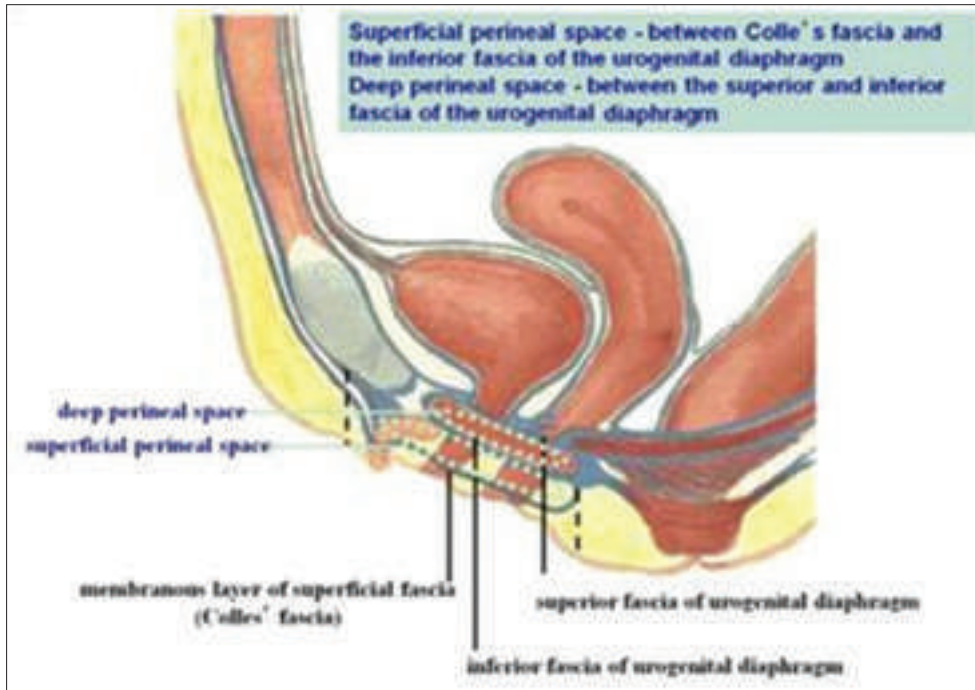
It is approximately 1.2 cm from the lateral

fornix.

## Perineal Pouches

After leaving hiatus urogenitalis, urethra and vagina enters deep perineal pouch.

Deep perineal pouch is formed by superior and inferior perineal membrane.

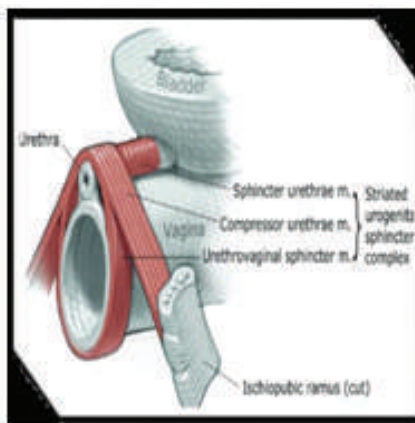
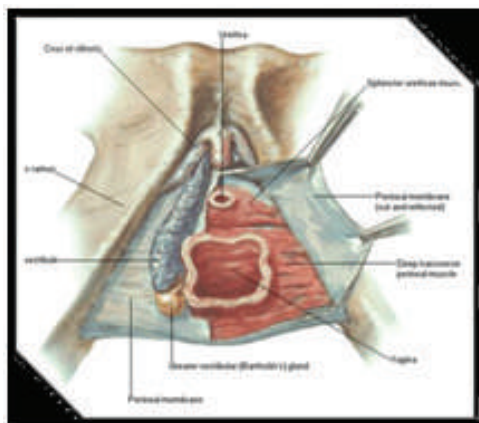


Perineal membrane is fibromuscular attached to lower border of pubic symphysis, descending rami of pubis, ischial tuberosity and to the base of perineal body.

After opening the inferior perineal membranes deep perineal pouch is visible in which deep transverse perineal muscle and striated

urogenital sphincter complex comprising sphincter urethrae, compressor urethrae and urethra vaginal sphincter and then urethra and vagina open at the vestibule.

Underneath the bulbospongiosus muscle, inferior perineal membrane is seen. On which vestibular bulb and bartholin gland is seen lat-



eral to vagina. Superficial perineal pouch is between the inferior perineal membrane above and Colle's fascia below.

Pelvic outlet is divided in two triangles anterior is urogenital and posterior is anal triangle.

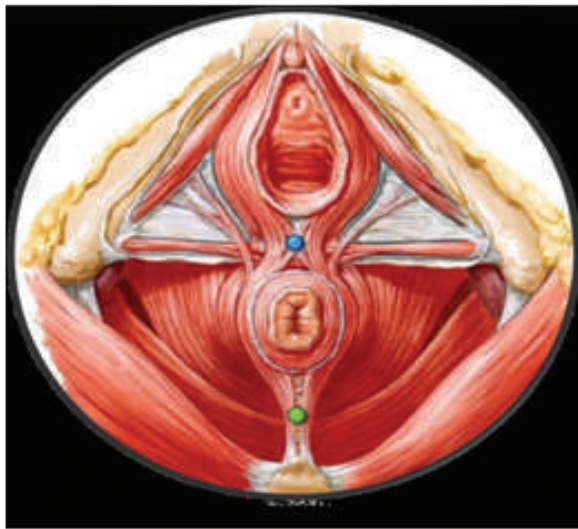
Inferior perineal membrane covers the urogenital triangle of pelvic outlet.

Posterior triangle is not covered by perineal membrane. It is comprised of levator ani muscles when perineal body contracts perineal membrane compresses the vaginal and urethral opening preventing incontinence of urine.

### Perineal Body

Three layers of the muscles of pelvic floor are represented in perineal body.

Formed by



1. Bulbospongiosus
2. Superficial transverse perineal muscle
3. External anal sphincter

Middle piece

Deep transverse perineal muscle

Sphincter urethrae

Compressor urethrae

Urethro vaginal sphincter

Apex

Formed by pubo rectalis, it is attached to

recto vaginal septum of endopelvic fascia.

### Relation of uterus with bladder and rectum

Dome of bladder is close to supra vaginal part of cervix.

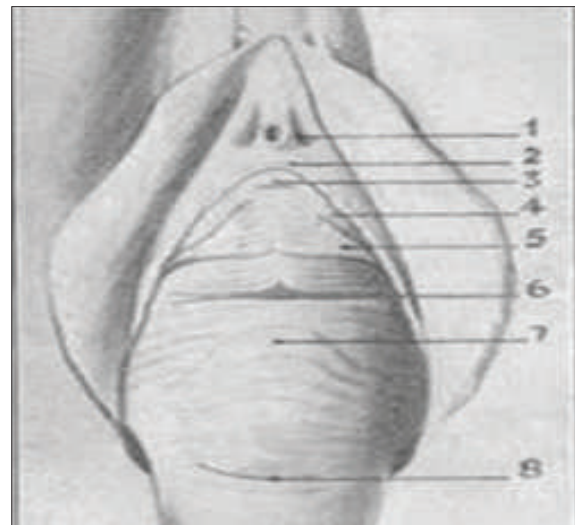
Posterior wall of bladder is in relation with upper two third of anterior vaginal wall. Urethra is resting on lower one third of anterior vaginal wall.

Upper one third of posterior vaginal wall is separated from rectum by pouch of Douglas. Middle one third of posterior vaginal wall is closed to rectum but separated by rectovaginal fascia.

Lower one third of posterior vaginal wall is related to perineal body.

### Sulci on anterior vaginal wall

1. Sub meatal sulcus
2. Transverse sulcus denotes urethro vesicle junction.



3. Vesical sulcus denotes upper limit of bladder.

### Applied Anatomy

Related to Perineal Surgery

1. In complete perineal tear posterior vaginal wall is to be separated from the rectum. This dissection should be in the rectovaginal space.

2. While suturing deep episiotomy and colpo perineorrhphy, complete perineal tear, approximation of the perineal muscles is necessary to build the perineal body.

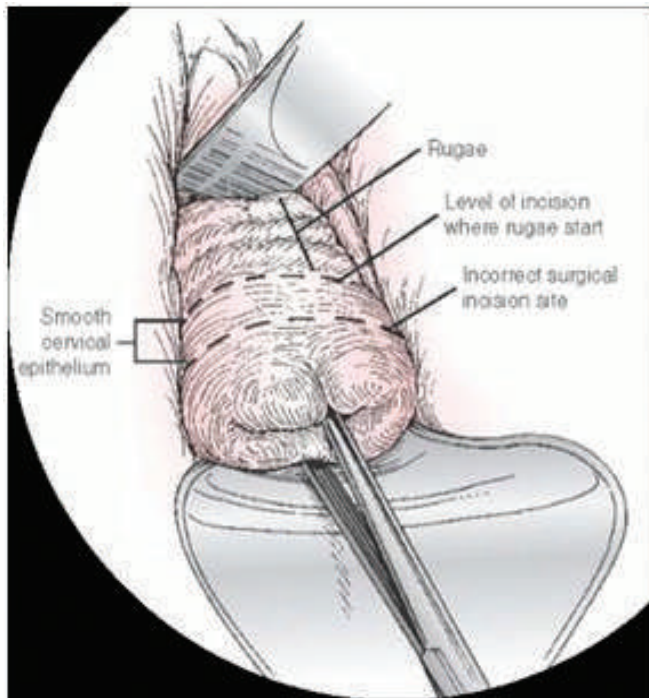
3. Identification of internal and external anal sphincter is essential for its approximation during repair of complete perineal tear.

4. In lower rectovaginal fistula repair is done by creating complete perineal tear.

### Related to Vaginal Hysterectomy

During vaginal hysterectomy, incision on anterior vaginal wall should be taken above the vesical sulcus where the rugosity starts. Below the vesical sulcus vagina is adherent to cervical tissue, incision taken on this smooth epithelium leads to disruption of cervical tissue leading to bleeding. This will cause difficulty in separation of bladder. If incision is above the vesical sulcus, inadvertent entry into the bladder may take place.

During prolapse surgery vertical incision on anterior vaginal wall should be upto transverse sulcus. Above the transverse sulcus urethra is adherent to vagina it may get damaged.

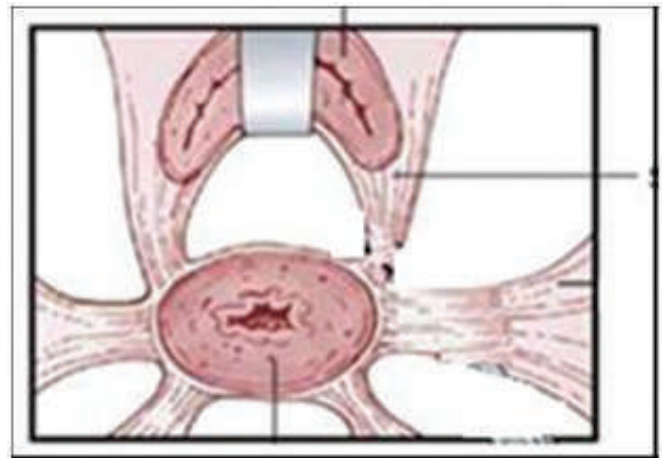


During vaginal hysterectomy separation of the bladder must be in the vesico cervical space to avoid bleeding.

After separation when the bladder is retracted, bladder pillars stand out which can be easily separated.

While opening the pouch of Douglas the incision should be at level of the rugosity.

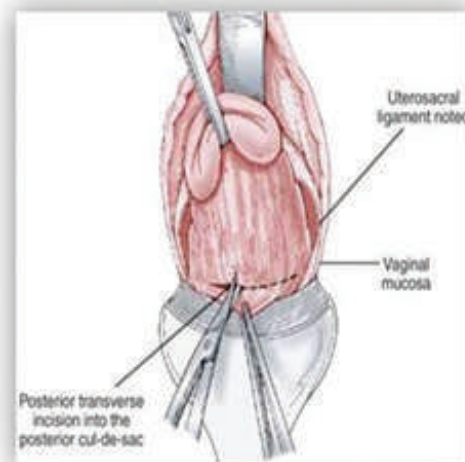
Opening of the pouch is done by two ways  
1. Direct opening along with vagina.



2. Separation of vagina is done, visualize the peritoneum and open it.

If the incision is more posterior to rugosity fat is visible.

Presence of fat denotes proximity to rectum, in turn, can lead to injury to rectum.



Uterosacral clamping and cutting should not be very close to cervix as ureters are only 0.9cm from the uterosacral.

Cardinal ligament clamping should be very close to cervix to avoid injury to ureter and uterine artery at ureteric tunnel.

In NDVH for adenomyosis or uterine fibroid, cardinal ligament may get displaced due to irregularity and enlargement of uterus.

In cervical fibroid before clamping ligaments enucleation is necessary as anatomy is distorted.

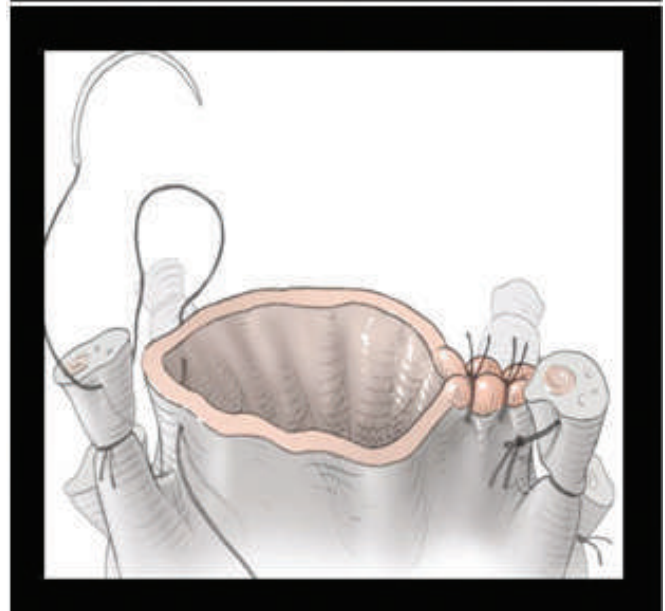
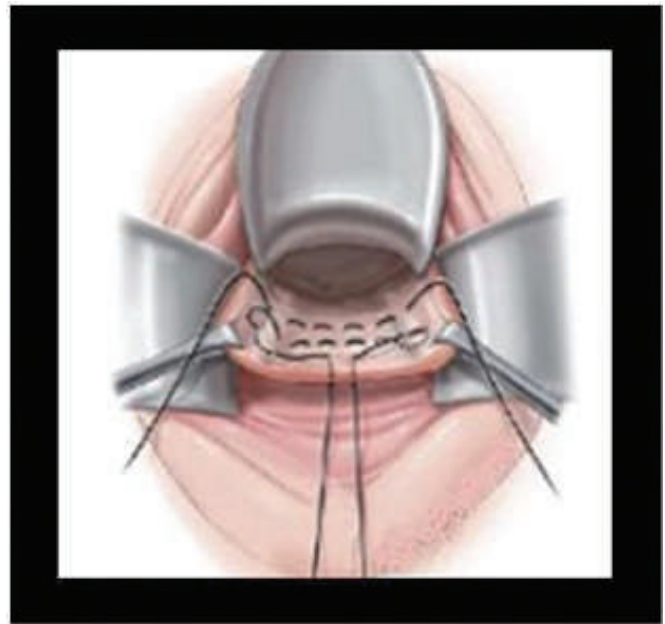
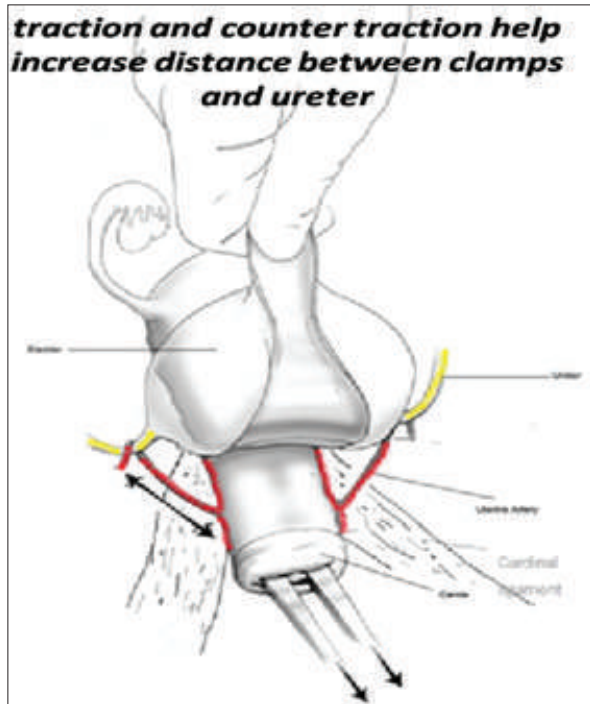
In prolapse uterus with supra vaginal elongation, there is fanning of cardinal ligament at its attachment to the lateral wall of supra vaginal part of cervix. May need multiple clamping and cutting for ligating the Mackenrodt ligament. If not, uterine artery may get damaged.

Uterine artery should be clamped and cut close to internal os to avoid injury to ureter.

In case of NDVH for broad ligament fibroid, extra care is necessary. Pseudo broad ligament fibroid arises from the lateral wall of uterus and enters into the broad ligament. Ureter and uterine artery are displaced laterally. In true broad

ligament fibroid, ureter and uterine are posterior medial to fibroid.

After uterine artery ligation, the clamp should be applied on cornue, which includes round ligament, ovarian ligament and tube. After removal of uterus, if enterocele is present, Macold's culdoplasty is done. Anchoring of utero sacral and Macendrot ligament is done to vaginal angle for prevention of vault prolapse.







During cystocele and rectocele repair if the plane is not proper, there will be bleeding as vagina is vascular.

During cystocele repair pubo vesico cervical fascia is approximated.

During rectocele repair it is essential to approximate the para rectal fascia and recto vaginal fascia.

It is attached to the apex of perineal body. It supports rectum and posterior vaginal wall preventing rectocele.

Perineorrhaphy is done to reduce the vestibule.

During conservative surgical procedure for prolapsed

A. Fothergill operation Mackenrodt is stitched anteriorly to support bladder base.

B. In Shirodkar's modification, utero sacral ligaments are brought anteriorly and stitched over the anterior wall of cervix making the uterus anteverted. Advancement of Pouch of Douglas is also done.

In stress incontinence secondary to posterior urethro vesicle angle disturbance, Kelly stitch is taken which should be at the level of transverse sulcus for restoration of angle.

Le Forte operation is essential to approximate fascia covering anterior and posterior vaginal wall which forms thick septum between tunnels of vagina.

### Vault Prolapse Repair

During sacrospinous fixation of vault, care should be taken to anchor the stitch by passing the needle 1 to 1.5 cm medial to ischial spine to prevent injury to pudendal vessel.

### Conclusion

For uneventful vaginal surgery precise knowledge of pelvic floor, proper training in different surgical procedures and perfect selection of the cases is essential.

### References

1. Gastroenterol Clin North Am. 2008 September; 37(3) 493-VII
2. Hawkins & Bourne; Shaws Textbook of Gynecology'; Chapter 1, Page 13 (14th Edition)
3. D C Datta's Textbook of Gynecology, Chapter 1, Page 13, (7th Edition)
4. Schorge Schaffer Halvorson, Hoffman Bradshaw Cunningham Williams Gynecology, Chapter 38, Page 779
5. State of the Art Vaginal Surgery by Neerja Goel, et all, Chapter 2, Page 8, 2nd Edition.
6. Pelvic Anatomy Revisited, Clinical Application, Dr. Nirmala Vaze, Chapter 2, Page 19, (1st Edition 2018)
7. American Journal of Obstetrics & Gynecology, Vol. 222, Issue 3, Page 204-218, Mar 1, 2020 .



## Tips & tricks in safely opening anterior & posterior pouches.

Vaginal hysterectomy is a common procedure performed routinely by gynaecologists efficiently. “Well begun is half done” is a famous English proverb. Opening the anterior and posterior pouches is the initial task involved in performing vaginal hysterectomy and it is also easily done mostly. It can however be opened with difficulties. This chapter gives a few tricks and tips to ensure successful and safe access and makes us sail through the whole procedure smoothly.

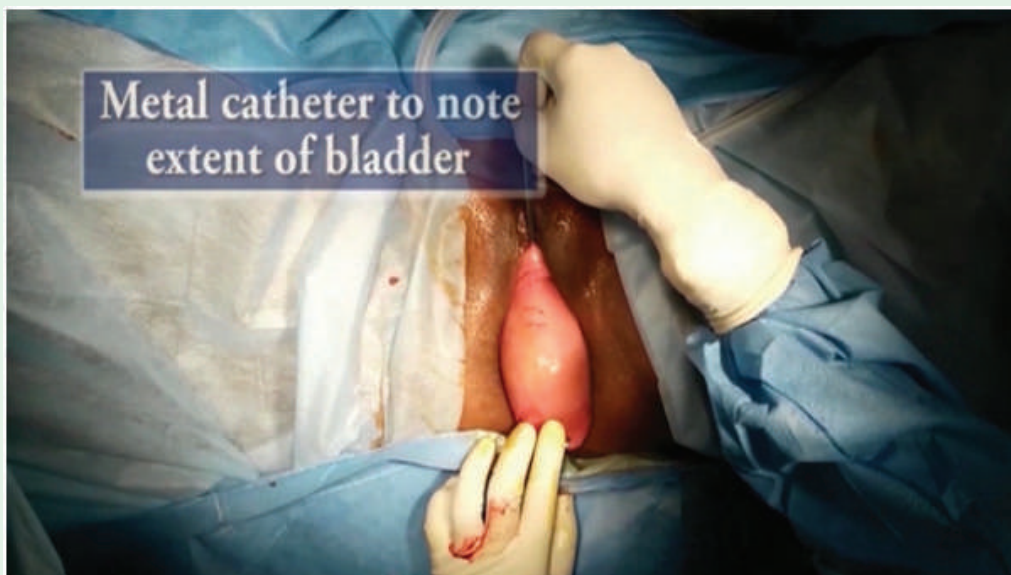
### Opening the anterior pouch.

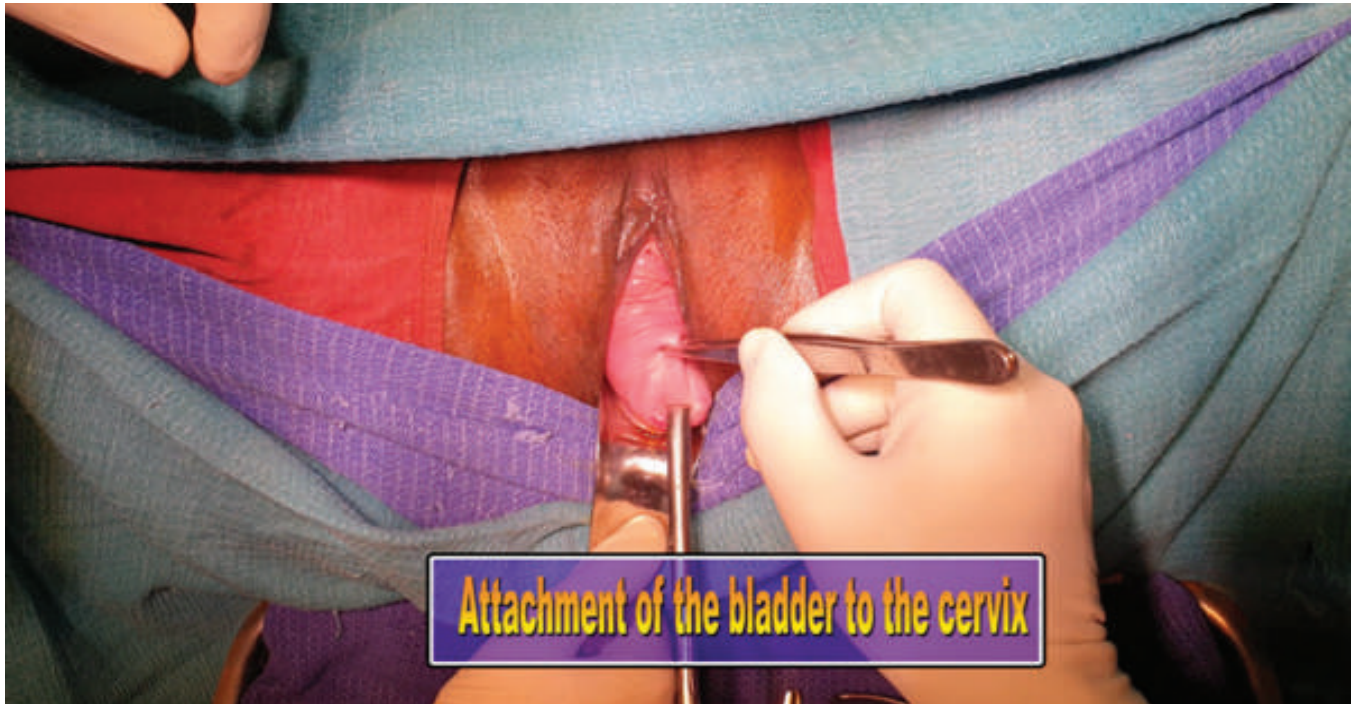
**Prof. Dr.  
Mrs. T. Srikala Prasad**

Professor & Head of the  
Department of Urology,  
Chengalpattu Medical College,  
Tamilnadu.

Where to put the circular incision in the anterior vaginal wall? This is an important deciding factor for successful **anterior colpotomy**. Emptying the bladder prior to any pelvic surgery is an important step which will empty the bladder and minimise the

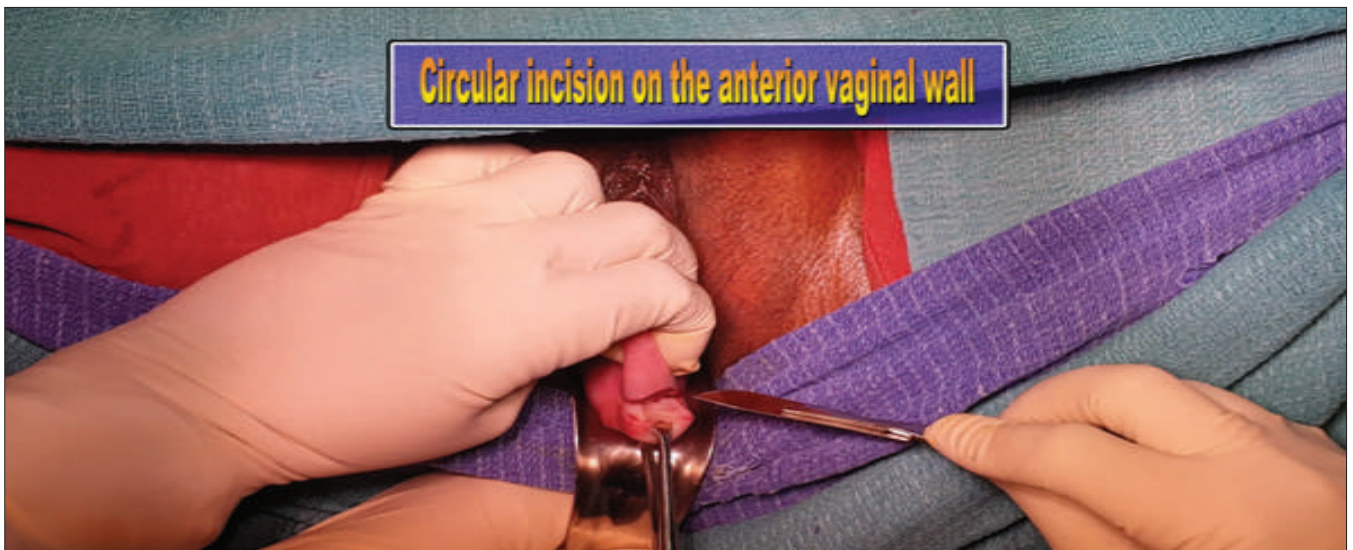chances of inadvertent bladder injury. The same metal catheter can be used to know the extent of the bladder.





The bladder sulcus is identified on the anterior vaginal wall. This can be seen as the place where the bulging bladder margin comes and gets inserted on to the cervix. We will be able to see a crease at the junction between the bladder and the cervix. This crease will get accentuated if we give to and fro movement of the uterus with a vulsellum forceps held on to the anterior lip of the cervix in the midline.

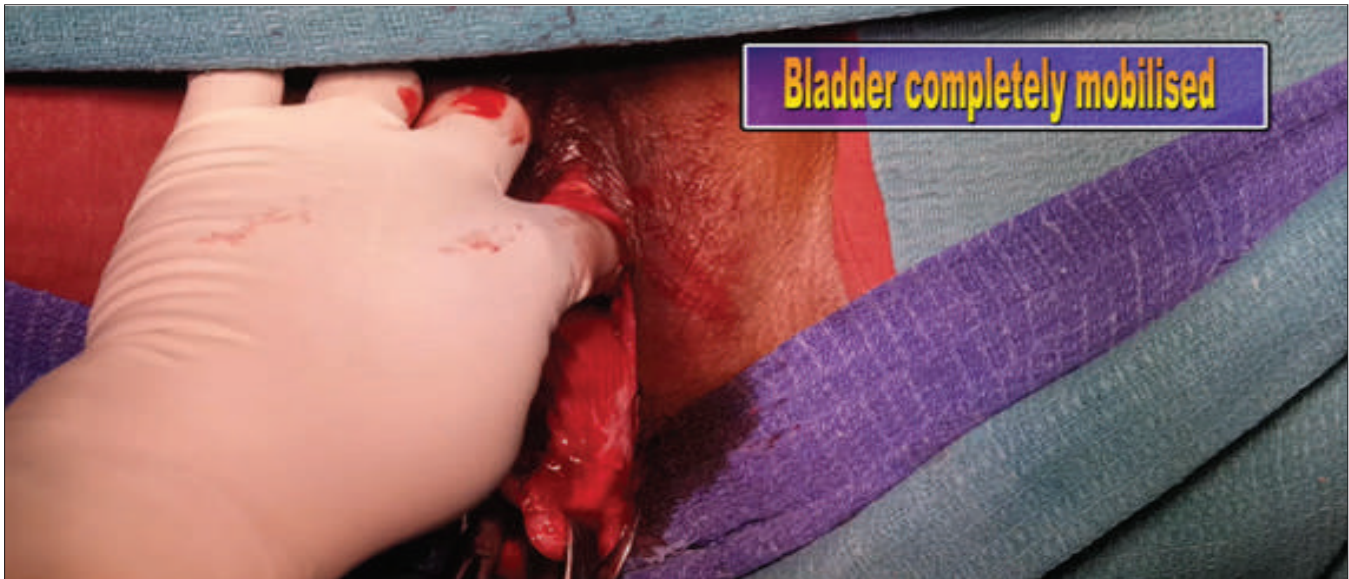With the anterior lip of the cervix being held with a vulsellum forceps and downward traction applied, we can use our nondominant hand to catch the anterior vaginal wall (including the cystocele) and give countertraction. This will clearly identify the place where the bladder and we can place our circular or transverse incision on the anterior vaginal wall from 9 o' clock to 3 o' clock.





Strong traction on the cervix and counter-traction with Allis forceps applied on the anterior vaginal wall is a key to successful colpotomy. This helps us to identify the bladder pillars which are the cervico vesical strands extending from the bladder to the cervix. With continued traction and countertraction, a curved scissors with curvature facing down-

wards is used to cut these strands and mobilise the bladder staying horizontal to the anterior aspect of the cervix and uterus. Having mobilised the bladder we now proceed to opening the thin utero-vesical (UV) fold of peritoneum. A bladder retractor now can be placed to safeguard the bladder.

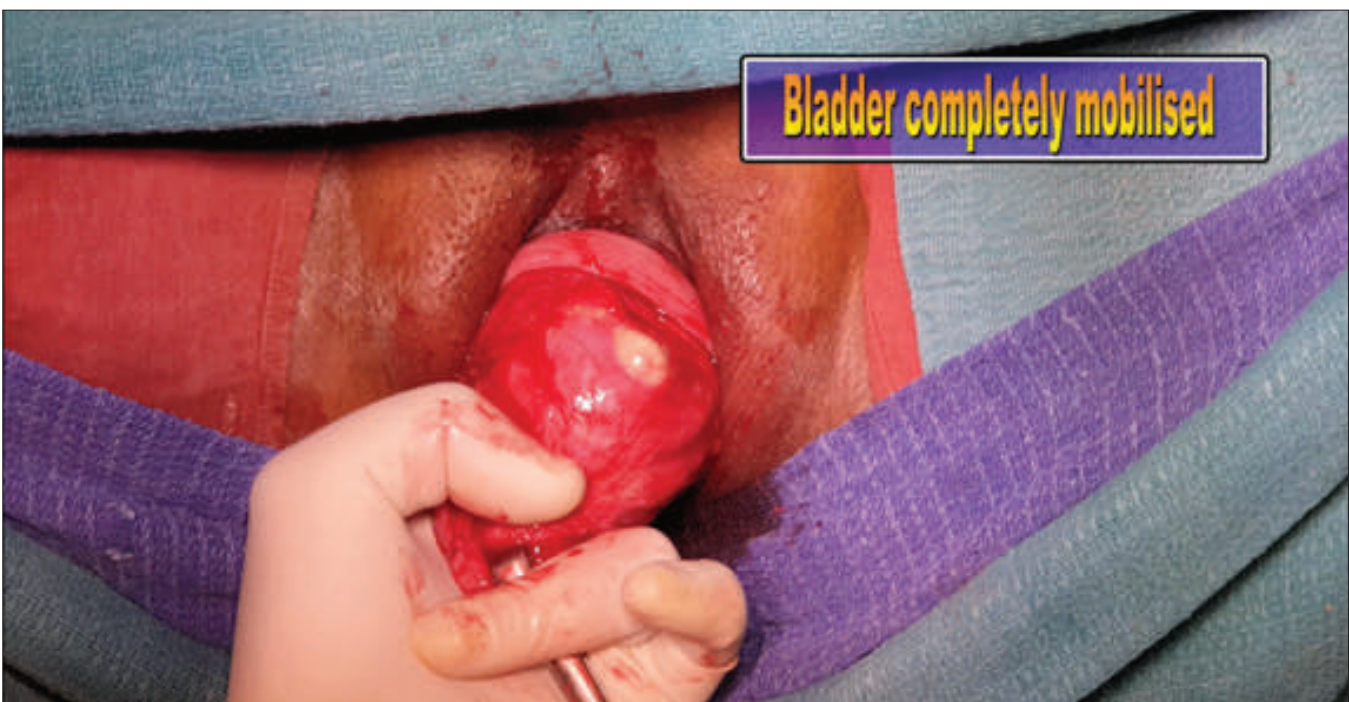

### Alternate approach

In case of difficulty in opening the UV fold of peritoneum in patients with Pelvic Organ Prolapse (POP) or in women with atrophic uterus, the Pouch of Douglas (POD) is opened and the fundus of the uterus is hooked and the

bladder is dissected from the uterus. We will now be able to see the thin UV fold of peritoneum, which is opened and the fundus of the uterus is delivered.

**Opening the UV fold of peritoneum through the POD**



### Difficult situations

#### Previous LSCS

Difficulty can be encountered when we handle a patient with history of previous LSCS. The bladder may be densely adherent to the lower uterine segment. The key to successful entry is using sharp dissection. The bladder may be lifted up using our left hand which helps in giving continued traction and by sharp dissection the bladder is safely mobilised. It is imperative to avoid pushing with gauze when the bladder is densely adherent, as it may result in bladder injury with the anterior wall of the bladder being pushed and the posterior wall adherent to the lower uterine segment. It is preferable to have few fibres of the uterus or the cervix on the bladder rather than have few fibres of the bladder on the uterus or the cervix.

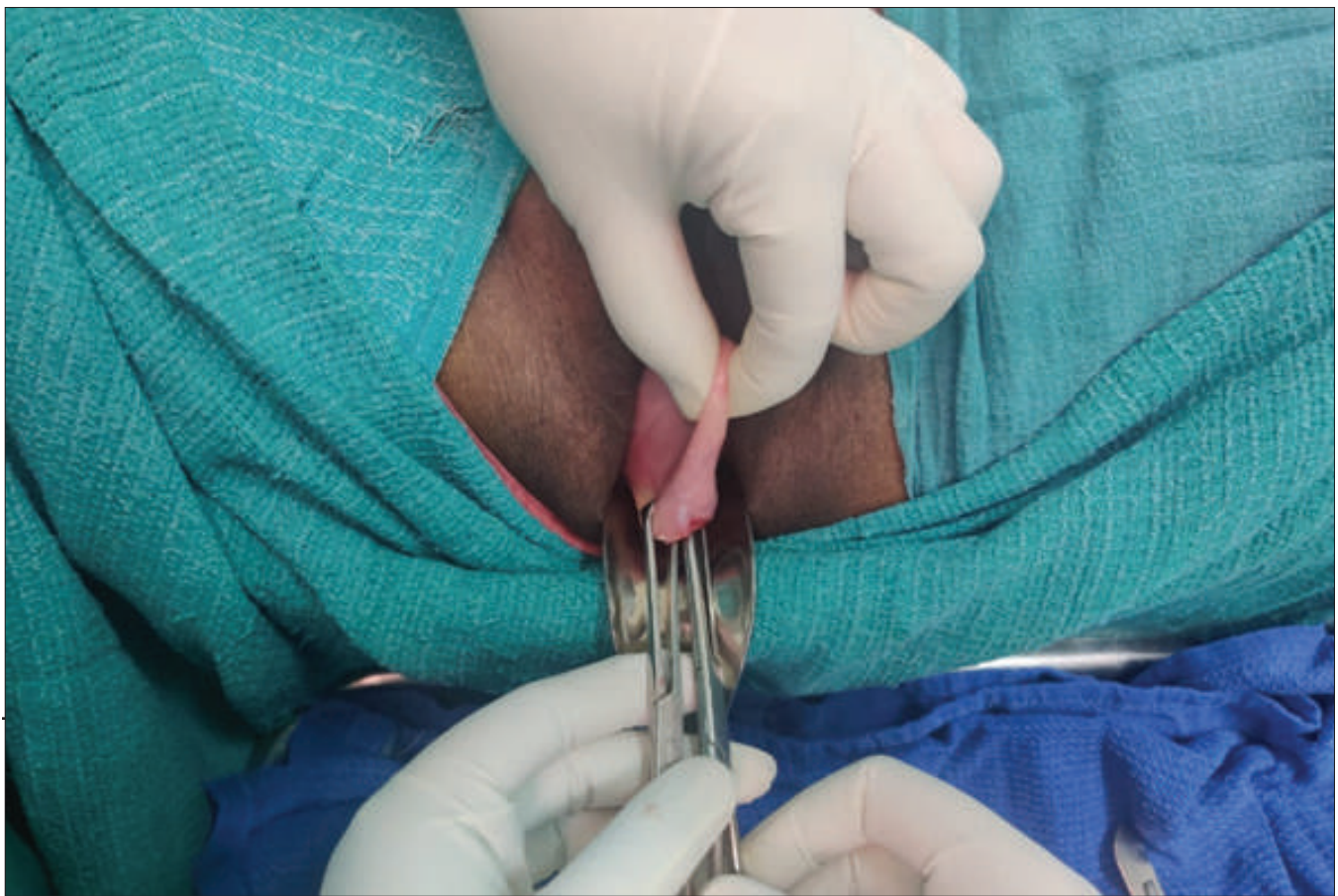Sheth's space (Uterocervical Broad Ligament Space). -Anatomically it is the middle three fifth of the bladder which is in close relation to the cervix and the lower uterine segment. The Sheth's space or the Uterocervical Broad Liga-

ment Space is the space in relation to the lateral one fifth of the bladder on either side which lies free and is not in close proximity. That is the reason we encounter dense bladder adhesions in the central three fifth in patients with previous history of single or multiple LSCS. Accessing this Sheth's space in women with previous history of LSCS would help us to prevent bladder injuries.

#### Masked anterior cervical lip

Anterior vaginal wall in some patients is seen stretching to reach the anterior lip of the cervix. This may make the access to the anterior pouch difficult. Allis forceps can be used instead of the vulsellum forceps to hold the cervix and they may be held in the 3 and 9'o clock position instead of the 12'o clock position. The anterior vaginal wall with the underlying cystocele may be held with the nondominant hand and used as traction while countertraction is given by the Allis holding the cervix. This will clearly demarcate where we have to put the incision and the rest of the procedure is the same.

### Masked Anterior Cervical Lip

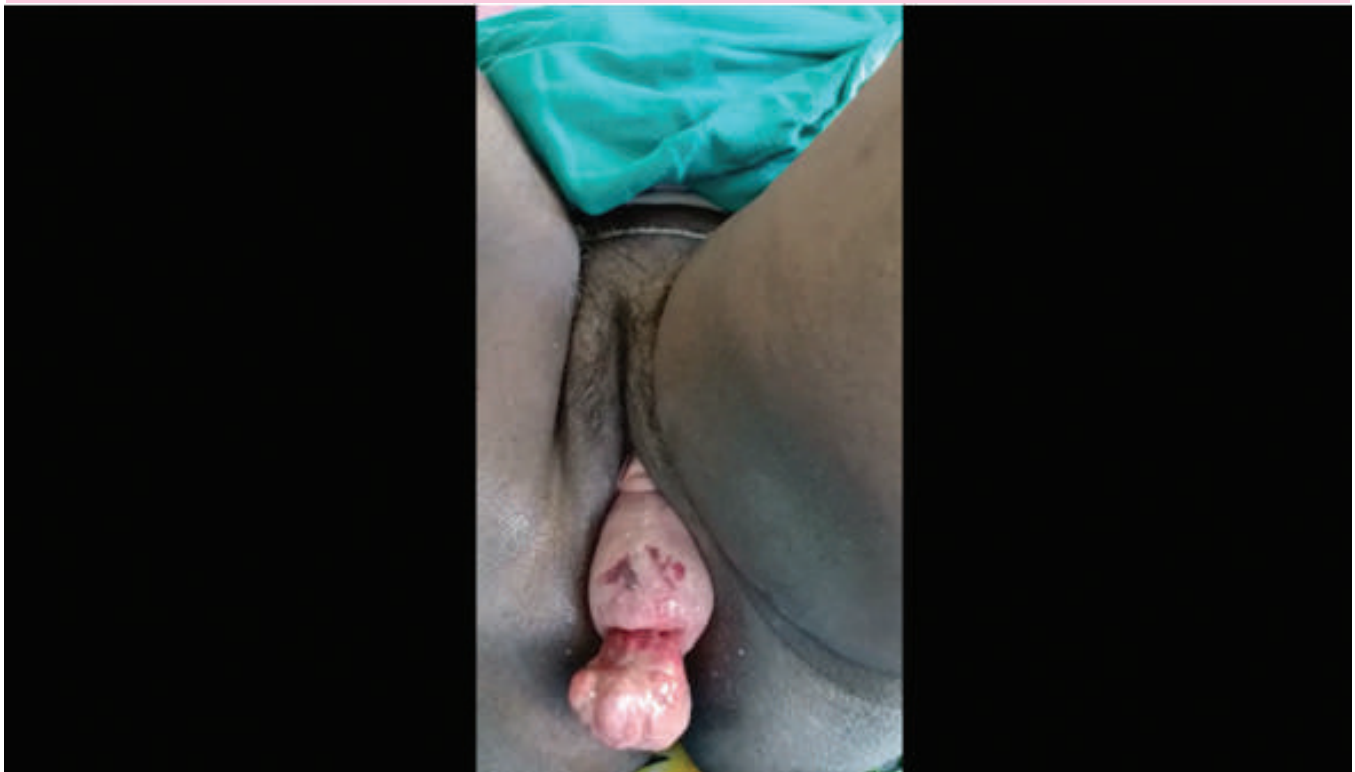

### Cervical elongation

In patients who have supravaginal elongation of cervix, the elongation of the cervix is above the bladder sulcus. The bladder sulcus is at the same level as in patients with a normal uterocervical length. The circular incision on the anterior vaginal wall is made in the usual way and further dissection is proceeded to reach the UV fold of peritoneum.

On the contrary, in patients with infra vaginal elongation, the cervical elongation is below the bladder sulcus. Depending on the length of the cervical elongation, the bladder sulcus may be far away from the external os and may be closer to the bladder neck (transverse vaginal sulcus). We need to exert care in identifying the place where the bladder gets attached and place the circular incision in the anterior vaginal wall correctly so that we enter the correct plane.

### Infra vaginal elongation of cervix with a fibroid polyp



### Anterior fibroids

Anterior cervical fibroid poses problems in dissection between the bladder and the cervix. It is better to proceed with opening the POD, tackling the USL-cardinal ligament complex and getting some more descent.

Infiltrating vasopressin into the planned area of the incision will help in reducing the bleeding. A midline vertical incision is made over the

anterior cervical wall with diathermy till we are able to see the compressed pseudo capsule over the myoma. Enucleation attempted in this plane will help removal of the myoma in a relatively bloodless way. We need to be aware of the possibility of severe bleeding in view of the fact that the uterines have not yet been tackled.

### Managing bladder injury

Detecting bladder injury is relatively easy

compared to detecting intraoperative ureteric injury. Metal catheter inserted will reveal bloodstained urine and will help identify the site of injury. Instilling methylene blue through the Foley catheter will help in identification of the injured site, in cases of a small rent.

The bladder rent can be closed in 2 layers in most patients vaginally itself. However in some patients, especially when NDVH has been done in patients who have undergone multiple LSCS we may face difficulty in repairing from below. The bladder will be at a higher level and there may be difficulty in safely accessing it for a meticulous repair. Even though we can try to improve access by giving an episiotomy or Schuchardt's, it is better to ensure safety and we need not hesitate to open. Bladder is a forgiving organ and heals beautifully when repaired well. The first repair is the best repair. All efforts to ensure a successful repair are taken.

We need to ensure that all the edges of the bladder are well mobilised and amenable to suturing. Sometimes the posterior wall of the bladder may be densely adherent to the lower uterine segment and needs to be mobilised. This situation can be managed with help from Urologist. We need to visualise both the ureteric orifices and confirm the ureteric jets. It is better to protect both the ureteric orifices from inadvertent inclusion during rent repair by DJ stenting or placing Infant feeding tubes which can be removed at the end of the procedure. There is no need to stent if the bladder rent is far away from the orifices. The ureteric orifices in some patients may be dan-

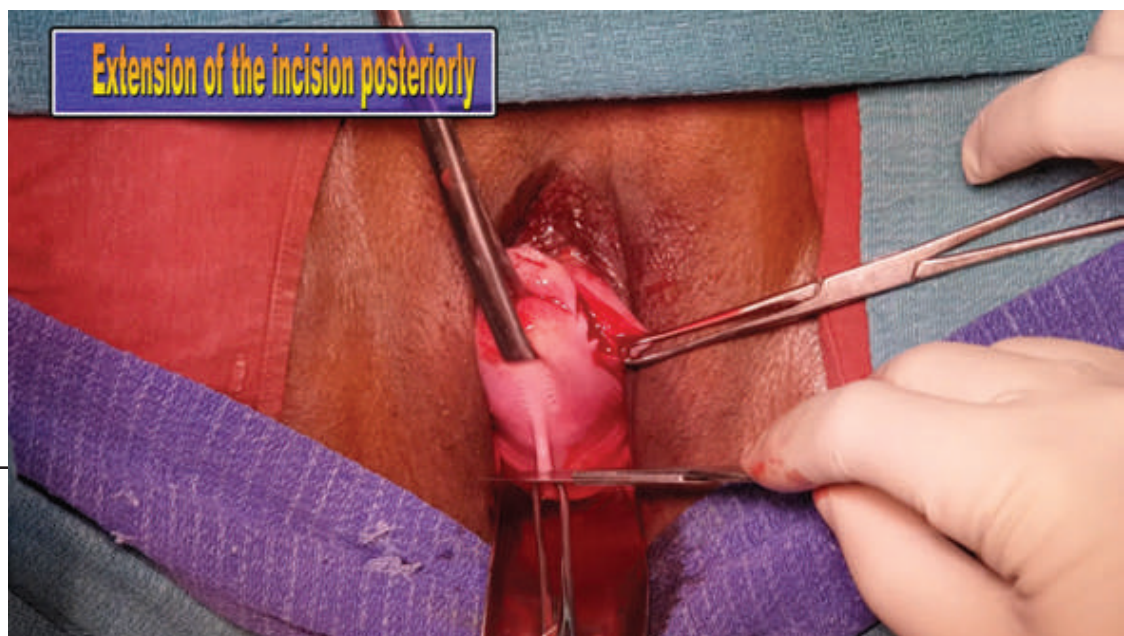gerously close requiring reimplantation. It is better to take the help of a urologist in such difficult situations. The bladder injury can be tackled after completion of hysterectomy. The bladder rent is closed in two layers with a suprapubic catheter inserted by Lowsley's technique. Excellent postoperative care ensuring adequate continuous drainage by catheter, antibiotics, analgesics and anticholinergics (to reduce bladder spasms) are given.

Simple bladder injuries can be tackled by the gynecologists. The services of a Urologist can be taken when difficulties are encountered or when the treating gynecologist does not have enough expertise in dealing with bladder injury.

### Opening the posterior pouch

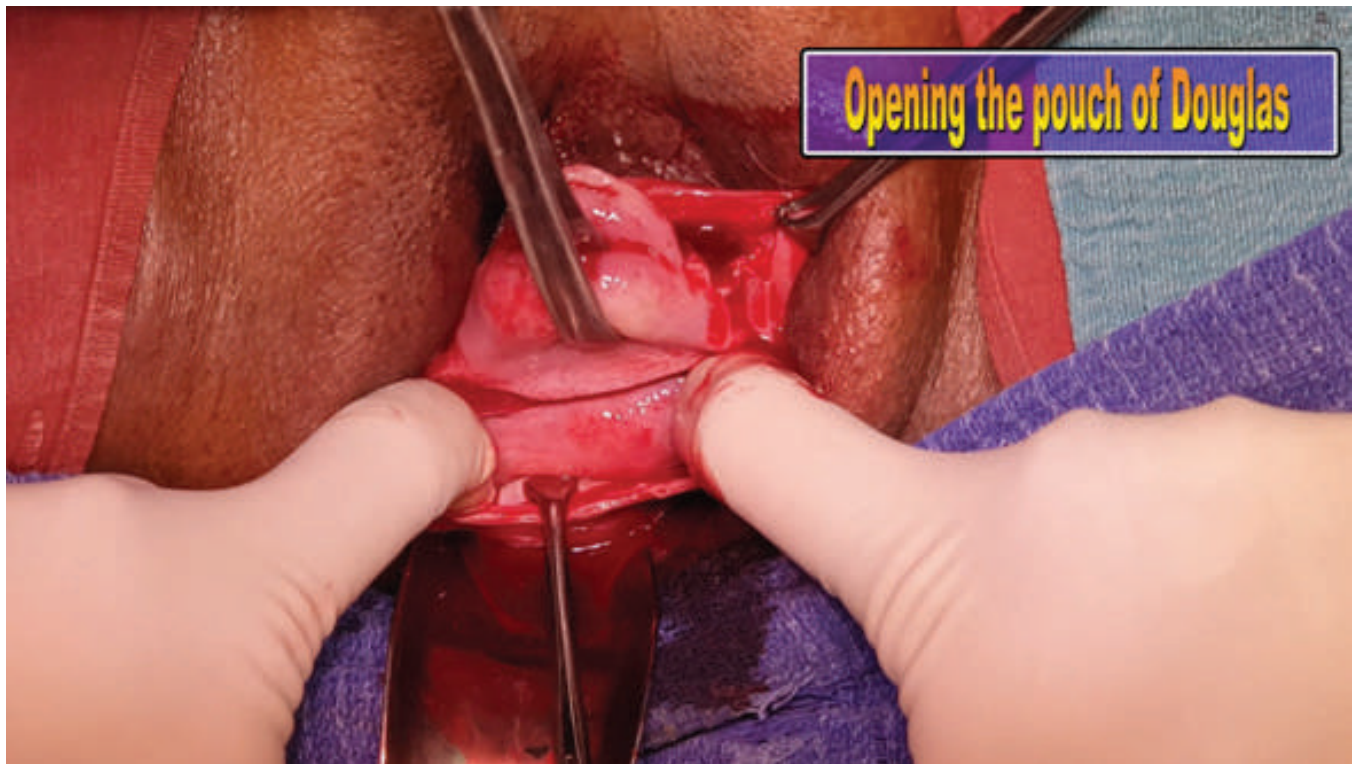
We need to know where to put the incision in the posterior vaginal wall.

The posterior lip of cervix is held with a volsellum and drawn anteriorly. The junction of the cervix and the posterior vaginal wall is identified by pushing the cervix slightly inside and looking for the transverse crease which is the first rugosity. The posterior vaginal wall and peritoneum is grasped 1-2 cm below the loose fold and a bold cut is made & the posterior vaginal wall & peritoneum are opened in one stroke itself. There will not be any bleeding as both the layers are together. Small amount of straw coloured peritoneal fluid may come out. We will be able to see the peritoneal cavity and its contents.



In case the peritoneum is not opened and we realise that only the transverse incision on the posterior vaginal wall has been made, we should proceed to safely opening the peritoneum. Two Allis forceps are used to hold the upper posterior edge and tent it. This ex-

poses the cervico vaginal fascia from which any adherent structures are cleared by pushing them away. We can catch the thin peritoneum with 2 hemostats and open it. We can see a small amount of peritoneal fluid coming out.



The opening may be extended with fingers and a Sims speculum is placed there. Catching the posterior vaginal wall and the peritoneum together with Allis forceps will ensure good hemostasis. The peritoneum is inspected for adhesions, mass lesions or other abnormalities that require care and caution. Vaginal hysterectomy can be safely proceeded now.

Difficult situations can arise which can be managed by vaginal surgeons having more surgical expertise in handling these challenging situations. The POD may be found obliterated because of endometriosis or pelvic inflammatory disorders or Genital Tuberculosis. There can be difficulty when the cervix is flushed with

the vaginal walls. Accessing either or both the anterior and posterior pouches will be a technically challenging one. It is better to begin attempting to access the posterior pouch first. Difficulty may also be encountered when the cervical lip is masked by overhanging of the posterior vaginal wall. In both these situations, the posterior vaginal wall is held in the midline from the posterior lip of cervix and reflected by a midline vertical incision preferably after hydrodissection. The fold of peritoneum is now held with hemostats and carefully opened.

The presence of posterior cervical fibroid makes access difficult. Experienced vaginal surgeons will manage with hydrodissection, vaso-





pressin infiltration, enucleation with assistance from myoma screw etc.

### **Rectal injury**

Inadvertent injury to the rectum is less common compared to the bladder being opened. We must be ready to tackle this problem. Cleansing of the rectum is done with adequate saline irrigation. The rectum is closed in 2 layers of intermittent suturing with a 2-0 delayed absorbable Polyglactin. Further protection is given by imbricating the pararectal fascia over the suture line as a third layer. It can easily be repaired by the gynecologist from below itself and does not need any diversion. In case, the site of injury appears high or the operating gynecologist feels insecure and does not have the needed surgical expertise, the services of a general surgeon or a

specialist gastro intestinal surgeon can be obtained. The need of an interpositional graft like Martius graft is not needed except in the rare instances where the vitality of the tissues are of poor quality and feared to give way.

We are sure to win if we follow the standard guidelines and safety measures and complete a vaginal hysterectomy successfully and safely. In case of difficulty one can request for a senior person's help or the help of a urologist or GI surgeon. It is not a shame to request for help or convert to open procedure or get laparoscopic assistance. The ultimate aim is 'patient safety' and our peace of mind. We need to go up the surgical ladder with adequate mentoring and continuing to do more demanding cases as we gain more expertise.





## NDVH for Big Uterus with Previous Multiple C - Section

### Index

- 1) Abstract
- 2) Introduction
- 3) Aims & Objectives
- 4) Material & Methods
- 5) Surgical steps
- 6) Results
- 7) Discussion
- 8) Conclusion
- 9) References

### Abstract :

A unique study was undertaken in an entrepreneur set up in a town with Institutional background of more than 33021 cases of Vaginal hysterectomy in cases without prolapse. The study included cases of multiple/ single large fibroids, previous 1-2 or 3 caesarean section, bulky uterus without descent till 20 weeks size, high risk cases with medical problems or bad abdominal hernia repaired by mesh, nulliparous patients with bulky uterus, case of bad abdominal kochs needing hysterectomy etc.

A new method of aqua dissection was done in all cases with simple significant modification of dissecting & not cutting the vessels in traditional fashion. The purpose of the study was to develop a simple method to do vaginal hysterectomy in difficult cases which can be easily

followed by all gynecologists the amateur & the experienced who wants to master the traditional this Indian traditional heritage to its fullest potential safely.

Out of 33021 vaginal hysterectomy there were only small complications in 0.3% cases with no mortality. The indications varied from multiple large fibroids, adnexal

masses, previous caesarean sections/abdominal surgery, high risk medically & surgically with abdominal mesh repair of hernia, many patients of more than 120 kg. to even 160 kg. in weight etc.

The major importance of this aquadissection technique is that this can be quickly learnt by any gynecologists & could be implemented in clinical practice.

"In today's era advanced costly technologies becomes inevitable in medical research, however finding 'n' avenues in already established surgery is more challenging to a skilled gynecologist. Such research solutions enhance skill, ease & excellence to do surgery for all gynecologist a novice or an expert."

**Dr. Vyomesh Shah**  
Consult Gyne. Patan (Gujarat)



### Introduction

In today's scenario, conscious attempts are being made to reduce the number of abdominal hysterectomies and replace them preferably with vaginal hysterectomy or with laparoscopic assistance as the next choice.

The vaginal approach has always been an art restricted to the gynaecologists only. Vaginal surgery differentiates the gynaecologist from the others. However, there are gynaecologists who do think of vaginal route only when there is uterine prolapse or with some uterine laxity. Is this justifiable? Is this scientific? Is doing vaginal hysterectomy in difficult situation a mental block or true skill limitation ?

Davies et al' reviewed 500 cases of Hysterectomies. 19.2 % of those were vaginal hysterectomies and 76 % done by the abdominal route in the absence of an absolute contraindication to Vaginal Hysterectomy. Common reasons given for not taking vaginal route were absence of prolapse in 76 %, presence of fibroid in 45 % and need for Oophorectomy in 43% dysfunctional uterine bleeding, suspected Adenomyosis and polyps can be clubbed together as the ideal set up for vaginal hysterectomy.

Nulliparity per se should it always contraindicate vaginal hysterectomy ?

Past history of abdominal or pelvic surgery does in itself constitute a contraindication to vaginal hysterectomy ? The commonest pelvic surgery is caesarean section and according to Chapron, currently 20 % or more of deliveries are by caesarean section in most countries.

Cervical Dysplasia; for severe dysplasia, when the decision is to resort to hysterectomy, in the absence of contraindication, vaginal hysterectomy could be the suitable procedure ? This makes gynecologists stand apart from others.

Oophorectomy at vaginal hysterectomy: Oophorectomy is technically possible and can

it be safely performed while doing vaginal hysterectomy without increasing the morbidity?

Medically High Risk cases : The vaginal technique becomes a clear option when the abdominal route and Laparoscopic route may be difficult and/or risky. Previous ventral scar hernia repaired with prolene mesh, repeated skin keloids, pulmonary fibrosis, tuberculous abdomen and hypertensive with diabetes are some of the examples inviting to resort to vaginal route for hysterectomy.

### AIMS AND OBJECTIVES

We evaluated that with the help of our Aqua Dissection Technique the feasibility of doing for Uterus without descent with various pathology, Vaginal Hysterectomy could be made very easy, fast, nearly blood less, economical with good quality of post operative life. Any Gynecologist with moderate surgical experience can confidently do Vaginal Hysterectomy for Non Descent Uterus without complications following standard teaching & meticulously implementing the suggestions given in this research study.

In our study we performed vaginal hysterectomy in uteri without any descent. All patients requiring hysterectomy with benign gynecological disorders of the uterus without descent were taken up for the study, provided the uterus was mobile, its size did not exceed 20 weeks gestational size and there was adequate vaginal access. Morcellation techniques like bisection, debulking by myoma removal after securing uterine arteries, wedge debulking or coring or combinations of these were employed in bigger size uteri.

Hysterectomy is one of the most common gynecological surgery perform all over worldwide. The Vaginal technique has been introduced and performed centuries back, but it has been successfully not done due to lack of confidence, experience among the gynecologist



due to misconception that abdomen Hysterectomy is safer and easier

By our technique at the present study it was concluded that NDVH is associated with less blood loss, faster, easier with best operative life compare to TAH, LAVH, AH with minimal stay in the hospital and faster convalescence.

### NDVH for big uterus with previous LSCS

As name suggest NDVH means normally difficult vaginal hysterectomy or non descent vaginal hysterectomy. Big uterus means size of the uterus is more than 14 to 16 weeks size on which one or multiple scar of LSCS is present.

Usually big uterus is due to

- 1) Severe Adenomyotic huge uterus
- 2) Multiple fibroids
- 3) Single huge fibroid may be intramural, sub serous or sub mucous and broad ligament fibroid.

In case of normal uterus without any LSCS scar very easy to operate as bladder doesn't come in the way

### Technique

- My technique is AQUA DISSECTION - where I am injecting normal saline approximate 200cc all around cervix on uterine wall which creates avascular tourniquet and compresses small vessels so bleeding will be less at the time of incision. Not only that due to AQUA DISSECTION technique we get beautiful plan for dissection which makes the surgery easy, fast and bloodless
- Here we are injecting extra 30cc of normal saline at the juncture of bladder on uterine wall which gives us place to cut and push the bladder away from the incision line and prevents bladder injury
- We use vessel sealer that is ligasure for cutting and cauterize that makes surgery very fast and bloodless

- As uterus is big due to severe Adenomyosis, we core out uterus by cutting or chopping it so gradually uterus shrinks and coming down. We go on coring till we remove uterus by myoma screw. We always remove fallopian tubes as per international study to prevent ovarian cancer, we don't use any special instrument for last pedicle that is tubo ovarian pedicle we cut and cauterize that pedicle or tube by our ligasure small jaw.
- By usage of cautery we minimize bleeding, bloodless and surgery becomes very very easy
- If uterus is having multiple fibroids we go on removing one by one and demass the uterus and facilitates descent of the uterus. Here we use same technique of aqua dissection and ligasure
- If uterus is big due to single fibroid and patient is multipara we remove the big fibroid by using myoma screw and aqua dissection. If patient is having no normal delivery we just go on coring the fibroid to make it smaller and smaller so we can have good descent of remaining part of the uterus.
- In case of previous LSCS as we already told we use extra aqua dissection technique at bladder anchoring on uterine wall and dissect and separate bladder away from area of surgery
- Our study of 33021 vaginal hysterectomy during 2001 to 2019 are as below.

### Material and Methods

All patients requiring hysterectomy for benign gynecological disorders without prolapse were studied from March 2001 to July 2019.

Prerequisites for vaginal route were: uterine size not exceeding 20 weeks of gravid uterus, adequate vaginal access and uterine mobility.



Patients with severely restricted mobility, complex adnexal mass and suspicion of malignancy were excluded, Informed consents were taken

Table 1: Indications and associated conditions for vaginal hysterectomy in patients- 33021 cases

Indications	Associated relevant details
Menorrhagia	
(a) Dysfunctional uterine bleeding & Adenomyosis (14694)	Nullipara(588)
(b) Uterine fibroids (13047)	Previous abdominal surgery (1950)
(c) Cervical polyp/fibroid	Previous vaginal surgery (1044)
Bulky Uterus	High risk (381)
Benign Adnexal pathology(936)	-
Carcinoma in situ of the cervix( 114)	
Endometrial cancer (288)	

### Contraindications:

- Uterus > 20 weeks' size
- Uterine volume > 400 cm<sup>3</sup>
- Restricted uterine mobility
- Diminished vaginal space
- Inaccessible cervix
- Vesicovaginal fistula repair
- Invasive cancer of the cervix
- Although the first four are vital and most commonly sought, the last two are uncommon in day- to-day practice.

### Preoperative investigations tests :

- Blood for complete count
- Blood group and Rh factor
- Creatinine
- Urea
- Sugar - fasting and 2 h after 75g glucose
- HbsAg - Australia antigen
- Hepatitis C antigen
- Human immunodeficiency virus
- Bleeding, clotting and prothrombin time and platelet count
- Urine routine examination

- Chest radiograph
- Ultrasonography
- Endometrial thickness
- CT/MRI in selected cases
- ECG
- Few Thalassaemia particularly in Mediterranean belt
- Rarely G6PD in certain geographical areas and communities
- CA-125 and allied tumour markers if Adnexal mass present
- Two dimensional echocardiography and stress test if necessary
- Pulmonary function tests in few
- Intraoperatively: frozen section histopathology

Our surgical step with new modifications :

### AQUA DISSECTION IN VAGINAL HYSTERECTOMY

#### 1. Material used :

- (a) Fluid-normal saline 150 to 250 ml
- (b) Suture-Polyglactin no. 1 suture material



- (c) For injection of normal saline - 10 cc syringe with 18 gauge needle
- (d) Adrenaline - dose 0.6 ml in 1 liter saline

### 2. Place where saline is injected :

Beneath vaginal mucosa all around cervix 1 cm away from external os, injected in 2 cm area circumferentially till blanching occurs approximately ½ cm deep to mucosa.

### 3. What is the advantage of this step?

Tissue beneath mucosa is flooded with fluid. It compresses vascular structures artery & veins creating vascular tourniquet in injected area.

- a) It creates vascular tourniquet in lower part of uterus - compress small vessels prevents bleeding at the time of surgery - bloodless surgical planes.
- b) Tissue planes are full with fluid which gives proper plane for dissection which becomes very clean, fast, bloodless, easy, artistic.

### How Vaginal Hysterectomy is simplified?

Vascular tamponade, easy tissue planes & safe to bladder.

### Technique in details

Step no. 1 : Aqua dissection as above.

#### Step no. 2 : Opening of peritoneal cavity

- We do not chase & open anterior pouch
- Give a stretch to pull posterior vaginal wall.
- Sharp cut with scissors will open posterior pouch and peritoneal cavity is opened.
- Small incision is made on anterior surface of cervix.
- Join anterior and posterior incision by cutting lateral vaginal wall making circumferential incision.

#### Step no. 3: Bladder mobilization

- Sharp dissection on anterior vaginal wall is made with scissors to cut utero vesical fascia and blunt blade of "vim's speculum"

will draw away the bladder from surgical field.

#### Step no. 4: Managing uterosacral ligament

- properly dissected uterosacral ligament is caught with single simple kocher's clamp-cut and ligated with polyglactin no. 1 suture and suspended on posterior vaginal wall at 5 O'clock and 7 O'clock position to prevent future vault prolapse.

#### Step no. 5: Managing uterine artery

- after securing utero sacral ligament on both side, proper skeletonisation of uterine complex is so artistic that single simple kocher's clamp is sufficient to secure uterine complex confidently
- both side uterine complex secured in same fashion.
- An important modification is routinely done by us wherein the uterine vessels are not cut after clamping, but going closure to the uterus it's shaved off with minimal uterine tissue. Thus even if we release the clamp the uterine arteries will not bleed since vessels are not cut. PN figures in operating technique.

#### Step no. 6: Managing ascending branch of uterine artery

- Once again sharp dissection with scissors will give proper exposure of the pedicle.
- This part also contain some collagen tissue so after separation, support of uterus is decreased which facilitates further easy descent of uterus.

#### Step no. 7: Management of last pedicle which contains

Round ligament, Tube, Uteroovarian ligament & vessels. Again simple single kocher's clamp take care of this pedicle, we



usually secure this pedicle twice as it contains ovarian vessel which is direct branch of aorta which can slip giving rise to profuse bleeding.

### Step no. 8: **Managing vaginal vault**

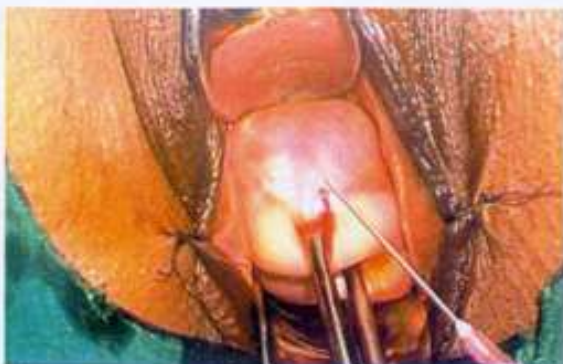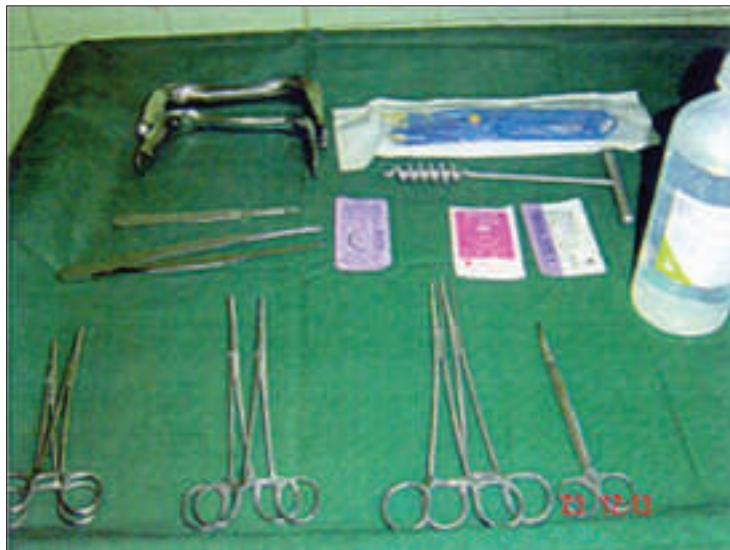One stitch is made at lateral angle of vault from anterior to posterior vaginal wall and tied with utero sacral ligament to give extra support to vault.

Continuous pursestring suture form pos-

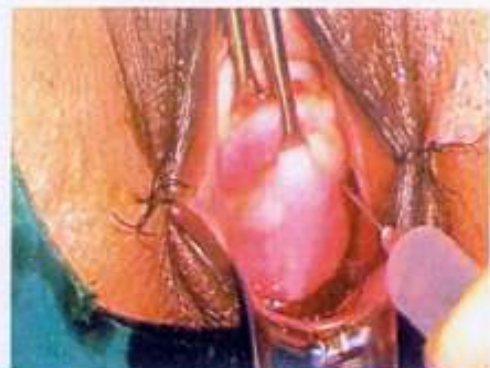terior vaginal wall to anterior vaginal wall is made - at the end middle half of vault is open which allows drainage of blood or fluid from peritoneal cavity.

Step no. 9: **Bladder catheter** is kept for 12 hours till patient walks to toilet on herself. Please read: VH = Vaginal Hysterectomy, Cx = Cervix, NS = Normal Saline, u/s = Utero Sacral Ligament Almost all cases were done under regional anesthesia, either spinal or epidural

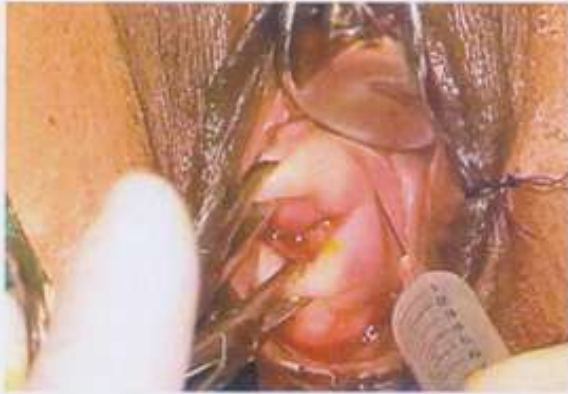### INSTRUMENTS



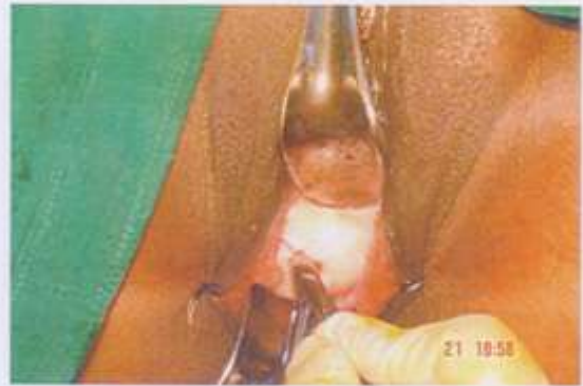Injection of Normal Saline Anteriorly



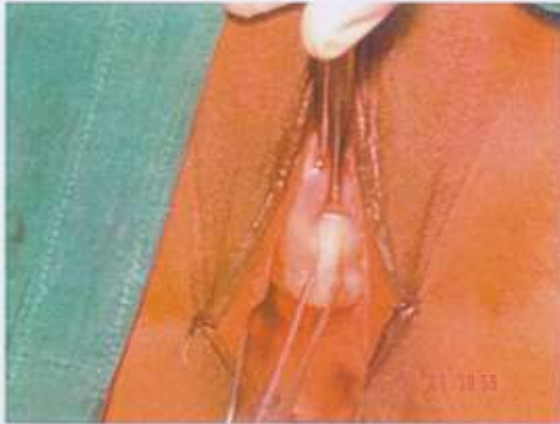Injection of Normal Saline



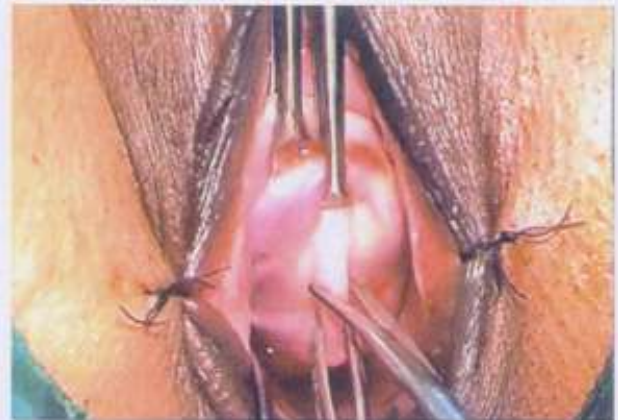
Injection of Normal Saline on laterally



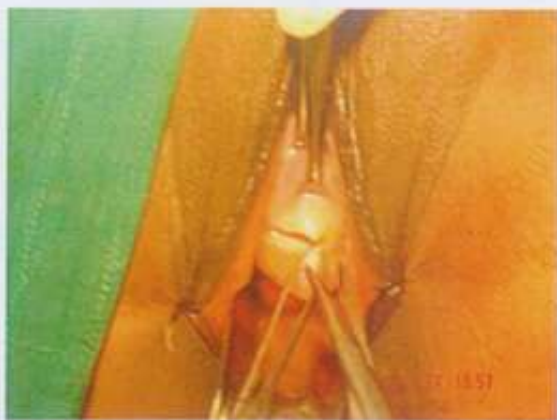Knife incision ~anterior vagina



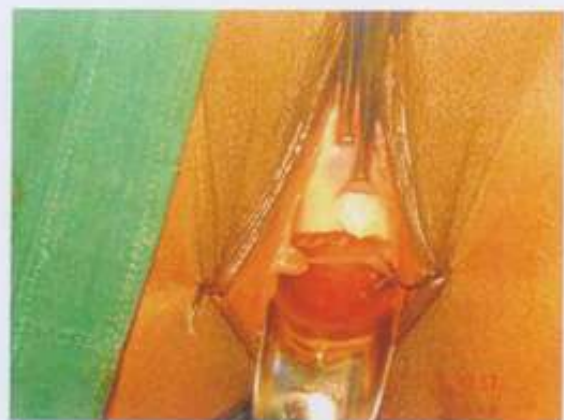Post .vagina made prominent



Vagina stretched Posteriorly

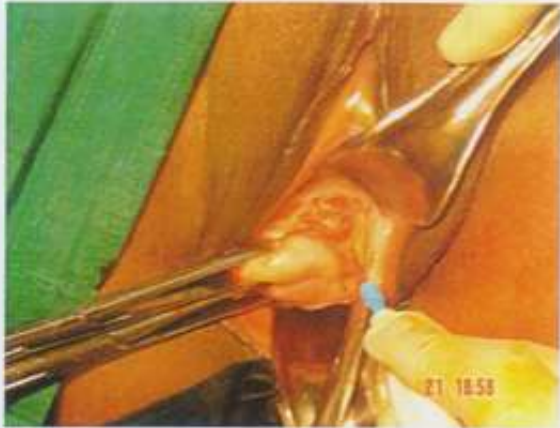

Opening of Pouch of Douglas

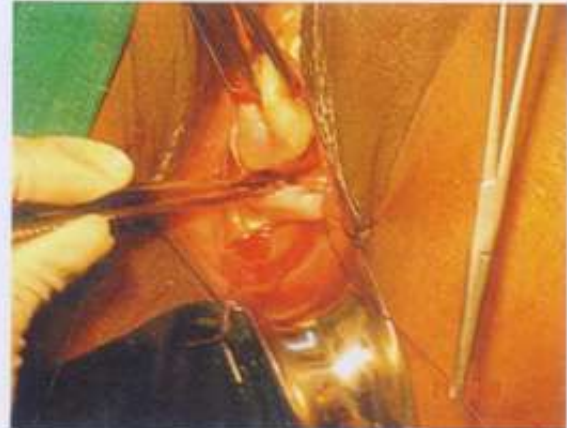

Opened of Pouch of Douglas

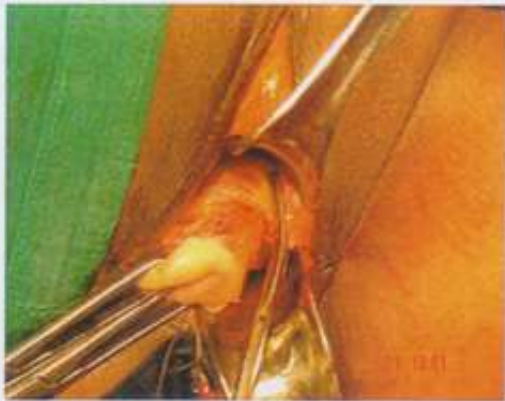



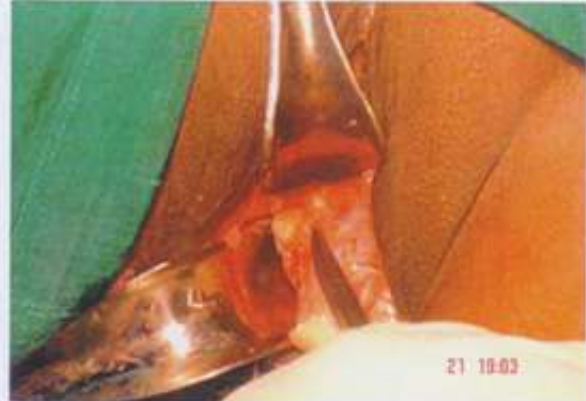Securing left Utero sacral Ligament



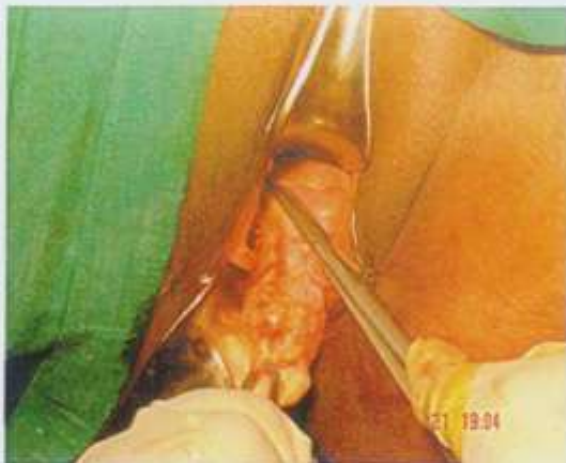Suspension of U/S lig.on post .vaginal wall



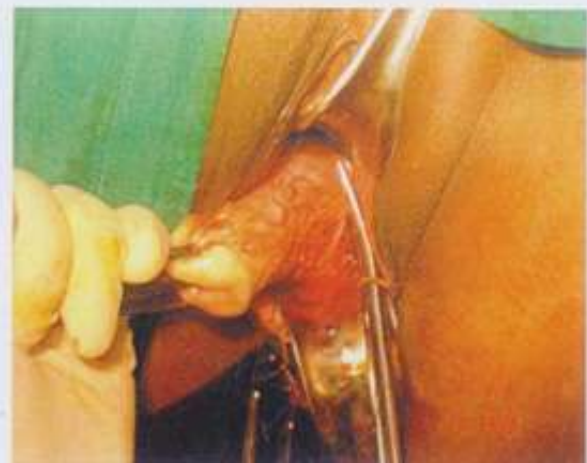Securing left Ut. Vessels with kocher's clamp



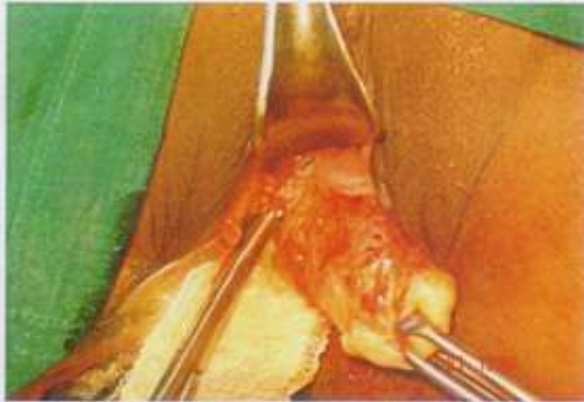
Securing Right Uterine vessels with Kocher's clamp



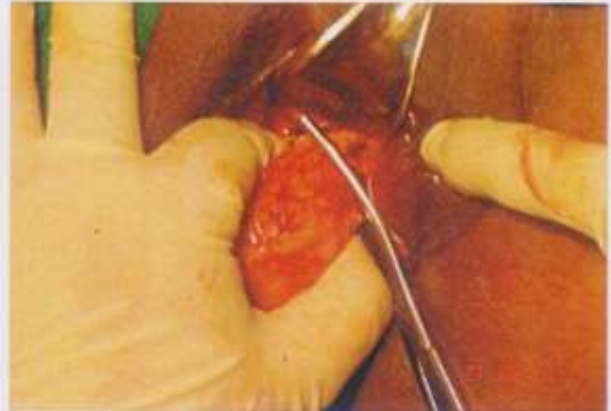
Opening of Anterior Pouch



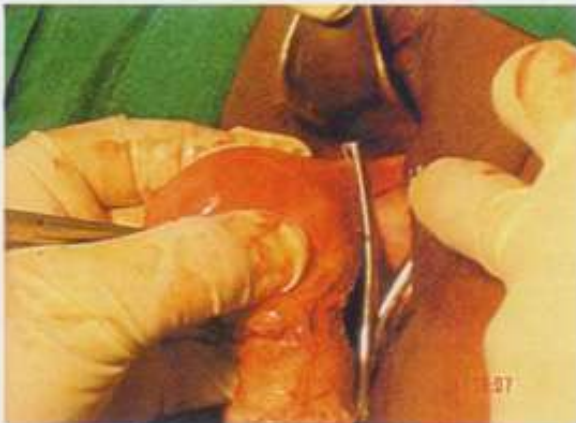Securing of ascending branch of left Ut.Artery



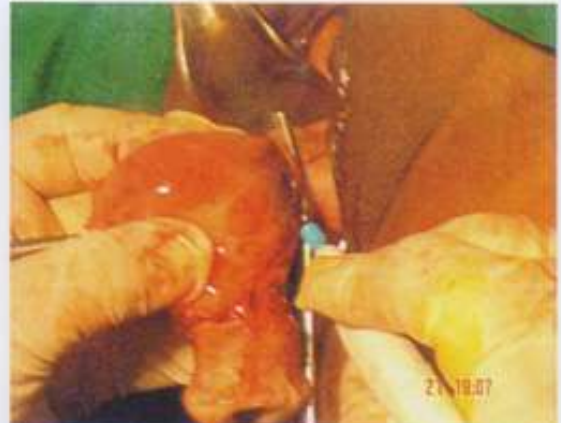Securing of ascending branch of right Ut.Artery



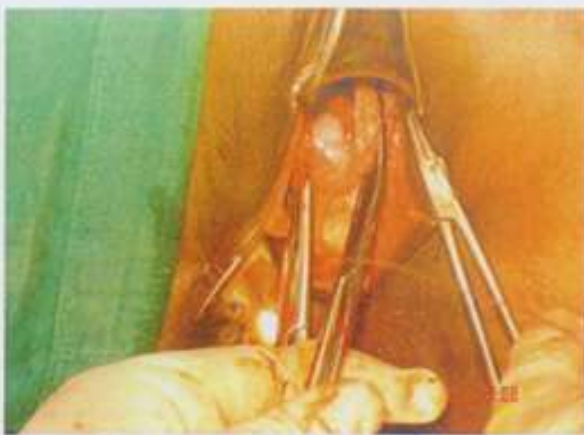Securing left round lig ,ovarian vessels & tube



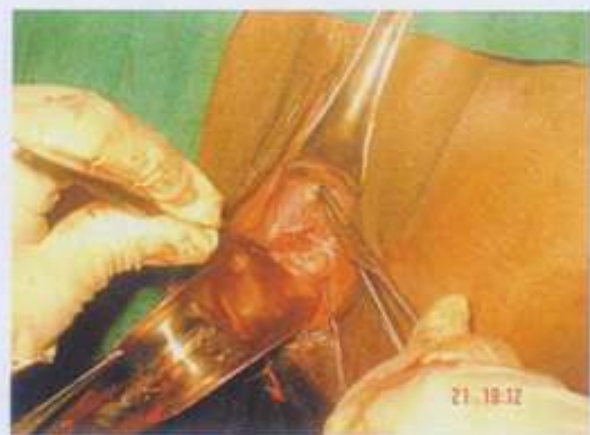Securing other last pedicle



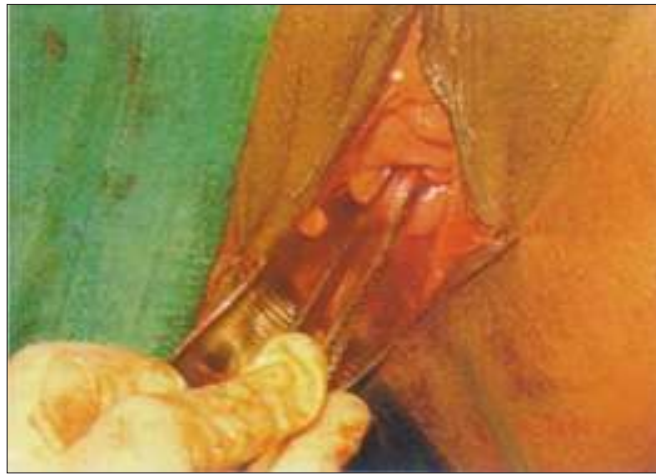Dissection of last pedicle with cautery



Showing last pedicles on both side



Vault closure by inverting margine of the vault

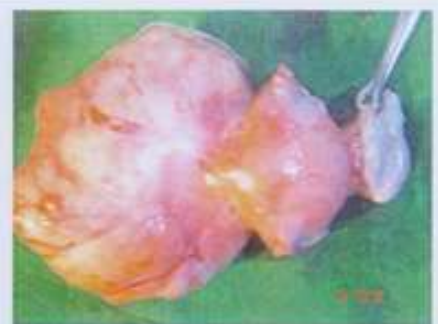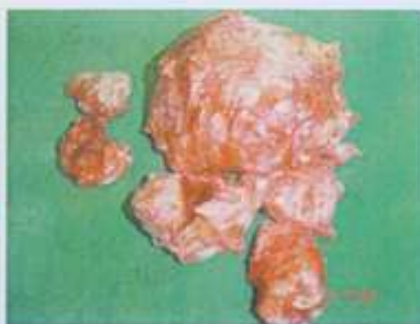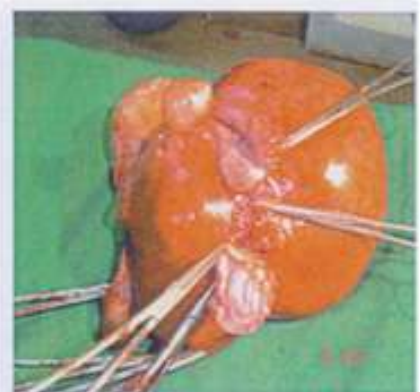
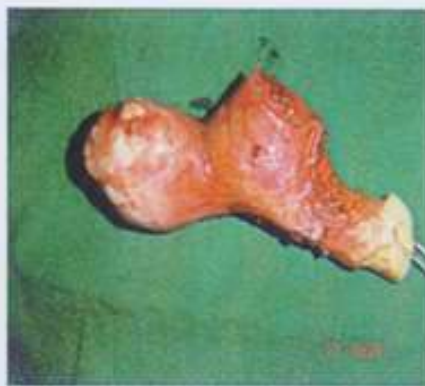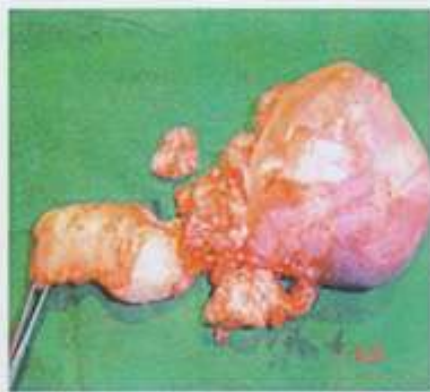


Middle 2/4 of the vault kept open for drainage of collected fluids

PN : This is actual surgery with hardly any blood loss

## **VARIOUS TYPE OF FIBROIDS REMOVED VAGINALLY**

**WITH LARGE UTERUS BY  
"AQUA DISSECTION"**





Result

**Table I.**

**Age and parity**

Age (Years)	No. of Patients	Parity	No. of Patients
35 - 40	(12%)	1	(4%)
41-45	(54%)	2	(24%)
46 - 50	(20%)	3	(46%)
Above 50	(14%)	4 and above	(24%)

**Table II**

**Indications for Vaginal Hysterectomy in 33021 patients :**

	Indications
Dysfunctional uterine bleeding/adenomyosis	14694
Uterine fibroids	13047
Nulliparity severe mental disability (included)	588
Previous abdominal Surgery	1950
Previous vaginal Surgery	360
Cervical polyp/ fibroid	1044
Carcinoma in situ of cervix	114
Endometrial cancer	288
Benign adnexal pathology	936
Total	33021

**Table II. Surgical results**

Parameters

Mean operating time

20 minutes (range 15-35 minutes)

Mean blood loss

20 ml (range 10-30 ml)

Average hospital stay

1 day

**Table III: Vaginal Hysterectomies: Complications**

Bladder injury	09
Rectum	01
Small bowel injury	01
Ureterinjury	Nil



Reactionary haemorrhage	06
Vaginal bleeding	10
Failures	06
Mortality	Nil

**Table IV:**

**Out come of the Study Non Descent Vaginal Hysterectomy with Aqua Dissection Method**

Criteria evaluated	Outcome
Patient's comfort	Excellent
Patient's recovery	Smooth & Fast
Operating time	Very Less
Surgeons Comfort	Most Comfortable
Anaesthetist Comfort	Very good & less Anaesthesia Time
Post Operative Analgesia	Minimal
Intra Operative Bleeding	Average <20 ml
Operative Complication	0.3 %
Cost of the Setup	Very Economical
Cost for Hysterectomy	Rs.10000 - 15000
Conversion to Abdominal Route	6 cases

**Comparison of Vaginal Hysterectomy with AquaDissection & Laparoscopic Hysterectomy**

Particulars	VH with Aqua Dissection	Laparoscopic Hysterectomy
Operative Time	< 30 Min.	>2 hour
Blood Loss	20 - 30 ml	> 300 ml
Hospital Stay	1 day	2-3 days
Recovery Period	Fast painless & Uneventful	Comparitively slow with Pain
Recovery Time	Resume duty in 3-7 days	May require > 10-15 days
Surgeons Comfort	Less operative time, very less bleeding	Much more operating time more bleeding
Anesthetist Comfort	Short anesthesia 20-60 minutes	Long-strainful >2 hour



### Discussion

Though India probably has the best vaginal surgeon on the earth who were our teachers & pioneers of the art of vaginal hysterectomy in even most difficult cases. Surprisingly it is a well-known fact that in many centres 60% to 70% of hysterectomies are performed by abdominal route and vaginal approach is usually used only in uterovaginal prolapse. The unfavorable factors for vaginal hysterectomy identified by many, are absence of significant uterovaginal descent, presence of significant uterine enlargement, previous caesarean section and the need for oophorectomy

With adequate vaginal access, technical skill, and good uterine mobility, vaginal hysterectomy can easily be achieved. The main supports of the uterus, the uterosacral and cardinal ligaments, situated in close proximity to the vaginal vault can be easily divided to produce descent. Multiparity, lax tissues due to poor involution following multiple deliveries and lesser tissue tensile strength gives a lot of comfort to vaginal surgeon even in the presence of significant uterine enlargement.

The second most important reason for the lower proportion of hysterectomies performed vaginally is the presence of uterine enlargement with leiomyomas', one of the most common indications. However, now big and bulky uteri can be dealt with by techniques like bisection, debulking myoma or morcellation. In our study, we could remove uteri of up to 20 weeks pregnancy size vaginally without any increase in surgical complications, blood loss, operative time or hospital stay. Similar findings are reported, operated upon uteri weighing 200 to 1700 gm, without any increase in complications as compared to Laparoscopic or abdominal hysterectomies. Complications in our study were minor and few. We consider vaginal hysterectomy safe upto 20 weeks size. Das and

Seth<sup>10,11</sup> use ultrasonographic calculation of uterine volume for assessing the feasibility of vaginal hysterectomy. They needed debulking for uteri with a volume of more than 300cm.

Vaginal hysterectomy in women with non-descent and moderately enlarged uteri is safe<sup>12,13</sup>. A combination of morcellation techniques is often needed and the surgeon needs to be familiar with them. With experience, operative time, blood loss and complications can be reduced. This technique should be practiced more frequently and there should be an active effort in residency training programmes to teach this.

With increasing concern over the containment of health care costs<sup>14</sup>, there is a need for expanding the indications for performing hysterectomies via the vaginal route rather than laparoscopic method, instead of confining it to uterine descent. Usual limitation of vaginal hysterectomy in non-descent uterus is its size but now with larger sizes, hysterectomy can be facilitated by bisection, myomectomy, wedge debulking and intramyometrial coring (morcellation)

Keeping in view that this approach could substantially decrease cost, duration of hospital stay and morbidity we decided to study vaginal hysterectomies in women with benign gynecological disorders, other than prolapse. Our aim was to find characteristics / indications other than prolapse, which make women suitable for vaginal hysterectomy and to explore different surgical techniques that make vaginal hysterectomy simpler and easier to perform.

### Conclusion

Most of the gynecologists are keen to do removal of uterus vaginally & a significant number are glamorized by Laparoscopic route", which has not convincingly reduced operating time, cost & most important patient's safety.



We chose the path which was lonely but now the whole world is joining, a difficult study was undertaken of more than 11000 removal of uterus without any descent with various pathologies over a decade. The conclusions were rewarding, useful to all gynecologists & most important affordable to all patients in towns, villages & even metros. With the help of aqua dissection & other innovative modification of specially securing uterine vessels Vaginal Hysterectomy for non descent uterus with various pathology is very simple, nearly bloodless, very fast with excellent quality of post operative life. With this technique an average gynecologist with average surgical skill can do vaginal hysterectomy for more than 95 % of the cases.

### Most important take home message of the study

1. By injecting normal saline in good quantity (150-250 cc), tissue is adequately infiltrated which provides bloodless field for dissection and works as a vascular tourniquet making surgery easy
2. Uterine vessels is not cut but it is dissected out close to uterus so least bleeding occurs even though opposite uterine artery intact.
3. Don't chase to open anterior pouch it will come on it's own.
4. Clamps remain flush to uterus & good retraction so no chances of damaging ureter.
5. In case of previous caesarean section, we inject 10 cc normal saline at anchoring area of bladder and by sharp dissection we push the bladder without any damage, this is usually a band of adhesion.
6. We are not closing vault completely but keeping middle portion open for drainage of blood, fluid etc to prevent post operative infection & pyrexia.
7. Both uterosacrals ligaments are suspended on posterior vaginal wall to prevent future vault prolapse.
8. We are not suspending ovary anywhere on the vault so there is no dragging pain or dyspareunia post operatively.

It is truly said that anatomical knowledge comes from cutting tissues apart but surgical wisdom comes from putting together. Don't let your mental inhibition prevent you to undertake apparently difficult vaginal surgery which you are actually capable of doing easily.

### References :

- 1) Davies A, Wizza E, Bournas N et al. How to increase the proportion of hysterectomies performed vaginally. *Am J Obstet Gynecol* 1998;179:1008-12.
- 2) Chapron C, Dubuisson J B Total hysterectomy by laparoscopy Advantage for the patient or only a surgical gimmick?
- 3) Kumar S, Antony ZK. Vaginal hysterectomy for benign nonprolapsed uterus - initial experience. *J Obstet Gynecol Ind* 2004;54:60-3.
- 4) Mazdisnian F, Kurzel RB, Coe S et al. Vaginal hysterectomy by uterine morcellation : efficient, nonmorbid procedure. *Obstet Gynecol* 1995;86:60-4.
- 5) Lash AF A method for reducing the size of uterus in vaginal hysterectomy *Am J Obstet Gynecol* 1941, 42 452-96.
- 6) Sheth S S, Malpani A Routine prophylactic oophorectomy at the time of vaginal hysterectomy in postmenopausal women *Arch Gynecol Obstet* 1992; 251:87-91.
- 7) Sheth SS The place of oophorectomy at vaginal hysterectomy *Br J Ohstet Gynecol* 1991.98 662-666
- 8) Davies A. O'Connor H, Magos AL A prospective study to evaluate oophorectomy at the time of vaginal hysterectomy



- Br J Obstet Gynecol 1996, 103 915-920
- 9) Sheth SS Uterine fibroids. In Sheth SS. Studd JWW. eds Vaginal Hysterectomy London Martin Dumt: Ltd. 2002, pp 79-84 Gynecologic surgery 1996, 1275-88
  - 10) Das S, Sheth S. Uterine volume: an aid to determine the route and technique of hysterectomy. J Obstet Gynecol Ind 2004;54:68-72.
  - 11) Sheth SS Preoperative sonographic estimation of uterine volume an aid to determine the route of hysterectomy J Gynecol Surgery 2002, 18 13-22 4.
  - 12) Sheth SS Vaginal or abdominal hysterectomy? In Sheth SS. Sutton C, eds Menorrhagia Oxford Isis Medical Medici, 1999.213-37
  - 13) Navratil E The place of vaginal hysterectomy J Ohstet Gynaecol Br Commonwith 1965, 72 841- 846
  - 14) Van Den Eeden, Glasser M, Mathais SD et al Quality of life health care utilization and costs among women undergoing hysterectomy in a managed care setting Am J Obstet Gynecol 1998, 17891-110

