

A Study of Interparietal Bone in 105 Human Skulls of Gujarat Population

Mayuri P. Shah*, Sarzoo G. Desai**, Sunita Gupta***

Abstract

Introduction : The squamous portion of the occipital bone consists of two different parts: the upper interparietal and the lower supraoccipital. The interparietal part may remain separated from the supraoccipital by a suture; it is then called the interparietal or Inca bone. **Aim :** In this study, incidence of interparietal bone has been estimated and compared with the other observations. **Methodology :** Total 105 cadaveric dry human skulls were examined to determine incidence of interparietal bone. **Observations :** The skulls which were observed, displayed many variations in the occipital region. In 7 cases, single or multiple separated bones were observed. In 4 cases (3.81%), the lower edge of these additional bones was situated above the external occipital protuberance and such bones could be classified as interparietal bones. In 3 cases (2.86%), the lower edge of these additional bones was much higher (between the lambda region and the highest nuchal line). The later can be classified as preinterparietal. **Importance :** Knowledge of interparietal bone is important for the radiologists, neurosurgeons, anthropologists, orthopedics and forensic experts to avoid misdiagnosis.

Key Words : Interparietal bone, Inca bone, Preinterparietal bone, squamous occipital bone.

Introduction :

The squamous part of occipital bone consists of two parts, supraoccipital and interparietal. The interparietal part may remain separated from the supraoccipital by a suture; it is then called the interparietal or Inca bone. Saint-Hilaire⁽¹⁾ first described it as the nonwormian epactal or interparietal bone. Tschudi⁽²⁾ labeled this bone as bone Inca. The squamous part of the occipital bone above the highest nuchal lines is developed in a fibrous membrane and it is ossified from two centres. Below the highest nuchal lines, the squamous part is pre-formed in the cartilage and it ossifies from two centres⁽³⁾. There is a controversy regarding the ossification of these two parts. Ranke⁽⁴⁾ described the interparietal part as developing from three pairs of ossification centres and the occasional appearance of an additional fourth pair at the upper angle of the interparietal part. The occurrence of these bones is very rare and is considered as variants. These unusual bones may confuse the radiologists and clinicians as fractures in the skull. They may end up in complications during neurosurgical interventions like burr-hole surgeries and their extensions may lead to continuation of fracture lines⁽⁵⁾. These may be used as identification features by the forensic experts while investigating the medicolegal cases for age and sex determination.⁽⁶⁾ Matsumra et al⁽⁷⁾ described the presence of the preinterparietal bones and stated that these bones developed from additional ossification centres and that they could be clearly differentiated from other anomalies (sutural bones) in the lambda region by the shape of their territory and by their location.

Differentiation of preinterparietal bone from sutural bone and from other variations in the interparietal region is important because of increase use of these bones in classification of nonmetric cranial variants for separation of populations.⁽⁸⁾

In this study, the incidence of the interparietal bone has been estimated and compared with the previous observations.

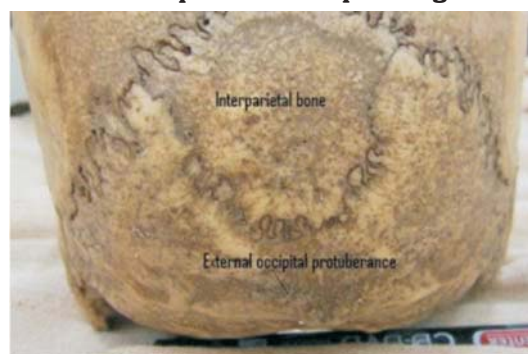
Methodology

Total 105 dry human skulls of unknown age and sex were examined from different medical and dental colleges of Gujarat. All the skulls were observed thoroughly for the presence of interparietal bone. The data was tabulated and analyzed.

Observations :

In present study out of 105 skull studied, 60 skulls from B.J. Medical College; 38 skulls from Government Dental College and 7 skulls from AMC MET Medical College, Ahmedabad were examined for the presence of interparietal bone. The interparietal bone was observed only in 4 skulls (3.81%). Out of 4 cases, in one case there was a single large ovoid shaped bone behind the lambda in between the two lambdoid sutures (fig.1). The suture separating the interparietal bone from the rest of the squamous occipital was seen to be 2.2 cm above the external occipital protuberance and 5.4 cm posteroinferior to the lambda (fig. 1). In remaining skulls, interparietal bones were of varying size and shape. The preinterparietal bone was found in 3 skulls (2.86%). Out of 3 cases, in one case the two small irregular sized preinterparietal bones were present posterior to the lambda and anterior to two Inca bones (fig.2).

Figure 1: The skull showing interparietal (Inca) bone in squamous occipital region.



* Associate Professor

** Assistant Professor

*** Professor and Head

Department of Anatomy, AMC MET Medical College, Ahmedabad

Correspondence : drdesaig@rediffmail.com

Figure 2 :The skull showing interparietal bone (1) with wormian bone bilaterally(2).



Figure 3: The skull showing two irregular shaped preinterparietal ossicles (2) with two interparietal (Inca) bones (1).



Figure 4: A single large interparietal bone (1) with preinterparietal bone (2) and on right side a wormian bone seen.



Discussion

The interparietal portion of the squamous occipital bone may remain partially separated from the supra-occipital portion by a suture and that separate bone is called as the interparietal or Inca bone. Sometimes, the additional centres occurring in front of the interparietal bone may fail to fuse and are called preinterparietal bones⁽⁹⁾.

The incidence of the interparietal bones varies among different populations. For example, it is 15% in Nigerians (both the interparietal and preinterparietal bones), 1.2% in Europeans, 0.8% in Australians, 4.8% in Northern Americans, 2.4% in Indians (both the interparietal and preinterparietal bones).⁽¹⁰⁻¹¹⁾ The ossification of the interparietal bone and the morphology of the preinterparietal bone have been reported earlier by Pal, Tamanker, Routal et al.⁽⁸⁾ They reported a case of single upper central piece (preinterparietal) and Pal⁽¹²⁾ also reported the presence of 2 preinterparietal in a skull from the collection in the Mutter Museum, Philadelphia. The interparietal may exist as a single bone, two symmetrical halves or in three pieces or even four, in which case the upper two constitute the preinterparietal.⁽¹³⁾

Srivastava⁽¹⁴⁾ in a study of 620 skulls found the complete separate interparietal bone in 3 skulls with an incidence of 0.8%. He found that the suture between the interparietal and supraoccipital parts lies 2 cm above the external occipital protuberance and 0.4 cm above the superior nuchal line near the lambdoid suture. Saxena et al⁽⁹⁾ reported the occurrence of a single interparietal bone in only one skull with an incidence of 2.5%. In contrast, the incidence of Inca bone was 1.6% observed by Singh et al.⁽¹⁰⁾ Marathe et al⁽⁵⁾ reported 1.3% incidence of Inca bones. A very high incidence (27.71%) of Inca bones were observed in Hispanic skulls between 300-1200 AC. Yucel et al⁽¹⁵⁾ in a study of 544 skulls, found the incidence of interparietal bones in 2.8% of the cases. However, complete separate interparietal bone was not found in any of the skulls. In the present study, out of 105 skulls observed the presence of Inca bone was found to be in 4 skulls (3.81%). In 2 skulls complete separate interparietal bone was present in our study. As compared to relevant studies incidence rate of interparietal bone was higher in present study (Table-1).

Srivastava⁽¹⁴⁾ had been also observed presence of preinterparietal bone in 2.99% of cases. Saxena et al⁽⁹⁾ found the incidence of preinterparietal bones in 2.5% of the cases in their study. Singh et al⁽¹⁰⁾ in study of 500 skulls observed 0.8% presence of preinterparietal bone. Gopinathan⁽¹⁶⁾ had been reported the presence of as many as 5 ossicles in the preinterparietal part of the squamous occipital bone with 0.8% incidence. In our study we observed 1 to 3 ossicles in the preinterparietal part of squamous occipital in 3 skulls (2.86%). Present incidence rate of preinterparietal bone was almost similar to other studies (Table-2).

Table 1: Comparison of incidence of interparietal bone among various studies

Author	Number	Percentage
Srivastava(14) (1977)	620	0.8
Singh et al (11)(1979)	500	1.6
Saxena et al(10)(1986)	40	2.5
Yucel et al(15)(1998)	540	2.8
Marathe et al(5)(2010)	380	1.3
Present study(2013)	105	3.81

Table 2: Comparison of incidence of preinterparietal bone among various studies

Author	Number	Percentage
Shrivastava(14)(1977)	620	2.99
Singh et al (11)(1979)	500	0.8
Saxena et al(10)(1986)	40	2.5
Gopinathan(16)(1992)	125	0.8
Present study(2013)	105	2.86

Conclusion

The present study observed the higher incidence of interparietal bone (3.81%) than the preinterparietal bone (2.86%). This study also gives idea about squamous occipital bone, presence of preinterparietal and interparietal bones and about their incidence. The interparietal bones may give a false appearance of fracture on radiographs. Such bones may lead to complications during burr-hole surgeries and their extensions may lead to continuation of fracture lines. So, Knowledge of interparietal bones in human skulls may be useful to neurosurgeons, orthopedic surgeons, anthropologists, forensic experts and radiologists.

References :

1. Saint-Hilaire. GE Reports and Considerations of Novaux Comparative osteology regarding Animals. Mem Paris Museum of Natural History, 1823; 10: 165.
2. Tschudi, J. J. Uber Die Ureinwohner Von Peru. Arch. Anat. Physiol. Wiss Med., 1844; 98-109.
3. Newell RLM. The back. In: Gray's Anatomy. 40th edition, Churchill Livingstone, Elsevier; 2008; 711.
4. Ranke J. Uber dasinterparietale und die Verknocherung des Schadelhdachs beim Affen 1913 Cited in: Quain's Elements of Anatomy, vol. IV, 11th edition, part 1, Longman Green: London, 1915; 53-55.
5. Marathe, RR, Yogesh, AS., Pandit, SV, Joshi, M. and Trivedi, GN. Inca interparietal bones in Neurocranium of human skulls in central India. J. of Neurosciences in Rural Practice. 2010, vol. 1, no.1, p. 14-16.
6. Purkait, R. and Chandra, H .The identity of Inca, medicolegal importance and suggested nomenclature of variants. J of Anat Society of India, 1989, vol. 38, n. 3, p. 162-171.
7. Matsumura G, Uchiumi T, Kida K, Ichikawa R, Kodama G. Developmental studies on the interparietal part of the human occipital squama. J Anat 1993; 182, 197-204.

8. Pal G P, Tamanker B P., Routal R V and Bhagwat S S. The ossification of membranous part of the squamous occipital bone in man. J. of Anat, 1984, vol. 138, n. 2, p. 259-266.
9. Frazer, JE. Anatomy of the Human Skeleton. 6th edition, London: J & A Churchill Ltd, 1965. p. 187-190.
10. Saxena S K, Chowdhary D S, & Jain S P. Interparietal bones in Nigerian Skulls. J. of Anat, 144: 235-7, 1986.
11. Singh P J, Gupta C D, & Arora A K. Incidence of interparietal bones in adult skulls of Agra region. Anat. Anz., 145: 528-31, 1979.
12. Pal G P. Variations of the interparietal bone in man. J. of Anatomy, 1987, vol. 152, p. 205-208.
13. Brash, JC. Cunningham's text book of anatomy. 9th ed. London: Oxford University Press, 1951. p. 220.
14. Srivastava HC. Development of ossification centres in the squamous portion of the occipital bone in man. J Anat. 1977; 124: 634 639.
15. Yucel F, Egilmez H, Akgun Z. A study of the interparietal bone in man. Turk J Med Sci. 1998; 28: 505 509.
16. Gopinathan, K. A rare anomaly of 5 ossicles in the preinterparietal part of the squamous occipital bone in north Indians. J of Anat, 1992, vol. 180, n. 1, p. 201-202.