

Intestinal Malrotation in Children: A Problem-solving Approach to the Upper Gastrointestinal Series¹

Kimberly E. Applegate, MD, MS • James M. Anderson, MD • Eugene C. Klatte, MD

TEACHING POINTS

See last page

Intestinal malrotation, which is defined by a congenital abnormal position of the duodenojejunal junction, may lead to midgut volvulus, a potentially life-threatening complication. An evaluation for malrotation is part of every upper gastrointestinal (GI) tract examination in pediatric patients, particularly neonates and infants. Although the diagnosis of malrotation is often straightforward, the imaging features in approximately 15% of upper GI tract examinations are equivocal and lead to a false-positive or false-negative interpretation. The clinical manifestations and upper GI tract findings of malrotation in older children and adults are less specific than are those in younger patients, and for this reason diagnosis of the condition may be more difficult. Successful differentiation between a normal variant and malrotation requires the use of optimal techniques in acquiring and interpreting the upper GI series. Familiarity with the upper GI series appearance of both normal and abnormal anatomic variants allows the radiologist to increase both diagnostic accuracy and confidence in the diagnosis of malrotation.

©RSNA, 2006

Abbreviation: GI = gastrointestinal

RadioGraphics 2006; 26:1485–1500 • Published online 10.1148/rg.265055167 • Content Codes: **GI** **PD**

¹From the Department of Radiology, Riley Hospital for Children, 702 Barnhill Dr, Room 1053B, Indianapolis, IN 46202. Presented as an education exhibit at the 2003 RSNA Annual Meeting. Received August 30, 2005; revision requested November 10 and received December 21; accepted April 4, 2006. All authors have no financial relationships to disclose. Address correspondence to K.E.A. (e-mail: kiappleg@iupui.edu).

©RSNA, 2006

Introduction

Intestinal malrotation, which is defined by a congenital abnormal position of the bowel within the peritoneal cavity, may lead to midgut volvulus, a potentially life-threatening condition. For this reason, an evaluation for malrotation should be part of every upper gastrointestinal (GI) tract examination in pediatric patients, particularly neonates and infants. The upper GI series can help the radiologist distinguish a normal position of the bowel from malrotation by depicting the position of the duodenojejunal junction. Successful differentiation of a normal variant in bowel location from malrotation, both in pediatric patients and in adults, requires the use of optimal techniques for acquiring and interpreting upper GI series.

In this article, the embryologic development and epidemiologic characteristics of malrotation are described, and the clinical symptoms and radiographic features of malrotation and resultant volvulus are compared with those of anatomic variants that are considered normal. To help maximize diagnostic accuracy and the radiologist's confidence in diagnosis, techniques for optimal image acquisition and interpretation are outlined and potential pitfalls are highlighted.

Definition of Malrotation

Malrotation is a congenital abnormal position of the bowel within the peritoneal cavity and usually involves both the small and the large bowel. Malrotation is accompanied by abnormal bowel fixation by mesenteric bands or absence of fixation of portions of the bowel, leading to increased risks of bowel obstruction, acute or chronic volvulus, and bowel necrosis. The term *malrotation* applies to a wide range of intestinal anomalies, from a readily apparent omphalocele in newborns to asymptomatic nonrotation of the large and small bowel in adults. Most people who are affected by malrotation show signs of the condition soon after birth; however, malrotation in an important minority is diagnosed long after infancy and is not manifested by the typical clinical sign of bilious vomiting (1–6).

In nonrotation, a subtype of malrotation associated with a lower risk of volvulus, the small bowel is located predominantly on the right side within the peritoneal cavity and the colon is located on the left side (7) (Fig 1). Various degrees of malrotation of the small or large bowel may occur, and the positions of the duodenojejunal junction (and, by implication, the ligament of Treitz) and colon depend on the developmental stage at which normal embryologic rotation

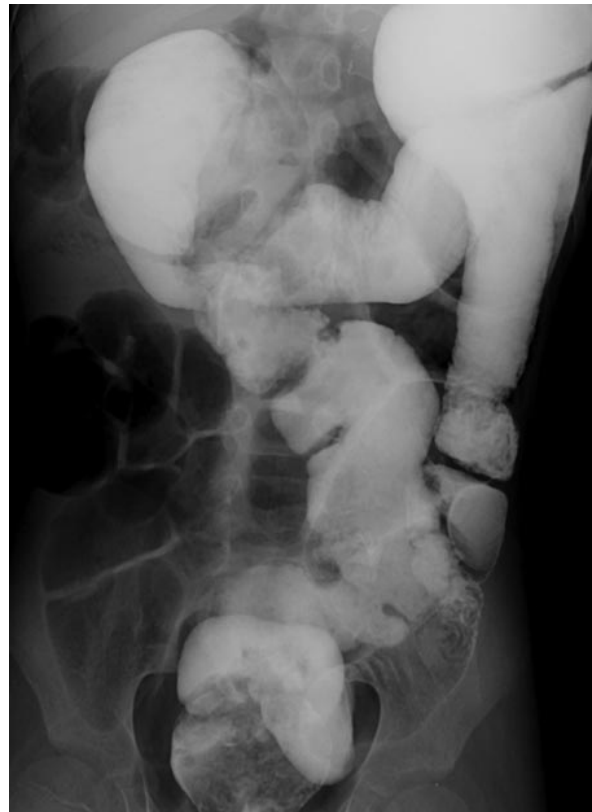

Figure 1. Nonrotation of the bowel. Radiograph shows the presence of iodinated contrast material from an abdominal computed tomographic (CT) examination 1 day earlier. The colon is located primarily in the left side of the abdomen, and the small bowel is in the right side.

failed. Because the second and third stages of rotation differ for the small versus the large bowel, the rotation of one may be normal while that of the other is abnormal.

Embryologic Origins

The gut develops from the yolk sac, which divides into three sections early in development: the foregut, which is supplied by the celiac artery; the midgut, which extends from the middle third of the duodenum to the distal transverse colon and which is supplied by the superior mesenteric artery; and the hindgut, which is supplied by the inferior mesenteric artery.

Early in embryonic life, before approximately 4 weeks of gestation, the gut is a short, straight, featureless tube. By 12 weeks, it has grown rapidly and, after a series of complex steps involving a total rotation of 270°, has undergone fixation in the normal position in the abdomen (8,9). At approximately 4 weeks the primitive intra-abdominal organs begin to grow, and by 6 weeks there is little room for all the organs. First, the duodenum rotates 90° counterclockwise to a position at the right of the superior mesenteric artery, while the colon rotates 90° to a location at the left of the

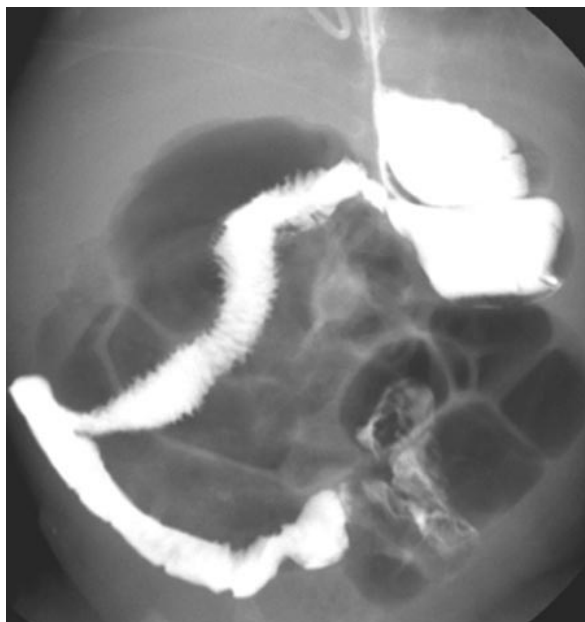

Figure 2. Radiograph obtained with barium in the upper GI tract of an infant with previously repaired gastroschisis and obligatory malrotation shows a markedly abnormal course of the duodenum and jejunum in the right abdomen.

Table 1
Syndromes Associated with Malrotation

Apple-peel intestinal atresia
Cornelia de Lange syndrome
Cantrell syndrome
Cat-eye syndrome
Chromosomal abnormalities (trisomies 13, 18, and 21)
Coffin-Siris syndrome
Familial intestinal malrotation
Heterotaxy (asplenia, polysplenia)
Marfan syndrome
Meckel syndrome
Mobile cecum syndrome
Prune-belly syndrome

Source.—Reference 19.

superior mesenteric artery. The midgut then herniates into the umbilical cord to continue its growth. During this time, the duodenum rotates counterclockwise another 90°, while the colon undergoes no rotation. At 10 weeks, the embryonic bowel returns to the abdominal cavity, and both the duodenum and the colon rotate again. At this time, the duodenum completes its final 90° counterclockwise rotation, until the duodenojejunal junction is located to the left of the spine, while the colon rotates counterclockwise 180°, until the cecum is located in the right lower quadrant of the abdomen. The completed normal

Table 2
Anatomic Anomalies Associated with Malrotation

Absence of kidney and ureter
Biliary atresia
Congenital diaphragmatic hernia
Duodenal or small-bowel stenosis or atresia
Duodenal web
Gastroschisis
Hirschsprung disease
Imperforate anus
Intestinal pseudo-obstruction
Intussusception
Malabsorption
Meckel diverticulum
Omphalocele
Pyloric stenosis

Source.—Reference 7.

rotation of the bowel produces a long mesenteric attachment for the small bowel (10).

Epidemiologic Description

Malrotation occurs in approximately 1 in 500 births (11). **Malrotation is usually diagnosed in newborns and young infants; up to 75% of symptomatic cases occur in newborns, and up to 90% of symptomatic cases occur within the 1st year of life (1,11–13).** The classic clinical manifestation of malrotation in newborns is bilious vomiting with or without abdominal distention associated with either duodenal obstructive bands or midgut volvulus (1,7,14). A delay in diagnosis and treatment may result in small-bowel necrosis, short-gut syndrome, and dependence on total parenteral nutrition. Mortality in affected newborns was approximately 30% in the 1950s and 1960s (15,16) but since then has markedly decreased, to 3%–5% (14,17,18).

Malrotation of the bowel is associated with a number of syndromes (Table 1) and other anomalies (Table 2). Fairly often, it occurs in association with other gastrointestinal abnormalities, especially jejunal and duodenal stenosis or atresia, annular pancreas, Hirschsprung disease (congenital megacolon), and intussusception (Table 2). Malrotation of the bowel is invariably present in children with an omphalocele, gastroschisis (Fig 2), or congenital diaphragmatic hernia (Bochdalek), in whom the normal embryologic positioning of the developing gut was disrupted. Malrotation is very common in children with heterotaxy syndrome (20,21) (Fig 3).



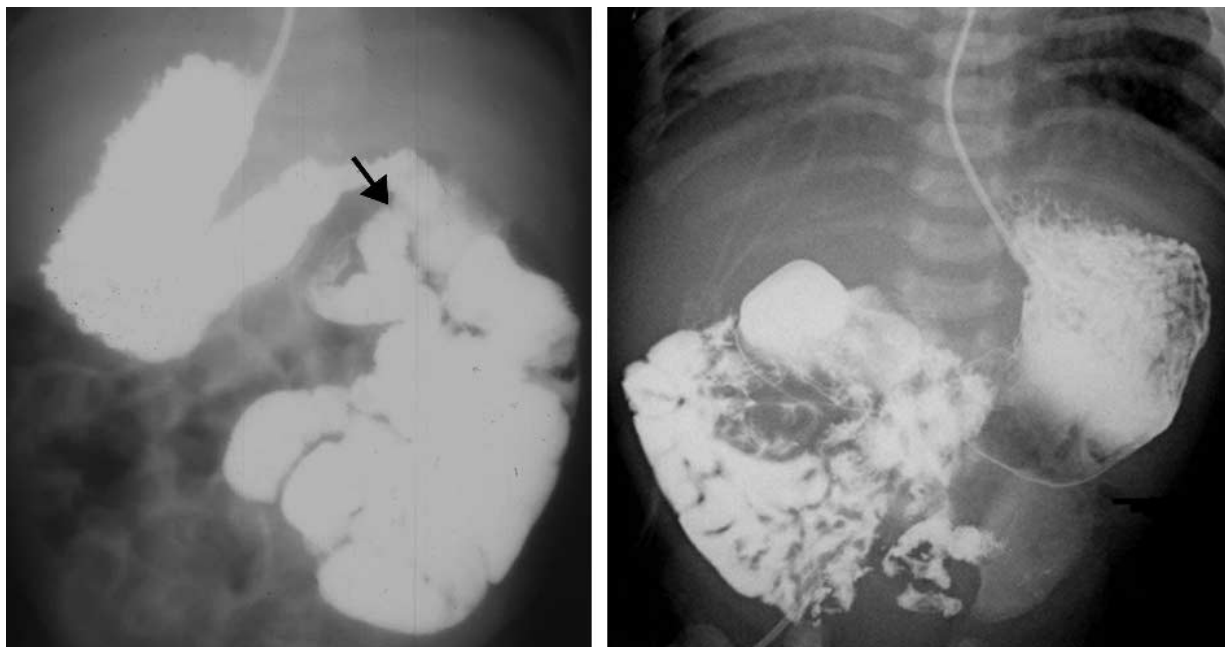


Figure 3. Malrotation in two infants with heterotaxy syndrome. **(a)** Radiograph from an upper GI series obtained with barium administered via a nasogastric tube shows a right-sided stomach, left-sided small bowel, and abnormal position of the duodenojejunal junction (arrow). **(b)** Radiograph in another infant shows a right-sided heart, left-sided barium-filled stomach, and right-sided barium-filled small bowel. The duodenojejunal junction (not shown) also was abnormally positioned.

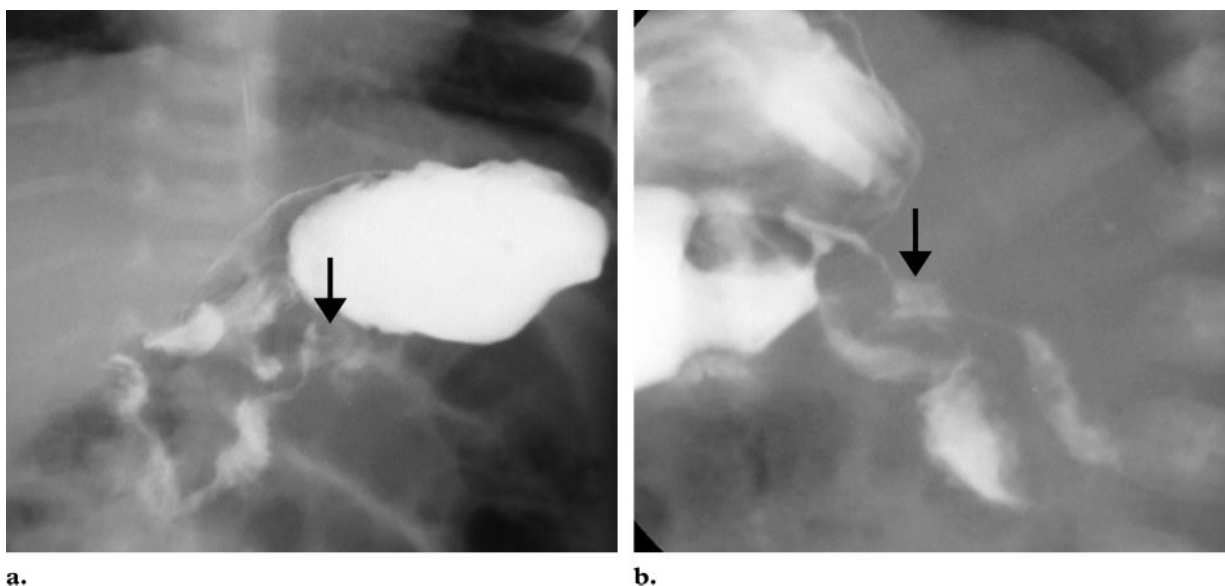


Figure 4. Normal upper GI series in an infant with vomiting. **(a)** Frontal view shows the duodenojejunal junction (arrow) to the left of a vertebral body pedicle and at the level of the pylorus. The duodenal bulb is not visible. **(b)** Lateral view shows a normal posterior position of the duodenum and location of the duodenojejunal junction (arrow) at the inferior aspect of the duodenal bulb (arrow).

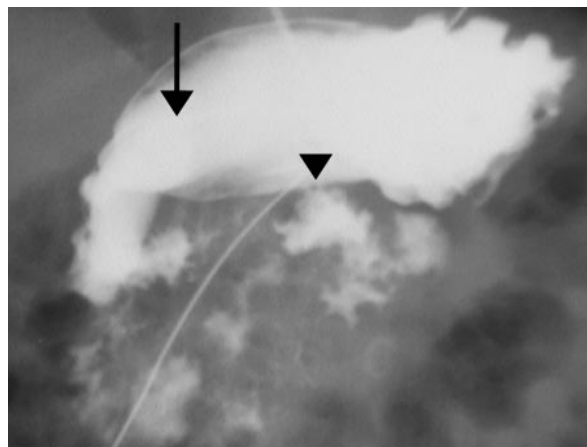
Volvulus Due to Malrotation

In individuals with malrotation, the mesenteric attachment of the midgut, particularly the portion from the duodenojejunal junction to the cecum, is abnormally short. The gut is therefore prone to twist counterclockwise around the superior mesenteric artery and vein. This condition, known as

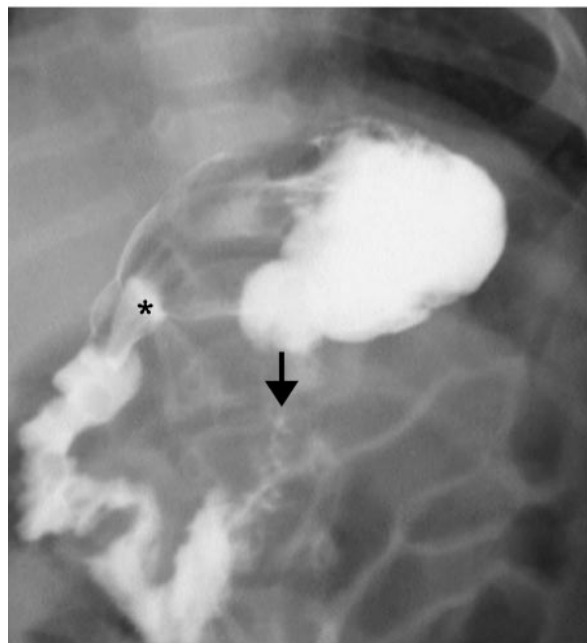
midgut volvulus, may cause intermittent abdominal distention and pain or acute bowel necrosis.

Clinical Manifestations in Older Children and Adults

Malrotation and midgut volvulus may be manifested also in older children and adults (5,20–22). The clinical manifestations in older patients often



a.



b.

Figure 5. Normal variants that mimic malrotation in two infants born prematurely. **(a)** Frontal view shows the position of the duodenal bulb (arrow), which is superimposed over the gastric antrum, and inferior displacement of the duodenojejunal junction (arrowhead). **(b)** Frontal view shows a similar inferior position of the duodenojejunal junction (arrow); * = duodenal bulb. Both the clinical manifestations and the findings on other images in these upper GI series were inconsistent with malrotation and, instead, indicative of normal variations.

are much less straightforward than are those in neonates and may include a wide variety of signs and symptoms (5,20–24). This fact has led to controversy and confusion in the literature, about whether older children and adults need surgical intervention (1,25). At present, there is no method for predicting which patients will develop volvulus as a result of malrotation. Given this situation and the often confusing manifestations in older patients, it is important that subtle abnormalities in the upper GI series be documented

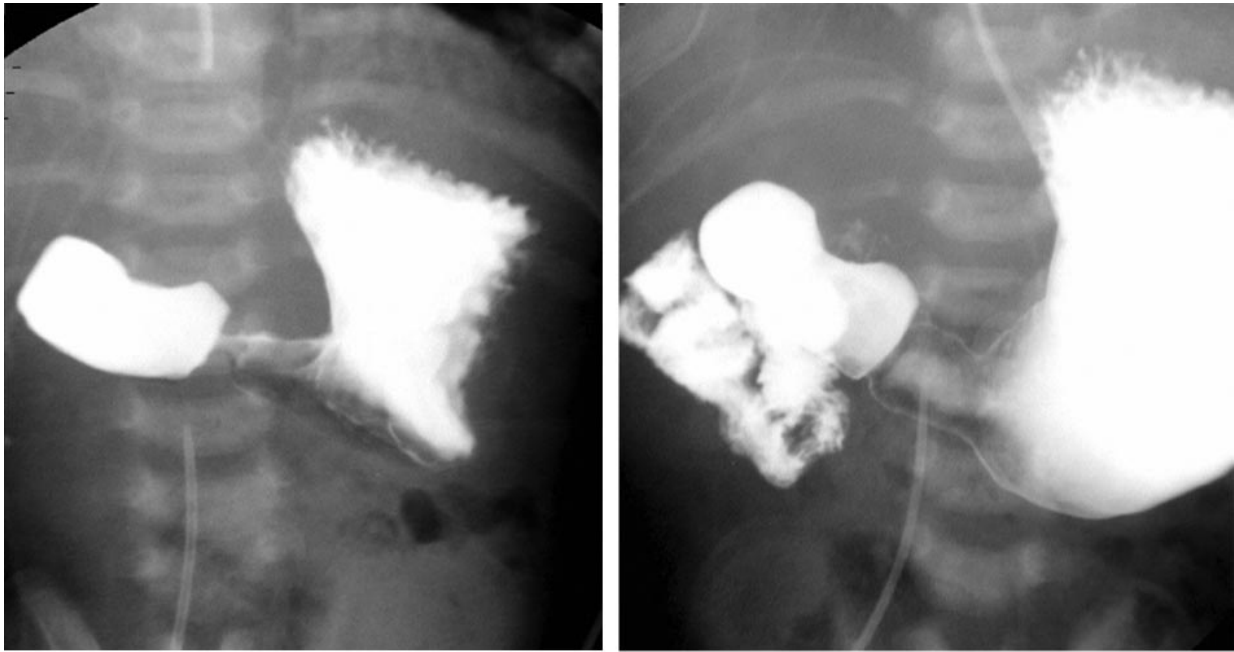
and discussed with the referring clinician. Long average delays of 1.7 years (13), 2.3 years (2), and up to 5 years (26) in the diagnosis of malrotation in symptomatic children after infancy are suggestive of the challenges of diagnosing the condition in older patients. Symptoms of malrotation in older children and adults range from acute abdominal pain and vomiting to mild intermittent pain and malabsorption (24,27–30). Other reported manifestations and complications of malrotation include short-gut syndrome, feeding difficulties, diarrhea, small-bowel obstruction, adhesive bands, internal hernia, malnutrition, failure to thrive, chylous ascites, mesenteric lymphocele, pneumatosis, and pneumonia (1,7,27,31–33). Malrotation also may be an incidental imaging finding, especially in adults (23,34).

Normal Anatomic Variations versus Malrotation

The upper GI series remains the imaging reference standard for the diagnosis of malrotation with or without volvulus (1,7,16,35). The goal of the examination for malrotation is to avert acute volvulus with its catastrophic complications, which include bowel necrosis. In acutely symptomatic patients, the upper GI tract examination should be performed urgently, since the treatment for acute volvulus is immediate surgery with the Ladd procedure (36,37). In the Ladd procedure, the surgeon cuts the Ladd bands to eliminate any obstruction, positions the small bowel in the right abdomen and the colon in the left abdomen, and performs an appendectomy. The bowel is not tacked in place, because the risk of volvulus will be very low after postoperative adhesions form.

Abdominal radiographs may be normal in appearance or may show distention of the stomach and proximal duodenum by air, with little distal bowel gas (16). The sensitivity of the upper GI series for the diagnosis of malrotation has been reported as 93% (38), 95% (11), and 100% (39), but a sensitivity of only 54% was reported for the diagnosis of midgut volvulus (39).

The normal position of the duodenojejunal junction is to the left of the left-sided pedicles of the vertebral body at the level of the duodenal bulb on frontal views (35) (Fig 4a) and posterior (retroperitoneal) on lateral views (Fig 4b). However, variations of the normal location may appear, particularly on frontal views in the upper GI series, that mimic malrotation. Inferior displacement of the normal duodenojejunal junction is a common variation seen on frontal views in infants (Fig 5). This finding, which in our experience is



a.

b.

Figure 6. Malrotation with obstructing duodenal bands. Radiographs show marked distention and obstruction of the proximal part of the duodenum (**a**) and an abnormal location of the duodenojejunal junction and the proximal part of the jejunum in the right upper abdominal quadrant (**b**).

more common in premature infants, may be due to displacement of the relatively mobile ligament of Treitz by the adjacent distended stomach or bowel (40).

In children with acute duodenal obstruction, the upper GI series may depict a Z-shaped configuration of the duodenum in the presence of obstructing peritoneal bands (Figs 6, 7) or a corkscrew-shaped duodenum in the presence of volvulus (Figs 8, 9) (1,41). In children who have bowel malrotation without volvulus, the upper GI series shows an abnormal position of the duodenojejunal junction and, implicitly (since it is not directly depicted), of the ligament of Treitz (Figs 10–13).

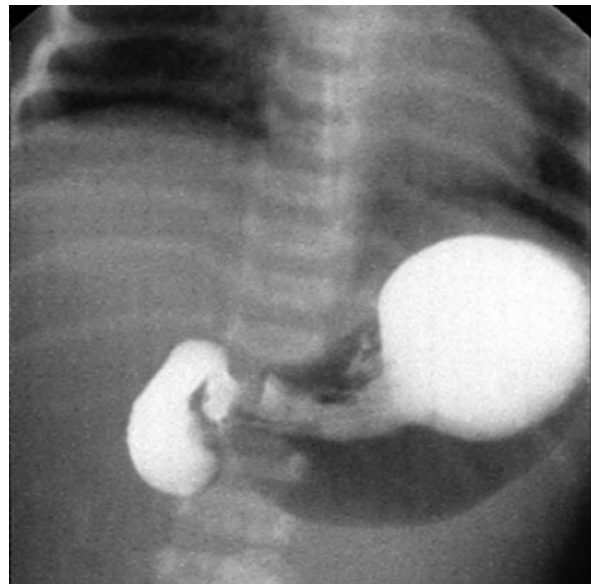
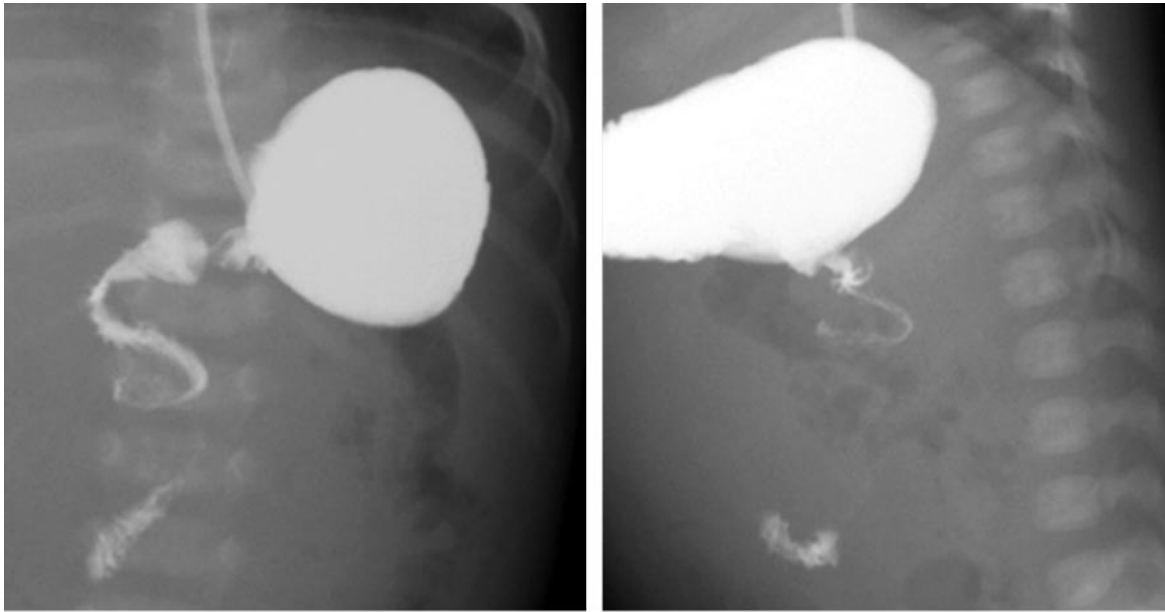
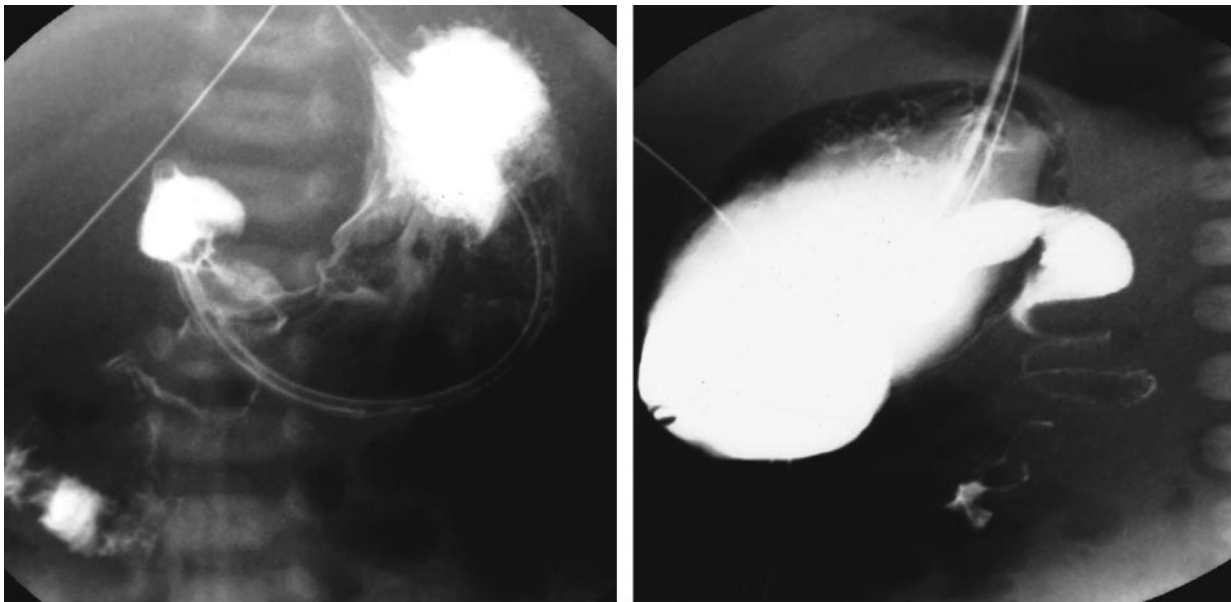


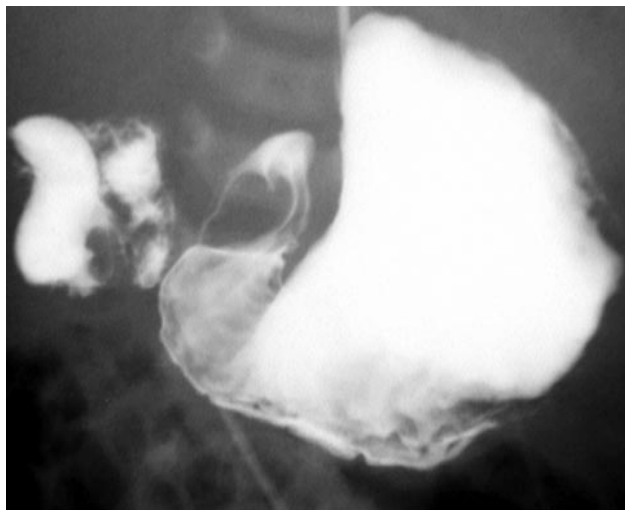
Figure 7. Malrotation with obstructing duodenal bands in a neonate. Radiograph shows distention of the proximal part of the duodenum by barium, but no air or barium in the distal part. In this situation, it may be impossible to distinguish duodenal atresia from malrotation and volvulus. The imaging findings therefore should be discussed with the referring physician and correlated with the clinical manifestations.



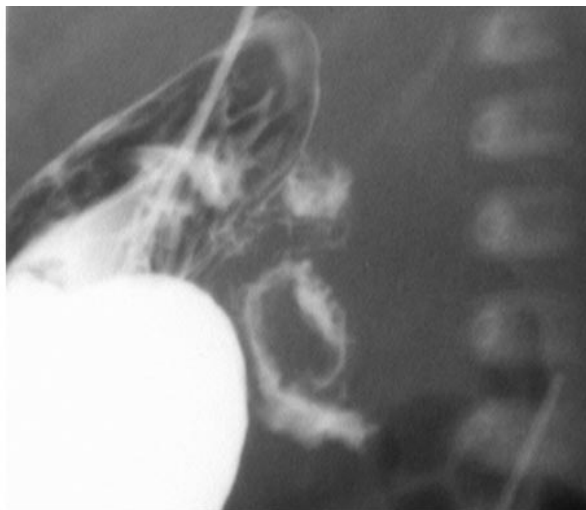a. **b.**
Figure 8. Malrotation with volvulus in a neonate. Radiographs obtained with barium administered via a nasogastric tube show a corkscrew appearance of the duodenum and an abnormal position of the duodenojejunal junction on both frontal (**a**) and lateral (**b**) views, features indicative of volvulus, which constitutes a surgical emergency.



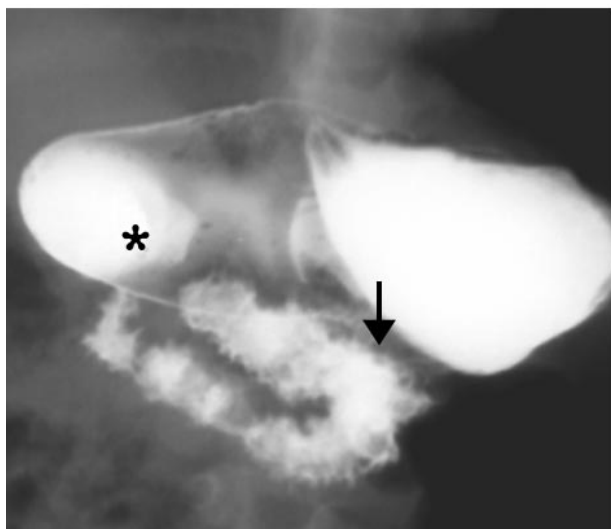
a. **b.**
Figure 9. Malrotation with volvulus in a neonate. Radiographs obtained with barium administered via a nasogastric tube show a corkscrew appearance of the duodenum and an abnormal position of the duodenojejunal junction on both frontal (**a**) and lateral (**b**) views, features diagnostic of volvulus, which constitutes a surgical emergency. The proximal part of the duodenum also is dilated because of obstruction by the volvulus.



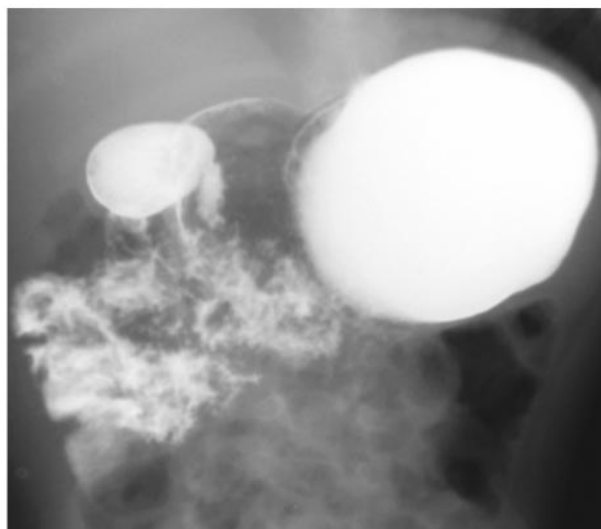
10a.



10b.



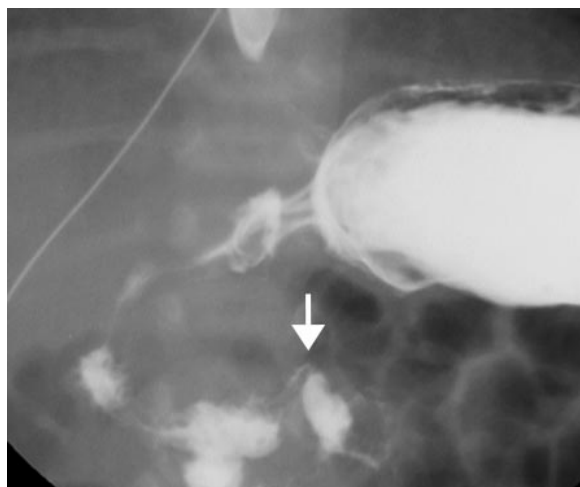
11a.



11b.

Figures 10, 11. (10) Malrotation without volvulus in an infant with nonbilious vomiting. (a) Frontal view shows the location of the entire duodenum to the right of the spine, a finding diagnostic of malrotation. (b) Lateral view shows an abnormal course of the duodenum, which is not downward and then back up to the level of the bulb, the normal location of the duodenojejunal junction. (11) Malrotation without volvulus in an infant with vomiting and failure to thrive. (a) Frontal radiograph shows the duodenojejunal junction (arrow), which does not cross to the left of the left pedicle of the vertebral body and which is located inferior to the duodenal bulb (*). The location of the proximal jejunal loop on the right is suggestive but not diagnostic of malrotation. (b) Delayed radiograph shows the location of the jejunal loops in the right side of the abdomen. Note that the duodenum does not cross the midline.

Figure 12. Malrotation without volvulus in a neonate. Frontal view from an upper GI series shows an abnormal location of the duodenojejunal junction (arrow) at the vertebral body pedicle and inferior to the duodenal bulb. The absence of distention in adjacent bowel loops and stomach, a condition that might have caused displacement of the duodenojejunal junction, indicates that this is not a normal anatomic variant.



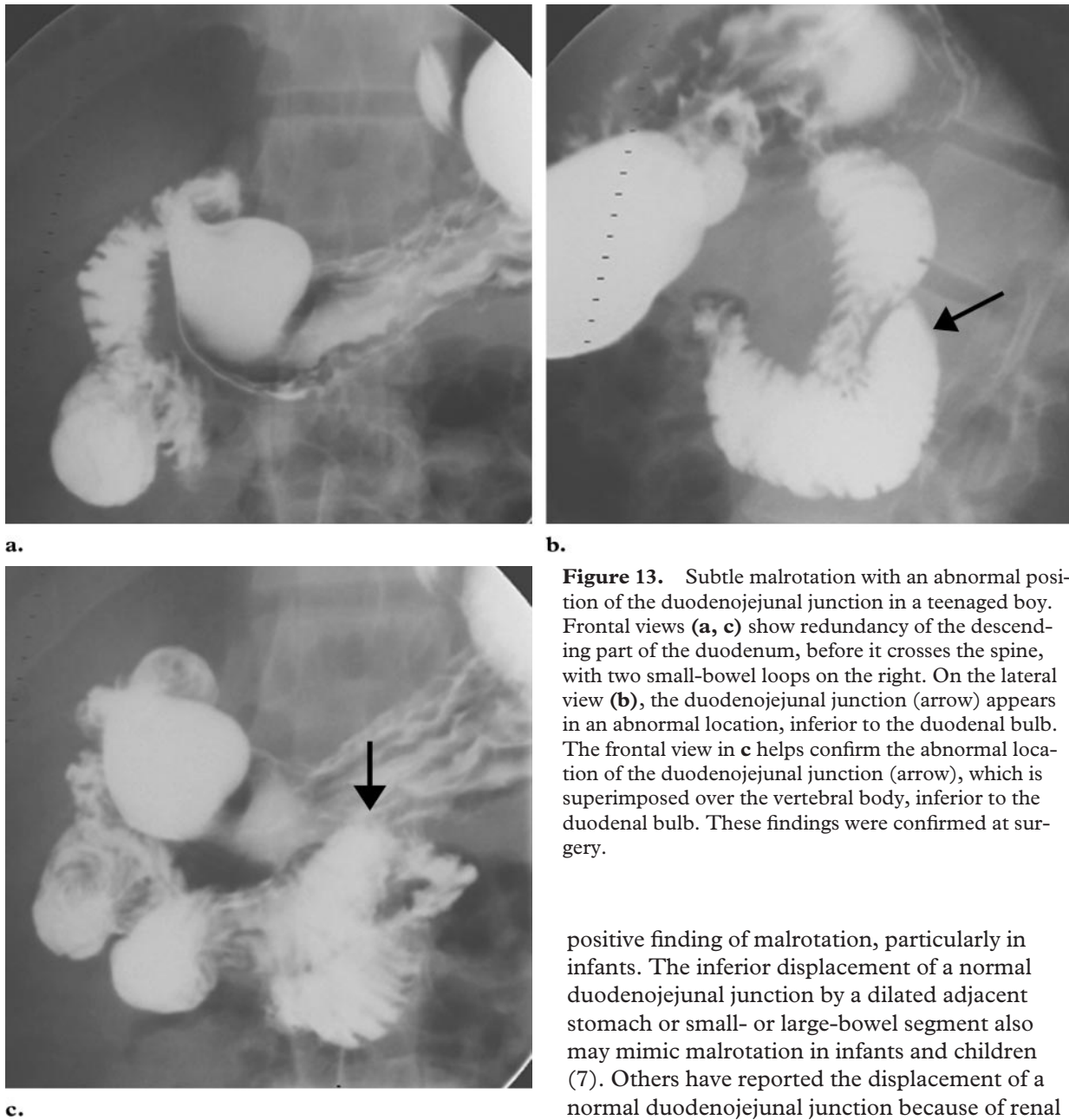
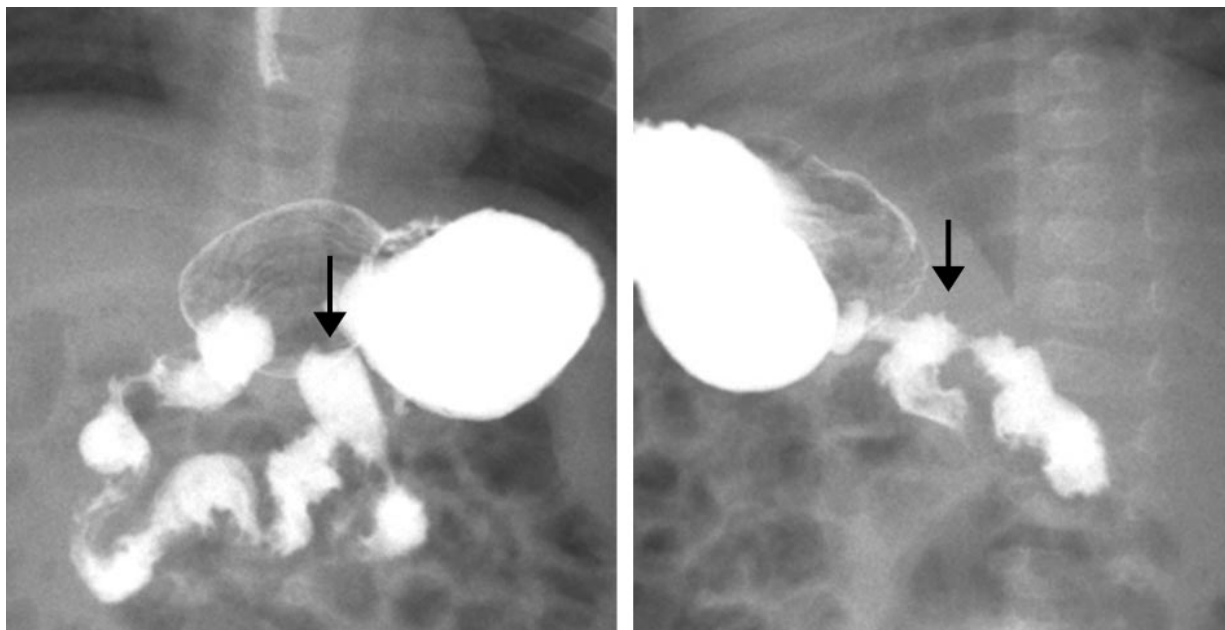


Figure 13. Subtle malrotation with an abnormal position of the duodenojejunal junction in a teenaged boy. Frontal views (**a, c**) show redundancy of the descending part of the duodenum, before it crosses the spine, with two small-bowel loops on the right. On the lateral view (**b**), the duodenojejunal junction (arrow) appears in an abnormal location, inferior to the duodenal bulb. The frontal view in **c** helps confirm the abnormal location of the duodenojejunal junction (arrow), which is superimposed over the vertebral body, inferior to the duodenal bulb. These findings were confirmed at surgery.

A 15% false-positive rate was reported for the detection of bowel malrotation in two studies of upper GI series in infants and children who subsequently underwent surgery with the Ladd procedure (23,35). The most common reason for a false-positive finding was a failure to recognize normal anatomic variations that mimicked malrotation. Variations such as the wandering duodenum (Fig 14), mobile duodenum, and duodenum inversum (42–44) observed on radiographs in the upper GI series may lead to a false-

positive finding of malrotation, particularly in infants. The inferior displacement of a normal duodenojejunal junction by a dilated adjacent stomach or small- or large-bowel segment also may mimic malrotation in infants and children (7). Others have reported the displacement of a normal duodenojejunal junction because of renal agenesis (45), enlargement of the spleen, or liver transplantation (7,46,47). An important factor in the displacement of a normal duodenojejunal junction in infants and young children is the relative laxity of their peritoneal ligaments. Because the peritoneal ligaments are lax in children younger than 4 years, the normal duodenojejunal junction is easily displaced during external manual palpation, by a dilated adjacent bowel segment, or by an enteric feeding tube (40).



a. **b.**
Figure 14. Wandering duodenum that mimics malrotation in an infant with vomiting. Frontal view (**a**) from an upper GI examination shows a longer and more meandering course of the duodenum instead of the typical C-shaped course, but both the frontal view and the oblique lateral view (**b**) show a normal position of the duodenojejunal junction (arrow).

False-negative findings in upper GI series also have been reported (35,42,48,49). False-negative rates of 3% (23), 5% (11), and 6% (3) have been cited, with most of the false-negative findings ascribed to misinterpretation of the duodenal course as indicative of normal variation rather than malrotation (42).

Problem Solving with the Upper GI Series

Meticulous technique in performing the upper GI tract examination is critical to avoid both false-positive and false-negative interpretations. The normal duodenum should remain in a posterior location. A normal position of the ligament of Treitz is implicit in the location of the duodenojejunal junction to the left of the spine, at the level of the duodenal bulb. The jejunum usually is located on the left side of the abdomen. It may be necessary to insert a nasogastric tube to control the influx of barium. If the position of the duodenojejunal junction is equivocal on radiographs from the upper GI series, diagnostic confidence and accuracy may be increased with a small-bowel follow-through examination to depict the

location of the small bowel and cecum. The cecum is abnormally positioned in 80% of patients with malrotation (1,42,48,50).

To improve the accuracy of identification of malrotation on the basis of the upper GI series, a number of steps should be followed.

■ **First, the initial passage of barium through the duodenum should be observed directly with fluoroscopy to confirm the course of the duodenum and the position of the duodenojejunal junction.** The duodenum often is obscured as the more distal loops of the small bowel fill with barium, and correct identification of the duodenum and duodenojejunal junction then becomes more challenging.

■ **Second, the position of the duodenojejunal junction should be documented with the acquisition of both frontal and true lateral projections.** On frontal views, the duodenojejunal junction should be located leftward of the left pedicle of the vertebral body at the level of the duodenal bulb or at least as high as its inferior aspect. A normal duodenojejunal junction may be displaced, particularly in the inferior direction, on the frontal projection. Such displacement may be caused by a horizontal stomach position, distention of the adjacent bowel, overfilling of the stomach with barium, enlargement of the spleen, liver

hing
int

hing
int

TP
cont.



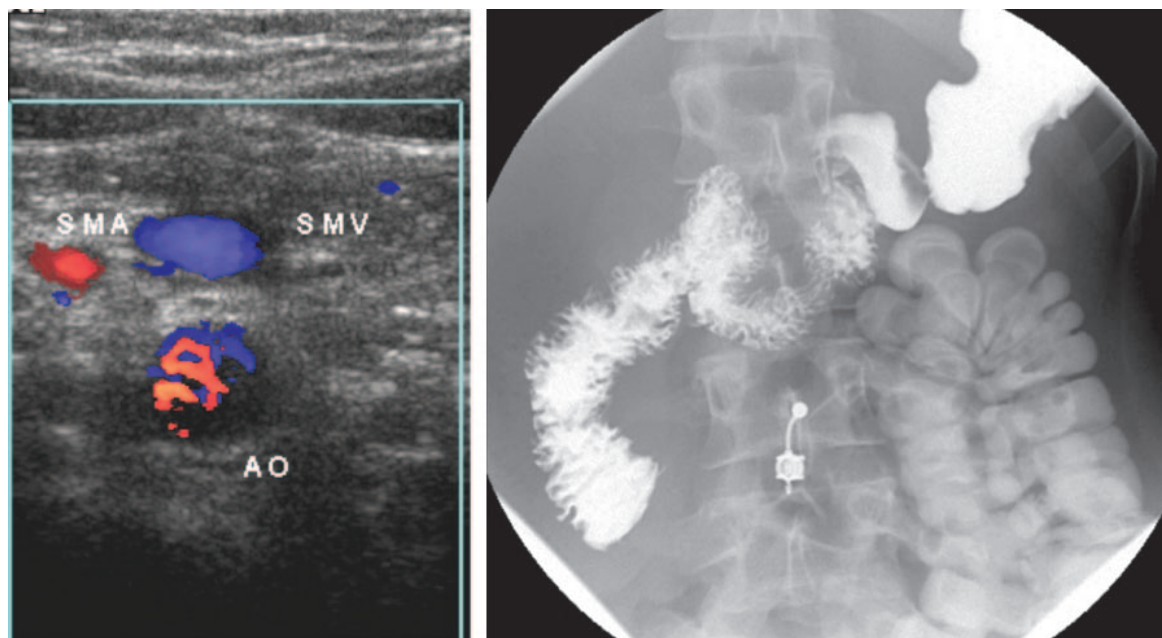


Figure 15. Malrotation in a 16-year-old girl with intermittent abdominal pain. **(a)** Transverse sonogram shows the reversal of the normal anatomic relation of the superior mesenteric artery (*SMA*) and superior mesenteric vein (*SMV*), a finding that prompted the radiologist to request an upper GI series. *AO* = aorta. **(b)** Fluoroscopic image shows an abnormal course of the duodenum into the right side of the abdomen. The colon, which is located in the left side of the abdomen, contains contrast material from an earlier CT examination. The patient underwent a Ladd procedure, which was successful.

transplantation, or scoliosis. In contrast, a posterior location of the duodenojejunal junction on true lateral views, as expected for a retroperitoneal structure, is reassuring (51). In children with malrotation, the distal course of the duodenum on the lateral view often does not reach the level of the duodenal bulb and instead turns in an anterior direction, into the peritoneal cavity (Fig 13b).

■ **Third, the stomach should not be overfilled with barium.** Bottle-fed infants, in particular, should not be given too large a quantity of barium. An overdistended stomach may obscure the duodenum and a normally positioned duodenojejunal junction and cause the radiologist to miss the first pass of the barium. In addition, overdistention of the stomach may cause inferior displacement of a normal duodenojejunal junction.

■ **Fourth, manual palpation may be used** during the upper GI study. This technique, as described by Lim-Dunham et al (47), allows the radiologist to **determine the mobility of the duodenum.** In normal children younger than 4 years, the bowel ligaments are lax, allowing greater mobility of the duodenojejunal junction, whereas the duodenojejunal junction in a child with malrotation is not

mobile (1,40). If the infant has an enteric feeding tube in the duodenum or jejunum, the tube may displace the normal duodenojejunal junction (1,40).

■ **Fifth, other imaging studies should be reviewed.** Is there an alternative explanation for an abnormal position of the duodenojejunal junction? For example, is there an enlarged spleen that displaces the duodenojejunal junction in a medial direction? Is there a bowel obstruction? Has the child undergone liver transplantation, a surgical procedure in which the ligament of Treitz is cut? Does the child have scoliosis? Does the patient have a syndrome (Table 1) or another anomaly (Table 2) associated with malrotation? Abdominal sonograms may depict the relation between the superior mesenteric artery and vein; CT and MR images also may show the relationship between the two vessels (52–56). The superior mesenteric vein is normally located to the right of and anterior to the superior mesenteric artery on axial views, but the relative positions of the vein and artery are reversed in 60% of individuals with malrotation (Fig 15) (54,55).

TP
cont.



ching
int

Back



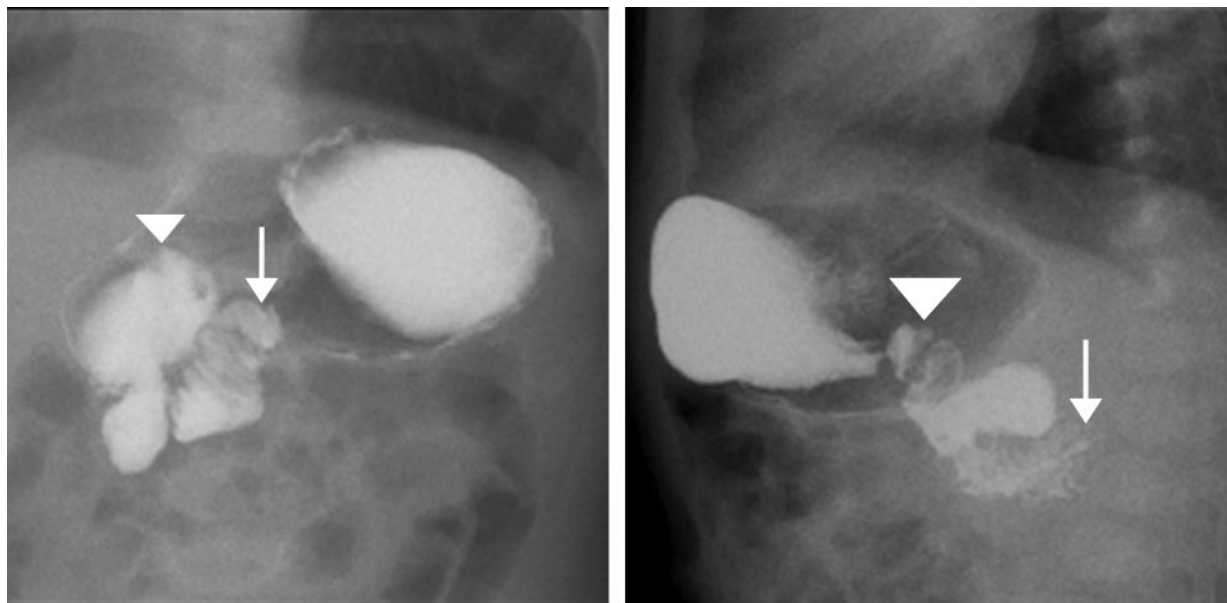
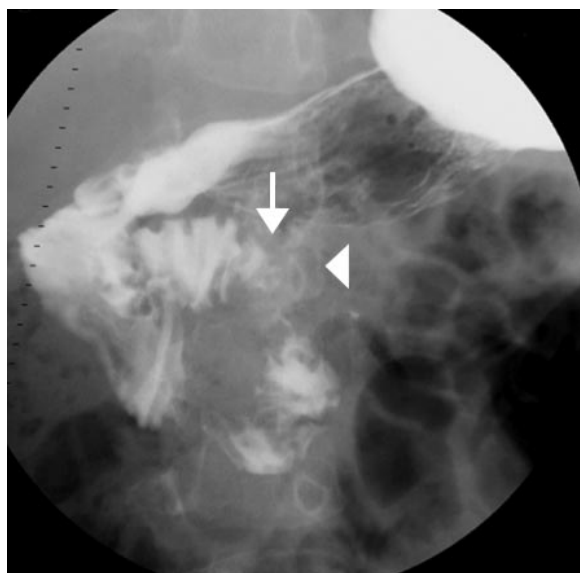


Figure 16. Subtle malrotation in an infant. **(a)** Frontal view from an upper GI series shows an abnormal location of the duodenojejunal junction (arrow), which is superimposed over the left pedicle of the vertebral body at the level of the duodenal bulb (arrowhead). **(b)** Lateral view shows an abnormal course of the duodenum and an abnormal position of the duodenojejunal junction (arrow), inferior to the duodenal bulb (arrowhead).

Figure 17. Subtle malrotation in an infant. Frontal view from an upper GI series demonstrates an abnormal position of the duodenojejunal junction (arrow), which does not pass to the left of the left pedicle of the vertebral body (arrowhead). The proximal jejunal loop courses to the right, a location that is suggestive but not diagnostic of malrotation. The diagnosis in this case might easily be missed, especially if the duodenojejunal junction abnormality is attributed to patient positioning.



■ Sixth, if the diagnosis remains in doubt or the upper GI tract findings are equivocal (Figs 16, 17a), delayed abdominal radiographs should be acquired to identify the position of the cecum.

Back

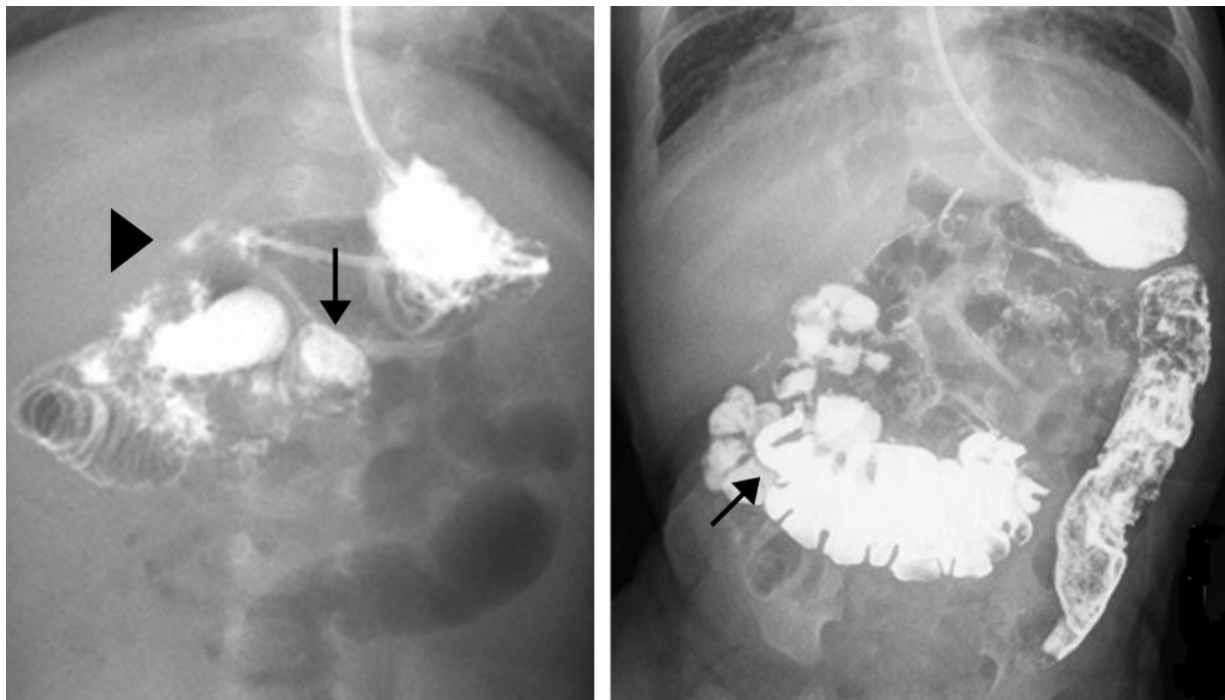


TP
cont.



While the position of the colon may be normal in a child with malrotation, 80% of individuals with malrotation have an abnormal cecal position (1,42,48,50) (Figs 17–20). As an alternative to delayed radiography, in an urgent situation, an enema may be administered with an iodinated contrast medium to demonstrate the position of

the colon. Generally, the shorter the distance between the duodenojejunal junction and the cecal apex, the shorter the length of the small-bowel mesentery and the greater the risk of volvulus.



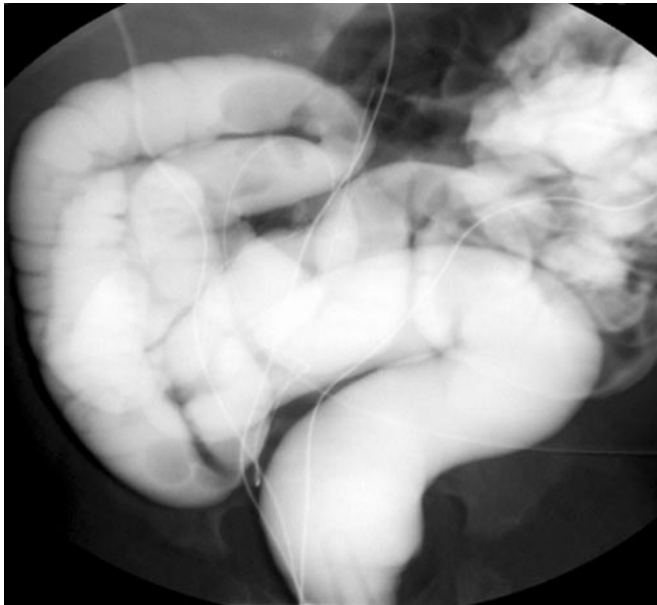
a.

b.

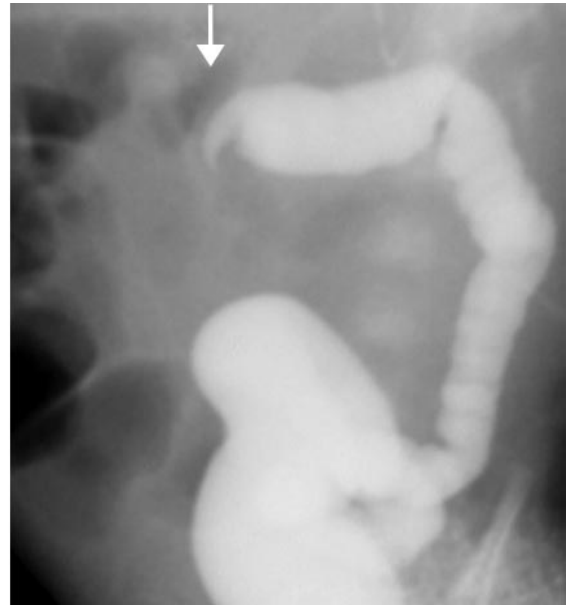
Figure 18. Subtle malrotation in a 5-month-old infant with Down syndrome, an uncorrected atrioventricular canal defect, and a clinical history of nonbilious vomiting. Because of the latter, an upper GI series (with barium administered via a nasogastric tube) was requested by the pediatrician prior to the surgical insertion of a gastric feeding tube. **(a)** Frontal view from the upper GI series demonstrates a mildly abnormal location of the duodenojejunal junction (arrow), inferior to the bulb (arrowhead) and overlying the midline rather than crossing over to the left of the pedicle. The right-sided location of the proximal jejunal loops also is visible. Because of these subtle abnormalities, the barium was followed through the small bowel to the colon. **(b)** Delayed radiograph shows an abnormal position of the cecum (arrow indicates the cecal apex and appendix). These anatomic abnormalities imply a foreshortening of the small-bowel mesentery. Malrotation was documented at surgery.

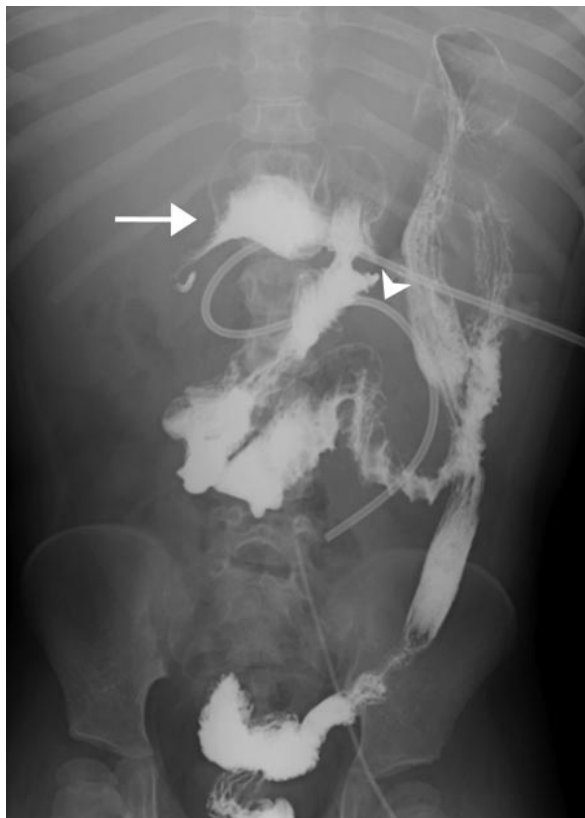

Figure 19. Malrotation in a 5-year-old girl. Delayed radiograph, obtained after an upper GI series, shows a markedly abnormal location of the cecum and appendix (arrow) in the epigastric region, a finding that implies a very short small-bowel mesentery and a high risk for volvulus. Barium outlines the entire colon, which is located in the left side of the abdomen. Note the gastrojejunal feeding tube, which follows the course of the duodenum and proximal jejunum. The distance between the cecum and the duodenojejunal junction (arrowhead) is very short.



21.



22.

Figures 21, 22. (21) Malrotation of the colon in a female infant with Cornelia de Lange syndrome and a history of feeding difficulties with gastrojejun tube feeds. Radiograph obtained with a barium enema shows an unusual position of the colon, which is located entirely on the right side of the abdomen, and a normal position of the small bowel. Surgery was not performed. (22) Acute volvulus of the transverse colon in a 3-week-old girl with trisomy 13, feeding intolerance (vomiting and abdominal distention), and decreased frequency of defecation. Radiograph obtained with a barium enema shows a beaklike disruption of the mid transverse colon (arrow), a sign of volvulus. At surgery for reduction of the volvulus, the colon was located mostly on the left side, and the small-bowel position was normal.

■ Seventh, if the clinical manifestations do not correspond to the upper GI tract findings, the upper GI series should be repeated on a subsequent day. A repeat upper GI series is much less invasive and less costly than a laparotomy. In infants, the barium may be best administered by using a nasogastric tube. Older children may be permitted to drink a limited amount of barium. The repeat upper GI series should be performed with a very small amount of barium, and the study should begin with the patient in the right lateral position to promote early emptying of the barium from the stomach to the duodenum. Air may be injected through the nasogastric tube to push the small amount of barium into the duodenum. The control of the barium volume and the careful positioning of the child allow the radiologist to avoid pitfalls such as overdistention of the stomach and filling of the proximal small bowel with barium before the position of the duodenojejunal junction has been documented.

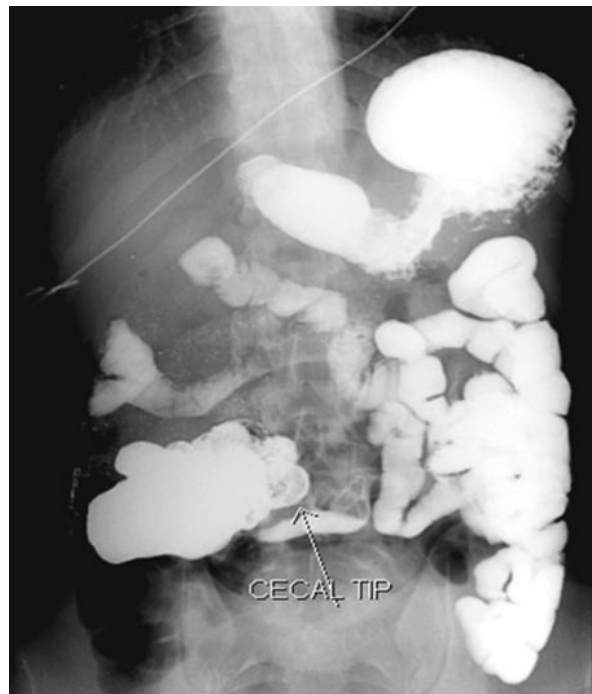

Figure 20. Malrotation in a 10-year-old boy. Delayed radiograph from an upper GI series shows the cecal apex at the level of the L3-L4 intervertebral space. The abnormal location of the cecum suggests a predisposition to volvulus due to foreshortening of the small-bowel mesentery.

hing
int

Back



Malrotation of the Colon Alone

A normal variant that all radiologists encounter is the mobile cecum, which is seen in up to 15% of individuals (1,7,44). Very rarely, an abnormal position of the colon may be seen in conjunction with a normal position of the small bowel. Malrotation limited to the colon is much rarer than that of the small bowel alone or that of both the small and the large bowel together (24,57–59). In infants who present with vomiting, an enema with iodinated contrast material may reveal a distal bowel obstruction due to an acute volvulus of the colon, usually at the level of the transverse colon (Figs 21, 22). Colonic volvulus may occur either because of abnormal embryonic rotation or because of redundancy of the transverse mesocolon.

Conclusions

The diagnosis of malrotation on the basis of an upper GI series may be challenging even for experienced radiologists. Various methods can be used to improve diagnostic accuracy and confidence, including direct fluoroscopic observation of the first pass of barium through the duodenum, documentation of the position of the duodenojejunal junction with the acquisition of both frontal and lateral views, limitation of the quantity of barium administered to children (with use of a nasogastric tube in infants), use of manual palpation during the performance of the upper GI series, review of previous imaging studies, delayed abdominal radiography to document the position of the cecum if the diagnosis is in doubt, and repetition of the upper GI series on a subsequent day if the clinical manifestations do not correspond to the upper GI tract appearance.

References

1. Strouse PJ. Disorders of intestinal rotation and fixation ("malrotation"). *Pediatr Radiol* 2004;34:837–851.
2. Maxson RT, Franklin PA, Wagner CW. Malrotation in the older child: surgical management, treatment, and outcome. *Am Surg* 1995;61:135–138.
3. Prasil P, Flageole H, Shaw KS, Nguyen LT, Youssef S, Laberge JM. Should malrotation in children be treated differently according to age? *J Pediatr Surg* 2000;35:756–758.
4. Wang CA, Welch CE. Anomalies of intestinal rotation in adolescents and adults. *Surgery* 1963;54:839–855.
5. Dietz DW, Walsh RM, Grundfest-Broniatowski S, Lavery IC, Fazio VW, Vogt DP. Intestinal malrotation: a rare but important cause of bowel obstruction in adults. *Dis Colon Rectum* 2002;45:1381–1386.
6. Friedland GW, Mason R, Poole GJ. Ladd's bands in older children, adolescents, and adults. *Radiology* 1970;95:363–368.
7. Jamieson D, Stringer D. Small bowel. In: Babyn PS. *Pediatric gastrointestinal imaging and intervention*. 2nd ed. Hamilton, Ontario: Decker, 2000; 311–332.
8. Dott NM. Anomalies of intestinal rotation: their embryology and surgical aspects—with report of five cases. *Br J Surg* 1923;11:251–286.
9. Mall FP. Development of the human intestine and its position in the adult. *J Morphol* 1898;12,14:197–208.
10. Snyder WH Jr, Chaffin L. Embryology and pathology of the intestinal tract: presentation of 40 cases of malrotation. *Ann Surg* 1954;140:368–379.
11. Torres AM, Ziegler MM. Malrotation of the intestine. *World J Surg* 1993;17:326–331.
12. Millar AJ, Rode H, Brown RA, Cywes S. The deadly vomit: malrotation and midgut volvulus. *Pediatr Surg Int* 1987;2:172–176.
13. Spigland N, Brandt ML, Yazbeck S. Malrotation presenting beyond the neonatal period. *J Pediatr Surg* 1990;25:1139–1142.
14. Bonadio WA, Clarkson T, Naus J. The clinical features of children with malrotation of the intestine. *Pediatr Emerg Care* 1991;7:348–349.
15. Rescorla FJ, Shedd FJ, Grosfeld JL, Vane DW, West KW. Anomalies of intestinal rotation in childhood: analysis of 447 cases. *Surgery* 1990;108:710–716.
16. Berdon WE, Baker DH, Bull S, et al. Midgut malrotation and volvulus. *Radiology* 1970;96:375–383.
17. Andrassy RJ, Mahour GH. Malrotation of the midgut in infants and children: a 25-year review. *Arch Surg* 1981;116:158–160.
18. Ford EG, Senac MO Jr, Srikanth MS, Weitzman JJ. Malrotation of the intestine in children. *Ann Surg* 1992;215:172–178.
19. Taybi H, Lachman R. *Radiology of syndromes, metabolic disorders, and skeletal dysplasias*. 3rd ed. Chicago, Ill: Yearbook Medical Publishers, 1990; 825–826.
20. Fukuya T, Brown BP, Lu CC. Midgut volvulus as a complication of intestinal malrotation in adults. *Dig Dis Sci* 1993;38:438–444.
21. Yanez R, Spitz L. Intestinal malrotation presenting outside the neonatal period. *Arch Dis Child* 1986;61:682–685.
22. Rao PL, Katariya RN, Rao PG, Sood S. Malrotation of midgut causing intestinal obstruction in adults. *J Assoc Physicians India* 1977;25:493–497.
23. Dilley AV, Pereira J, Shi EC, et al. The radiologist says malrotation: does the surgeon operate? *Pediatr Surg Int* 2000;16:45–49.
24. Balthazar EJ. Intestinal malrotation in adults. *AJR Am J Roentgenol* 1976;126:358–367.

25. Gohl ML, DeMeester TR. Midgut nonrotation in adults: an aggressive approach. *Am J Surg* 1975;129:319-323.
26. el-Gohari MA, Cook RC. Intestinal malrotation beyond the neonatal period. *Z Kinderchir* 1984;39:237-241.
27. Berdon WE. The diagnosis of malrotation and volvulus in the older child and adult: a trap for radiologists. *Pediatr Radiol* 1995;25:101-103.
28. Berardi RS. Anomalies of midgut rotation in the adult. *Surg Gynecol Obstet* 1980;151:113-124.
29. Brandt ML, Pokorny WJ, McGill CW, Harberg FJ. Late presentations of midgut malrotation in children. *Am J Surg* 1985;150:767-771.
30. Taylor GA, Teele RL. Chronic intestinal obstruction mimicking malrotation in children. *Pediatr Radiol* 1985;15:392-394.
31. Howell CG, Voza F, Shaw S, et al. Malrotation, malnutrition, and ischemic bowel disease. *J Pediatr Surg* 1982;17:469-473.
32. West KW, Rescorla FJ, Grosfeld JL, Vane DW. Pneumatosis intestinalis in children beyond the neonatal period. *J Pediatr Surg* 1989;24:818-822.
33. Zimmerman LM, Laufman H. Intra-abdominal hernias due to developmental and rotational anomalies. *Ann Surg* 1953;138:82-91.
34. Zissin R, Rathaus V, Oscadchy A, Kots E, Gayer G, Shapiro-Feinberg M. Intestinal malrotation as an incidental finding on CT in adults. *Abdom Imaging* 1999;24:550-555.
35. Long FR, Kramer SS, Markowitz RI, Taylor GE, Liacouras CA. Intestinal malrotation in children: tutorial on radiographic diagnosis in difficult cases. *Radiology* 1996;198:775-780.
36. Ladd WE. Congenital obstruction of the duodenum in children. *N Engl J Med* 1932;206:277-283.
37. Ladd WE. Surgical diseases of the alimentary tract in infants. *N Engl J Med* 1936;215:705-708.
38. Lin JN, Lou CC, Wang KL. Intestinal malrotation and midgut volvulus: a 15-year review. *J Formos Med Assoc* 1995;94(4):178-181.
39. Seashore JH, Touloukian RJ. Midgut volvulus: an ever-present threat. *Arch Pediatr Adolesc Med* 1994;148:43-46.
40. Katz ME, Siegel MJ, Shackelford GD, McAlister WH. The position and mobility of the duodenum in children. *AJR Am J Roentgenol* 1987;148:947-951.
41. Ablow RC, Hoffer FA, Seashore JH, Touloukian RJ. Z-shaped duodenojejunal loop: sign of mesenteric fixation anomaly and congenital bands. *AJR Am J Roentgenol* 1983;141:461-464.
42. Long FR, Kramer SS, Markowitz RI, Taylor GE. Radiographic patterns of intestinal malrotation in children. *RadioGraphics* 1996;16:547-556.
43. Long FR, Mutabagani KH, Caniano DA, Dumont RC. Duodenal inversion mimicking mesenteric artery syndrome. *Pediatr Radiol* 1999;29:602-604.
44. Beasley SW, de Campo JF. Pitfalls in the radiological diagnosis of malrotation. *Australas Radiol* 1987;31:376-383.
45. Meyers MA, Whalen JP, Evans JA, Viamonte M. Malposition and displacement of the bowel in renal agenesis and ectopia: new observations. *Am J Roentgenol Radium Ther Nucl Med* 1973;117:323-333.
46. Benya EC, Ben-Ami TE, Whittington PF, Alonso EM, Millis JM, Yousefzadeh DK. Duodenum and duodenal-jejunal junction in children: position and appearance after liver transplantation. *Radiology* 1998;207:233-236.
47. Lim-Dunham JE, Ben-Ami T, Yousefzadeh DK. Manual epigastric compression during upper gastrointestinal examination of neonates: value in diagnosis of intestinal malrotation and volvulus. *AJR Am J Roentgenol* 1999;173:979-983.
48. Slovis TL, Klein MD, Watts FB. Incomplete rotation of the intestine with a normal cecal position. *Surgery* 1980;87:325-330.
49. Schey WL, Donaldson JS, Sty JR. Malrotation of bowel: variable patterns with different surgical considerations. *J Pediatr Surg* 1993;28:96-101.
50. Lewis EJ. Partial duodenal obstruction with incomplete duodenal rotations. *J Pediatr Surg* 1966;1:47-53.
51. Koplewitz BZ, Daneman A. The lateral view: a useful adjunct in the diagnosis of malrotation. *Pediatr Radiol* 1999;29:144-145.
52. Cunningham T, Sover E. Recognizing malrotation: the superior mesenteric vein rotation sign [letter]. *AJR Am J Roentgenol* 1994;163:1267.
53. Chou CK, Mak CW, Hou CC, Chang JM, Tzeng WS. CT of the mesenteric vascular anatomy. *Abdom Imaging* 1997;22:477-482.
54. Zerlin JM, DiPietro MA. Mesenteric vascular anatomy at CT: normal and abnormal appearances. *Radiology* 1991;179:739-742.
55. Zerlin JM, DiPietro MA. Superior mesenteric vascular anatomy at US in patients with surgically proved malrotation of the midgut. *Radiology* 1992;183:693-694.
56. Ashley LM, Allen S, Teele RL. A normal sonogram does not exclude malrotation. *Pediatr Radiol* 2001;31(5):354-356.
57. Black RE, Cox JA. Volvulus of the transverse colon in children: report of a case and review of the literature. *Z Kinderchir* 1984;39:69-71.
58. Anderson JR, Lee D, Taylor TV, Ross AH. Volvulus of the transverse colon. *Br J Surg* 1981;68:179-181.
59. Samuel M, Boddy SA, Nicholls E, Capps S. Large bowel volvulus in childhood. *Aust N Z J Surg* 2000;70:258-262.

Intestinal Malrotation in Children: A Problem-solving Approach to the Upper Gastrointestinal Series

Kimberly E. Applegate, MD, MS et al

RadioGraphics 2006; 26:1485–1500 • Published online 10.1148/rg.265055167 • Content Codes:  

Page 1487

Malrotation is usually diagnosed in newborns and young infants; up to 75% of symptomatic cases occur in newborns, and up to 90% of symptomatic cases occur within the 1st year of life.

Page 1488

In individuals with malrotation, the mesenteric attachment of the midgut, particularly the portion from the duodenojejunal junction to the cecum, is abnormally short..

Page 1489

The normal position of the duodenojejunal junction is to the left of the left-sided pedicles of the vertebral body at the level of the duodenal bulb on frontal views and posterior (retroperitoneal) on lateral views.

Page 1494

The cecum is abnormally positioned in 80% of patients with malrotation.

Pages 1494–1496, 1498

To improve the accuracy of identification of malrotation on the basis of the upper GI series, a number of steps should be followed. First, the initial passage of barium through the duodenum should be observed directly with fluoroscopy to confirm the course of the duodenum and the position of the duodenojejunal junction. ... Second, the position of the duodenojejunal junction should be documented with the acquisition of both frontal and true lateral projections. ... Third, the stomach should not be overfilled with barium. ... Fourth, manual palpation may be used during the upper GI study to determine the mobility of the duodenum. ... Fifth, other imaging studies should be reviewed. ... Sixth, if the diagnosis remains in doubt or the upper GI tract findings are equivocal, delayed abdominal radiographs should be acquired to identify the position of the cecum. ... Seventh, if the clinical manifestations do not correspond to the upper GI tract findings, the upper GI series should be repeated on a subsequent day.