

Fluoroscopy

Double-Contrast Barium Swallow Guide

Version 3

Marie L. Duan Meservy & Samuel Q. Armstrong
2-26-2018

Special thanks to:

Chandler D. Connell, RT

Crista S. Cimis, RT

Judith Austin-Strohbehn, MD

Nancy J. McNulty, MD

Therese J. Vaccaro, MD

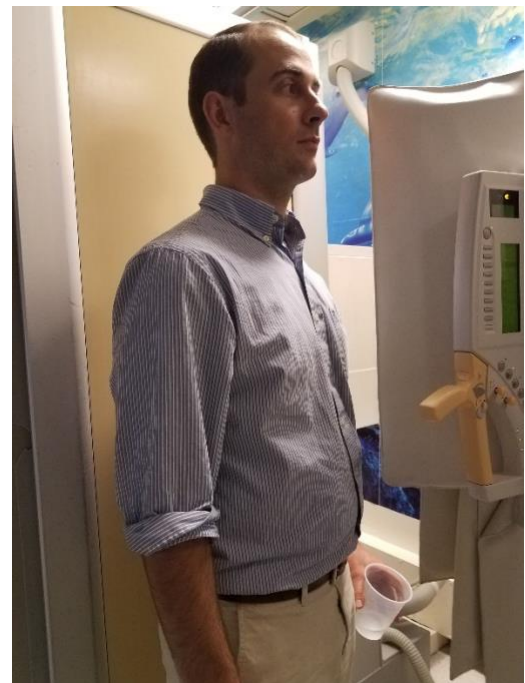Introduction

Introduce yourself as Dr. [last name]. Ask the patient why he or she is having a barium swallow and give a brief explanation of the study. Use professional terms such as "contrast" rather than "stuff." One key history point to elicit is if the patient is having dysphagia symptoms. Ask if they have difficulty swallowing breads and meats, namely, if they have the sensation of food sticking in the throat or chest and perhaps require additional swallows of fluid to help them go down. Regardless of the location of the perceived dysphagia, be sure to include rapid sequence imaging of the hypopharynx, because the perceived level of obstruction often does not correlate with pathology at that level.

Double-contrast esophagram

Patient position

The patient should stand upright (fluoroscopy table at 90 degrees) in the left posterior oblique position in order to offset the esophagus from the spine.



Double-contrast esophagram

Images and patient instructions

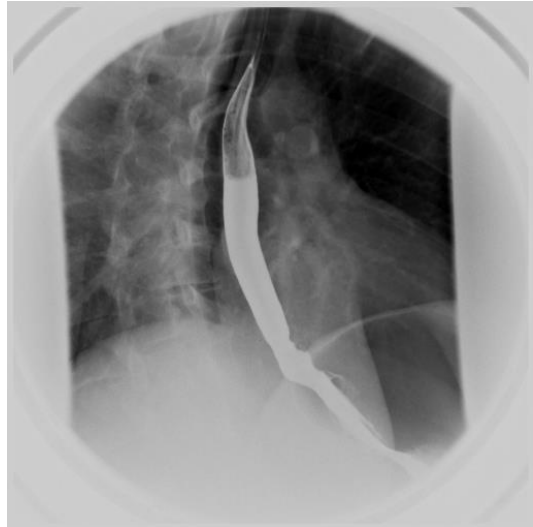
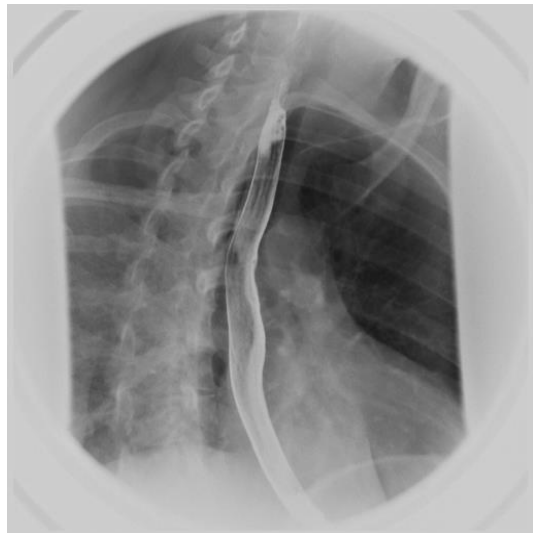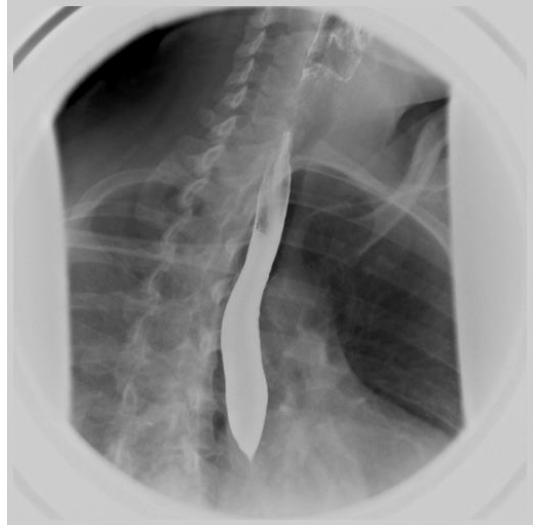1st drink: This is a carbonated drink, which includes swallowing dry effervescent crystals followed by a sip of water. Alternatively, the water and crystals may be mixed and swallowed together, however, mixing prior to drinking may allow a significant amount of the carbon dioxide to escape before ingestion. Instruct the patient not to burp despite the sensation to do so.

2nd drink: Instruct the patient to "please take a large gulp" of thick barium. The key is to take images of a maximally distended esophagus, that is, "double contrast" images (double contrast refers to barium and air). The barium coated esophageal mucosa is distended by carbon dioxide, which is produced by the reaction of the crystals and water interacting with each other. Have the patient take additional large gulps of thick barium until you have completed the imaging for this step.

Take exposures (also known as "real" images) of the upper, mid, and lower thirds of the distended esophagus. It is best to "park" the tower at the level you plan to take an exposure image in order to mitigate any motion artifact. Take spot fluorostore images of the esophagus in between exposures to capture as much relevant information as needed.

Purpose

The double-contrast esophagram is used to evaluate the esophageal mucosa and mural submucosa for abnormalities, most commonly related to infection, inflammation, neoplasm. There are normal and abnormal extrinsic impressions of the cervical and thoracic esophagus, which are important to recognize, namely, the aortic arch, left bronchus, pulmonary veins, and diaphragmatic hiatus.



Coating the stomach

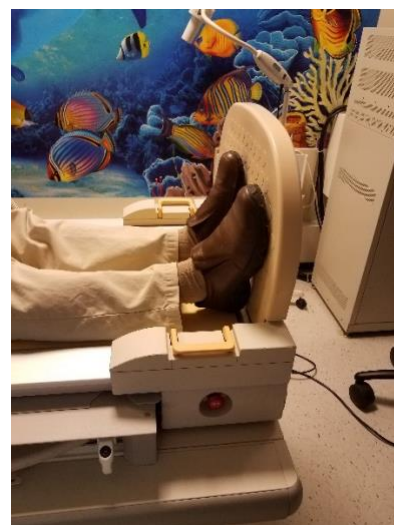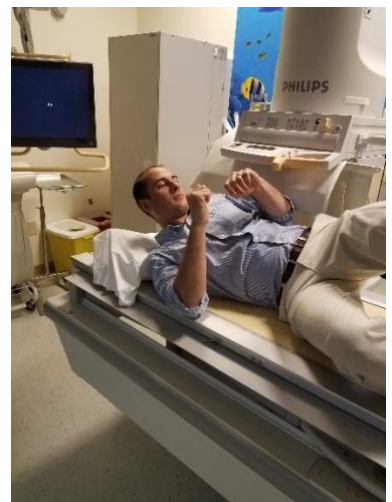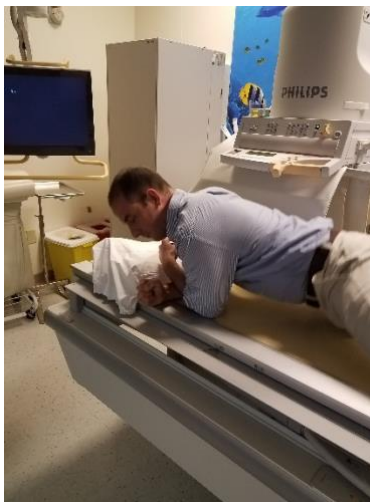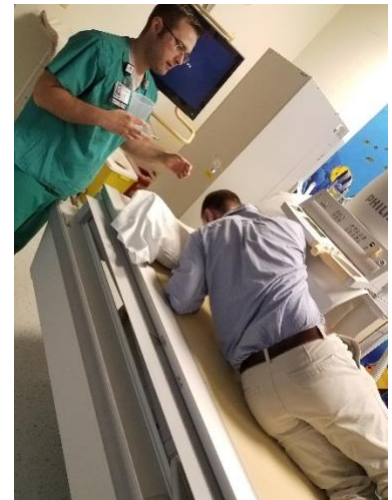
Patient position and instructions

The patient should face the tower while the fluoroscopy table is moved from 90 to 0 degrees. Once the table is down, the patient should roll completely twice.

Inform the patient that the table will be lowered. Once the table is flat, then instruct the patient to roll over ("barrel roll") twice. Also, instruct the patient to do the roll toward their left—away from the gastric antrum—in order to prevent contrast from leaving the stomach.

Having the patient roll ensures coating of the stomach mucosa with the thick barium. This allows for evaluation of the gastric fundus in the next step.

Before bringing the fluoroscopy table back to 90 degrees be sure to instruct the patient to have their feet touching the platform.



Upright lateral view of the distended stomach

Patient position

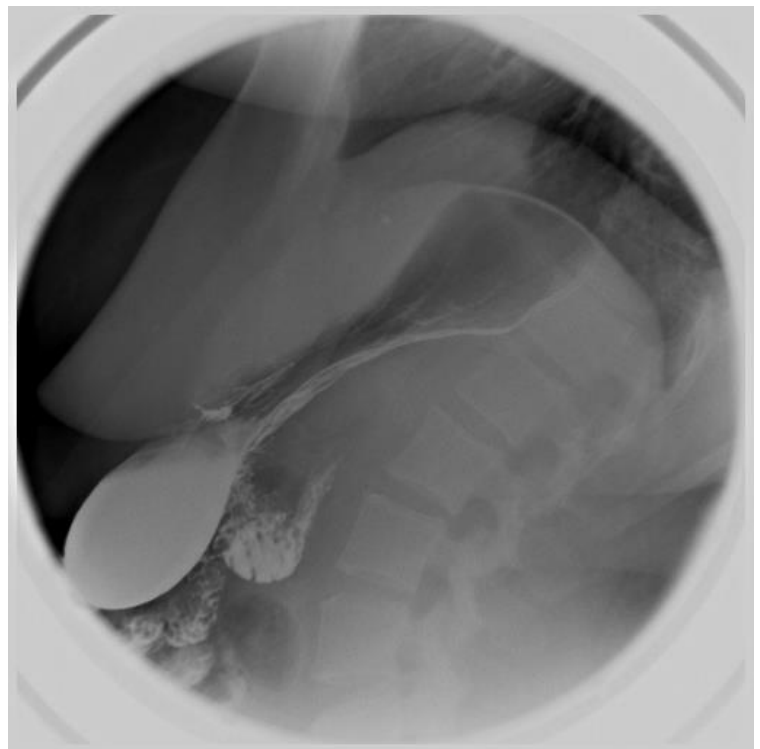
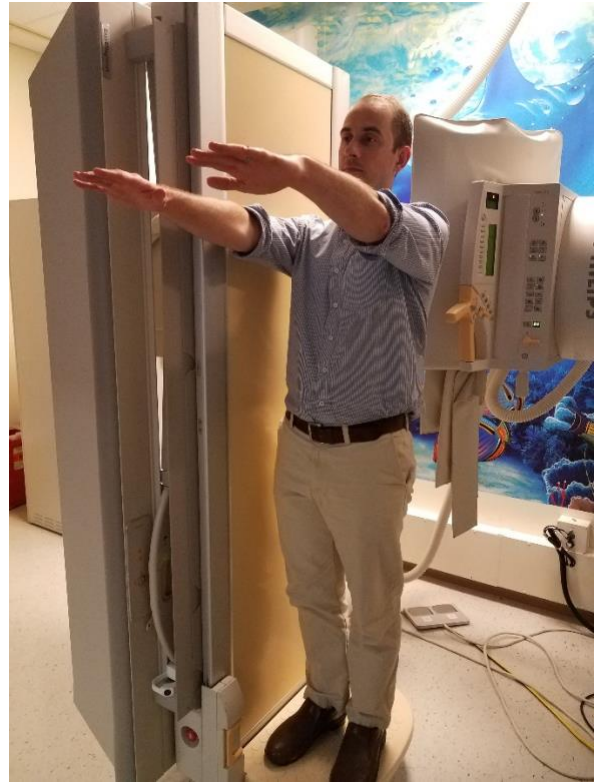Bring the fluoroscopy table back to 90 degrees and position the patient laterally with arms extended ("sleepwalking position") to allow a true lateral view of stomach. Extending the arms keeps them out of the way and allowing for an unobscured image of the stomach to be obtained.

Images and patient instructions

Instruct patient to turn to their right (face you) and put their arms out in front of them (in a "sleepwalker" posture). Use spot-images to get your tower in the best position, centering on the fundus, then take an exposure of the stomach. The gastric fundus should be filled with air and the mucosa coated with barium.

Purpose

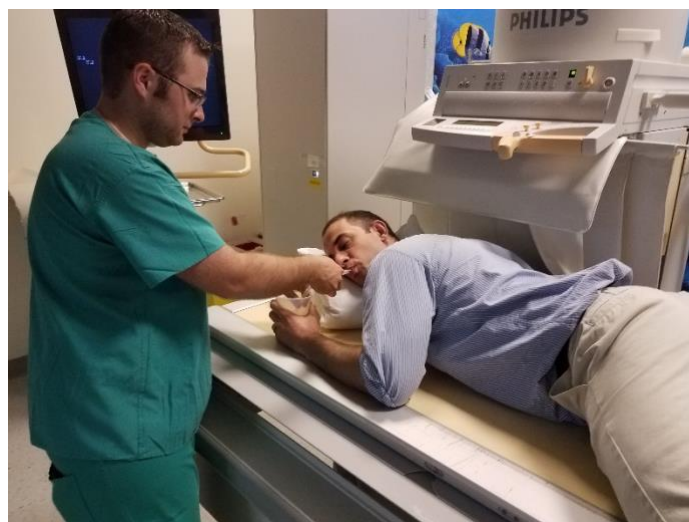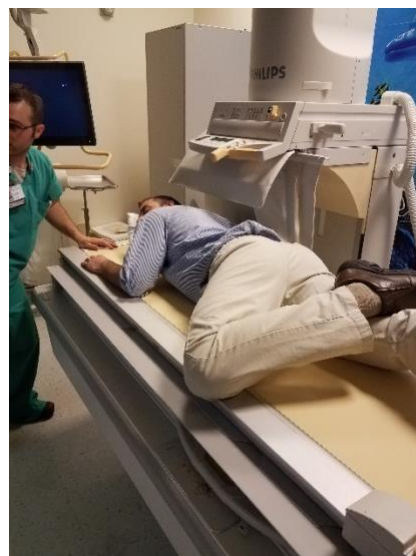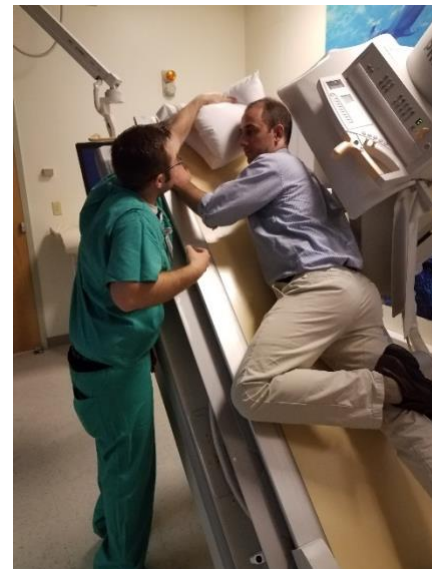This double-contrast view of the fundus allows the mucosa to be evaluated for pathology, such as filling defects, masses, ulcerations, and postsurgical changes, for example, Nissen wrap.



Single-contrast esophagram

Patient position

Have the patient assume a partial RAO position while standing upright then place the table flat (0 degrees) again and have the patient lie in the right anterior oblique (RAO) position with their head resting on a pillow. Alternatively, the patient may be placed in RAO after flattening the table.



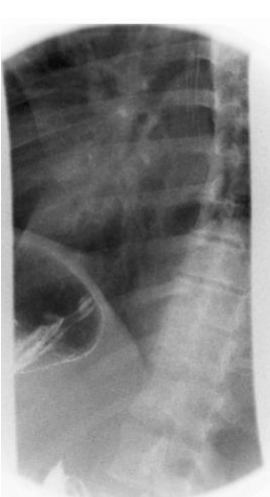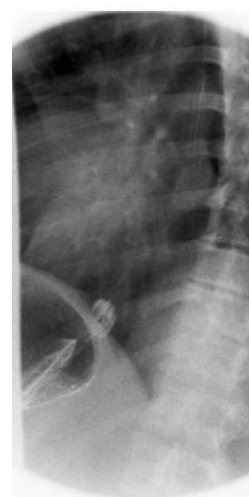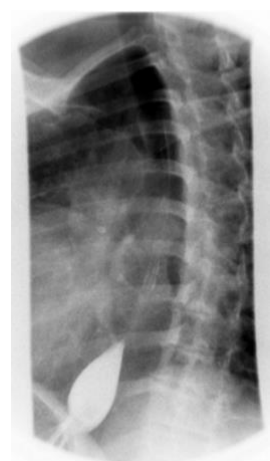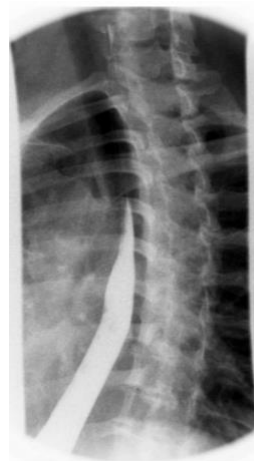
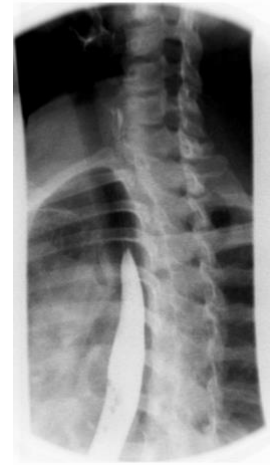
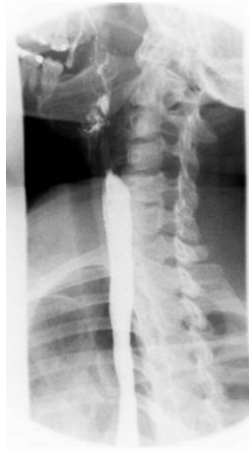Single-contrast esophagram

Images and patient instructions

Have the patient drink thin barium from a straw and observe two to three single swallows by taking fluorostore images of the top of the barium column as it passes through the proximal and distal esophagus and into the stomach. Have the patient open their mouth after the swallow and wait 20 seconds between subsequent swallows.

Purpose

The single-contrast esophagram allows for an assessment of esophageal motility. Having the patient open their mouth after the swallows prevents them from initiating extra swallows during the exam. Waiting 20 seconds between swallows allows for the barium to be cleared from the esophagus, which is normally about 13 seconds. If the barium bolus is retained for more than 20 seconds then clearing time is delayed. (The reference work for the normal range of esophageal clearing time provided above is *Esophageal motility disorders*. W.G. Paterson, Raj K. Goyal and Fortunée Irene Habib. *GI Motility online* (2006). doi :10.1038/gimo20.)



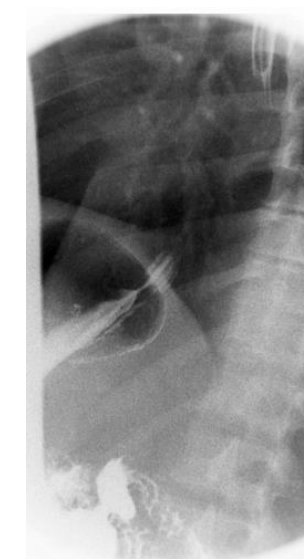
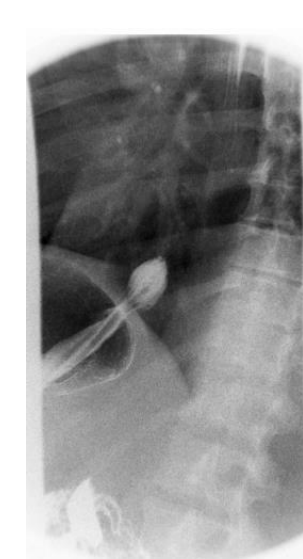
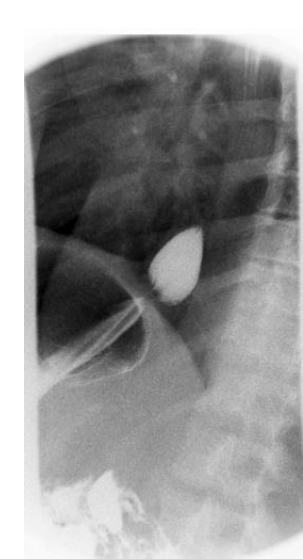
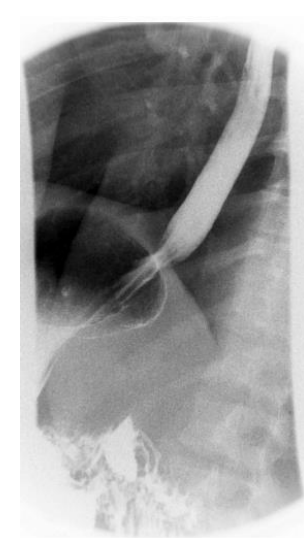
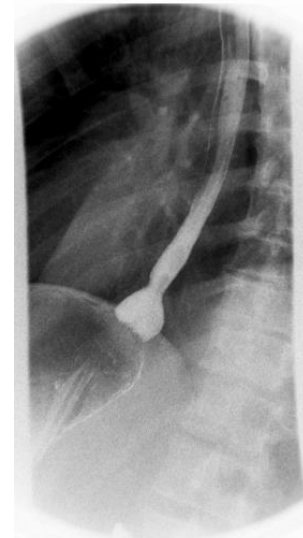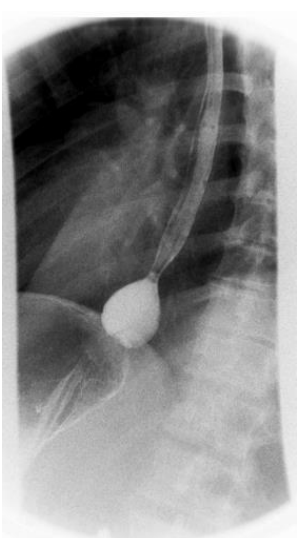
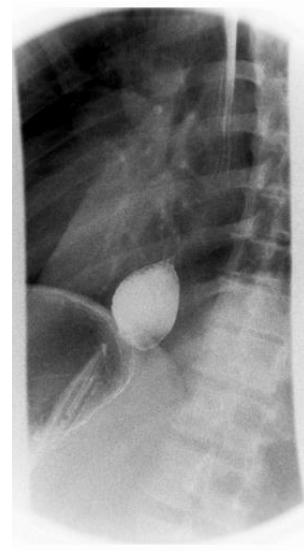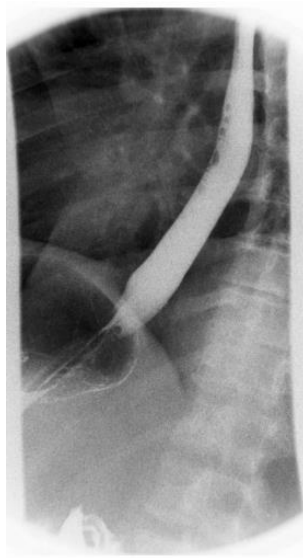
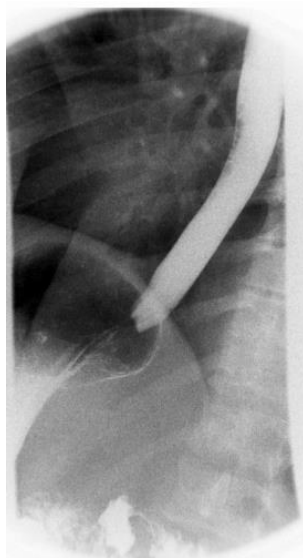
Barium bolus with Valsalva

Patient position

Keep the patient in the same RAO position.

Images and patient instructions

With the gastroesophageal junction in view, have the patient take a large swallow of thin barium then instruct the patient to Valsalva. Take fluorostore images of the gastroesophageal junction as the barium passes through it into the stomach to assess for a sliding hiatal hernia.



Collapsed mucosal view of the esophagus

Patient position

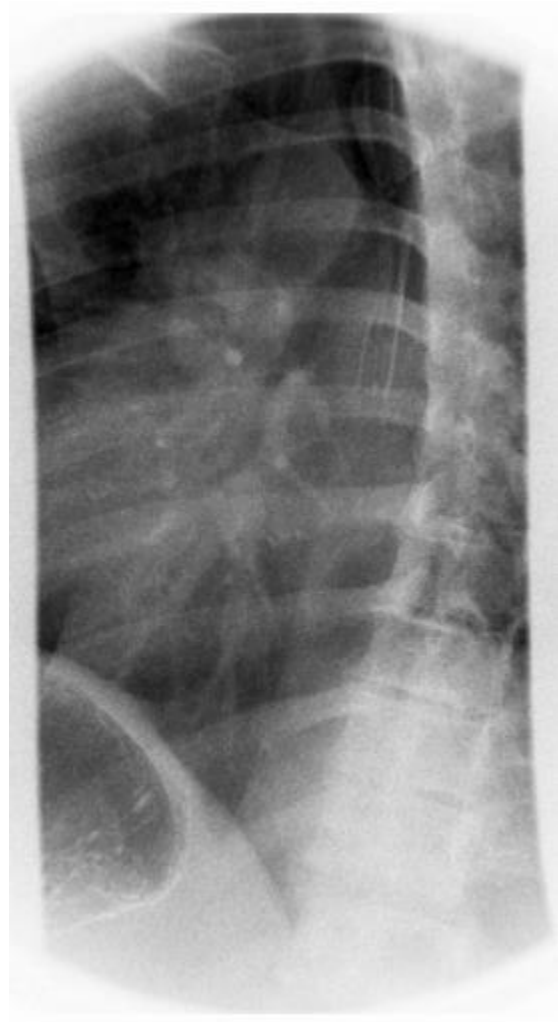The same RAO position.

Images and patient instructions

Fluorostore a collapsed mucosal view of the empty esophagus after the last swallow.

Purpose

This view allows for certain pathology to be visualized such as thickened folds due to esophagitis or filling defects such as uphill varices.



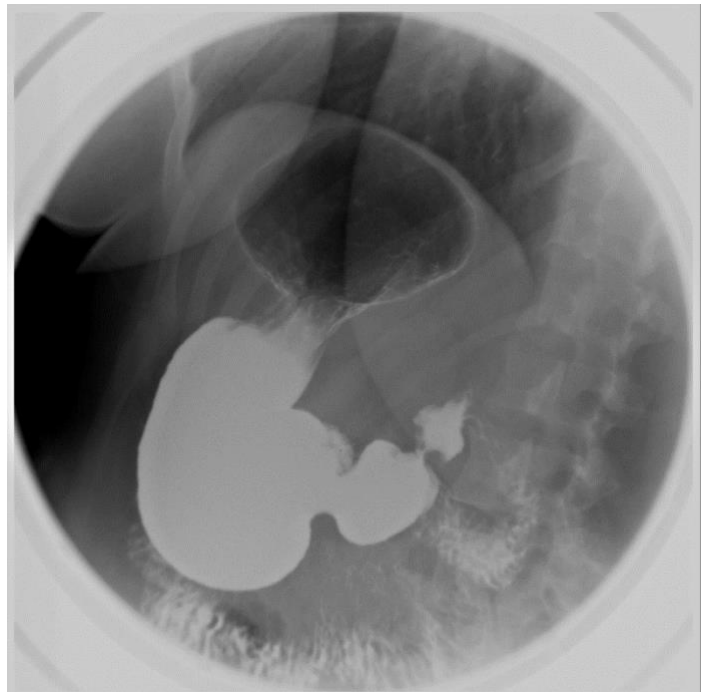
RAO view of the stomach

Patient position

The patient remains in the RAO position.

Purpose

This view allows for evaluation of pathology in a contrast-filled stomach, namely, filling defects and masses.



Evaluation of Gastroesophageal Reflux

Patient position

This step starts with the patient still in RAO and the table flat. Then the patient is instructed to roll toward their left. The patient's final position is in LAO with the table still flat.



Images and patient instructions

Instruct the patient to roll toward their left while monitoring the gastroesophageal junction under fluoroscopy. If any contrast refluxes from the stomach into the esophagus then image and document reflux of the contrast column as far cephalad as possible.

Purpose

This step of the study is to evaluate for gastroesophageal reflux. Imaging the top of the reflux column allows for comment on the degree of reflux, namely, mild, moderate, or severe.

Nota bene, barium swallow is not a sensitive or specific study for reflux.

Hypopharyngeal mucosal evaluation via PA projection

Patient position

Have the patient return to supine position. Bring fluoroscopy table back to 90 degrees. Three upright AP images are taken of the hypopharynx, followed by 3 upright lateral views of the hypopharynx.

Images and patient instructions

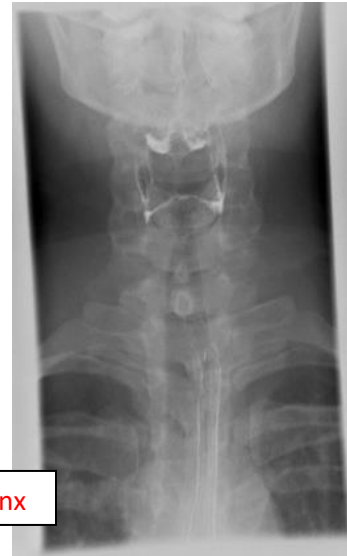Have the patient take three to five sips of thick barium prior to taking any images. Then take three exposures of the hypopharynx in the frontal projection, that is, one exposure in neutral, one during phonation, and one with puffed cheeks. Note the vocal cord movement and symmetric apposition of the vocal cords. Turn the patient into the lateral position and repeat the exposures of neutral, phonation, and puffed cheeks in this projection.

Purpose

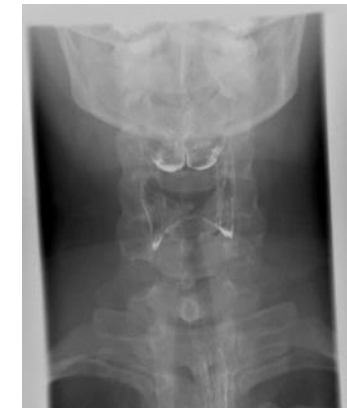These views allow for visualization of the hypopharyngeal mucosa, which may reveal a mass or mucosal asymmetry.



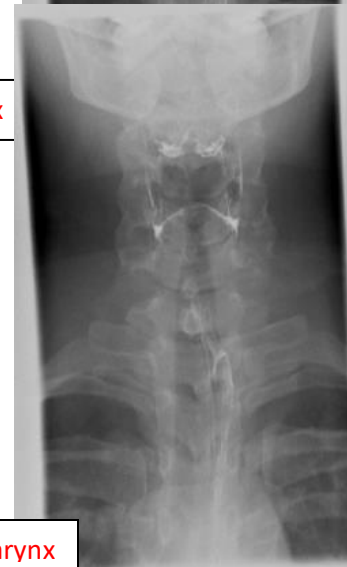Frontal neutral hypopharynx



Frontal phonation hypopharynx



Frontal puffed cheeks hypopharynx



Hypopharyngeal mucosal evaluation via the lateral projection

Patient position

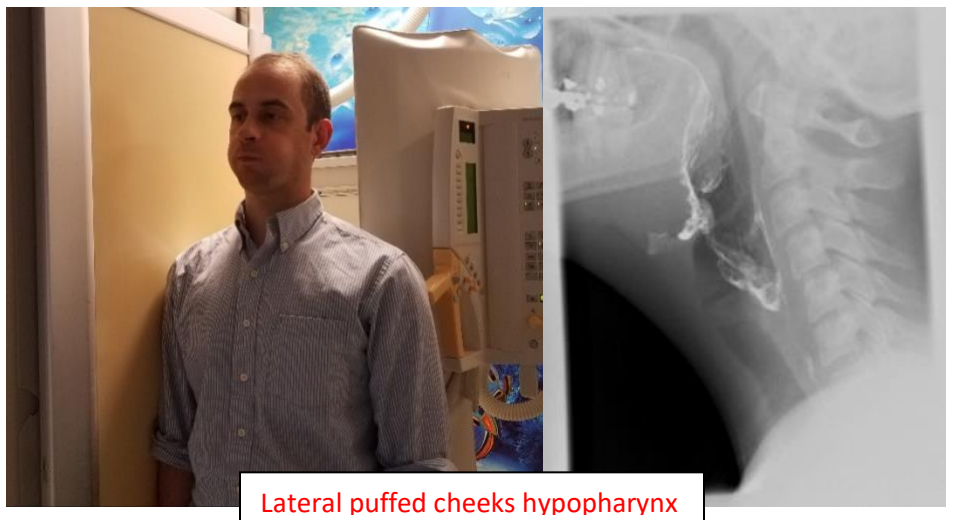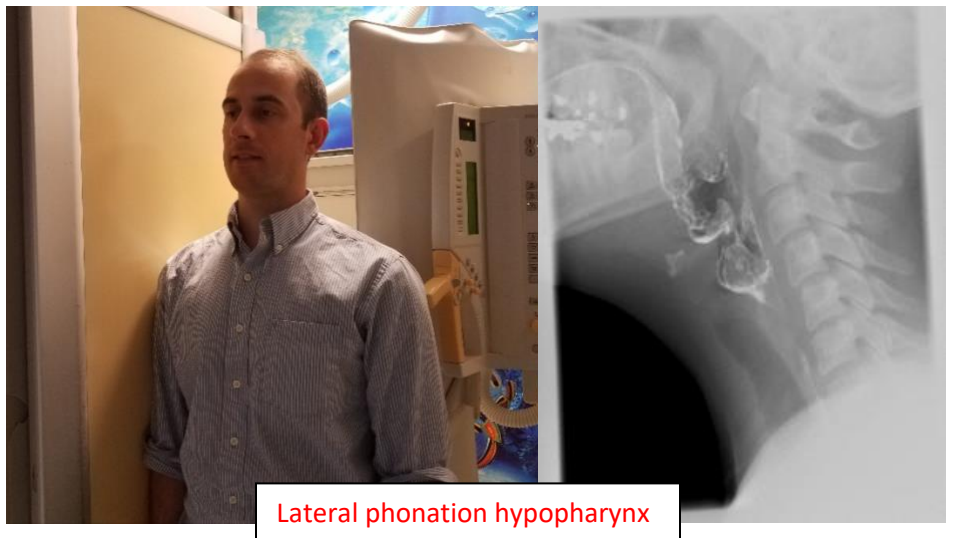
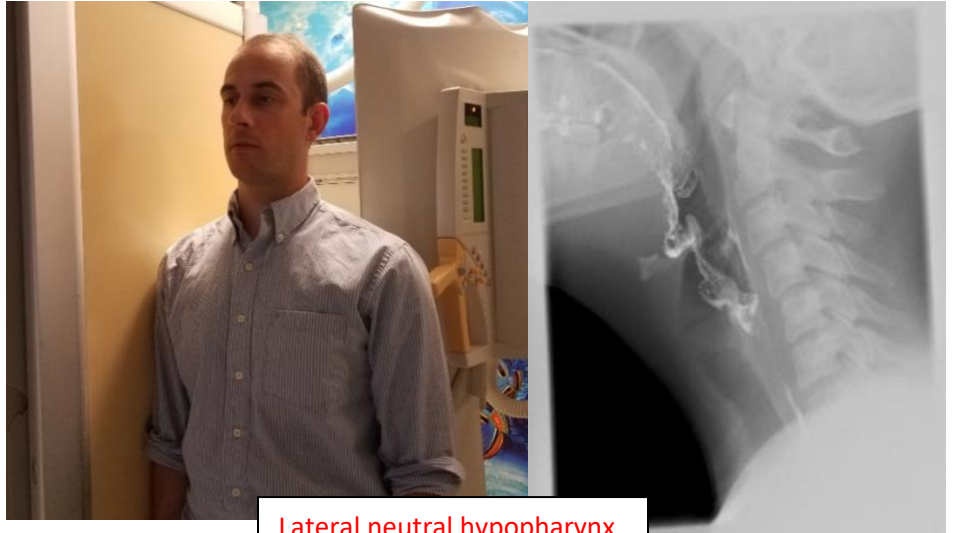Now have the patient turn and face toward your left to obtain upright lateral views of the hypopharynx.

Images and patient instructions

You may need to have the patient take additional sips of thick barium prior to taking these images if the hypopharynx is no longer coated. Once again take three exposures of the hypopharynx, one exposure in neutral, one during phonation, and one with puffed cheeks.

Purpose

These views allow for visualization of the hypopharyngeal mucosa, which may reveal a mass or mucosal asymmetry.



Dynamic swallowing at the hypopharynx

Patient position

Keep the patient upright and facing laterally as in the previous step.

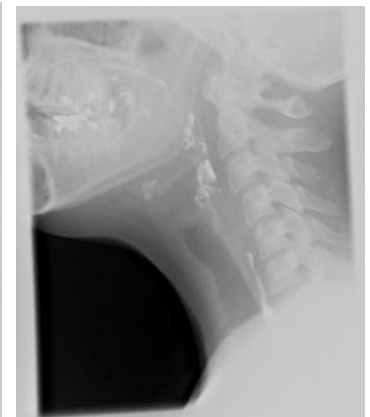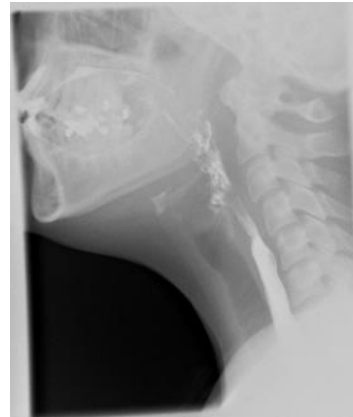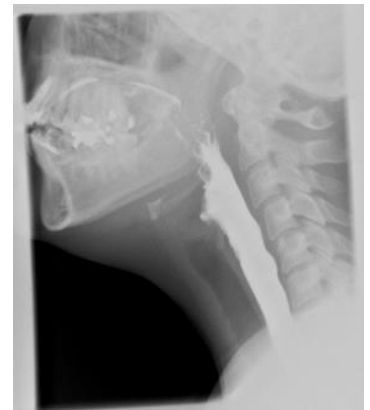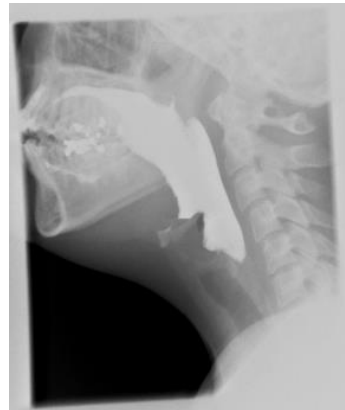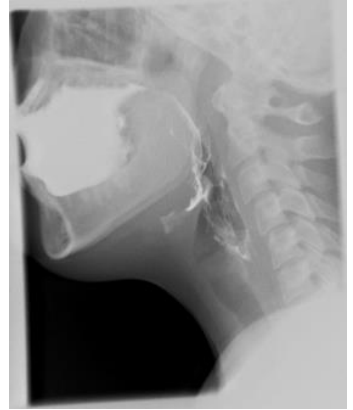Images and patient instructions

In this step you will be taking rapid sequence (4 frames per second) exposure images of the patient swallowing a bolus of thin barium.

Have the patient take a drink of thin barium and hold it in their mouth until you tell them to swallow. Tell the patient that you will count to three and then you will instruct them to swallow. Then say, "One, two, three, swallow." Start taking the exposure images once you reach two in your count so you do not miss the dynamic swallow.

Purpose

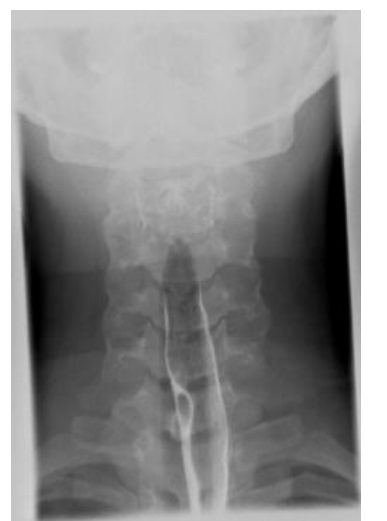
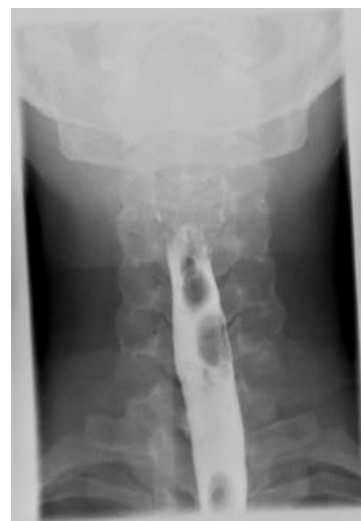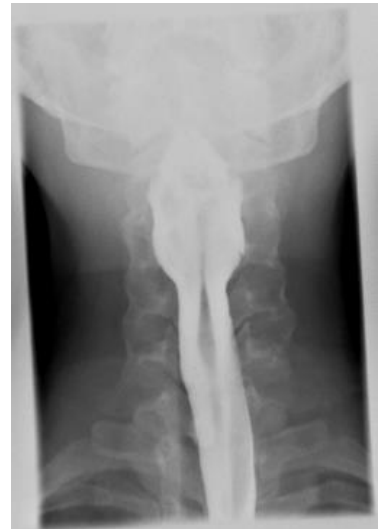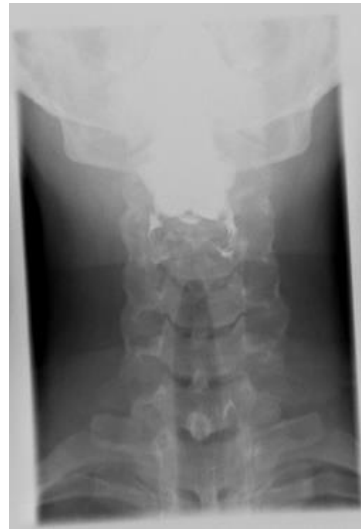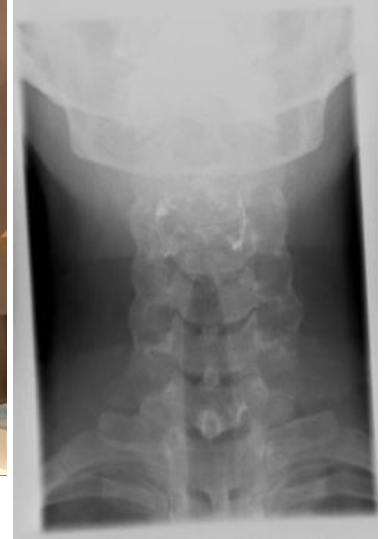The dynamic swallow allows for evaluation of gross aspiration.



Dynamic swallowing at the hypopharynx

Patient position

Now have the patient face forward and repeat the dynamic swallow.



13-mm barium tablet

Patient position

Now have the patient--still upright--turn to a left posterior oblique position so the esophagus is projected off the spine.

Images and patient instructions

Have the patient place a 13 mm barium pill in their mouth and when you are ready have them take drink water to wash it down or let patient swallow the pill as they normally do at home. Be sure to instruct the patient to return the cup to their side as soon as they are done drinking. Watch the pill as it travels down the esophagus and take fluorostore images to document its course. If the pill "hangs up" in the esophagus, take an image of it, note how long it remains there, and ask the patient if they can feel it stuck. If the pill passes easily into the stomach, and becomes obscured by barium, then take a fluorostore of the gastroesophageal junction and stomach to document the pill having passed into the stomach.

Purpose

The barium tablet may get "caught" in the hypopharynx or esophagus. The use of the barium tablet is helpful at confirming a subtle esophageal stricture or distal mucosal ring.

