

Pitfalls in the Staging Squamous Cell Carcinoma of the Hypopharynx

Amy Y. Chen, MD^a, Patricia A. Hudgins, MD^{b,*}

KEYWORDS

• Squamous cell carcinoma • Hypopharynx • Aryepiglottic fold • Larynx

KEY POINTS

- To accurately interpret pretreatment and posttreatment imaging in patients with hypopharyngeal squamous cell carcinoma (SCC), one must understand the complex anatomy of this part of the aerodigestive system.
- Common patterns of spread must be recognized.
- Pitfalls in imaging must be understood.
- This article reviews the epidemiology, anatomy, staging, treatment and pitfalls in imaging of hypopharyngeal SCC.

INTRODUCTION AND EPIDEMIOLOGY

Compared with laryngeal neoplasms, primary hypopharyngeal (HP) tumors, especially those exclusively in the HP subsites, are relatively uncommon, accounting for about 4% of all head and neck tumors. Tumors of the hypopharynx are generally advanced stage when detected, and have often already extended to the larynx or cervical esophagus. Imaging is critical in staging these advanced primary tumors for guiding treatment planning, and because locoregional control may be difficult to attain, accurate staging is especially critical.

Epidemiology is difficult to report, as laryngeal and oral-cavity squamous cell carcinoma (SCC) statistics are often lumped together with HP numbers.¹ Patients are generally older than 50 years, and men are more commonly affected than women at a rate of 3:1. Tobacco and alcohol abuse are the risk factors responsible for SCC,

statistically the most common malignancy of the hypopharynx. Alcohol potentiates the mutagenic effects of tobacco. The biology of HP SCC is interesting, and an area of ongoing study. Mutations in the *p53* tumor suppressor gene are more common in HP SCC than in other head and neck sites.^{2,3} Field carcinogenesis, the concept that carcinogens affect surrounding tissue that has yet to be transformed to tumor, also is common in HP SCC. Thus tumors may be multicentric, spread submucosally, and be very difficult to stage with imaging or endoscopy alone. At presentation tumors are often at an advanced stage, and the rich lymphatic drainage of the hypopharynx and cervical esophagus result in frequent nodal metastases. The role of human papillomavirus (HPV) in HP SCC is still being determined, but early evidence suggests HPV infection is less commonly involved in SCC of HP than are oropharyngeal subsites.^{4,5}

^a Department of Otolaryngology-Head & Neck Surgery, Emory University School of Medicine, 1364 Clifton Road, Northeast Atlanta, GA 30322, USA; ^b Department of Radiology and Imaging Sciences, Division of Neuro-radiology, Head & Neck Section, Emory University School of Medicine, BG-27, 1364 Clifton Road, Northeast, Atlanta, GA 30322, USA

* Corresponding author. Department of Head and Neck Radiology, Emory University School of Medicine, Atlanta, GA 30322.

E-mail address: phudgin@emory.edu

A rare but well-described syndrome of upper esophageal webs, iron-deficiency anemia, and postcricoid HP SCC is Plummer-Vinson syndrome. Patients are usually Caucasian women between 40 and 70 years of age. Better nutrition including iron supplementation has led to a marked decrease in this syndrome.⁶

NORMAL ANATOMY AND BOUNDARIES

To conceptualize HP anatomy, one must understand that the larynx and the hypopharynx are so interrelated that it is impossible to know the anatomy of one without understanding the other. A simplified concept is that the larynx is immediately anterior with respect to the hypopharynx, forms the anterior wall of the hypopharynx, and the larynx “bulges into” the anterior aspect of the hypopharynx. Boundaries of the hypopharynx are often described as they relate to laryngeal subsites. The craniocaudal boundaries are quite specific: the superior boundary is at a plane at the hyoid bone level, and the inferior boundary is the lower border of the cricoid cartilage (**Fig. 1**). As such, the hypopharynx is that portion of the aerodigestive tract between the oropharynx (superior) and the proximal cervical esophagus (inferior). The hyoid bone and cricoid are parts of the laryngeal skeleton. Immediately posterior and deep to the hypopharynx is the retropharyngeal space.

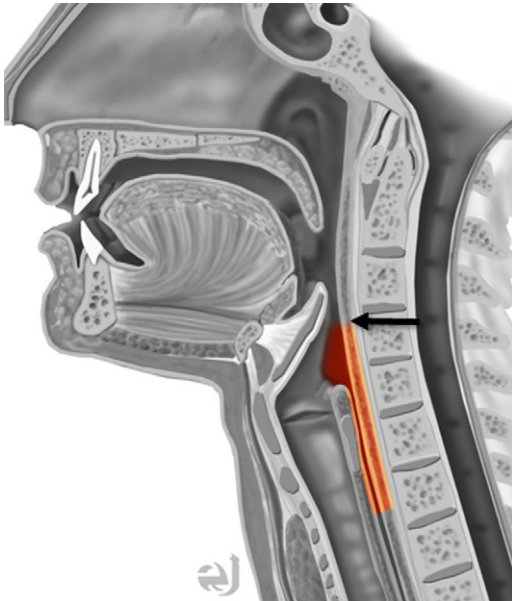


Fig. 1. Hypopharyngeal (HP) boundaries, depicted in orange. The hypopharynx extends from the posterior pharyngeal wall (arrow) at the level of the hyoid bone, to the proximal cervical esophagus. The hypopharynx is posterior to the larynx and anterior to the retropharyngeal space. (Courtesy of Eric Jablonowski.)

Another helpful way to understand HP anatomy is to know the individual subsite anatomy. The 3 HP subsites are the pyriform sinuses, lateral and posterior HP walls, and the postcricoid region. The pyriform sinuses are paired, right and left, and they extend from the pharyngoepiglottic folds of the suprahyoid epiglottis to the inferior cricoid cartilage. For each pyriform sinus, the lateral border is the lateral pharyngeal wall and the medial border is the aryepiglottic fold, specifically the HP surface of the aryepiglottic fold. The pyriform sinuses are shaped like upside down pyramids, with the apex located at the true vocal cord level. So even if they are collapsed and not filled with air, if the axial image is at the true vocal cord or arytenoid cartilage level, each pyriform sinus apex is posterior and lateral. The pyriform sinus is the most common location for HP SCC, accounting for about 60% of all cases.

The second subsite, the posterior HP wall, is the inferior extension of the posterior wall of the oropharynx. This portion extends to the postcricoid subsite of the hypopharynx.

The postcricoid portion of the hypopharynx, also the caudalmost region, is accurately named as located posterior to the cricoid cartilage, extending from the posterior wall of the hypopharynx at the cricoarytenoid joint level to the inferior cricoid cartilage and proximal cervical esophagus. On axial images, therefore, the mucosal overlying the posterior cricoid cartilage is the anterior aspect of the postcricoid HP. The posterior portion of the postcricoid HP is the cricopharyngeus muscle, which merges with the cervical esophagus. Postcricoid tumors are the least common of HP SCC.

AMERICAN JOINT COMMITTEE ON CANCER STAGING

The American Joint Committee on Cancer (AJCC) staging manual should be used as a guide, as it clearly lays out the anatomic details necessary to accurately stage tumors of the hypopharynx (**Table 1**). Like other subsites, the difference between AJCC sixth and seventh editions is primarily the division of T4 lesions into T4a or moderately advanced disease and T4b, or very advanced local disease.⁷

Staging HP tumors requires both clinical and radiologic information.⁸ Knowledge of the specific subsites and the maximum diameter of the tumor are essential (see **Table 1**). A T1 tumor involves one subsite (posterior pharyngeal wall, pyriform sinus, or postcricoid hypopharynx) or is 2 cm or smaller in greatest dimension (**Figs. 2-4**). A T2 tumor invades another HP subsite or an adjacent site (for example, a laryngeal subsite), or is greater than

Table 1
AJCC 7: hypopharynx

| Primary Tumor (T) | |
|---|--|
| TX | Primary tumor cannot be assessed |
| T0 | No evidence of primary tumor |
| Tis | Carcinoma in situ |
| T1 | Tumor limited to one subsite of hypopharynx and/or 2 cm or less in greatest dimension |
| T2 | Tumor invades more than one subsite of hypopharynx or an adjacent site, or measures more than 2 cm but not more than 4 cm in greatest dimension without fixation of hemilarynx |
| T3 | Tumor more than 4 cm in greatest dimension or with fixation of hemilarynx or extension to esophagus |
| T4a | Moderately advanced local disease Tumor invades thyroid/cricoid cartilage, hyoid bone, thyroid gland or central compartment soft tissue (includes prelaryngeal strap muscles and subcutaneous fat) |
| T4b | Very advanced local disease Tumor invades prevertebral fascia, encases carotid artery, or involves mediastinal structures |
| Regional Lymph Nodes (N) | |
| NX | Regional lymph nodes cannot be assessed |
| N0 | No regional lymph node metastasis |
| N1 | Metastasis in a single ipsilateral lymph node, 3 cm or less in greatest dimension |
| N2 | Metastasis in a single ipsilateral lymph node, more than 3 cm but not more than 6 cm in greatest dimension; or in multiple ipsilateral lymph nodes, none more than 6 cm in greatest dimension; or in bilateral or contralateral lymph nodes, none more than 6 cm in greatest dimension |
| N2a | Metastasis in single ipsilateral lymph node more than 3 cm but not more than 6 cm in greatest dimension |
| N2b | Metastasis in multiple ipsilateral lymph nodes, none more than 6 cm in greatest dimension |
| N2c | Metastasis in bilateral or contralateral lymph nodes, none more than 6 cm in greatest dimension |
| N3 | Metastasis in a lymph node more than 6 cm in greatest dimension |
| Note: Metastases at level VII are considered regional lymph node metastases | |
| Distant Metastasis (M) | |
| M0 | No distant metastasis |
| M1 | Distant metastasis |

From Edge SB, Byrd DR, Compton CC, et al. Editorial Board. AJCC Cancer staging manual. 7th edition. Chicago: Springer; 2010. p. 41–56; with permission.

2 cm but less than 4 cm (Fig. 5). By definition, there is no fixation of the hemilarynx for a T1 or T2 tumor.

Fixation of the hemilarynx is defined as impaired motion of the true vocal cord. For HP SCC, this can be a result of tumor invading the larynx at the cricoarytenoid joint or the intrinsic laryngeal muscles. Thus, the vocal cord paralysis is from tumor extending from the hypopharynx into the larynx. Other mechanisms for vocal cord dysfunction from HP SCC are invasion of the recurrent laryngeal nerve or direct invasion of the posterior cricoarytenoid muscle.⁹ Tumor on the medial pyriform sinus wall often involves the

hemilarynx, usually at the insertion of the aryepiglottic fold to the arytenoid cartilage (Fig. 6). Therefore, vocal cord motion is often impaired when the tumor is in the medial pyriform sinus. Bulky pyriform sinus carcinomas may cause hemilarynx fixation owing to a weight effect. The tumor may cause arytenoid cartilage immobility at the top of the cartilage, but the base is still mobile. The arytenoid appears immobile to the endoscopist, but there is really no histologic tumor invasion of the arytenoid cartilage. Vocal cord, and not just arytenoid cartilage mobility, should be reported by the endoscopist.⁹

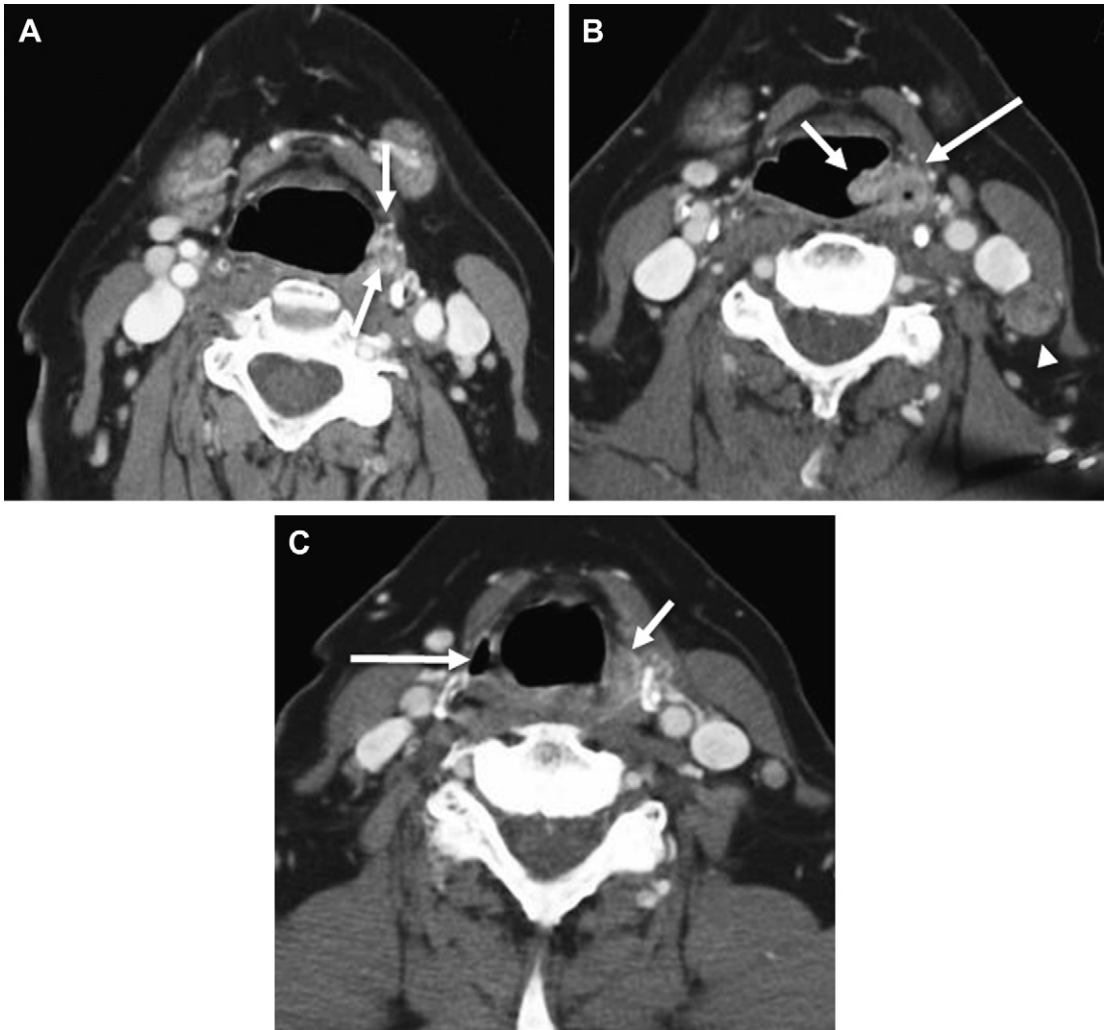


Fig. 2. T1 pyriform sinus SCC on left, missed on initial image interpretation. (A) Axial contrast-enhanced computed tomography (CECT) shows left SCC (<2 cm) at the superior pyriform sinus (arrows). This study was interpreted as “Normal neck CT. No tumor.” (B) Axial CECT obtained 16 months after A shows increase in size of the mass filling the pyriform sinus, and involvement of the laryngeal surface of the left aryepiglottic fold (AEF) (arrow). Note extension to the posterior paraglottic fat (long arrow). Posterior left level III node is now larger with unequivocal necrosis (arrowhead). (C) Axial CECT at low pyriform sinus level shows normal right air-filled sinus (long arrow). Note tumor in left pyriform sinus (short arrow). On subsequent images tumor was present in the apex of the sinus, a finding that was not present on the initial study. Pyriform apex involvement carries a poor prognosis when compared with tumor only at the superior aspect of the pyriform sinus.

Staging a tumor as T3 or T4 requires knowing whether the true vocal cord is mobile. Because this is best determined clinically by direct visualization of the larynx, it is not possible to accurately stage an HP tumor with imaging alone. In their practice, the authors usually describe the extent and size of an HP tumor, but do not always report a T stage because knowledge of the cord mobility may not be available at the time of image interpretation.

Three criteria define a T3 HP tumor: greater than 4 cm, fixation of the hemilarynx, or extension to the

cervical esophagus (Fig. 7). By definition, if the hemilarynx is “fixed,” the tumor has extended from the boundaries of the hypopharynx and involves part of the larynx or the recurrent laryngeal nerve.

T4 tumor is subdivided, as with all other subsites, into T4a or moderately advanced local disease and T4b, very advanced local disease. Criteria for T4a tumor involves invasion of the thyroid or cricoid cartilage, the hyoid bone, thyroid gland, or central compartment including the infrahyoid prelaryngeal strap muscles and subcutaneous fat. T4b tumor

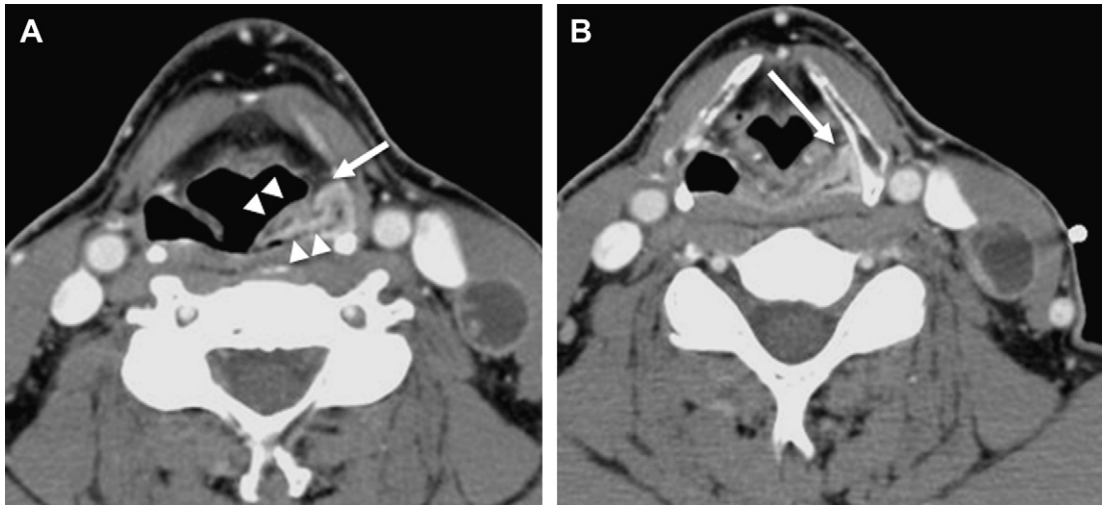


Fig. 3. T1 left pyriform sinus SCC. (A) Axial CECT image at superior AEF shows tumor encircling pyriform sinus (*arrowheads*), with extension into posterior paraglottic fat (*arrow*). (B) Image is slightly lower, but tumor is still present in sinus and posterior paraglottic fat (*long arrow*). The laryngeal surface of the AEF is normal and symmetric with right side.

invades the prevertebral fascia, extending through the retropharyngeal space, encases the common carotid artery, or extends inferiorly to the mediastinum.

The hypopharynx has a rich lymphatic drainage system, and nodal metastases are common. Neck disease is staged as all other head and neck subsites: N1 through N3. The primary nodal stations are high, mid, and low jugular chains, or levels II, III, and IV. Tumors on the posterior wall of the hypopharynx may metastasize to the retropharyngeal nodes. Bilateral nodal disease, or

N2c, increases with increasing tumor stage. Distant metastasis is either M0 (no distant disease) or M1 (definite distant disease). Lungs are the most common site for distant disease, and mediastinal nodal metastases are considered distant disease.⁷

Because staging HP SCC requires imaging and endoscopic information, a multispecialty tumor board is ideally the best way to stage and recommend treatment for the patient with HP SCC.

IMAGING PROTOCOLS

No randomized prospective trial has been done to compare contrast-enhanced computed tomography (CECT), magnetic resonance imaging (MRI), positron emission tomography/CT (PET-CT), or PET-CECT for HP SCC. Early evidence suggests that PET-CT was more sensitive than 3.0-T whole-body MRI for detecting distant metastases and second primary cancers.¹⁰ However, there is no current consensus as to which modality is best for staging HP SCC, but the argument for PET-CECT is strong. In the authors' practice, all patients with HP SCC undergo a staging combined PET-CECT (see **Fig. 7**). The advantages of this combined anatomic and metabolic study are accurate staging of the primary tumor via CECT, while PET is superior for detecting nodal disease, distant metastases, and second primary tumors, which are common in HP SCC. The authors use at least 100 mL nonionic iodinated contrast, with variable injection protocols but at least a 75-second delay before the CT is performed. This delay makes both mucosal and vascular enhancement optimal, and

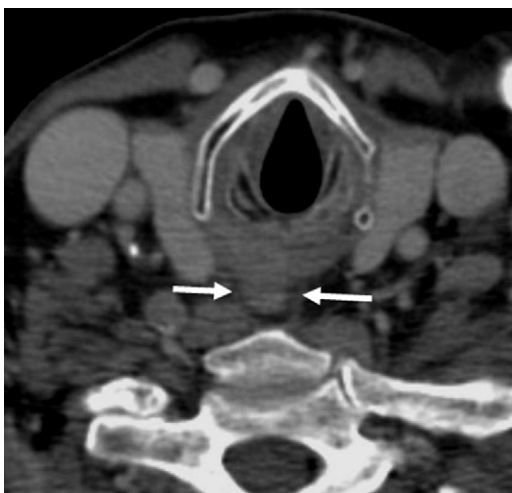

Fig. 4. T1 postcricoid HP SCC. Axial CECT shows a small mass (*arrows*) of the postcricoid hypopharynx. There is a crescent of normal fat around the posterior portion of the tumor, suggesting no invasion of retropharyngeal space or prevertebral muscles.

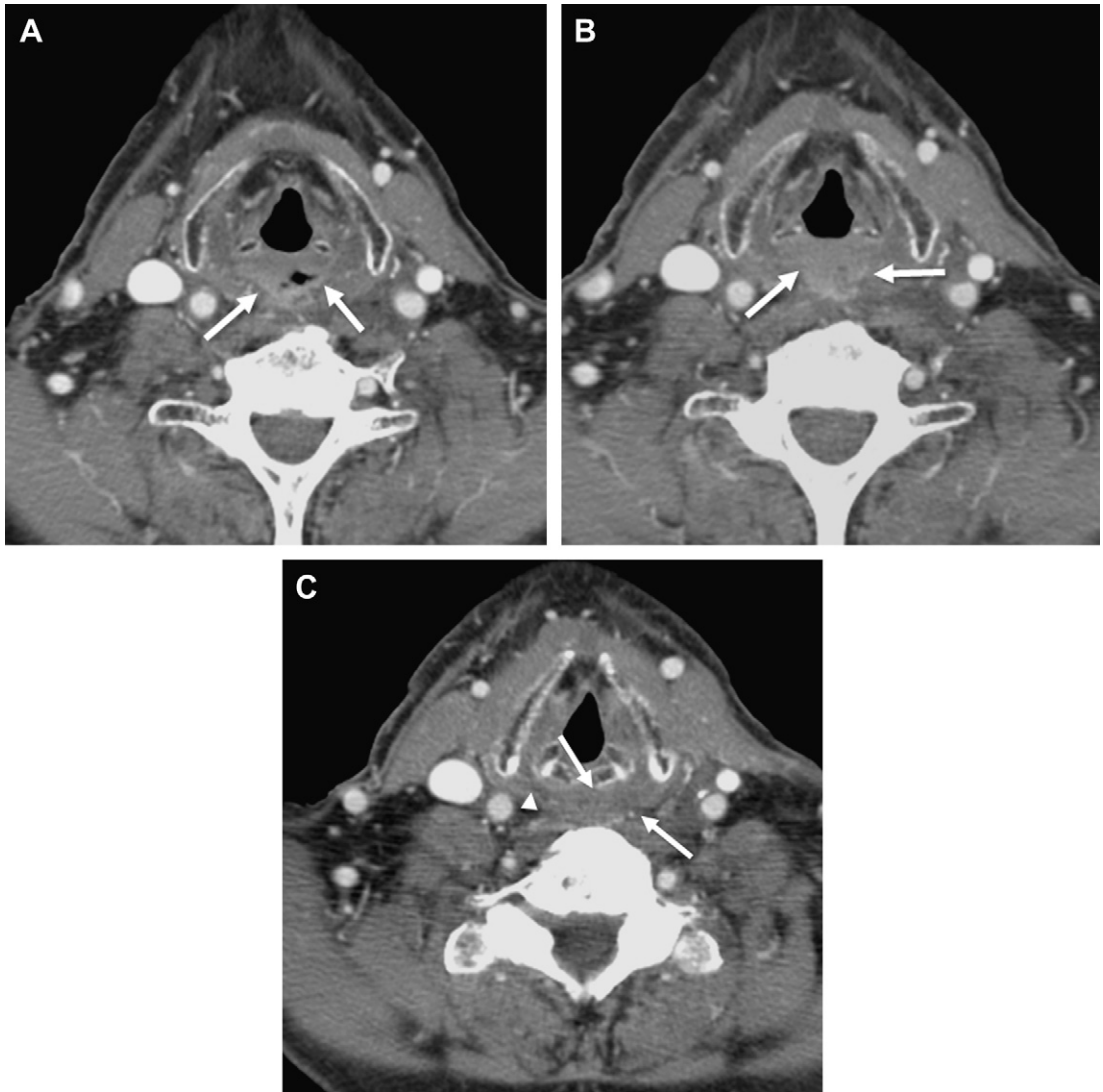


Fig. 5. T2 posterior HP wall SCC. At endoscopy the larynx was normal. Tumor is staged as T2, as 2 HP subsites are involved. (A) CECT shows a peripherally enhancing mass (*arrows*) on the posterior wall, with air in a central ulceration. (B) CECT obtained 3 mm inferior to A shows anterior displacement of the larynx by the HP mass (*arrows*). (C) CECT image at postcricoid hypopharynx shows subtle but definite asymmetric fullness on left (*arrows*). Note normal intramural fat planes (*arrowhead*) on right.

also is long enough to detect necrosis. Detailed technical parameters for the PET portion are beyond the scope of this article, but 15 to 18 mCi of ^{18}F -fluorodeoxyglucose is administered intravenously and then whole-body imaging is performed 60 minutes later. Standardized uptake values (SUV) of the tumor and nodes are measured and reported. The staging PET-CECT provides a baseline for comparison to a posttreatment PET-CECT at 8 to 10 weeks after therapy.

The CECT is interpreted by the Head and Neck Imaging section, the PET by the Nuclear Medicine section, and 2 separate dictations are generated. If

the interpretations are discordant, a consensus discussion comes up with a recommendation on how to resolve the issue in question.

MRI is rarely requested, and is reserved for problem solving. The most common indications for MRI are questionable cartilage penetration, confirming extralaryngeal or extrapharyngeal tumor extension, and to determine if the prevertebral fascia is clear of tumor. The authors' MRI protocol includes imaging through the area of question only, as the neck has already been staged with PET-CECT. Standard neck phased-array surface coils are used. T1-weighted images in all 3 planes are always

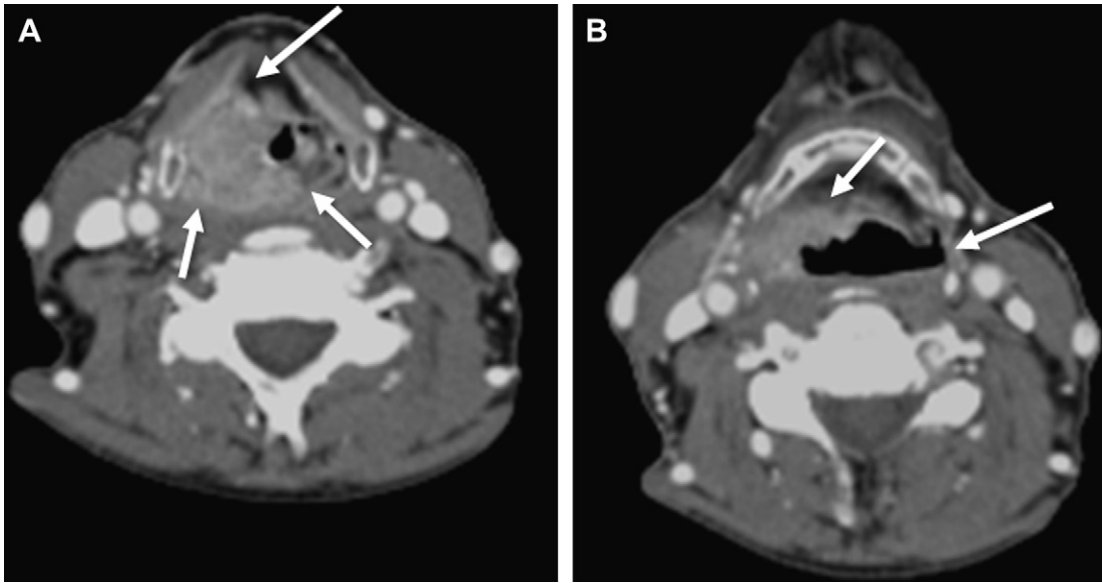


Fig. 6. T3 laryngohypopharyngeal SCC based on tumor (>4 cm) and fixation of right hemilarynx. (A) Large bulky right laryngohypopharyngeal SCC involves right AEF, pyriform sinus, and posterior laryngeal and HP walls (*short arrows*). Note tumor extending into right paraglottic fat (*long arrow*). (B) At hyoid bone level, there is invasion of right pre-epiglottic fat (*short arrow*). Note normal left lateral HP wall (*long arrow*), and compare with right lateral wall, which is filled with tumor.

performed, followed by T2-weighted images with fat saturation, in the axial and sagittal planes. After gadolinium is injected, the 3 T1-weighted sequences are repeated, and at least 2 have fat saturation.

On staging workup, indeterminate lymph nodes are described and are generally treated with neck

dissection, or the chain is included in the neck radiation field. Ultrasound-guided fine-needle aspiration (UG-FNA) is used frequently to resolve discordant CECT and PET findings. Most aspirations, however, are for indeterminate nodal disease after treatment, and rarely is pretreatment nodal sampling performed.

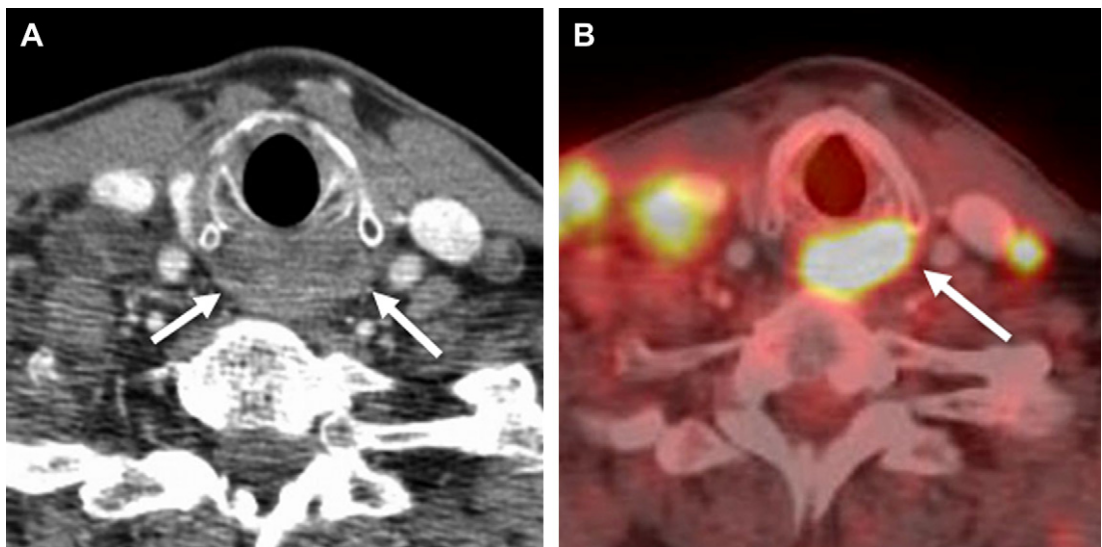


Fig. 7. Axial CECT performed with PET shows value of PET for HP tumor staging, especially at cervical esophagus. (A) Postcricoid hypopharynx (*arrows*) is greater than 10 mm anteroposterior, and there is anterior displacement of larynx by the mass. Bilateral metastatic adenopathy is consistent with N2c disease. (B) Fused positron emission tomography (PET)-CECT portion of the study at same level confirms increased metabolic activity in mass (*arrow*).

PITFALLS

Most pitfalls in staging HP SCC can be overcome by knowing the anatomy of the hypopharynx and surrounding structures, high-quality imaging with either CECT, PET-CECT, or MRI, and close communication with other members of the Head and Neck Tumor Board (**Table 2**). Patient care is improved when imaging interpretation is not done in a vacuum without clinical information, but rather when closely coordinated with the head and neck surgeon or endoscopist.

Hypopharyngeal tumor commonly extends in a submucosal pattern, and this behavior accounts for one of the most important staging pitfalls.^{11–13} One histopathologic study showed 60% incidence of submucosal extension.¹³ Imaging, therefore, is extremely important as the endoscopist may only see the proverbial tip of the iceberg. However, even metabolic imaging, like PET, may inaccurately stage HP submucosal spread.

Each HP subsite has its own difficulties or pitfalls with imaging and staging, and by knowing the subsites the radiologist can anticipate patterns of disease.

Extension and complications of pyriform sinus SCC, the most common location for HP SCC, depends on location of the tumor: medial wall versus lateral wall, and apex versus high pyriform sinus tumor. Tumors on the medial wall, or the HP surface of the aryepiglottic fold, may extend caudally to the arytenoid cartilage and cricoarytenoid joint. Tumors arising on the lateral pyriform

sinus wall often spread anteriorly and laterally to involve the laryngeal paraglottic fat and the posterior thyroid cartilage (see **Fig. 6**). Tumor in the pyriform sinus apex may spread anteriorly between the thyroid and arytenoid cartilages. It is essential to describe extension across the midline, as this has significant surgical implications. More pharyngeal mucosa will need to be resected, and thus free-flap reconstruction will be necessary.

Tumors of the second subsite, the posterior HP wall, are often large at presentation, as symptoms are similar to those of gastroesophageal reflux and there is a delay in diagnosis. Posterior HP wall tumors extend superiorly to involve the posterior oropharyngeal wall and base of the tongue (**Fig. 8**). When this occurs, the tumor has by definition involved a second site: the oropharynx. Inferior extension from the postcricoid hypopharynx to the cervical esophagus is another pattern of spread that by definition involves another subsite: the esophagus. Likewise, postcricoid HP extension from a cervical esophageal SCC is, in the authors' experience, often overlooked on staging imaging (**Fig. 9**). It is critical to identify posterior extension into the retropharyngeal and prevertebral spaces, as in the AJCC seventh edition invasion of prevertebral fascia is T4b stage. Patients may present with the neck in a fixed position, and a barium esophagogram shows lack of normal motion during the swallowing phase. MRI has been shown to have excellent negative predictive value (**Fig. 10**). If the retropharyngeal fat between the tumor and the prevertebral compartment is

Table 2
Pitfalls in staging of HP SCC

| Pitfall | Advice |
|---|---|
| HP SCC frequently spread via submucosal route | Careful contrast technique on CECT MRI may be more accurate PET combined with CECT or MRI probably best technique |
| Medial pyriform sinus wall tumor | Assess for laryngeal extension to arytenoid cartilage and cricoarytenoid joint |
| Lateral pyriform sinus wall tumor | Assess for supraglottic laryngeal extension to paraglottic fat or thyroid cartilage |
| Pyriform sinus apex tumor | Assess for extension through thyroarytenoid space |
| Posterior wall tumor | Assess posterior wall at oropharyngeal level, about level of epiglottis |
| Missing esophageal extension | Assess verge and proximal cervical esophagus PET-CECT may be best technique |
| Upstaging to T4b | Prevertebral fascia invasion can only be determined directly during surgery |
| PET-CT too early after surgery or biopsy | Wait at least 8 wks |

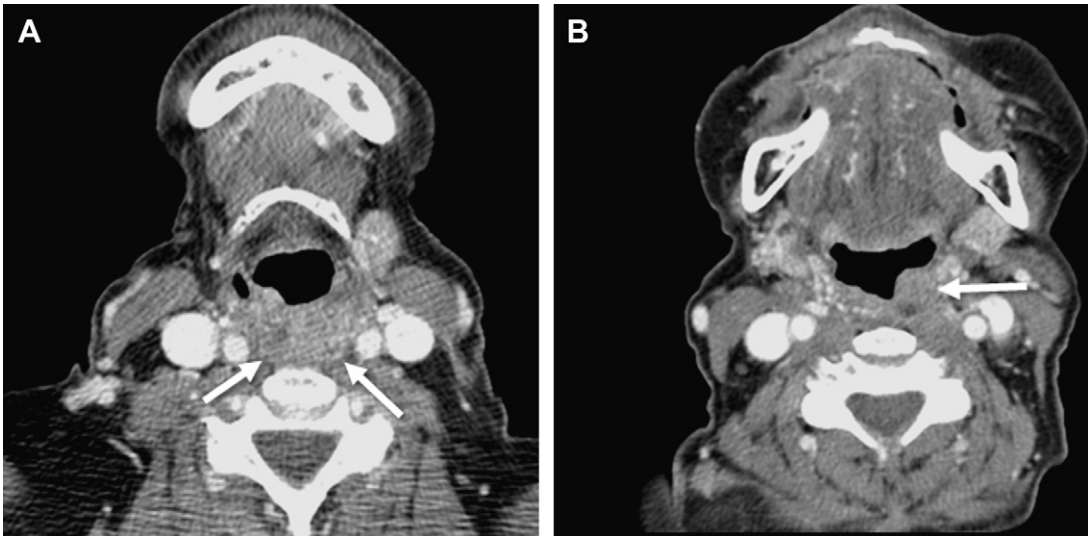


Fig. 8. Posterior HP wall tumor with superior extension to posterior oropharyngeal wall. (A) Axial CECT shows symmetric fullness of posterior HP wall (arrows). Image is noisy, as patient was scanned with arms over head. (B) Axial CECT at oropharyngeal level, above the epiglottis. Note asymmetric mass on left lateral posterior wall (arrow). Although this did not change the final stage, it affected treatment, as the patient was deemed unresectable and was treated with chemoradiation.

preserved on T1-weighted sagittal and axial images, there is no invasion of the prevertebral space (**Fig. 11**).¹⁴ However, if the fat signal is interrupted the converse is not true.¹⁵ The only reliable

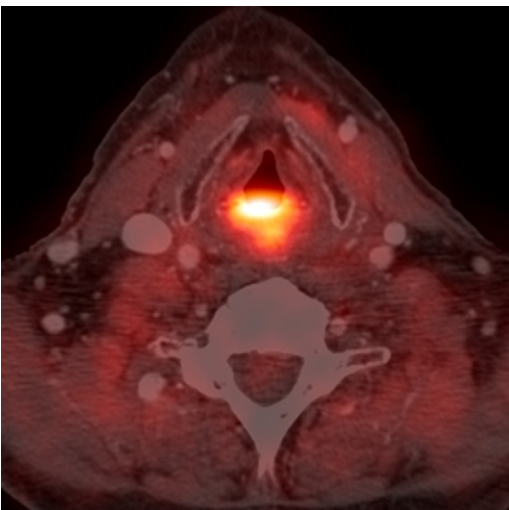


Fig. 9. Fused PET-CECT image in a patient who “recurred” after radiation for cervical esophageal SCC. Within 1 month following treatment for cervical esophageal SCC, the patient underwent PET-CECT because of persistent dysphagia and pain. A pretreatment PET had not been performed. The initial tumor was probably understaged and likely already involved the postcricoid hypopharynx. In the authors’ experience, understaging HP SCC at the proximal cervical esophagus is a common pitfall.

way to determine prevertebral compartment tumor extension, based on personal experience and the literature, is direct surgical inspection (**Fig. 12**).

Tumors in the third subsite, the postcricoid HP, are relatively uncommon, and almost always locally invasive at the time of diagnosis. With high-resolution cross-sectional imaging the anatomy at the postcricoid HP can clearly be delineated. Intramural fat planes are commonly

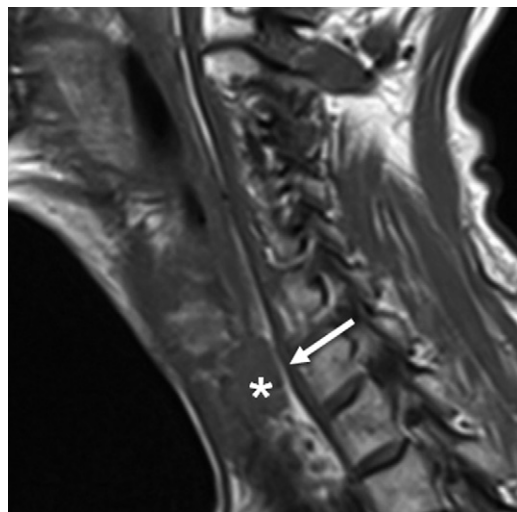


Fig. 10. Sagittal T1-weighted image in a patient with a small postcricoid SCC of hypopharynx (asterisk). Preservation of high signal intensity retropharyngeal fat (arrow) is strong evidence that there is no invasion.

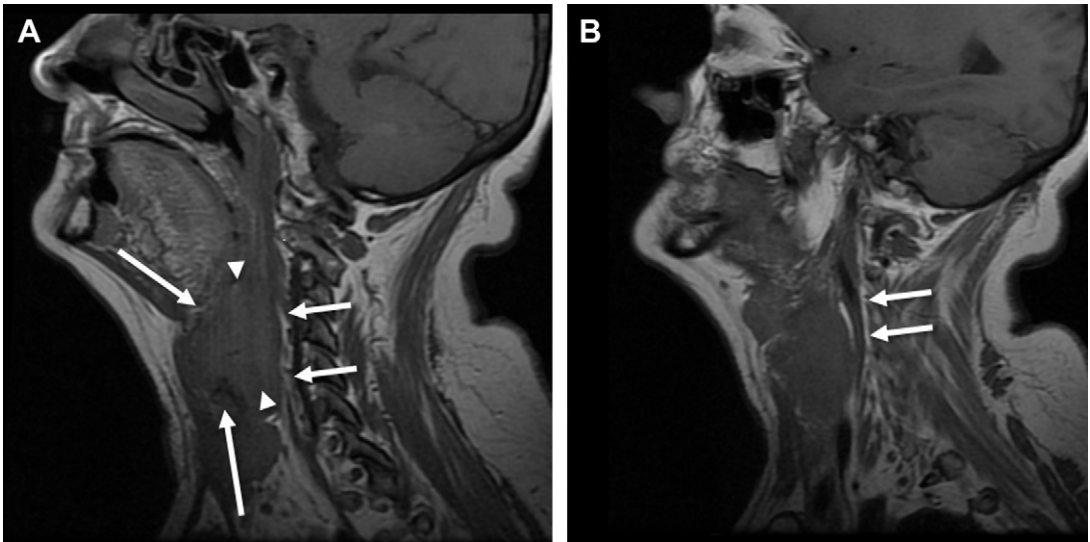


Fig. 11. Parasagittal (A) and further lateral parasagittal (B) T1-weighted MR images of bulky laryngohypopharyngeal tumor. Note bulky tumor involving both larynx (*long arrows*) and hypopharynx (*arrowheads*). Fat stripe is preserved (*short arrows*), implying no involvement of the retropharynx or prevertebral fascia.

present in the HP walls, and loss of the planes is seen with tumor (see **Fig. 5C**). The anteroposterior (AP) diameter of the postcricoid region is normally less than 10 mm, and if greater than 10 mm, in a patient with HP SCC, should be considered abnormal.¹⁶ In a patient with cervical esophageal

tumor, a postcricoid AP diameter greater than 10 mm implies extension of the tumor to the hypopharynx. Variability in the width or transverse dimension on the postcricoid HP is broad, so that this measurement is not reliable for staging. The proximal cervical esophagus AP diameter

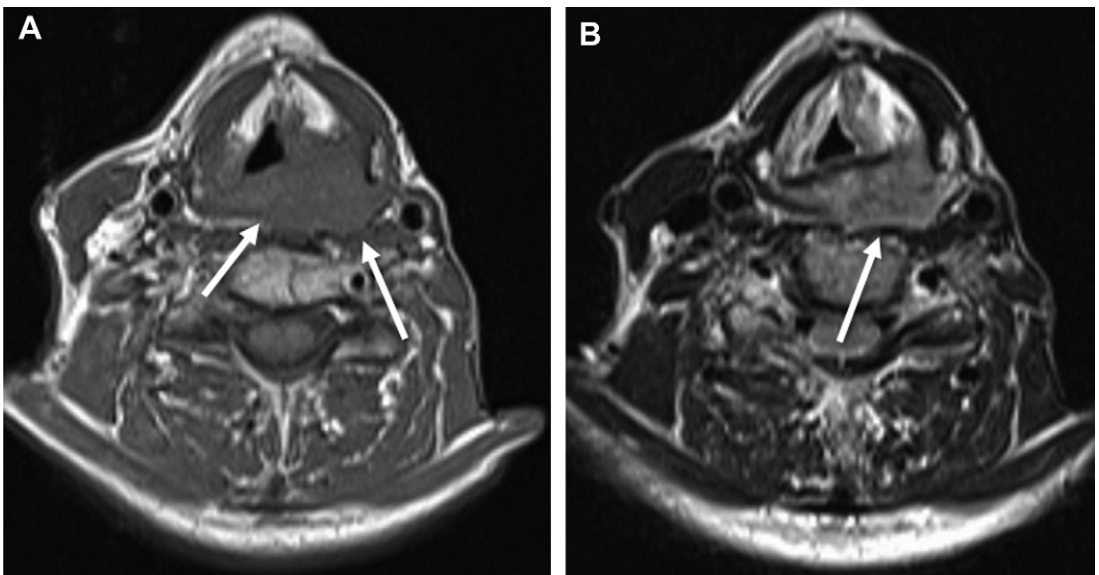


Fig. 12. Laryngohypopharyngeal SCC with preoperative imaging suggesting prevertebral fascia invasion. (A) T1-weighted axial image shows apparent obliteration of fat in the retropharyngeal space (*arrows*). (B) T2-weighted axial image at the same level shows loss of fat in retropharyngeal space but smooth interface between posterior aspect of tumor and prevertebral muscles (*arrow*). At surgery the fascia over prevertebral muscles was intact and the tumor was completely resected.

should be no greater than 16 mm. Of course, these measurements should not be used in a patient who has undergone radiation or in the setting of gastroesophageal reflux disease, as mucosal edema will affect these measurements.

Postcricoid tumors can cause vocal cord dysfunction by recurrent laryngeal nerve spread or direct anterior extension to the posterior larynx. Inferior extension through the cricopharyngeus muscle into the proximal cervical esophagus has enormous treatment implications.

The extra-HP surrounding structures most commonly invaded by HP SCC are the posterior oropharyngeal wall (superior), the larynx (anterior), and the proximal cervical esophagus (inferior). Posterior extension through the retropharyngeal space occurs less commonly and is only accurately detected at surgery, but is important because the patient is then truly nonoperable.

TREATMENT

No randomized trial comparing surgical with nonsurgical management of SCC of the hypopharynx has been reported, and treatment data have been extrapolated from studies of laryngeal SCC. Treatment of HP SCC has evolved significantly in the past decade. The goal of any treatment plan, whether surgical or chemoradiation

(CRT), is the same: local control of disease while preserving, maintaining, or improving voice quality and swallowing, and avoiding aspiration and airway compromise. Treatment considerations must include subsite, stage, presence of distant metastases, laryngohypopharyngeal function at presentation, status of laryngeal cartilage, and patient preference (Fig. 13). Patient preference is, of course, always a consideration, but especially in laryngeal and HP SCC. A review of treatment in the 1980s and 1990s showed that surgery was the primary treatment 42% of the time, and radiotherapy or CRT without surgery was used 41% of the time, with relatively similar survival outcomes.¹⁷ Radiation therapy and surgery have similar outcomes for early-stage disease.¹⁸

Two arguments are used to advocate for CRT or radiation alone. First, there is high propensity for HP SCC to spread submucosally, with the likelihood of positive surgical margins. Second, even with a clinical and radiologic N0 neck, the chance of micrometastases has been reported to be as high as 40%.¹⁹ In general, T1 or T2 disease is treated much like supraglottic laryngeal carcinoma, and treatment depends on function. The 20% of patients who present with T1 or T2 disease can be treated with surgery, radiation, chemotherapy, or CRT. The role of transoral endoscopic

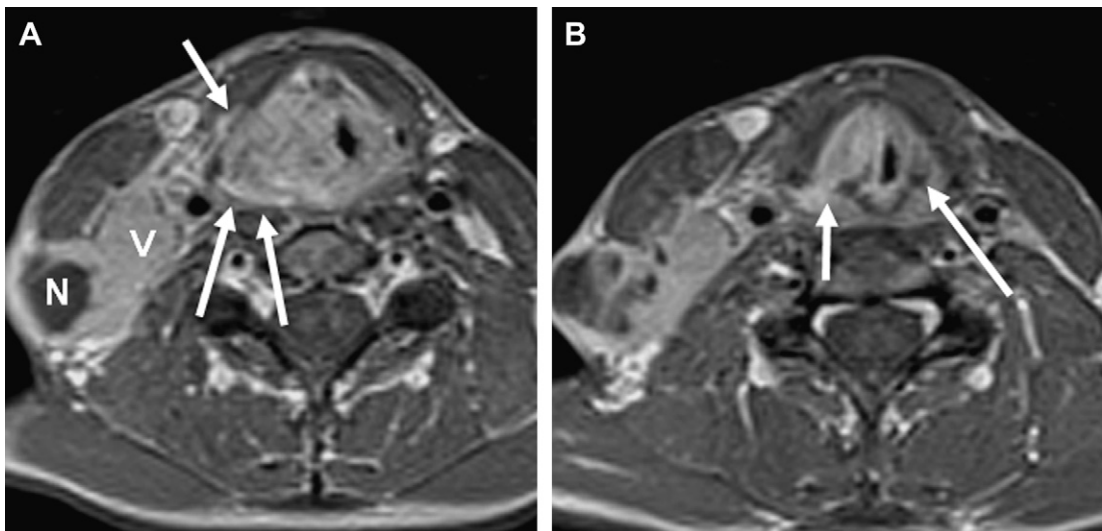


Fig. 13. Large laryngohypopharyngeal SCC with extralaryngeal spread. The patient ultimately underwent laryngohypopharyngectomy and radical neck dissection. (A) Postcontrast T1-weighted axial image shows enhancing tumor, with direct extension through the right thyroid cartilage (*short arrow*) into infrahyoid strap muscle. Note smooth interface (*long arrows*) with prevertebral fascia, which was uninvolved at surgery. Nodal disease fills the right jugular vein (V). Necrotic nodal mass (N) is present immediately beneath the skin. (B) Postcontrast T1-weighted axial image at glottic level shows extralaryngeal extension through right thyroarytenoid space (*short arrow*). Note normal left space (*long arrow*) between posterior thyroid ala and arytenoid cartilage. The tumor enhances robustly, but there is no enhancement in the cartilage, suggesting it is not invaded at this location.

resection (TORS) is still unknown, but may be a significant addition to the surgical armamentarium.²⁰ If there is significant laryngeal or HP dysfunction, radical resection or laryngohypopharyngectomy with reconstruction is chosen. In general, partial hypopharyngectomy is reconstructed with a myocutaneous flap, whereas a free jejunal flap is used to reconstruct a total or circumferential hypopharyngectomy. Posterior pharyngeal wall tumors are almost always treated nonsurgically with CRT, as the oropharyngeal wall is often involved as well (see **Fig. 8**).

SURVEILLANCE

Well-designed prospective studies determining sensitivity and specificity of different imaging modalities for assessing treatment response in HP SCC are lacking. Most available studies are retrospective and are not sufficiently careful with uniform adherence to imaging technique or protocol. However, relapse rate in advanced SCC of the head and neck, including the hypopharynx, is more than 50%.²¹ In the authors' practice, the initial study posttreatment is PET-CECT. Because of the chance for false-positive findings, this is generally obtained 8 to 10 weeks following surgery or at the end of CRT. Mucosal edema after CRT can be particularly difficult to differentiate from residual disease. Thickened aryepiglottic folds with collapse of the entire pyriform sinus from the superior inlet to the apex are an expected and universal finding following CRT. The posterior pharyngeal wall and postcricoid hypopharynx also have a boggy edematous appearance, making submucosal residual disease especially difficult to identify with cross-sectional imaging. Enhancement on CECT helps differentiate edema from tumor, as tumor tends to enhance in a homogeneous pattern, and only the mucosal surface should enhance with edema. However, current accepted chemotherapeutic regimens may include a monoclonal antibody such as cetuximab, an epidermal growth factor receptor inhibitor, or bevacizumab, a vascular endothelial growth factor A inhibitor, and both agents directly or indirectly affect tumor angiogenesis, potentially changing contrast enhancement appearances on CECT. PET is very helpful in this regard. Posttreatment mucosal edema generally has a lower SUV than residual tumor.

As with pretreatment PET-CECT, the 2 components of the examination are interpreted separately, then in a consensus fashion. When there are discordant findings in the primary tumor bed or neck, for example, CECT shows a large necrotic node but PET shows no increased metabolic

activity in the node, UG-FNA or neck dissection is performed. No findings should be interpreted in isolation, however. Symptoms such as ear pain or dysphagia strongly suggest persistent or residual disease. Posttreatment image interpretation should not be performed by the radiologist without sufficient history, especially as it relates to treatment.

FUTURE DIRECTIONS AND ADVANCED IMAGING

There are many unanswered questions regarding the staging of HP SCC, surveillance imaging, and the role of the various imaging techniques. Prospective comparison of both staging and surveillance modalities must be performed to determine the most accurate modalities. Because treatment is often nonsurgical, and it is therefore impossible to know the accurate extent of disease, both surgical and clinical outcome measures need to be used as end points. For example, without pathologic confirmation, imaging could overstage or understage tumor size and local invasion, or nodal disease could be inaccurately determined. If tumor is treated with radiation therapy or systemic therapy, we may not know how accurate the imaging staging is unless clinical outcomes are used to compare modalities. The prospective imaging trials, therefore, must include surgeons, radiation therapists, and oncologists in addition to radiologists.

To understand postoperative changes in the larynx and hypopharynx, the radiologist will need to be familiar with new reconstructive flap techniques, innovative methods to reconstruct the HP mucosal surface, and the expected appearance after TORS for small T1 and T2 HP resections.

Radiologists also need to stay current and abreast in developments in molecular-targeted therapy, which will have a significant effect on tumor metabolic activity and thus imaging appearance of HP SCC on conventional modalities. Neuroradiologists are already experienced with incorporating new knowledge about treatment in imaging interpretations. In neurooncology, changes in size and enhancement of glioblastoma multiforme on brain MRI can no longer be used to imply tumor progression or regression, but may be due to "pseudoprogression" or "pseudoregression."²² Interpreting brain tumor imaging can no longer be performed without knowing details of treatment: whether the patient is on steroids, which chemotherapeutic agents were used and at what doses, and how the patient is doing clinically. As new CRT regimens are developed for SCC of the hypopharynx, we will also need to know the

treatment details to recognize toxicities and tumor recurrence.

In summary, to accurately interpret pretreatment and posttreatment imaging in patients with HP SCC, one must understand the complex anatomy of this part of the aerodigestive system, recognize common patterns of spread, and know the pitfalls in imaging. With this infrastructure and foundation, even the most complex new developments will make sense.

REFERENCES

1. Surveillance Epidemiology and End Results (SEER) cancer statistics review. 1975-2008. Available at: <http://seer.cancer.gov>. Accessed March, 2012.
2. Karsai S, Abel U, Roesch-Ely M, et al. Comparison of p16INK4a expression with p53 alterations in head and neck cancer by tissue microarray analysis. *J Pathol* 2007;211:314–22.
3. Somers KD, Merrick MA, Lopez MF, et al. Frequent p53 mutations in head and neck cancer. *Cancer Res* 1992;52(21):5997–6000.
4. Boscolo-Rizzo P, Da Mosto MC, Fuson R, et al. HPV-16 E6 L83V variant in squamous cell carcinomas of the upper aerodigestive tract. *J Cancer Res Clin Oncol* 2009;135(4):559–66.
5. Rodrigo JP, Gonzalez MV, Lazo PS, et al. Genetic alterations in squamous cell carcinomas of the hypopharynx with correlations to clinicopathological features. *Oral Oncol* 2002;38:357–63.
6. Song L-M. Plummer-Vinson syndrome. Medscape reference. Available at: <http://emedicine.medscape.com/article/187341-overview#a0199>. Accessed March, 2012.
7. Edge SB, Byrd DR, Compton CC, et al. Editorial Board. *AJCC cancer staging manual*. 7th edition. Chicago: Springer; 2010. p. 41–56.
8. Thabet HM, Sessions DG, Gado MY, et al. Comparison of clinical evaluation and computed tomographic diagnostic accuracy for tumor of the larynx and hypopharynx. *Laryngoscope* 1996;106:589–94.
9. Katilmis H, Ozturkcan S, Ozdemir I, et al. A clinicopathological study of laryngeal and hypopharyngeal carcinoma: correlation of cord-arytenoid mobility with histopathologic involvement. *Otolaryngol Head Neck Surg* 2007;136:291–5.
10. Chan SC, Wang HM, Yen TC, et al. ¹⁸F-FDG PET/CT and 3.0 T whole-body MRI for the detection of distant metastases and second primary tumours in patients with untreated oropharyngeal/hypopharyngeal carcinoma: a comparative study. *Eur J Nucl Med Mol Imaging* 2011;38:1607–19.
11. Gourin CG, Terris DJ. Carcinoma of the hypopharynx. *Surg Oncol Clin N Am* 2004;13:81–98.
12. Ho CM, Lam KH, Wei WI, et al. Squamous cell carcinoma of the hypopharynx—analysis of treatment results. *Head Neck* 1993;15:405–12.
13. Ho CM, Ng WF, Lam KH, et al. Submucosal tumor extension in hypopharyngeal cancer. *Arch Otolaryngol Head Neck Surg* 1997;123:959–65.
14. Hsu WC, Loevner LA, Karpati R, et al. Accuracy of magnetic resonance imaging in predicting absence of fixation of head and neck cancer to the prevertebral space. *Head Neck* 2005;27:95–100.
15. Loevner LA, Ott IL, Yousem DM, et al. Neoplastic fixation to the prevertebral compartment by squamous cell carcinoma of the head and neck. *AJR Am J Roentgenol* 1998;170:1389–94.
16. Schmalfuss IM, Mancuso AA, Tart RP. Postcricoid region and cervical esophagus: normal appearance at CT and MR Imaging. *Radiology* 2000;213:237–46.
17. Hoffman HT, Karnell LH, Shah JP, et al. Hypopharyngeal cancer patient care evaluation. *Laryngoscope* 1997;107:1005–17.
18. Wei WI. The dilemma of treating hypopharyngeal carcinoma: more or less. *Arch Otolaryngol Head Neck Surg* 2002;128:229–32.
19. Pfister DG, Hu KS, Lefebvre JL. Chapter 17. Cancer of the hypopharynx and cervical esophagus. In: Harrison LB, Sessions RB, Hong WK, editors. *Head and neck cancer*. 3rd edition. Philadelphia: Lippincott Williams & Wilkins; 2009. p. 397–435.
20. Genden EM, Desai S, Sung CK. Transoral robotic surgery for the management of head and neck cancer: a preliminary experience. *Head Neck* 2009;31:283–9.
21. Machiels JP, Schmitz S. Molecular-targeted therapy of head and neck squamous cell carcinoma: beyond cetuximab-based therapy. *Curr Opin Oncol* 2011;23:241–8.
22. Fatterpekar GM, Galheigo D, Narayana A, et al. Treatment-related change versus tumor recurrence in high-grade gliomas: a diagnostic conundrum—use of dynamic susceptibility contrast-enhanced (DSC) perfusion MRI. *AJR Am J Roentgenol* 2012;198:19–26.