



Thickening of Small Bowel Folds

Ronald L. Eisenberg¹

Thickening of small bowel folds (> 3 mm) can be caused by any process that increases the volume of fluid or cells in the submucosal or mucosal region (Table 1). The critical diagnostic observation is whether the general pattern of the thickening is regular or irregular. *Regular* thickening of small bowel folds, which are perpendicular to the bowel lumen and parallel to neighboring folds, is usually caused by fluid, generally hemorrhage or edema (Fig. 1). *Irregular* thickening of small bowel folds is produced by an extensive group of diseases that infiltrate the bowel wall with deposition of cells or other amorphous material. In these conditions, the folds are distorted, not perpendicular to the lumen, and are angled with respect to neighboring folds (Fig. 2).

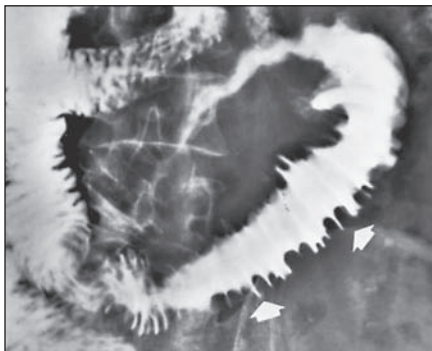


Fig. 1—Regular thickening of small bowel folds (arrows) related to hemorrhage.




Fig. 2—Irregular thickening of small bowel folds in Whipple disease.

Keywords: irregular thickening, regular thickening, small bowel folds

DOI:10.2214/AJR.09.2762

Received March 17, 2009; accepted after revision May 13, 2009.

All figures reprinted with permission from Eisenberg RL. *Gastrointestinal radiology: a pattern approach*, 4th ed. Philadelphia, PA: Lippincott Williams & Wilkins, 2002.

¹Department of Radiology, Beth Israel Deaconess Medical Center, 330 Brookline Ave., Boston, MA 02215. Address correspondence to R. L. Eisenberg (rleisenb@bidmc.harvard.edu).

WEB

This is a Web exclusive article.

AJR 2009; 193:W1–W6

0361–803X/09/1931–W1

© American Roentgen Ray Society

Regular Thickening

Any cause of bleeding into the bowel wall can lead to uniform, regular thickening of small bowel folds with sharply delineated margins (Fig. 1). The parallel arrangement produces a symmetric, spikelike configuration simulating a stack of coins or picket fence. There usually is segmental involvement, especially of the jejunum. Concomitant bleeding into the mesentery often results in separation of bowel loops (Fig. 3) and even an eccentric mass simulating malignancy. Causes of this pattern include anticoagulant therapy; ischemic bowel disease; vasculitis such as connective tissue diseases (Fig. 4); and Schönlein-Henoch purpura, hemophilia, and coagulation defects secondary to other diseases such as hypoprothrombinemia, leukemia, multiple myeloma, lymphoma, and metastatic carcinoma (Fig. 5).

Intestinal edema produces generalized regular thickening of the small bowel. The most common cause is hypoproteinemia secondary to cirrhosis (Fig. 6), nephrotic syndrome, or protein-losing enteropathy. A similar pattern can be produced by lymphatic blockage, especially tumor infiltration, and angioneurotic edema, which tends to be episodic and more localized.

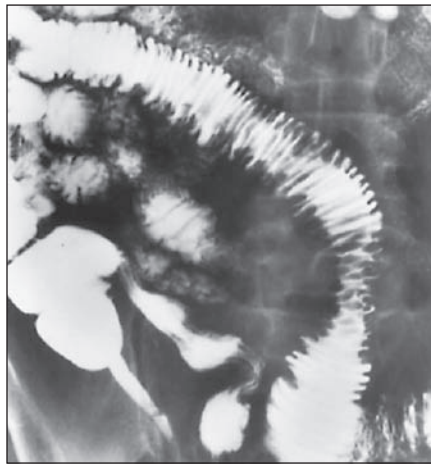


Fig. 3—Hemorrhage. Regular thickening of small bowel folds with separation of bowel loops due to bleeding into bowel wall and mesentery.



Fig. 4—Systemic lupus erythematosus. Ischemic and hemorrhagic changes in bowel wall produce radiographic pattern of regular thickening of small bowel folds.

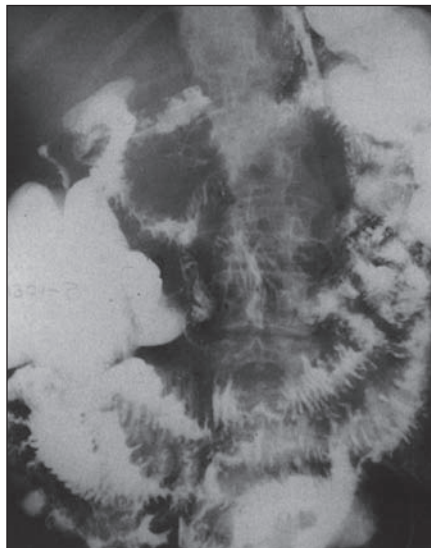


Fig. 5—Lymphatic blockage due to diffuse liver metastases. Obstruction of portal blood flow causes regular thickening of small bowel folds.

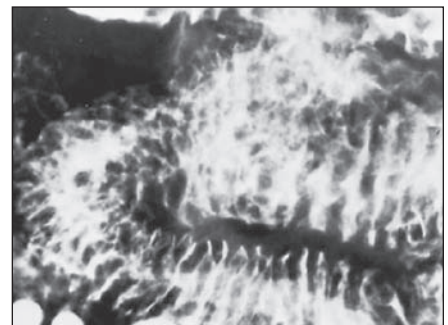


Fig. 6—Intestinal edema due to hypoproteinemia secondary to cirrhosis. Regular thickening of small bowel folds.

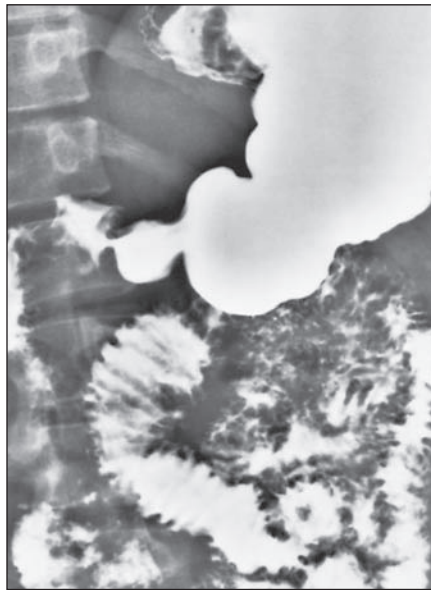Thickening of Small Bowel Folds

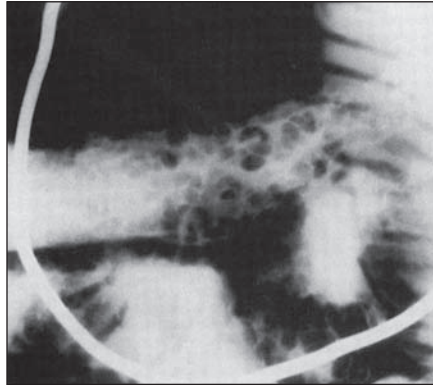
Irregular Thickening

Infiltrative processes causing irregular thickening of small bowel folds may be due to an infection, nonspecific inflammation, or malignancy. Distinguishing among the many diseases that cause this pattern requires an analysis of the site of the lesion, associated radiographic findings, and clinical history. For example, the presence of malabsorption syndrome and extraintestinal symptoms (arthritis, fever, lymphadenopathy) suggests Whipple disease (Fig. 2), which on histologic examination shows characteristic p-aminosalicylic acid (PAS)-positive granules in the lamina propria. A history of travel to an endemic area (e.g., St. Petersburg, India, the Rocky Mountains of Colorado) raises the suspicion of giardiasis (Fig. 7). Irregular thickening of the terminal ileum, skip lesions, string sign, narrowing, separation of bowel loops, and fistula formation are typical manifestations of Crohn disease (Fig. 8). Concomitant involvement of the stomach is a hallmark of eosinophilic gastroenteritis (Fig. 9). Other inflammatory and deposition diseases that may present with irregular thickening of small bowel folds include amyloidosis (Fig. 10), mastocytosis, strongyloidiasis, *Yersinia* enterocolitis, and typhoid fever.


As in almost every pattern involving the small bowel, it is necessary to think of lymphoma (Fig. 11), which may be primary or secondary (about 25% of patients with lymphoma have small bowel involvement at autopsy). Other small bowel findings of this "great mimicker" include isolated or multifocal polypoid masses (Fig. 12), circumferential infiltration of bowel wall, and neoplastic involvement of adjacent mesentery and lymph nodes.

Fig. 7—Giardiasis. Irregular thickening of folds most prominently involves proximal small bowel.

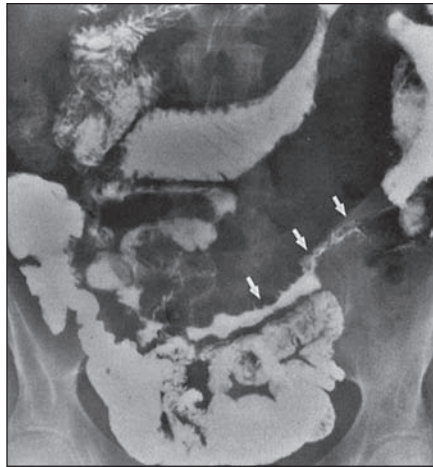




A



B



C

Fig. 8—Crohn disease.

A, Cobblestone appearance is produced by transverse and longitudinal ulcerations separating islands of thickened mucosa and submucosa.

B, Characteristic skip lesions (arrows) with widely separated areas of disease.

C, String sign (arrows) produced by severe segmental narrowing in jejunum.

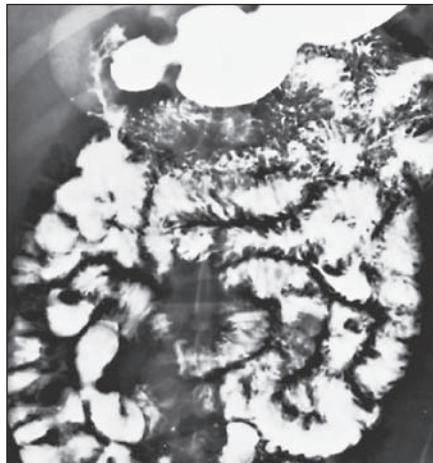


Fig. 9—Eosinophilic gastroenteritis. Irregular thickening of folds involves jejunum. In this case there is no concomitant involvement of stomach.

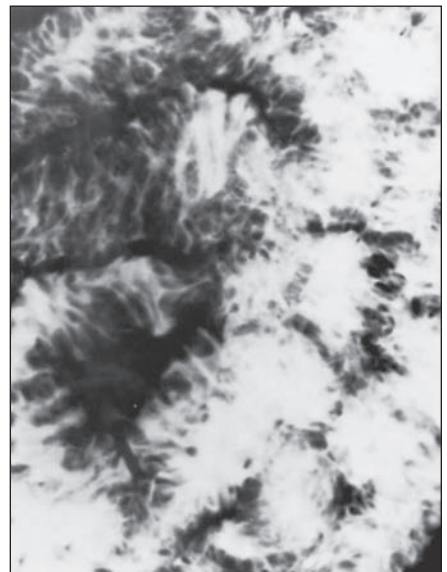


Fig. 10—Amyloidosis.

Thickening of Small Bowel Folds

Fig. 11—Lymphoma. In addition to diffuse, irregular thickening of small bowel folds, there is mesenteric involvement causing separation of bowel loops.

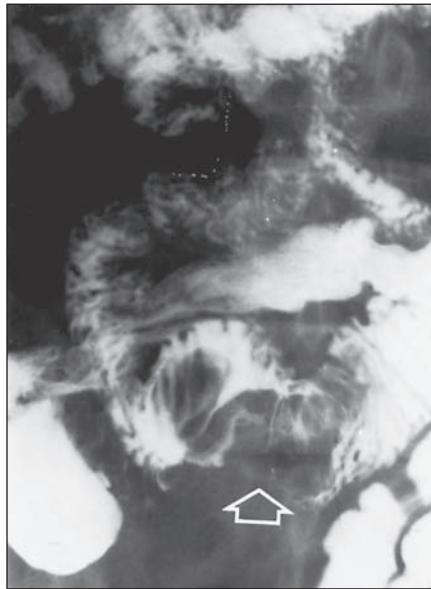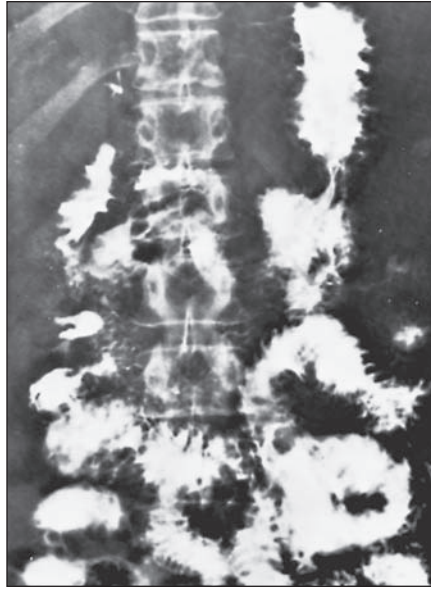


Fig. 12—Lymphoma. Large, bulky, irregular lesion (arrow).

TABLE I: Causes of Regular and Irregular Thickening of Small Bowel Folds

Regular
Hemorrhage into bowel wall
Anticoagulant therapy
Ischemic bowel disease
Vasculitis
Hemophilia
Coagulation defects secondary to other diseases
Intestinal edema
Cirrhosis
Nephrotic syndrome
Protein-losing enteropathy
Lymphatic blockage
Angioneurotic edema
Irregular
Infection
Giardiasis
Tuberculosis
Histoplasmosis
Strongyloidiasis
<i>Yersinia</i> enterocolitis
Typhoid fever
Nonspecific inflammation/deposition disorders
Whipple disease
Amyloidosis
Eosinophilic enteritis
Crohn disease
Mastocytosis
Malignancy
Lymphoma

Suggested Reading

1. Clemett AR, Marshak RH. Whipple's disease: roentgen features and differential diagnosis. *Radiol Clin North Am* 1969; 1:105
2. Marshak RH, Khilnani MT, Eliasoph J, et al. Intestinal edema. *AJR* 1967; 101:379
3. Rubesin SF, Rubin RA, Herlinger H. Small bowel malabsorption: clinical and radiological perspectives. *Radiology* 1992; 184:297
4. Wiot JF. Intramural small intestinal hemorrhage: a differential diagnosis. *Semin Roentgenol* 1966; 1:219