

Biventricular implantable cardiac defibrillator in dextrocardia with situs viscerum inversus

Giuseppina Belotti, Antonio Pitì, Antonio Curnis*

Cardiology Department, Hospital of Treviglio, Treviglio (BG), *Cardiology Department, Spedali Civili, Brescia, Italy

Key words:
Implantable
cardioverter-
defibrillator; Pacing.

A case of dextrocardia in situs viscerum inversus, prior myocardial infarction, dilated cardiomyopathy with severe left ventricular systolic dysfunction, ventricular tachyarrhythmias and recurrent episodes of heart failure is described. Coronary artery bypass grafting for multivessel coronary artery disease had been previously performed; coronary and graft anatomy evaluation excluded the possibility of any further revascularization procedure. Electrocardiography showed left bundle branch block and echocardiography revealed significant interventricular mechanical dyssynchrony. After a complete vascular and cardiac anatomy evaluation, the patient was submitted to biventricular cardiac defibrillator implantation via a right approach and using conventional fluoroscopic equipment.

(Ital Heart J 2004; 5 (7): 559-562)

© 2004 CEPI Srl

Received February 11, 2004; revision received May 18, 2004; accepted June 8, 2004.

Address:

Dr.ssa Giuseppina Belotti

Divisione
di Cardiologia
Ospedale di Treviglio
Piazza Ospedale, 1
24047 Treviglio (BG)
E-mail:
giuseppina.belotti@tin.it

Introduction

Biventricular pacing in dilated cardiomyopathy with severe left ventricular (LV) systolic dysfunction, electromechanical delay and chronic heart failure (HF) despite optimal drug therapy, has been demonstrated in randomized clinical studies to improve quality of life¹⁻³, functional class¹⁻³, exercise capability¹⁻⁵, and echocardiographic parameters¹⁻⁴. Recent trials⁶⁻⁸ showed that mortality in patients with ischemic heart disease and a low ejection fraction was significantly reduced using an implantable cardioverter-defibrillator (ICD). The effect of biventricular pacing and biventricular ICD on mortality is under investigation even for nonischemic dilated cardiomyopathy with HF^{9,10}. Dextrocardia is a congenital heart malposition in which the cardiac apex is located in the right side of the chest; the identification of the viscerotrial situs, ventricular morphology and function and great artery relationship by means of echocardiography and angiography or nuclear magnetic resonance completely defines this anatomical situation¹¹. Situs viscerum inversus is a mirror image of the normal, occurring in approximately 2 out of 10 000 live births¹² and could be associated with other abnormalities¹³. Dextrocardia has been described in a few cases of conventional cardiac pacing¹⁴⁻¹⁶; however, to date no cases of biventricular ICD implantation have been described in the literature.

Case report

A 65-year-old male was evaluated in our Department. He had a previous diagnosis of dextrocardia in situs viscerum inversus; he had suffered from inferior myocardial infarction and, because of multivessel disease, in 1983 he underwent coronary artery bypass grafting. Subsequently, he had no more angina, but he suffered from recurrent HF episodes, despite optimal drug therapy, with LV dilation and an impaired systolic function at echocardiography. Furthermore, he had been placed on amiodarone treatment because of nonsustained ventricular tachycardia during 24-hour Holter monitoring. Electrocardiography, performed with a setting suitable for dextrocardia, showed sinus rhythm and a wide QRS due to left bundle branch block. Two-dimensional echocardiography confirmed dextrocardia with a morphologically and anteriorly located right ventricle with a normal tricuspid valve, a left ventricle morphologically and functionally showing dilation and severe systolic dysfunction (ejection fraction 25%), with a normal aortic valve and a morphologically abnormal mitral valve, with moderate regurgitation. An interventricular mechanical dyssynchrony of 50 ms was calculated. Myocardial tomoscintigraphy confirmed the viability of the anterior, posterior and lateral LV walls, a fixed perfusion defect of the inferior wall and the absence of re-

versible defects. Coronary angiography revealed a patent venous graft on the left anterior descending artery and the occlusion of venous grafts on the closed circumflex and right coronary vessels. The coronary sinus was not clearly visible during the venous phase of coronary angiography; only a light smoke seemed to localize its ostium at the midseptal region of the right atrium. During the same procedure, venous angiography documented a left-sided inferior vena cava, a right-sided brachiocephalic trunk and a left subclavian vein flowing into a left-sided superior vena cava. Contrast computed tomography scan confirmed both the presence of dextrocardia in situs viscerum inversus and the venous system anatomy and clarified the relations of the great arteries with the aorta toward the left, situated to the left of the pulmonary artery. In view of the coronary anatomy and the results of myocardial tomoscintigraphy, the hypothesis of a new revascularization procedure was excluded and a biventricular ICD was proposed. Having obtained the patient's informed consent, we performed this procedure via a right approach; anteroposterior, 30° left anterior oblique and 40° right anterior oblique fluoroscopic images were obtained. A two-coil defibrillation lead was introduced via the right cephalic vein through the right-sided brachiocephalic trunk and the left-sided superior vena cava into the right ventricle, along the interventricular septum. An atrial lead for the right appendage and a long guide catheter for the coronary sinus were introduced through the right subclavian vein. Having cannulated the ostium, we performed coronary sinus angiography (Fig. 1); a vein on the LV lateral wall was reached by a wire (Balance MiddleWeight, Guidant, St. Paul, MN, USA) and an over-the-wire bipolar lead (Easytrak II, Guidant) was advanced. During removal of the guiding catheter, an unfavorable curve of the lead in the right atrium was noticed and toward the end of this phase, the lead fell backward down along the coro-

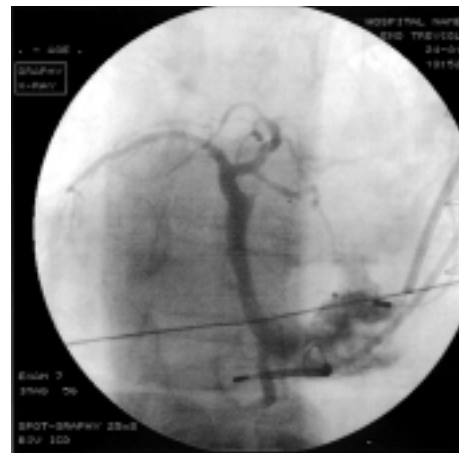


Figure 1. The target lateral vein of the coronary sinus at angiography, 40° right anterior oblique view.

nary sinus as far as the right atrium. The coronary sinus was cannulated again, the lead was repositioned and a stiffer wire (Iron Man, Guidant) was used to advance the lead to a more forward position in the vein; the guiding catheter was manipulated during extraction avoiding the unfavorable curve of the lead in the atrium and then the wire was removed without further lead dislocation (Fig. 2). The device (Renewal II, Guidant) was connected and during general anesthesia (i.v. propofol) ventricular fibrillation was provoked by delivery of a shock in T wave; the device correctly recognized and successfully treated the arrhythmia by a first 17 J shock. Electrocardiography showed a decrease in the QRS width, from 200 ms during sinus rhythm to 140 ms during biventricular pacing (Fig. 3). The subsequent clinical course was uneventful; at pre-discharge chest X-ray (Fig. 4) the position of the leads was found to be stable and the device showed stable electrical parameters. Ambulatory evaluation performed 10 days after

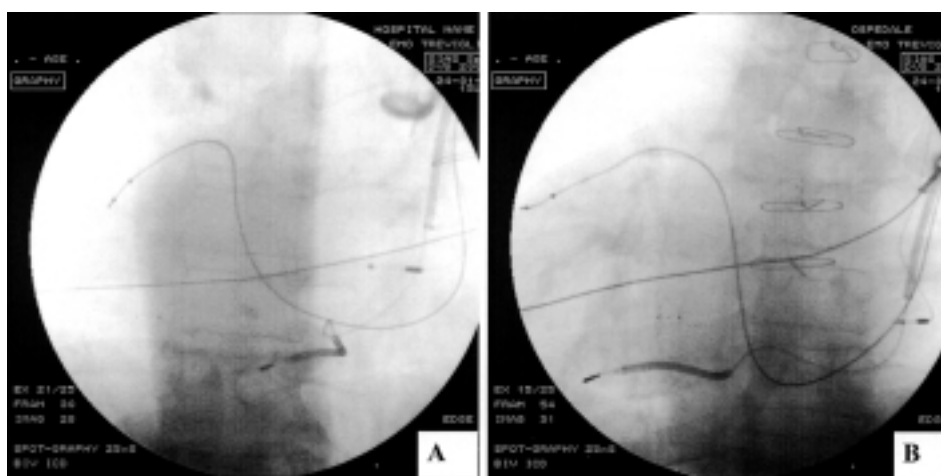

Figure 2. Final position of the lead for left ventricular pacing in the lateral vein of the coronary sinus 40° right anterior oblique view (A) and 30° left anterior oblique view (B).

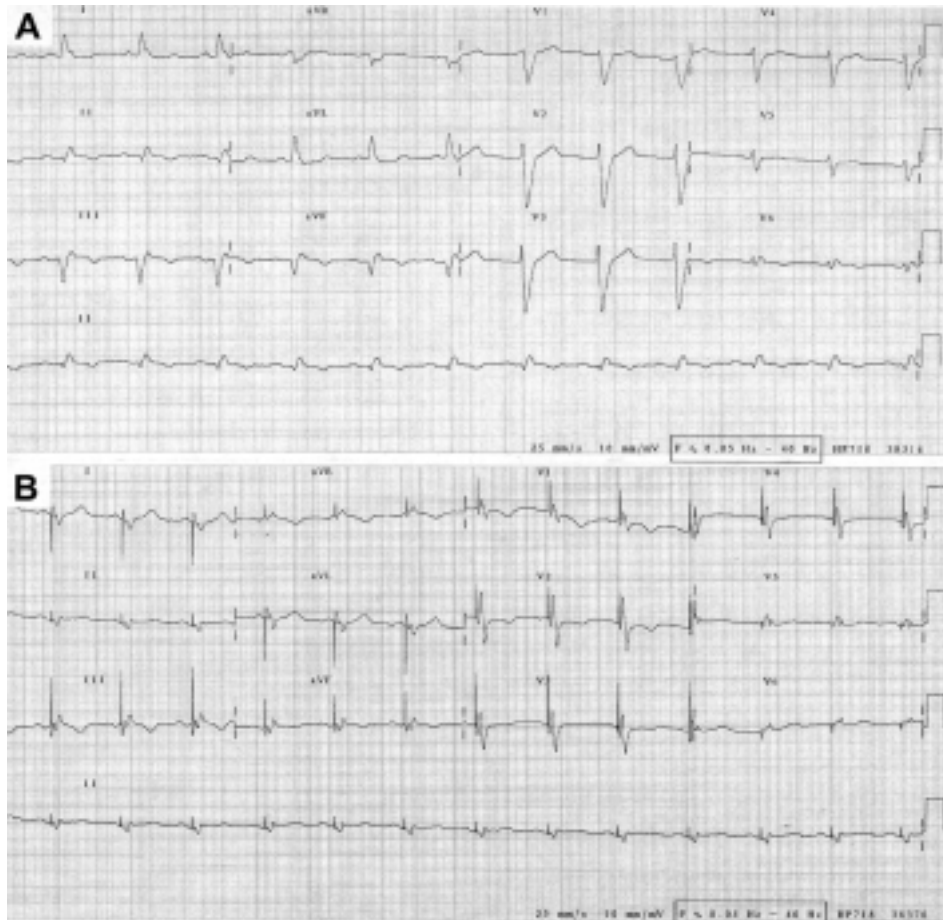


Figure 3. A: electrocardiogram before biventricular pacing showing left bundle branch block and a wide QRS (maximal duration 200 ms). B: electrocardiogram during atrial-synchronized biventricular pacing with a decrease in the width of the QRS (maximal duration 140 ms).

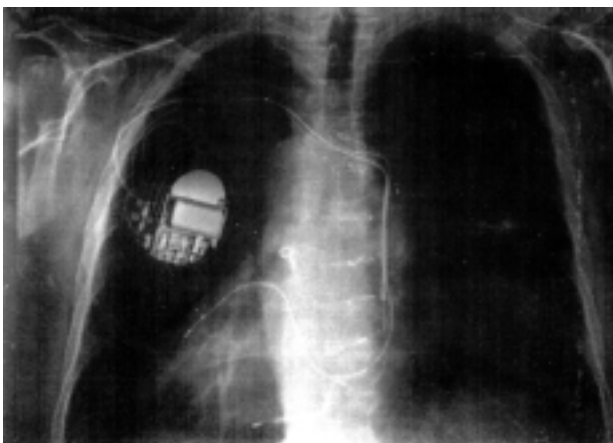


Figure 4. Pre-discharge chest X-ray showing dextrocardia and the final position of all the leads.

discharge, revealed an improvement in NYHA class (from III to II) and in LV systolic function (ejection fraction 35%), with interventricular mechanical resynchronization at echocardiography.

Discussion

Biventricular pacing is a more difficult procedure than conventional pacing because dilation of the right chambers and the variable anatomy of the coronary sinus result in a more difficult cannulation and placement of the lead for LV pacing. The reported success rate is 85% or higher^{17,18} and the target mid lateral or posterolateral wall position may be reached in about 75% of patients, using various technologies¹⁹. Although the reported complications in centers with extensive experience are generally rare, these are poorly tolerated in hemodynamically unstable HF patients¹⁹ and they include coronary sinus or cardiac vein dissection and perforation that may result in cardiac tamponade. Our patient had recurrent HF episodes despite optimal therapy, without any chance of further revascularization; therefore, biventricular pacing was indicated and an ICD was positioned because of previous myocardial infarction, ejection fraction < 30% and nonsustained ventricular tachycardia. Furthermore, our patient had dextrocardia with situs viscerum inversus; therefore, before implant, both the venous vascular bed and cardiac anatomy were accurately evaluated by

means of echocardiography, computed tomography and angiography. It is important to completely evaluate the anatomy before the procedure as the often unstable hemodynamic conditions could render an already difficult conventional pacing implant in such a HF patient even more problematic. The complexity of a biventricular procedure in itself necessitating more time in an anatomically normal patient suffering from HF, might make LV pacing critical or impossible in case of an unknown cardiac and vascular malposition. Furthermore, some technical problems related to the presence of dextrocardia, such as the most adequate approach and setting of the fluoroscopic images, have been reported. A left approach is obligatory for biventricular pacing as it facilitates both coronary sinus ostium cannulation and lead location in one of its veins. However, in situs viscerum inversus, the cardiac morphology and vascular bed are a mirror image of the normal and the shape of the systems available from industries for LV pacing is less suitable with a left approach both for a right-sided coronary sinus and for a left subclavian vein flowing into a left superior vena cava at an acute angle. Therefore, in this specific anatomical condition, a right approach is theoretically the most favorable.

On the other hand, the right implantation of an ICD in patients with dextrocardia might also be associated with lower defibrillation thresholds as the heart is better enclosed by the shock wave with a right pectoral ICD device (plus proximal coil) toward the distal defibrillation lead coil.

Furthermore, real-time fluoroscopy resulted more feasible and useful than fluoroscopy inversion, the latter allowing us to see the usual images as in a heart without malposition. In fact, in dextrocardia the inverted fluoroscopic images look more familiar because they are similar to those obtained in case of a normal anatomy, but they do not fit in with the actual anatomy and hamper the coordination of the movements of the operator's hands. The technical problem of recurrent dislocation of the lead for LV pacing might also occur in an anatomically normal heart; we in fact encountered this problem and resolved it by further advancement of the lead with a stiffer wire to a more distal and stable site and by avoiding the occurrence, during guiding catheter removal, of abnormal curves of the lead that favor its dislodgment.

References

1. Abraham WT, Fisher WG, Smith AL, et al, for the MIRACLE Study Group. Multicenter InSync Randomized Clinical Evaluation. Cardiac resynchronization in chronic heart failure. *N Engl J Med* 2002; 346: 1845-53.
2. Cazeau S, Leclercq C, Lavergne T, et al, for the Multisite Stimulation In Cardiomyopathies (MUSTIC) Study Investigators. Effects of multisite biventricular pacing in patients with heart failure and intraventricular conduction delay. *N Engl J Med* 2001; 344: 873-80.

3. Linde C, Leclercq C, Rex S, et al. Long-term benefits of biventricular pacing in congestive heart failure: results from the Multisite Stimulation In Cardiomyopathy (MUSTIC) Study. *J Am Coll Cardiol* 2002; 40: 111-8.
4. Saxon LA, De Marco T, Schafer J, Chatterjee K, Kumar UN, Foster E, for the VIGOR Congestive Heart Failure Investigators. Effects of long-term biventricular stimulation for resynchronization on echocardiographic measures of remodeling. *Circulation* 2002; 105: 1304-10.
5. Auricchio A, Stellbrink C, Sack S, et al, for the PATH-CHF Study Group. Long-term clinical effect of hemodynamically optimized cardiac resynchronization therapy in patients with heart failure and ventricular conduction delay. *J Am Coll Cardiol* 2002; 39: 1895-8.
6. Moss AJ, Hall WJ, Cannom WS, et al. Improved survival with an implanted defibrillator in patients with coronary disease at high risk for ventricular arrhythmia. Multicenter Automatic Defibrillator Implantation Trial Investigators. *N Engl J Med* 1996; 335: 1933-40.
7. Buxton AE, Lee KL, Fisher JD, Josephson ME, Prystowsky EN, Hafley G. A randomized study of the prevention of sudden death in patients with coronary artery disease. Multicenter UnSustained Tachycardia Trial Investigators. *N Engl J Med* 1999; 341: 1882-90.
8. Moss AJ, Zareba W, Hal WJ, et al, for the Multicenter Automatic Defibrillator Implantation Trial II Investigators. Prophylactic implantation of a defibrillator in patients with myocardial infarction and reduced ejection fraction. *N Engl J Med* 2002; 346: 877-83.
9. Bristow MR, Feldman AM, Saxon LA, for the COMPANION Steering Committee and COMPANION Clinical Investigators. Heart failure management using implantable devices for ventricular resynchronization: comparison of medical therapy, pacing, and defibrillation in chronic heart failure (COMPANION) trial. *J Card Fail* 2000; 6: 276-85.
10. Cleland JGF, Daubert JC, Erdmann E, et al, on behalf of the CARE-HF Study Steering Committee and Investigators. The CARE-HF study (CArdiac RESynchronisation in Heart Failure study): rationale, design and end-points. *Eur J Heart Fail* 2001; 3: 481-9.
11. Freedman WF. Congenital heart disease in infancy and childhood. In: Braunwald E, ed. Heart disease. A textbook of cardiovascular medicine. Philadelphia, PA: WB Saunders, 1988: 896-1022.
12. Sands SS, Taylor JF. Prescreen evaluation of situs inversus patients. *Int Surg* 2001; 86: 254-8.
13. Amor DJ, Craig JE. Situs inversus totalis and congenital hypoglossia. *Clin Dysmorphol* 2001; 10: 47-50.
14. Garcia OL, Metha AV, Pickoff AS, et al. Left isomerism and complete atrioventricular block: a report of six cases. *Am J Cardiol* 1981; 48: 1103-7.
15. Badui E, Lepe L, Solorio S, Sanchez H, Enciso R, Garcia P. Heart block in dextrocardia with situs inversus. A case report. *Angiology* 1995; 46: 537-40.
16. Brito MR, Miranda CE, Barros VC, Castro LR, Borges MH. Heart block in dextrocardia and situs inversus: a case report. *Ann Noninvasive Electrocardiol* 2001; 6: 369-72.
17. Pürerfellner H, Nesser HJ, Winter S, et al, for the EASYTRAK Clinical Investigation Study Group and the European EASYTRAK Registry. Transvenous left ventricular lead implantation with the EASYTRAK lead system: the European experience. *Am J Cardiol* 2000; 86 (Suppl): 157K-164K.
18. Ricci R, Ansalone G, Toscono S, et al. Cardiac resynchronization: materials, technique and results. The InSync Italian Registry. *Eur Heart J* 2000; 2 (Suppl J): J6-J15.
19. Leclercq C, Kass DA. Retiming the failing heart: principles and current clinical status of cardiac resynchronization. *J Am Coll Cardiol* 2002; 39: 194-201.